Name [redacted]

Plant: Millington, N.J.

No. 28318

Reading Date 2/19/72

Interpretation of Single roentgenogram of chest

taken on 2/9/72

No significant abnormality seen.

GEORGE W. WRIGHT, M. D.
Saint Luke's Hospital
11311 Shaker Boulevard
Cleveland, Ohio 44104

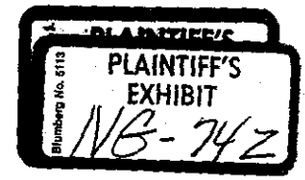

131132

Sept. List

Name

Plant: Millington, N.J.

No. 28318

Reading Date 11-23-70

Interpretation of single roentgenogram of chest

taken on 10-28-70

Since 1961, there has been a slight increase in the bronchovascular markings. The exposure and work habits of this man should be reviewed carefully.

GEORGE W. WRIGHT, M. D.
Saint Luke's Hospital
11311 Shaker Boulevard
Cleveland, Ohio 44104

Name

Plant: Millington, New Jersey

No. 28318

Reading Date 7-5-68

Interpretation of single roentgenogram of chest

taken on 6-28-68

No significant abnormality seen.

The current film appearance does not fit the one described in 1966. Did I have the wrong film in 1966?

GEORGE W. WRIGHT, M. D.
Saint Luke's Hospital
11311 Shaker Boulevard
Cleveland, Ohio 44104

131341

Name _____ Plant: Millington, N.J.

No. 28318 Reading Date 5-31-66

Interpretation of single roentgenogram of chest

taken on 5-16-66

The bronchovascular markings are rather prominent with slight beading in some areas at the bases. Scattered, tiny calcific densities in the lower one-half of each lung are also seen. While it seems almost certain that in a man this young (25) these appearances represent a healed phase of some earlier infection such as histoplasmosis, one would like a complete occupational history to further evaluate this film.

PLEASE HANDLE AS DISCUSSED PER PHONE CALL 6/2/66.

F. H. Z.

GEORGE W. WRIGHT, M. D.
Saint Luke's Hospital
11311 Shaker Boulevard
Cleveland, Ohio 44104

Name

Plant: Millington, N.J.

No. 28318

Reading Date 11/18/64

Interpretation of single roentgenogram of chest

taken on 9/22/64

No significant abnormality seen.

GEORGE W. WRIGHT, M. D.
Saint Luke's Hospital
11311 Shaker Boulevard
Cleveland 4, Ohio

13136

Name

Plant: Millington, N. J.

No. 100-62

Reading Date: 7/6/62

Interpretation of single roentgenogram of chest

taken on 6/27/62

No significant abnormality seen.

GEORGE W. WRIGHT, M. D.
Saint Luke's Hospital
11311 Shaker Boulevard
Cleveland 4, Ohio

NGC

Name

Plant: Millington, NJ

No. 523

Reading Date: 4/14/61

Interpretation of single roentgenogram of chest

taken on 3/27/61 compared with taken on

No significant abnormality seen.

GEORGE W. WRIGHT, M. D.
Saint Luke's Hospital
11311 Shaker Boulevard
Cleveland 4, Ohio

13135

NAME [redacted] DATE 10-27-69

ADDRESS NATIONAL GYPSUM AGE 29 DR. Chrobok

8 3 / 1 8

October 28, 1969

J.M.Chrobok,D.O.
1390 Valley Road
Stirling,New Jersey

Re:

Dear Dr. Chrobok:

LEFT FIFTH FINGER

Appropriate views were obtained.

A fracture of the proximal end of the first phalanx of the left fifth finger is demonstrated; the alignment and apposition of the fragments is satisfactory.

Thank you for referring to us.

Sincerely yours,

Enrico C. Funaro, M.D.

ECF/sn
Xray No 28318

131139

Name

Plant Millington, N.J.

No. 28318

Reading Date 2/19/72

Interpretation of Single roentgenogram of chest

taken on 2/9/72

No significant abnormality seen.

GEORGE W. WRIGHT, M. D.
Saint Luke's Hospital
11311 Shaker Boulevard
Cleveland, Ohio 44104

131-15

Name

Plant: Millington, N.J.

No. 28318

Reading Date 11-23-70

Interpretation of single roentgenogram of chest

taken on 10-28-70

Since 1961, there has been a slight increase in the bronchovascular markings. The exposure and work habits of this man should be reviewed carefully.

GEORGE W. WRIGHT, M. D.
Saint Luke's Hospital
11311 Shaker Boulevard
Cleveland, Ohio 44104

131-16

Name

Plant: Millington, New Jersey

No. 28318

Reading Date 7-3-68

Interpretation of single roentgenogram of chest

taken on 6-28-68

No significant abnormality seen.

The current film appperance does not fit the one described in 1966. Did I have the wrong film in 1966?

GEORGE W. WRIGHT, M. D.
Saint Luke's Hospital
11311 Shaker Boulevard
Cleveland, Ohio 44104

131 17

Name

Plant: Millington, N.J.

No. 28318

Reading Date 5-31-66

Interpretation of single roentgenogram of chest

taken on 5-16-66

The bronchovascular markings are rather prominent with slight beading in some areas at the bases. Scattered, tiny calcific densities in the lower one-half of each lung are also seen. While it seems almost certain that in a man this young (25) these appearances represent a healed phase of some earlier infection such as histoplasmosis, one would like a complete occupational history to further evaluate this film.

PLEASE HANDLE AS DISCUSSED PER PHONE CALL 6/2/66.

F. H. Z.

GEORGE W. WRIGHT, M. D.
Saint Luke's Hospital
11311 Shaker Boulevard
Cleveland, Ohio 44104

31-15

NGC

Name Plant: Millington, NJ

No. 523 Reading Date: 4/14/61

Interpretation of single roentgenogram of chest

taken on 3/27/61 compared with taken on

No significant abnormality seen.

GEORGE W. WRIGHT, M. D.
Saint Luke's Hospital
11311 Shaker Boulevard
Cleveland 4, Ohio

131.19

Name

Plant: Millington, N. J.

No. 100-62

Reading Date: 7/6/62

Interpretation of single roentgenogram of chest

taken on 6/27/62

No significant abnormality seen.

GEORGE W. WRIGHT, M. D.
Saint Luke's Hospital
11311 Shaker Boulevard
Cleveland 4, Ohio

13151

Name

No. 28318

Interpretation of single roentgenogram of chest

taken on 9/22/64

Plant: Millington, N.J.

Reading Date 11/18/64

No significant abnormality seen.

GEORGE W. WRIGHT, M. D.
Saint Luke's Hospital
11311 Shaker Boulevard
Cleveland 4, Ohio

13151

NATIONAL GYPSUM COMPANY

PLANT, OFFICE, SALES DISTRICT ~~Millington-Hour~~

PHYSICAL EXAMINATION RECORD

DATE 9-30-65

☐ PRE-EMPLOYMENT ☐ REINSTATEMENT ☐ PERIODIC HEALTH

NAME _____ ADDRESS _____

_ OF BIRTH 12/19/40 (AGE 25) ☒ SINGLE ☐ MARRIED OTHER _____

LAST EMPLOYMENT National Gypsum Company

HEIGHT	DISFIGUREMENT – FACE, HEAD OR NECK	VISION-DISTANT	VISION-NEAR	WASSERMAN Hb:
6'	no gross defects			To lab
WEIGHT 170		C.R.E. 20/20	20/	URINALYSIS
		U.L.E. 20/20	20/	SUGAR Neg ALBUMIN Neg

HEART	CHEST	HERNIA	ABDOMEN L.M.P.
Good Quality no murmurs	well developed	Neg	Flat - well developed

CONFIGURATION CHEST EXPANSION	BLOOD PRESSURE	INGUINAL RINGS	NORMAL ENLARGED RELAXED
Equal bilaterally	100/60	R Normal L Normal	

LUNGS	OPERATIVE SCARS
Clear	None

BACK AND EXTREMITIES – EDEMA, AMPUTATIONS, FUNCTIONAL DEFECTS, DEFORMITIES

Grossly normal

FIC FINDINGS – NEUROLOGICAL

Neg

SKIN ERUPTION

Neg

SUMMARY OF PERMANENT DEFECTS, IMPAIRMENTS; EXAMINEE HAS BEEN ADVISED OF SIGNIFICANT FINDINGS ☐ YES ☐ NO

EMOTIONAL STABILITY	INTELLIGENCE
Good	Good

APPLICANT'S SIGNATURE	Accept	Condit. Accept	Reject	PHYSICIAN'S SIGNATURE
				A. M. Shkane

JOB ASSIGNMENT	PREVIOUS MEDICAL

COMPANY APPROVALS	DATE	PART EXAMINED	FILM NO.
PERSONNEL MANAGER BUFFALO	X-RAY REPORT – RADIOGRAPHIC FINDINGS		
DISTRICT SALES MA ER			
ST MANAGER			
SAFETY SUPER.			M.D.

13152

NG 909 Rev.

NATIONAL GYPSUM COMPANY

Office

Name _____ Address _____ Plant Millington-Hourly Payroll

Date 9/22/64 Dept. _____ Check No. _____

Age 23 Color _____ S X M W - D* Children _____

PHYSICAL RECORD
(TO BE COMPLETED BY PERSONNEL DEPARTMENT)

Arthritis No Epilepsy No Hernia No

Operations Tonsillectomy-1947 List on reverse side any hospital admissions in past 5 years. See over

Venereal Diseases No Tuberculosis No

Liquor No Tobacco No Drugs No

Other Illnesses No

Injuries – description, location, % disability Fibula bone in both legs broken - 3 Metatarsal bones broken in left foot-July 6, 1964 No disability

Compensation Received None Do you have a Workmen's compensation case pending for either injury or illness? No

Have you a history of silicosis or any other dust disease? No Have you ever been in military service? Yes

Have any of your parents or brothers or sisters had Tuberculosis, Cancer, Diabetes, Epilepsy or Insanity? No

Last previous employment U. S. Army - B51 Training Group-Boundbrook, N. J.

I certify that the above answers are true, correctly recorded, and that I am in good health, and that I have ____ history)

Signature of Applicant _____ Witness J. C. Simpson

* If divorced, give date and place

PHYSICAL EXAMINATION
(TO BE COMPLETED BY DOCTOR)

Height 71" Weight 163 ~~Over Weight~~ ~~Normal Weight~~ ~~Under Weight~~

Vision: Right 20/20 Left 20/20 Corrected: Right _____ Left _____ Binocular Vision 20/20

Pupils Reg. normally to light & dist. Cornea Normal

Lungs Clear Shortness of Breath None Chest X-Ray _____

Heart Normal Blood Pressure _____ Pulse _____

Ears Normal Nose _____ Teeth _____

Throat and Tonsils Throat OK. Tonsils out Hearing: Right 15/15 Left 15/15

Abdomen Flat, no scars or masses Hernia None - no inguinal scars

Spine Normal Hemorrhoids None - external

Extremities Small scar at left finger on nail bed. Perfect use of extremities

Scars Normal appearance (Note % of defects if any exist) Musculature Normal

Skin Clear and dark Glands Not enlarged (Head and neck only – give location) Genitals Normal

Reflexes Normal Mentality Normal

Blood Test To Date Pending Urinalysis Neg - Sugar, Alb. Blood

General Condition: Good ✓ Fair Poor Nutrition: Good ✓ Fair Poor

Do you recommend applicant for work? Yes Type of Work? 1315-1

Remarks Pt should not be hearing wk. for long period of time due to need for practice. Pt not fitted

APPROVED

FOREMAN _____ Date _____

SAFETY SUPERVISOR _____

PLANT MANAGER _____

Examined by _____ M.D. 9/22/64

THIS EMPLOYEE'S CONDITION IS KNOWN BY HIS SUPERVISOR. YES ☐ NO ☐

MEDICAL RECORD

ILLNESS OR INJURY

DATE	DIAGNOSIS AND TREATMENT	BY WHOM	DISABLED	
			FROM	TO
7/6/64	Fibula bone broken in both legs- 3 Metatarsal bones broken in left foot - Confined to Ireland Army Hospital, Fort Knox, Kentucky	Capt. Smith	7/6/64	8/28/64

11155

NATIONAL GYPSUM COMPANY

Sales District

Office

Name | Address | Plant Millington, N.J.

Date | Dept. | Check No. 12

e 22 | Color | S M W D* | Children

PHYSICAL RECORD
(TO BE COMPLETED BY PLANT OR OFFICE)

Arthritis | Epilepsy | Hernia

Operations — List on reverse side any hospital admissions in past 5 years.

Venereal Diseases | Tuberculosis

Liquor | Tobacco | Drugs

Other Illnesses

Injuries – description, location, % disability

Compensation Received — Do you have a workmen's compensation case pending for either injury or illness?

Have you a history of silicosis or any other dust disease? — Have you ever been in military service?

Have any of your parents or brothers or sisters had Tuberculosis, Cancer, Diabetes, Epilepsy or Insanity?

Last previous employment

I certify that the above answers are true, correctly recorded, and that I am in good health, and that I have never suffered from Silicosis, except (history)

Signature of Applicant | Witness

* If divorced, give date and place

PHYSICAL EXAMINATION
(TO BE COMPLETED BY DOCTOR)

Over Weight
Normal Weight —
Under Weight

..eight 6' 0" | Weight 175

Eyes: Right 20/20 | Left 20/20 | Corrected: Right | Left | Binocular Vision 20/20

Pupils ✓ | Cornea ✓

Lungs ✓ | Shortness of Breath none | Chest X-Ray —

Heart ✓ | Blood Pressure 116/70 | Pulse 72

Ears ✓ | Nose ✓ | Teeth ✓

Throat and Tonsils ✓ | Hearing: Right 20/20 | Left 20/20

Abdomen ✓ | Hernia ✓

Spine ✓ | Hemorrhoids ✓

Extremities ✓

Scars ✓ (Note % of defects if any exist) | Musculature ✓

Skin ✓ | Glands (Head and neck only – give location) ✓ | Genitals ✓

Reflexes ✓ | Mentality ✓

Blood Test ✓ | Urinalysis

General Condition: Good ✓ Fair | Poor | Nutrition: Good ✓ Fair | Poor

Do you recommend applicant for work? A- | Type of Work?

emarks 13156

APPROVED

FOREMAN | Date 6/12/63

SAFETY SUPERVISOR

PLANT

Examined by A H Bauman MD

THIS EMPLOYEE'S CONDITION IS KNOWN BY HIS SUPERVISOR. YES ☒ NO ☐