Circulate
File
B. H. Sand
G Rusch
T Stewart
K Morgan
Return to JB Chan

NATIONAL TOXICOLOGY PROGRAM
Technical Report Series
No. 295

TOXICOLOGY AND CARCINOGENESIS STUDIES OF CHRYSOTILE ASBESTOS

(CAS NO. 12001-29-5)

IN F344/N RATS

(FEED STUDIES)

U.S. DEPARTMENT OF HEALTH AND HUMAN SERVICES
Public Health Service
National Institutes of Health

HWBUI0001485

NATIONAL TOXICOLOGY PROGRAM

The National Toxicology Program (NTP), established in 1978, develops and evaluates scientific information about potentially toxic and hazardous chemicals. This knowledge can be used for protecting the health of the American people and for the primary prevention of disease. By bringing together the relevant programs, staff, and resources from the U.S. Public Health Service, DHHS, the National Toxicology Program has centralized and strengthened activities relating to toxicology research, testing and test development/validation efforts, and the dissemination of toxicological information to the public and scientific communities and to the research and regulatory agencies.

The NTP is made up of four charter DHHS agencies: the National Cancer Institute (NCI), National Institutes of Health; the National Institute of Environmental Health Sciences (NIEHS), National Institutes of Health; the National Center for Toxicological Research (NCTR), Food and Drug Administration; and the National Institute for Occupational Safety and Health (NIOSH), Centers for Disease Control. In July 1981, the Carcinogenesis Bioassay Testing Program, NCI, was transferred to the NIEHS.

HWBUI0001486

NTP TECHNICAL REPORT

ON THE

TOXICOLOGY AND CARCINOGENESIS STUDIES OF CHRYSOTILE ASBESTOS

(CAS NO. 12001-29-5)

IN F344/N RATS

(FEED STUDIES)



NATIONAL TOXICOLOGY PROGRAM
P.O. Box 12233
Research Triangle Park, NC 27709

November 1985

NTP TR 295

NIH Publication No. 86-2551

U.S. DEPARTMENT OF HEALTH AND HUMAN SERVICES
Public Health Service
National Institutes of Health

HWBUI0001487

NOTE TO THE READER

These studies are designed and conducted to characterize and evaluate the toxicologic potential, including carcinogenic activity, of selected chemicals in laboratory animals (usually two species, rats and mice). Chemicals selected for testing in the NTP Carcinogenesis Program are chosen primarily on the bases of human exposure, level of production, and chemical structure. Selection per se is not an indicator of a chemical's carcinogenic potential. Negative results, in which the test animals do not have a greater incidence of cancer than control animals, do not necessarily mean that a test chemical is not a carcinogen, inasmuch as the experiments are conducted under a limited set of conditions. Positive results demonstrate that a test chemical is carcinogenic for animals under the conditions of the test and indicate that exposure to the chemical has the potential for hazard to humans. The determination of the risk to humans from chemicals found to be carcinogenic in animals requires a wider analysis which extends beyond the purview of this study.

Five categories of interpretative conclusions were adopted for use in June 1983 in the Technical Reports series to specifically emphasize consistency and the concept of actual evidence of carcinogenicity. For each definitive study result (male rats, female rats, male mice, female mice), one of the following quintet will be selected to describe the findings. These categories refer to the strength of the experimental evidence and not to either potency or mechanism.

- **Clear Evidence of Carcinogenicity** is demonstrated by studies that are interpreted as showing a chemically related increased incidence of malignant neoplasms, studies that exhibit a substantially increased incidence of benign neoplasms, or studies that exhibit an increased incidence of a combination of malignant and benign neoplasms where each increases with dose.
- **Some Evidence of Carcinogenicity** is demonstrated by studies that are interpreted as showing a chemically related increased incidence of benign neoplasms, studies that exhibit marginal increases in neoplasms of several organs/tissues, or studies that exhibit a slight increase in uncommon malignant or benign neoplasms.
- **Equivocal Evidence of Carcinogenicity** is demonstrated by studies that are interpreted as showing a chemically related marginal increase of neoplasms.
- **No Evidence of Carcinogenicity** is demonstrated by studies that are interpreted as showing no chemically related increases in malignant or benign neoplasms.
- **Inadequate Study of Carcinogenicity** demonstrates that because of major qualitative or quantitative limitations, the studies cannot be interpreted as valid for showing either the presence or absence of a carcinogenic effect.

Additionally, the following concepts (as patterned from the International Agency for Research on Cancer Monographs) have been adopted by the NTP to give further clarification of these issues:

> The term *chemical carcinogenesis* generally means the induction by chemicals of neoplasms not usually observed, the earlier induction by chemicals of neoplasms that are commonly observed, or the induction by chemicals of more neoplasms than are generally found. Different mechanisms may be involved in these situations. Etymologically, the term *carcinogenesis* means induction of cancer, that is, of malignant neoplasms; however, the commonly accepted meaning is the induction of various types of neoplasms or of a combination of malignant and benign neoplasms. In the Technical Reports, the words *tumor* and *neoplasm* are used interchangeably.

This study was conducted under contract to the National Institute of Environmental Health Sciences, National Toxicology Program. The studies described in this Technical Report have been conducted in compliance with NTP chemical health and safety requirements and must meet or exceed all applicable Federal, state, and local health and safety regulations. All NTP toxicology and carcinogenesis studies are subjected to a data audit before being presented for peer review.

Although every effort is made to prepare the Technical Reports as accurately as possible, mistakes may occur. Readers are requested to identify any mistakes so that corrective action may be taken. Further, anyone who is aware of related ongoing or published studies not mentioned in this report is encouraged to make this information known to the NTP. Comments and questions about the National Toxicology Program Technical Reports on Toxicology and Carcinogenesis Studies should be directed to Dr. J.E. Huff, National Toxicology Program, P.O. Box 12233, Research Triangle Park, NC 27709 (919-541-3780).

These NTP Technical Reports are available for sale from the National Technical Information Service, U.S. Department of Commerce, 5285 Port Royal Road, Springfield, VA 22161 (703-487-4650). Single copies of this Technical Report are available without charge (and while supplies last) from the NTP Public Information Office, National Toxicology Program, P.O. Box 12233, Research Triangle Park, NC 27709.

HWBUI0001488

CONTENTS

PAGE

ABSTRACT 12

CONTRIBUTORS 14

PEER REVIEW PANEL 16

SUMMARY OF PEER REVIEW COMMENTS 17

I. INTRODUCTION 19

II. MATERIALS AND METHODS 23

PROCUREMENT AND CHARACTERIZATION OF TEST MATERIALS 24

PREPARATION OF FORMULATED DIETS AND DOSE MIXTURES 24

FORMULATED DIETS 24

DOSE MIXTURES OF ASBESTOS FOR GAVAGE ADMINISTRATION 26

DOSE MIXTURES OF 1,2-DIMETHYLHYDRAZINE DIHYDROCHLORIDE FOR GAVAGE ADMINISTRATION 26

LIFETIME STUDIES OF SHORT-RANGE OR INTERMEDIATE-RANGE CHRYSOTILE ASBESTOS 26

STUDY DESIGN 26

SOURCE AND SPECIFICATIONS OF TEST ANIMALS 26

ANIMAL MAINTENANCE 27

SAFETY PRECAUTIONS 27

CLINICAL EXAMINATIONS AND PATHOLOGY 27

STATISTICAL METHODS 31

III. RESULTS 33

LIFETIME STUDIES OF SHORT-RANGE OR INTERMEDIATE-RANGE CHRYSOTILE ASBESTOS 34

ESTABLISHMENT OF TEST GROUPS 34

BODY WEIGHTS AND FEED CONSUMPTION 34

PATHOGEN BURDEN 34

CLINICAL SIGNS 39

SURVIVAL 40

PATHOLOGY AND STATISTICAL ANALYSES OF RESULTS 44

IV. DISCUSSION AND CONCLUSIONS 55

V. REFERENCES 61

HWBUI0001489

TABLES

PAGE

TABLE 1 FIBER CHARACTERISTICS AND CHEMICAL-INSTRUMENTAL ANALYSES OF CHRYSOTILE ASBESTOS 25

TABLE 2 SUMMARY OF DISTRIBUTION OF RATS IN THE LIFETIME FEED STUDIES OF INTERMEDIATE-RANGE CHRYSOTILE ASBESTOS 28

TABLE 3 EXPERIMENTAL DESIGN AND MATERIALS AND METHODS IN THE LIFETIME FEED STUDIES OF SHORT-RANGE AND INTERMEDIATE-RANGE CHRYSOTILE ASBESTOS 29

TABLE 4 MEAN BODY WEIGHTS AND SURVIVAL OF RATS IN THE LIFETIME FEED STUDIES OF SHORT-RANGE CHRYSOTILE ASBESTOS 35

TABLE 5 MEAN BODY WEIGHTS AND SURVIVAL OF RATS IN THE LIFETIME FEED STUDIES OF INTERMEDIATE-RANGE CHRYSOTILE ASBESTOS 37

TABLE 6 SURVIVAL OF RATS IN THE LIFETIME FEED STUDIES OF SHORT-RANGE CHRYSOTILE ASBESTOS 40

TABLE 7 SURVIVAL OF RATS IN THE LIFETIME FEED STUDIES OF SHORT-RANGE CHRYSOTILE ASBESTOS AT VARIOUS TIME POINTS 40

TABLE 8 SURVIVAL OF RATS IN THE LIFETIME FEED STUDIES OF INTERMEDIATE-RANGE CHRYSOTILE ASBESTOS 42

TABLE 9 SURVIVAL OF RATS IN THE LIFETIME STUDIES OF 1,2-DIMETHYLHYDRAZINE DIHYDROCHLORIDE WITH AND WITHOUT INTERMEDIATE-RANGE CHRYSOTILE ASBESTOS IN THE FEED 42

TABLE 10 SURVIVAL OF RATS IN THE LIFETIME FEED STUDIES OF INTERMEDIATE-RANGE CHRYSOTILE ASBESTOS AT VARIOUS TIME POINTS 44

TABLE 11 ALIMENTARY TRACT TUMORS IN RATS IN THE LIFETIME FEED STUDIES OF SHORT-RANGE CHRYSOTILE ASBESTOS 46

TABLE 12 INCIDENCE OF NONNEOPLASTIC LESIONS IN THE ALIMENTARY TRACT OF RATS IN THE LIFETIME FEED STUDIES OF SHORT-RANGE CHRYSOTILE ASBESTOS 47

TABLE 13 ALIMENTARY TRACT TUMORS IN RATS IN THE LIFETIME FEED STUDIES OF INTERMEDIATE-RANGE CHRYSOTILE ASBESTOS 48

HWBUI0001490

TABLES (Continued)

PAGE

TABLE 14 INCIDENCE OF NONNEOPLASTIC LESIONS IN THE ALIMENTARY TRACT OF RATS IN THE LIFETIME FEED STUDIES OF INTERMEDIATE-RANGE CHRYSOTILE ASBESTOS 49

TABLE 15 ANALYSIS OF INTEGUMENTARY SYSTEM TUMORS IN MALE RATS IN THE LIFETIME FEED STUDY OF INTERMEDIATE-RANGE CHRYSOTILE ASBESTOS 50

TABLE 16 ANALYSIS OF CLITORAL GLAND TUMORS IN FEMALE RATS IN THE LIFETIME FEED STUDY OF INTERMEDIATE-RANGE CHRYSOTILE ASBESTOS 50

TABLE 17 SUMMARY OF GASTROINTESTINAL TUMORS IN RATS ADMINISTERED 1,2-DIMETHYLHYDRAZINE DIHYDROCHLORIDE WITH AND WITHOUT INTERMEDIATE-RANGE CHRYSOTILE ASBESTOS 52

TABLE 18 SUMMARY OF NONGASTROINTESTINAL TUMORS IN RATS ADMINISTERED 1,2-DIMETHYLHYDRAZINE DIHYDROCHLORIDE WITH AND WITHOUT INTERMEDIATE-RANGE CHRYSOTILE ASBESTOS 53

TABLE 19 ANALYSIS OF KIDNEY TUMORS IN FEMALE RATS IN THE LIFETIME FEED STUDY OF INTERMEDIATE-RANGE CHRYSOTILE ASBESTOS WITH 1,2-DIMETHYL-HYDRAZINE DIHYDROCHLORIDE 53

TABLE 20 ANALYSIS OF THYROID GLAND TUMORS IN MALE RATS IN THE LIFETIME FEED STUDY OF INTERMEDIATE-RANGE CHRYSOTILE ASBESTOS WITH 1,2-DIMETHYL-HYDRAZINE DIHYDROCHLORIDE 54

HWBUI0001491

FIGURES

PAGE

FIGURE 1 SCHEDULE OF MAJOR EVENTS IN RATS IN THE LIFETIME FEED STUDIES OF INTERMEDIATE-RANGE CHRYSOTILE ASBESTOS 26

FIGURE 2 GROWTH CURVES FOR RATS FED DIETS CONTAINING SHORT-RANGE CHRYSOTILE ASBESTOS IN LIFETIME STUDIES 36

FIGURE 3 GROWTH CURVES FOR RATS FED DIETS CONTAINING INTERMEDIATE-RANGE CHRYSOTILE ASBESTOS WITH AND WITHOUT 1,2-DIMETHYLHYDRAZINE DIHYDROCHLORIDE IN LIFETIME STUDIES 38

FIGURE 4 KAPLAN-MEIER SURVIVAL CURVES FOR RATS FED DIETS CONTAINING SHORT-RANGE CHRYSOTILE ASBESTOS IN LIFETIME STUDIES 41

FIGURE 5 KAPLAN-MEIER SURVIVAL CURVES FOR RATS FED DIETS CONTAINING INTERMEDIATE-RANGE CHRYSOTILE ASBESTOS WITH AND WITHOUT 1,2-DIMETHYLHYDRAZINE DIHYDROCHLORIDE IN LIFETIME STUDIES 43

HWBUI0001492

APPENDIXES

PAGE

APPENDIX A SUMMARY OF THE INCIDENCE OF NEOPLASMS IN RATS IN THE LIFETIME FEED STUDIES OF SHORT-RANGE CHRYSOTILE ASBESTOS 67

TABLE A1 SUMMARY OF THE INCIDENCE OF NEOPLASMS IN MALE RATS IN THE LIFETIME FEED STUDY OF SHORT-RANGE CHRYSOTILE ASBESTOS 68

TABLE A2 SUMMARY OF THE INCIDENCE OF NEOPLASMS IN FEMALE RATS IN THE LIFETIME FEED STUDY OF SHORT-RANGE CHRYSOTILE ASBESTOS 73

TABLE A3 INDIVIDUAL ANIMAL TUMOR PATHOLOGY OF MALE RATS IN THE LIFETIME FEED STUDY OF SHORT-RANGE CHRYSOTILE ASBESTOS 78

TABLE A4 INDIVIDUAL ANIMAL TUMOR PATHOLOGY OF FEMALE RATS IN THE LIFETIME FEED STUDY OF SHORT-RANGE CHRYSOTILE ASBESTOS 106

APPENDIX B SUMMARY OF THE INCIDENCE OF NEOPLASMS IN RATS IN THE LIFETIME FEED STUDIES OF INTERMEDIATE-RANGE CHRYSOTILE ASBESTOS 135

TABLE B1 SUMMARY OF THE INCIDENCE OF NEOPLASMS IN MALE RATS IN THE LIFETIME FEED STUDY OF INTERMEDIATE-RANGE CHRYSOTILE ASBESTOS ... 136

TABLE B2 SUMMARY OF THE INCIDENCE OF NEOPLASMS IN FEMALE RATS IN THE LIFETIME FEED STUDY OF INTERMEDIATE-RANGE CHRYSOTILE ASBESTOS ... 145

TABLE B3 INDIVIDUAL ANIMAL TUMOR PATHOLOGY OF MALE RATS IN THE LIFETIME FEED STUDY OF INTERMEDIATE-RANGE CHRYSOTILE ASBESTOS 152

TABLE B4 INDIVIDUAL ANIMAL TUMOR PATHOLOGY OF FEMALE RATS IN THE LIFETIME FEED STUDY OF INTERMEDIATE-RANGE CHRYSOTILE ASBESTOS 212

APPENDIX C SUMMARY OF THE INCIDENCE OF NONNEOPLASTIC LESIONS IN RATS IN THE LIFETIME FEED STUDIES OF SHORT-RANGE CHRYSOTILE ASBESTOS ... 273

TABLE C1 SUMMARY OF THE INCIDENCE OF NONNEOPLASTIC LESIONS IN MALE RATS IN THE LIFETIME FEED STUDY OF SHORT-RANGE CHRYSOTILE ASBESTOS ... 274

TABLE C2 SUMMARY OF THE INCIDENCE OF NONNEOPLASTIC LESIONS IN FEMALE RATS IN THE LIFETIME FEED STUDY OF SHORT-RANGE CHRYSOTILE ASBESTOS 282

HWBUI0001493

APPENDIXES (Continued)

PAGE

APPENDIX D SUMMARY OF THE INCIDENCE OF NONNEOPLASTIC LESIONS IN RATS IN THE LIFETIME FEED STUDIES OF INTERMEDIATE-RANGE CHRYSOTILE ASBESTOS 289

TABLE D1 SUMMARY OF THE INCIDENCE OF NONNEOPLASTIC LESIONS IN MALE RATS IN THE LIFETIME FEED STUDY OF INTERMEDIATE-RANGE CHRYSOTILE ASBESTOS 290

TABLE D2 SUMMARY OF THE INCIDENCE OF NONNEOPLASTIC LESIONS IN FEMALE RATS IN THE LIFETIME FEED STUDY OF INTERMEDIATE-RANGE CHRYSOTILE ASBESTOS 303

APPENDIX E ANALYSES OF PRIMARY TUMORS IN RATS IN THE LIFETIME FEED STUDIES OF SHORT-RANGE AND INTERMEDIATE-RANGE CHRYSOTILE ASBESTOS AND INTERMEDIATE-RANGE CHRYSOTILE ASBESTOS PLUS 1,2-DIMETHYLHYDRAZINE DIHYDROCHLORIDE 313

TABLE E1 ANALYSIS OF PRIMARY TUMORS IN MALE RATS IN THE LIFETIME FEED STUDY OF SHORT-RANGE CHRYSOTILE ASBESTOS 314

TABLE E2 ANALYSIS OF PRIMARY TUMORS IN FEMALE RATS IN THE LIFETIME FEED STUDY OF SHORT-RANGE CHRYSOTILE ASBESTOS 318

TABLE E3 ANALYSIS OF PRIMARY TUMORS IN MALE RATS IN THE LIFETIME FEED STUDY OF INTERMEDIATE-RANGE CHRYSOTILE ASBESTOS 321

TABLE E4 ANALYSIS OF PRIMARY TUMORS IN FEMALE RATS IN THE LIFETIME FEED STUDY OF INTERMEDIATE-RANGE CHRYSOTILE ASBESTOS 326

TABLE E5 ANALYSIS OF PRIMARY TUMORS IN MALE RATS IN THE LIFETIME FEED STUDY OF INTERMEDIATE-RANGE CHRYSOTILE ASBESTOS PLUS 1,2-DIMETHYLHYDRAZINE DIHYDROCHLORIDE 329

TABLE E6 ANALYSIS OF PRIMARY TUMORS IN FEMALE RATS IN THE LIFETIME FEED STUDY OF INTERMEDIATE-RANGE CHRYSOTILE ASBESTOS PLUS 1,2-DIMETHYLHYDRAZINE DIHYDROCHLORIDE 334

APPENDIX F INCIDENCES OF TUMORS IN F344/N RATS RECEIVING NO TREATMENT IN CONTEMPORARY LIFETIME ASBESTOS STUDIES 339

TABLE F1 INCIDENCE OF EPITHELIAL TUMORS OF THE LARGE INTESTINE IN MALE F344/N RATS RECEIVING NO TREATMENT IN LIFETIME STUDIES 340

HWBUI0001494

APPENDIXES (Continued)

PAGE

TABLE F2 INCIDENCE OF INTEGUMENTARY SYSTEM KERATOACANTHOMAS IN MALE F344/N RATS RECEIVING NO TREATMENT IN LIFETIME STUDIES 340

TABLE F3 INCIDENCE OF CLITORAL GLAND TUMORS IN FEMALE F344/N RATS RECEIVING NO TREATMENT IN LIFETIME STUDIES 341

TABLE F4 INCIDENCE OF ADRENAL GLAND TUMORS IN MALE F344/N RATS RECEIVING NO TREATMENT IN LIFETIME STUDIES 341

TABLE F5 INCIDENCE OF MESOTHELIOMAS IN MALE F344/N RATS RECEIVING NO TREATMENT IN LIFETIME STUDIES 341

APPENDIX G ANALYSIS OF FORMULATED DIETS AND DOSE MIXTURES 343

TABLE G1 ANALYSIS OF FORMULATED DIETS IN THE LIFETIME FEED STUDIES OF SHORT-RANGE CHRYSOTILE ASBESTOS 345

TABLE G2 ANALYSIS OF FORMULATED DIETS IN THE LIFETIME FEED STUDIES OF INTERMEDIATE-RANGE CHRYSOTILE ASBESTOS 346

TABLE G3 ANALYSIS OF DOSE MIXTURES OF 1,2-DIMETHYLHYDRAZINE DIHYDROCHLORIDE IN THE LIFETIME FEED STUDIES OF INTERMEDIATE-RANGE CHRYSOTILE ASBESTOS 348

APPENDIX H FEED AND COMPOUND CONSUMPTION BY RATS IN THE LIFETIME FEED STUDIES OF CHRYSOTILE ASBESTOS 349

TABLE H1 FEED AND COMPOUND CONSUMPTION BY MALE RATS IN THE LIFETIME FEED STUDY OF SHORT-RANGE CHRYSOTILE ASBESTOS 350

TABLE H2 FEED AND COMPOUND CONSUMPTION BY FEMALE RATS IN THE LIFETIME FEED STUDY OF SHORT-RANGE CHRYSOTILE ASBESTOS 351

TABLE H3 FEED AND COMPOUND CONSUMPTION BY MALE RATS IN THE LIFETIME FEED STUDY OF INTERMEDIATE-RANGE CHRYSOTILE ASBESTOS 352

TABLE H4 FEED AND COMPOUND CONSUMPTION BY FEMALE RATS IN THE LIFETIME FEED STUDY OF INTERMEDIATE-RANGE CHRYSOTILE ASBESTOS 353

TABLE H5 FEED AND COMPOUND CONSUMPTION BY MALE RATS RECEIVING DMH WITH AND WITHOUT INTERMEDIATE-RANGE CHRYSOTILE ASBESTOS IN THE LIFETIME FEED STUDY OF INTERMEDIATE-RANGE CHRYSOTILE ASBESTOS ... 354

HWBUI0001495

APPENDIXES (Continued)

PAGE

TABLE H6 FEED AND COMPOUND CONSUMPTION BY FEMALE RATS RECEIVING DMH WITH AND WITHOUT INTERMEDIATE-RANGE CHRYSOTILE ASBESTOS IN THE LIFETIME FEED STUDY OF INTERMEDIATE-RANGE CHRYSOTILE ASBESTOS .. 355

APPENDIX I PATHOGEN BURDEN IN RATS IN THE LIFETIME FEED STUDIES OF SHORT-RANGE CHRYSOTILE ASBESTOS 357

TABLE I1 INDIVIDUAL HISTOPATHOLOGIC FINDINGS IN F_0 RATS IN THE LIFETIME FEED STUDIES OF SHORT-RANGE CHRYSOTILE ASBESTOS 359

TABLE I2 MICROSCOPIC EXAMINATION FOR ENDOPARASITES AND BACTERIA IN F_0 RATS IN THE LIFETIME FEED STUDIES OF SHORT-RANGE CHRYSOTILE ASBESTOS 360

TABLE I3 MURINE VIRUS ANTIBODY DETERMINATION IN F_0 RATS IN THE LIFETIME FEED STUDIES OF SHORT-RANGE CHRYSOTILE ASBESTOS 361

TABLE I4 INDIVIDUAL HISTOPATHOLOGIC FINDINGS IN F_1 RATS IN THE LIFETIME FEED STUDIES OF SHORT-RANGE CHRYSOTILE ASBESTOS 363

TABLE I5 MICROSCOPIC EXAMINATION FOR ENDOPARASITES AND BACTERIA IN F_1 RATS IN THE LIFETIME FEED STUDIES OF SHORT-RANGE CHRYSOTILE ASBESTOS 364

APPENDIX J PATHOGEN BURDEN IN RATS IN THE LIFETIME FEED STUDIES OF INTERMEDIATE-RANGE CHRYSOTILE ASBESTOS 365

TABLE J1 INDIVIDUAL HISTOPATHOLOGIC FINDINGS IN F_0 RATS IN THE LIFETIME FEED STUDIES OF INTERMEDIATE-RANGE CHRYSOTILE ASBESTOS 368

TABLE J2 MICROSCOPIC EXAMINATION FOR ENDOPARASITES AND BACTERIA IN F_0 RATS IN THE LIFETIME FEED STUDIES OF INTERMEDIATE-RANGE CHRYSOTILE ASBESTOS 369

TABLE J3 MURINE VIRUS ANTIBODY DETERMINATION IN F_1 RATS IN THE LIFETIME FEED STUDIES OF INTERMEDIATE-RANGE CHRYSOTILE ASBESTOS 371

TABLE J4 INDIVIDUAL HISTOPATHOLOGIC FINDINGS IN F_1 RATS IN THE LIFETIME FEED STUDIES OF INTERMEDIATE-RANGE CHRYSOTILE ASBESTOS 372

TABLE J5 MICROSCOPIC EXAMINATION FOR ENDOPARASITES AND BACTERIA IN F_1 RATS IN THE LIFETIME FEED STUDIES OF INTERMEDIATE-RANGE CHRYSOTILE ASBESTOS 373

HWBUI0001496

APPENDIXES (Continued)

PAGE

APPENDIX K CLINICAL SIGNS IN RATS IN THE LIFETIME FEED STUDIES OF SHORT-RANGE CHRYSOTILE ASBESTOS 375

TABLE K1 SUMMARY OF CLINICAL SIGNS OBSERVED IN RATS BEFORE MORIBUND KILL IN THE LIFETIME FEED STUDIES OF SHORT-RANGE CHRYSOTILE ASBESTOS: UNTREATED CONTROL 376

TABLE K2 SUMMARY OF CLINICAL SIGNS OBSERVED IN RATS BEFORE MORIBUND KILL IN THE LIFETIME FEED STUDIES OF SHORT-RANGE CHRYSOTILE ASBESTOS: SHORT-RANGE 377

APPENDIX L CLINICAL SIGNS IN RATS IN THE LIFETIME FEED STUDIES OF INTERMEDIATE-RANGE CHRYSOTILE ASBESTOS 379

TABLE L1 SUMMARY OF CLINICAL SIGNS OBSERVED IN RATS BEFORE MORIBUND KILL IN THE LIFETIME FEED STUDIES OF INTERMEDIATE-RANGE CHRYSOTILE ASBESTOS: UNTREATED CONTROL 380

TABLE L2 SUMMARY OF CLINICAL SIGNS OBSERVED IN RATS BEFORE MORIBUND KILL IN THE LIFETIME FEED STUDIES OF INTERMEDIATE-RANGE CHRYSOTILE ASBESTOS: DMH 381

TABLE L3 SUMMARY OF CLINICAL SIGNS OBSERVED IN RATS BEFORE MORIBUND KILL IN THE LIFETIME FEED STUDIES OF INTERMEDIATE-RANGE CHRYSOTILE ASBESTOS: INTERMEDIATE-RANGE 383

TABLE L4 SUMMARY OF CLINICAL SIGNS OBSERVED IN RATS BEFORE MORIBUND KILL IN THE LIFETIME FEED STUDIES OF INTERMEDIATE-RANGE CHRYSOTILE ASBESTOS: IR + DMH 385

TABLE L5 SUMMARY OF CLINICAL SIGNS OBSERVED IN RATS BEFORE MORIBUND KILL IN THE LIFETIME FEED STUDIES OF INTERMEDIATE-RANGE CHRYSOTILE ASBESTOS: IR/PW 387

APPENDIX M DATA AUDIT SUMMARY 389

HWBUI0001497

ABSTRACT

Lifetime toxicology and carcinogenesis studies of short-range (SR) and intermediate-range (IR) fiber length chrysotile asbestos were conducted in groups of 88-250 male and female F344/N rats. Both forms of asbestos were administered at a concentration of 1% in pelleted diet for the lifetime of the rats, starting with the dams of the test animals. Subgroups of 100 male and 100 female IR chrysotile-exposed rats also received 0.47 mg/g IR chrysotile asbestos in water by gavage during lactation (preweaning [PW]). At 9 weeks of age, additional subgroups (125-175) of control and IR chrysotile-exposed rats received 7.5 mg/kg (male) or 15 mg/kg (female) 1,2-dimethylhydrazine dihydrochloride (DMH) by gavage every other week for a total of five doses. When the survival of either the control or test group reached 10%, both groups were killed.

Neither type of fiber affected fertility or litter size. The offspring from mothers exposed to SR chrysotile were similar in body weight to the controls at birth and remained so throughout their lives. The offspring of IR chrysotile-exposed mothers were similar in weight at birth but were slightly smaller (13%) at weaning and remained so throughout their lives, with the exception of those in the IR/PW chrysotile group, which weighed slightly more during their lifetimes. Feed consumption and survival were comparable among the SR and IR chrysotile asbestos groups and controls. The DMH-exposed groups showed decreased survival due primarily to the development of lethal neoplasms.

The administration of SR chrysotile for the lifetime of exposed male and female rats did not cause any overt toxicity. In addition, no neoplastic or nonneoplastic disease was associated with SR chrysotile exposure.

Male and female rats exposed to IR chrysotile asbestos did not show any adverse clinical signs. Benign epithelial neoplasms (adenomatous polyps) were observed in the large intestine of IR chrysotile asbestos male rats (9/250, 3.6%). Although not statistically significant ($P=0.08$) compared with concurrent controls (0/85), the incidence of these neoplasms was highly significant ($P=0.003$) when compared with the incidence of epithelial neoplasms (benign and malignant combined) of the large intestine in the pooled male control groups of all the NTP oral asbestos lifetime studies (3/524, 0.6%). The biologic importance of this finding was supported by the observation of lesions of similar morphology in the small intestine or glandular stomach of four additional IR chrysotile male rats and by a low incidence (2/100, 2.0%) of adenomatous polyps in the large intestine of male rats in the IR/PW group.

A significant ($P<0.05$) increase in keratoacanthomas of the skin was observed in male IR (19/250, 7.6%) and IR/PW (8/100, 8.0%) chrysotile-exposed rats compared with the concurrent controls (1/88, 1.1%). The biologic importance of this observation was discounted because the incidence in these groups did not greatly exceed the rate observed in the combined male control groups from all the other NTP oral asbestos studies (19/441, 4.3%). An apparent increase in the incidence of clitoral gland neoplasms in female IR (18/250, 7.2%) and IR/PW (4/100, 4.0%) chrysotile-exposed rats compared with that in the concurrent controls (1/88, 1.1%) was also discounted because of a lack of statistical significance when compared with the pooled female control groups from the other NTP oral asbestos studies (21/441, 4.8%).

Rats exposed to DMH and DMH plus IR chrysotile asbestos exhibited neoplasia in those organs known to be targets for DMH (gastrointestinal tract, Zymbal gland, liver, and kidney). There was a significant difference ($P<0.05$) in the incidence of DMH-induced mixed-cell tumors of the kidney between the DMH alone (13/125, 10%) and DMH plus IR chrysotile asbestos (34/175, 19%) female groups. An increased incidence of thyroid follicular cell tumors was observed in DMH plus IR chrysotile male rats (28/175, 16.0%) compared with the DMH alone group (9/124, 7.3%). The biologic importance of both observations is questionable, since neither organ represents a primary target organ for

HWBUI0001498

asbestos and no difference between DMH and DMH plus IR chrysotile was observed for the primary target organs (intestine and mesothelium).

An audit of the experimental data was conducted for these lifetime carcinogenesis studies of chrysotile asbestos. No data discrepancies were found that influenced the final interpretations.

Under the conditions of these lifetime studies, short-range and intermediate-range chrysotile asbestos did not induce overt toxicity and did not affect survival when ingested at a level of 1% in the diet by male and female F344/N rats. There was *no evidence of carcinogenicity** in male or female rats exposed to SR chrysotile asbestos or in female rats exposed to IR chrysotile asbestos. There was *some evidence of carcinogenicity* in male rats exposed to IR chrysotile asbestos as indicated by an increased incidence of adenomatous polyps in the large intestine. The cocarcinogenesis studies of 1,2-dimethylhydrazine dihydrochloride and IR chrysotile asbestos were considered inconclusive for determining whether IR chrysotile asbestos had either a tumor-enhancing or protective effect, although an increased incidence of neoplasms was observed in the kidneys of female rats exposed to DMH plus IR chrysotile as compared with those exposed to DMH alone.

*Categories of evidence of carcinogenicity are defined in the Note to the Reader on page 2.

HWBUI0001499

CONTRIBUTORS

The NTP Technical Report on the Toxicology and Carcinogenesis Studies of Chrysotile Asbestos is based on the lifetime studies that began in October 1977 and ended in May 1980 at Hazleton Laboratories America, Inc.

National Toxicology Program
(Evaluated Experiment, Interpreted Results, and Reported Findings)

E.E. McConnell, D.V.M., Chemical Manager

Gary A. Boorman, D.V.M., Ph.D.
Rajendra S. Chhabra, Ph.D.
David M. DeMarini, Ph.D.
Joseph K. Haseman, Ph.D.
James Huff, Ph.D.
C.W. Jameson, Ph.D.
G.N. Rao, D.V.M., Ph.D.
B. A. Schwetz, D.V.M., Ph.D.
Raymond W. Tennant, Ph.D.

NTP Pathology Working Groups
(Evaluated Slides and Prepared Pathology Report on Short-Range Chrysotile Asbestos on 5/6/82)

R. Sauer, V.M.D. (Chair)
Clement Associates
G. Boorman, D.V.M., Ph.D.
NTP
S. Eustis, D.V.M., Ph.D.
NTP
N. MacLachlan, D.V.M., Ph.D.
North Carolina State University
E. McConnell, D.V.M.
NTP
H. Solleveld, D.V.M., Ph.D.
NTP

(Evaluated Slides and Prepared Pathology Report on Intermediate-Range Chrysotile Asbestos in Female Rats on 12/7/82)

R. Sauer, V.M.D. (Chair)
Clement Associates
G. Boorman, D.V.M., Ph.D.
NTP
S. Eustis, D.V.M., Ph.D.
NTP
C. Hollander, D.V.M., Ph.D.
IVEG-TNO, Netherlands
E. McConnell, D.V.M.
NTP
H. Solleveld, D.V.M., Ph.D.
NTP

(Evaluated Slides and Prepared Pathology Report on Intermediate-Range Chrysotile Asbestos in Male Rats on 1/6/83)

R. Sauer, V.M.D. (Chair)
Clement Associates
K. Ayers, D.V.M.
Burroughs Wellcome
G. Boorman, D.V.M., Ph.D.
NTP
E. McConnell, D.V.M.
NTP
M. Stedham, D.V.M.
Tracor Jitco

HWBUI0001500

CONTRIBUTORS (Continued)

Principal Contributors at Hazleton Laboratories America, Inc.
(Conducted Studies and Evaluated Tissues)

Henry A. Rutter, Ph.D.
Principal Investigator
B. Ulland, D.V.M.
Pathologist

S. Mahatka, D.V.M.
Pathologist

Principal Contributors at Experimental Pathology Laboratory
(Provided Pathology Quality Assurance)

D. Banas, D.V.M.

W. Iverson, D.V.M.

Principal Contributors at Carltech Associates, Inc.
(Contractor for Technical Report Preparation)

William D. Theriault, Ph.D.
Project Manager
Abigail C. Jacobs, Ph.D.
Senior Scientist

John Warner, M.S.
Chemist/Statistician

HWBUI0001501

PEER REVIEW PANEL

The members of the Peer Review Panel who evaluated the draft Technical Report on chrysotile asbestos on July 27, 1984, are listed below. Panel members serve as independent scientists, not as representatives of any institution, company, or governmental agency. In this capacity, Panel members have five major responsibilities: (a) to ascertain that all relevant literature data have been adequately cited and interpreted, (b) to determine if the design and conditions of the NTP studies were appropriate, (c) to ensure that the Technical Report presents the experimental results and conclusions fully and clearly, (d) to judge the significance of the experimental results by scientific criteria, and (e) to assess the evaluation of the evidence of carcinogenicity and other observed toxic responses.

National Toxicology Program Board of Scientific Counselors Technical Reports Review Subcommittee

Jerry B. Hook, Ph.D. (Chair)*
Vice President, Preclinical Research and Development
Smith Kline & French Laboratories
Philadelphia, Pennsylvania

Curtis Harper, Ph.D. (Acting Chair)
Associate Professor of Pharmacology
School of Medicine
University of North Carolina
Chapel Hill, North Carolina

James Swenberg, D.V.M., Ph.D.*
Chief of Pathology
Chemical Industry Institute of Toxicology
Research Triangle Park, North Carolina

Ad Hoc Subcommittee Panel of Experts

Louis S. Beliczky, M.S., M.P.H.
Director, Department of Industrial Hygiene
United Rubber Workers International Union
Akron, Ohio

Devra L. Davis, Ph.D. (Principal Reviewer)
Board on Toxicology and Environmental Health Hazards
National Academy of Sciences
Washington, D.C.

Seymour L. Friess, Ph.D.
Arlington, Virginia

Thomas C. Jones, D.V.M.
(Principal Reviewer)
Professor, Comparative Pathology
New England Regional Primate Research Center
Harvard Medical School
Southborough, Massachusetts

Richard J. Kociba, D.V. M., Ph.D.
Dow Chemical USA
Midland, Michigan

David Kotelchuck, Ph.D.
Research Department
United Electrical, Radio and Machine Workers of America
New York, New York

Tom Slaga, Ph.D.*
Science Park, Research Division
University of Texas System Cancer Center
Smithville, Texas

Steven R. Tannenbaum, Ph.D.
Professor, Department of Nutrition and Food Science
Massachusetts Institute of Technology
Cambridge, Massachusetts

Bruce W. Turnbull, Ph.D. (Principal Reviewer)
Professor and Associate Director
College of Engineering
Cornell University
Ithaca, New York

John R. Van Ryzin, Ph.D.
Division of Biostatistics
School of Public Health
Columbia University
New York, New York

---

* Unable to attend meeting

HWBUI0001502

SUMMARY OF PEER REVIEW COMMENTS ON THE TOXICOLOGY AND CARCINOGENESIS STUDIES OF CHYRSOTILE ASBESTOS

On July 27, 1984, the draft Technical Report on the toxicology and carcinogenesis studies of chrysotile asbestos received peer review by the National Toxicology Program Board of Scientific Counselors' Technical Reports Review Subcommittee and associated Panel of Experts. The review meeting began at 9:00 a.m. in the Conference Center, Building 101, South Campus, National Institute of Environmental Health Sciences, Research Triangle Park, North Carolina.

Dr. Jones, a principal reviewer, agreed with the conclusions as written. Dr. Jones agreed also with the decision to discount the biologic significance of the increased incidences of keratoacanthomas in males and neoplasms of the clitoral gland in females but asked that the reasons for this decision be discussed in greater depth. He noted that prior to the meeting he had examined the slides of large intestine sections from male rats exposed to the IR form and agreed that the adenomatous polyps were clearly neoplastic.

Dr. Turnbull, a second principal reviewer, also agreed with the conclusions. He suggested, however, that more details be given regarding the choice of a 1% dose and the relation of this dose to the maximum tolerated dose, if any. Dr. R. Shapiro, NIEHS, said the 1% level represented an appropriate dose based on earlier feed studies in rats and was much greater than the estimated dose to which humans are exposed. Dr. Turnbull asked for clarification of the use and temporal relationship of the various control groups. Dr. E. McConnell, NTP, explained that the rats used for concurrent controls in this study and those used for pooled control groups in the three previous NTP dosed feed studies of the other asbestos fiber types came from the same animal source, were used in studies conducted at the same laboratory, and were on test at approximately the same times. Dr. J. Haseman, NIEHS, said the concurrent controls were used in the primary statistical analysis. When a possible carcinogenic effect was observed, the additional control groups were employed to help evaluate further the biologic significance of the effect.

A third principal reviewer, Dr. Davis, questioned the use of the pooled control data to support the biologic importance and statistical significance of the intestinal tumors and, on the other hand, to discount the importance of the keratoacanthomas in male rats and clitoral gland neoplasms in female rats. Dr. McConnell stated that no increases in incidences of skin neoplasms have been observed in asbestos inhalation studies sponsored by the NTP or by others in which the whole animal was exposed. Dr. Friess said the reason for discounting needed to be highlighted nonetheless. Dr. Davis asked if the standard paper feed bags were impermeable to the pelleted asbestos and if the pelleting process may have altered the fiber size of the asbestos. Mr. Beliczky wondered whether there may have been incidental inhalation exposure of the test animals. Dr. McConnell replied that a pelleted dose form was used to minimize exposure of laboratory personnel and the amount of exposure by inhalation. Dr. Shapiro noted that fiber size distribution for all the fiber types was examined before and after pelleting, and few or no differences were found.

Dr. Kotelchuck observed that the apparent kidney-tumor-enhancing effect of IR asbestos in female rats dosed with dimethylhydrazine dihydrochloride should be noted in the conclusions. Dr. McConnell agreed. Dr. A. Berlin, Commission of the European Communities, asked if there had been any attempt to measure asbestos at the tumor sites. Dr. McConnell replied that since this was a lifetime exposure, the presence of fibers throughout the intestine would be expected, and further, translocation artifacts would likely confound such an analysis.

HWBUI0001503

Dr. Jones moved that the Technical Report on the toxicology and carcinogenesis studies of chrysotile asbestos be accepted with the modifications as discussed. Dr. Turnbull seconded the motion and the report was approved unanimously by the Peer Review Panel.

HWBUI0001504

I. INTRODUCTION

HWBUI0001505

I. INTRODUCTION

The term "asbestos" has a commercial/industrial derivation limited to naturally occurring fibrous minerals of the serpentine or amphibole series. Chrysotile is the only asbestos in the serpentine series, whereas the amphibole series is represented by actinolite, amosite, anthophyllite, crocidolite, and tremolite. The essential characteristic of asbestos minerals is their fibrous nature. The gross fibers, which are visible to the naked eye, are actually bundles of much finer fibrils that are submicroscopic in size (Bureau of Mines, 1980).

Studies conducted during the past 25 years have established a clear association between occupational exposure to asbestos and increased risk of cancer. Human studies have shown that increased tumor risk is associated with crocidolite, chrysotile, amosite, and anthophyllite exposure. Crocidolite asbestos is considered the most "dangerous" form of asbestos in humans because of its strong association with mesothelioma (Craighead, 1982). Excellent reviews of the carcinogenic and public health effects associated with inhaled asbestos are those by Selikoff (1980) and Selikoff and Hammond (1979) and those published by the U.S. Environmental Protection Agency (USEPA, 1980), the International Agency for Research on Cancer (IARC, 1977), and Environmental Health Perspectives (EHP, 1983). Lung cancer and mesothelioma are the neoplasms most frequently observed in humans exposed to asbestos. A modest increase in the incidence of gastrointestinal tumors has been observed in asbestos insulation workers, miners, and factory workers. The increased incidence of gastrointestinal cancer and possible peritoneal mesothelioma in occupationally exposed populations may be the consequence of direct fiber ingestion or ingestion of inhaled fibers that were cleared from the nasal or tracheobronchial portions of the respiratory system by mucociliary processes.

Large portions of the population ingest chrysotile asbestos through consumption of food and water (Rowe, 1983). Analysis of water samples from 359 cities found that 65% of the samples had detectable levels of various types of asbestos, including chrysotile (Millette et al., 1983). The water supplies of 41 cities have had asbestos concentrations in water which exceeded 10 million fibers per liter, but the length of the vast majority of fibers is under 5 µm. Asbestos or asbestos-like fibers may enter water supplies as a result of mining (e.g., operations at Lake Superior). Natural serpentine or amphibole deposits have been detected in watersheds (Seattle, Washington, and San Francisco, California); under certain conditions, the presence of asbestos may have resulted from the use of chrysotile asbestos-cement pipe for municipal water supplies (USEPA, 1980). In the latter instance, erosion of the pipe (and release of fibers) is associated with the "aggressiveness" of the water, a term representing a mathematical expression of alkalinity and calcium content. Approximately 69% of the water systems in the United States have aggressive water that has the potential to erode asbestos-cement pipe (USEPA, 1980).

The health effects of ingested asbestos have been reviewed recently (EHP, 1983). Harrington et al. (1978) failed to detect an association between the use of asbestos-cement pipe for municipal water supplies and the incidence of gastrointestinal cancer. Statistically significant trends for the incidence of several cancer types, including stomach, gallbladder, esophageal, and peritoneal cancer, were found when census tracts were analyzed on a gradient of low to high asbestos content in municipal water in the San Francisco Bay area (Cooper et al., 1979). The association between asbestos concentration in San Francisco Bay area drinking water and cancer was confirmed in subsequent studies (Kanarek, 1983; Conforti, 1983). The presence of chrysotile asbestos in the drinking water (200×10^6 fibers/liter) was not clearly associated with an increased cancer risk in the Everett, Washington area (Polissar et al., 1983).

Beer and wine have in the past contained asbestos, possibly from asbestos filters used in the preparation of these products (Cunningham and Pontefract, 1971). According to one hypothesis, the ingestion of rice treated with talc that contains chrysotile asbestos is associated with an increased incidence of stomach cancer in Japan (Merliss, 1971a,b).

Studies of the migration of asbestos fibers through the gastrointestinal mucosa have been

HWBUI0001506

confounded by asbestos contamination from water during tissue section preparation; contamination from the gut lumen, blood plasma, or lymph fluid; or contamination from filters used for sample preparation (Meek, 1983). Several studies have provided evidence that ingestion of asbestos in either food or water can result in the migration of asbestos through the gastrointestinal mucosa. Chrysotile asbestos has been reported in the urine of humans and in the lymph fluid and kidney cortex of rats (Patel-Mandlik and Millette, 1983) and baboons (Patel-Mandlik and Millette, 1980) exposed by ingestion or gavage. The amounts of chrysotile detected accounted for only 10^{-4} to 10^{-7} of the amount ingested (Cook, 1983; Sebastien et al., 1980).

Inhalation of asbestos by laboratory animals produces lung carcinoma and mesothelioma in the pleural cavity. Intrapleural, intratracheal, and intraperitoneal injection of asbestos will also produce neoplasia in several species of laboratory animals. These studies have been reviewed by Levine (1978).

Stanton et al. (1981) in their classic intrapleural inoculation studies have clearly shown that the carcinogenic potential of various types of natural and manmade fibers are related to their length and width and the ratio thereof (aspect ratio). They determined that the more carcinogenic fibers were greater than 8 μm in length and less than 1.5 μm in diameter.

Asbestos (chrysotile, amosite, and crocidolite) has been shown to be cytotoxic in vitro to human embryonic intestinal cells, mouse epithelial-like colon-derived cells, and rat liver epithelial cells (Reiss et al., 1979). Chrysotile asbestos was far more toxic than the amphibole fibers, and the effects were more pronounced in the intestine-derived cells than in those from the liver. Asbestos also was found to be cytotoxic to Syrian hamster (Bey and Harrington, 1971) and mouse (Wright et al., 1983) peritoneal macrophages and to rabbit alveolar macrophages (Desai and Richards, 1983).

Chrysotile asbestos was not mutagenic in *Salmonella typhimurium* or *Escherichia coli* (Chamberlain and Tarmy, 1977) or at the HGPRT locus in mammalian cells (Reiss et al., 1982; Oshimura et al., 1984). However, Huang et al. (1978) reported a weak but statistically significant increase in mutation frequency at the HGPRT locus in V79 cells if the results of several experiments were combined. Although chrysotile asbestos does not appear to cause gene mutations, it has been shown to cause chromosomal aberrations and alterations in the number of chromosomes. Chrysotile asbestos induced chromosomal aberrations in Chinese hamster ovary (CHO) cells (Sincock and Seabright, 1975; Sincock, 1977), human lymphocytes in vitro (Valerio et al., 1983), and Syrian hamster embryo (SHE) cells (Oshimura et al., 1984). However, it did not induce chromosomal aberrations in the bone marrow of Rhesus monkeys or Swiss mice (Lavappa et al., 1975) or in primary human fibroblasts or human lymphoblastoid lines (Sincock et al., 1983). Chrysotile asbestos did not induce sister-chromatid exchanges (SCE's) in rat mesothelial cells (Kaplan et al., 1980) or human fibroblasts, human lymphoblastoid, or CHO cells (Casey, 1983); however, in another study, chrysotile did induce SCE's in CHO cells (Babu et al., 1981).

Polyploidy, which is the gain of one or more entire sets of chromosomes, was associated with chrysotile asbestos treatment of CHO cells (Sincock and Seabright, 1975; Sincock, 1977) and SHE cells (Oshimura et al., 1984). However, chrysotile asbestos did not induce polyploidy in human lymphocytes (Valerio et al., 1983) or human fibroblasts (Sincock et al., 1983). Chrysotile asbestos also has been shown to induce aneuploidy, which is the gain or loss of one or more individual chromosomes, in human lymphocytes in vitro (Valerio et al., 1983) and in SHE cells (Oshimura et al., 1984). In addition, chrysotile asbestos has been shown to induce binucleated cells (Brown et al., 1979; Jaurand et al., 1983; Oshimura et al., 1984). Recently, Hesterberg and Barrett (1984) and Oshimura et al. (1984) have shown that chrysotile abestos caused morphologic transformation of SHE cells. In summary, chrysotile asbestos does not appear to be a gene mutagen, but it does induce cytogenetic alterations, including chromosomal aberrations, polyploidy, and aneuploidy. It also causes morphologic transformation of mammalian cells in vitro.

HWBUI0001507

I. INTRODUCTION

In 1973, the National Institute of Environmental Health Sciences and the Environmental Protection Agency cosponsored a symposium on the possible biologic effects of ingested asbestos (EHP, 1974). The participants at this conference concluded that the data concerning the effects of ingested asbestos were inadequate and that specific research was needed.

A subcommittee of the Department of Health, Education, and Welfare Committee to Coordinate Toxicology and Related Programs subsequently reviewed existing data and prepared a draft research protocol that the Committee felt was responsive to the major public health consensus. On the basis of comments received, a revised protocol was developed for long-term animal toxicology and carcinogenesis studies. The forms of asbestos included chrysotile tested in Syrian golden hamsters (NTP TR 246, in press) and in F344/N rats (this report), amosite in Syrian golden hamsters (NTP, 1983) and in F344/N rats (NTP TR 279, in press), crocidolite in F344/N rats (NTP TR 280, in press), and a nonfibrous tremolite, which contained low levels of asbestiform fibers, in F344/N rats (NTP TR 277, in press). Certain studies (IR chrysotile in hamsters and amosite and IR chrysotile in rats) also incorporated the intestinal carcinogen 1,2-dimethylhydrazine dihydrochloride (DMH) as part of the protocol to test the cocarcinogenic effects of asbestos. DMH is a well-known intestinal carcinogen in animals and produces epithelial neoplasms at sites of intimate exposure to asbestos. All studies encompassed the lifetime of the animal, including exposure of the dam from which the test animals were derived. A single dose level of 1% of the diet was chosen because it represented the highest dose thought to be reasonable from a biologic standpoint and could be tolerated in a lifetime study.

This Technical Report presents the results of those studies undertaken to determine the effects of short-range (SR) or intermediate-range (IR) chrysotile asbestos fed to male and female F344/N rats in the diet. These studies were conducted because of the widespread human exposure via the oral route and the known carcinogenic potential of inhaled asbestos in animals and humans. In addition, the study was designed to determine if the ingestion of IR chrysotile asbestos modified the response to DMH.

HWBUI0001508

II. MATERIALS AND METHODS

PROCUREMENT AND CHARACTERIZATION OF TEST MATERIALS

PREPARATION OF FORMULATED DIETS AND DOSE MIXTURES

Formulated Diets

Dose Mixtures of Asbestos for Gavage Administration

Dose Mixtures of 1,2-Dimethylhydrazine Dihydrochloride for Gavage Administration

LIFETIME STUDIES OF SHORT-RANGE OR INTERMEDIATE-RANGE CHRYSOTILE ASBESTOS

Study Design

Source and Specifications of Test Animals

Animal Maintenance

Safety Precautions

Clinical Examinations and Pathology

Statistical Methods

HWBUI0001509

II. MATERIALS AND METHODS

PROCUREMENT AND CHARACTERIZATION OF TEST MATERIALS

Asbestos is a general term applied to certain natural silicates when they are present in a fibrous form. Chrysotile is a fibrous member of the serpentine mineral group; its chemical formula is $Mg_3Si_2O_5(OH)_4$. Two types of chrysotile were selected for testing; they are referred to as short-range (SR) and intermediate-range (IR) chrysotile based on relative fiber length (Table 1).

The SR chrysotile asbestos was purchased from the Union Carbide Corporation (Niagara Falls, New York), which referred to the material as COF-25. The chrysotile had been mined from the New Idria serpentine mass located in the southern part of the Diablo Range in southwestern San Benito and western Fresno counties of California.

The IR asbestos was purchased from the Johns Manville Company, which referred to the material as Plastobest-20. This material is a particularly clean grade of chrysotile used in the plastics industry. The chrysotile originated in the Jeffrey mine, Asbestos, Quebec, Canada.

Each of the two chrysotile asbestos test materials was purchased in quantities of about 1,000 pounds. Each material was packaged in new fiberboard drums of 25 (short-range) or 50 (intermediate-range) pounds and stored with other forms of asbestos in a special warehouse room at Research Triangle Park, North Carolina. Each drum received a color marking unique to the specific asbestos type.

The homogeneity of the samples and the physical and chemical properties of the materials were extensively characterized by the Bureau of Mines, U.S. Department of the Interior (Bureau of Mines, 1980) and by the Fine Particle Laboratories, Illinois Institute of Technology Research Institute, Chicago, Illinois (IITRI, Special Report and Addendum on Project L6085, Contract NO1-ES-5-3157). Copies of these reports are available upon request from the National Toxicology Program. Selected chemical and physical properties that define differences between the two chrysotile test materials are given in Table 1.

Short-range chrysotile was detected at greater than 96% by volume; minor amounts of calcite, brucite, talc, feldspar, quartz, and other opaques were present. Intermediate-range chrysotile was detected at greater than 96% by volume; minor amounts of platy serpentine, calcite, brucite, pyroxene, talc, magnetite, and other opaques were also detected.

Crystalline 1,2-dimethylhydrazine dihydrochloride (DMH) (greater than 97% pure) was obtained from Aldrich Chemical, Metuchen, New Jersey, (lot no. 072967JA). Thin-layer chromatographic analysis of a 200-µg sample did not detect any hydrazine or 1,1-dimethylhydrazine. Faint traces of methylazoxymethane and azoxymethane were detected by high-performance liquid chromatography (Fiala et al., 1976). Three percent of the impurities in DMH were not accounted for. 1,2-Dimethylhydrazine dihydrochloride was stored at 4° C.

PREPARATION OF FORMULATED DIETS AND DOSE MIXTURES

Formulated Diets

NIH 31 open formula rodent diet, prepared by Zeigler Brothers Inc. (Gardners, Pennsylvania), was used. The appropriate chrysotile asbestos at a concentration of 1% was mixed with feed. Pilot studies were conducted in which transmission electron microscopy was used to assess fiber distribution and alteration; and atomic absorption analysis for magnesium was used to assess chrysotile concentration. From these studies, it was determined that a homogeneous mixture of asbestos and feed could be obtained by mixing alternate layers of feed and asbestos in a Patterson-Kelly® V-blender equipped with an intensifier bar. All feed was pelleted with a California pellet mill; the pellets were oval, three-eighths of an inch by three-fourths of an inch. Pelleted feed was packaged in 25-lb, color-coded, standard paper feed bags. Each lot of blended feed was analyzed for asbestos concentration by atomic absorption analysis for magnesium; the results of these analyses are given in Appendix G. The concentration of IR chrysotile asbestos in feed was within 10% of the target concentration 79% (31/39) of the time. The concentration of SR chrysotile asbestos in feed was within 10% of the target concentration 59% (13/22) of the time.

HWBUI0001510

TABLE 1. FIBER CHARACTERISTICS AND CHEMICAL-INSTRUMENTAL ANALYSES OF CHRYSOTILE ASBESTOS (a)

	Short Range	Intermediate Range
Fiber Characteristics		
Surface area (m^2/g)	(b) 54.3 ± 3.9 (c) 54.2 ± 0.9	(b) 20.2 ± 0.1 (c) 24.9 ± 2.2
Density (g/cm^3)	2.577 ± 0.022 (8)	2.607 ± 0.016 (8)
Measurement, transmission electron microscopy		
Fiber count/gram	0.6081×10^{13}	0.1291×10^{12}
Median length (µm)	0.66	0.82
Range of length (µm) (d)	0.088-51.1	0.104-783.4
Median diameter (µm)	0.059	0.089
Range of diameter (µm)	0.019-1.67	0.019-11.5
Median fiber aspect ratio (length divided by diameter)	11.1698	8.435
Frequency distribution by length (µm); optical microscopy		
10 percentile	1.3	1.4
20 percentile	1.7	1.9
30 percentile	2.2	3.0
40 percentile	2.6	5.4
50 percentile	3.1	14.0
60 percentile	3.8	29.0
70 percentile	4.5	48.0
80 percentile	5.8	76.0
90 percentile	7.8	130.0
Chemical Instrument Analyses (expressed as weight percent)		
Al_2O_3	0.66	1.47
CaO	0.32	0.05
FeO	Not detected	Not detected
Fe_2O_3	2.02	2.93
MgO	40.62	40.26
K_2O	Not detected	0.08
SiO_2	39.77	39.90
Na_2O	0.01	0.04
TiO_2	0.03	0.04
MnO	0.07	0.06
Cr_2O_3	0.17	0.06
NiO	0.17	0.06
Co_2O_3	0.01	Not detected
CO_2	0.78	0.51
H_2O-	1.54	1.17
H_2O+	12.69	12.81
Benzene extracted organics	0.026	0.011

(a) Measurements by transmission electron microscopy were performed at the Illinois Institute of Technology Research Institute; all other analyses were performed by the Bureau of Mines (RI 8452, 1980).
(b) As measured with the Quantachrome surface area instrument on 15-30 independent samples
(c) As measured with the Perkin-Elmer surface area instrument on 15-30 independent samples
(d) Short range comprises short fibers, with 98% <10 µm. Intermediate range consists of 65% >10 µm, with a significant number of fibers (~14%) longer than 100 µm.

HWBUI0001511

Dose Mixtures of Asbestos for Gavage Administration

The appropriate weighed amount of IR chrysotile asbestos was mixed with sterile water in a beaker with a magnetic stirrer to prepare the dosing suspension.

Dose Mixtures of 1,2-Dimethylhydrazine Dihydrochloride for Gavage Administration

Immediately before use, DMH was mixed with ice-cooled 0.2 M acetate buffer (pH 5.0) in 15-ml screw-cap, Teflon®-lined centrifuge tubes in an ice bath. Results of colorimetric analysis of the dose mixtures indicated that the concentration of DMH was usually less than 80% of the target concentration of 3.9 and 7.8 mg/ml (Appendix G, Table G3).

LIFETIME STUDIES OF SHORT-RANGE OR INTERMEDIATE-RANGE CHRYSOTILE ASBESTOS

Study Design

Groups of 88-250 rats of each sex were fed pelleted diets containing 0% or 1% chrysotile asbestos (either SR or IR) in lifetime studies. The mothers of those in the groups that were administered asbestos started receiving asbestos 7-12 days before mating. Subgroups of 100 male and 100 female rats also received 0.47 mg/g IR chrysotile asbestos in water by gavage, 7 days per week for 3 weeks, starting at 1 day of age. These two groups were referred to as the preweaning (PW) gavage groups. At 9 weeks of age, subgroups of 125-175 rats (one control and one IR group) received 7.5 mg/kg (male) or 15 mg/kg (female) DMH in acetate buffer (pH 5.0) by gavage, every other week for a total of five doses. These doses were based on a pilot study (McConnell et al., 1980) which showed that DMH at these doses produced an incidence of approximately 15% intestinal neoplasia. When the survival of either of the paired groups reached 10%, both groups were killed (Table 2).

Source and Specifications of Test Animals

Parental Generation: The male and female F344/N rats used in this study were produced under strict barrier conditions at Charles River Breeding Laboratories under a contract to the Carcinogenesis Program. Breeding starts for the foundation colony at the production facility originated at the National Institutes of Health Repository. Animals shipped for testing were progeny of defined microflora-associated parents that were transferred from isolators to barrier-maintained rooms. The rats were shipped to the testing laboratory and were quarantined for 4 weeks (intermediate-range studies) or 5 weeks

TABLE 2. SUMMARY OF DISTRIBUTION OF RATS IN THE LIFETIME FEED STUDIES OF INTERMEDIATE-RANGE CHRYSOTILE ASBESTOS

Generation	Test Group	No. of Animals		Chrysotile		DMH (mg/kg) (a)	
		Male	Female	Percent	mg/g	Male	Female
F_0	control	60	120	0	--	--	--
	IR chrysotile (b)	200	400	1.0	--	--	--
F_1	control	88	88	0	--	--	--
	DMH	125	125	0	--	7.5	15.0
	IR chrysotile	250	250	1.0	--	--	--
	IR chrysotile and DMH	175	175	1.0	--	7.5	15.0
	IR chrysotile and preweaning gavage	100	100	1.0	(c) 0.47	--	--

(a) 1,2-dimethylhydrazine dihydrochloride (DMH) administered by gavage
(b) Intermediate-range chrysotile asbestos
(c) Preweaning gavage with IR chrysotile

HWBUI0001512

(short-range studies) (Figure 1). Thereafter, a complete pathologic examination was performed on eight animals of each sex to assess their health. Males and females then were assigned to test or control diets, according to a table of random numbers. After 11-13 days (intermediate range) or 7 days (short range), the parents of the test rats were placed in breeding cages (one male to two females). After approximately 20 days, females were housed individually and males were rehoused two per cage.

Filial Generation: Litters were culled to no more than eight pups. Litters of the control and dosed groups were assigned to the corresponding control or dosed groups such that birth dates were equally distributed. Litters in which only one sex was present were excluded. After weaning at 21 days, pups from exposed or control dams were randomly assigned to various exposed (except the IR/PW gavage group) or control groups according to a table of random numbers (Table 2). Pups assigned to the IR/PW chrysotile gavage group were administered 0.47 mg/g IR chrysotile asbestos in sterile water by gavage during lactation as described previously.

Animal Maintenance

F_1 rats were housed three per cage in polycarbonate cages. Control or formulated diets and water were available ad libitum (Table 3).

Safety Precautions

The incoming air to the animal rooms was filtered to remove particulate matter. Ten to 15 changes of room air per hour were provided. Before initiation of the study, air samples were collected and analyzed for baseline asbestos concentrations. Additional samples were collected approximately every 6 months for analysis to assure personnel safety.

Other measures used for personnel protection included the wearing of fully protective disposable suits, gloves, boots, and bouffant caps and the use of a dust/mist respirator mask approved by the Occupational Safety and Health Administration (OSHA). Personnel leaving the animal rooms were required to dispose of their protective clothing and to take showers. In addition, physical examinations including pulmonary function tests and chest radiographs were conducted at the initiation of the study, yearly thereafter, and at the end of the study.

Clinical Examinations and Pathology

Rats were observed two times per day. Body weights by cage were recorded once per week for the duration of the study. Mean body weights were calculated for each group. Moribund animals were killed, as were animals that survived to the end of the study. A necropsy was performed on all animals, including those found dead unless they were excessively autolyzed or cannibalized. Thus, the number of animals from which particular organs or tissues were examined microscopically varies and is not necessarily equal to the number of animals that were placed on study in each group. Animals were killed when exhibiting any one of these conditions:

1. Palpable masses within the abdominal cavity (excluding retained testes)
2. Masses protruding from the rectum.
3. Rectal discharge of bright red fluid (an indication of the presence of a bleeding colonic or rectal neoplasm)
4. Large ulcerated masses in the area of the ears or on the side of the face (Zymbal gland tumors)
5. Large subcutaneous masses that were ulcerated or infected.
6. Masses that interfered with breathing and eating or that severely hampered locomotion
7. Huge tissue masses
8. Central nervous system signs accompanied by weight loss (head tilt, circling, incoordination, ataxia, paralysis)
9. Severe weight loss or emaciation
10. Coma or extreme weakness.

When the remaining number of animals of either sex in the DMH group or the corresponding IR + DMH group was reduced to 10% of those starting the study, both groups of that sex were killed. When survival of the control, IR chrysotile, or IR/PW groups of either sex reached 10%, all remaining animals of that sex in those groups were killed.

HWBUI0001513

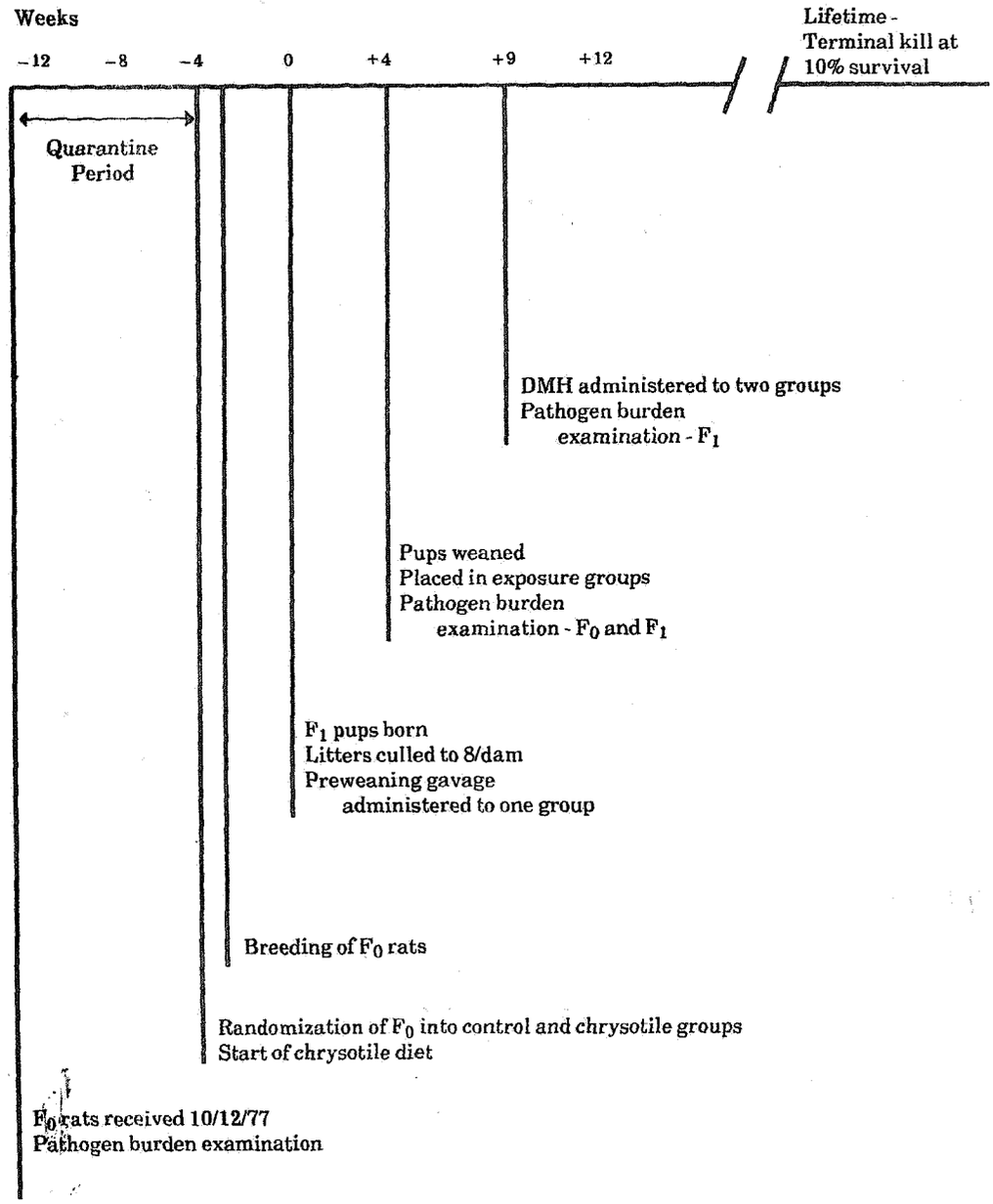

FIGURE 1. SCHEDULE OF MAJOR EVENTS IN RATS IN THE LIFETIME FEED STUDIES OF INTERMEDIATE-RANGE CHRYSOTILE ASBESTOS

HWBUI0001514

TABLE 3. EXPERIMENTAL DESIGN AND MATERIALS AND METHODS IN THE LIFETIME FEED STUDIES OF SHORT-RANGE AND INTERMEDIATE-RANGE CHRYSOTILE ASBESTOS

	Short-Range (SR) Studies	Intermediate-Range (IR) Studies
EXPERIMENTAL DESIGN		
Size of Test Groups	Untreated--88; SR--250 rats of each sex	Untreated--88; IR--250; IR + PW (a)--100; DMH (b)--125; IR + DMH--175 rats of each sex
Doses	0% or 1%	IR--0% or 1%; PW--0.47 mg/g; DMH--7.5 mg/kg (male), 15 mg/kg (female)
Date of First Dose	F_0--11/1/77, bred starting 11/8/77; F_1--1/15/78 (date of weaning)	F_0--11/9-11/11/77, bred starting 11/22/77; F_1--1/12/78 (date of weaning)
Duration of Dosing	131 wk (male); 139 wk (female)	IR--136 wk (male), 139 wk (female) DMH--125 wk (male), 112 wk (female)
Type and Frequency of Observation	Observed 2 × d; examined clinically 1 × wk; weighed 1 × wk	Same as SR studies
Necropsy and Histologic Examination	A necropsy was performed on all animals. Tissues examined histologically: blood smear; mandibular lymph node; mammary gland; salivary glands; sternebrae, femur, or vertebrae including marrow; thyroid gland; parathyroids; duodenum; ileum; jejunum; cecum; rectum; colon (carpet rolled); liver; prostate/testes/epididymis or ovaries/uterus; heart; stomach; esophagus; brain; thymus; trachea; pancreas; spleen; kidneys; adrenal glands; urinary bladder; pituitary gland; spinal cord (if neurologic signs were present); eyes (if grossly abnormal); Zymbal gland; lungs and mainstem bronchi; gross lesions; regional lymph nodes	Same as SR studies
ANIMALS AND ANIMAL MAINTENANCE		
Strain and Species	F344/N	F344/N
Animal Source	Charles River Breeding Laboratories (Wilmington, MA)	Same as SR studies
Testing Laboratory	Hazleton Laboratories of America	Same as SR studies
Time Held Before Test	F_0--5 wk	F_0--4 wk
Age When Placed on Study	F_0--9-10 wk	F_0--8-9 wk
Age When Killed	F_1--131 wk (male); 139 wk (female)	F_1--IR and IR + PW--136 wk (male), 139 wk (female); DMH--125 wk (male), 112 wk (female)

HWBUI0001515

TABLE 3. EXPERIMENTAL DESIGN AND MATERIALS AND METHODS IN THE LIFETIME FEED STUDIES OF SHORT-RANGE AND INTERMEDIATE-RANGE CHRYSOTILE ASBESTOS (Continued)

	Short-Range Studies	Intermediate-Range Studies
ANIMALS AND ANIMAL MAINTENANCE (Continued)		
Necropsy Dates	Lifetime study	Lifetime study
Method of Animal Distribution	Computer-generated random number tables	Same as SR studies
Feed	NIH 31 autoclavable pellets (Zeigler Bros., Inc., Gardners, PA); available ad libitum	Same as SR studies
Bedding	Sani Chips® (J. P. Murphy, Rochelle Park, NJ, and Shurfire, Baltimore, MD)	Same as SR studies
Water	Tap water ad libitum	Same as SR studies
Cages	Polycarbonate (Hazleton Systems, Aberdeen, MD)	Same as SR studies
Cage Filters	Remay nonwoven polyester sheets (Nationwide Papers, Washington, DC)	Same as SR studies
Animals per Cage	F_0--1 male, 2 females during breeding, 2 males, 1 female after breeding; F_1--3	Same as SR studies
Other Chemicals on Test in the Same Room	None	None (control and dosed animals housed in separate rooms)
Animal Room Environment	Temp--23° C ± 2° C; hum--50% ± 10%; fluorescent light 12 h/d 10-15 room air changes/h	Same as SR studies
CHEMISTRY		
Lot Numbers Used	N/A	IR--N/A; DMH--072967JA
Supplier	Union Carbide (Niagara Falls, NY); obtained from serpentine mass in the southern Diablo range, CA	Johns Manville; obtained from Jeffrey Mine, Asbestos, Quebec, Canada
CHEMICAL/VEHICLE		
Preparation	20 lb asbestos/ton of feed mixed in a Patterson-Kelly® V-blender with intensifier bar; pellets prepared with a California model CL-3 pellet mill	IR--same as SR studies DMH--mixed with ice-cooled 0.2 M acetate buffer, pH 5.0; PW--gavage solution mixed with sterile water on a magnetic stirrer
Maximum Storage Time	N/A	IR--N/A; DMH--used on the day of preparation
Storage Conditions	N/A	IR--N/A; DMH--kept on ice during use

(a) PW--preweaning gavage
(b) DMH--1,2-dimethylhydrazine dihydrochloride

HWBUI0001516

The gastrointestinal tract, chosen as one of the target organs before these studies began, was handled in a slightly different manner than in standard long-term rodent studies. Before being placed in fixative, the entire esophagus was opened and pinned with the exterior surface adjacent to cardboard. The stomach and cecum were prepared similarly. Two-centimeter lengths of duodenum and ileum and two portions of jejunum were placed unopened in fixative. The remaining small intestine was opened, washed gently with saline, and carefully examined by transillumination on a radiograph viewing box. Suspected lesions were processed separately and identified individually as to location. Likewise, the entire colon with anus was opened, examined, and pinned to cardboard before fixation. The size and location of masses were recorded. Masses greater than 1 mm in diameter were removed as separate specimens for processing. After fixation and before embedding, the colon was "carpet-rolled" starting at the posterior end, with the mucosal surface inward.

Examinations for grossly visible lesions were performed on major tissues or organs. Tissues were preserved in 10% neutral buffered formalin, embedded in paraffin, sectioned, and stained with hematoxylin and eosin. Tissues examined microscopically are listed in Table 3.

When the pathology examination was completed, the slides, individual animal data records, and summary tables were sent to an independent quality assurance laboratory. Individual animal records and tables were compared for accuracy, slides and tissue counts were verified, and histotechnique was evaluated. All tumor diagnoses, all target tissues, and all tissues from a randomly selected 10% of the animals were evaluated by a quality assurance pathologist. Slides of all target tissues and those about which the original and quality assurance pathologists disagreed were submitted to the Chairperson of the Pathology Working Group (PWG) for evaluation. Representative coded slides selected by the Chairperson were reviewed by PWG pathologists, who reached a consensus and compared their findings with the original and quality assurance diagnoses. When diagnostic differences were found, the PWG sent the appropriate slides and comments to the original pathologist for review. This procedure has been described, in part, by Maronpot and Boorman (1982) and Boorman et al. (1985). The final diagnoses represent a consensus of contractor pathologists and the NTP Pathology Working Group.

Statistical Methods

Data Recording: Data on this experiment were recorded in the Carcinogenesis Bioassay Data System (Linhart et al., 1974). The data elements include descriptive information on the chemicals, animals, experimental design, survival, body weight, and individual pathologic results, as recommended by the International Union Against Cancer (Berenblum, 1969).

Survival Analyses: The probability of survival was estimated by the product-limit procedure of Kaplan and Meier (1958) and is presented in the form of graphs. Animals were censored from the survival analyses at the time they were found dead of other than natural causes or were found to be missing; animals dying from natural causes were not censored. Statistical analyses for a possible dose-related effect on survival used the method of Cox (1972). All reported P values for the survival analysis are two-sided.

Calculation of Incidence: The incidence of neoplastic or nonneoplastic lesions has been given as the ratio of the number of animals bearing such lesions at a specific anatomic site to the number of animals in which that site was examined. In most instances, the denominators include only those animals for which the site was examined histologically. However, when macroscopic examination was required to detect lesions (e.g., skin or mammary tumors) prior to histologic sampling, or when lesions could have appeared at multiple sites (e.g., lymphomas), the denominators consist of the number of animals on which a necropsy was performed.

Analysis of Tumor Incidence: Three statistical methods are used to analyze tumor incidence data. The two that adjust for intercurrent mortality employ the classical method for combining contingency tables developed by Mantel and Haenszel (1959). Tests of significance included pairwise comparisons of

HWBUI0001517

dosed groups with untreated controls and with each other.

For studies in which compound administration has little effect on survival, the results of the three alternative analyses will generally be similar. When differing results are obtained by the three methods, the final interpretation of the data will depend on the extent to which the tumor under consideration is regarded as being the cause of death. All reported P values for tumor analyses are one-sided.

Life Table Analyses--The first method of analysis assumed that all tumors of a given type observed in animals dying before the end of the study were "fatal"; i.e., they either directly or indirectly caused the death of the animal. According to this approach, the proportions of tumor-bearing animals in the various groups were compared at each point in time at which an animal died with a tumor of interest. The denominators of these proportions were the total number of animals at risk in each group. These results, including the data from animals killed at the end of the study, were then combined by the Mantel-Haenszel method to obtain an overall P value. This method of adjusting for intercurrent mortality is the life table method of Cox (1972).

Incidental Tumor Analyses--The second method of analysis assumed that all tumors of a given type observed in animals that died before the end of the study were "incidental"; i.e., they were merely observed at necropsy in animals dying of an unrelated cause. According to this approach, the proportions of tumor-bearing animals in dosed and control groups were compared in each of five time intervals: DMH studies (including controls)--0-52 weeks, 53-78 weeks, 79-104 weeks, week 105 to the week before the terminal kill period, and the terminal kill period; IR chrysotile (including controls) without DMH and SR chrysotile studies--0-60 weeks, 61-86 weeks, 87-112 weeks, 113-126 weeks, and week 127 to the end of the studies. The denominators of these proportions were the number of animals on which a necropsy was actually performed during the time interval. The individual time interval comparisons were then combined by the previously described method to obtain a single overall result. (See Haseman, 1984, for the computational details of both methods.)

Unadjusted Analyses--Primarily, survival-adjusted methods are used to evaluate tumor incidence. In addition, the results of the Fisher's exact test for pairwise comparisons (Gart et al., 1979) are given in the appendix containing the analyses of primary tumor incidence. This test is based on the overall proportion of tumor-bearing animals and does not adjust for survival differences.

HWBUI0001518

III. RESULTS

LIFETIME STUDIES OF SHORT-RANGE OR INTERMEDIATE-RANGE CHRYSOTILE ASBESTOS

- Establishment of Test Groups
- Body Weights and Feed Consumption
- Pathogen Burden
- Clinical Signs
- Survival
- Pathology and Statistical Analyses of Results

HWBUI0001519

III. RESULTS

LIFETIME STUDIES OF SHORT-RANGE OR INTERMEDIATE-RANGE CHRYSOTILE ASBESTOS

Establishment of Test Groups

The experiment was designed to evaluate the effects of ingested chrysotile asbestos during the entire life of the animal. When the first litters were born, therefore, the mated female rats had been on test diets for approximately 4 weeks. To minimize the chance that the mothers would reject or cannibalize their young, the litters were not handled during lactation except for weighing and culling at birth, and the animals were administered IR chrysotile by preweaning gavage. Litter size and survival of offspring were unaffected by the presence of SR or IR chrysotile asbestos in the mothers' diet. The average number of live fetuses born to SR chrysotile-exposed dams was 7.7 versus 7.6 for the control groups; the average number born to IR chrysotile-exposed dams was 7.5 versus 7.6 for the control group. The average weight at birth of the SR chrysotile-exposed pups was 5.2 g versus 5.1 g for the controls, and average weight of the IR-exposed groups was 5.3 versus 5.0 for the controls. Fetal weights were determined by dividing the weight of each litter by the number of live pups. The SR chrysotile-exposed offspring were slightly larger (8%) at weaning, 29.1 g versus 26.7 g for the controls, whereas the IR chrysotile offspring were slightly smaller (13%) at weaning (23.3 g vs 26.8 g).

A summary of groups, number of animals, diets for the parental (F_0) animals, as well as the distribution of and diets for the filial (F_1) animals is presented in Table 2.

Body Weights and Feed Consumption

Short Range Groups: Mean body weights of dosed and control rats were comparable throughout the studies (Table 4 and Figure 2). The average daily feed consumption per rat by SR rats was 100% that of the controls for males and females (Appendix H, Tables H1 and H2).

Intermediate-Range and Preweaning Groups: The mean body weight of the male IR/PW group was approximately 5% greater than that of the controls and 14% greater than that of the IR group at week 7; for females the mean body weight of the IR/PW group was approximately 4% lower than that of controls and 5% greater than that of the IR group (Table 5 and Figure 3). The mean body weights of the males and females in the IR/PW groups were greater than those of the IR groups throughout most of the studies; the mean body weights of the IR groups were 8% lower than those of the controls at week 7 and remained lower throughout most of the studies. Average daily feed consumption by IR rats was 100% that of the controls for males and females. Average daily feed consumption by IR/PW rats was 102% that of controls for males and 100% for females (Appendix H, Tables H3 and H4).

1,2-Dimethylhydrazine Dihydrochloride With and Without Intermediate-Range Chrysotile Asbestos: The mean body weights of the controls and of the groups that received DMH without IR chrysotile asbestos were comparable throughout most of the studies (Table 5 and Figure 3). The mean body weights of groups that received DMH and IR chrysotile asbestos, especially female rats, were lower than those of groups that received DMH without IR chrysotile asbestos. Average daily feed consumption by male rats that received DMH with and without IR chrysotile asbestos was 100% that of controls. Average daily feed consumption by female rats was 100% that of the controls for those that received DMH without IR chrysotile asbestos and 92% that of the controls for those that received DMH with IR chrysotile asbestos.

Pathogen Burden

Short-Range: All lung sections of the F_0 animals evaluated for pathogen burden revealed evidence of mild respiratory disease (Appendix I). In some rats, small foci of mononuclear cells were present adjacent to the bronchial tissue and in other rats, small cuffs of lymphoid cells were evident, particularly at the bifurcation of the bronchi. These lesions were very mild.

In the lungs of all F_1 rats examined, evidence of early respiratory disease was again present. In one male rat of Group 1 (basal control) and one male rat of Group 2 (SR chrysotile), only small foci of mononuclear cells were present adjacent

HWBUI0001520

TABLE 4. MEAN BODY WEIGHTS AND SURVIVAL OF RATS IN THE LIFETIME FEED STUDIES OF SHORT-RANGE CHRYSOTILE ASBESTOS

Weeks on Study (from birth)	Control		One Percent		
	Av. Wt. (grams)	No. of Survivors	Av. Wt. (grams)	Wt. (percent of controls)	No. of Survivors
MALE					
6	129	88	130	101	250
7	152	88	156	103	250
8	175	88	182	104	250
9	200	88	205	103	250
10	222	88	224	101	250
11	236	88	240	102	250
12	250	88	254	102	250
13	262	88	267	102	250
14	271	88	275	101	250
15	280	88	285	102	250
16	283	88	290	102	250
17	295	88	291	99	250
18	301	88	299	99	250
19	310	88	308	99	250
20	314	88	316	101	250
30	366	88	356	97	250
40	394	88	396	101	250
50	423	85	424	100	250
60	430	85	429	100	249
70	452	84	451	100	248
80	467	81	462	99	246
90	470	78	470	100	237
100	461	71	456	99	213
110	444	60	430	97	180
120	430	51	411	96	131
130	376	24	383	102	73
FEMALE					
6	109	88	114	105	250
7	124	88	129	104	250
8	135	88	139	103	250
9	143	88	149	104	250
10	153	88	156	102	250
11	157	88	162	103	250
12	163	88	168	103	250
13	167	88	172	103	250
14	170	88	175	103	250
15	175	88	180	103	250
16	174	88	180	103	250
17	181	88	180	99	250
18	182	88	181	99	250
19	187	88	185	99	250
20	188	88	189	101	250
30	206	88	204	99	250
40	220	88	223	101	249
50	247	88	244	99	248
60	262	88	269	103	246
70	290	88	291	100	246
80	311	87	316	102	240
90	326	84	331	102	233
100	332	73	328	99	209
110	324	63	308	95	182
120	326	44	312	96	132
130	303	26	291	96	85
140	293	15	279	95	33

HWBUI0001521

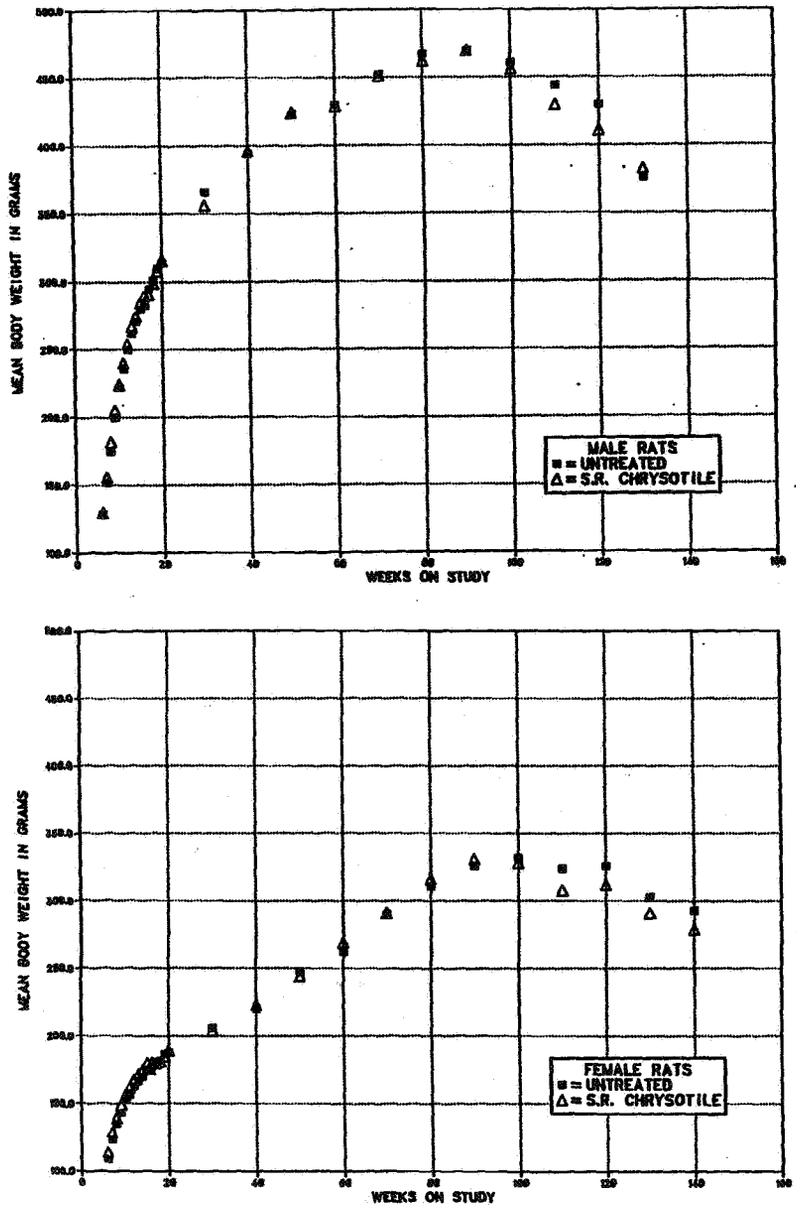

FIGURE 2. GROWTH CURVES FOR RATS FED DIETS CONTAINING SHORT-RANGE CHRYSOTILE ASBESTOS IN LIFETIME STUDIES

HWBUI0001522

TABLE 5. MEAN BODY WEIGHTS AND SURVIVAL OF RATS IN THE LIFETIME FEED STUDIES OF INTERMEDIATE-RANGE CHRYSOTILE ASBESTOS

Weeks on Study (from birth)	Control		DMH			IR			IR + DMH			IR/PW		
	Av. Wt. (grams)	No. of Survivors	Av. Wt. (grams)	Wt. (% of controls)	No. of Survivors	Av. Wt. (grams)	Wt. (% of controls)	No. of Survivors	Av. Wt. (grams)	Wt. (% of controls)	No. of Survivors	Av. Wt. (grams)	Wt. (% of controls)	No. of Survivors
MALE														
7	115	88	111	97	125	106	92	250	101	88	175	121	105	100
8	134	88	131	98	125	136	101	250	134	100	175	148	110	100
9	159	88	150	94	125	160	101	250	154	97	175	166	104	100
10	183	88	177	97	125	180	98	250	181	99	175	195	107	100
11	203	88	199	98	125	197	97	250	197	97	175	221	109	100
12	218	88	216	99	125	216	99	250	214	98	175	234	107	100
13	231	88	226	98	125	227	98	250	221	96	175	245	106	100
14	246	88	245	100	125	234	95	250	233	95	175	254	103	100
15	256	88	252	98	125	245	96	250	242	95	175	266	104	100
16	258	88	259	100	125	257	100	250	253	98	175	276	107	100
17	267	88	262	98	125	267	100	250	261	98	175	286	107	100
18	278	88	274	99	125	276	99	250	270	97	175	295	106	99
19	285	88	282	99	125	281	99	250	277	97	175	303	106	99
20	294	88	294	100	125	290	99	250	281	96	175	312	106	99
21	293	88	290	99	125	292	100	250	288	98	175	319	109	99
31	344	88	340	99	124	333	97	248	332	97	175	355	103	99
41	393	88	390	99	124	371	94	248	370	94	175	400	102	97
51	402	88	416	103	122	396	99	248	390	97	173	419	104	95
61	417	88	421	101	121	401	96	248	402	96	169	417	100	94
71	443	87	446	101	117	424	96	244	423	95	164	441	100	94
81	460	86	452	98	112	433	94	238	426	93	159	458	100	91
91	463	82	462	100	96	432	93	227	437	94	125	462	100	87
101	452	77	461	102	72	423	94	208	421	93	96	447	99	84
111	446	67	447	100	55	415	93	183	407	91	74	426	96	78
121	423	43	410	97	37	393	93	128	387	91	48	405	96	55
131	394	28	374	95	19	359	91	85	362	92	20	373	95	28
141	352	9	—	—	—	327	93	35	—	—	—	354	101	16
FEMALE														
7	106	88	102	96	125	97	92	250	93	88	175	102	96	100
8	119	88	115	97	125	114	96	250	110	92	175	116	97	100
9	131	88	126	96	125	126	96	250	120	92	175	130	99	100
10	141	88	137	97	125	134	95	250	133	94	175	140	99	100
11	144	88	145	101	125	143	99	250	137	95	175	151	105	100
12	154	88	152	99	125	149	97	250	144	94	175	155	101	100
13	158	88	152	96	125	151	96	250	144	91	175	159	101	100
14	165	88	161	98	125	154	93	250	151	92	175	164	99	100
15	166	88	160	96	125	157	95	250	153	92	175	168	101	100
16	167	88	162	97	125	162	97	250	160	96	175	173	104	100
17	169	88	164	97	125	166	98	250	162	96	175	175	104	100
18	173	88	168	97	125	169	98	250	166	96	174	180	104	100
19	175	88	173	99	125	171	98	250	170	97	174	182	104	100
20	180	88	179	99	125	175	97	250	170	94	174	184	102	100
21	178	88	174	98	125	175	98	250	173	97	174	189	106	100
31	196	88	196	100	125	190	97	249	190	97	173	201	103	99
41	219	88	217	99	124	207	95	248	204	93	172	223	102	99
51	235	88	239	102	121	224	95	247	224	95	170	241	103	99
61	259	88	261	101	119	251	97	247	247	95	165	257	99	98
71	280	88	285	102	111	272	97	244	267	95	153	277	99	97
81	303	86	303	100	104	291	96	240	280	92	137	303	100	94
91	323	81	316	98	74	302	93	229	293	91	110	313	97	87
101	330	76	325	98	46	303	92	207	294	89	71	320	97	82
111	329	63	314	95	28	303	92	179	284	86	44	315	96	73
121	324	49	—	—	—	300	93	132	—	—	—	315	97	56
131	308	27	—	—	—	268	87	91	—	—	—	301	98	31
141	286	13	—	—	—	255	89	41	—	—	—	287	100	15

HWBUI0001523

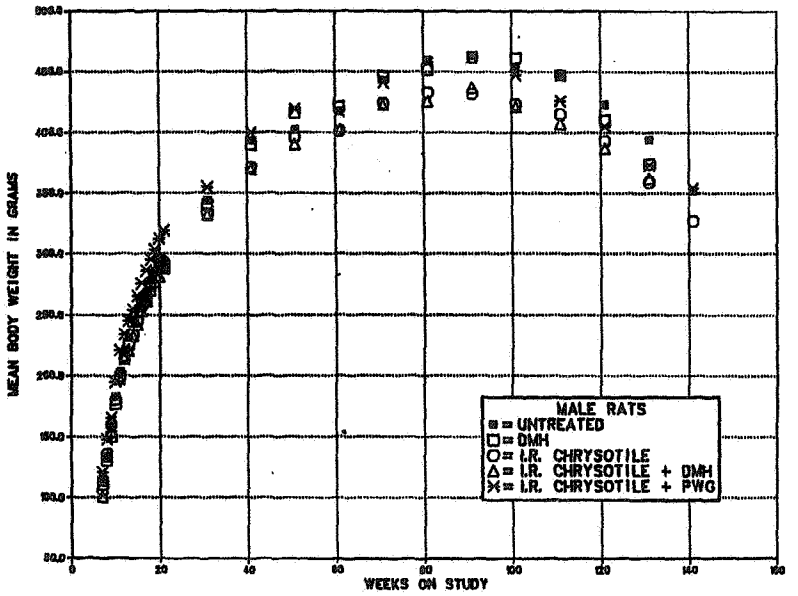

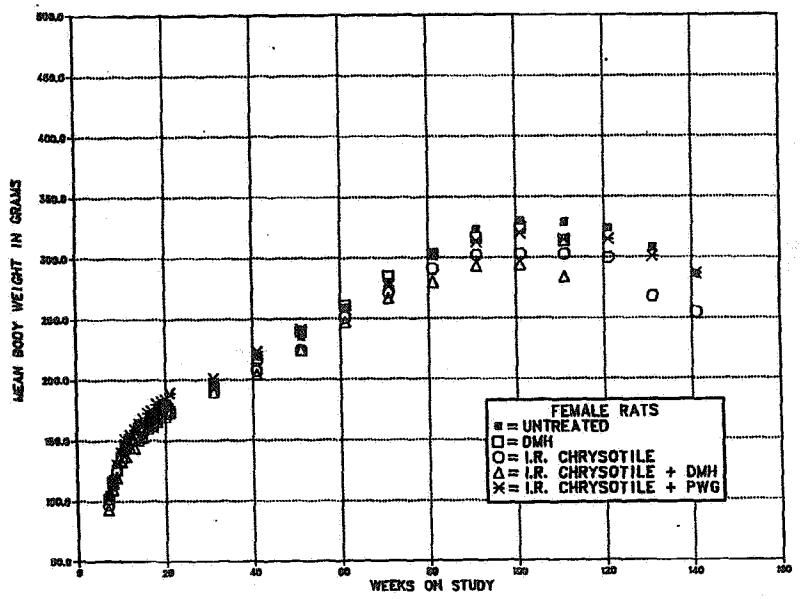

FIGURE 3. GROWTH CURVES FOR RATS FED DIETS CONTAINING INTERMEDIATE-RANGE CHRYSOTILE ASBESTOS WITH AND WITHOUT 1,2-DIMETHYLHYDRAZINE DIHYDROCHLORIDE IN LIFETIME STUDIES

HWBUI0001524

to the bronchioles. In the remaining rats, minimal-to-slight peribronchial lymphoid hyperplasia was present.

Intermediate Range: The tissues of the F_0 animals evaluated for pathogen burden revealed evidence of early respiratory disease present in nearly all animals (Appendix J). This consisted of minimal-to-moderate peribronchial lymphoid hyperplasia in six males and seven females, a few focal accumulations of mononuclear cells in two males, focal accumulations of alveolar macrophages in one female, and minimal perivascular lymphoid hyperplasia in another female. In nearly all the F_1 animals examined, evidence of early respiratory disease, consisting of minimal-to-slight peribronchial lymphoid hyperplasia, was present. No serologic evidence of Sendai virus was present in either F_0 or F_1 animals.

Clinical Signs

Short Range: A summary of clinical signs observed before moribund kill is presented in Appendix K. Specific clinical signs occurred at essentially comparable frequencies in the control group and the dosed group throughout the studies. No distinct compound-related signs were noted in any of the dosed animals during the first 52 weeks on study. The following representative findings were observed at generally comparable frequencies among all groups: soft feces; urine stains; pale, thin and/or hunched appearance; depression; localized alopecia or sores on head or body; rough haircoats; abnormal eyes (pale, cloudy, bloody crust, red, lacrimation, squinting, enlarged, sores, swollen, red discharge, protruding, small and/or necrotic); head tilt; salivation; localized swellings; stains on fur; bloated appearance; necrotic or abscessed tail; discharge from anus or vagina; protruding penis or vagina; small or enlarged testes; wheezing; wasting feed or decreased feed consumption; and labored respiration and/or abnormal central nervous system responses (circling, hyperactivity, loss of equilibrium, tremors, isolated occurrences of paralysis and/or ataxia).

As the study proceeded, the incidence of clinical signs increased among all the groups. At intervals in which a large number of animals were killed in a moribund condition in any one particular group, the clinical signs most frequently observed were supportive of the conditions for moribund kills previously outlined in the Materials and Methods section.

Intermediate Range: Specific clinical signs occurred at essentially comparable frequencies in the control group and the DMH group throughout the studies. No distinct compound-related signs were noted in any of the dosed animals during the first 52 weeks on study. The following representative findings were observed at generally comparable frequencies among all groups: soft feces; urine stains; pale, thin, and/or hunched appearance; depression; localized alopecia or sores on head or body; rough haircoats; abnormal eyes (pale, cloudy, bloody crust, red, lacrimation, squinting, enlarged, sores, swollen, red discharge, protruding, small and/or necrotic); head tilt; salivation; localized swellings; stains on fur; bloated appearance; necrotic or abscessed tail; discharge from anus or vagina; small or enlarged testes; wheezing; wasting feed or decreased feed consumption; and labored respiration and/or abnormal central nervous system responses (circling, hyperactivity, loss of equilibrium, tremors, isolated occurences of paralysis and/or ataxia). A summary of clinical signs observed before moribund kills is presented in Appendix L.

As the study proceeded, the incidences of clinical signs increased among all the groups. At intervals in which a large number of animals were killed in a moribund condition in any one particular group, the clinical signs most frequently observed were supportive of the conditions for moribund kills previously outlined in the Materials and Methods section. A comparison of clinical signs observed during the same selected intervals between all the groups revealed a larger number of palpable abdominal masses, tissue masses, and red discharge and protruding masses from the rectum in the DMH group and the IR plus DMH group. In addition, the incidence of tissue masses, nodules, and wart-like lesions of the head and ear region was greater in the DMH group and the IR plus DMH group throughout the studies. These findings were not clinically observed with any frequency in any group administered only IR chrysotile and thus are presumed to be due to administration of 1,2-dimethylhydrazine dihydrochloride.

HWBUI0001525

Survival

Estimates of the probabilities of the survival of male and female rats fed diets containing chrysotile asbestos at the concentrations used in these studies and those of the controls are shown in the Kaplan and Meier curves in Figures 4 and 5. Additional survival data are summarized in Tables 6 through 10.

Short Range: Survival of rats exposed to SR was similar to that of the controls throughout the studies (Tables 6 and 7).

TABLE 6. SURVIVAL OF RATS IN THE LIFETIME FEED STUDIES OF SHORT-RANGE CHRYSOTILE ASBESTOS

	Untreated Control	SR (a)
MALE (b)		
Animals initially in study	88	250
Nonaccidental deaths before termination (c)	76	224
Accidentally killed	3	0
Killed at termination	9	26
Survival P values (d)		0.676
FEMALE (b)		
Animals initially in study	88	250
Nonaccidental deaths before termination (c)	79	225
Killed at termination	9	25
Survival P values (d)		0.978

(a) Administered 1% short-range (SR) chrysotile asbestos in the diet
(b) Terminal kill period: male--week 137; female--week 145
(c) Includes animals killed in a moribund condition
(d) The result of the life table pairwise comparison with the controls

TABLE 7. SURVIVAL OF RATS IN THE LIFETIME FEED STUDIES OF SHORT-RANGE CHRYSOTILE ASBESTOS AT VARIOUS TIME POINTS

		Male		Female	
Group	Age in Weeks	No. Alive/ Total No.	Percent Survival	No. Alive/ Total No.	Percent Survival
Control	100	71/88	81	73/88	83
	110	60/88	68	63/88	72
	120	51/88	58	44/88	50
	130	24/88	27	26/88	30
SR	100	213/250	85	209/250	84
	110	180/250	72	182/250	73
	120	131/250	52	132/250	53
	130	73/250	29	85/250	34

HWBUI0001526

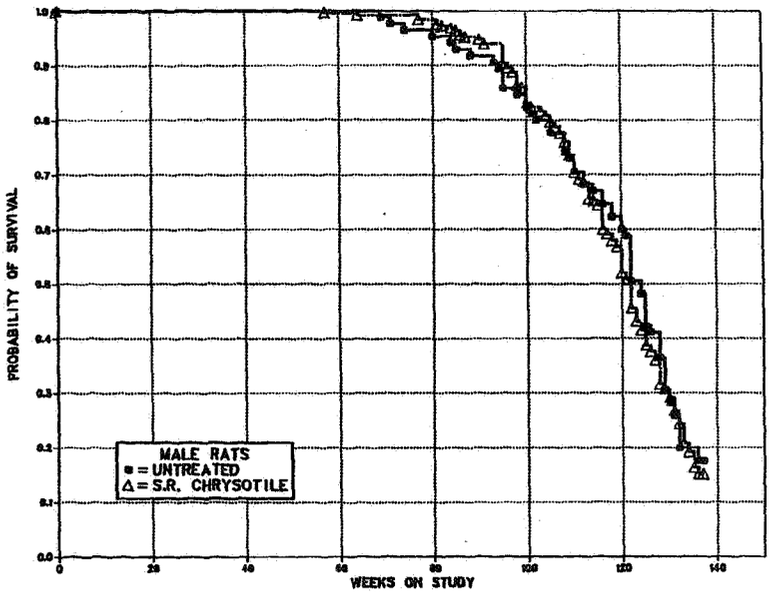

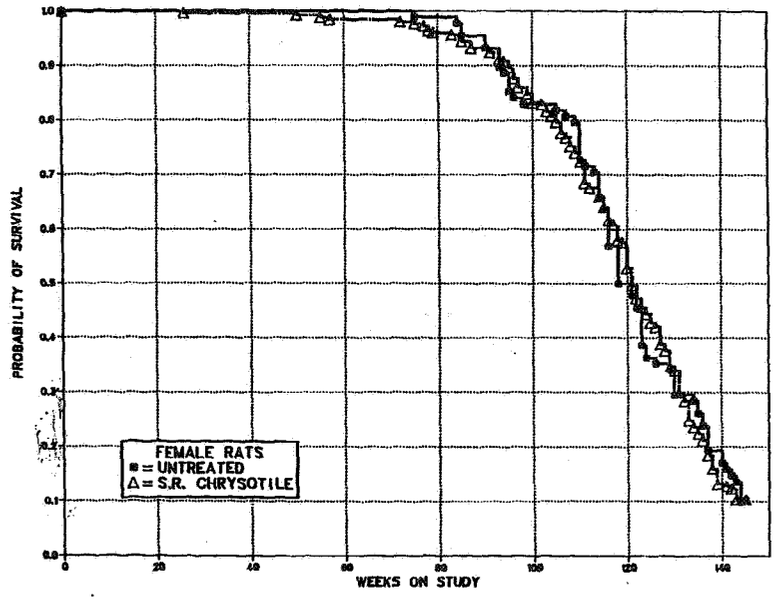

FIGURE 4. KAPLAN-MEIER SURVIVAL CURVES FOR RATS FED DIETS CONTAINING SHORT-RANGE CHRYSOTILE ASBESTOS IN LIFETIME STUDIES

HWBUI0001527

Intermediate Range: Survival of untreated controls was similar to that of dosed IR groups throughout the studies (Table 8). The survival of both groups of DMH-exposed rats was considerably lower than that of the untreated controls. However, survival of the IR plus DMH group was comparable to that of the DMH alone group (Table 9).

TABLE 8. SURVIVAL OF RATS IN THE LIFETIME FEED STUDIES OF INTERMEDIATE-RANGE CHRYSOTILE ASBESTOS

	Untreated Control	IR (a)	IR/PW	IR vs IR/PW
MALE (b)				
Animals initially in study	88	250	100	
Nonaccidental deaths before termination (c)	81	220	89	
Accidentally killed	0	1	0	
Killed at termination	7	29	11	
Survival P values (d)		0.590	0.885	0.750
FEMALE (b)				
Animals initially in study	88	250	100	
Nonaccidental deaths before termination (c)	79	225	91	
Killed at termination	9	25	9	
Survival P values (d)		0.793	0.982	0.713

(a) Administered 1% intermediate-range (IR) chrysotile asbestos in the diet
(b) Terminal kill period: male--week 144; female--week 146
(c) Includes animals killed in a moribund condition
(d) The results of the life table pairwise comparisons with the controls are in the dosed columns. The third value is the pairwise comparison between the dosed groups.

TABLE 9. SURVIVAL OF RATS IN THE LIFETIME STUDIES OF 1,2-DIMETHYLHYDRAZINE DIHYDROCHLORIDE WITH AND WITHOUT INTERMEDIATE-RANGE CHRYSOTILE ASBESTOS IN THE FEED

	Untreated Control	DMH (a)	IR + DMH (b)	DMH vs IR + DMH
MALE (c)				
Animals initially in study	88	125	175	
Nonaccidental deaths before termination (d)	81	107	159	
Killed at termination	7	18	14	
Died during termination period	0	0	2	
Survival P values (e)		< 0.001	< 0.001	0.348
FEMALE (c)				
Animals initially in study	88	125	175	
Nonaccidental deaths before termination (d)	79	109	148	
Killed at termination	9	16	26	
Died during termination period	0	0	1	
Survival P values (e)		< 0.001	< 0.001	0.568

(a) Administered 1,2-dimethylhydrazine dihydrochloride (DMH) by gavage
(b) Administered 1% intermediate-range (IR) chrysotile asbestos in the diet and DMH by gavage
(c) Terminal kill period: male--control, week 144; DMH, week 129; IR plus DMH, week 132; female--control, week 146; DMH, week 116; IR plus DMH, week 119
(d) Includes animals killed in a moribund condition
(e) The results of the life table pairwise comparisons with the controls are in the dosed columns. The third value is the pairwise comparison between the dosed groups.

HWBUI0001528

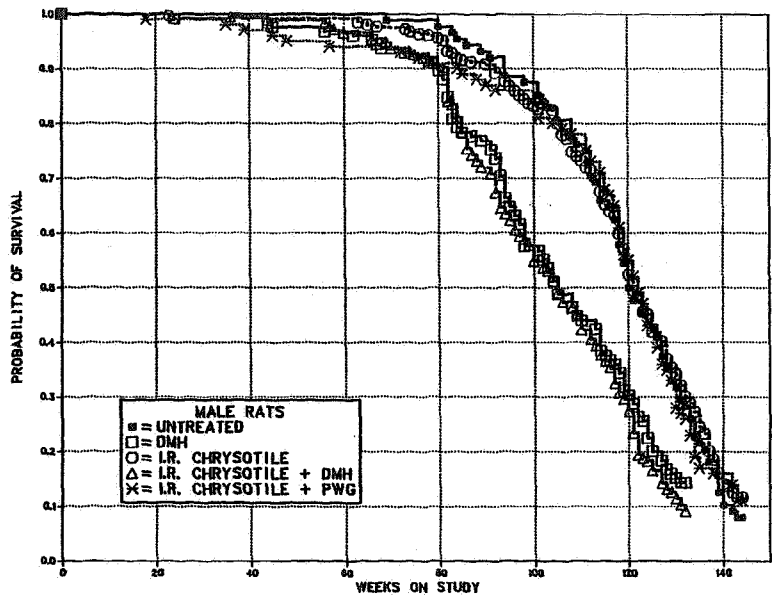

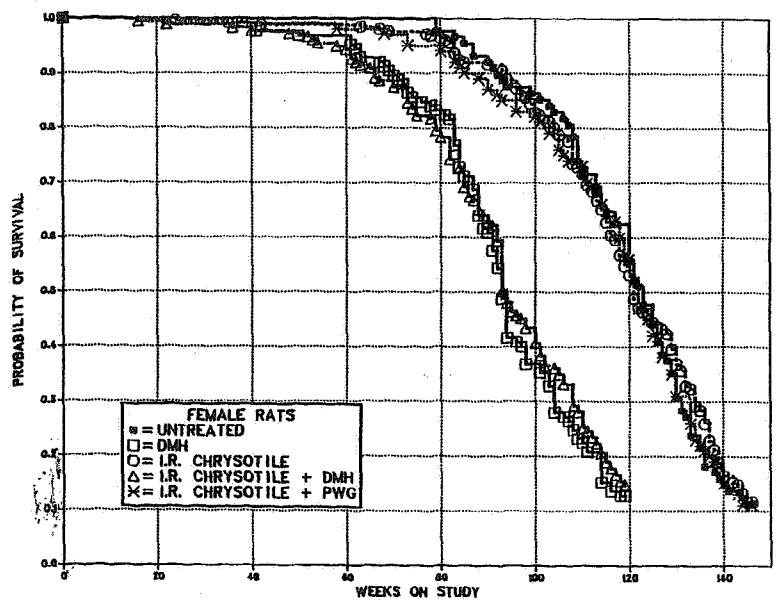

FIGURE 5. KAPLAN-MEIER SURVIVAL CURVES FOR RATS FED DIETS CONTAINING INTERMEDIATE-RANGE CHRYSOTILE ASBESTOS WITH AND WITHOUT 1,2-DIMETHYLHYDRAZINE DIHYDROCHLORIDE IN LIFETIME STUDIES

HWBUI0001529

TABLE 10. SURVIVAL OF RATS IN THE LIFETIME FEED STUDIES OF INTERMEDIATE-RANGE CHRYSOTILE ASBESTOS AT VARIOUS TIME POINTS

Group	Age in Weeks	Male		Female	
		No. Alive/ Total No.	Percent Survival	No. Alive/ Total No.	Percent Survival
Control	111	67/88	76	63/88	72
	121	43/88	49	49/88	56
	131	28/88	32	27/88	31
	141	9/88	10	13/88	15
DMH	111	55/125	44	28/125	22
	121	37/125	30	--	--
	131	19/125	15	--	--
	141	--	--	--	--
IR	111	183/250	73	179/250	72
	121	128/250	51	132/250	53
	131	85/250	34	91/250	36
	141	35/250	14	41/250	16
IR+DMH	111	74/175	42	44/175	25
	121	48/175	27	--	--
	131	20/175	11	--	--
	141	--	--	--	--
IR/PW	111	78/100	78	73/100	73
	121	55/100	55	56/100	56
	131	28/100	28	31/100	31
	141	16/100	16	15/100	15

Pathology and Statistical Analyses of Results

This section describes the significant or noteworthy changes in the incidences of rats with neoplastic or nonneoplastic lesions. Histopathologic findings on neoplasms in rats are summarized in Appendix A (Tables A1 and A2) (short range) and Appendix B (Tables B1 and B2) (intermediate range); Appendix A (Tables A3 and A4) and Appendix B (Tables B3 and B4) give the survival and tumor status for individual male and female rats. Findings on nonneoplastic lesions are summarized in Appendix C (Tables C1 and C2) (short range) and Appendix D (Tables D1 and D2) (intermediate range). Appendix E (Tables E1-E6) contain the statistical analyses of those primary tumors that occurred with an incidence of at least 5% in one of the three groups. The statistical analyses used are discussed in Chapter II (Statistical Methods) and Appendix E (footnotes).

Classification of Observed Gastrointestinal Tract Neoplasms

The gastrointestinal tract was examined in detail as described in the Materials and Methods section. Neoplasms were classed as to morphologic type by the following criteria (Pozharisski, 1975):

Stomach: Squamous cell papillomas occurred in the forestomach (nonglandular) as exophytic growths of epithelium resting on a proliferative connective tissue stalk. Squamous cell carcinomas were characterized by proliferating small basophilic squamous cells that were invading into the lamina propria and occasionally formed keratin pearls.

Intestinal tract neoplasms: The induced primary epithelial neoplasms were separated into three major types, based on morphology and biologic behavior: adenomatous polyps, adenocarcinoma arising in an adenomatous polyp, and carcinomata.

HWBUI0001530

Adenomatous polyps--The adenomatous polyps were exophytic lesions of the mucosa supported on a pedicle of fibrous tissue and/or elevated submucosa which appeared to extend up into the growth. The epithelial cells were usually deeply basophilic and hypertrophic and formed glands of varying sizes. Surface necrosis of these lesions was common and often was accompanied by an inflammatory response. Invasion of the pedicle was not observed. These polyps often occurred as multiple neoplasms in the large intestine.

Adenocarcinoma arising in an adenomatous polyp--These neoplasms were exophytic lesions of the mucosa composed of proliferating deeply basophilic hypertrophic epithelial cells similar to those previously mentioned. In addition, they often showed disorganization, loss of relationship to the basement membrane, and abnormal mitoses. Local invasion of the pedicle was a consistent finding; however, metastases were rarely observed.

Carcinomata--This classification includes signet ring cell carcinoma, adenocarcinoma, mucinous cystadenocarcinoma, and carcinoma. Biologically, all were similar and were usually characterized by transmural growth that penetrated the muscular tunics and serosa and spread throughout the coelomic cavity inducing a severe desmoplastic response. Metastasis to regional lymph nodes was common; metastasis to the lung and mediastinum occurred to a lesser extent. Grossly, in advanced cases, the loops of intestines were fused into an inseparable mass of tumor and desmoplastic tissue. Classification was based on the most prominent feature at the primary site. Signet ring cell carcinomas were composed of masses of signet ring cells. Mucinous cystadenocarcinomas were characterized by the formation of multiple large ectatic glands or spaces that were filled with mucus and cellular debris. Adenocarcinomas consisted of clusters of cells and/or glands in pools of mucus or sequestered in desmoplastic tissue. The carcinomas were anaplastic neoplasms lacking acinar formations. In some cases, there was an overlap of cell types in the same tumor, suggesting that the above morphologic types probably have the same histogenesis.

Short-Range Groups

At no site was the incidence of neoplasms in dosed groups significantly greater than that in the control groups. The incidences of neoplastic and nonneoplastic lesions of the alimentary tract are shown in Tables 11 and 12.

Decreased Incidence of Primary Neoplasms: A decreased incidence of neoplasms in male SR chrysotile groups occurred in the following organs: liver (neoplastic nodules/carcinomas combined)--15/88, 17% (control) versus 19/248, 8% (SR chrysotile) and parathyroid gland (adenomas)--6/83, 7% (control) versus 4/229, 2% (SR chrysotile).

Intermediate-Range and Preweaning Gavage Groups

Alimentary Tract: The incidences of epithelial neoplasms of the alimentary tract are summarized in Table 13 by site and morphologic type. Only the incidence of adenomatous polyp of the large intestine (dosed, 9/250 (4%) versus control, 0/85) in male rats is possibly compound related.

There were also two polyps in the descending colon in the male IR/PW chrysotile group. All of these polyps were grossly visible at necropsy. If epithelial neoplasms of similar morphology from the small intestine and glandular stomach are also counted, the incidence is 14/250, 6% (IR chrysotile) versus 0/88 (control) and 2/100, 2% (IR/PW chrysotile). There were also 3/250 animals with neoplasms of squamous cell origin (squamous cell papilloma, keratoacanthoma, and squamous cell carcinoma) in the oral cavity in the male IR chrysotile group and none in the controls. No increase in epithelial neoplasms was observed in IR chrysotile-exposed female rats.

No nonneoplastic lesions were associated with the administration of IR chrysotile asbestos (Table 14).

HWBUI0001531

TABLE 11. ALIMENTARY TRACT TUMORS IN RATS IN THE LIFETIME FEED STUDIES OF SHORT-RANGE (SR) CHRYSOTILE ASBESTOS

	Male		Female	
	Control	SR	Control	SR
Hard palate (No. examined)	88	250	88	250
Squamous cell papilloma	0	1 (<1%)	0	0
Oral mucous membrane (No. examined)	88	250	88	250
Squamous cell carcinoma	0	0	0	1 (<1%)
Tongue (No. examined)	88	250	88	250
Squamous cell papilloma	0	0	0	1 (<1%)
Squamous cell carcinoma	0	0	0	1 (<1%)
Stomach (No. examined)	88	248	87	245
Squamous cell papilloma	0	1 (<1%)	0	0
Squamous cell carcinoma	0	1 (<1%)	0	1 (<1%)
Sarcoma	0	1 (<1%)	0	0
Forestomach (No. examined)	88	248	87	245
Squamous cell papilloma	1 (1%)	0	0	0
Gastric fundus (No. examined)	88	248	87	245
Carcinoma-in-situ	0	1 (<1%)	0	0
Duodenum (No. examined)	88	248	87	244
Adenomatous polyp	0	1 (<1%)	0	0
Leiomyosarcoma	0	0	0	2 (1%)
Jejunum (No. examined)	88	248	87	244
Mucinous cystadenocarcinoma	1 (1%)	0	0	1 (<1%)
Adenocarcinoma in adenomatous polyp	0	0	0	1 (<1%)
Leiomyoma	0	0	0	1 (<1%)
Ileum (No. examined)	88	248	87	244
Leiomyosarcoma	0	0	1 (1%)	0
Total small intestine (No. examined)	88	248	87	244
Adenomatous polyp	0	1 (<1%)	0	0
Mucinous cystadenocarcinoma	1 (1%)	0	0	1 (<1%)
Adenocarcinoma in adenomatous polyp	0	0	0	1 (<1%)
Leiomyoma	0	0	0	1 (<1%)
Leiomyosarcoma	0	0	1 (1%)	2 (1%)
Cecum (No. examined)	87	248	87	244
Lipoma	0	1 (<1%)	0	0
Leiomyosarcoma	0	1 (<1%)	0	0
Adenomatous polyp	0	0	1 (1%)	0
Colon (No. examined)	87	248	87	244
Adenomatous polyp	0	1 (<1%)	0	0
Leiomyosarcoma	0	1 (<1%)	0	0
Transverse colon (No. examined)	87	248	87	244
Leiomyosarcoma	1 (1%)	0	0	0
Adenomatous polyp	0	0	0	1 (<1%)
Descending colon (No. examined)	87	248	87	244
Adenomatous polyp	0	0	0	2 (1%)
Leiomyosarcoma	0	0	0	1 (<1%)
Total large intestine (No. examined)	87	248	87	244
Adenomatous polyp	0	1 (<1%)	1 (1%)	3 (1%)
Lipoma	0	1 (<1%)	0	0
Leiomyosarcoma	1 (1%)	2 (1%)	0	1 (<1%)

HWBUI0001532

TABLE 12. INCIDENCE OF NONNEOPLASTIC LESIONS IN THE ALIMENTARY TRACT OF RATS IN *THE LIFETIME FEED STUDIES OF SHORT-RANGE (SR) CHRYSOTILE ASBESTOS*

	Male		Female	
	Control	SR	Control	SR
Esophagus (No. examined)	86	247	87	244
Hyperkeratosis	6 (7%)	16 (6%)	4 (5%)	8 (3%)
Stomach (No. examined)	88	248	87	245
Mineralization	3 (3%)	2 (1%)	0	0
Inflammation	12 (14%)	35 (14%)	16 (18%)	46 (19%)
Ulcer	4 (5%)	10 (4%)	7 (8%)	21 (9%)
Adhesion	1 (1%)	1 (<1%)	2 (2%)	1 (<1%)
Necrosis	13 (15%)	40 (16%)	14 (16%)	35 (14%)
Hyperplasia, epithelial	3 (3%)	0	0	0
Hyperkeratosis	8 (9%)	29 (12%)	21 (24%)	59 (24%)
Acanthosis	11 (13%)	36 (15%)	19 (22%)	59 (24%)
Gastric muscularis (No. examined)	88	248	87	245
Degeneration	2 (2%)	0	0	1 (<1%)
Colon (No. examined)	87	248	87	244
Inflammation			2 (2%)	2 (1%)
Parasitism	13 (15%)	22 (9%)	8 (9%)	13 (5%)
Cecum (No. examined)	87	248	87	244
Inflammation	0	6 (2%)	2 (2%)	5 (2%)
Necrosis	0	5 (2%)	2 (2%)	3 (1%)

HWBUI0001533

TABLE 13. ALIMENTARY TRACT TUMORS IN RATS IN THE LIFETIME FEED STUDIES OF INTERMEDIATE-RANGE (IR) CHRYSOTILE ASBESTOS

	Male			Female		
	Control	IR	IR/PW	Control	IR	IR/PW
Mouth/oral cavity (No. examined)	88	250	100	88	250	100
Squamous cell carcinoma	0	1 (<1%)	0	0	1 (<1%)	0
Hard palate (No. examined)	88	250	100	88	250	100
Keratoacanthoma	0	1 (<1%)	0	0	0	0
Squamous cell papilloma	0	0	1 (1%)	0	1 (<1%)	0
Squamous cell carcinoma	0	0	0	0	0	1 (1%)
Tongue (No. examined)	88	250	100	88	250	100
Squamous cell papilloma	0	1 (<1%)	0	1 (1%)	0	1 (1%)
Esophagus (No. examined)	83	250	98	88	250	100
Fibrosarcoma	0	0	1 (1%)	0	0	0
[b]Stomach (No. examined)	85	250	100	87	250	99
Squamous cell papilloma	0	0	0	0	0	1 (1%)
Squamous cell carcinoma	0	0	0	1 (1%)	0	1 (1%)
Adenomatous polyp	0	0	0	0	1 (<1%)	0
Adenocarcinoma	0	1 (<1%)	0	0	0	0
Carcinoid tumor	0	0	0	0	2 (1%)	0
Leiomyosarcoma	0	0	0	0	1 (<1%)	0
Small intestine (No. examined)	85	250	100	87	249	99
Leiomyosarcoma	0	0	1 (1%)	0	0	0
Duodenum (No. examined)	85	250	100	87	249	99
Adenomatous polyp	0	1 (<1%)	0	0	0	0
Mucinous cystadenocarcinoma	0	1 (<1%)	0	0	0	0
Signet ring carcinoma	0	1 (<1%)	0	0	0	0
Leiomyoma	0	1 (<1%)	0	1 (1%)	0	0
Jejunum (No. examined)	85	250	100	87	249	99
Leiomyosarcoma	0	2 (1%)	0	0	0	0
Ileum (No. examined)	85	250	100	87	249	99
Leiomyoma	1 (1%)	0	1 (1%)	0	0	0
Total small intestine (No. examined)	85	250	100	87	249	99
Adenomatous polyp	0	1 (<1%)	0	0	0	0
Mucinous cystadenocarcinoma	0	1 (<1%)	0	0	0	0
Signet ring carcinoma	0	1 (<1%)	0	0	0	0
Leiomyoma	1 (1%)	1 (<1%)	1 (1%)	1 (1%)	0	0
Leiomyosarcoma	0	2 (1%)	1 (1%)	0	0	0
Ascending colon (No. examined)	85	250	100	87	250	99
Adenomatous polyp	0	2 (1%)	0	0	0	0
Leiomyoma	0	0	0	0	0	1 (1%)
Transverse colon (No. examined)	85	250	100	87	250	99
Leiomyosarcoma	0	0	1 (1%)	0	0	0
Descending colon (No. examined)	85	250	100	87	250	99
Adenomatous polyp	0	7 (3%)	2 (2%)	0	1 (<1%)	0
Leiomyoma	0	0	0	0	1 (<1%)	0
Total large intestine (No. examined)	85	250	100	87	250	99
Adenomatous polyp	0	9 (4%)	2 (2%)	0	1 (<1%)	0
Leiomyoma	0	0	0	0	1 (<1%)	1 (1%)
Leiomyosarcoma	0	0	1 (1%)	0	0	0

HWBUI0001534

TABLE 14. INCIDENCE OF NONNEOPLASTIC LESIONS IN THE ALIMENTARY TRACT OF RATS IN THE LIFETIME FEED STUDIES OF INTERMEDIATE-RANGE (IR) CHRYSOTILE ASBESTOS

	Male			Female		
	Control	IR	IR/PW	Control	IR	IR/PW
Esophagus (No. examined)	83	250	98	86	250	99
Hyperkeratosis	1 (1%)	0	2 (2%)	0	0	2 (2%)
Stomach (No. examined)	85	250	100	87	250	99
Mineralization	1 (1%)	5 (2%)	0	0	0	0
Cyst	2 (2%)	1 (<1%)	0	1 (1%)	1 (<1%)	1 (1%)
Edema	5 (6%)	0	0	0	0	0
Ulcer	13 (15%)	27 (11%)	9 (9%)	7 (8%)	26 (10%)	7 (7%)
Inflammation	18 (22%)	29 (12%)	9 (9%)	9 (10%)	33 (13%)	10 (10%)
Necrosis, focal	0	4 (2%)	0	0	2 (1%)	1 (1%)
Hyperplasia, epithelial	0	0	1 (1%)	0	1 (<1%)	0
Hyperplasia, basal cell	1 (1%)	1 (<1%)	0	0	0	0
Hyperkeratosis	7 (8%)	0	0	2 (2%)	4 (2%)	5 (5%)
Acanthosis	10 (12%)	18 (7%)	14 (14%)	7 (8%)	20 (8%)	10 (10%)
Gastric submucosa (No. examined)	85	250	100	87	250	99
Edema	1 (1%)	23 (9%)	10 (10%)	2 (2%)	14 (6%)	2 (2%)
Large intestine (No. examined)	85	250	100	87	250	99
Parasitism	3 (4%)	0	0	0	0	0
Colon (No. examined)	85	250	100	87	250	99
Parasitism	0	11 (4%)	0	0	6 (2%)	1 (1%)
Cecum (No. examined)	85	250	100	87	250	99
Edema	0	5 (2%)	0	0	0	0
Inflammation	2 (2%)	1 (<1%)	0	0	3 (1%)	3 (3%)

HWBUI0001535

Integumentary System: The incidences of keratoacanthomas of the integumentary system in male rats in the IR and IR/PW groups were significantly greater than that in the controls (Table 15).

Clitoral Gland: The incidence of carcinomas or squamous cell carcinomas (combined) in the female IR group (but not the IR/PW group) was significantly greater than that in the controls (Table 16).

Adrenal Gland: The incidence of pheochromocytomas or malignant pheochromocytomas (combined) in the male IR/PW group (32/100, 32%) but not in the IR group (63/250, 25%) was significantly greater than that in the controls (17/85, 20%).

TABLE 15. ANALYSIS OF INTEGUMENTARY SYSTEM TUMORS IN MALE RATS IN THE LIFETIME FEED STUDY OF INTERMEDIATE-RANGE CHRYSOTILE ASBESTOS (a)

	Untreated Control	IR (b)	IR/PW	IR vs IR/PW
Keratoacanthoma				
Overall Rates	1/88 (1%)	19/250 (8%)	8/100 (8%)	
Adjusted Rates	3.2%	23.9%	32.7%	
Terminal Rates	0/7 (0%)	3/29 (10%)	3/11 (27%)	
Life Table Test		P=0.039	P=0.048	P=0.506
Incidental Tumor Test		P=0.027	P=0.026	P=0.512

(a) The statistical analyses used are discussed in Chapter II (Statistical Methods) and Appendix E (footnotes).
(b) Administered 1% intermediate-range (IR) chrysotile asbestos in the diet

TABLE 16. ANALYSIS OF CLITORAL GLAND TUMORS IN FEMALE RATS IN THE LIFETIME FEED STUDY OF INTERMEDIATE-RANGE CHRYSOTILE ASBESTOS

	Untreated Control	IR (a)	IR/PW	IR vs IR/PW
Carcinoma				
Overall Rates	0/88 (0%)	16/250 (6%)	4/100 (4%)	
Carcinoma or Squamous Cell Carcinoma				
Overall Rates	1/88 (1%)	18/250 (7%)	4/100 (4%)	
Adjusted Rates	3.2%	26.1%	12.6%	
Terminal Rates	0/10 (0%)	5/29 (17%)	0/11 (0%)	
Life Table Test		P=0.037	P=0.214	P=0.218N
Incidental Tumor Test		P=0.031	P=0.247	P=0.186N

(a) Administered 1% intermediate-range (IR) chrysotile asbestos in the diet

HWBUI0001536

Decreased Incidence of Primary Neoplasms: The only organ that showed a decreased tumor incidence in the IR-chrysotile groups compared with the controls was the pituitary gland in female rats (controls--53/87, 61%; IR--117/249, 47%; IR/PW--51/100, 51%)

Liver: The incidences of cystic degeneration in the male IR and IR/PW groups were greater than those in the controls (male: control, 4/85, 5%; IR, 44/250, 18%; IR/PW, 21/100, 21%; female: control, 0/87; IR, 0/250; IR/PW, 2/99, 2%).

Prostate: The incidences of inflammation (acute, acute focal, suppurative, acute/chronic, or chronic) or abscess in the IR and IR/PW groups were greater than that in the controls (control, 17/85, 20%; IR, 87/249, 35%; IR/PW, 45/99, 45%). The incidence of hyperplasia (NOS, focal, or epithelial) was increased in the IR group as compared with that in the controls (control, 2/85, 2%; IR, 31/249, 12%; IR/PW, 3/99, 3%).

Lymph nodes: The incidence of hyperplasia (lymphoid, reticulum, and plasma cell) in the mandibular lymph node of the male rats was greater in the IR (57/250, 23%) and IR/PW groups (47/100, 47%) than in the concurrent controls (12/88, 14%). Similar types of hyperplasia were not observed in other lymph nodes (cervical, mediastinal, celiac, pancreatic, mesenteric, ileocolic, iliac, renal, or axillary) in the males or in any lymph node in IR-exposed female rats.

The incidences of pigmentation in the mediastinal lymph node of the male IR group (58/250, 23%) and IR/PW group (41/100, 41%) were increased as compared with the control group (5/85, 6%). A similar observation was noted in the mesenteric lymph nodes (IR: 28/250, 11%; IR/PW: 28/100, 28%; control: 0/85) and possibly the pancreatic lymph node (IR: 14/250, 6%; IR/PW: 6/100, 6%; control: 0/85).

The incidence of pigmentation was increased in certain lymph nodes of female IR-exposed rats: mediastinal (IR: 91/250, 36%; IR/PW: 39/99, 39%; control: 22/87, 25%); pancreatic (IR: 19/250, 8%; IR/PW: 5/99 5%; control: 0/87); and mesenteric (IR: 40/250, 16%; IR/PW: 4/99, 4%; control: 10/87, 11%).

DMH With and Without Intermediate-Range Chrysotile Asbestos

DMH was associated with increased incidences of neoplasms in multiple organs: skin, liver, kidney, pancreas, thyroid gland, Zymbal gland, hematopoietic system, and gastrointestinal tract (Tables 17 and 18). The only significant differences in the incidences of neoplasms between the DMH group and the IR/DMH group were observed in the kidneys of female rats and the thyroid gland of male rats (Tables 19 and 20).

Large Intestine: The incidences of adenomatous polyps, mucinous cystadenocarcinomas, and adenomatous polyps, adenocarcinomas, or mucinous cystadenocarcinomas (combined) in DMH and IR plus DMH groups were comparable (Table 17) in male (DMH, 32%; IR plus DMH, 35%) and female (DMH, 37%; IR plus DMH, 35%) rats.

Kidney: The incidence of mixed malignant tumors of the kidney in female rats that received IR chrysotile plus DMH was significantly ($P<0.05$) greater than that in the group that received DMH alone (Table 19).

Thyroid Gland: The incidence of follicular cell adenomas in male rats that received IR chrysotile asbestos plus DMH was significantly greater than in those that received DMH without IR chrysotile. The incidence of follicular cell carcinomas in male rats receiving DMH was approximately the same as that in male rats that received both DMH and IR chrysotile asbestos. The incidences of follicular cell adenomas, follicular cell carcinomas, and follicular cell adenomas or carcinomas (combined) in males that received IR chrysotile asbestos plus DMH were significantly ($P<0.05$) greater than those in the controls (Table 20).

HWBUI0001537

TABLE 17. SUMMARY OF GASTROINTESTINAL TUMORS IN RATS ADMINISTERED 1,2-DIMETHYLHYDRAZINE DIHYDROCHLORIDE WITH AND WITHOUT INTERMEDIATE-RANGE CHRYSOTILE ASBESTOS

	Male		Female	
	DMH (a)	IR + DMH (b)	DMH	IR + DMH
Tongue				
Squamous cell papilloma	0/125 (0%)	1/175 (1%)	1/125 (1%)	0/175 (0%)
Squamous cell carcinoma	0/125 (0%)	0/175 (0%)	1/125 (1%)	0/175 (0%)
Small intestine, Site unknown				
Mucinous cystadenocarcinoma	0/125 (0%)	0/175 (0%)	0/125 (0%)	1/175 (1%)
Duodenum				
Adenocarcinoma	0/125 (0%)	1/175 (1%)	0/125 (0%)	0/175 (0%)
Mucinous cystadenocarcinoma	0/125 (0%)	1/175 (1%)	2/125 (2%)	2/175 (1%)
Signet ring carcinoma	0/125 (0%)	1/175 (1%)	0/125 (0%)	2/175 (1%)
Jejunum				
Adenomatous polyp	0/125 (0%)	0/175 (0%)	0/125 (0%)	1/175 (1%)
Adenocarcinoma	0/125 (0%)	1/175 (1%)	0/125 (0%)	0/175 (0%)
Mucinous cystadenocarcinoma	0/125 (0%)	1/175 (1%)	0/125 (0%)	0/175 (0%)
Ileum				
Adenocarcinoma in adenomatous polyp	0/125 (0%)	0/175 (0%)	0/125 (0%)	1/175 (1%)
Total small intestine				
Adenomatous polyp	0/125 (0%)	0/175 (0%)	0/125 (0%)	1/175 (1%)
Adenocarcinoma	0/125 (0%)	2/175 (1%)	0/125 (0%)	0/175 (0%)
Mucinous cystadenocarcinoma	0/125 (0%)	2/175 (1%)	2/125 (2%)	3/175 (3%)
Adenocarcinoma in adenomatous polyp	0/125 (0%)	0/175 (0%)	0/125 (0%)	1/175 (1%)
Signet ring carcinoma	0/125 (0%)	1/175 (1%)	0/125 (0%)	2/175 (1%)
Colon				
Adenomatous polyp	0/125 (0%)	0/175 (0%)	2/125 (2%)	1/175 (1%)
Mucinous cystadenocarcinoma	0/125 (0%)	0/175 (0%)	0/125 (0%)	1/175 (1%)
Cecum				
Adenocarcinoma	1/125 (1%)	0/175 (0%)	1/125 (1%)	0/175 (0%)
Adenomatous polyp	0/125 (0%)	1/175 (1%)	0/125 (0%)	3/175 (2%)
Mucinous cystadenocarcinoma	4/125 (3%)	4/175 (2%)	(c) 8/125 (6%)	(c) 8/175 (5%)
Signet ring carcinoma	0/125 (0%)	0/175 (0%)	1/125 (1%)	0/175 (0%)
Ascending colon				
Adenocarcinoma,	0/125 (0%)	1/175 (1%)	0/125 (0%)	3/175 (2%)
Adenomatous polyp	3/125 (2%)	3/175 (2%)	2/125 (2%)	6/175 (3%)
Adenocarcinoma in adenomatous polyp	0/125 (0%)	1/175 (1%)	0/125 (0%)	0/175 (0%)
Mucinous cystadenocarcinoma	3/125 (2%)	(c) 11/175 (6%)	5/125 (4%)	6/175 (3%)
Signet ring carcinoma	1/125 (1%)	0/175 (0%)	1/125 (1%)	2/175 (1%)
Leiomyosarcoma	0/125 (0%)	0/175 (0%)	1/125 (1%)	0/175 (0%)
Transverse colon				
Adenocarcinoma	1/125 (1%)	0/175 (0%)	0/125 (0%)	0/175 (0%)
Adenomatous polyp	4/125 (3%)	6/175 (3%)	(c) 9/125 (7%)	(c) 8/175 (5%)
Adenocarcinoma in adenomatous polyp	0/125 (0%)	0/175 (0%)	0/125 (0%)	4/175 (2%)
Mucinous cystadenocarcinoma	0/125 (0%)	0/175 (0%)	0/125 (0%)	1/175 (1%)
Descending colon				
Adenomatous polyp	(c) 24/125 (19%)	(c) 37/175 (21%)	(c) 24/125 (19%)	(c) 30/175 (17%)
Adenocarcinoma in adenomatous polyp	0/125 (0%)	2/175 (1%)	2/125 (2%)	2/175 (1%)
Mucinous cystadenocarcinoma	0/125 (0%)	4/175 (2%)	1/125 (1%)	0/175 (0%)
Signet ring carcinoma	0/125 (0%)	1/175 (1%)	0/125 (0%)	0/175 (0%)
Total large intestine				
Adenomatous polyp	(c) 31/125 (25%)	(c) 45/175 (26%)	(c) 33/125 (26%)	(c) 46/175 (26%)
Adenocarcinoma	2/125 (2%)	1/175 (1%)	1/125 (1%)	3/175 (2%)
Mucinous cystadenocarcinoma	(c) 7/125 (6%)	(c) 19/175 (11%)	(c) 14/125 (11%)	(c) 16/175 (9%)
Adenocarcinoma in adenomatous polyp	0/125 (0%)	3/175 (2%)	2/125 (2%)	6/175 (3%)
Signet ring carcinoma	1/125 (1%)	1/175 (1%)	2/125 (2%)	2/175 (1%)
Leiomyosarcoma	0/125 (0%)	0/175 (0%)	1/125 (1%)	0/175 (0%)
Anus				
Adenomatous polyp	1/125 (1%)	0/175 (0%)	0/125 (0%)	0/175 (0%)

(a) Administered 1,2-dimethylhydrazine dihydrochloride (DMH) by gavage
(b) Administered 1% intermediate-range (IR) chrysotile asbestos in the diet and DMH by gavage
(c) Incidence significantly greater than that in the controls ($P<0.05$)

HWBUI0001538

TABLE 18. SUMMARY OF NONGASTROINTESTINAL TUMORS IN RATS ADMINISTERED 1,2-DIMETHYLHYDRAZINE DIHYDROCHLORIDE WITH AND WITHOUT INTERMEDIATE-RANGE CHRYSOTILE ASBESTOS

	Male		Female	
	DMH (a)	IR + DMH (b)	DMH	IR + DMH
Integumentary system				
Keratoacanthoma	(c*) 6/125 (5%)	(c) 11/175 (6%)	0/125 (0%)	2/175 (1%)
Hematopoietic system				
Leukemia	(c*) 42/125 (34%)	(c*) 71/175 (41%)	(c) 70/125 (56%)	(c) 93/175 (53%)
Liver				
Neoplastic nodule	(c*) 12/125 (10%)	10/175 (6%)	(c) 12/125 (10%)	(c) 21/175 (12%)
Hepatocellular carcinoma	(c) 17/125 (14%)	(c) 20/175 (11%)	(c) 12/125 (10%)	(c) 19/175 (11%)
Pancreas				
Acinar cell adenoma	7/124 (6%)	(c) 14/174 (8%)	1/124 (1%)	0/175 (0%)
Kidney				
Mixed tumor, malignant	0/125 (0%)	1/175 (1%)	(c) 13/125 (10%)	(c,d) 34/175 (19%)
Thyroid gland				
Follicular cell adenoma	1/124 (1%)	(c,d) 14/175 (8%)	(c*) 7/124 (6%)	9/174 (5%)
Follicular cell carcinoma	8/124 (6%)	(c*) 14/175 (8%)	(c*) 5/124 (4%)	(c*) 7/174 (4%)
Zymbal gland				
Squamous cell papilloma, adenoma	1/125 (1%)	3/175 (2%)	1/125 (1%)	3/175 (2%)
Squamous cell carcinoma or carcinoma	(c) 18/125 (14%)	(c) 24/175 (14%)	(c) 14/125 (11%)	(c) 26/175 (15%)

(a) Administered 1,2-dimethylhydrazine dihydrochloride (DMH) by gavage
(b) Administered 1% intermediate-range (IR) chrysotile asbestos in the diet and DMH by gavage
(c) Incidence significantly greater than that in the controls ($P<0.05$); (c*) differences significant ($P<0.05$) by life table analysis only
(d) Incidence significantly greater than that in the DMH group ($P<0.05$)

TABLE 19. ANALYSIS OF KIDNEY TUMORS IN FEMALE RATS IN THE LIFETIME FEED STUDY OF INTERMEDIATE-RANGE CHRYSOTILE ASBESTOS WITH 1,2-DIMETHYLHYDRAZINE DIHYDROCHLORIDE

	Untreated Control	DMH (a)	IR + DMH (b)	DMH vs IR + DMH
Mixed Tumor, Malignant				
Overall Rates	0/87 (0%)	13/125 (10%)	34/175 (19%)	
Adjusted Rates	0.0%	21.8%	30.0%	
Terminal Rates	0/55 (0%)	1/16 (6%)	0/27 (0%)	
Life Table Test		$P<0.001$	$P<0.001$	$P=0.043$
Incidental Tumor Test		$P=0.073$	$P=0.022$	$P=0.021$

(a) Administered 1,2-dimethylhydrazine dihydrochloride (DMH) by gavage
(b) Administered 1% intermediate-range (IR) chrysotile asbestos in the diet and DMH by gavage

HWBUI0001539

TABLE 20. ANALYSIS OF THYROID GLAND TUMORS IN MALE RATS IN THE LIFETIME FEED STUDY OF INTERMEDIATE-RANGE CHRYSOTILE ASBESTOS WITH 1,2-DIMETHYLHYDRAZINE DIHYDROCHLORIDE

	Untreated Control	DMH (a)	IR + DMH (b)	DMH vs IR + DMH
Follicular Cell Adenoma				
Overall Rates	1/84 (1%)	1/124 (1%)	14/175 (8%)	
Adjusted Rates	2.1%	2.8%	28.5%	
Terminal Rates	0/26 (0%)	0/18 (0%)	2/18 (11%)	
Life Table Test		P=0.720	P=0.001	P=0.003
Incidental Tumor Test		P=0.752	P=0.011	P=0.006
Follicular Cell Carcinoma				
Overall Rates	5/84 (6%)	8/124 (6%)	14/175 (8%)	
Adjusted Rates	13.1%	29.9%	19.7%	
Terminal Rates	2/26 (8%)	4/18 (22%)	0/18 (0%)	
Life Table Test		P=0.130	P=0.045	P=0.299
Incidental Tumor Test		P=0.171	P=0.246	P=0.403
Follicular Cell Adenoma or Carcinoma				
Overall Rates	6/84 (7%)	9/124 (7%)	28/175 (16%)	
Adjusted Rates	14.9%	31.8%	42.7%	
Terminal Rates	2/26 (8%)	4/18 (22%)	2/18 (11%)	
Life Table Test		P=0.138	P<0.001	P=0.010
Incidental Tumor Test		P=0.184	P=0.009	P=0.020

(a) Administered 1,2-dimethylhydrazine dihydrochloride (DMH) by gavage
(b) Administered 1% intermediate-range (IR) chrysotile asbestos in the diet and DMH by gavage

HWBUI0001540

IV. DISCUSSION AND CONCLUSIONS

HWBUI0001541

IV. DISCUSSION AND CONCLUSIONS

Two types (short-range [SR] and intermediate-range [IR] fiber length) of chrysotile asbestos were administered at a level of 1% in the diet to male and female F344/N rats for their lifetime, including exposure of their dams to the test material. A further study included two groups (control and IR chrysotile exposed) of weanling rats exposed to five biweekly doses of 1,2-dimethylhydrazine dihydrochloride (DMH), a known intestinal carcinogen in rodents, to investigate the promotional or cocarcinogenic effects of DMH and IR chrysotile asbestos.

The clinicopathologic results in this study showed that the ingestion of either SR or IR chrysotile asbestos did not adversely affect the fertility of the mothers or the litter size of the F_1 animals. The average weight of the offspring at birth from mothers exposed to either SR or IR chrysotile asbestos before and during gestation was similar to that of the offspring of nonexposed mothers. At weaning, however, the average weight of the offspring of SR chrysotile-exposed mothers was 8% greater, and that of the offspring of IR chrysotile-exposed mothers 13% lower, than that of the offspring of the nonexposed mothers.

The IR chrysotile asbestos-exposed rats remained smaller throughout their lives, although the weight gains paralleled those of the nonexposed rats. Similar findings were reported in previous NTP ingestion studies in rats of amosite (NTP TR 279) and crocidolite (NTP TR 280, in press) asbestos, in which the offspring of exposed mothers were also smaller at weaning and remained so throughout their lives. The cause of the decreased body weight gain is unknown, but the IR chrysotile rats consumed slightly less feed during the study (Appendix H, Tables H3 and H4).

The mean body weight of the rats exposed to the preweaning (PW) gavage and subsequently to IR chrysotile asbestos was slightly greater than that of those exposed to IR chrysotile alone. This may be related to the high rate of mortality (approximately 50%) induced in the neonates by the PW technique, which would allow the remaining pups more milk during lactation. For neonates, the physical stress of gavaging routinely results in a high rate of mortality. This high mortality resulted in a group of test animals that may not be representative of the group (i.e., biased toward more hardy individuals). Exposure to DMH caused a small reduction in body weight gain in male and female rats.

No clinical signs were observed that could be attributed to the ingestion of either SR or IR chrysotile asbestos. Starting at 9 months of age, the DMH exposed rats showed signs attributable to DMH-related neoplasia, but no difference was noted between the DMH and IR plus DMH groups.

The survival of the rats (control and chrysotile-exposed) in these studies compares favorably with other NTP studies. The survival of males at 111 weeks of age was: untreated control, 67%; IR chrysotile, 73%; and IR/PW, 78%. The percentages of female rats alive at this time were: control, 72%; IR chrysotile, 72%; and IR/PW, 73%. In reviewing 25 recent NTP feed studies, Haseman (1983a) found an average of 66% of control males and 73% of control females alive at 112 weeks of age. In most 2-year carcinogenesis studies involving rats, females survive longer than males.

The survival of rats exposed to DMH was significantly lower than that of the untreated controls and the chrysotile groups. Both males and females that received IR chrysotile and DMH showed similar survival rates throughout the studies compared with those that received DMH alone.

Based on these observations, it appears that the rats could possibly have tolerated a higher level of asbestos exposure, although a level of 1% in the diet for the entire life of the animal is considered substantial. This dose level ranges from 1.6×10^5 to 1.6×10^{10} times the projected level of possible human exposure (DHEW Committee to Coordinate Toxicology and Related Programs, Subcommittee on Asbestos Protocols, unpublished data).

Ingestion of SR chrysotile asbestos over the lifetime of these rats did not cause any biologically significant increase of neoplasms at

HWBUI0001542

any anatomic site when compared with the concurrent controls. Mesotheliomas (all sites) appeared to be increased (not statistically significant, $P>0.05$) in male rats receiving SR chrysotile alone compared with the controls (6% vs 2%), but the incidence in the control group was somewhat low compared with the IR chrysotile control group (6%) and pooled male control groups from all the NTP oral asbestos studies (24/529, 4.5% [Appendix F]). Therefore, the biologic importance of this finding is discounted. SR chrysotile also did not produce any apparent increase in nonneoplastic disease. In summary, the ingestion of short-range chrysotile asbestos did not cause any adverse effect in either male or female F344/N rats.

Ingestion of IR chrysotile asbestos was associated with an increased incidence of neoplasia. Since the gastrointestinal tract was designated as a possible target organ based on epidemiologic studies in humans (Cooper et al., 1979) and because the test material was administered via the diet, the incidence of gastrointestinal neoplasms was examined in particular detail. For this reason, the increase in adenomatous polyps, which were grossly visible in the large intestine of IR chrysotile-exposed male rats, deserves special attention. These lesions are uncommon in standard 2-year carcinogenesis studies: 1/1,727 for male and 0/1,777 for female F344/N rats (Haseman et al., 1984). Overall, the incidence in dosed male rats in this study was low (9/250, 4%) and not statistically significant ($P=0.08$) compared with the concurrent controls (0/85). Despite the apparent marginal significance ($P<0.10$) of the large intestine tumor incidence in the IR chrysotile groups relative to concurrent controls, the actual level of significance associated with this comparison is greater than the nominal level because of the rarity of adenomatous polyps (Haseman, 1983b). For example, if the background incidence of large intestine tumors in lifetime studies of male F344/N rats is 0.6% (as suggested by the 3/524 rate observed in the pooled asbestos controls), then the probability of observing 9 or more (out of 250) adenomatous polyps of the large intestine by chance alone is less than 1 in 10,000. Further, the overall incidence of adenomatous polyps of the large intestine (9/250) was significant ($P=0.003$) relative to the rate in the pooled controls (3/524).

It is noteworthy that the other NTP asbestos studies were carried out at the same laboratory, conducted during an overlapping time frame, and used animals that were received from the same source and exposed to the same environmental conditions. The post mortem examinations were conducted with an identical protocol by the same technicians; the histopathologic examination used the same morphologic classification; and every neoplasm in question was reviewed by the Quality Assurance contractor and the NTP Pathology Working Group. It is particularly appropriate in this study, therefore, to give more credence than usual to the historical data. Further evidence for the relevance of this observation was the occurrence of adenomatous polyps in 2/100 male IR/PW chrysotile asbestos-exposed rats. Also, an additional 4/250 IR chrysotile male rats had neoplasms of similar histogenesis in the small intestine or glandular stomach, whereas none was found in the concurrent control group. These factors support the conclusion that the observed effect in the gastrointestinal tract, particularly the large intestine, of the male IR chrysotile asbestos group is quite unlikely to be due to chance alone.

To place this observation in proper context: First, adenomatous polyps are considered benign neoplasms. Second, no malignant epithelial neoplasms were observed in the large intestine in this study. Third, there was no evidence that any of the polyps had progressed to carcinoma, although this progression occurs with known intestinal carcinogens (e.g., in the DMH portion of this study). Fourth, because this was a lifetime study, more time was available for malignant progression. Fifth, an increase in gastrointestinal epithelial tumors was not observed in female IR chrysotile rats.

The above observations, which show a carcinogenic response to IR chrysotile but not to SR chrysotile asbestos, can probably be explained by the studies of Stanton et al. (1981) in which various types of natural and manmade mineral fibers were implanted into the pleural

HWBUI0001543

cavity of rats. Using pleural fibrosis and mesothelioma as end points, the investigators observed a correlation between fiber length and width and the fibers' carcinogenic potential. To be carcinogenic, fibers needed to be greater than 8 μm in length and less than 1.5 μm in diameter. Fibers of this type have been referred to as "S" (for Stanton) fibers (Harington, 1975). A far greater number of such "S" fibers were present in the IR than in the SR chrysotile asbestos used in these studies. It is also noteworthy that, when a chrysotile fiber breaks (in vivo or in vitro), it fractures in a longitudinal fashion, theoretically yielding more fibers of the "S" type and thus increasing the carcinogenic potential.

Keratoacanthomas of the skin were significantly increased in male IR chrysotile-exposed rats (19/250, 8%) and in the IR/PW groups (8/100, 8%) as compared with the controls (1/88, 1%). This observation deserves some consideration, since the increase was observed in both IR chrysotile studies; however, the incidence does not greatly exceed the mean control rates observed in all NTP rat oral asbestos studies: 20/529, 4% (Appendix F). Thus, this increase is not clearly related to the administration of IR chrysotile asbestos. The chrysotile asbestos used in these studies was incorporated into solid feed pellets, but the potential for skin exposure remains because asbestos particles are dislodged during eating. Nevertheless, even in inhalation studies in which considerable skin exposure also occurs, no increases in this lesion have been reported. If keratoacanthomas are actually related to chrysotile asbestos, which seems unlikely, direct exposure of the skin rather than a systemic route is the most plausible mechanism for induction of these neoplasms.

The incidence of neoplasms in the clitoral gland of female IR (18/250, 7%) and IR/PW (4/100, 4%) rats was increased compared with the concurrent controls (1/88, 1%). Only in the IR chrysotile alone group was the incidence significantly ($P<0.05$) increased. The incidence observed in the IR chrysotile groups did not differ significantly from the rate observed in all NTP oral asbestos studies (22/529, 4%). Moreover, no increase in neoplasia was observed in the male preputial gland (histogenetically related to the clitoral gland). Thus, this increase is not clearly related to the administration of IR chrysotile. Again, if these neoplasms were related to IR chrysotile, a direct route of exposure is the most probable cause.

Pheochromocytomas occurred at a greater incidence in male rats exposed to IR (63/250, 25%) and IR/PW (32/100, 32%) chrysotile than in the controls (17/85, 20%). Only in the IR/PW chrysotile group, however, was the incidence statistically significant (incidental tumor test, $P=0.02$). These rates are also comparable to those observed in all NTP oral asbestos studies (158/525, 30%). Therefore these neoplasms are not considered to be related to IR chrysotile asbestos exposure.

Nonneoplastic lesions that showed increased incidences in asbestos-exposed groups include cystic degeneration of the liver and inflammation of the prostate in male IR and IR/PW chrysotile groups. An explanation for these findings is not apparent, and their biologic relevance in this study is unknown.

Rats exposed to DMH exhibited neoplasia at those sites known as targets for this chemical: the gastrointestinal tract, Zymbal gland, liver, and kidney. In addition, the appearance of the DMH-induced neoplasms was comparable to those described previously in rats exposed to hydrazine compounds (Pozharisski, 1975). The incidence of intestinal neoplasia was slightly greater (male 32%, female 37%) in the DMH groups than the predicted incidence of 15% ± 5% based on a preliminary dose response study (McConnell et al., 1980). In the previous NTP oral amosite asbestos study in rats, in which DMH was administered at the same dose as in this study, the rate of intestinal neoplasia was 60-70%. A similar study of IR chrysotile asbestos and DMH in hamsters failed to elicit any neoplastic response in the intestine (NTP TR 246, in press). Apparently, the neoplastic dose response to DMH is relatively steep and duplication of a given incidence, particularly at the low end of the dose-response curve, is difficult to produce.

In addition to the previously mentioned neoplasms, DMH (with and without IR chrysotile) was also associated with an apparent

HWBUI0001544

increase in leukemia (decreased latency) in both male and female rats. The difference was statistically significant ($P<0.05$, life table analysis) compared with the concurrent controls, and the significance was enhanced when compared with the combined incidence of leukemia in the control groups from the other NTP oral asbestos studies. Although leukemia is not usually considered a response to DMH exposure, most DMH studies use a dose that produces a high incidence of lethal neoplasms in other organs. In such studies, the possibility exists that a leukemic effect might not be manifested or recognized due to the lethality of other types of neoplasms. Therefore, the increased incidence in leukemia in female rats in this study is considered to be related to DMH exposure, and IR chrysotile asbestos is not considered to affect its development.

If IR chrysotile has a cocarcinogenic or protective effect on DMH, it should have been manifested in one of the target organs. This relationship is not apparent in the intestine, liver, or Zymbal gland. There was a significant ($P<0.05$) increase, however, in neoplasms of the kidney in the IR plus DMH rats compared with the female rats that received DMH alone. Although the observation cannot be totally discounted, its biologic significance is questionable in light of the lack of a tumor-enhancing effect in the other three potential target organs.

The only other tumor incidence that was significantly ($P<0.05$) different in DMH groups as compared with IR plus DMH groups was that of thyroid follicular cell neoplasms (adenomas alone and adenomas or carcinomas combined) in male rats. The incidence in the DMH group was identical to that of the untreated controls, and there was no tumor-enhancing effect in females. For these reasons and because the thyroid gland is not usually affected by administration of either DMH or asbestos, this increase probably lacks biologic significance.

In summary, IR chrysotile asbestos did not appear to influence the rate of neoplasia induced by DMH, especially in the primary target organ (i.e., intestine). In contrast, IR chrysotile alone caused a slight increase in the incidence of adenomatous polyps in the large intestine of male rats. The keratoacanthomas of the skin in male rats and clitoral gland neoplasms in female rats were probably not related to IR chrysotile exposure.

Studies involving the long-term ingestion of other types of asbestos are few. Donham et al. (1980) reported equivocal tumor results in the intestine of F344 rats that were fed a diet containing 10% chrysotile for their lifetime. Although a significant ($P<0.05$) increase in the number of tumors in exposed animals was not observed, the authors believed that there was a trend toward increased colon lesions in general. They cited evidence of penetration of asbestos into the colonic mucosa and possible cytotoxicity to colonic tissues and suggested a relationship to peritoneal mesothelioma. Another equivocal study is that reported by Gibel et al. (1976), who described increases in malignant tumors in the lung, kidneys, liver, and reticuloendothelial system but not in intestinal neoplasia in Wistar rats fed asbestos filter material (20 mg/day) for 8-14 months. Cunningham et al. (1977), reported two studies (24 months or 30 months) in which Wistar male rats were administered 1% chrysotile asbestos in the diet. These authors concluded that trace amounts of ingested asbestos can penetrate the walls of the gastrointestinal tract, but evidence of carcinogenicity was inconclusive. No evidence of carcinogenicity was found by Gross et al. (1974), who fed rats a diet containing 5% chrysotile asbestos for 21 months. Bolton et al. (1982) exposed groups of 22-24 male HAN SPF Wistar-derived rats to amosite, crocidolite, or UICC standard reference chrysotile (similar to IR chrysotile) asbestos in the diet at a rate of approximately 250 mg/rat per week for 25 months and monitored the rats for the remainder of their lifespan. They concluded that no significant adverse effects occurred as a result of ingestion of any of these forms of asbestos. Previous NTP oral asbestos studies in rats in which amosite (NTP TR 279, in press) or crocidolite (NTP TR 280, in press) was administered with and without DMH did not show any indication of a carcinogenic response.

An oral asbestos study in hamsters was reported by Smith et al. (1980). Groups of 30 male and 30 female hamsters were exposed via drinking water for their lifetime to amosite asbestos, mine tailings, beach rock, or Lake Superior drinking water. No adverse effects on body

HWBUI0001545

weight or survival were observed for any of the groups. One peritoneal mesothelioma, one pulmonary carcinoma, and two early squamous cell carcinomas of the nonglandular stomach were found in the hamsters exposed to amosite. The authors concluded that the study was "essentially negative." A subsequent study in rats in which similar materials were used also failed to elicit a carcinogenic response (Hilding et al., 1981)

In companion studies to the rat studies in this report, Syrian golden hamsters were exposed to either short-range or intermediate-range chrysotile asbestos at a rate of 1% in the diet for their natural lifespan (NTP TR 246, in press). In both studies, no adverse effects were observed for body weight gain or survival, and no asbestos-related neoplasms were diagnosed. An ingestion study of amosite asbestos in hamsters using a similar design to this study did not demonstrate a carcinogenic response (NTP, 1983).

Except for the studies of Donham et al. (1980), Smith et al. (1980), Bolton et al. (1982), and the NTP studies, the other studies were conducted with relatively small numbers of animals. Also, some were conducted for an insufficient period of time to adequately test the carcinogenic potential of ingested asbestos.

The inhalation of asbestos fibers is clearly associated with lung cancer in humans (Selikoff, 1980) and in rats (Wagner et al., 1974). In the present studies chrysotile asbestos administered in the feed was associated with adenomatous polyps of the large intestine in male F344/N rats. The carcinogenic potential of chrysotile asbestos may be related to its cytogenetic effects. In support of this view, Oshimura et al. (1984) found an association between chrysotile asbestos and the induction of chromosomal alterations (chromosomal aberrations, polyploidy, and aneuploidy) in Syrian hamster embryo (SHE) cells. By electron microscopy, Hesterberg et al. (1982) demonstrated that asbestos fibers accumulated in the perinuclear region of SHE cells within 24-48 hours after exposure in vitro. Chromosomal aberrations and changes in the number of chromosomes are associated with a wide variety of rodent and human tumors (Sasaki, 1982; Yunis, 1983), and several mechanisms have been described to explain how certain chromosomal alterations may induce neoplasia (Ohno, 1977; Levan, 1981; Cavenne et al., 1983; Klein, 1983; Sandberg, 1983; Tsutsui et al., 1983). The occurrence of chromosomal aberrations at or near the site of cellular proto-oncogenes provides additional support for the concept that certain chromosomal changes may lead to cancer (Rowely, 1983). In summary, the current evidence suggests that the ability of chrysotile asbestos to induce chromosomal alterations may be a possible mechanism by which chrysotile asbestos induces neoplasia.

Conclusions: Under the conditions of these lifetime studies, short-range and intermediate-range chrysotile asbestos did not induce overt toxicity and did not affect survival when ingested at a level of 1% in the diet by male and female F344/N rats. There was *no evidence of carcinogenicity** in male or female rats exposed to SR chrysotile asbestos or in female rats exposed to IR chrysotile asbestos. There was *some evidence of carcinogenicity* in male rats exposed to IR chrysotile asbestos as indicated by an increased incidence of adenomatous polyps in the large intestine. The cocarcinogenesis studies of 1,2-dimethylhydrazine dihydrochloride and IR chrysotile asbestos were considered inconclusive for determining whether IR chrysotile asbestos had either a tumor-enhancing or protective effect, although an increased incidence of neoplasms was observed in the kidneys of female rats exposed to DMH plus IR chrysotile as compared with those exposed to DMH alone

*Categories of evidence of carcinogenicity are defined in the Note to the Reader on page 2.

HWBUI0001546

V. REFERENCES

HWBUI0001547

V. REFERENCES

1. Babu, K.; Nigam, S.; Lakkad, B.; Bhatt, D.; Karnik, A.; Thakore, K.; Kashyap, S.; Chatterjee, S. (1981) Effect of chrysotile asbestos (AP-I) on sister chromatid exchanges in Chinese hamster ovary cells. Environ. Res. 24:325-329.

2. Berenblum, I., Ed. (1969) Carcinogenicity Testing: A Report of the Panel on Carcinogenicity of the Cancer Research Commission of UICC, Vol. 2. Geneva: International Union Against Cancer.

3. Bey, E.; Harrington, J. (1971) Cytotoxic effects of some mineral dusts on Syrian hamster peritoneal macrophages. J. Exp. Med. 133:1149-1169.

4. Bolton, R.; Davis, J.; Lamb, D. (1982) The pathological effects of prolonged asbestos ingestion in rats. Environ. Res. 29:134-150.

5. Boorman, G.; Montgomery, C., Jr.; Hardisty, J.; Eustis, S.; Wolfe, M., McConnell, E. (1985): Quality assurance in pathology for rodent toxicology and carcinogenicity tests. Milman, H.; Weisburger, E., Eds.: Handbook of Carcinogen Testing. Park Ridge, NJ: Noyes Publications (in press).

6. Brown, R.; Chamberlain, M.; Davies, R.; Gaffen, J.; Skidmore, J. (1979) In vitro biological effects of glass fibers. J. Environ. Pathol. Toxicol. 2:1369-1383.

7. Bureau of Mines (1980) U.S. Department of the Interior, No. RI 28.23:8452.

8. Casey, G. (1983) Sister chromatid exchange and cell kinetics in CHO-Kl cells, human fibroblasts and lymphoblastoid cells exposed in vitro to asbestos and glass fibre. Mutat. Res. 116:369-377.

9. Cavenne, W.; Dryja, T.; Phillips, R.; Benedict, W.; Godbout, R.; Gallie, B.; Murphree, A.; Strong, L.; White, R. (1983) Expression of recessive alleles by chromosomal mechanisms in retinoblastoma. Nature 305:779-784.

10. Chamberlain, M.; Tarmy, E. (1977) Asbestos and glass fibers in bacterial mutation tests. Mutat. Res. 43:159-164.

11. Conforti, P. (1983) Effect of population density on the results of the study of water supplies in five California counties. Environ. Health Perspect. 53:69-78.

12. Cook, P. (1983) Review of published studies on gut penetration by ingested asbestos fibers. Environ. Health Perspect. 53:121-130.

13. Cooper, R.; Tarter, M.; Kanarek, M.; Murchio, J.; Conforti, P.; Jackson, L.; Callard, R.; Lysmer, D. (1979) Asbestos in Domestic Water Supplies in Five California Counties. EHS Pub. No. 79-1, Division of Environmental Health Sciences, School of Public Health, University of California, Berkeley.

14. Cox, D. (1972) Regression models and life tables. J. R. Stat. Soc. B34:187-220.

15. Craighead, J. (1982) Asbestos-associated diseases. Arch. Pathol. Lab. Med. 106:544-596.

16. Cunningham, H.; Pontefract, R. (1971) Asbestos fibers in beverages and drinking water. Nature 232:332-333.

17. Cunningham, H.; Moodie, C.; Lawrence, G.; Pontefract, R. (1977) Chronic effects of ingested asbestos in rats. Arch. Environ. Contam. Toxicol. 6:507-513.

18. Desai, R.; Richards, R. (1983) Effects of chrysotile on a lysosomal enzyme preparation and on the hydrolytic enzyme activity of cultured alveolar macrophages. Environ. Health Perspect. 51:125-130.

19. Donham, K.; Berg, J.; Will, L.; Leininger, J. (1980) The effects of long-term ingestion of asbestos on the colon of F344 rats. Cancer 45:1073-1084.

20. Environmental Health Perspectives (EHP) (1974) Proceedings of the Joint NIEHS-EPA Conference on Biological Effects of Ingested Asbestos. Environ. Health Perspect. 9:113-462.

21. Environmental Health Perspectives (EHP) (1983) Asbestos. U.S. Department of Health and Human Services, Public Health Service, National Institutes of Health, National Institute of Environmental Health Services, Vol. 53, November. 210 pp.

HWBUI0001548

22. Fiala, E.; Bobotas, G.; Kalukis, C.; Weisburger, J. (1976) Separation of 1,2-dimethylhydrazine metabolites by high pressure liquid chromatography. J. Chromatog. 117:181-185.

23. Gart, J.; Chu, K.; Tarone, R. (1979) Statistical issues in interpretation of chronic bioassay tests for carcinogenicity. J. Natl. Cancer Inst. 62(4):957-974.

24. Gibel, W.; Lohs, K.; Horn, K.; Wildner, G.; Hoffman, F., (1976) Investigation into a carcinogenic effect of asbestos filter materials following oral intake in experimental animals. Arch. fur Geschwulstforschung 46:437-442.

25. Gross, P.; Harley, R.; Swinberne, L.; Davis, J.; Green, W. (1974) Ingested mineral fibers, do they penetrate tissue or cause cancer? Arch. Environ. Health 29:341-347.

26. Harington, J.; Allison, A.; Badami, D. (1975) Mineral fibers: Chemical, physicochemical, and biological properties. Adv. Pharmacol. Chemother. 12:291-360.

27. Harrington, J.; Craun, G.; Meigs, J.; Landrigen, P.; Flannery, J. (1978) An investigation of the use of asbestos cement pipe for public water supply and the incidence of gastrointestinal cancer in Connecticut, 1935-1973. Am. J. Epidemiol. 107:96-103.

28. Haseman, J. (1983a) A reexamination of false-positive rates for carcinogenesis studies. Fundam. Appl. Toxicol. 3:334-339.

29. Haseman, J. (1983b) Patterns of tumor incidence in two-year cancer bioassay feeding studies in Fischer 344 rats. Fundam. Appl. Toxicol. 3:1-9.

30. Haseman, J. (1984) Statistical issues in the design, analysis and interpretation of animal carcinogenicity studies. Environ. Health Perspect. 58:385-392.

31. Haseman, J.; Huff, J.; Boorman, G. (1984) Use of historical control data in carcinogenicity studies in rodents. Toxicol. Pathol. 12:126-135.

32. Hesterberg, T.; Cummings, T.; Brody, A.; Barrett, J. (1982) Asbestos induces morphological transformation of Syrian hamster embryo cells in culture. J. Cell Biol. 95:449.

33. Hesterberg, T.; Barrett, J. (1984) Dependence of asbestos- and mineral dust-induced transformation of mammalian cells in culture on fiber dimension. Cancer Res. 44:2170-2180.

34. Hilding, A.; Hilding, D.; Larsen, D.; Aufderheide, A. (1981) Biological effects of ingested amosite asbestos, taconite tailings, diatomaceous earth and Lake Superior water in rats. Arch. Environ. Health 36:298-303.

35. Huang, S.; Saggioro, D.; Michelmann, H.; Malling, H. (1978) Genetic effects of crocidolite asbestos in Chinese hamster lung cells. Mutat. Res. 57:225-232.

36. Illinois Institute of Technology Research Institute (IITRI) Special Report and Addendum on Project L6085. IITRI, Fine Particle Laboratories, Chicago.

37. International Agency for Research on Cancer (IARC) (1977) Asbestos, IARC monographs on the evaluation of the carcinogenic risk of chemical to man, Vol. 14. Lyon, France, pp. 1-106.

38. Jaurand, M.; Bastie-Sigeac, I.; Renier, A.; Bignon, J. (1983) Comparative toxicities of different forms of asbestos on rat pleural mesothelial cells. Environ. Health Perspect. 51:153-159.

39. Kanarek, M. (1983) The San Francisco Bay epidemiology studies on asbestos in drinking water and cancer incidence: Relationship to studies in other locations and pointers for further research. Environ. Health Perspect. 51:105-106.

40. Kaplan, E.; Meier, P. (1958) Nonparametric estimation of incomplete observations. J. Am. Stat. Assoc. 53:457-481.

41. Kaplan, H.; Renier, A.; Jaurand, M.; Bignon, J. (1980) Sister chromatid exchanges in mesothelial cells cultured with chrysotile fibers. Brown, R., et al., Eds: The In Vitro Effects of Mineral Dusts. New York: Academic Press, pp. 251-253.

HWBUI0001549

42. Klein, G. (1983) Specific chromosomal translocations and the genesis of β-cell-derived tumors in mice and men. Cell 32:311-315.

43. Lavappa, K.; Fu, M.; Epstein, S. (1975) Cytogenetic studies on chrysotile asbestos. Environ. Res. 10:165-173.

44. Levan, G.; Mitelman, F. (1981) The different origin of primary and secondary chromosome aberrations in cancer. Haematol. Blood Transfusion 26:160-166.

45. Levine, R. (1978) Asbestos: An information resource. U.S. Department of Health and Human Services, National Institutes of Health, NIH 78-1681.

46. Linhart, M.; Cooper, J.; Martin, R.; Page, N.; Peters, J. (1974) Carcinogenesis bioassay data system. Comp. Biomed. Res. 7:230-248.

47. Mantel, N.; Haenszel, W. (1959) Statistical aspects of the analysis of data from retrospective studies of disease. J. Natl. Cancer Inst. 22:719-748.

48. Maronpot, R.; Boorman, G. (1982) Interpretation of rodent hepatocellular proliferative alterations and hepatocellular tumors in chemical safety assessment. Toxicol. Pathol. 10:71-80.

49. McConnell, E.; Wilson, R.; Moore, J.; Haseman, J. (1980) Dose response of 1,2-dimethylhydrazine and methylazoxymethanol acetate in the F344 rat. Cancer Lett. 8:271-278.

50. Meek, M. (1983) Transmigration of ingested asbestos. Environ. Health Perspect. 53:149-152.

51. Merliss, R. (1971a) Talc and asbestos contamination of rice. JAMA 216:2144.

52. Merliss, R. (1971b) Talc-treated rice and Japanese stomach cancer. Science 173:1141-1142.

53. Millette, J.; Clark, P.; Stober, J.; Rosenthal, M. (1983) Asbestos in water supplies of the United States. Environ. Health Perspect. 53:45-48.

54. National Toxicology Program (NTP) (in press) Lifetime Carcinogenesis Studies of Chrysotile Asbestos in Syrian Golden Hamsters. NTP TR 246. U.S. Department of Health and Human Services, Public Health Service, National Institutes of Health.

55. National Toxicology Program (NTP) (1983) Lifetime Carcinogenesis Studies of Amosite Asbestos in Syrian Golden Hamsters. NTP TR 249. U.S. Department of Health and Human Services, Public Health Service, National Institutes of Health.

56. National Toxicology Program (NTP) (in press) Lifetime Carcinogenesis Studies of Tremolite Asbestos in F344/N Rats. NTP TR 277. U.S. Department of Health and Human Services, Public Health Service, National Institutes of Health.

57. National Toxicology Program (NTP) (in press) Lifetime Carcinogenesis Studies of Amosite Asbestos in F344/N Rats. NTP TR 279. U.S. Department of Health and Human Services, Public Health Service, National Institutes of Health.

58. National Toxicology Program (NTP) (in press) Lifetime Carcinogenesis Studies of Crocidolite Asbestos in F344/N Rats. NTP TR 280. U.S. Department of Health and Human Services, Public Health Service, National Institutes of Health.

59. Ohno, S. (1977) Aneuploidy as a possible means employed by malignant cells to express recessive phenotypes. German, J., Ed.: Chromosomes and Cancer. New York: John Wiley, pp. 77-94.

60. Oshimura, M.; Hesterberg, T.; Tsutsui, T.; Barrett, J. (1984) Correlation of asbestos-induced cytogenetic effects with cell transformation of Syrian hamster embryo cells in culture. Cancer Res. 44:5017-5022.

61. Patel-Mandlik, K.; Millette, J. (1980) Evidence of migration of ingested asbestos into various baboon organs. Scanning Electron Microsc. 1:347-355.

HWBUI0001550

62. Patel-Mandlik, K.; Millette, J. (1983) Accumulation of ingested asbestos fibers in rat tissues over time. Environ. Health Perspect. 53:197-200.

63. Polissar, L.; Severson, R.; Boatman, E. (1983) Cancer risk from asbestos in drinking water: Summary of a case-control study in western Washington. Environ. Health Perspect. 53:57-60.

64. Pozharisski, K. (1975) Morphology and morphogenesis of experimental epithelial tumors of the intestine. J. Natl. Cancer Inst. 54:1115-1135.

65. Reiss, B.; Weisburger, J.; Williams, G. (1979) Asbestos and gastrointestinal cancer: Cell culture studies. U.S. Environmental Protection Agency, EPA-600/1-79-023, July.

66. Reiss, B.; Solomon, S.; Tong, C.; Levenstein, M.; Rosenberg, S.; Williams, G. (1982) Absence of mutagenic activity of three forms of asbestos in liver epithelial cells. Environ. Res. 27:389-397.

67. Rowe, J. (1983) Relative source contributions of diet and air to ingested asbestos exposure. Environ. Health Perspect. 53:115-120.

68. Rowely, J. (1983) Human oncogene locations and chromosome aberrations. Nature (London) 301:290-291.

69. Sandberg, A. (1983) A chromosomal hypothesis of oncogenesis. Cancer Genet. Cytogenet. 81:277-285.

70. Sasaki, M. (1982) Current status of cytogenetic studies in animal tumors with special reference to nonrandom chromosome changes. Cancer Genet. Cytogenet. 5:153-172.

71. Sebastien, P.; Masse, R.; Bignon, J. (1980) Recovery of ingested asbestos fibers from the gastrointestinal lymph in rats. Environ. Res. 22:201-216.

72. Selikoff, I. (1980) Asbestos-associated disease. Last, J., Ed.: Maxcy-Rosehau's Public Health and Preventive Medicine, 11th ed. Appleton-Century-Croft, pp. 568-589.

73. Selikoff, I.; Hammond, E., Eds. (1979) Health hazards of asbestos exposure. Ann. N.Y. Acad. Sci. B30:1-814.

74. Sincock, A. (1977) Preliminary studies of the in vitro cellular effects of asbestos and fine glass dusts. Hiatt, H; Watson, J.; Winsten, J, Eds: Origin of Human Cancer, Book B. New York: Cold Spring Harbor Laboratory, pp. 941-954.

75. Sincock, A.; Seabright, M. (1975) Induction of chromosome changes in Chinese hamster cells by exposure to asbestos fibers. Nature (London) 257:56-58.

76. Sincock, A.; Delhanty, J.; Casey, G. (1983) A comparison of the cytogenetic response to asbestos and glass fibre in Chinese hamster and human cell lines. Demonstration of growth inhibition in primary human fibroblasts. Mutat. Res. 101:257-268.

77. Smith, W.; Hubert, D.; Sobel, H.; Peters, E.; Doerfler, T. (1980) Health in experimental animals drinking water with and without amosite and other mineral particles. J. Environ. Pathol. Toxicol. 3:277-300.

78. Stanton, M.; Layard, M.; Tegaris, A.; Miller, E.; May, M.; Morgan, E.; Smith, A. (1981) Relation of particle dimension to the carcinogenicity in amphibole asbestoses and other fibrous minerals. J. Natl. Cancer Inst. 67:965-975.

79. Tsutsui, T.; Maizumi, H.; McLachlan, J.; Barrett, J. (1983) Aneuploidy induction and cell transformation by diethylstilbestrol: A possible chromosomal mechanism in carcinogenesis. Cancer Res. 43:3816-3821.

80. U.S. Department of Health, Education, and Welfare (DHEW). DHEW Committee to Coordinate Toxicology and Related Programs, Subcommittee on Asbestos Protocols.

81. U.S. Environmental Protection Agency (USEPA) (1980) Ambient Water Quality Criteria for Asbestos. EPA 440/5-80-022. Washington, DC: USEPA, Office of Water Regulations and Standards.

HWBUI0001551

82. Valerio, F.; de Ferrari, M.; Ottaggio, L.; Repetto, E.; Santi, L. (1983) Chromosomal aberrations induced by chrysotile and crocidolite in human lymphocytes in vitro. Mutat. Res. 122:397-402.

83. Wagner, J.; Berry, G.; Skidmore, J.; Timbrell, V. (1974) The effects of the inhalation of asbestos in rats. Br. J. Cancer 29:252-269.

84. Wright, A.; Donaldson, K.; Davis, J. (1983) Cytotoxic effect of asbestos on macrophages in different activation states. Environ. Health Perspect. 51:147-152.

85. Yunis, J. (1983) The chromosomal basis of human neoplasia. Science 221:227-236.

HWBUI0001552

APPENDIX A

SUMMARY OF THE INCIDENCE OF NEOPLASMS IN RATS IN THE LIFETIME FEED STUDIES OF SHORT-RANGE CHRYSOTILE ASBESTOS

HWBUI0001553

TABLE A1. SUMMARY OF THE INCIDENCE OF NEOPLASMS IN MALE RATS IN THE LIFETIME FEED STUDY OF SHORT-RANGE CHRYSOTILE ASBESTOS

	CONTROL (UNTR)	SHORT RANGE
ANIMALS INITIALLY IN STUDY	88	250
ANIMALS NECROPSIED	88	250
ANIMALS EXAMINED HISTOPATHOLOGICALLY	88	248
INTEGUMENTARY SYSTEM		
*HARDERIAN GLAND	(88)	(250)
FIBROUS HISTIOCYTOMA, MALIGNANT	1 (1%)	
*MULTIPLE ORGANS	(88)	(250)
FIBROUS HISTIOCYTOMA, MALIGNANT	1 (1%)	1 (0%)
*SKIN	(88)	(250)
SQUAMOUS CELL PAPILLOMA	1 (1%)	7 (3%)
SQUAMOUS CELL CARCINOMA		3 (1%)
BASAL-CELL TUMOR		5 (2%)
BASAL-CELL CARCINOMA	3 (3%)	12 (5%)
TRICHOEPITHELIOMA		1 (0%)
SEBACEOUS ADENOMA		1 (0%)
KERATOACANTHOMA	5 (6%)	14 (6%)
FIBROUS HISTIOCYTOMA		1 (0%)
FIBROUS HISTIOCYTOMA, MALIGNANT	1 (1%)	1 (0%)
*SUBCUT TISSUE	(88)	(250)
SQUAMOUS CELL CARCINOMA, INVASIVE	1 (1%)	
SARCOMA, NOS		3 (1%)
FIBROMA	13 (15%)	25 (10%)
FIBROSARCOMA	4 (5%)	6 (2%)
FIBROUS HISTIOCYTOMA, MALIGNANT		1 (0%)
MYXOSARCOMA		1 (0%)
LIPOMA		1 (0%)
LIPOSARCOMA	1 (1%)	2 (1%)
LEIOMYOSARCOMA, INVASIVE		1 (0%)
NEUROFIBROMA	1 (1%)	9 (4%)
NEUROFIBROSARCOMA	3 (3%)	2 (1%)
RESPIRATORY SYSTEM		
*NASAL TURBINATE	(88)	(250)
CARCINOMA, NOS		1 (0%)
SQUAMOUS CELL CARCINOMA		1 (0%)
#TRACHEA	(87)	(248)
FOLLICULAR-CELL CARCINOMA, INVASIVE		1 (0%)
C-CELL CARCINOMA, METASTATIC		1 (0%)
#LUNG	(88)	(247)
CARCINOMA, NOS, METASTATIC	1 (1%)	
SQUAMOUS CELL CARCINOMA, METASTATIC		3 (1%)
ALVEOLAR/BRONCHIOLAR ADENOMA		1 (0%)
ALVEOLAR/BRONCHIOLAR CARCINOMA	2 (2%)	6 (2%)
C-CELL CARCINOMA, METASTATIC		2 (1%)
FIBROSARCOMA, METASTATIC		1 (0%)
LIPOSARCOMA, METASTATIC		4 (2%)
MESOTHELIOMA, METASTATIC		1 (0%)
OSTEOSARCOMA, METASTATIC		1 (0%)
HEMATOPOIETIC SYSTEM		
*MULTIPLE ORGANS	(88)	(250)
MALIGNANT LYMPHOMA, NOS		2 (1%)
MALIG. LYMPHOMA, UNDIFFER-TYPE		1 (0%)
MALIG. LYMPHOMA, LYMPHOCYTIC TYPE	1 (1%)	1 (0%)
MALIG. LYMPHOMA, HISTIOCYTIC TYPE	1 (1%)	1 (0%)
MYELOMONOCYTIC LEUKEMIA	1 (1%)	
MONOCYTIC LEUKEMIA	34 (39%)	105 (42%)
LEUKEMIA, MONONUCLEAR CELL	1 (1%)	1 (0%)

HWBUI0001554

TABLE A1. SUMMARY OF THE INCIDENCE OF NEOPLASMS IN MALE RATS IN THE LIFETIME FEED STUDY OF SHORT-RANGE CHRYSOTILE ASBESTOS (Continued)

	CONTROL (UNTR)	SHORT RANGE
#BONE MARROW	(88)	(247)
LIPOSARCOMA, INVASIVE		1 (0%)
#SPLEEN	(88)	(247)
MESOTHELIOMA, METASTATIC		1 (0%)
MALIG. LYMPHOMA, HISTIOCYTIC TYPE		1 (0%)
#MANDIBULAR L. NODE	(88)	(248)
CARCINOMA, NOS, METASTATIC		1 (0%)
C-CELL CARCINOMA, METASTATIC		1 (0%)
SARCOMA, NOS, INVASIVE		1 (0%)
FIBROSARCOMA, INVASIVE		1 (0%)
#CERVICAL LYMPH NODE	(88)	(248)
C-CELL CARCINOMA, METASTATIC		1 (0%)
#MEDIASTINAL LYMPH NODE	(88)	(248)
MESOTHELIOMA, METASTATIC	1 (1%)	1 (0%)
#ILEOCOLIC LYMPH NODE	(88)	(248)
SQUAMOUS CELL CARCINOMA, METASTATIC		1 (0%)
#RENAL LYMPH NODE	(88)	(248)
INTERSTITIAL-CELL TUMOR, METASTATIC		1 (0%)
#LIVER	(88)	(248)
MONOCYTIC LEUKEMIA	1 (1%)	3 (1%)
#THYMUS	(76)	(197)
CARCINOMA, NOS		1 (1%)
ADENOCARCINOMA, NOS	1 (1%)	
CIRCULATORY SYSTEM		
*MULTIPLE ORGANS	(88)	(250)
HEMANGIOSARCOMA, METASTATIC		1 (0%)
*MEDIASTINUM	(88)	(250)
HEMANGIOSARCOMA		1 (0%)
*SKIN	(88)	(250)
HEMANGIOMA		1 (0%)
*SUBCUT TISSUE	(88)	(250)
HEMANGIOSARCOMA		2 (1%)
HEMANGIOPERICYTOMA, MALIGNANT	1 (1%)	
#SPLEEN	(88)	(247)
HEMANGIOMA		1 (0%)
HEMANGIOSARCOMA	2 (2%)	5 (2%)
#HEART	(88)	(247)
CARCINOMA, NOS, INVASIVE		1 (0%)
FIBROSARCOMA, METASTATIC		1 (0%)
#LIVER	(88)	(248)
HEMANGIOSARCOMA, METASTATIC		1 (0%)
DIGESTIVE SYSTEM		
*HARD PALATE	(88)	(250)
SQUAMOUS CELL PAPILLOMA		1 (0%)
#SALIVARY GLAND	(87)	(243)
SARCOMA, NOS		1 (0%)
FIBROSARCOMA		3 (1%)
#LIVER	(88)	(248)
NEOPLASTIC NODULE	12 (14%)	17 (7%)
HEPATOCELLULAR CARCINOMA	3 (3%)	2 (1%)
C-CELL CARCINOMA, METASTATIC		1 (0%)
FIBROSARCOMA, METASTATIC		1 (0%)
#PANCREAS	(86)	(247)
ACINAR-CELL ADENOMA	7 (8%)	14 (6%)
MIXED TUMOR, BENIGN		3 (1%)
#STOMACH	(88)	(248)
SQUAMOUS CELL PAPILLOMA		1 (0%)
SQUAMOUS CELL CARCINOMA		1 (0%)
SARCOMA, NOS		1 (0%)

HWBUI0001555

TABLE A1. SUMMARY OF THE INCIDENCE OF NEOPLASMS IN MALE RATS IN THE LIFETIME FEED STUDY OF SHORT-RANGE CHRYSOTILE ASBESTOS (Continued)

	CONTROL (UNTR)	SHORT RANGE
REPRODUCTIVE SYSTEM (Continued)		
*PREPUTIAL GLAND	(88)	(250)
CARCINOMA, NOS	4 (5%)	8 (3%)
SQUAMOUS CELL CARCINOMA	2 (2%)	5 (2%)
ADENOMA, NOS		1 (0%)
KERATOACANTHOMA		1 (0%)
#PROSTATE	(87)	(247)
ADENOMA, NOS		2 (1%)
#TESTIS	(87)	(246)
INTERSTITIAL-CELL TUMOR	81 (93%)	238 (97%)
INTERSTITIAL-CELL TUMOR, MALIGNANT		1 (0%)
*EPIDIDYMIS	(88)	(250)
MESOTHELIOMA, INVASIVE	1 (1%)	2 (1%)
*SCROTUM	(88)	(250)
MESOTHELIOMA, INVASIVE	1 (1%)	2 (1%)
NERVOUS SYSTEM		
#CEREBRUM	(88)	(248)
ASTROCYTOMA	2 (2%)	3 (1%)
#BRAIN	(88)	(248)
CARCINOMA, NOS, INVASIVE		1 (0%)
#CEREBELLUM	(88)	(248)
ASTROCYTOMA	2 (2%)	2 (1%)
SPECIAL SENSE ORGANS		
*HARDERIAN GLAND	(88)	(250)
CARCINOMA,NOS	1 (1%)	
*ZYMBAL GLAND	(88)	(250)
SQUAMOUS CELL PAPILLOMA	1 (1%)	1 (0%)
SQUAMOUS CELL CARCINOMA	4 (5%)	4 (2%)
MUSCULOSKELETAL SYSTEM		
*SKULL	(88)	(250)
OSTEOSARCOMA		1 (0%)
*MANDIBLE	(88)	(250)
SQUAMOUS CELL CARCINOMA, INVASIVE	1 (1%)	
*LUMBAR VERTEBRA	(88)	(250)
LIPOSARCOMA		1 (0%)
LIPOSARCOMA, INVASIVE		1 (0%)
*SACRUM	(88)	(250)
LIPOSARCOMA, INVASIVE		1 (0%)
*STERNUM	(88)	(250)
OSTEOSARCOMA	1 (1%)	
*RIB	(88)	(250)
OSTEOSARCOMA	1 (1%)	
*FEMUR	(88)	(250)
OSTEOSARCOMA		1 (0%)
BODY CAVITIES		
*MEDIASTINUM	(88)	(250)
ALVEOLAR/BRONCHIOLAR CARCINOMA, INVASIVE		1 (0%)
FIBROSARCOMA, INVASIVE		1 (0%)
*ABDOMINAL CAVITY	(88)	(250)
PHEOCHROMOCYTOMA, METASTATIC		1 (0%)
*MESENTERY	(88)	(250)
FIBROSARCOMA		1 (0%)
MESOTHELIOMA, MALIGNANT		1

HWBUI0001556

TABLE A1. SUMMARY OF THE INCIDENCE OF NEOPLASMS IN MALE RATS IN THE LIFETIME FEED STUDY OF SHORT-RANGE CHRYSOTILE ASBESTOS (Continued)

	CONTROL (UNTR)	SHORT RANGE
BODY CAVITIES (Continued)		
*TUNICA VAGINALIS	(88)	(250)
MESOTHELIOMA, MALIGNANT	2 (2%)	14 (6%)
ALL OTHER SYSTEMS		
*MULTIPLE ORGANS	(88)	(250)
CARCINOMA, NOS, INVASIVE	1 (1%)	
SQUAMOUS CELL CARCINOMA, INVASIVE		1 (0%)
C-CELL CARCINOMA, METASTATIC		1 (0%)
PHEOCHROMOCYTOMA, METASTATIC	1 (1%)	
FIBROSARCOMA, INVASIVE		1 (0%)
FIBROUS HISTIOCYTOMA, METASTATIC	1 (1%)	
MESOTHELIOMA, INVASIVE	1 (1%)	13 (5%)
OSTEOSARCOMA, METASTATIC	1 (1%)	
ANIMAL DISPOSITION SUMMARY		
ANIMALS INITIALLY IN STUDY	88	250
NATURAL DEATH@	13	43
MORIBUND SACRIFICE	63	181
SCHEDULED SACRIFICE		
TERMINAL SACRIFICE	9	26
DOSING ACCIDENT		
ACCIDENTALLY KILLED, NDA	3	
ACCIDENTALLY KILLED, NOS		
ANIMAL MISSING		
ANIMAL MISSEXED		
OTHER CASES		
TUMOR SUMMARY		
TOTAL ANIMALS WITH PRIMARY TUMORS**	85	248
TOTAL PRIMARY TUMORS	315	847
TOTAL ANIMALS WITH BENIGN TUMORS	82	244
TOTAL BENIGN TUMORS	197	552
TOTAL ANIMALS WITH MALIGNANT TUMORS	71	199
TOTAL MALIGNANT TUMORS	106	278
TOTAL ANIMALS WITH SECONDARY TUMORS##	7	40
TOTAL SECONDARY TUMORS	12	59
TOTAL ANIMALS WITH TUMORS UNCERTAIN-BENIGN OR MALIGNANT	12	17
TOTAL UNCERTAIN TUMORS	12	17
TOTAL ANIMALS WITH TUMORS UNCERTAIN-PRIMARY OR METASTATIC		
TOTAL UNCERTAIN TUMORS		

* NUMBER OF ANIMALS NECROPSIED
** PRIMARY TUMORS: ALL TUMORS EXCEPT SECONDARY TUMORS
# NUMBER OF ANIMALS WITH TISSUE EXAMINED MICROSCOPICALLY
SECONDARY TUMORS: METASTATIC TUMORS OR TUMORS INVASIVE INTO AN ADJACENT ORGAN
@ INCLUDES AUTOLYZED ANIMALS

HWBUI0001557

TABLE A2. SUMMARY OF THE INCIDENCE OF NEOPLASMS IN FEMALE RATS IN THE LIFETIME FEED STUDY OF SHORT-RANGE CHRYSOTILE ASBESTOS

	CONTROL (UNTR)	SHORT RANGE
ANIMALS INITIALLY IN STUDY	88	250
ANIMALS NECROPSIED	88	250
ANIMALS EXAMINED HISTOPATHOLOGICALLY	87	245
INTEGUMENTARY SYSTEM		
*SKIN	(88)	(250)
SQUAMOUS CELL PAPILLOMA	1 (1%)	4 (2%)
SQUAMOUS CELL CARCINOMA	1 (1%)	5 (2%)
BASAL-CELL TUMOR		1 (0%)
BASAL-CELL CARCINOMA	1 (1%)	
TRICHOEPITHELIOMA		1 (0%)
KERATOACANTHOMA	2 (2%)	2 (1%)
FIBROSARCOMA		1 (0%)
*SUBCUT TISSUE	(88)	(250)
SQUAMOUS CELL CARCINOMA, INVASIVE	2 (2%)	
FIBROMA	1 (1%)	3 (1%)
FIBROSARCOMA	2 (2%)	3 (1%)
LIPOMA	1 (1%)	1 (0%)
LIPOSARCOMA	1 (1%)	
OSTEOSARCOMA		1 (0%)
NEUROFIBROMA		1 (0%)
RESPIRATORY SYSTEM		
*NASAL TURBINATE	(88)	(250)
SQUAMOUS CELL CARCINOMA	1 (1%)	
SQUAMOUS CELL CARCINOMA, INVASIVE		1 (0%)
#TRACHEA	(87)	(245)
C-CELL CARCINOMA, INVASIVE		1 (0%)
#LUNG	(87)	(245)
SQUAMOUS CELL CARCINOMA, METASTATIC	1 (1%)	
ADENOCARCINOMA, NOS, METASTATIC		2 (1%)
ALVEOLAR/BRONCHIOLAR CARCINOMA	1 (1%)	1 (0%)
FOLLICULAR-CELL CARCINOMA, METASTATIC	1 (1%)	
C-CELL CARCINOMA, METASTATIC		3 (1%)
GRANULOSA-CELL CARCINOMA, METASTATIC		1 (0%)
PHEOCHROMOCYTOMA, METASTATIC		1 (0%)
CARCINOSARCOMA, METASTATIC		1 (0%)
OSTEOSARCOMA, METASTATIC		1 (0%)
HEMATOPOIETIC SYSTEM		
*MULTIPLE SITES	(88)	(250)
MALIG. LYMPHOMA, HISTIOCYTIC TYPE		1 (0%)
*MULTIPLE ORGANS	(88)	(250)
MALIG. LYMPHOMA, UNDIFFER-TYPE		1 (0%)
MALIG. LYMPHOMA, HISTIOCYTIC TYPE	1 (1%)	
MYELOMONOCYTIC LEUKEMIA		1 (0%)
MONOCYTIC LEUKEMIA	26 (30%)	99 (40%)
LEUKEMIA, MONONUCLEAR CELL	1 (1%)	1 (0%)
#CERVICAL LYMPH NODE	(87)	(245)
C-CELL CARCINOMA, METASTATIC		2 (1%)
#MEDIASTINAL L. NODE	(87)	(245)
ADENOCARCINOMA, NOS, METASTATIC		1 (0%)
#RENAL LYMPH NODE	(87)	(245)
ADENOCARCINOMA, NOS, METASTATIC		1 (0%)
#LIVER	(87)	(244)
MONOCYTIC LEUKEMIA	1 (1%)	

HWBUI0001558

TABLE A2. SUMMARY OF THE INCIDENCE OF NEOPLASMS IN FEMALE RATS IN THE LIFETIME FEED STUDY OF SHORT-RANGE CHRYSOTILE ASBESTOS (Continued)

	CONTROL (UNTR)	SHORT RANGE
HEMATOPOIETIC SYSTEM (Continued)		
#THYMUS	(67)	(190)
ADENOCARCINOMA, NOS		2 (1%)
TERATOMA, BENIGN		1 (1%)
MALIG. LYMPHOMA, UNDIFFER-TYPE		1 (1%)
CIRCULATORY SYSTEM		
#SPLEEN	(87)	(245)
ANGIOMA	1 (1%)	
#HEART	(87)	(245)
C-CELL CARCINOMA, METASTATIC		1 (0%)
#ENDOCARDIUM	(87)	(245)
SARCOMA, NOS	1 (1%)	
DIGESTIVE SYSTEM		
*ORAL MUCOUS MEMBRANE	(88)	(250)
SQUAMOUS CELL CARCINOMA		1 (0%)
*TONGUE	(88)	(250)
SQUAMOUS CELL PAPILLOMA		1 (0%)
SQUAMOUS CELL CARCINOMA		1 (0%)
#SALIVARY GLAND	(87)	(243)
SQUAMOUS CELL CARCINOMA, INVASIVE		1 (0%)
#LIVER	(87)	(244)
ISLET-CELL CARCINOMA, METASTATIC		1 (0%)
NEOPLASTIC NODULE	3 (3%)	5 (2%)
C-CELL CARCINOMA, METASTATIC		1 (0%)
OSTEOSARCOMA, METASTATIC		1 (0%)
#PANCREAS	(86)	(245)
ADENOCARCINOMA, NOS	1 (1%)	
ACINAR-CELL ADENOMA	1 (1%)	1 (0%)
ACINAR-CELL CARCINOMA	1 (1%)	
GRANULOSA-CELL CARCINOMA, METASTATIC		1 (0%)
*PHARYNX	(88)	(250)
SQUAMOUS CELL CARCINOMA, INVASIVE	1 (1%)	
#STOMACH	(87)	(245)
CARCINOMA, NOS, METASTATIC		1 (0%)
SQUAMOUS CELL CARCINOMA		1 (0%)
#DUODENUM	(87)	(244)
LEIOMYOSARCOMA		2 (1%)
#JEJUNUM	(87)	(244)
ADENOCA IN ADENOMATOUS POLYP		1 (0%)
MUCINOUS CYSTADENOCARCINOMA		1 (0%)
LEIOMYOMA		1 (0%)
#ILEUM	(87)	(244)
LEIOMYOSARCOMA	1 (1%)	
#CECUM	(87)	(244)
ADENOMATOUS POLYP, NOS	1 (1%)	
#TRANSVERSE COLON	(87)	(244)
ADENOMATOUS POLYP, NOS		1 (0%)
#DESCENDING COLON	(87)	(244)
ADENOMATOUS POLYP, NOS		2 (1%)
LEIOMYOSARCOMA		1 (0%)
URINARY SYSTEM		
#KIDNEY	(87)	(245)
TRANSITIONAL-CELL CARCINOMA		1 (0%)
PHEOCHROMOCYTOMA, METASTATIC		1 (0%)
#URINARY BLADDER	(87)	(242)
ENDOMETRIAL STROMAL SARCOMA, INVASIVE		1 (0%)

HWBUI0001559

TABLE A2. SUMMARY OF THE INCIDENCE OF NEOPLASMS IN FEMALE RATS IN THE LIFETIME FEED STUDY OF SHORT-RANGE CHRYSOTILE ASBESTOS (Continued)

	CONTROL (UNTR)	SHORT RANGE
ENDOCRINE SYSTEM		
#PITUITARY	(87)	(244)
CARCINOMA, NOS	6 (7%)	13 (5%)
ADENOMA, NOS	39 (45%)	101 (41%)
GANGLIONEUROMA		1 (0%)
NEUROFIBROSARCOMA		1 (0%)
#ADRENAL	(87)	(245)
CORTICAL ADENOMA	2 (2%)	8 (3%)
PHEOCHROMOCYTOMA	9 (10%)	38 (16%)
PHEOCHROMOCYTOMA, MALIGNANT		1 (0%)
#THYROID	(87)	(244)
FOLLICULAR-CELL ADENOMA	1 (1%)	4 (2%)
FOLLICULAR-CELL CARCINOMA	4 (5%)	8 (3%)
C-CELL ADENOMA	11 (13%)	20 (8%)
C-CELL CARCINOMA	7 (8%)	21 (9%)
CARCINOSARCOMA, INVASIVE		1 (0%)
#PARATHYROID	(85)	(222)
ADENOMA, NOS		1 (0%)
#PANCREATIC ISLETS	(86)	(245)
ISLET-CELL ADENOMA	2 (2%)	5 (2%)
ISLET-CELL CARCINOMA	2 (2%)	3 (1%)
REPRODUCTIVE SYSTEM		
*MAMMARY GLAND	(88)	(250)
CARCINOMA, NOS	1 (1%)	
ADENOMA, NOS	2 (2%)	14 (6%)
ADENOCARCINOMA, NOS	6 (7%)	19 (8%)
PAPILLARY ADENOCARCINOMA		1 (0%)
PAPILLARY CYSTADENOMA, NOS	1 (1%)	5 (2%)
PAPILLARY CYSTADENOCARCINOMA, NOS	1 (1%)	
FIBROSARCOMA	1 (1%)	1 (0%)
FIBROADENOMA	49 (56%)	146 (58%)
*CLITORAL GLAND	(88)	(250)
CARCINOMA, NOS	1 (1%)	8 (3%)
SQUAMOUS CELL PAPILLOMA		1 (0%)
SQUAMOUS CELL CARCINOMA	1 (1%)	9 (4%)
ADENOMA, NOS	1 (1%)	1 (0%)
KERATOACANTHOMA		4 (2%)
*VAGINA	(88)	(250)
SQUAMOUS CELL PAPILLOMA		1 (0%)
#UTERUS	(87)	(245)
CARCINOMA,NOS	2 (2%)	
ADENOCARCINOMA, NOS		1 (0%)
ENDOMETRIAL STROMAL POLYP	15 (17%)	34 (14%)
ENDOMETRIAL STROMAL SARCOMA		4 (2%)
#CERVIX UTERI	(87)	(245)
CARCINOMA-IN-SITU, NOS	1 (1%)	1 (0%)
ENDOMETRIAL STROMAL SARCOMA, INVASIVE		2 (1%)
#UTERUS/ENDOMETRIUM	(87)	(245)
CARCINOSARCOMA	1 (1%)	
#OVARY	(87)	(245)
THECOMA	2 (2%)	
GRANULOSA-CELL TUMOR	1 (1%)	3 (1%)
GRANULOSA-CELL CARCINOMA		2 (1%)
MESOTHELIOMA, NOS		1 (0%)

HWBUI0001560

TABLE A2. SUMMARY OF THE INCIDENCE OF NEOPLASMS IN FEMALE RATS IN THE LIFETIME FEED STUDY OF SHORT-RANGE CHRYSOTILE ASBESTOS (Continued)

	CONTROL (UNTR)	SHORT RANGE
NERVOUS SYSTEM		
#CEREBRUM	(87)	(245)
CARCINOMA, NOS, INVASIVE	3 (3%)	8 (3%)
CARCINOMA, NOS, METASTATIC	1 (1%)	
ASTROCYTOMA		4 (2%)
MENINGIOMA		1 (0%)
#CEREBELLUM	(87)	(245)
CARCINOMA, NOS, INVASIVE	2 (2%)	3 (1%)
MENINGIOMA		1 (0%)
SPECIAL SENSE ORGANS		
*ZYMBAL GLAND	(88)	(250)
SQUAMOUS CELL PAPILLOMA		1 (0%)
SQUAMOUS CELL CARCINOMA	3 (3%)	1 (0%)
CARCINOSARCOMA		1 (0%)
MUSCULOSKELETAL SYSTEM		
*MAXILLA	(88)	(250)
SQUAMOUS CELL CARCINOMA, INVASIVE		1 (0%)
*SACRUM	(88)	(250)
OSTEOSARCOMA	1 (1%)	
*RIB	(88)	(250)
OSTEOSARCOMA		1 (0%)
*FEMUR	(88)	(250)
OSTEOSARCOMA		1 (0%)
BODY CAVITIES		
*ABDOMINAL CAVITY	(88)	(250)
PHEOCHROMOCYTOMA, INVASIVE		1 (0%)
ALL OTHER SYSTEMS		
*MULTIPLE ORGANS	(88)	(250)
CARCINOMA, NOS, INVASIVE	1 (1%)	
SQUAMOUS CELL CARCINOMA, INVASIVE	2 (2%)	1 (0%)
SARCOMA, NOS, INVASIVE	1 (1%)	
SARCOMA, NOS, METASTATIC	1 (1%)	
CHEEK		
SQUAMOUS CELL CARCINOMA, INVASIVE	1	
LEG		
OSTEOSARCOMA		1
ANIMAL DISPOSITION SUMMARY		
ANIMALS INITIALLY IN STUDY	88	250
NATURAL DEATH@	10	31
MORIBUND SACRIFICE	69	194
SCHEDULED SACRIFICE		
TERMINAL SACRIFICE	9	25
DOSING ACCIDENT		
ACCIDENTALLY KILLED, NDA		
ACCIDENTALLY KILLED, NOS		
ANIMAL MISSING		
ANIMAL MISSEXED		
OTHER CASES		

HWBUI0001561

TABLE A2. SUMMARY OF THE INCIDENCE OF NEOPLASMS IN FEMALE RATS IN THE LIFETIME FEED STUDY OF SHORT-RANGE CHRYSOTILE ASBESTOS (Continued)

	CONTROL (UNTR)	SHORT RANGE
TUMOR SUMMARY		
TOTAL ANIMALS WITH PRIMARY TUMORS**	86	239
TOTAL PRIMARY TUMORS	224	644
TOTAL ANIMALS WITH BENIGN TUMORS	75	212
TOTAL BENIGN TUMORS	142	405
TOTAL ANIMALS WITH MALIGNANT TUMORS	52	177
TOTAL MALIGNANT TUMORS	78	230
TOTAL ANIMALS WITH SECONDARY TUMORS##	11	30
TOTAL SECONDARY TUMORS	17	41
TOTAL ANIMALS WITH TUMORS UNCERTAIN-BENIGN OR MALIGNANT	4	9
TOTAL UNCERTAIN TUMORS	4	9
TOTAL ANIMALS WITH TUMORS UNCERTAIN-PRIMARY OR METASTATIC		
TOTAL UNCERTAIN TUMORS		

* NUMBER OF ANIMALS NECROPSIED
** PRIMARY TUMORS: ALL TUMORS EXCEPT SECONDARY TUMORS
# NUMBER OF ANIMALS WITH TISSUE EXAMINED MICROSCOPICALLY
SECONDARY TUMORS: METASTATIC TUMORS OR TUMORS INVASIVE INTO AN ADJACENT ORGAN
@ INCLUDES AUTOLYZED ANIMALS

HWBUI0001562

TABLE A3. INDIVIDUAL ANIMAL TUMOR PATHOLOGY OF MALE RATS IN THE LIFETIME FEED STUDY OF SHORT-RANGE CHRYSOTILE ASBESTOS: UNTREATED CONTROL

ANIMAL NUMBER	54901	55301	55302	55502	55503	55504	55505	55506	55507	55508	55509	55601	55701	55702	55703	55704	55705	55706	55707	55708	55709	55801	55802	55803	55804	55805
WEEKS ON STUDY	112	131	122	123	126	106	135	137	111	153	137	122	104	149	144	133	137	126	109	108	110	118	109	108	132	122
INTEGUMENTARY SYSTEM																										
SKIN	+	+	+	+	+	+	+	+	+	+	+	+	+	+	+	+	+	+	+	+	+	+	+	+	+	M
SQUAMOUS CELL PAPILLOMA										X																
BASAL-CELL CARCINOMA		X																				X				
KERATOACANTHOMA					X													X								
FIBROUS HISTIOCYTOMA, MALIGNANT																										
SUBCUTANEOUS TISSUE	+	+	+	+	+	+	+	+	+	+	+	+	+	+	+	+	+	+	+	+	+	+	+	+	+	M
SQUAMOUS CELL CARCINOMA, INVASIVE																										
FIBROMA							X										X								X
FIBROSARCOMA																			X							X
LIPOSARCOMA																										
HEMANGIOPERICYTOMA, MALIGNANT																										
NEUROFIBROMA																										
NEUROFIBROSARCOMA														X												
RESPIRATORY SYSTEM																										
LUNGS AND BRONCHI	+	+	+	+	+	+	+	+	+	+	+	+	+	+	+	+	+	+	+	+	+	+	+	+	+	+
CARCINOMA, NOS, METASTATIC																										
ALVEOLAR/BRONCHIOLAR CARCINOMA																										
TRACHEA	+	+	-	+	+	+	+	+	+	+	+	+	+	+	+	+	+	+	+	+	+	+	+	+	+	+
HEMATOPOIETIC SYSTEM																										
BONE MARROW	+	+	+	+	+	+	+	+	+	+	+	+	+	+	+	+	+	+	+	+	+	+	+	+	+	+
SPLEEN	+	+	+	+	+	+	+	+	+	+	+	+	+	+	+	+	+	+	+	+	+	+	+	+	+	+
HEMANGIOSARCOMA							X																			
LYMPH NODES	+	+	+	+	+	+	+	+	+	+	+	+	+	+	+	+	+	+	+	+	+	+	+	+	+	+
MESOTHELIOMA, METASTATIC																										
THYMUS	+	+	+	+	+	+	+	+	-	+	+	+	+	+	+	+	+	+	+	+	+	+	+	+	+	+
ADENOCARCINOMA, NOS																										
CIRCULATORY SYSTEM																										
HEART	+	+	+	+	+	+	+	+	+	+	+	+	+	+	+	+	+	+	+	+	+	+	+	+	+	+
DIGESTIVE SYSTEM																										
SALIVARY GLAND	+	+	-	+	+	+	+	+	+	+	+	+	+	+	+	+	+	+	+	+	+	+	+	+	+	+
LIVER	+	+	+	+	+	+	+	+	+	+	+	+	+	+	+	+	+	+	+	+	+	+	+	+	+	+
NEOPLASTIC NODULE							X				X															
HEPATOCELLULAR CARCINOMA	X																									
MONOCYTIC LEUKEMIA																										
BILE DUCT	+	+	+	+	+	+	+	+	+	+	+	+	+	+	+	+	+	+	+	+	+	+	+	+	+	+
GALLBLADDER & COMMON BILE DUCT	N	N	N	+	N	N	N	N	N	N	N	N	N	N	N	N	N	N	N	N	N	N	N	N	N	N
PANCREAS	+	+	+	+	+	+	+	+	+	+	+	+	+	+	+	+	+	+	-	+	+	+	+	+	+	+
ACINAR-CELL ADENOMA																										
ESOPHAGUS	+	+	+	+	+	+	+	+	+	+	+	+	+	+	+	-	+	+	+	+	+	+	+	+	+	+
STOMACH	+	+	+	+	+	+	+	+	+	+	+	+	+	+	+	+	+	+	+	+	+	+	+	+	+	+
SQUAMOUS CELL PAPILLOMA																										
SMALL INTESTINE	+	+	+	+	+	+	+	+	+	+	+	+	+	+	+	+	+	+	+	+	+	+	+	+	+	+
MUCINOUS CYSTADENOCARCINOMA																										
LARGE INTESTINE	+	+	+	+	+	+	+	+	+	+	+	+	+	+	+	+	+	+	+	+	+	+	+	+	+	+
LEIOMYOSARCOMA																										
URINARY SYSTEM																										
KIDNEY	+	+	+	+	+	+	+	+	+	+	+	+	+	+	+	+	+	+	+	+	+	+	+	+	+	+
TUBULAR-CELL ADENOMA																										
TUBULAR-CELL ADENOCARCINOMA																										X
MIXED TUMOR, MALIGNANT														X												
URINARY BLADDER	+	+	+	+	+	+	+	+	+	+	-	+	+	+	+	+	+	+	+	+	+	+	+	+	+	+
TRANSITIONAL-CELL PAPILLOMA																										

+: TISSUE EXAMINED MICROSCOPICALLY
-: REQUIRED TISSUE NOT EXAMINED MICROSCOPICALLY
X: TUMOR INCIDENCE
N: NECROPSY, NO AUTOLYSIS, NO MICROSCOPIC EXAMINATION
S: ANIMAL MIS-SEXED
: NO TISSUE INFORMATION SUBMITTED
C: NECROPSY, NO HISTOLOGY DUE TO PROTOCOL
A: AUTOLYSIS
M: ANIMAL MISSING
B: NO NECROPSY PERFORMED

HWBUI0001563

TABLE A3. INDIVIDUAL ANIMAL TUMOR PATHOLOGY OF MALE RATS IN THE LIFETIME FEED STUDY OF SHORT-RANGE CHRYSOTILE ASBESTOS: UNTREATED CONTROL (Continued)

ANIMAL NUMBER	54901	55011	55122	55253	55345	55506	55637	55716	55816	55937	56022	56149	56204	56304	56432	56537	56618	56705	56808	56901	57011	57118	57210	57330
WEEKS ON STUDY	122	131	122	125	125	069	137	137	116	137	137	122	049	049	049	132	137	128	095	080	101	118	108	130	122
ENDOCRINE SYSTEM																									
PITUITARY	+	+	+	+	+	+	+	+	+	+	+	+	-	+	+	+	+	+	+	+	+	+	+	+	+
CARCINOMA, NOS																									
ADENOMA, NOS																	X	X					X	X	
ADRENAL	+	+	+	+	+	+	+	+	+	+	+	+	+	+	+	+	+	+	+	+	+	+	+	+	+
PHEOCHROMOCYTOMA		X					X	X			X						X	X							
PHEOCHROMOCYTOMA, MALIGNANT	X																								
THYROID	+	+	-	+	+	+	+	+	+	+	+	+	+	+	+	+	+	+	+	+	+	+	+	+	+
FOLLICULAR-CELL ADENOMA							X																X		
FOLLICULAR-CELL CARCINOMA																				X					
C-CELL ADENOMA		X																	X						
C-CELL CARCINOMA				X				X							-		X						X	X	
PARATHYROID	+	+	-	+	+	-	+	+	-	+	+	+	+	+	+	+	+	+	+	-	+	+	+	+	+
ADENOMA, NOS		X																							
C-CELL CARCINOMA, INVASIVE																									
PANCREATIC ISLETS	+	+	+	+	+	+	+	+	+	+	+	+	+	+	+	+	+	+	-	+	+	+	+	+	+
ISLET-CELL ADENOMA		X																							
ISLET-CELL CARCINOMA																									
REPRODUCTIVE SYSTEM																									
MAMMARY GLAND	+	+	+	+	+	N	+	+	+	+	+	N	+	+	+	+	+	+	+	+	+	+	+	+	N
ADENOCARCINOMA, NOS																									
FIBROADENOMA		X															X								
TESTIS	+	+	+	+	+	+	+	+	+	+	+	+	+	+	+	+	+	+	+	+	+	+	+	+	+
INTERSTITIAL-CELL TUMOR	X	X	X	X	X		X	X	X	X	X	X				X	X	X	X	X	X	X	X	X	X
PROSTATE	+	+	+	+	+	+	+	+	+	+	+	+	+	+	+	+	+	+	+	+	+	+	+	+	+
PREPUTIAL/CLITORAL GLAND	N	N	N	N	N	N	N	N	N	N	N	N	N	N	N	N	N	N	N	N	N	N	N	N	N
CARCINOMA, NOS																				X					
SQUAMOUS CELL CARCINOMA																	X								
EPIDIDYMIS	N	N	N	N	N	N	N	N	N	N	N	N	N	N	N	N	N	N	N	N	N	N	N	N	N
MESOTHELIOMA, INVASIVE	X																								
NERVOUS SYSTEM																									
BRAIN	+	+	+	+	+	+	+	+	+	+	+	+	+	+	+	+	+	+	+	+	+	+	+	+	+
ASTROCYTOMA						X			X																
SPECIAL SENSE ORGANS																									
HARDERIAN GLAND	N	N	N	N	N	N	N	N	N	N	N	N	N	N	N	N	N	N	N	N	N	N	N	N	N
CARCINOMA, NOS																									
FIBROUS HISTIOCYTOMA, MALIGNANT																									
ZYMBAL'S GLAND	+	+	+	+	+	+	+	+	+	+	+	+	+	+	+	+	+	+	+	+	+	+	+	+	+
SQUAMOUS CELL PAPILLOMA																									
SQUAMOUS CELL CARCINOMA																									
MUSCULOSKELETAL SYSTEM																									
BONE	+	N	N	N	N	N	N	N	N	N	N	+	N	N	N	N	N	N	N	N	N	N	N	N	N
SQUAMOUS CELL CARCINOMA, INVASIVE																									
OSTEOSARCOMA																									
BODY CAVITIES																									
TUNICA VAGINALIS	+	+	+	+	+	+	+	+	+	+	+	+	+	+	+	+	+	+	+	+	+	+	+	+	+
MESOTHELIOMA, MALIGNANT	X																								
ALL OTHER SYSTEMS																									
MULTIPLE ORGANS NOS	N	N	N	N	N	N	N	N	N	N	N	N	N	N	N	N	N	N	N	N	N	N	N	N	N
CARCINOMA, NOS, INVASIVE																									
PHEOCHROMOCYTOMA, METASTATIC	X																								
FIBROUS HISTIOCYTOMA, MALIGNANT																									
FIBROUS HISTIOCYTOMA, METASTATIC																									
MESOTHELIOMA, INVASIVE																									
OSTEOSARCOMA, METASTATIC																									
MALIG.LYMPHOMA, LYMPHOCYTIC TYPE																									
MALIG.LYMPHOMA, HISTIOCYTIC TYPE				X																					
MYELOMONOCYTIC LEUKEMIA																									
MONOCYTIC LEUKEMIA			X		X		X									X	X	X			X	X	X		
LEUKEMIA, MONONUCLEAR CELL																									
SCROTUM NOS																									
MESOTHELIOMA, INVASIVE	X																								

HWBUI0001564

TABLE A3. INDIVIDUAL ANIMAL TUMOR PATHOLOGY OF MALE RATS IN THE LIFETIME FEED STUDY OF SHORT-RANGE CHRYSOTILE ASBESTOS: UNTREATED CONTROL (Continued)

ANIMAL NUMBER	57401	57515	57616	57717	57818	57919	58012	58111	58229	58337	58410	58521	58602	58724	58874	58932	59004	59129	59237	59323	59418	59529	59625	59737	59810
WEEKS ON STUDY	116	125	109	131	098	128	112	093	129	137	110	121	102	124	074	132	094	129	137	103	126	128	125	137	100
INTEGUMENTARY SYSTEM																									
SKIN	+	+	+	+	+	+	+	+	+	+	+	+	+	+	+	+	+	+	+	+	+	+	+	+	+
SQUAMOUS CELL PAPILLOMA																									
BASAL-CELL CARCINOMA																				X					
KERATOACANTHOMA																			X	X					
FIBROUS HISTIOCYTOMA, MALIGNANT																									
SUBCUTANEOUS TISSUE	+	+	+	+	+	+	+	+	+	+	+	+	+	+	+	+	+	+	+	+	+	+	+	+	+
SQUAMOUS CELL CARCINOMA, INVASIVE																									
FIBROMA		X	X	X		X						X				X			X				X		
FIBROSARCOMA																		X				X			
LIPOSARCOMA																									
HEMANGIOPERICYTOMA, MALIGNANT																									
NEUROFIBROMA																									
NEUROFIBROSARCOMA																									
RESPIRATORY SYSTEM																									
LUNGS AND BRONCHI	+	+	+	+	+	+	+	+	+	+	+	+	+	+	+	+	+	+	+	+	+	+	+	+	+
CARCINOMA, NOS, METASTATIC																									
ALVEOLAR/BRONCHIOLAR CARCINOMA																			X						
TRACHEA	+	+	+	+	+	+	+	+	+	+	+	+	+	+	+	+	+	+	+	+	+	+	+	+	+
HEMATOPOIETIC SYSTEM																									
BONE MARROW	+	+	+	+	+	+	+	+	+	+	+	+	+	+	+	+	+	+	+	+	+	+	+	+	+
SPLEEN	+	+	+	+	+	+	+	+	+	+	+	+	+	+	+	+	+	+	+	+	+	+	+	+	+
HEMANGIOSARCOMA																									
LYMPH NODES	+	+	+	+	+	+	+	+	+	+	+	+	+	+	+	+	+	+	+	+	+	+	+	+	+
MESOTHELIOMA, METASTATIC													X												
THYMUS	-	+	-	+	+	+	+	+	+	+	+	-	+	+	-	+	+	+	+	+	+	+	+	+	-
ADENOCARCINOMA, NOS																									
CIRCULATORY SYSTEM																									
HEART	+	+	+	+	+	+	+	+	+	+	+	+	+	+	+	+	+	+	+	+	+	+	+	+	+
DIGESTIVE SYSTEM																									
SALIVARY GLAND	+	+	+	+	+	+	+	+	+	+	+	+	+	+	+	+	+	+	+	+	+	+	+	+	+
LIVER	+	+	+	+	+	+	+	+	+	+	+	+	+	+	+	+	+	+	+	+	+	+	+	+	+
NEOPLASTIC NODULE		X	X						X				X								X				
HEPATOCELLULAR CARCINOMA																									
MONOCYTIC LEUKEMIA																									
BILE DUCT	+	+	+	+	+	+	+	+	+	+	+	+	+	+	+	+	+	+	+	+	+	+	+	+	+
GALLBLADDER & COMMON BILE DUCT	N	N	N	N	N	N	N	N	N	N	N	N	N	N	N	N	N	+	N	N	N	N	N	N	N
PANCREAS	+	+	+	+	+	+	+	+	+	+	+	+	+	+	+	+	+	+	+	+	+	+	+	+	+
ACINAR-CELL ADENOMA												X							X						
ESOPHAGUS	+	+	-	+	+	+	+	+	+	+	+	+	+	+	+	+	+	+	+	+	+	+	+	+	+
STOMACH	+	+	+	+	+	+	+	+	+	+	+	+	+	+	+	+	+	+	+	+	+	+	+	+	+
SQUAMOUS CELL PAPILLOMA																									
SMALL INTESTINE	+	+	+	+	+	+	+	+	+	+	+	+	+	+	+	+	+	+	+	+	+	+	+	+	+
MUCINOUS CYSTADENOCARCINOMA																									
LARGE INTESTINE	+	+	+	+	+	+	+	+	+	+	+	+	+	+	+	+	+	+	+	+	+	+	+	+	+
LEIOMYOSARCOMA																									
URINARY SYSTEM																									
KIDNEY	+	+	+	+	+	+	+	+	+	+	+	+	+	+	+	+	+	+	+	+	+	+	+	+	+
TUBULAR-CELL ADENOMA																									
TUBULAR-CELL ADENOCARCINOMA																									
MIXED TUMOR, MALIGNANT																							X		
URINARY BLADDER	+	+	+	+	+	+	+	+	+	+	+	+	+	+	+	+	+	-	+	+	+	+	+	+	+
TRANSITIONAL-CELL PAPILLOMA																									

HWBUI0001565

TABLE A3. INDIVIDUAL ANIMAL TUMOR PATHOLOGY OF MALE RATS IN THE LIFETIME FEED STUDY OF SHORT-RANGE CHRYSOTILE ASBESTOS: UNTREATED CONTROL (Continued)

ANIMAL NUMBER	57 4	57 5	57 6	57 7	57 8	57 9	58 0	58 1	58 2	58 3	58 4	58 5	58 6	58 7	58 8	58 9	59 0	59 1	59 2	59 3	59 4	59 5	59 6	59 7	59 8
WEEKS ON STUDY	116	125	109	131	098	128	112	093	129	137	110	121	102	124	074	132	094	129	137	108	126	120	125	137	100
ENDOCRINE SYSTEM																									
PITUITARY	+	+	+	+	+	+	+	+	+	+	+	+	+	+	+	+	+	+	+	+	+	+	+	+	+
CARCINOMA,NOS										X															
ADENOMA, NOS				X									X	X		X		X				X		X	
ADRENAL	+	+	+	+	+	+	+	+	+	+	+	+	+	+	+	+	+	+	+	+	+	+	+	+	+
PHEOCHROMOCYTOMA				X	X		X		X	X		X				X		X		X		X			
PHEOCHROMOCYTOMA, MALIGNANT																									
THYROID	+	+	-	+	+	+	+	+	+	+	+	+	+	+	+	+	+	+	+	+	+	+	+	+	+
FOLLICULAR-CELL ADENOMA												X													
FOLLICULAR-CELL CARCINOMA						X		X			X											X			
C-CELL ADENOMA	X								X																
C-CELL CARCINOMA											X														
PARATHYROID	+	+	-	+	+	+	+	+	+	+	+	+	+	+	+	+	+	+	+	+	+	+	+	+	+
ADENOMA, NOS				X																					
C-CELL CARCINOMA, INVASIVE																									
PANCREATIC ISLETS	+	+	+	+	+	+	+	+	+	+	+	+	+	+	+	+	+	+	+	+	+	+	+	+	+
ISLET-CELL ADENOMA														X											
ISLET-CELL CARCINOMA										X															
REPRODUCTIVE SYSTEM																									
MAMMARY GLAND	+	+	+	+	+	+	+	+	+	+	+	+	+	+	+	+	N	+	+	+	+	+	+	+	+
ADENOCARCINOMA, NOS																						X			
FIBROADENOMA																						X			
TESTIS	+	+	+	+	+	+	+	+	+	+	+	+	+	+	+	+	+	+	+	+	+	+	+	+	+
INTERSTITIAL-CELL TUMOR	X	X	X	X	X	X	X	X	X	X	X	X	X	X	X	X	X	X	X	X	X	X	X	X	X
PROSTATE	+	+	+	+	+	+	+	+	+	+	+	+	+	+	+	+	+	+	+	+	+	+	+	+	+
PREPUTIAL/CLITORAL GLAND	N	N	N	N	N	N	N	N	N	N	N	N	N	N	N	N	N	N	N	N	N	N	N	N	N
CARCINOMA,NOS																									
SQUAMOUS CELL CARCINOMA																									
EPIDIDYMIS	N	N	N	N	N	N	N	N	N	N	N	N	N	N	N	N	N	N	N	N	N	N	N	N	N
MESOTHELIOMA, INVASIVE																									
NERVOUS SYSTEM																									
BRAIN	+	+	+	+	+	+	+	+	+	+	+	+	+	+	+	+	+	+	+	+	+	+	+	+	+
ASTROCYTOMA												X													
SPECIAL SENSE ORGANS																									
HARDERIAN GLAND	N	N	N	N	N	N	N	N	N	N	N	N	N	N	N	N	N	N	N	N	N	N	N	N	N
CARCINOMA,NOS																									
FIBROUS HISTIOCYTOMA, MALIGNANT																									
ZYMBAL'S GLAND	+	+	+	+	+	+	+	+	+	+	+	+	+	+	+	+	+	+	+	+	+	+	+	+	+
SQUAMOUS CELL PAPILLOMA																								X	
SQUAMOUS CELL CARCINOMA	X														X			X							
MUSCULOSKELETAL SYSTEM																									
BONE	N	N	N	N	N	N	N	N	N	N	N	N	N	N	N	N	N	N	N	N	N	N	N	N	N
SQUAMOUS CELL CARCINOMA, INVASIVE																					X				
OSTEOSARCOMA																									
BODY CAVITIES																									
TUNICA VAGINALIS	+	+	+	+	+	+	+	+	+	+	+	+	+	+	+	+	+	+	+	+	+	+	+	+	+
MESOTHELIOMA, MALIGNANT													X												
ALL OTHER SYSTEMS																									
MULTIPLE ORGANS NOS	N	N	N	N	N	N	N	N	N	N	N	N	N	N	N	N	N	N	N	N	N	N	N	N	N
CARCINOMA, NOS, INVASIVE																									
PHEOCHROMOCYTOMA, METASTATIC																									
FIBROUS HISTIOCYTOMA, MALIGNANT																									
FIBROUS HISTIOCYTOMA, METASTATIC																									
MESOTHELIOMA, INVASIVE													X												
OSTEOSARCOMA, METASTATIC																									
MALIG.LYMPHOMA, LYMPHOCYTIC TYPE																									
MALIG.LYMPHOMA, HISTIOCYTIC TYPE								X																	
MYELOMONOCYTIC LEUKEMIA																									
MONOCYTIC LEUKEMIA		X	X	X	X		X		X		X			X			X				X	X			X
LEUKEMIA,MONONUCLEAR CELL																									
SCROTUM NOS																									
MESOTHELIOMA, INVASIVE																									

HWBUI0001566

TABLE A3. INDIVIDUAL ANIMAL TUMOR PATHOLOGY OF MALE RATS IN THE LIFETIME FEED STUDY OF SHORT-RANGE CHRYSOTILE ASBESTOS: UNTREATED CONTROL (Continued)

ANIMAL NUMBER	59	60	60	60	60	60	60	60	60	60	60	61	61	61	61	61	61	61	61	61	62	62	62	62
	90	01	11	23	03	04	05	06	07	08	09	01	11	12	31	14	15	16	17	18	01	11	22	23
WEEKS ON STUDY	12	11	13	07	12	12	13	13	13	12	08	09	12	10	12	13	12	12	12	10	10	09	12	08
	22	14	16	11	19	15	10	17	17	22	04	15	14	10	19	12	22	19	18	18	05	15	10	18
INTEGUMENTARY SYSTEM																								
SKIN	N	+	+	+	+	+	+	+	+	+	+	+	+	+	+	+	+	+	+	+	+	+	+	+
SQUAMOUS CELL PAPILLOMA																								
BASAL-CELL CARCINOMA																								
KERATOACANTHOMA																								
FIBROUS HISTIOCYTOMA, MALIGNANT																								
SUBCUTANEOUS TISSUE	N	+	+	+	+	+	+	+	+	+	+	+	+	+	+	+	+	+	+	+	+	+	+	+
SQUAMOUS CELL CARCINOMA, INVASIVE																					X			
FIBROMA	X						X																	
FIBROSARCOMA																								
LIPOSARCOMA																	X							
HEMANGIOPERICYTOMA, MALIGNANT																								
NEUROFIBROMA																								
NEUROFIBROSARCOMA										X														
RESPIRATORY SYSTEM																								
LUNGS AND BRONCHI	+	+	+	+	+	+	+	+	+	+	+	+	+	+	+	+	+	+	+	+	+	+	+	+
CARCINOMA, NOS, METASTATIC															X									
ALVEOLAR/BRONCHIOLAR CARCINOMA										X														
TRACHEA	+	+	+	+	+	+	+	+	+	+	+	+	+	+	+	+	+	+	+	+	+	+	+	+
HEMATOPOIETIC SYSTEM																								
BONE MARROW	+	+	+	+	+	+	+	+	+	+	+	+	+	+	+	+	+	+	+	+	+	+	+	+
SPLEEN	+	+	+	+	+	+	+	+	+	+	+	+	+	+	+	+	+	+	+	+	+	+	+	+
HEMANGIOSARCOMA																								
LYMPH NODES	+	+	+	+	+	+	+	+	+	+	+	+	+	+	+	+	+	+	+	+	+	+	+	+
MESOTHELIOMA, METASTATIC																								
THYMUS	+	+	-	-	+	+	+	+	+	+	+	+	+	+	-	+	+	-	+	-	+	+	+	+
ADENOCARCINOMA, NOS																								
CIRCULATORY SYSTEM																								
HEART	+	+	+	+	+	+	+	+	+	+	+	+	+	+	+	+	+	+	+	+	+	+	+	+
DIGESTIVE SYSTEM																								
SALIVARY GLAND	+	+	+	+	+	+	+	+	+	+	+	+	+	+	+	+	+	+	+	+	+	+	+	+
LIVER	+	+	+	+	+	+	+	+	+	+	+	+	+	+	+	+	+	+	+	+	+	+	+	+
NEOPLASTIC NODULE																								
HEPATOCELLULAR CARCINOMA			X				X		X				X											
MONOCYTIC LEUKEMIA																								
BILE DUCT	+	+	+	+	+	+	+	+	+	+	+	+	+	+	+	+	+	+	+	+	+	+	+	+
GALLBLADDER & COMMON BILE DUCT	N	N	N	N	N	N	N	N	N	N	N	N	N	N	N	N	N	N	N	N	N	N	N	N
PANCREAS	+	+	+	+	+	+	+	+	+	+	+	+	+	+	+	+	+	+	+	+	+	+	+	+
ACINAR-CELL ADENOMA	X		X		X					X					X								
ESOPHAGUS	+	+	+	+	+	+	+	+	+	+	+	+	+	+	+	+	+	+	+	+	+	+	+	+
STOMACH	+	+	+	+	+	+	+	+	+	+	+	+	+	+	+	+	+	+	+	+	+	+	+	+
SQUAMOUS CELL PAPILLOMA																	X							
SMALL INTESTINE	+	+	+	+	+	+	+	+	+	+	+	+	+	+	+	+	+	+	+	+	+	+	+	+
MUCINOUS CYSTADENOCARCINOMA																	X							
LARGE INTESTINE	+	+	+	+	+	+	+	+	+	+	+	+	+	+	+	+	+	+	+	+	+	+	+	+
LEIOMYOSARCOMA																		X						
URINARY SYSTEM																								
KIDNEY	+	+	+	+	+	+	+	+	+	+	+	+	+	+	+	+	+	+	+	+	+	+	+	+
TUBULAR-CELL ADENOMA																								
TUBULAR-CELL ADENOCARCINOMA																								
MIXED TUMOR, MALIGNANT																								
URINARY BLADDER	+	+	+	+	+	+	+	+	+	+	+	+	+	+	+	+	+	+	+	+	+	+	+	+
TRANSITIONAL-CELL PAPILLOMA																								

HWBUI0001567

TABLE A3. INDIVIDUAL ANIMAL TUMOR PATHOLOGY OF MALE RATS IN THE LIFETIME FEED STUDY OF SHORT-RANGE CHRYSOTILE ASBESTOS: UNTREATED CONTROL (Continued)

ANIMAL NUMBER	59 9	60 8	60 1	60 2	60 3	60 4	60 5	60 6	60 7	60 8	60 9	61 0	61 1	61 2	61 3	61 4	61 5	61 6	61 7	61 8	61 9	62 0	62 1	62 2	62 3
WEEKS ON STUDY	112	114	136	071	129	125	130	137	137	122	084	095	124	100	129	132	122	129	128	110	108	105	095	120	088
ENDOCRINE SYSTEM																									
PITUITARY	+	+	+	+	+	+	+	+	+	+	+	+	+	+	+	+	+	+	+	+	+	+	+	+	+
CARCINOMA,NOS																									
ADENOMA, NOS								X							X	X	X								
ADRENAL	+	+	+	+	+	+	+	+	+	+	+	+	+	+	+	+	+	+	+	+	+	+	+	+	+
PHEOCHROMOCYTOMA			X			X	X						X												
PHEOCHROMOCYTOMA, MALIGNANT																									X
THYROID	+	+	+	+	+	+	+	+	+	+	+	+	+	+	+	+	+	+	+	+	+	+	+	+	+
FOLLICULAR-CELL ADENOMA																									
FOLLICULAR-CELL CARCINOMA													X												
C-CELL ADENOMA									X	X															
C-CELL CARCINOMA					X			X								X									
PARATHYROID	+	+	+	+	+	+	+	+	+	+	+	+	+	+	+	+	+	+	+	+	+	+	+	+	+
ADENOMA, NOS					X								X												
C-CELL CARCINOMA, INVASIVE																X									
PANCREATIC ISLETS	+	+	+	+	+	+	+	+	+	+	+	+	+	+	+	+	+	+	+	+	+	+	+	+	+
ISLET-CELL ADENOMA	X				X																				
ISLET-CELL CARCINOMA																		X							
REPRODUCTIVE SYSTEM																									
MAMMARY GLAND	N	+	+	+	+	+	+	+	+	+	+	+	+	+	+	+	+	+	N	+	+	+	+	+	+
ADENOCARCINOMA, NOS																								X	
FIBROADENOMA			X		X		X		X															X	
TESTIS	+	+	+	+	+	+	+	+	+	+	+	+	+	+	+	+	+	+	+	+	+	+	+	+	+
INTERSTITIAL-CELL TUMOR	X	X	X	X	X	X	X	X	X	X	X	X	X	X	X	X		X	X	X		X	X	X	X
PROSTATE	+	+	+	+	+	+	+	+	+	+	+	+	+	+	+	+	+	+	+	+	+	+	+	+	+
PREPUTIAL/CLITORAL GLAND	N	N	N	N	N	N	N	N	N	N	N	N	N	N	N	N	N	N	N	N	N	N	N	N	N
CARCINOMA,NOS							X		X																
SQUAMOUS CELL CARCINOMA																	X								
EPIDIDYMIS	N	N	N	N	N	N	N	N	N	N	N	N	N	N	N	N	N	N	N	N	N	N	N	N	N
MESOTHELIOMA, INVASIVE																									
NERVOUS SYSTEM																									
BRAIN	+	+	+	+	+	+	+	+	+	+	+	+	+	+	+	+	+	+	+	+	+	+	+	+	+
ASTROCYTOMA			X																						
SPECIAL SENSE ORGANS																									
HARDERIAN GLAND	N	N	N	N	N	N	N	N	N	N	N	N	N	N	N	N	N	N	N	N	N	N	N	N	N
CARCINOMA,NOS															X										
FIBROUS HISTIOCYTOMA, MALIGNANT				X																					
ZYMBAL'S GLAND	+	+	+	+	+	+	+	+	+	+	+	+	+	+	+	+	+	+	+	+	+	+	+	+	+
SQUAMOUS CELL PAPILLOMA																									
SQUAMOUS CELL CARCINOMA																						X			
MUSCULOSKELETAL SYSTEM																									
BONE	N	+	N	N	N	N	N	N	N	N	N	N	N	N	N	N	N	N	N	N	N	N	N	N	N
SQUAMOUS CELL CARCINOMA, INVASIVE																						X			
OSTEOSARCOMA		X																							
BODY CAVITIES																									
TUNICA VAGINALIS	+	+	+	+	+	+	+	+	+	+	+	+	+	+	+	+	+	+	+	+	+	+	+	+	+
MESOTHELIOMA, MALIGNANT																									
ALL OTHER SYSTEMS																									
MULTIPLE ORGANS NOS	N	N	N	N	N	N	N	N	N	N	N	N	N	N	N	N	N	N	N	N	N	N	N	N	N
CARCINOMA, NOS, INVASIVE															X										
PHEOCHROMOCYTOMA, METASTATIC																									
FIBROUS HISTIOCYTOMA, MALIGNANT																									
FIBROUS HISTIOCYTOMA, METASTATIC				X																					
MESOTHELIOMA, INVASIVE																									
OSTEOSARCOMA, METASTATIC		X																							
MALIG LYMPHOMA, LYMPHOCYTIC TYPE				X																					
MALIG LYMPHOMA, HISTIOCYTIC TYPE																									
MYELOMONOCYTIC LEUKEMIA																									
MONOCYTIC LEUKEMIA													X	X		X	X		X	X	X				X
LEUKEMIA,MONONUCLEAR CELL																									
SCROTUM NOS																									
MESOTHELIOMA, INVASIVE																									

HWBUI0001568

TABLE A3. INDIVIDUAL ANIMAL TUMOR PATHOLOGY OF MALE RATS IN THE LIFETIME FEED STUDY OF SHORT-RANGE CHRYSOTILE ASBESTOS: UNTREATED CONTROL (Continued)

ANIMAL NUMBER	62	62	62	62	62	62	63	63	63	63	63	63	63	TOTAL
	24	25	26	27	28	29	01	11	12	33	34	35	36	TISSUES
WEEKS ON STUDY	137	085	137	128	136	132	132	118	137	137	137	112	105	TUMORS
INTEGUMENTARY SYSTEM														
SKIN	+	+	+	+	+	+	+	+	+	+	+	+	+	88*
SQUAMOUS CELL PAPILLOMA														1
BASAL-CELL CARCINOMA														3
KERATOACANTHOMA										X				5
FIBROUS HISTIOCYTOMA, MALIGNANT							X							1
SUBCUTANEOUS TISSUE	+	+	+	+	+	+	+	+	+	+	+	+	+	88*
SQUAMOUS CELL CARCINOMA, INVASIVE														1
FIBROMA														13
FIBROSARCOMA														4
LIPOSARCOMA														1
HEMANGIOPERICYTOMA, MALIGNANT				X										1
NEUROFIBROMA											X			1
NEUROFIBROSARCOMA					X									3
RESPIRATORY SYSTEM														
LUNGS AND BRONCHI	+	+	+	+	+	+	+	+	+	+	+	+	+	88
CARCINOMA, NOS, METASTATIC														1
ALVEOLAR/BRONCHIOLAR CARCINOMA														2
TRACHEA	+	+	+	+	+	+	+	+	+	+	+	+	+	87
HEMATOPOIETIC SYSTEM														
BONE MARROW	+	+	+	+	+	+	+	+	+	+	+	+	+	88
SPLEEN	+	+	+	+	+	+	+	+	+	+	+	+	+	88
HEMANGIOSARCOMA			X											2
LYMPH NODES	+	+	+	+	+	+	+	+	+	+	+	+	+	88
MESOTHELIOMA, METASTATIC														1
THYMUS	+	+	-	+	+	+	+	+	+	+	+	+	+	76
ADENOCARCINOMA, NOS						X								1
CIRCULATORY SYSTEM														
HEART	+	+	+	+	+	+	+	+	+	+	+	+	+	88
DIGESTIVE SYSTEM														
SALIVARY GLAND	+	+	+	+	+	+	+	+	+	+	+	+	+	87
LIVER	+	+	+	+	+	+	+	+	+	+	+	+	+	88
NEOPLASTIC NODULE			X									X		12
HEPATOCELLULAR CARCINOMA					X									3
MONOCYTIC LEUKEMIA											X			1
BILE DUCT	+	+	+	+	+	+	+	+	+	+	+	+	+	88
GALLBLADDER & COMMON BILE DUCT	N	N	N	N	N	N	N	N	N	N	N	N	N	88*
PANCREAS	+	+	+	+	+	+	+	+	+	+	+	-	+	86
ACINAR-CELL ADENOMA														7
ESOPHAGUS	+	+	+	+	+	+	+	+	+	+	+	+	+	86
STOMACH	+	+	+	+	+	+	+	+	+	+	+	+	+	88
SQUAMOUS CELL PAPILLOMA														1
SMALL INTESTINE	+	+	+	+	+	+	+	+	+	+	+	+	+	88
MUCINOUS CYSTADENOCARCINOMA														1
LARGE INTESTINE	+	+	+	+	+	+	+	+	+	+	+	-	+	87
LEIOMYOSARCOMA														1
URINARY SYSTEM														
KIDNEY	+	+	+	+	+	+	+	+	+	+	+	+	+	88
TUBULAR-CELL ADENOMA														1
TUBULAR-CELL ADENOCARCINOMA														1
MIXED TUMOR, MALIGNANT														1
URINARY BLADDER	+	+	+	+	+	+	+	+	+	+	+	-	+	85
- TRANSITIONAL-CELL PAPILLOMA								X						1

HWBUI0001569

TABLE A3. INDIVIDUAL ANIMAL TUMOR PATHOLOGY OF MALE RATS IN THE LIFETIME FEED STUDY OF SHORT-RANGE CHRYSOTILE ASBESTOS: UNTREATED CONTROL (Continued)

ANIMAL NUMBER	62246	62255	62266	62277	62288	62299	63300	63311	63322	63331	63344	63355	63366	TOTAL TISSUES TUMORS
WEEKS ON STUDY	13 7	10 8	11 3	11 8	11 3	11 3	13 2	11 8	13 7	13 7	13 7	11 2	10 5	
ENDOCRINE SYSTEM														
PITUITARY	+	+	+	+	+	+	+	+	+	+	+	+	+	87
CARCINOMA,NOS														1
ADENOMA, NOS	X				X			X		X			X	20
ADRENAL	+	+	+	+	+	+	+	+	+	+	+	+	+	88
PHEOCHROMOCYTOMA		X			X	X				X				25
PHEOCHROMOCYTOMA, MALIGNANT														1
THYROID	+	+	+	+	+	+	+	+	+	+	+	+	+	86
FOLLICULAR-CELL ADENOMA						X							X	4
FOLLICULAR-CELL CARCINOMA														2
C-CELL ADENOMA			X	X		X	X	X						13
C-CELL CARCINOMA														11
PARATHYROID	+	+	+	+	+	+	+	+	+	+	+	+	+	83
ADENOMA, NOS											X			6
C-CELL CARCINOMA, INVASIVE														1
PANCREATIC ISLETS	+	+	+	+	+	+	+	+	+	+	+	-	+	86
ISLET-CELL ADENOMA				X							X			6
ISLET-CELL CARCINOMA									X					3
REPRODUCTIVE SYSTEM														
MAMMARY GLAND	+	+	+	+	+	+	+	+	+	+	+	+	+	88*
ADENOCARCINOMA, NOS			X											3
FIBROADENOMA	X								X		X			11
TESTIS	+	+	+	+	+	+	+	+	+	+	+	-	+	87
INTERSTITIAL-CELL TUMOR	X	X	X	X	X	X	X	X	X	X	X		X	81
PROSTATE	+	+	+	+	+	+	+	+	+	+	+	-	+	87
PREPUTIAL/CLITORAL GLAND	N	N	N	N	N	N	N	N	N	N	N	N	N	88*
CARCINOMA,NOS		X												4
SQUAMOUS CELL CARCINOMA														2
EPIDIDYMIS	N	N	N	N	N	N	N	N	N	N	N	N	N	88*
MESOTHELIOMA, INVASIVE														1
NERVOUS SYSTEM														
BRAIN	+	+	+	+	+	+	+	+	+	+	+	+	+	88
ASTROCYTOMA														4
SPECIAL SENSE ORGANS														
HARDERIAN GLAND	N	N	N	N	N	N	N	N	N	N	N	N	N	88*
CARCINOMA,NOS														1
FIBROUS HISTIOCYTOMA, MALIGNANT														1
ZYMBAL'S GLAND	+	+	+	+	+	+	+	+	+	+	+	+	+	88*
SQUAMOUS CELL PAPILLOMA														1
SQUAMOUS CELL CARCINOMA														4
MUSCULOSKELETAL SYSTEM														
BONE	N	N	N	N	N	N	N	N	N	N	N	N	N	88*
SQUAMOUS CELL CARCINOMA, INVASIVE														1
OSTEOSARCOMA														2
BODY CAVITIES														
TUNICA VAGINALIS	+	+	+	+	+	+	+	+	+	+	+	N	+	88*
MESOTHELIOMA, MALIGNANT														2
ALL OTHER SYSTEMS														
MULTIPLE ORGANS NOS	N	N	N	N	N	N	N	N	N	N	N	N	N	88*
CARCINOMA, NOS, INVASIVE														1
PHEOCHROMOCYTOMA, METASTATIC														1
FIBROUS HISTIOCYTOMA, MALIGNANT									X					1
FIBROUS HISTIOCYTOMA, METASTATIC														1
MESOTHELIOMA, INVASIVE														1
OSTEOSARCOMA, METASTATIC														1
MALIG.LYMPHOMA, LYMPHOCYTIC TYPE														1
MALIG.LYMPHOMA, HISTIOCYTIC TYPE														1
MYELOMONOCYTIC LEUKEMIA														1
MONOCYTIC LEUKEMIA	X		X		X			X		X				34
LEUKEMIA,MONONUCLEAR CELL							X							1
SCROTUM NOS														
MESOTHELIOMA, INVASIVE														1

* ANIMALS NECROPSIED

HWBUI0001570

TABLE A3. INDIVIDUAL ANIMAL TUMOR PATHOLOGY OF MALE RATS IN THE LIFETIME FEED STUDY OF SHORT-RANGE CHRYSOTILE ASBESTOS: SHORT-RANGE



HWBUI0001571

TABLE A3. INDIVIDUAL ANIMAL TUMOR PATHOLOGY OF MALE RATS IN THE LIFETIME FEED STUDY OF SHORT-RANGE CHRYSOTILE ASBESTOS: SHORT-RANGE (Continued)



HWBUI0001572

TABLE A3. INDIVIDUAL ANIMAL TUMOR PATHOLOGY OF MALE RATS IN THE LIFETIME FEED STUDY OF SHORT-RANGE CHRYSOTILE ASBESTOS: SHORT-RANGE (Continued)

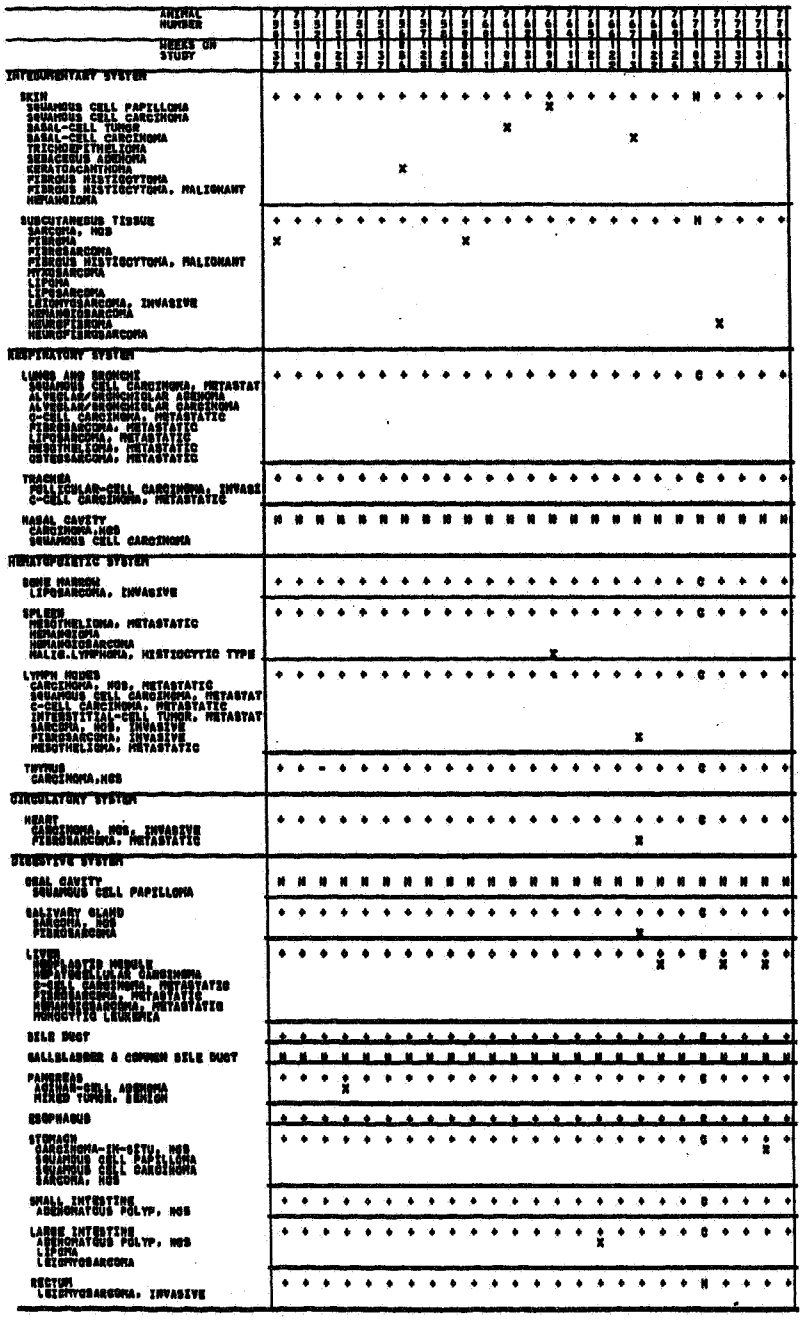

HWBUI0001573

TABLE A3. INDIVIDUAL ANIMAL TUMOR PATHOLOGY OF MALE RATS IN THE LIFETIME FEED STUDY OF SHORT-RANGE CHRYSOTILE ASBESTOS: SHORT-RANGE (Continued)

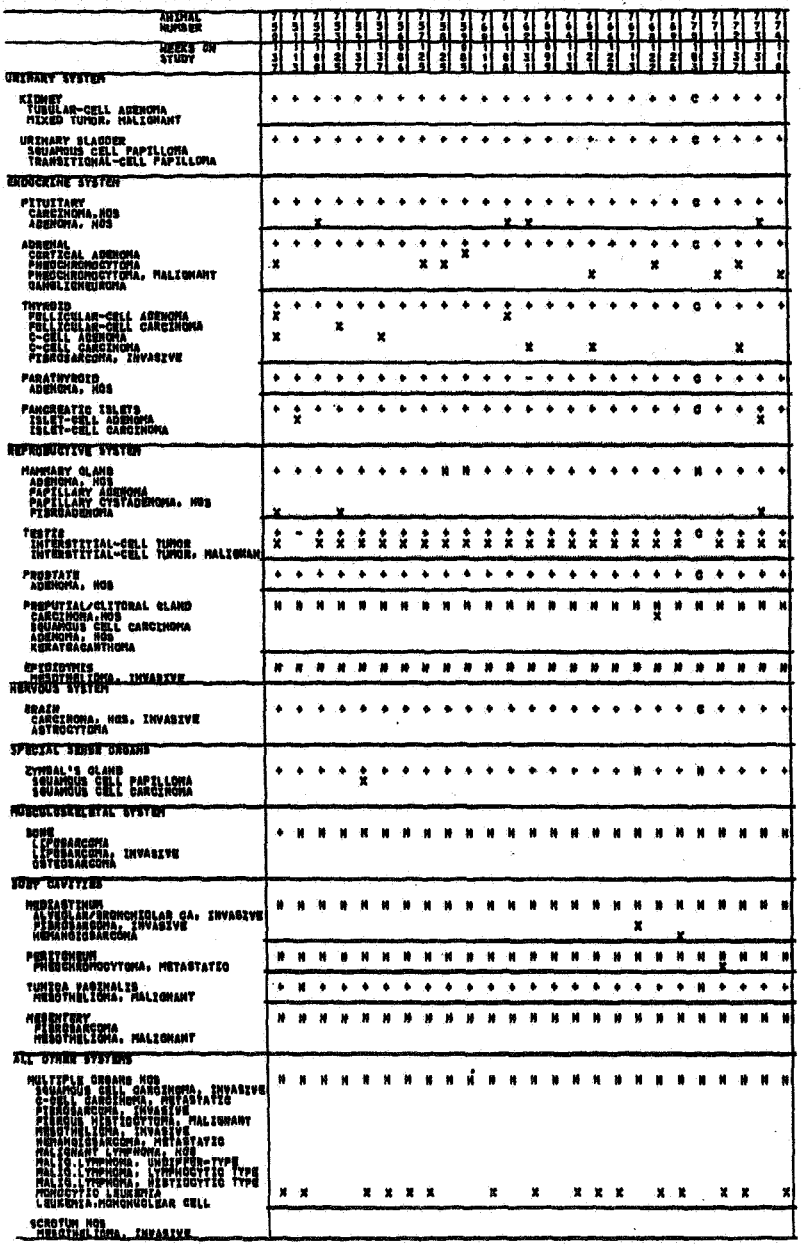

HWBUI0001574

TABLE A3. INDIVIDUAL ANIMAL TUMOR PATHOLOGY OF MALE RATS IN THE LIFETIME FEED STUDY OF SHORT-RANGE CHRYSOTILE ASBESTOS: SHORT-RANGE (Continued)

ANIMAL NUMBER	71 71 71 71 71 71 71 71 71 71 71 71 71 71 71 71 71 71 71 71 71 71 71 71 71 71 71 71 71 71
WEEKS ON STUDY	13 14 15 17 18 19 20 21 23 24 25 26 27 28 29 30 31 32 33 34 35 36 37 38 39 40 41 42 43 44
INTEGUMENTARY SYSTEM	
SKIN	+ +
SQUAMOUS CELL PAPILLOMA	X
SQUAMOUS CELL CARCINOMA	
BASAL-CELL TUMOR	
BASAL-CELL CARCINOMA	
TRICHOEPITHELIOMA	
SEBACEOUS ADENOMA	
KERATOACANTHOMA	X
FIBROUS HISTIOCYTOMA	
FIBROUS HISTIOCYTOMA, MALIGNANT	
HEMANGIOMA	
SUBCUTANEOUS TISSUE	+ +
SARCOMA, NOS	X X X X X X X X X X
FIBROMA	X
FIBROSARCOMA	X X X X X
FIBROUS HISTIOCYTOMA, MALIGNANT	
MYXOSARCOMA	
LIPOMA	
LIPOSARCOMA	
LEIOMYOSARCOMA, INVASIVE	
HEMANGIOSARCOMA	
NEUROFIBROMA	X X X
NEUROFIBROSARCOMA	
RESPIRATORY SYSTEM	
LUNGS AND BRONCHI	+ +
SQUAMOUS CELL CARCINOMA, METASTAT	
ALVEOLAR/BRONCHIOLAR ADENOMA	
ALVEOLAR/BRONCHIOLAR CARCINOMA	
C-CELL CARCINOMA, METASTATIC	
FIBROSARCOMA, METASTATIC	
LIPOSARCOMA, METASTATIC	
MESOTHELIOMA, METASTATIC	
OSTEOSARCOMA, METASTATIC	
TRACHEA	+ +
FOLLICULAR-CELL CARCINOMA, INVASI	
C-CELL CARCINOMA, METASTATIC	
NASAL CAVITY	M M M M M M M M M M M M M M M M M M M M M M M M M M M M M M
CARCINOMA,NOS	
SQUAMOUS CELL CARCINOMA	
HEMATOPOIETIC SYSTEM	
BONE MARROW	+ +
LIPOSARCOMA, INVASIVE	
SPLEEN	+ +
MESOTHELIOMA, METASTATIC	
HEMANGIOMA	X
HEMANGIOSARCOMA	
MALIG.LYMPHOMA, HISTIOCYTIC TYPE	
LYMPH NODES	+ +
CARCINOMA, NOS, METASTATIC	
SQUAMOUS CELL CARCINOMA, METASTAT	
C-CELL CARCINOMA, METASTATIC	
INTERSTITIAL-CELL TUMOR, METASTAT	
SARCOMA, NOS, INVASIVE	
FIBROSARCOMA, INVASIVE	
MESOTHELIOMA, METASTATIC	
THYMUS	+ + - + + - + + + + + + + - + + + + + + + + + + + + + +
CARCINOMA,NOS	
CIRCULATORY SYSTEM	
HEART	+ +
CARCINOMA, NOS, INVASIVE	
FIBROSARCOMA, METASTATIC	
DIGESTIVE SYSTEM	
ORAL CAVITY	M M M M M M M M M M M M M M M M M M M M M M M M M M M M M M
SQUAMOUS CELL PAPILLOMA	
SALIVARY GLAND	+ + + + + + + + + + + + - + + + + + + + + + + + + + + + + +
SARCOMA, NOS	
FIBROSARCOMA	
LIVER	+ +
NEOPLASTIC NODULE	X
HEPATOCELLULAR CARCINOMA	
C-CELL CARCINOMA, METASTATIC	
FIBROSARCOMA, METASTATIC	
HEMANGIOSARCOMA, METASTATIC	
MONOCYTIC LEUKEMIA	
BILE DUCT	+ +
GALLBLADDER & COMMON BILE DUCT	M M M M M M M M M M M M M M M M M M M M M M M M M M M M M M
PANCREAS	+ +
ACINAR-CELL ADENOMA	X X X X
MIXED TUMOR, BENIGN	X X
ESOPHAGUS	+ +
STOMACH	+ +
CARCINOMA-IN-SITU, NOS	
SQUAMOUS CELL PAPILLOMA	
SQUAMOUS CELL CARCINOMA	
SARCOMA, NOS	
SMALL INTESTINE	+ +
ADENOMATOUS POLYP, NOS	
LARGE INTESTINE	+ +
ADENOMATOUS POLYP, NOS	
LIPOMA	
LEIOMYOSARCOMA	
RECTUM	+ +
LEIOMYOSARCOMA, INVASIVE	

HWBUI0001575

TABLE A3. INDIVIDUAL ANIMAL TUMOR PATHOLOGY OF MALE RATS IN THE LIFETIME FEED STUDY OF SHORT-RANGE CHRYSOTILE ASBESTOS: SHORT-RANGE (Continued)



HWBUI0001576

TABLE A3. INDIVIDUAL ANIMAL TUMOR PATHOLOGY OF MALE RATS IN THE LIFETIME FEED STUDY OF SHORT-RANGE CHRYSOTILE ASBESTOS: SHORT-RANGE (Continued)

ANIMAL NUMBER	0 0 0 1 3	0 0 0 1 4	0 0 0 1 5	0 0 0 1 6	0 0 0 1 7	0 0 0 1 8	0 0 0 1 9	0 0 0 2 0	0 0 0 2 1	0 0 0 2 2	0 0 0 2 3	0 0 0 2 4	0 0 0 2 5	0 0 0 2 6	0 0 0 2 7	0 0 0 2 8	0 0 0 2 9	0 0 0 3 0	0 0 0 3 1	0 0 0 3 2	0 0 0 3 3	0 0 0 3 4	0 0 0 3 5	0 0 0 3 6	0 0 0 3 7	0 0 0 3 8	0 0 0 3 9	0 0 0 4 0
WEEKS ON STUDY	0 3 5	1 4 7	1 4 8	1 3 1	1 3 6	1 2 4	1 2 6	0 1 7	1 4 7	1 4 8	1 4 9	0 1 1	0 0 9	1 3 2	1 3 5	1 3 7	1 4 1	1 3 9	1 3 9	1 4 0	1 4 1	1 4 1	1 4 1	1 4 1	1 4 1	1 4 1	1 4 1	1 4 1
INTEGUMENTARY SYSTEM																												
SKIN	+	+	+	+	+	+	+	+	+	+	+	+	+	+	+	+	+	+	+	+	+	+	+	+	+	+	+	+
SQUAMOUS CELL PAPILLOMA																								X	X			
SQUAMOUS CELL CARCINOMA																												
BASAL-CELL TUMOR													X															
BASAL-CELL CARCINOMA															X													
TRICHOEPITHELIOMA																												
SEBACEOUS ADENOMA																												
KERATOACANTHOMA																								X				
FIBROUS HISTIOCYTOMA																												
FIBROUS HISTIOCYTOMA, MALIGNANT																												
HEMANGIOMA																												
SUBCUTANEOUS TISSUE	+	+	+	+	+	+	+	+	+	+	+	+	+	+	+	+	+	+	+	+	+	+	+	+	+	+	+	+
SARCOMA, NOS	X						X	X																				
FIBROMA																												
FIBROSARCOMA																												
FIBROUS HISTIOCYTOMA, MALIGNANT																												
MYXOSARCOMA																												
LIPOMA																												
LIPOSARCOMA																												
LEIOMYOSARCOMA, INVASIVE															X		X											
HEMANGIOSARCOMA																												
NEUROFIBROMA																												
NEUROFIBROSARCOMA		X																										
RESPIRATORY SYSTEM																												
LUNGS AND BRONCHI	+	+	+	+	+	+	+	+	+	+	+	+	+	+	+	+	+	+	+	+	+	+	+	+	+	+	+	+
SQUAMOUS CELL CARCINOMA, METASTAT																												
ALVEOLAR/BRONCHIOLAR ADENOMA																												
ALVEOLAR/BRONCHIOLAR CARCINOMA																												
C-CELL CARCINOMA, METASTATIC																												
FIBROSARCOMA, METASTATIC																												
LIPOSARCOMA, METASTATIC																												
MESOTHELIOMA, METASTATIC																												
OSTEOSARCOMA, METASTATIC																												
TRACHEA	+	+	+	+	+	+	+	+	+	+	+	+	+	+	+	+	+	+	+	+	+	+	+	+	+	+	+	+
FOLLICULAR-CELL CARCINOMA, INVASI																												
C-CELL CARCINOMA, METASTATIC																												
NASAL CAVITY	M	M	M	M	M	M	M	M	M	M	M	M	M	M	M	M	M	M	M	M	M	+	M	M	M			
CARCINOMA, NOS																												
SQUAMOUS CELL CARCINOMA																												
HEMATOPOIETIC SYSTEM																												
BONE MARROW	+	+	+	+	+	+	+	+	+	+	+	+	+	+	+	+	+	+	+	+	+	+	+	+	+	+	+	+
LIPOSARCOMA, INVASIVE																												
SPLEEN	+	+	+	+	+	+	+	+	+	+	+	+	+	+	+	+	+	+	+	+	+	+	+	+	+	+	+	+
MESOTHELIOMA, METASTATIC																										X		
HEMANGIOMA																												
HEMANGIOSARCOMA																												
MALIG.LYMPHOMA, HISTIOCYTIC TYPE																												
LYMPH NODES	+	+	+	+	+	+	+	+	+	+	+	+	+	+	+	+	+	+	+	+	+	+	+	+	+	+	+	+
CARCINOMA, NOS, METASTATIC																												
SQUAMOUS CELL CARCINOMA, METASTAT																												
C-CELL CARCINOMA, METASTATIC																												
INTERSTITIAL-CELL TUMOR, METASTAT																												
SARCOMA, NOS, INVASIVE																												
FIBROSARCOMA, INVASIVE																												
MESOTHELIOMA, METASTATIC																												
THYMUS	+	+	+	+	-	+	+	+	+	-	+	+	+	+	+	+	+	+	-	+	+	+	+	-	-	+		
CARCINOMA, NOS																X												
CIRCULATORY SYSTEM																												
HEART	+	+	+	+	+	+	+	+	+	+	+	+	+	+	+	+	+	+	+	+	+	+	+	+	+	+	+	+
CARCINOMA, NOS, INVASIVE																X												
FIBROSARCOMA, METASTATIC																												
DIGESTIVE SYSTEM																												
ORAL CAVITY	M	M	M	M	M	M	M	M	M	M	M	M	M	M	M	M	M	M	M	M	M	M	M	M	M	M	M	M
SQUAMOUS CELL PAPILLOMA																												
SALIVARY GLAND	+	+	+	+	+	+	+	+	+	+	+	+	+	+	+	+	+	+	+	+	+	+	+	+	+	+	+	+
SARCOMA, NOS																												
FIBROSARCOMA																												
LIVER	+	+	+	+	+	+	+	+	+	+	+	+	+	+	+	+	+	+	+	+	+	+	+	+	+	+	+	+
NEOPLASTIC NODULE																												
HEPATOCELLULAR CARCINOMA																X												
C-CELL CARCINOMA, METASTATIC																												
FIBROSARCOMA, METASTATIC																												
HEMANGIOSARCOMA, METASTATIC																												
MONOCYTIC LEUKEMIA																												
BILE DUCT	+	+	+	+	+	+	+	+	+	+	+	+	+	+	+	+	+	+	+	+	+	+	+	+	+	+	+	+
GALLBLADDER & COMMON BILE DUCT	M	M	M	M	M	M	M	M	M	M	M	M	M	M	M	M	M	M	M	M	M	M	M	M	M	M	M	M
PANCREAS	+	+	+	+	+	+	+	+	+	+	+	+	+	+	+	+	+	+	+	+	+	+	+	+	+	+	+	+
ACINAR-CELL ADENOMA																												
MIXED TUMOR, BENIGN																												
ESOPHAGUS	+	+	+	+	+	+	+	+	+	+	+	+	+	+	+	+	+	+	+	+	+	+	+	+	+	+	+	+
STOMACH	+	+	+	+	+	+	+	+	+	+	+	+	+	+	+	+	+	+	+	+	+	+	+	+	+	+	+	+
CARCINOMA-IN-SITU, NOS																												
SQUAMOUS CELL PAPILLOMA																												
SQUAMOUS CELL CARCINOMA																												
SARCOMA, NOS																												
SMALL INTESTINE	+	+	+	+	+	+	+	+	+	+	+	+	+	+	+	+	+	+	+	+	+	+	+	+	+	+	+	-
ADENOMATOUS POLYP, NOS																												
LARGE INTESTINE	+	+	+	+	+	+	+	+	+	+	+	+	+	+	+	+	+	+	+	+	+	+	+	+	+	+	+	+
ADENOMATOUS POLYP, NOS																												
LIPOMA																												
LEIOMYOSARCOMA																												
RECTUM	+	+	+	+	+	+	+	+	+	+	+	+	+	N	+	+	+	+	+	+	N	+	+	+	+	+	+	+
LEIOMYOSARCOMA, INVASIVE																												

HWBUI0001577

TABLE A3. INDIVIDUAL ANIMAL TUMOR PATHOLOGY OF MALE RATS IN THE LIFETIME FEED STUDY OF SHORT-RANGE CHRYSOTILE ASBESTOS: SHORT-RANGE (Continued)



HWBUI0001578

TABLE A3. INDIVIDUAL ANIMAL TUMOR PATHOLOGY OF MALE RATS IN THE LIFETIME FEED STUDY OF SHORT-RANGE CHRYSOTILE ASBESTOS: SHORT-RANGE (Continued)

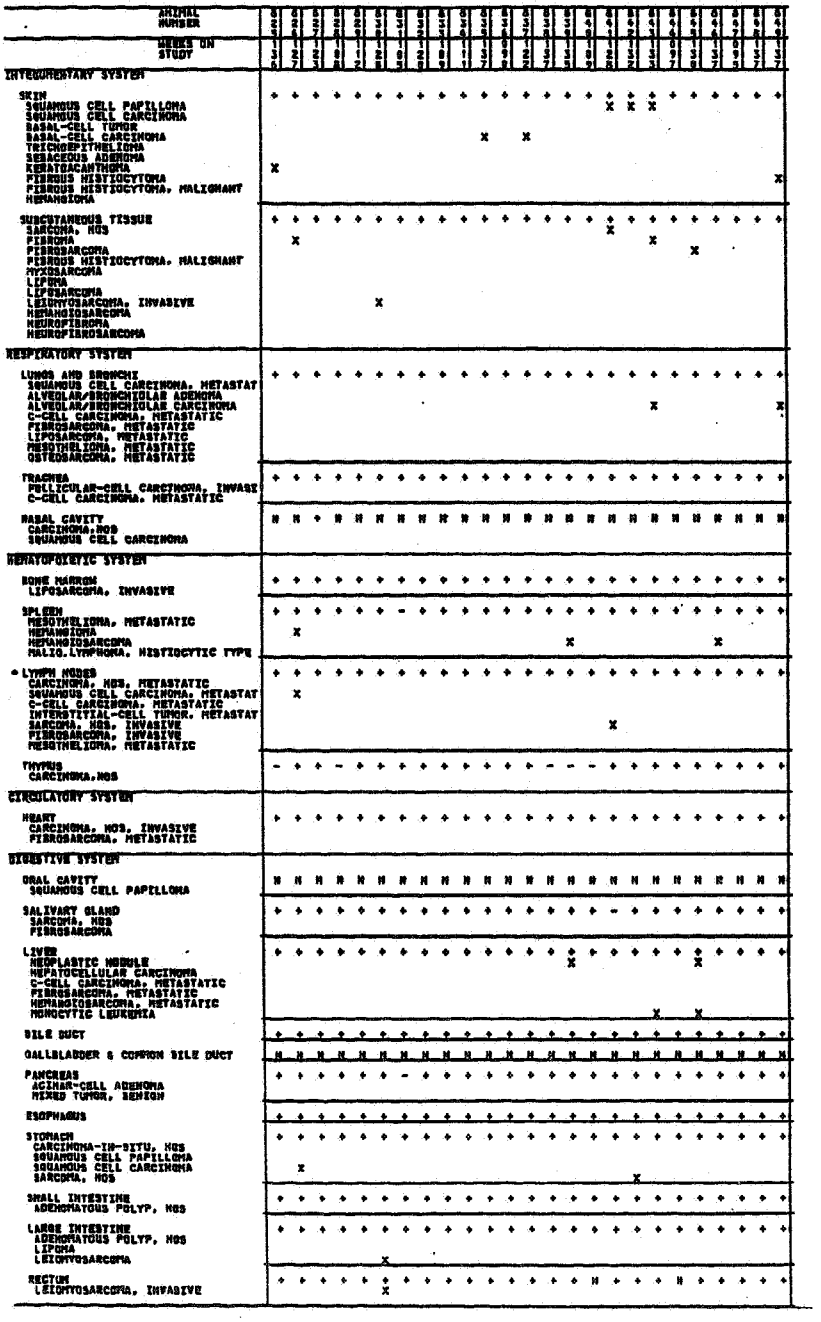

HWBUI0001579

TABLE A3. INDIVIDUAL ANIMAL TUMOR PATHOLOGY OF MALE RATS IN THE LIFETIME FEED STUDY OF SHORT-RANGE CHRYSOTILE ASBESTOS: SHORT-RANGE (Continued)



HWBUI0001580

TABLE A3. INDIVIDUAL ANIMAL TUMOR PATHOLOGY OF MALE RATS IN THE LIFETIME FEED STUDY OF SHORT-RANGE CHRYSOTILE ASBESTOS: SHORT-RANGE (Continued)

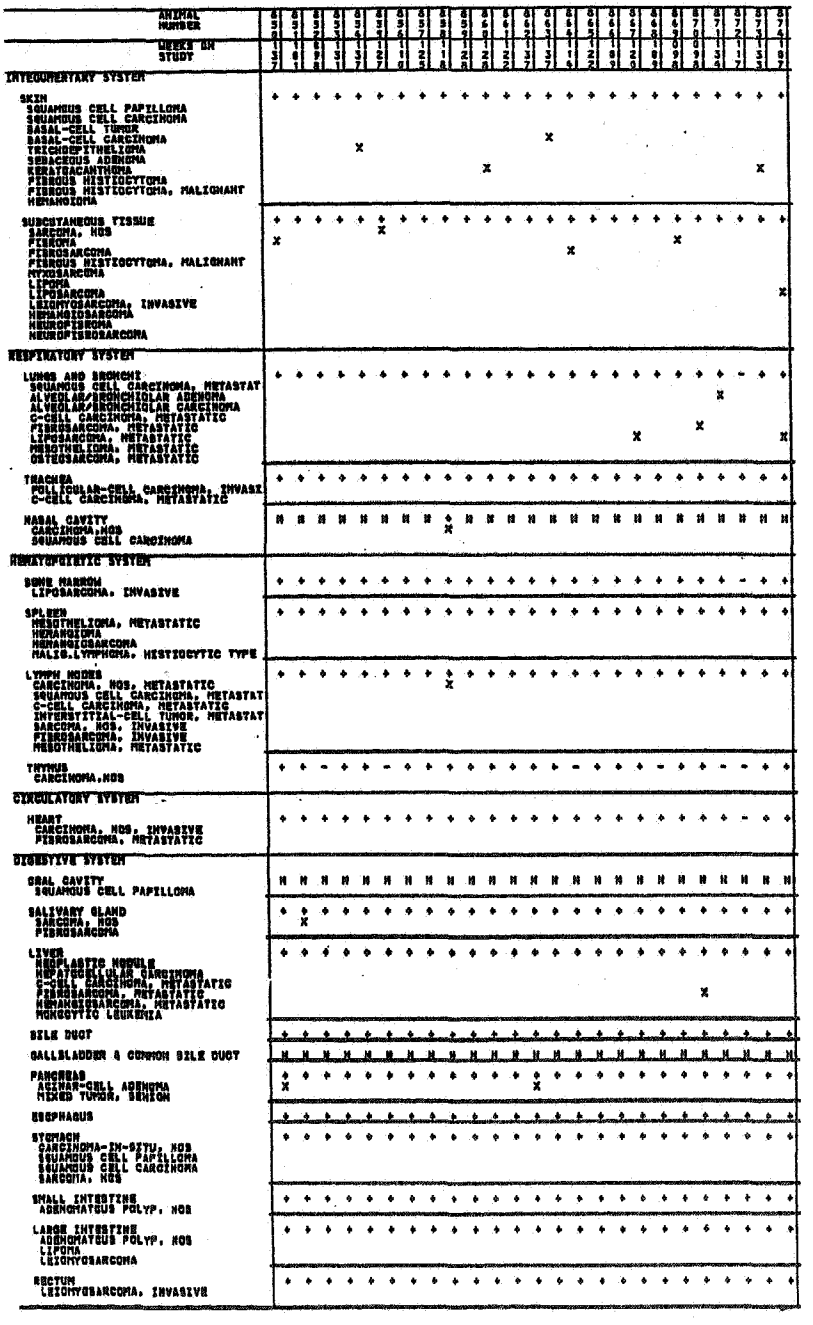

HWBUI0001581

TABLE A3. INDIVIDUAL ANIMAL TUMOR PATHOLOGY OF MALE RATS IN THE LIFETIME FEED STUDY OF SHORT-RANGE CHRYSOTILE ASBESTOS: SHORT-RANGE (Continued)



HWBUI0001582

TABLE A3. INDIVIDUAL ANIMAL TUMOR PATHOLOGY OF MALE RATS IN THE LIFETIME FEED STUDY OF SHORT-RANGE CHRYSOTILE ASBESTOS: SHORT-RANGE (Continued)

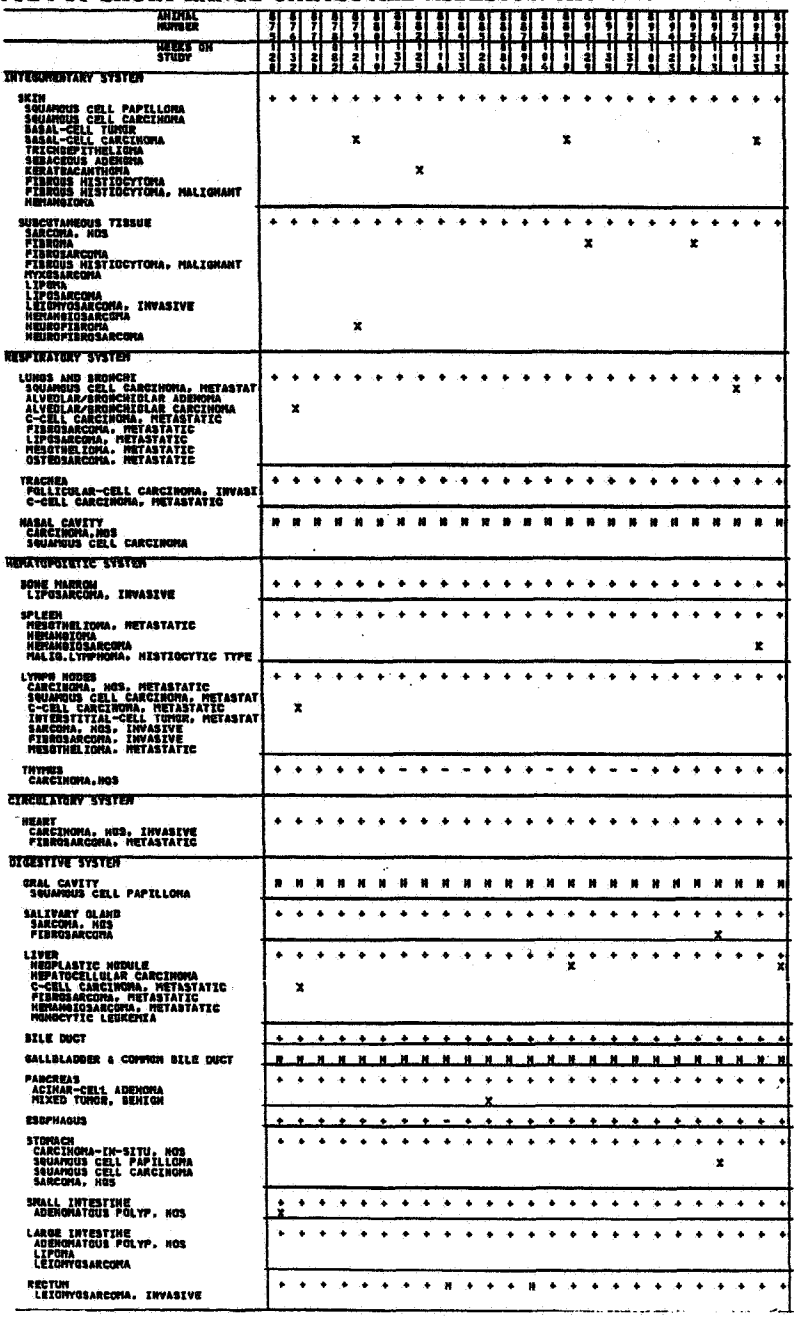

HWBUI0001583

TABLE A3. INDIVIDUAL ANIMAL TUMOR PATHOLOGY OF MALE RATS IN THE LIFETIME FEED STUDY OF SHORT-RANGE CHRYSOTILE ASBESTOS: SHORT-RANGE (Continued)



HWBUI0001584

TABLE A3. INDIVIDUAL ANIMAL TUMOR PATHOLOGY OF MALE RATS IN THE LIFETIME FEED STUDY OF SHORT-RANGE CHRYSOTILE ASBESTOS: SHORT-RANGE (Continued)

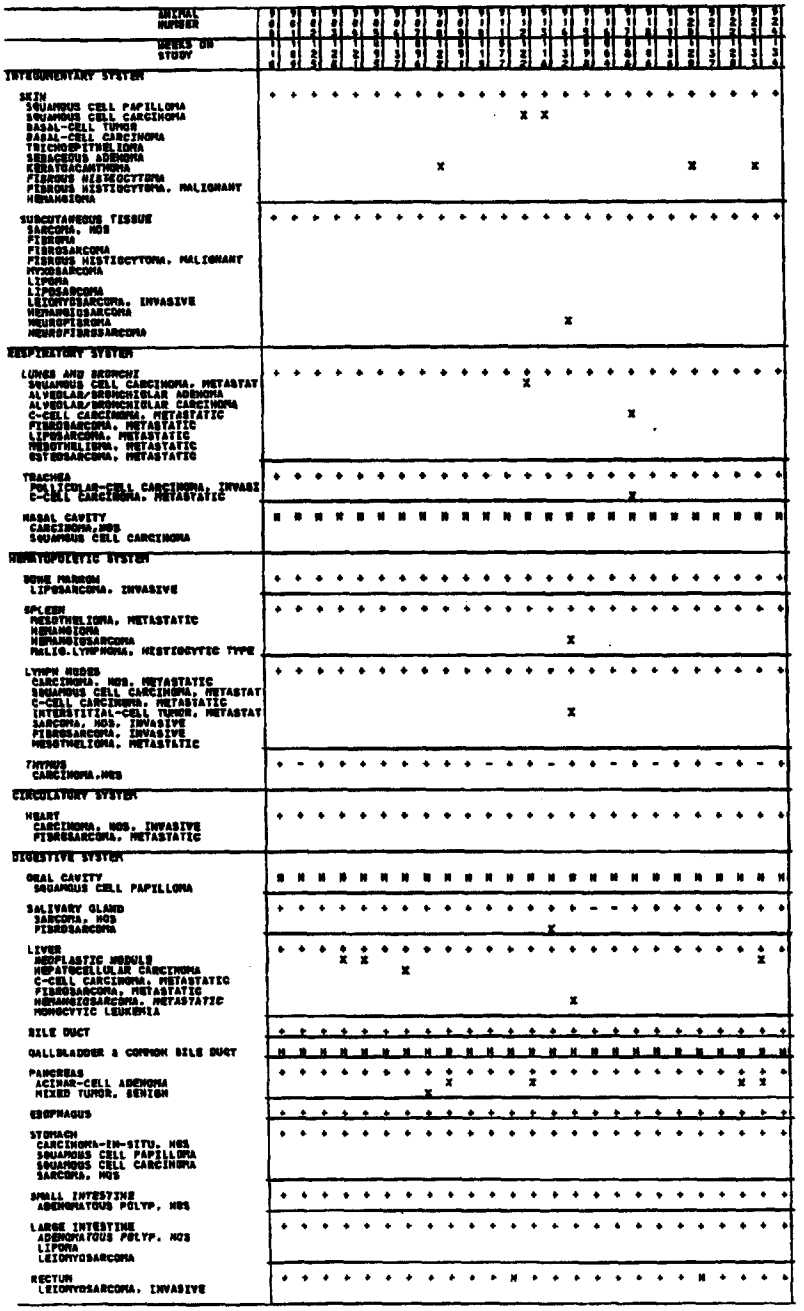

HWBUI0001585

TABLE A3. INDIVIDUAL ANIMAL TUMOR PATHOLOGY OF MALE RATS IN THE LIFETIME FEED STUDY OF SHORT-RANGE CHRYSOTILE ASBESTOS: SHORT-RANGE (Continued)



HWBUI0001586

TABLE A3. INDIVIDUAL ANIMAL TUMOR PATHOLOGY OF MALE RATS IN THE LIFETIME FEED STUDY OF SHORT-RANGE CHRYSOTILE ASBESTOS: SHORT-RANGE (Continued)



TABLE A3. INDIVIDUAL ANIMAL TUMOR PATHOLOGY OF MALE RATS IN THE LIFETIME FEED STUDY OF SHORT-RANGE CHRYSOTILE ASBESTOS: SHORT-RANGE (Continued)

ANIMAL NUMBER	0 0 2 0	0 0 3 0	0 0 7 0	0 0 8 0	0 0 9 0	0 1 0 0	0 1 2 0	0 1 3 0	0 1 4 0	0 1 5 0	0 1 6 0	0 1 7 0	0 1 8 0	0 1 9 0	0 2 0 0	0 2 1 0	0 2 2 0	0 2 3 0	0 2 4 0	0 2 5 0	0 2 6 0	0 2 7 0	0 2 8 0	0 2 9 0	0 3 0 0
WEEKS ON STUDY	0 3 5	0 3 5	0 3 7	0 3 8	0 3 9	0 3 9	0 3 9	0 3 9	0 3 9	0 3 9	0 3 9	0 3 9	0 3 9	0 3 9	0 3 9	0 3 9	0 3 9	0 3 9	0 3 9	0 3 9	0 3 9	0 3 9	0 3 9	0 3 9	0 3 9	0 3 9
URINARY SYSTEM																									
KIDNEY	+	+	+	+	+	+	+	+	+	+	+	+	+	+	+	+	+	+	+	+	+	+	+	+	+
TUBULAR-CELL ADENOMA																									
MIXED TUMOR, MALIGNANT																									
URINARY BLADDER	+	+	+	+	+	+	+	+	+	-	+	+	+	+	+	+	+	+	+	+	+	+	+	+	+
SQUAMOUS CELL PAPILLOMA																									
TRANSITIONAL-CELL PAPILLOMA																									
ENDOCRINE SYSTEM																									
PITUITARY	+	+	+	+	+	+	+	+	+	+	+	+	+	+	+	+	+	+	+	+	+	+	+	+	+
CARCINOMA, NOS																									
ADENOMA, NOS	X															X								X	
ADRENAL	+	+	+	+	+	+	+	+	+	+	+	+	+	+	+	+	+	+	+	+	+	+	+	+	+
CORTICAL ADENOMA		X								X	X			X											X
PHEOCHROMOCYTOMA																									
PHEOCHROMOCYTOMA, MALIGNANT																									
GANGLIONEUROMA																									
THYROID	+	+	+	+	+	+	+	+	+	+	+	+	+	+	+	+	+	+	+	+	+	+	+	+	+
FOLLICULAR-CELL ADENOMA																X				X					
FOLLICULAR-CELL CARCINOMA																									
C-CELL ADENOMA											X			X										X	
C-CELL CARCINOMA																X									
FIBROSARCOMA, INVASIVE																									
PARATHYROID	+	+	+	+	+	+	+	+	+	+	+	+	+	+	+	+	+	+	+	+	-	+	+	+	+
ADENOMA, NOS																									
PANCREATIC ISLETS	+	+	+	+	+	+	+	+	+	+	+	+	+	+	+	+	+	+	+	+	+	+	+	+	+
ISLET-CELL ADENOMA																X								X	
ISLET-CELL CARCINOMA										X						X								X	
REPRODUCTIVE SYSTEM																									
MAMMARY GLAND	+	+	+	+	+	+	+	+	+	+	+	+	+	+	+	+	+	+	+	+	+	+	+	+	+
ADENOMA, NOS																									
PAPILLARY ADENOMA																									
PAPILLARY CYSTADENOMA, NOS																									
FIBROADENOMA																X				X					
TESTIS	+	+	+	+	+	+	+	+	+	+	+	+	+	+	+	+	+	+	+	+	+	+	+	+	+
INTERSTITIAL-CELL TUMOR		X	X	X	X	X	X	X	X	X	X	X	X		X	X	X	X	X	X	X	X	X	X	X
INTERSTITIAL-CELL TUMOR, MALIGNAN																									
PROSTATE	+	+	+	+	+	+	+	+	+	-	+	+	+	+	+	+	+	+	+	+	+	+	+	+	+
ADENOMA, NOS																									
PREPUTIAL/CLITORAL GLAND	M	M	M	M	M	M	M	M	M	M	M	M	M	M	M	M	M	M	M	M	M	M	M	M	M
CARCINOMA, NOS																									
SQUAMOUS CELL CARCINOMA																									
ADENOMA, NOS																									
KERATOACANTHOMA																									
EPIDIDYMIS	M	M	M	M	M	M	M	M	M	M	M	M	M	M	M	M	M	M	M	M	M	M	M	M	M
MESOTHELIOMA, INVASIVE																									
NERVOUS SYSTEM																									
BRAIN	+	+	+	+	+	+	+	+	+	+	+	+	+	+	+	+	+	+	+	+	+	+	+	+	+
CARCINOMA, NOS, INVASIVE																									
ASTROCYTOMA																									
SPECIAL SENSE ORGANS																									
ZYMBAL'S GLAND	M	+	+	+	+	+	+	+	+	+	M	+	+	+	+	+	+	+	+	+	+	+	+	+	+
SQUAMOUS CELL PAPILLOMA																									
SQUAMOUS CELL CARCINOMA																									
MUSCULOSKELETAL SYSTEM																									
BONE	M	M	M	M	M	M	M	M	M	M	M	M	M	M	M	M	M	M	M	M	M	M	M	M	M
LIPOSARCOMA																									
LIPOSARCOMA, INVASIVE																									
OSTEOSARCOMA						X															X				
BODY CAVITIES																									
MEDIASTINUM	M	M	M	M	M	M	M	M	M	M	M	M	M	M	M	M	M	M	M	M	M	M	M	M	M
ALVEOLAR/BRONCHIOLAR CA, INVASIVE																									
FIBROSARCOMA, INVASIVE																									
HEMANGIOSARCOMA																									
PERITONEUM	M	M	M	M	M	M	M	M	M	M	M	M	M	M	M	M	M	M	M	M	M	M	M	M	M
PHEOCHROMOCYTOMA, METASTATIC																									
TUNICA VAGINALIS	+	+	+	+	+	+	+	+	+	+	+	+	+	+	+	+	+	+	+	+	+	+	+	+	+
MESOTHELIOMA, MALIGNANT																									
MESENTERY	M	M	M	M	M	M	M	M	M	M	M	M	M	M	M	M	M	M	M	M	M	M	M	M	M
FIBROSARCOMA																									
MESOTHELIOMA, MALIGNANT																									
ALL OTHER SYSTEMS																									
MULTIPLE ORGANS NOS	M	M	M	M	M	M	M	M	M	M	M	M	M	M	M	M	M	M	M	M	M	M	M	M	M
SQUAMOUS CELL CARCINOMA, INVASIVE																									
C-CELL CARCINOMA, METASTATIC																X									
FIBROSARCOMA, INVASIVE																									
FIBROUS HISTIOCYTOMA, MALIGNANT																									
MESOTHELIOMA, INVASIVE																									
HEMANGIOSARCOMA, METASTATIC																									
MALIGNANT LYMPHOMA, NOS																									
MALIG.LYMPHOMA, UNDIFFER-TYPE																									
MALIG.LYMPHOMA, LYMPHOCYTIC TYPE																									
MALIG.LYMPHOMA, HISTIOCYTIC TYPE																									
MONOCYTIC LEUKEMIA			X	X			X	X	X		X			X	X		X	X	X		X			X	X
LEUKEMIA,MONONUCLEAR CELL																									
SCROTUM NOS																									
MESOTHELIOMA, INVASIVE																									

HWBUI0001588

TABLE A3. INDIVIDUAL ANIMAL TUMOR PATHOLOGY OF MALE RATS IN THE LIFETIME FEED STUDY OF SHORT-RANGE CHRYSOTILE ASBESTOS: SHORT-RANGE (Continued)

ANIMAL NUMBER / WEEKS ON STUDY	TOTAL TISSUES / TUMORS
INTEGUMENTARY SYSTEM	
SKIN	250
SQUAMOUS CELL PAPILLOMA	7
SQUAMOUS CELL CARCINOMA	2
BASAL-CELL TUMOR	5
BASAL-CELL CARCINOMA	12
TRICHOEPITHELIOMA	1
SEBACEOUS ADENOMA	1
KERATOACANTHOMA	14
FIBROUS HISTIOCYTOMA	1
FIBROUS HISTIOCYTOMA, MALIGNANT	1
HEMANGIOMA	1
SUBCUTANEOUS TISSUE	250
SARCOMA, NOS	3
FIBROMA	22
FIBROSARCOMA	6
FIBROUS HISTIOCYTOMA, MALIGNANT	1
MYXOSARCOMA	1
LIPOMA	1
LIPOSARCOMA	2
LEIOMYOSARCOMA, INVASIVE	1
HEMANGIOSARCOMA	2
NEUROFIBROMA	9
NEUROFIBROSARCOMA	2
RESPIRATORY SYSTEM	
LUNGS AND BRONCHI	247
SQUAMOUS CELL CARCINOMA, METASTAT	3
ALVEOLAR/BRONCHIOLAR ADENOMA	1
ALVEOLAR/BRONCHIOLAR CARCINOMA	6
C-CELL CARCINOMA, METASTATIC	2
FIBROSARCOMA, METASTATIC	1
LIPOSARCOMA, METASTATIC	4
MESOTHELIOMA, METASTATIC	1
OSTEOSARCOMA, METASTATIC	1
TRACHEA	249
FOLLICULAR-CELL CARCINOMA, INVASI	1
C-CELL CARCINOMA, METASTATIC	1
NASAL CAVITY	250
CARCINOMA,NOS	1
SQUAMOUS CELL CARCINOMA	1
HEMATOPOIETIC SYSTEM	
BONE MARROW	247
LIPOSARCOMA, INVASIVE	1
SPLEEN	247
MESOTHELIOMA, METASTATIC	1
HEMANGIOMA	1
HEMANGIOSARCOMA	3
MALIG.LYMPHOMA, HISTIOCYTIC TYPE	1
LYMPH NODES	248
CARCINOMA, NOS, METASTATIC	1
SQUAMOUS CELL CARCINOMA, METASTAT	1
C-CELL CARCINOMA, METASTATIC	2
INTERSTITIAL-CELL TUMOR, METASTAT	1
SARCOMA, NOS, INVASIVE	1
FIBROSARCOMA, INVASIVE	1
MESOTHELIOMA, METASTATIC	1
THYMUS	197
CARCINOMA,NOS	1
CIRCULATORY SYSTEM	
HEART	247
CARCINOMA, NOS, INVASIVE	1
FIBROSARCOMA, METASTATIC	1
DIGESTIVE SYSTEM	
ORAL CAVITY	250
SQUAMOUS CELL PAPILLOMA	1
SALIVARY GLAND	243
SARCOMA, NOS	1
FIBROSARCOMA	1
LIVER	248
NEOPLASTIC NODULE	17
HEPATOCELLULAR CARCINOMA	2
C-CELL CARCINOMA, METASTATIC	1
FIBROSARCOMA, METASTATIC	1
HEMANGIOSARCOMA, METASTATIC	1
MONOCYTIC LEUKEMIA	1
BILE DUCT	250
GALLBLADDER & COMMON BILE DUCT	250
PANCREAS	247
ACINAR-CELL ADENOMA	14
MIXED TUMOR, BENIGN	1
ESOPHAGUS	247
STOMACH	248
CARCINOMA-IN-SITU, NOS	1
SQUAMOUS CELL PAPILLOMA	1
SQUAMOUS CELL CARCINOMA	1
SARCOMA, NOS	1
SMALL INTESTINE	248
ADENOMATOUS POLYP, NOS	1
LARGE INTESTINE	248
ADENOMATOUS POLYP, NOS	1
LIPOMA	1
LEIOMYOSARCOMA	2
RECTUM	250
LEIOMYOSARCOMA, INVASIVE	1

HWBUI0001589

TABLE A3. INDIVIDUAL ANIMAL TUMOR PATHOLOGY OF MALE RATS IN THE LIFETIME FEED STUDY OF SHORT-RANGE CHRYSOTILE ASBESTOS: SHORT-RANGE (Continued)



* ANIMALS NECROPSIED

HWBUI0001590

TABLE A4. INDIVIDUAL ANIMAL TUMOR PATHOLOGY OF FEMALE RATS IN THE LIFETIME FEED STUDY OF SHORT-RANGE CHRYSOTILE ASBESTOS: UNTREATED CONTROL

ANIMAL NUMBER	63137	63138	63139	64401	64412	64423	64434	64445	64456	64467	64478	64489	64501	65511	65522	65533	65544	65555	65566	65577	65588	65599	66601	66611
WEEKS ON STUDY	1 1 4 5	1 3 3 7	0 8 5	1 2 4	1 4 5	1 4 4	1 1 6	1 3 7	1 2 1	0 9 0	1 1 4	1 4 0	1 0 9	1 1 4	1 1 6	1 1 1	1 4 4	1 2 4	1 3 5	0 9 3	1 2 1	1 1 8	1 3 4	1 1 6	1 3 7
INTEGUMENTARY SYSTEM																								
SKIN	+	+	+	+	+	+	+	+	+	+	+	+	+	+	+	+	+	+	+	+	+	+	+	+
SQUAMOUS CELL PAPILLOMA																								
SQUAMOUS CELL CARCINOMA																								
BASAL-CELL CARCINOMA																								
KERATOACANTHOMA																								
SUBCUTANEOUS TISSUE	+	+	+	+	+	+	+	+	+	+	+	+	+	+	+	+	+	+	+	+	+	+	+	+
SQUAMOUS CELL CARCINOMA, INVASIVE																								
FIBROMA											X													
FIBROSARCOMA																								
LIPOMA																	X							
LIPOSARCOMA																								
RESPIRATORY SYSTEM																								
LUNGS AND BRONCHI	+	+	+	+	+	+	+	+	+	+	+	+	+	+	+	+	+	+	+	+	+	+	+	+
SQUAMOUS CELL CARCINOMA, METASTAT																								
ALVEOLAR/BRONCHIOLAR CARCINOMA	X																							
FOLLICULAR-CELL CARCINOMA, METAST																								
TRACHEA	+	+	+	+	+	+	+	+	+	+	+	+	+	+	+	+	+	+	+	+	+	+	+	+
NASAL CAVITY	N	N	N	N	N	N	N	N	N	N	+	N	N	N	N	N	N	N	N	N	N	N	N	N
SQUAMOUS CELL CARCINOMA											X													
HEMATOPOIETIC SYSTEM																								
BONE MARROW	+	+	+	+	+	+	+	+	+	+	+	+	+	+	+	+	+	+	+	+	+	+	+	+
SPLEEN	+	+	+	+	+	+	+	+	+	+	+	+	+	+	+	+	+	+	+	+	+	+	+	+
ANGIOMA																								
LYMPH NODES	+	+	+	+	+	+	+	+	+	+	+	+	+	+	+	+	+	+	+	+	+	+	+	+
THYMUS	+	+	+	+	+	+	–	+	+	+	+	+	+	+	–	–	–	+	+	+	+	+	–	+
CIRCULATORY SYSTEM																								
HEART	+	+	+	+	+	+	+	+	+	+	+	+	+	+	+	+	+	+	+	+	+	+	+	+
SARCOMA, NOS																								X
DIGESTIVE SYSTEM																								
ORAL CAVITY	N	N	N	N	N	N	N	N	N	N	N	N	N	N	N	N	N	N	N	N	N	N	N	N
SQUAMOUS CELL CARCINOMA, INVASIVE																								
SALIVARY GLAND	+	+	+	+	+	+	+	+	+	+	+	+	+	+	+	+	+	+	+	+	+	+	+	+
LIVER	+	+	+	+	+	+	+	+	+	+	+	+	+	+	+	+	+	+	+	+	+	+	+	+
NEOPLASTIC NODULE																					X			
MONOCYTIC LEUKEMIA																								
BILE DUCT	+	+	+	+	+	+	+	+	+	+	+	+	+	+	+	+	+	+	+	+	+	+	+	+
GALLBLADDER & COMMON BILE DUCT	N	N	N	N	N	N	N	N	N	N	N	N	N	N	N	N	N	N	N	N	N	N	N	N
PANCREAS	+	+	+	+	+	+	+	+	+	+	+	+	+	+	+	+	+	+	–	+	+	+	+	+
ADENOCARCINOMA, NOS																								
ACINAR-CELL ADENOMA																	X							
ACINAR-CELL CARCINOMA																								
ESOPHAGUS	+	+	+	+	+	+	+	+	+	+	+	+	+	+	+	+	+	+	+	+	+	+	+	+
STOMACH	+	+	+	+	+	+	+	+	+	+	+	+	+	+	+	+	+	+	+	+	+	+	+	+
SMALL INTESTINE	+	+	+	+	+	+	+	+	+	+	+	+	+	+	+	+	+	+	+	+	+	+	+	+
LEIOMYOSARCOMA														X										
LARGE INTESTINE	+	+	+	+	+	+	+	+	+	+	+	+	+	+	+	+	+	+	+	+	+	+	+	+
ADENOMATOUS POLYP, NOS																								
URINARY SYSTEM																								
KIDNEY	+	+	+	+	+	+	+	+	+	+	+	+	+	+	+	+	+	+	+	+	+	+	+	+
URINARY BLADDER	+	+	+	+	+	+	+	+	+	+	+	+	+	+	+	+	+	+	+	+	+	+	+	+

+: TISSUE EXAMINED MICROSCOPICALLY
–: REQUIRED TISSUE NOT EXAMINED MICROSCOPICALLY
X: TUMOR INCIDENCE
N: NECROPSY, NO AUTOLYSIS, NO MICROSCOPIC EXAMINATION
S: ANIMAL MIS-SEXED
: NO TISSUE INFORMATION SUBMITTED
C: NECROPSY, NO HISTOLOGY DUE TO PROTOCOL
A: AUTOLYSIS
M: ANIMAL MISSING
B: NO NECROPSY PERFORMED

HWBUI0001591

TABLE A4. INDIVIDUAL ANIMAL TUMOR PATHOLOGY OF FEMALE RATS IN THE LIFETIME FEED STUDY OF SHORT-RANGE CHRYSOTILE ASBESTOS: UNTREATED CONTROL (Continued)

ANIMAL NUMBER	652	653	654	655	656	657	658	659	670	671	672	673	674	675	676	677	678	679	680	681	682	683	684	685	686
WEEKS ON STUDY	110	110	075	123	098	114	145	130	136	130	084	118	122	085	126	145	090	118	113	114	123	144	093	123	123
ENDOCRINE SYSTEM																									
PITUITARY	+	+	A	+	+	+	+	+	+	+	+	+	+	+	+	+	+	+	+	+	+	+	+	+	+
CARCINOMA,NOS																									
ADENOMA, NOS	X				X		X		X				X	X	X			X			X	X		X	
ADRENAL	+	+	A	+	+	+	+	+	+	+	+	+	+	+	+	+	+	+	+	+	+	+	+	+	+
CORTICAL ADENOMA													X		X										
PHEOCHROMOCYTOMA							X					X													
THYROID	+	+	A	+	+	+	+	+	+	+	+	+	+	+	+	+	+	+	+	+	+	+	+	+	+
FOLLICULAR-CELL ADENOMA																									
FOLLICULAR-CELL CARCINOMA							X																		
C-CELL ADENOMA									X															X	
C-CELL CARCINOMA																									
PARATHYROID	+	+	A	+	+	+	+	+	+	+	+	+	+	+	+	–	+	+	+	+	+	+	+	+	+
PANCREATIC ISLETS	+	+	A	+	+	+	+	+	+	+	+	+	+	+	+	+	+	+	+	+	+	+	+	+	+
ISLET-CELL ADENOMA																									
ISLET-CELL CARCINOMA										X															
REPRODUCTIVE SYSTEM																									
MAMMARY GLAND	+	+	N	+	+	+	+	+	+	+	+	+	+	+	+	+	+	+	+	+	+	+	+	+	+
CARCINOMA,NOS																									
ADENOMA, NOS															X										
ADENOCARCINOMA, NOS							X								X	X						X			
PAPILLARY CYSTADENOMA, NOS																									
PAPILLARY CYSTADENOCARCINOMA,NOS																								X	
FIBROSARCOMA																									
FIBROADENOMA		X			X		X	X		X	X		X		X	X		X			X	X	X	X	X
PREPUTIAL/CLITORAL GLAND	N	N	N	N	N	N	N	N	N	N	N	N	N	N	N	N	N	N	N	N	N	N	N	N	N
CARCINOMA,NOS																									
SQUAMOUS CELL CARCINOMA																									
ADENOMA, NOS																									X
UTERUS	+	+	A	+	+	+	+	+	+	+	+	+	+	+	+	+	+	+	+	+	+	+	+	+	+
CARCINOMA-IN-SITU, NOS																					X				
CARCINOMA,NOS									X																
ENDOMETRIAL STROMAL POLYP				X				X								X				X		X			
CARCINOSARCOMA																									
OVARY	+	+	A	+	+	+	+	+	+	+	+	+	+	+	+	+	+	+	+	+	+	+	+	+	+
THECOMA																									
GRANULOSA-CELL TUMOR																									
NERVOUS SYSTEM																									
BRAIN	+	+	A	+	+	+	+	+	+	+	+	+	+	+	+	+	+	+	+	+	+	+	+	+	+
CARCINOMA, NOS, INVASIVE																									
CARCINOMA, NOS, METASTATIC																									
SPECIAL SENSE ORGANS																									
ZYMBAL'S GLAND	+	+	N	+	+	+	+	+	+	+	+	+	+	N	+	+	+	+	N	+	+	+	+	+	+
SQUAMOUS CELL CARCINOMA						X																			
MUSCULOSKELETAL SYSTEM																									
BONE	N	N	N	N	N	N	N	N	N	N	N	N	N	N	N	N	N	N	N	N	N	N	N	N	N
OSTEOSARCOMA								X																	
ALL OTHER SYSTEMS																									
MULTIPLE ORGANS NOS	N	N	N	N	N	N	N	N	N	N	N	N	N	N	N	N	N	N	N	N	N	N	N	N	N
CARCINOMA, NOS, INVASIVE									X																
SQUAMOUS CELL CARCINOMA, INVASIVE																									
SARCOMA, NOS, INVASIVE																									
SARCOMA, NOS, METASTATIC																									
MALIG.LYMPHOMA, HISTIOCYTIC TYPE																									
MONOCYTIC LEUKEMIA	X							X							X	X			X	X	X	X			
LEUKEMIA,MONONUCLEAR CELL																									
CHEEK, NOS																									
SQUAMOUS CELL CARCINOMA, INVASIVE																									

HWBUI0001592

TABLE A4. INDIVIDUAL ANIMAL TUMOR PATHOLOGY OF FEMALE RATS IN THE LIFETIME FEED STUDY OF SHORT-RANGE CHRYSOTILE ASBESTOS: UNTREATED CONTROL (Continued)

ANIMAL NUMBER	68701	68802	68903	69004	69105	69206	69307	69408	69509	69610	69711	69812	69913	70014	70115	70216	70317	70418	70519	70620	70721	70822	70923	71024	71125
WEEKS ON STUDY	110	142	110	136	095	115	145	122	087	118	116	116	096	129	145	123	130	091	095	141	145	081	143	130	140
INTEGUMENTARY SYSTEM																									
SKIN	+	+	+	+	+	+	+	+	+	+	+	+	+	+	+	+	+	+	+	+	+	+	+	+	+
SQUAMOUS CELL PAPILLOMA												X													
SQUAMOUS CELL CARCINOMA																									
BASAL-CELL CARCINOMA							X																		
KERATOACANTHOMA			X																						
SUBCUTANEOUS TISSUE	+	+	+	+	+	+	+	+	+	+	+	+	+	+	+	+	+	+	+	+	+	+	+	+	+
SQUAMOUS CELL CARCINOMA, INVASIVE		X																							
FIBROMA																									
FIBROSARCOMA																									
LIPOMA																		X							
LIPOSARCOMA																									
RESPIRATORY SYSTEM																									
LUNGS AND BRONCHI	+	+	+	+	+	+	+	+	+	+	+	+	+	+	+	+	+	+	+	+	+	+	+	+	+
SQUAMOUS CELL CARCINOMA, METASTAT																									
ALVEOLAR/BRONCHIOLAR CARCINOMA																									
FOLLICULAR-CELL CARCINOMA, METAST																							X		
TRACHEA	+	+	+	+	+	+	+	+	+	+	+	+	+	+	+	+	+	+	+	+	+	+	+	+	+
NASAL CAVITY	N	N	N	N	N	N	N	N	N	N	N	N	N	N	N	N	N	N	N	N	N	N	N	N	N
SQUAMOUS CELL CARCINOMA																									
HEMATOPOIETIC SYSTEM																									
BONE MARROW	-	+	+	+	+	+	+	+	+	+	+	+	+	+	+	+	+	+	+	+	+	+	+	+	+
SPLEEN	+	+	+	+	+	+	+	+	+	+	+	+	+	+	+	+	+	+	+	+	+	+	+	+	+
ANGIOMA																									
LYMPH NODES	+	+	+	+	+	+	+	+	+	+	+	+	+	+	+	+	+	+	+	+	+	+	+	+	+
THYMUS	+	+	-	+	+	-	-	-	-	-	+	+	-	-	+	+	+	+	+	+	+	+	+	+	+
CIRCULATORY SYSTEM																									
HEART	+	+	+	+	+	+	+	+	+	+	+	+	+	+	+	+	+	+	+	+	+	+	+	+	+
SARCOMA, NOS																									
DIGESTIVE SYSTEM																									
ORAL CAVITY	N	N	N	N	N	N	N	N	N	N	N	N	N	N	N	N	N	N	N	N	N	N	N	N	N
SQUAMOUS CELL CARCINOMA, INVASIVE																									
SALIVARY GLAND	+	+	+	+	+	+	+	+	+	+	+	+	+	+	+	+	+	+	+	+	+	+	+	+	+
LIVER	+	+	+	+	+	+	+	+	+	+	+	+	+	+	+	+	+	+	+	+	+	+	+	+	+
NEOPLASTIC NODULE																									
MONOCYTIC LEUKEMIA																									
BILE DUCT	+	+	+	+	+	+	+	+	+	+	+	+	+	+	+	+	+	+	+	+	+	+	+	+	+
GALLBLADDER & COMMON BILE DUCT	N	N	N	N	N	N	N	N	N	N	N	N	N	N	N	N	N	N	N	N	N	N	N	N	N
PANCREAS	+	+	+	+	+	+	+	+	+	+	+	+	+	+	+	+	+	+	+	+	+	+	+	+	+
ADENOCARCINOMA, NOS																									
ACINAR-CELL ADENOMA																									
ACINAR-CELL CARCINOMA																									
ESOPHAGUS	+	+	+	+	+	+	+	+	+	+	+	+	+	+	+	+	+	+	+	+	+	+	+	+	+
STOMACH	+	+	+	+	+	+	+	+	+	+	+	+	+	+	+	+	+	+	+	+	+	+	+	+	+
SMALL INTESTINE	+	+	+	+	+	+	+	+	+	+	+	+	+	+	+	+	+	+	+	+	+	+	+	+	+
LEIOMYOSARCOMA																									
LARGE INTESTINE	+	+	+	+	+	+	+	+	+	+	+	+	+	+	+	+	+	+	+	+	+	+	+	+	+
ADENOMATOUS POLYP, NOS																									
URINARY SYSTEM																									
KIDNEY	+	+	+	+	+	+	+	+	+	+	+	+	+	+	+	+	+	+	+	+	+	+	+	+	+
URINARY BLADDER	+	+	+	+	+	+	+	+	+	+	+	+	+	+	+	+	+	+	+	+	+	+	+	+	+

HWBUI0001593

TABLE A4. INDIVIDUAL ANIMAL TUMOR PATHOLOGY OF FEMALE RATS IN THE LIFETIME FEED STUDY OF SHORT-RANGE CHRYSOTILE ASBESTOS: UNTREATED CONTROL (Continued)

ANIMAL NUMBER	68771	68881	68891	69011	69112	69123	69134	69145	69156	69167	69178	69189	69196	70011	70022	70033	70044	70055	70066	70077	70088	70099	71100	71116
WEEKS ON STUDY	110	142	110	136	95	115	145	122	107	118	116	116	96	129	145	123	130	94	95	141	145	143	95	140
ENDOCRINE SYSTEM																								
PITUITARY	+	+	+	+	+	+	+	+	+	+	+	+	+	+	+	+	+	+	+	+	+	+	+	+
CARCINOMA,NOS	X	X												X										
ADENOMA, NOS						X	X	X			X	X			X	X	X			X	X	X	X	X
ADRENAL	+	+	+	+	+	+	+	+	+	+	+	+	+	+	+	+	+	+	+	+	+	+	+	+
CORTICAL ADENOMA																								
PHEOCHROMOCYTOMA								X	X													X		
THYROID	+	+	+	+	+	+	+	+	+	+	+	+	+	+	+	+	+	+	+	+	+	+	+	+
FOLLICULAR-CELL ADENOMA																					X			
FOLLICULAR-CELL CARCINOMA																								
C-CELL ADENOMA	X	X	X																			X		
C-CELL CARCINOMA				X																				
PARATHYROID	+	+	+	+	+	+	+	+	+	+	+	+	+	+	+	+	+	+	+	+	+	+	+	+
PANCREATIC ISLETS	+	+	+	+	+	+	+	+	+	+	+	+	+	+	+	+	+	+	+	+	+	+	+	+
ISLET-CELL ADENOMA																								
ISLET-CELL CARCINOMA														X										
REPRODUCTIVE SYSTEM																								
MAMMARY GLAND	+	+	+	+	+	+	+	+	+	+	+	+	+	+	+	+	+	+	+	+	+	+	+	+
CARCINOMA,NOS																				X				
ADENOMA, NOS		X																						
ADENOCARCINOMA, NOS		X																				X		
PAPILLARY CYSTADENOMA, NOS																								
PAPILLARY CYSTADENOCARCINOMA,NOS														X										
FIBROSARCOMA																								
FIBROADENOMA		X			X									X	X	X		X		X	X	X		X
PREPUTIAL/CLITORAL GLAND	N	N	N	N	N	N	N	N	N	N	N	N	N	N	N	N	N	N	N	N	N	N	N	N
CARCINOMA,NOS																				X				
SQUAMOUS CELL CARCINOMA																								
ADENOMA, NOS																								
UTERUS	+	+	+	+	+	+	+	+	+	+	+	+	+	+	+	+	+	+	+	+	+	+	+	+
CARCINOMA-IN-SITU, NOS																								
CARCINOMA,NOS														X										
ENDOMETRIAL STROMAL POLYP					X			X						X				X						X
CARCINOSARCOMA																								
OVARY	+	+	+	+	+	+	+	+	+	+	+	+	+	+	+	+	+	+	+	+	+	+	+	+
THECOMA																								
GRANULOSA-CELL TUMOR																						X		
NERVOUS SYSTEM																								
BRAIN	+	+	+	+	+	+	+	+	+	+	+	+	+	+	+	+	+	+	+	+	+	+	+	+
CARCINOMA, NOS, INVASIVE	Xa	X																						
CARCINOMA, NOS, METASTATIC																								
SPECIAL SENSE ORGANS																								
ZYMBAL'S GLAND	+	+	+	+	+	+	+	+	+	+	+	+	+	+	+	+	+	+	+	+	+	+	+	+
SQUAMOUS CELL CARCINOMA		X																						
MUSCULOSKELETAL SYSTEM																								
BONE	N	+	N	+	N	N	N	N	N	N	N	N	N	N	N	N	N	N	N	N	N	N	N	N
OSTEOSARCOMA																								
ALL OTHER SYSTEMS																								
MULTIPLE ORGANS NOS	N	N	N	N	N	N	N	N	N	N	N	N	N	N	N	N	N	N	N	N	N	N	N	N
CARCINOMA, NOS, INVASIVE																								
SQUAMOUS CELL CARCINOMA, INVASIVE																								
SARCOMA, NOS, INVASIVE																								
SARCOMA, NOS, METASTATIC																								
MALIG.LYMPHOMA, HISTIOCYTIC TYPE																								
MONOCYTIC LEUKEMIA												X	X	X			X			X	X			X
LEUKEMIA,MONONUCLEAR CELL		X																						
CHEEK,NOS																								
SQUAMOUS CELL CARCINOMA, INVASIVE		X																						

a: MULTIPLE OCCURENCE OF MORPHOLOGY

HWBUI0001594

TABLE A4. INDIVIDUAL ANIMAL TUMOR PATHOLOGY OF FEMALE RATS IN THE LIFETIME FEED STUDY OF SHORT-RANGE CHRYSOTILE ASBESTOS: UNTREATED CONTROL (Continued)

ANIMAL NUMBER	7 0 2	7 0 3	7 0 4	7 0 5	7 0 6	7 0 7	7 0 8	7 0 9	7 1 0	7 1 1	7 1 2	7 1 3	7 1 4	7 1 5	TOTAL TISSUES TUMORS
WEEKS ON STUDY	4 5	5 0	5 1	5 3	5 3	5 7	5 7	5 8	5 9	6 0	6 1	6 1	6 4	6 4	
INTEGUMENTARY SYSTEM															
SKIN	+	+	+	+	+	+	+	+	+	+	+	+	+	+	88M
SQUAMOUS CELL PAPILLOMA															1
SQUAMOUS CELL CARCINOMA															1
BASAL-CELL CARCINOMA															1
KERATOACANTHOMA															2
SUBCUTANEOUS TISSUE	+	+	+	+	+	+	+	+	+	+	+	+	+	+	88M
SQUAMOUS CELL CARCINOMA, INVASIVE															1
FIBROMA			X												1
FIBROSARCOMA															2
LIPOMA															1
LIPOSARCOMA															1
RESPIRATORY SYSTEM															
LUNGS AND BRONCHI	+	+	+	+	+	+	+	+	+	+	+	+	+	+	87
SQUAMOUS CELL CARCINOMA, METASTAT															1
ALVEOLAR/BRONCHIOLAR CARCINOMA															1
FOLLICULAR-CELL CARCINOMA, METAST															1
TRACHEA	+	+	+	+	+	+	+	+	+	+	+	+	+	+	87
NASAL CAVITY	M	M	M	M	M	M	M	M	M	M	M	M	M	M	88M
SQUAMOUS CELL CARCINOMA															1
HEMATOPOIETIC SYSTEM															
BONE MARROW	+	+	+	+	+	+	+	+	+	+	+	+	+	+	84
SPLEEN	+	+	+	+	+	+	+	+	+	+	+	+	+	+	87
ANGIOMA															1
LYMPH NODES	+	+	+	+	+	+	+	+	+	+	+	+	+	+	87
THYMUS	+	+	+	+	+	+	+	-	+	+	-	+	+		67
CIRCULATORY SYSTEM															
HEART	+	+	+	+	+	+	+	+	+	+	+	+	+	+	87
SARCOMA, NOS															1
DIGESTIVE SYSTEM															
ORAL CAVITY	M	M	M	M	M	M	M	M	M	M	M	M	M	M	88M
SQUAMOUS CELL CARCINOMA, INVASIVE															1
SALIVARY GLAND	+	+	+	+	+	+	+	+	+	+	+	+	+	+	87
LIVER	+	+	+	+	+	+	+	+	+	+	+	+	+	+	87
NEOPLASTIC NODULE															3
MONOCYTIC LEUKEMIA															1
BILE DUCT	+	+	+	+	+	+	+	+	+	+	+	+	+	+	87
GALLBLADDER & COMMON BILE DUCT	M	M	M	M	M	M	M	M	M	M	M	M	M	M	88M
PANCREAS	+	+	+	+	+	+	+	+	+	+	+	+	+	+	86
ADENOCARCINOMA, NOS									X						1
ACINAR-CELL ADENOMA															1
ACINAR-CELL CARCINOMA							X								1
ESOPHAGUS	+	+	+	+	+	+	+	+	+	+	+	+	+	+	87
STOMACH	+	+	+	+	+	+	+	+	+	+	+	+	+	+	87
SMALL INTESTINE	+	+	+	+	+	+	+	+	+	+	+	+	+	+	87
LEIOMYOSARCOMA															1
LARGE INTESTINE	+	+	+	+	+	+	+	+	+	+	+	+	+	+	87
ADENOMATOUS POLYP, NOS															1
URINARY SYSTEM															
KIDNEY	+	+	+	+	+	+	+	+	+	+	+	+	+	+	87
URINARY BLADDER	+	+	+	+	+	+	+	+	+	+	+	+	+	+	87

HWBUI0001595

TABLE A4. INDIVIDUAL ANIMAL TUMOR PATHOLOGY OF FEMALE RATS IN THE LIFETIME FEED STUDY OF SHORT-RANGE CHRYSOTILE ASBESTOS: UNTREATED CONTROL (Continued)

ANIMAL NUMBER	71271	71311	71491	71511	71611	71711	71811	71911	72011	72111	72211	72311	72411	TOTAL TISSUES TUMORS
WEEKS ON STUDY	104	111	118	133	135	142	145	149	153	155	161	164	170	
ENDOCRINE SYSTEM														
PITUITARY	+	+	+	+	+	+	+	+	+	+	+	+	+	87
CARCINOMA,NOS								X		X	X			6
ADENOMA, NOS	X						X		X					39
ADRENAL	+	+	+	+	+	+	+	+	+	+	+	+	+	87
CORTICAL ADENOMA														2
PHEOCHROMOCYTOMA	X					X						X		9
THYROID	+	+	+	+	+	+	+	+	+	+	+	+	+	87
FOLLICULAR-CELL ADENOMA							X							1
FOLLICULAR-CELL CARCINOMA	X													4
C-CELL ADENOMA			X										X	11
C-CELL CARCINOMA							X							7
PARATHYROID	+	+	+	+	+	+	+	+	+	+	+	+	+	85
PANCREATIC ISLETS	+	+	+	+	+	+	+	+	+	+	+	+	+	86
ISLET-CELL ADENOMA														2
ISLET-CELL CARCINOMA														2
REPRODUCTIVE SYSTEM														
MAMMARY GLAND	+	+	+	+	+	+	+	+	+	+	+	+	+	88M
CARCINOMA,NOS														1
ADENOMA, NOS														2
ADENOCARCINOMA, NOS														6
PAPILLARY CYSTADENOMA, NOS														1
PAPILLARY CYSTADENOCARCINOMA,NOS														1
FIBROSARCOMA														1
FIBROADENOMA	X	X	X	X	X	X	X		X				X	49
PREPUTIAL/CLITORAL GLAND	M	M	M	M	M	M	M	M	M	M	M	M	M	88M
CARCINOMA,NOS														1
SQUAMOUS CELL CARCINOMA														1
ADENOMA, NOS														1
UTERUS	+	+	+	+	+	+	+	+	+	+	+	+	+	87
CARCINOMA-IN-SITU, NOS														1
CARCINOMA,NOS														2
ENDOMETRIAL STROMAL POLYP					X							X	X	15
CARCINOSARCOMA						X								1
OVARY	+	+	+	+	+	+	+	+	+	+	+	+	+	87
THECOMA														2
GRANULOSA-CELL TUMOR	X													1
NERVOUS SYSTEM														
BRAIN	+	+	+	+	+	+	+	+	+	+	+	+	+	87
CARCINOMA, NOS, INVASIVE										X	X			4
CARCINOMA, NOS, METASTATIC														1
SPECIAL SENSE ORGANS														
ZYMBAL'S GLAND	+	+	+	+	+	+	+	+	+	+	+	M	+	88M
SQUAMOUS CELL CARCINOMA														3
MUSCULOSKELETAL SYSTEM														
BONE	M	M	M	M	M	M	M	M	M	M	M	M	M	88M
OSTEOSARCOMA														1
ALL OTHER SYSTEMS														
MULTIPLE ORGANS NOS	M	M	M	M	M	M	M	M	M	M	M	M	M	88M
CARCINOMA, NOS, INVASIVE														1
SQUAMOUS CELL CARCINOMA, INVASIVE														2
SARCOMA, NOS, INVASIVE														1
SARCOMA, NOS, METASTATIC														1
MALIG.LYMPHOMA, HISTIOCYTIC TYPE														1
MONOCYTIC LEUKEMIA					X		X				X		X	26
LEUKEMIA,MONONUCLEAR CELL														1
CHEEK, NOS														
SQUAMOUS CELL CARCINOMA, INVASIVE														1

M ANIMALS NECROPSIED

HWBUI0001596

TABLE A4. INDIVIDUAL ANIMAL TUMOR PATHOLOGY OF FEMALE RATS IN THE LIFETIME FEED STUDY OF SHORT-RANGE CHRYSOTILE ASBESTOS: SHORT-RANGE

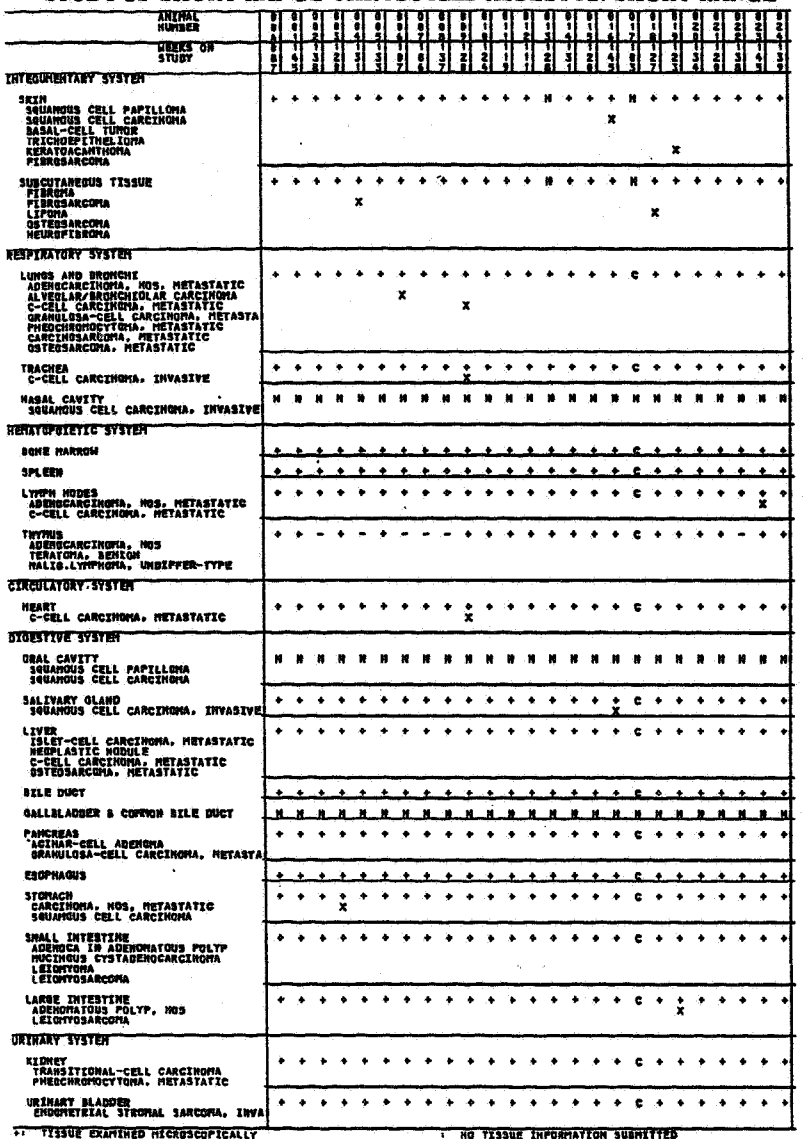

HWBUI0001597

TABLE A4. INDIVIDUAL ANIMAL TUMOR PATHOLOGY OF FEMALE RATS IN THE LIFETIME FEED STUDY OF SHORT-RANGE CHRYSOTILE ASBESTOS: SHORT-RANGE (Continued)

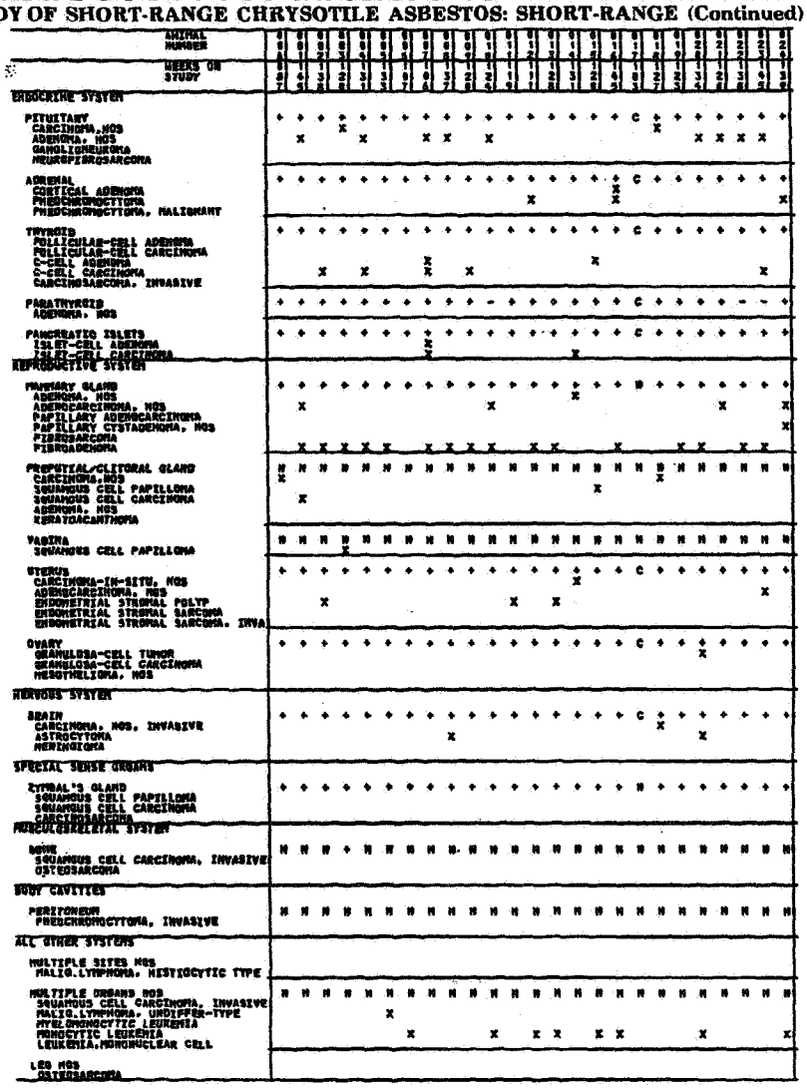

HWBUI0001598

TABLE A4. INDIVIDUAL ANIMAL TUMOR PATHOLOGY OF FEMALE RATS IN THE LIFETIME FEED STUDY OF SHORT-RANGE CHRYSOTILE ASBESTOS: SHORT-RANGE (Continued)



HWBUI0001599

TABLE A4. INDIVIDUAL ANIMAL TUMOR PATHOLOGY OF FEMALE RATS IN THE LIFETIME FEED STUDY OF SHORT-RANGE CHRYSOTILE ASBESTOS: SHORT-RANGE (Continued)



HWBUI0001600

TABLE A4. INDIVIDUAL ANIMAL TUMOR PATHOLOGY OF FEMALE RATS IN THE LIFETIME FEED STUDY OF SHORT-RANGE CHRYSOTILE ASBESTOS: SHORT-RANGE (Continued)

| ANIMAL NUMBER | 0 0 0

TABLE A4. INDIVIDUAL ANIMAL TUMOR PATHOLOGY OF FEMALE RATS IN THE LIFETIME FEED STUDY OF SHORT-RANGE CHRYSOTILE ASBESTOS: SHORT-RANGE (Continued)



HWBUI0001602

TABLE A4. INDIVIDUAL ANIMAL TUMOR PATHOLOGY OF FEMALE RATS IN THE LIFETIME FEED STUDY OF SHORT-RANGE CHRYSOTILE ASBESTOS: SHORT-RANGE (Continued)



HWBUI0001603

TABLE A4. INDIVIDUAL ANIMAL TUMOR PATHOLOGY OF FEMALE RATS IN THE LIFETIME FEED STUDY OF SHORT-RANGE CHRYSOTILE ASBESTOS: SHORT-RANGE (Continued)



HWBUI0001604

TABLE A4. INDIVIDUAL ANIMAL TUMOR PATHOLOGY OF FEMALE RATS IN THE LIFETIME FEED STUDY OF SHORT-RANGE CHRYSOTILE ASBESTOS: SHORT-RANGE (Continued)

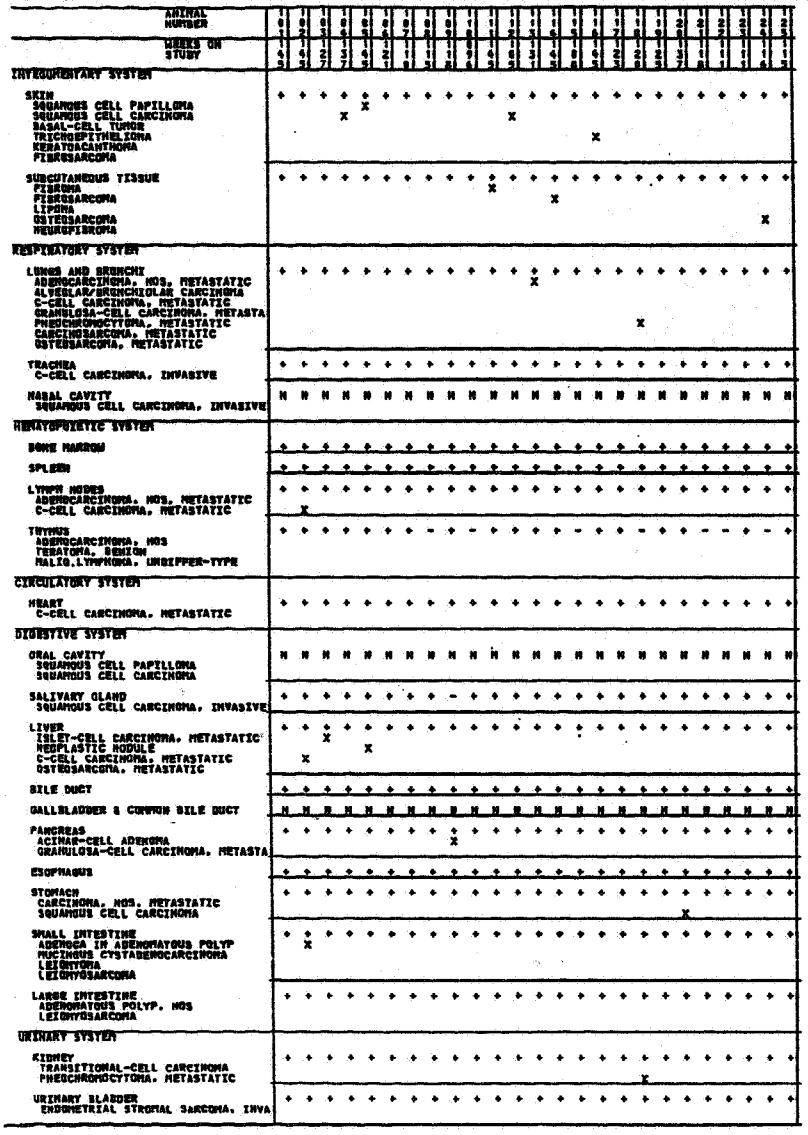

HWBUI0001605

TABLE A4. INDIVIDUAL ANIMAL TUMOR PATHOLOGY OF FEMALE RATS IN THE LIFETIME FEED STUDY OF SHORT-RANGE CHRYSOTILE ASBESTOS: SHORT-RANGE (Continued)



HWBUI0001606

TABLE A4. INDIVIDUAL ANIMAL TUMOR PATHOLOGY OF FEMALE RATS IN THE LIFETIME FEED STUDY OF SHORT-RANGE CHRYSOTILE ASBESTOS: SHORT-RANGE (Continued)

ANIMAL NUMBER	1 2 2 2 2 3 3 3 3 3 3 3 3 3 3 3 3 4 4 4 4 4 4 4 4 4 4
WEEKS ON STUDY	0 3 6 3 6 6 7 3 6 6 2 6 2 3 6 6 3 1 2 3 1 1 1 4 5 6 8
	6 1 9 7 7 3 1 9 1 9 1 6 2 8 4 1 1 1 1 1 8 3 7 5 8 4
INTEGUMENTARY SYSTEM	
SKIN	+ + + + + + + + + + + + + + N + + + + + + + + + + +
SQUAMOUS CELL PAPILLOMA	
SQUAMOUS CELL CARCINOMA	X
BASAL-CELL TUMOR	
TRICHOEPITHELIOMA	
KERATOACANTHOMA	
FIBROSARCOMA	
SUBCUTANEOUS TISSUE	+ + + + + + + + + + + + + + N + + + + + + + + + + +
FIBROMA	
FIBROSARCOMA	
LIPOMA	
OSTEOSARCOMA	
NEUROFIBROMA	
RESPIRATORY SYSTEM	
LUNGS AND BRONCHI	+ + + + + + + + + + + + + + C + + + + + + + + + + +
ADENOCARCINOMA, NOS, METASTATIC	
ALVEOLAR/BRONCHIOLAR CARCINOMA	
C-CELL CARCINOMA, METASTATIC	
GRANULOSA-CELL CARCINOMA, METASTA	X
PHEOCHROMOCYTOMA, METASTATIC	
CARCINOSARCOMA, METASTATIC	
OSTEOSARCOMA, METASTATIC	
TRACHEA	+ + + + + + + + + + + + + + C + + + + + + + + + + +
C-CELL CARCINOMA, INVASIVE	
NASAL CAVITY	M M M M M M M M M M M M M M M M M M M M M M M M M M
SQUAMOUS CELL CARCINOMA, INVASIVE	
HEMATOPOIETIC SYSTEM	
BONE MARROW	+ + + + + + - + + + + + + + C + + + + - + + + + + +
SPLEEN	+ + + + + + + + + + + + + + C + + + + + + + + + + +
LYMPH NODES	+ + + + + + + + + + + + + + C + + + + + + + + + + +
ADENOCARCINOMA, NOS, METASTATIC	
C-CELL CARCINOMA, METASTATIC	
THYMUS	+ + - + + + + + + + + - + + C + + + + + + + + + + +
ADENOCARCINOMA, NOS	
TERATOMA, BENIGN	
MALIG.LYMPHOMA, UNDIFFER-TYPE	
CIRCULATORY SYSTEM	
HEART	+ + + + + + + + + + + + + + C + + + + + + + + + + +
C-CELL CARCINOMA, METASTATIC	
DIGESTIVE SYSTEM	
ORAL CAVITY	M M M M M M M M M M M M M M M M M M M M M M M M M M
SQUAMOUS CELL PAPILLOMA	X
SQUAMOUS CELL CARCINOMA	
SALIVARY GLAND	+ + + + + + + + + + + + + + C + + + + + + + + + + +
SQUAMOUS CELL CARCINOMA, INVASIVE	
LIVER	+ + + + + + + + + + + + + + C + + + + + + + + + + +
ISLET-CELL CARCINOMA, METASTATIC	X
NEOPLASTIC NODULE	
C-CELL CARCINOMA, METASTATIC	
OSTEOSARCOMA, METASTATIC	
BILE DUCT	+ + + + + + + + + + + + + + C + + + + + + + + + + +
GALLBLADDER & COMMON BILE DUCT	M M M M M M M M M M M M M M M M M M M M M M M M M M
PANCREAS	+ + + + + + + + + + + + + + C + + + + + + + + + + +
ACINAR-CELL ADENOMA	
GRANULOSA-CELL CARCINOMA, METASTA	
ESOPHAGUS	+ + + + + + + + + + + + + + C + + + + + + + + + + +
STOMACH	+ + + + + + + + + + + + + + C + + + + + + + + + + +
CARCINOMA, NOS, METASTATIC	
SQUAMOUS CELL CARCINOMA	
SMALL INTESTINE	+ + + + + + + + + + + + + + C + + + + + + + + + + +
ADENOCA IN ADENOMATOUS POLYP	
MUCINOUS CYSTADENOCARCINOMA	
LEIOMYOMA	
LEIOMYOSARCOMA	
LARGE INTESTINE	+ + + + + + + + + + + + + + C + + + + + + + + + + +
ADENOMATOUS POLYP, NOS	X
LEIOMYOSARCOMA	
URINARY SYSTEM	
KIDNEY	+ + + + + + + + + + + + + + C + + + + + + + + + + +
TRANSITIONAL-CELL CARCINOMA	
PHEOCHROMOCYTOMA, METASTATIC	
URINARY BLADDER	+ + + + + + + + + + + + + + C + + + + + + + + + + +
ENDOMETRIAL STROMAL SARCOMA, INVA	

HWBUI0001607

TABLE A4. INDIVIDUAL ANIMAL TUMOR PATHOLOGY OF FEMALE RATS IN THE LIFETIME FEED STUDY OF SHORT-RANGE CHRYSOTILE ASBESTOS: SHORT-RANGE (Continued)



ANIMAL NUMBER	1 2 1 0	1 2 1 1	1 2 1 2	1 2 1 3	1 2 1 4	1 2 1 5	1 2 1 6	1 2 1 7	1 2 1 8	1 2 1 9	1 2 2 0	1 2 2 1	1 2 2 2	1 2 2 3	1 2 2 4	1 2 2 5	1 2 2 6	1 2 2 7	1 2 2 8	1 2 2 9	1 2 3 0	1 2 3 1	1 2 3 2	1 2 3 3	1 2 3 4	1 2 3 5
WEEKS ON STUDY	1 5 0	1 5 0	1 5 0	1 5 1	1 5 1	1 5 1	1 5 1	1 5 1	1 5 1	1 5 1	1 5 2	1 5 2	1 5 2	1 5 2	1 5 2	1 5 2	1 5 2	1 5 2	1 5 2	1 5 2	1 5 3	1 5 3	1 5 3	1 5 3	1 5 3	1 5 4
ENDOCRINE SYSTEM																										
PITUITARY	+	+	+	+	+	+	+	+	+	+	+	+	+	+	+	C	+	+	+	+	+	+	+	+	+	+
CARCINOMA, NOS																	X									
ADENOMA, NOS					X			X	X		X		X					X		X				X	X	
GANGLIONEUROMA																										
NEUROFIBROSARCOMA																										X
ADRENAL	+	+	+	+	+	+	+	+	+	+	+	+	+	+	+	C	+	+	+	+	+	+	+	+	+	+
CORTICAL ADENOMA																					X					
PHEOCHROMOCYTOMA	X											X						X		X				X		X
PHEOCHROMOCYTOMA, MALIGNANT																										
THYROID	+	+	+	+	+	+	+	+	+	+	+	+	+	+	+	C	+	+	+	+	+	+	+	+	+	+
FOLLICULAR-CELL ADENOMA																										
FOLLICULAR-CELL CARCINOMA	X								X																	X
C-CELL ADENOMA																										
C-CELL CARCINOMA																										
CARCINOSARCOMA, INVASIVE																										
PARATHYROID	+	+	-	+	+	+	+	-	+	+	+	+	+	+	C	+	+	+	+	+	+	+	+	-	+	
ADENOMA, NOS																										
PANCREATIC ISLETS	+	+	+	+	+	+	+	+	+	+	+	+	+	+	C	+	+	+	+	+	+	+	+	+	+	
ISLET-CELL ADENOMA																										
ISLET-CELL CARCINOMA																										
REPRODUCTIVE SYSTEM																										
MAMMARY GLAND	+	+	+	+	+	+	+	+	+	+	+	+	+	+	B	+	+	+	+	+	+	+	+	+	+	+
ADENOMA, NOS		X						X			X															
ADENOCARCINOMA, NOS							X																			
PAPILLARY ADENOCARCINOMA																										
PAPILLARY CYSTADENOMA, NOS																										
FIBROSARCOMA																										
FIBROADENOMA	X		X	X	X		X			X		X	X				X	X	X		X	X	X	X	X	X
PREPUTIAL/CLITORAL GLAND	M	M	M	M	M	M	M	M	M	M	M	M	M	M	M	M	M	M	M	M	M	M	M	M	M	M
CARCINOMA, NOS																										
SQUAMOUS CELL PAPILLOMA			X																							
SQUAMOUS CELL CARCINOMA																										
ADENOMA, NOS																				X						
KERATOACANTHOMA																										
VAGINA	M	M	M	M	M	M	M	M	M	M	M	M	M	M	M	M	M	M	M	M	M	M	M	M	M	M
SQUAMOUS CELL PAPILLOMA																										
UTERUS	+	+	+	+	+	+	+	+	+	+	+	+	+	+	C	+	+	+	+	+	+	+	+	+	+	+
CARCINOMA-IN-SITU, NOS																										
ADENOCARCINOMA, NOS		X																								
ENDOMETRIAL STROMAL POLYP																										
ENDOMETRIAL STROMAL SARCOMA																										
ENDOMETRIAL STROMAL SARCOMA, INVA																										
OVARY	+	+	+	+	+	+	+	+	+	+	+	+	+	+	C	+	+	+	+	+	+	+	+	+	+	+
GRANULOSA-CELL TUMOR																										
GRANULOSA-CELL CARCINOMA						X																				
MESOTHELIOMA, NOS																										
NERVOUS SYSTEM																										
BRAIN	+	+	+	+	+	+	+	+	+	+	+	+	+	+	C	+	+	+	+	+	+	+	+	+	+	+
CARCINOMA, NOS, INVASIVE																X										
ASTROCYTOMA																										
MENINGIOMA																										
SPECIAL SENSE ORGANS																										
ZYMBAL'S GLAND	+	+	+	+	+	+	M	+	+	+	+	+	+	+	M	+	+	M	+	+	+	+	+	+	+	+
SQUAMOUS CELL PAPILLOMA								X																		
SQUAMOUS CELL CARCINOMA																										
CARCINOSARCOMA																										
MUSCULOSKELETAL SYSTEM																										
BONE	M	M	M	M	M	M	M	M	M	M	M	M	M	M	M	M	M	M	M	M	M	M	M	M	M	M
SQUAMOUS CELL CARCINOMA, INVASIVE																										
OSTEOSARCOMA																										
BODY CAVITIES																										
PERITONEUM	M	M	M	M	M	M	M	M	M	M	M	M	M	M	M	M	M	M	M	M	M	M	M	M	M	M
PHEOCHROMOCYTOMA, INVASIVE																										
ALL OTHER SYSTEMS																										
MULTIPLE SITES NOS																										
MALIG.LYMPHOMA, HISTIOCYTIC TYPE																										
MULTIPLE ORGANS NOS	M	M	M	M	M	M	M	M	M	M	M	M	M	M	M	M	M	M	M	M	M	M	M	M	M	M
SQUAMOUS CELL CARCINOMA, INVASIVE																										
MALIG.LYMPHOMA, UNDIFFER-TYPE																										
MYELOMONOCYTIC LEUKEMIA																										
MONOCYTIC LEUKEMIA	X	X	X		X		X				X					X		X	X	X	X			X	X	
LEUKEMIA,MONONUCLEAR CELL																										
LEG NOS																										
OSTEOSARCOMA																										

HWBUI0001608

TABLE A4. INDIVIDUAL ANIMAL TUMOR PATHOLOGY OF FEMALE RATS IN THE LIFETIME FEED STUDY OF SHORT-RANGE CHRYSOTILE ASBESTOS: SHORT-RANGE (Continued)

| ANIMAL NUMBER | 1 1 1

TABLE A4. INDIVIDUAL ANIMAL TUMOR PATHOLOGY OF FEMALE RATS IN THE LIFETIME FEED STUDY OF SHORT-RANGE CHRYSOTILE ASBESTOS: SHORT-RANGE (Continued)



HWBUI0001610

TABLE A4. INDIVIDUAL ANIMAL TUMOR PATHOLOGY OF FEMALE RATS IN THE LIFETIME FEED STUDY OF SHORT-RANGE CHRYSOTILE ASBESTOS: SHORT-RANGE (Continued)

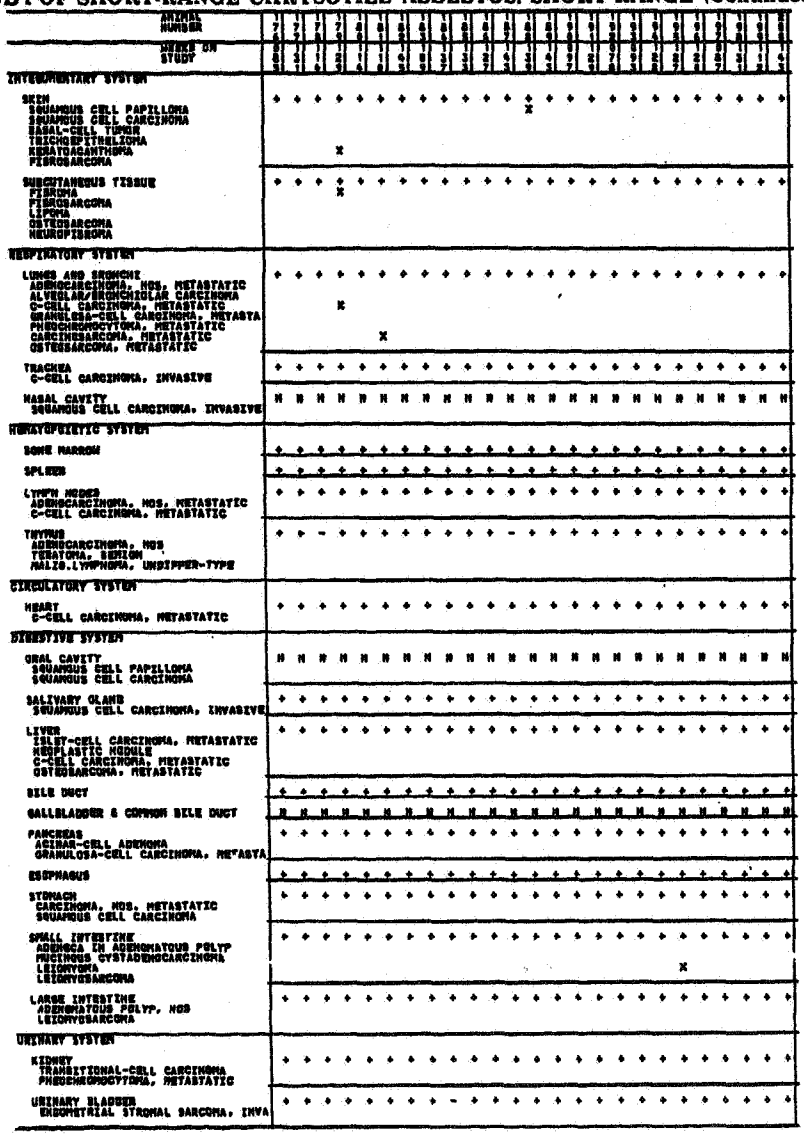

HWBUI0001611

TABLE A4. INDIVIDUAL ANIMAL TUMOR PATHOLOGY OF FEMALE RATS IN THE LIFETIME FEED STUDY OF SHORT-RANGE CHRYSOTILE ASBESTOS: SHORT-RANGE (Continued)



HWBUI0001612

TABLE A4. INDIVIDUAL ANIMAL TUMOR PATHOLOGY OF FEMALE RATS IN THE LIFETIME FEED STUDY OF SHORT-RANGE CHRYSOTILE ASBESTOS: SHORT-RANGE (Continued)

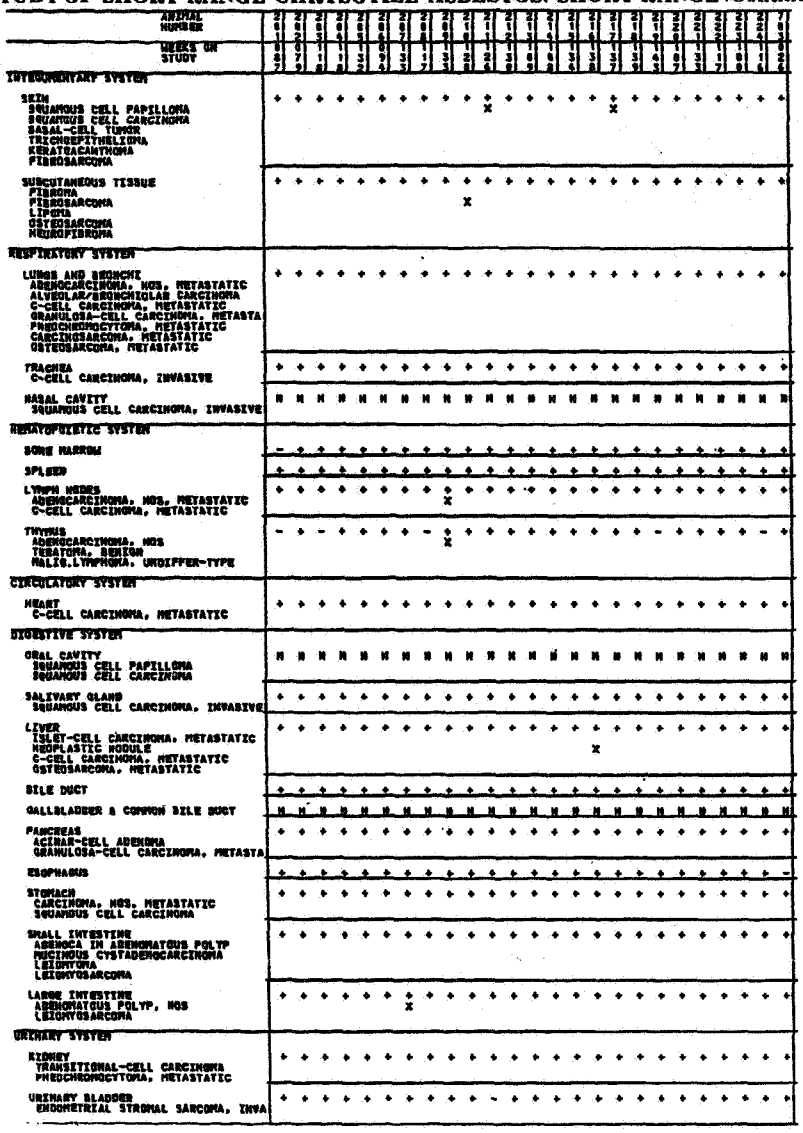

HWBUI0001613

TABLE A4. INDIVIDUAL ANIMAL TUMOR PATHOLOGY OF FEMALE RATS IN THE LIFETIME FEED STUDY OF SHORT-RANGE CHRYSOTILE ASBESTOS: SHORT-RANGE (Continued)



HWBUI0001614

TABLE A4. INDIVIDUAL ANIMAL TUMOR PATHOLOGY OF FEMALE RATS IN THE LIFETIME FEED STUDY OF SHORT-RANGE CHRYSOTILE ASBESTOS: SHORT-RANGE (Continued)

ANIMAL NUMBER / WEEKS ON STUDY	0 1 1	0 1 2	0 1 4	0 1 4	0 1 4	0 1 4	0 1 4	0 1 4	0 1 4	0 1 4	0 1 4	0 1 4	0 1 4	0 1 4	0 1 4	0 1 4	0 1 4	0 1 4	0 1 4	0 1 4	0 1 4	0 1 4	0 1 4	0 1 4	0 1 4	0 1 4	0 1 4	0 1 4	0 1 4	0 1 4	TOTAL TISSUES TUMORS
INTEGUMENTARY SYSTEM																															
SKIN	+	+	+	+	+	+	+	+	+	+	+	+	+	+	+	+	M	+	+	+	+	+	+	+	+	+	+	+	+	+	250M
SQUAMOUS CELL PAPILLOMA						X																									4
SQUAMOUS CELL CARCINOMA																															5
BASAL-CELL TUMOR																															1
TRICHOEPITHELIOMA																															1
KERATOACANTHOMA																															2
FIBROSARCOMA				X																											1
SUBCUTANEOUS TISSUE	+	+	+	+	+	+	+	+	+	+	+	+	+	+	+	+	M	+	+	+	+	+	+	+	+	+	+	+	+	+	250M
FIBROMA																															3
FIBROSARCOMA																															4
LIPOMA																															1
OSTEOSARCOMA																															1
NEUROFIBROMA		X																													1
RESPIRATORY SYSTEM																															
LUNGS AND BRONCHI	+	+	+	+	+	+	+	+	+	+	+	+	+	+	+	+	C	+	+	+	+	+	+	+	+	+	+	+	+	+	245
ADENOCARCINOMA, NOS, METASTATIC																															2
ALVEOLAR/BRONCHIOLAR CARCINOMA																															1
C-CELL CARCINOMA, METASTATIC																															3
GRANULOSA-CELL CARCINOMA, METASTA																															1
PHEOCHROMOCYTOMA, METASTATIC																															1
CARCINOSARCOMA, METASTATIC																															1
OSTEOSARCOMA, METASTATIC																															1
TRACHEA	+	+	+	+	+	+	+	+	+	+	+	+	+	+	+	+	C	+	+	+	+	+	+	+	+	+	+	+	+	+	245
C-CELL CARCINOMA, INVASIVE																															1
NASAL CAVITY	M	M	M	M	M	M	M	M	M	M	M	M	M	M	M	M	M	M	M	M	M	M	M	M	M	M	M	M	M	M	238M
SQUAMOUS CELL CARCINOMA, INVASIVE																															1
HEMATOPOIETIC SYSTEM																															
BONE MARROW	+	+	+	+	+	+	+	+	+	+	+	+	+	+	+	+	C	+	+	+	+	+	+	+	+	+	+	+	+	+	241
SPLEEN	+	+	+	+	+	+	+	+	+	+	+	+	+	+	+	+	C	+	+	+	+	+	+	+	+	+	+	+	+	+	245
LYMPH NODES	+	+	+	+	+	+	+	+	+	+	+	+	+	+	+	+	C	+	+	+	+	+	+	+	+	+	+	+	+	+	245
ADENOCARCINOMA, NOS, METASTATIC																															2
C-CELL CARCINOMA, METASTATIC																															2
THYMUS	-	+	+	-	+	+	-	+	-	+	+	+	+	+	C	-	-	+	-	+	+	+	+	+	+	+	+	+	+	+	198
ADENOCARCINOMA, NOS					X																										2
TERATOMA, BENIGN																															1
MALIG.LYMPHOMA, UNDIFFER-TYPE																															1
CIRCULATORY SYSTEM																															
HEART	+	+	+	+	+	+	+	+	+	+	+	+	+	+	+	+	C	+	+	+	+	+	+	+	+	+	+	+	+	+	245
C-CELL CARCINOMA, METASTATIC																															1
DIGESTIVE SYSTEM																															
ORAL CAVITY	M	M	M	M	M	M	M	M	M	M	M	M	M	M	M	M	M	M	M	M	M	M	M	M	M	M	M	M	M	M	250M
SQUAMOUS CELL PAPILLOMA																															1
SQUAMOUS CELL CARCINOMA																															2
SALIVARY GLAND	+	+	+	+	+	+	+	+	+	+	+	+	+	+	+	+	C	+	+	+	+	+	+	+	+	+	+	+	+	+	243
SQUAMOUS CELL CARCINOMA, INVASIVE																															1
LIVER	+	+	+	+	+	+	+	+	+	+	+	+	+	+	+	+	C	+	+	-	+	+	+	+	+	+	+	+	+	+	244
ISLET-CELL CARCINOMA, METASTATIC																															1
NEOPLASTIC NODULE																				X											5
C-CELL CARCINOMA, METASTATIC																															1
OSTEOSARCOMA, METASTATIC																															1
BILE DUCT	+	+	+	+	+	+	+	+	+	+	+	+	+	+	+	+	C	+	+	-	+	+	+	+	+	+	+	+	+	+	244
GALLBLADDER & COMMON BILE DUCT	M	M	M	M	M	M	M	M	M	M	M	M	M	M	M	M	M	M	M	M	M	M	M	M	M	M	M	M	M	M	238M
PANCREAS	+	+	+	+	+	+	+	+	+	+	+	+	+	+	+	+	C	+	+	+	+	+	+	+	+	+	+	+	+	+	245
ACINAR-CELL ADENOMA																															1
GRANULOSA-CELL CARCINOMA, METASTA																															1
ESOPHAGUS	+	+	+	+	+	+	+	+	+	+	+	+	+	+	+	+	C	+	+	+	+	+	+	+	+	+	+	+	+	+	244
STOMACH	+	+	+	+	+	+	+	+	+	+	+	+	+	+	+	+	C	+	+	+	+	+	+	+	+	+	+	+	+	+	245
CARCINOMA, NOS, METASTATIC																															1
SQUAMOUS CELL CARCINOMA																															1
SMALL INTESTINE	+	+	+	+	+	+	+	+	+	+	+	+	+	+	+	+	C	+	+	-	+	+	+	+	+	+	+	+	+	+	244
ADENOCA IN ADENOMATOUS POLYP																															1
MUCINOUS CYSTADENOCARCINOMA																															1
LEIOMYOMA																															1
LEIOMYOSARCOMA																												X			2
LARGE INTESTINE	+	+	+	+	+	+	+	+	+	+	+	+	+	+	+	+	C	+	+	-	+	+	+	+	+	+	+	+	+	+	244
ADENOMATOUS POLYP, NOS																															3
LEIOMYOSARCOMA				X																											1
URINARY SYSTEM																															
KIDNEY	+	+	+	+	+	+	+	+	+	+	+	+	+	+	+	+	C	+	+	+	+	+	+	+	+	+	+	+	+	+	245
TRANSITIONAL-CELL CARCINOMA																															1
PHEOCHROMOCYTOMA, METASTATIC																															1
URINARY BLADDER	-	+	+	+	+	+	+	+	+	+	+	+	+	+	+	+	C	+	+	+	+	+	+	+	+	+	+	+	+	+	242
ENDOMETRIAL STROMAL SARCOMA, INVA																															1

HWBUI0001615

TABLE A4. INDIVIDUAL ANIMAL TUMOR PATHOLOGY OF FEMALE RATS IN THE LIFETIME FEED STUDY OF SHORT-RANGE CHRYSOTILE ASBESTOS: SHORT-RANGE (Continued)

| ANIMAL NUMBER | | |

HWBUI0001617

APPENDIX B

SUMMARY OF THE INCIDENCE OF NEOPLASMS IN RATS IN THE LIFETIME FEED STUDIES OF INTERMEDIATE-RANGE CHRYSOTILE ASBESTOS

HWBUI0001618

TABLE B1. SUMMARY OF THE INCIDENCE OF NEOPLASMS IN MALE RATS IN THE LIFETIME FEED STUDY OF INTERMEDIATE-RANGE (IR) CHRYSOTILE ASBESTOS

	CONTROL (UNTR)	DMH	IR	IR + DMH	IR/PW
ANIMALS INITIALLY IN STUDY	88	125	250	175	100
ANIMALS NECROPSIED	88	125	250	175	100
ANIMALS EXAMINED HISTOPATHOLOGICALLY	85	125	250	175	100
INTEGUMENTARY SYSTEM					
*HEAD	(88)	(125)	(250)	(175)	(100)
FIBROUS HISTIOCYTOMA, MALIGNANT					1 (1%)
*AXILLA	(88)	(125)	(250)	(175)	(100)
FIBROUS HISTIOCYTOMA, MALIGNANT				1 (1%)	
*SKIN	(88)	(125)	(250)	(175)	(100)
PAPILLOMA, NOS	5 (6%)				
SQUAMOUS CELL PAPILLOMA		2 (2%)	8 (3%)	4 (2%)	3 (3%)
SQUAMOUS CELL CARCINOMA		2 (2%)	3 (1%)	3 (2%)	1 (1%)
BASAL-CELL TUMOR			2 (1%)	2 (1%)	
BASAL-CELL CARCINOMA	2 (2%)		1 (0%)	1 (1%)	
TRICHOEPITHELIOMA		4 (3%)			
SEBACEOUS ADENOMA			2 (1%)	1 (1%)	
SEBACEOUS ADENOCARCINOMA			1 (0%)		
KERATOACANTHOMA	1 (1%)	6 (5%)	†19 (8%)	11 (6%)	7 (7%)
FIBROMA					1 (1%)
FIBROSARCOMA			1 (0%)		
NEUROFIBROSARCOMA				1 (1%)	
*SUBCUT TISSUE	(88)	(125)	(250)	(175)	(100)
CARCINOMA, NOS			1 (0%)		
SQUAMOUS CELL CARCINOMA	3 (3%)	1 (1%)	1 (0%)	1 (1%)	2 (2%)
BASAL-CELL TUMOR	1 (1%)				
BASAL-CELL CARCINOMA			1 (0%)	1 (1%)	
TRICHOEPITHELIOMA		1 (1%)		1 (1%)	1 (1%)
KERATOACANTHOMA					1 (1%)
SARCOMA, NOS	1 (1%)	2 (2%)	3 (1%)	2 (1%)	5 (5%)
FIBROMA	17 (19%)	13 (10%)	51 (20%)	15 (9%)	11 (11%)
FIBROSARCOMA	7 (8%)	3 (2%)	5 (2%)	2 (1%)	1 (1%)
FIBROUS HISTIOCYTOMA, MALIGNANT			2 (1%)	2 (1%)	
LIPOMA		1 (1%)	1 (0%)	2 (1%)	
RHABDOMYOSARCOMA				1 (1%)	1 (1%)
OSTEOSARCOMA			2 (1%)		1 (1%)
AMELOBLASTIC ODONTOMA				1 (1%)	
NEUROFIBROMA					1 (1%)
NEUROFIBROSARCOMA			1 (0%)		
RESPIRATORY SYSTEM					
*NASAL CAVITY	(88)	(125)	(250)	(175)	(100)
ADENOMA, NOS		1 (1%)			
*NASAL TURBINATE	(88)	(125)	(250)	(175)	(100)
SQUAMOUS CELL CARCINOMA, INVASIVE				1 (1%)	
ADENOMA, NOS		1 (1%)			
ADENOCARCINOMA, NOS				1 (1%)	
#TRACHEA	(85)	(124)	(250)	(175)	(99)
SQUAMOUS CELL CARCINOMA, INVASIVE				1 (1%)	
FIBROSARCOMA, INVASIVE	1 (1%)				

HWBUI0001619

TABLE B1. SUMMARY OF THE INCIDENCE OF NEOPLASMS IN MALE RATS IN THE LIFETIME FEED STUDY OF INTERMEDIATE-RANGE (IR) CHRYSOTILE ASBESTOS (Continued)

	CONTROL (UNTR)	DMH	IR	IR + DMH	IR/PW
RESPIRATORY SYSTEM (Continued)					
#LUNG	(85)	(125)	(250)	(175)	(99)
CARCINOMA, NOS, METASTATIC				1 (1%)	
SQUAMOUS CELL CARCINOMA	1 (1%)				1 (1%)
SQUAMOUS CELL CARCINOMA, METASTATIC			1 (0%)	1 (1%)	2 (2%)
ADENOCARCINOMA, NOS, METASTATIC		1 (1%)	2 (1%)		
HEPATOCELLULAR CARCINOMA, METASTATIC				1 (1%)	
ALVEOLAR/BRONCHIOLAR ADENOMA		1 (1%)	4 (2%)	1 (1%)	
ALVEOLAR/BRONCHIOLAR CARCINOMA	2 (2%)		1 (0%)		
C-CELL CARCINOMA, METASTATIC	1 (1%)	1 (1%)			
PHEOCHROMOCYTOMA, METASTATIC	1 (1%)		4 (2%)		
SARCOMA, NOS, METASTATIC				2 (1%)	
FIBROSARCOMA, METASTATIC		1 (1%)	1 (0%)		
FIBROUS HISTIOCYTOMA, METASTATIC			1 (0%)		
LIPOSARCOMA, METASTATIC			1 (0%)		
MIXED TUMOR, METASTATIC				1 (1%)	
CARCINOSARCOMA, METASTATIC				1 (1%)	
MESOTHELIOMA, NOS			1 (0%)		
OSTEOSARCOMA, METASTATIC		1 (1%)	1 (0%)	1 (1%)	
MENINGIOMA, METASTATIC			1 (0%)		
HEMATOPOIETIC SYSTEM					
*MULTIPLE ORGANS	(88)	(125)	(250)	(175)	(100)
MALIG.LYMPHOMA, HISTIOCYTIC TYPE	1 (1%)	2 (2%)	1 (0%)	2 (1%)	3 (3%)
MYELOMONOCYTIC LEUKEMIA			3 (1%)	2 (1%)	
MONOCYTIC LEUKEMIA	28 (32%)	40 (32%)	90 (36%)	65 (37%)	36 (36%)
LEUKEMIA, MONONUCLEAR CELL	3 (3%)	2 (2%)	1 (0%)	2 (1%)	
#SPLEEN	(85)	(125)	(250)	(175)	(99)
INTERSTITIAL-CELL TUMOR, METASTATIC			1 (0%)		
SARCOMA, NOS			1 (0%)		
MALIG.LYMPHOMA, HISTIOCYTIC TYPE		1 (1%)			
MONOCYTIC LEUKEMIA			2 (1%)	2 (1%)	
#MANDIBULAR L. NODE	(85)	(125)	(250)	(175)	(100)
CARCINOMA, NOS, INVASIVE				1 (1%)	
SQUAMOUS CELL CARCINOMA, METASTATIC		1 (1%)			
SARCOMA, NOS		1 (1%)			
SARCOMA, NOS, INVASIVE			1 (0%)		
#CERVICAL LYMPH NODE	(85)	(125)	(250)	(175)	(100)
CARCINOMA, NOS, METASTATIC				1 (1%)	
C-CELL CARCINOMA, METASTATIC					1 (1%)
SARCOMA, NOS, INVASIVE			1 (0%)		

HWBUI0001620

TABLE B1. SUMMARY OF THE INCIDENCE OF NEOPLASMS IN MALE RATS IN THE LIFETIME FEED STUDY OF INTERMEDIATE-RANGE (IR) CHRYSOTILE ASBESTOS (Continued)

	CONTROL (UNTR)	DMH	IR	IR + DMH	IR/PW
HEMATOPOIETIC SYSTEM (Continued)					
#MEDIASTINAL L. NODE	(85)	(125)	(250)	(175)	(100)
SQUAMOUS CELL CARCINOMA, METASTATIC			1 (0%)		
SARCOMA, NOS, METASTATIC				1 (1%)	
FIBROUS HISTIOCYTOMA, METASTATIC			1 (0%)		
#MESENTERIC L. NODE	(85)	(125)	(250)	(175)	(100)
MUCINOUS CYSTADENOCARCINOMA, METASTATIC				3 (2%)	
#ILEOCOLIC LYMPH NODE	(85)	(125)	(250)	(175)	(100)
MUCINOUS CYSTADENOCARCINOMA, METASTATIC		1 (1%)		4 (2%)	
SIGNET RING CARCINOMA, METASTATIC		1 (1%)			
#LIVER	(85)	(125)	(250)	(175)	(100)
MALIG.LYMPHOMA, HISTIOCYTIC TYPE		1 (1%)			
MONOCYTIC LEUKEMIA					1 (1%)
CIRCULATORY SYSTEM					
#SPLEEN	(85)	(125)	(250)	(175)	(99)
HEMANGIOSARCOMA			3 (1%)		
#LUNG	(85)	(125)	(250)	(175)	(99)
HEMANGIOSARCOMA, METASTATIC		1 (1%)			
#HEART	(85)	(125)	(250)	(175)	(99)
ADENOCARCINOMA, NOS, METASTATIC	1 (1%)		1 (0%)	1 (1%)	
#LIVER	(85)	(125)	(250)	(175)	(100)
HEMANGIOSARCOMA		2 (2%)			
#ASCENDING COLON	(85)	(125)	(250)	(175)	(100)
HEMANGIOSARCOMA	1 (1%)				
DIGESTIVE SYSTEM					
*MOUTH/ORAL CAVITY	(88)	(125)	(250)	(175)	(100)
SQUAMOUS CELL CARCINOMA			1 (0%)		
*HARD PALATE	(88)	(125)	(250)	(175)	(100)
SQUAMOUS CELL PAPILLOMA					1 (1%)
KERATOACANTHOMA			1 (0%)		
*TONGUE	(88)	(125)	(250)	(175)	(100)
SQUAMOUS CELL PAPILLOMA			1 (0%)	1 (1%)	
#SALIVARY GLAND	(84)	(124)	(247)	(173)	(98)
CARCINOMA, NOS				2 (1%)	
SARCOMA, NOS		5 (4%)	3 (1%)	1 (1%)	
FIBROSARCOMA	3 (4%)		2 (1%)		
FIBROSARCOMA, INVASIVE	1 (1%)		1 (0%)		
#PAROTID GLAND	(84)	(124)	(247)	(173)	(98)
SARCOMA, NOS		1 (1%)			
#LIVER	(85)	(125)	(250)	(175)	(100)
NEOPLASTIC NODULE	6 (7%)	12 (10%)	13 (5%)	10 (6%)	5 (5%)
HEPATOCELLULAR CARCINOMA	2 (2%)	17 (14%)	7 (3%)	20 (11%)	1 (1%)
FIBROSARCOMA, METASTATIC					
FIBROUS HISTIOCYTOMA, METASTATIC				1 (1%)	
LIPOMA				1 (1%)	
LIPOSARCOMA				2 (1%)	
LIPOSARCOMA, METASTATIC			1 (0%)		

HWBUI0001621

TABLE B1. SUMMARY OF THE INCIDENCE OF NEOPLASMS IN MALE RATS IN THE LIFETIME FEED STUDY OF INTERMEDIATE-RANGE (IR) CHRYSOTILE ASBESTOS (Continued)

	CONTROL (UNTR)	DMH	IR	IR + DMH	IR/PW
DIGESTIVE SYSTEM (Continued)					
#PANCREAS	(85)	(124)	(249)	(174)	(99)
ACINAR-CELL ADENOMA	3 (4%)	7 (6%)	23 (9%)	14 (8%)	9 (9%)
ACINAR-CELL CARCINOMA	1 (1%)		2 (1%)		
MESOTHELIOMA, METASTATIC					1 (1%)
#PANCREATIC DUCT	(85)	(124)	(249)	(174)	(99)
ADENOCARCINOMA, NOS		1 (1%)			
#ESOPHAGUS	(83)	(125)	(250)	(174)	(98)
FIBROSARCOMA					1 (1%)
#STOMACH	(85)	(124)	(250)	(175)	(100)
ADENOCARCINOMA, NOS			1 (0%)		
#GASTRIC SEROSA	(85)	(124)	(250)	(175)	(100)
MESOTHELIOMA, METASTATIC					1 (1%)
#SMALL INTESTINE	(85)	(125)	(250)	(175)	(100)
LEIOMYOSARCOMA					1 (1%)
#DUODENUM	(85)	(125)	(250)	(175)	(100)
ADENOCARCINOMA, NOS				1 (1%)	
ADENOMATOUS POLYP, NOS			1 (0%)		
MUCINOUS CYSTADENO-CARCINOMA			1 (0%)	1 (1%)	
SIGNET RING CARCINOMA			1 (0%)	1 (1%)	
LEIOMYOMA			1 (0%)		
#JEJUNUM	(85)	(125)	(250)	(175)	(100)
ADENOCARCINOMA, NOS				1 (1%)	
MUCINOUS CYSTADENO-CARCINOMA				1 (1%)	
LEIOMYOSARCOMA			2 (1%)		
#ILEUM	(85)	(125)	(250)	(175)	(100)
LEIOMYOMA	1 (1%)				1 (1%)
#COLONIC SEROSA	(85)	(125)	(250)	(175)	(100)
MESOTHELIOMA, METASTATIC				1 (1%)	
#CECUM	(85)	(125)	(250)	(175)	(100)
ADENOCARCINOMA, NOS		1 (1%)			
ADENOMATOUS POLYP, NOS				1 (1%)	
MUCINOUS CYSTADENO-CARCINOMA		4 (3%)		4 (2%)	
MUCINOUS CYSTADENOCA, METASTATIC				1 (1%)	
#ASCENDING COLON	(85)	(125)	(250)	(175)	(100)
ADENOCARCINOMA, NOS				1 (1%)	
ADENOMATOUS POLYP, NOS		3 (2%)	2 (1%)	3 (2%)	
ADENOCARCINOMA IN ADENOMATOUS POLYP				1 (1%)	
MUCINOUS CYSTADENO-CARCINOMA		3 (2%)		11 (6%)	
MUCINOUS CYSTADENO-CARCINOMA, METASTATIC		1 (1%)			
SIGNET RING CARCINOMA		1 (1%)			
#TRANSVERSE COLON	(85)	(125)	(250)	(175)	(100)
ADENOCARCINOMA, NOS		1 (1%)			
ADENOMATOUS POLYP, NOS		4 (3%)		6 (3%)	
LEIOMYOSARCOMA					1 (1%)
#DESCENDING COLON	(85)	(125)	(250)	(175)	(100)
ADENOMATOUS POLYP, NOS		24 (19%)	7 (3%)	37 (21%)	2 (2%)
ADENOCARCINOMA IN ADENOMATOUS POLYP				2 (1%)	
MUCINOUS CYSTADENO-CARCINOMA				4 (2%)	
SIGNET RING CARCINOMA				1 (1%)	

HWBUI0001622

TABLE B1. SUMMARY OF THE INCIDENCE OF NEOPLASMS IN MALE RATS IN THE LIFETIME FEED STUDY OF INTERMEDIATE-RANGE (IR) CHRYSOTILE ASBESTOS (Continued)

	CONTROL (UNTR)	DMH	IR	IR + DMH	IR/PW
DIGESTIVE SYSTEM (Continued)					
*ANUS	(88)	(125)	(250)	(175)	(100)
ADENOMATOUS POLYP, NOS		1 (1%)			
URINARY SYSTEM					
#KIDNEY	(85)	(125)	(250)	(175)	(100)
TUBULAR-CELL ADENO-CARCINOMA		1 (1%)	1 (0%)		
TUBULAR ADENOCARCINOMA			1 (0%)		
LIPOMA			1 (0%)		
LIPOSARCOMA, INVASIVE			1 (0%)		
MIXED TUMOR, MALIGNANT			1 (0%)	1 (1%)	
#RIGHT KIDNEY	(85)	(125)	(250)	(175)	(100)
MIXED TUMOR, MALIGNANT		1 (1%)			
*RIGHT URETER	(88)	(125)	(250)	(175)	(100)
MIXED TUMOR, MALIGNANT		1 (1%)			
#URINARY BLADDER	(84)	(124)	(249)	(174)	(98)
PAPILLOMA, NOS		1 (1%)			
TRANSITIONAL-CELL PAPILLOMA		1 (1%)	1 (0%)	1 (1%)	
TRANSITIONAL-CELL CARCINOMA			1 (0%)		
ENDOCRINE SYSTEM					
#PITUITARY	(85)	(124)	(246)	(175)	(100)
CARCINOMA, NOS	4 (5%)	3 (2%)	3 (1%)	1 (1%)	1 (1%)
ADENOMA, NOS	14 (16%)	12 (10%)	49 (20%)	16 (9%)	18 (18%)
#ADRENAL	(85)	(125)	(250)	(175)	(100)
CORTICAL ADENOMA			4 (2%)	1 (1%)	1 (1%)
CORTICAL CARCINOMA	2 (2%)				
PHEOCHROMOCYTOMA	14 (16%)	20 (16%)	57 (23%)	31 (18%)	30 (30%)
PHEOCHROMOCYTOMA, MALIGNANT	1 (1%)		4 (2%)		
#ADRENAL MEDULLA	(85)	(125)	(250)	(175)	(100)
PHEOCHROMOCYTOMA	2 (2%)		2 (1%)	3 (2%)	2 (2%)
PHEOCHROMOCYTOMA, MALIGNANT			1 (0%)		
#THYROID	(84)	(124)	(250)	(175)	(99)
FOLLICULAR-CELL ADENOMA	1 (1%)	1 (1%)	12 (5%)	14 (8%)	3 (3%)
FOLLICULAR-CELL CARCINOMA	5 (6%)	8 (6%)	13 (5%)	14 (8%)	2 (2%)
C-CELL ADENOMA	13 (15%)	11 (9%)	29 (12%)	18 (10%)	9 (9%)
C-CELL CARCINOMA	19 (23%)	15 (12%)	38 (15%)	21 (12%)	23 (23%)
SARCOMA, NOS, INVASIVE			1 (0%)		
FIBROSARCOMA, INVASIVE	1 (1%)				
#PARATHYROID	(78)	(119)	(243)	(166)	(93)
ADENOMA, NOS	3 (4%)	1 (1%)	4 (2%)		
C-CELL CARCINOMA, INVASIVE	1 (1%)		1 (0%)		
#PANCREATIC ISLETS	(85)	(124)	(249)	(174)	(99)
ISLET-CELL ADENOMA	5 (6%)	1 (1%)	6 (2%)	5 (3%)	5 (5%)
ISLET-CELL CARCINOMA	3 (4%)	6 (5%)	17 (7%)	4 (2%)	6 (6%)
REPRODUCTIVE SYSTEM					
*MAMMARY GLAND	(88)	(125)	(250)	(175)	(100)
ADENOMA, NOS	1 (1%)	3 (2%)	6 (2%)		1 (1%)
ADENOCARCINOMA, NOS		1 (1%)	1 (0%)		
FIBROMA			1 (0%)		
FIBROUS HISTIOCYTOMA, INVASIVE				1 (1%)	
CARCINOSARCOMA			1 (0%)		
FIBROADENOMA	3 (3%)	1 (1%)	16 (6%)	4 (2%)	7 (7%)

HWBUI0001623

TABLE B1. SUMMARY OF THE INCIDENCE OF NEOPLASMS IN MALE RATS IN THE LIFETIME FEED STUDY OF INTERMEDIATE-RANGE (IR) CHRYSOTILE ASBESTOS (Continued)

	CONTROL (UNTR)	DMH	IR	IR + DMH	IR/PW
REPRODUCTIVE SYSTEM (Continued)					
*PREPUCE	(88)	(125)	(250)	(175)	(100)
SQUAMOUS CELL CARCINOMA			1 (0%)		
*PREPUTIAL GLAND	(88)	(125)	(250)	(175)	(100)
CARCINOMA, NOS	2 (2%)	6 (5%)	10 (4%)	9 (5%)	3 (3%)
SQUAMOUS CELL CARCINOMA	1 (1%)	1 (1%)	1 (0%)	1 (1%)	
ADENOMA, NOS	1 (1%)				
#PROSTATE	(85)	(125)	(249)	(174)	(99)
CARCINOMA, NOS			2 (1%)		
SQUAMOUS CELL CARCINOMA					1 (1%)
ADENOMA, NOS		1 (1%)	3 (1%)	2 (1%)	
MESOTHELIOMA, NOS	1 (1%)				
*SEMINAL VESICLE	(88)	(125)	(250)	(175)	(100)
SQUAMOUS CELL CARCINOMA, INVASIVE					1 (1%)
#TESTIS	(84)	(125)	(250)	(175)	(100)
INTERSTITIAL-CELL TUMOR	79 (94%)	112 (90%)	237 (95%)	160 (91%)	89 (89%)
INTERSTITIAL-CELL TUMOR, MALIGNANT		1 (1%)	1 (0%)		
*EPIDIDYMIS	(88)	(125)	(250)	(175)	(100)
LIPOSARCOMA			1 (0%)		
MESOTHELIOMA, NOS				1 (1%)	
*SCROTUM	(88)	(125)	(250)	(175)	(100)
FIBROMA		1 (1%)			
MESOTHELIOMA, MALIGNANT			2 (1%)		
MESOTHELIOMA, METASTATIC		1 (1%)			
NERVOUS SYSTEM					
#CEREBRUM	(85)	(125)	(250)	(175)	(100)
CARCINOMA, NOS, INVASIVE		1 (1%)			
ASTROCYTOMA	1 (1%)		1 (0%)		1 (1%)
#BRAIN	(85)	(125)	(250)	(175)	(100)
CARCINOMA, NOS, INVASIVE	2 (2%)		1 (0%)	1 (1%)	1 (1%)
OSTEOMA				1 (1%)	
GRANULAR-CELL TUMOR, NOS				1 (1%)	
ASTROCYTOMA			2 (1%)	1 (1%)	
MENINGIOMA			1 (0%)		
#CEREBELLUM	(85)	(125)	(250)	(175)	(100)
GRANULAR-CELL TUMOR, NOS					1 (1%)
*SPINAL CORD	(88)	(125)	(250)	(175)	(100)
NEURILEMOMA, MALIGNANT		1 (1%)			
*PARA AORTIC BODY	(88)	(125)	(250)	(175)	(100)
PARAGANGLIOMA, NOS			2 (1%)		
SPECIAL SENSE ORGANS					
*EYE	(88)	(125)	(250)	(175)	(100)
ADENOCARCINOMA, NOS, INVASIVE				1 (1%)	
SARCOMA, NOS				1 (1%)	
*EYE/IRIS	(88)	(125)	(250)	(175)	(100)
MALIGNANT MELANOMA			1 (0%)		
*HARDERIAN GLAND	(88)	(125)	(250)	(175)	(100)
SARCOMA, NOS, INVASIVE			1 (0%)		
*EAR	(88)	(125)	(250)	(175)	(100)
FIBROSARCOMA		1 (1%)			

HWBUI0001624

TABLE B1. SUMMARY OF THE INCIDENCE OF NEOPLASMS IN MALE RATS IN THE LIFETIME FEED STUDY OF INTERMEDIATE-RANGE (IR) CHRYSOTILE ASBESTOS (Continued)

	CONTROL (UNTR)	DMH	IR	IR + DMH	IR/PW
SPECIAL SENSE ORGANS (Continued)					
*ZYMBAL GLAND	(88)	(125)	(250)	(175)	(100)
CARCINOMA, NOS	1 (1%)	3 (2%)	2 (1%)	2 (1%)	
SQUAMOUS CELL PAPILLOMA		1 (1%)		3 (2%)	
SQUAMOUS CELL CARCINOMA	1 (1%)	15 (12%)	8 (3%)	22 (13%)	3 (3%)
KERATOACANTHOMA			1 (0%)	1 (1%)	
CARCINOSARCOMA			1 (0%)	1 (1%)	
MUSCULOSKELETAL SYSTEM					
*MANDIBLE	(88)	(125)	(250)	(175)	(100)
SQUAMOUS CELL PAPILLOMA			1 (0%)		
SQUAMOUS CELL CARCINOMA					2 (2%)
*VERTEBRA	(88)	(125)	(250)	(175)	(100)
OSTEOSARCOMA	1 (1%)				
*STERNUM	(88)	(125)	(250)	(175)	(100)
OSTEOSARCOMA				1 (1%)	
*RIB	(88)	(125)	(250)	(175)	(100)
SARCOMA, NOS					1 (1%)
OSTEOSARCOMA	1 (1%)		1 (0%)		
*INTERCHONDRAL JOINT	(88)	(125)	(250)	(175)	(100)
OSTEOSARCOMA			1 (0%)		
*MUSCLE OF LEG	(88)	(125)	(250)	(175)	(100)
RHABDOMYOSARCOMA					1 (1%)
BODY CAVITIES					
*THORACIC CAVITY	(88)	(125)	(250)	(175)	(100)
SQUAMOUS CELL CARCINOMA			1 (0%)		
*MEDIASTINUM	(88)	(125)	(250)	(175)	(100)
ADENOCARCINOMA, NOS, METASTATIC			1 (0%)		
MESOTHELIOMA, NOS			1 (0%)		
*ABDOMINAL CAVITY	(88)	(125)	(250)	(175)	(100)
LIPOSARCOMA			1 (0%)		
OSTEOSARCOMA					1 (1%)
CHONDROMA					1 (1%)
*PERITONEUM	(88)	(125)	(250)	(175)	(100)
MESOTHELIOMA, INVASIVE	1 (1%)				
*PLEURA	(88)	(125)	(250)	(175)	(100)
ADENOCARCINOMA, NOS, METASTATIC			1 (0%)		
*MESENTERY	(88)	(125)	(250)	(175)	(100)
MUCINOUS CYSTADENOCA, METASTATIC				1 (1%)	
SARCOMA, NOS		1 (1%)			
FIBROSARCOMA			1 (0%)		
LIPOMA			1 (0%)		
MESOTHELIOMA, INVASIVE	1 (1%)				
*TUNICA VAGINALIS	(88)	(125)	(250)	(175)	(100)
MESOTHELIOMA, NOS	2 (2%)	1 (1%)	1 (0%)	3 (2%)	1 (1%)
ALL OTHER SYSTEMS					
*MULTIPLE ORGANS	(88)	(125)	(250)	(175)	(100)
ADENOCARCINOMA, NOS, INVASIVE		1 (1%)			
ADENOCARCINOMA, NOS, METASTATIC		1 (1%)		2 (1%)	
C-CELL CARCINOMA, METASTATIC	1 (1%)				

HWBUI0001625

TABLE B1. SUMMARY OF THE INCIDENCE OF NEOPLASMS IN MALE RATS IN THE LIFETIME FEED STUDY OF INTERMEDIATE-RANGE (IR) CHRYSOTILE ASBESTOS (Continued)

	CONTROL (UNTR)	DMH	IR	IR + DMH	IR/PW
ALL OTHER SYSTEMS					
*MULTIPLE ORGANS (Continued)	(88)	(125)	(250)	(175)	(100)
MUCINOUS CYSTADENOCA, METASTATIC		3 (2%)		3 (2%)	
SIGNET RING CARCINOMA, METASTATI				2 (1%)	
SARCOMA, NOS, INVASIVE	1 (1%)			1 (1%)	
FIBROSARCOMA, INVASIVE			1 (0%)		
FIBROSARCOMA, METASTATIC			1 (0%)		
FIBROUS HISTIOCYTOMA, METASTATIC			1 (0%)	1 (1%)	
CARCINOSARCOMA, METASTATIC			1 (0%)		
MESOTHELIOMA, MALIGNANT	2 (2%)	5 (4%)	13 (5%)	4 (2%)	5 (5%)
MESOTHELIOMA, MALIGNANT			1 (0%)		
MESOTHELIOMA, INVASIVE	1 (1%)				
MESOTHELIOMA, METASTATIC		4 (3%)	13 (5%)	3 (2%)	4 (4%)
OSTEOSARCOMA, METASTATIC	1 (1%)		2 (1%)		3 (3%)
HEAD					
SARCOMA, NOS			1		
ORBITAL REGION					
OSTEOSARCOMA					1
BACK					
RHABDOMYOSARCOMA			1		
LUMBAR REGION					
CHONDROSARCOMA			1		
COCCYGEAL REGION					
NEUROFIBROSARCOMA				1	
BASE OF TAIL					
RHABDOMYOSARCOMA		1			
AXILLA					
FIBROMA					1
LOWER LEG					
OSTEOSARCOMA			1		
ADIPOSE TISSUE					
MUCINOUS CYSTADENO-CARCINOMA, METASTATIC				1	
MIXED MESENCHYMAL TUMOR, MALIGNANT			1		
MESOTHELIOMA, METASTATIC				1	
ANIMAL DISPOSITION SUMMARY					
ANIMALS INITIALLY IN STUDY	88	125	250	175	100
NATURAL DEATH	21	21	29	25	16
MORIBUND SACRIFICE	60	86	191	134	73
TERMINAL SACRIFICE	7	18	29	16	11
ACCIDENTALLY KILLED, NDA			1		

HWBUI0001626

TABLE B1. SUMMARY OF THE INCIDENCE OF NEOPLASMS IN MALE RATS IN THE LIFETIME FEED STUDY OF INTERMEDIATE-RANGE (IR) CHRYSOTILE ASBESTOS (Continued)

	CONTROL (UNTR)	DMH	IR	IR + DMH	IR/PW
TUMOR SUMMARY					
TOTAL ANIMALS WITH PRIMARY TUMORS**	85	122	246	173	95
TOTAL PRIMARY TUMORS	272	411	857	603	320
TOTAL ANIMALS WITH BENIGN TUMORS	80	117	242	163	91
TOTAL BENIGN TUMORS	164	236	555	361	205
TOTAL ANIMALS WITH MALIGNANT TUMORS	65	98	192	145	77
TOTAL MALIGNANT TUMORS	99	162	284	227	108
TOTAL ANIMALS WITH SECONDARY TUMORS##	13	19	39	31	13
TOTAL SECONDARY TUMORS	15	20	47	42	14
TOTAL ANIMALS WITH TUMORS UNCERTAIN--BENIGN OR MALIGNANT	9	12	17	13	7
TOTAL UNCERTAIN TUMORS	9	13	18	15	7

* NUMBER OF ANIMALS NECROPSIED
** PRIMARY TUMORS: ALL TUMORS EXCEPT SECONDARY TUMORS
# NUMBER OF ANIMALS WITH TISSUE EXAMINED MICROSCOPICALLY
SECONDARY TUMORS: METASTATIC TUMORS OR TUMORS INVASIVE INTO AN ADJACENT ORGAN
† MULTIPLE OCCURRENCE OF MORPHOLOGY IN THE SAME ORGAN. TISSUE IS ONLY COUNTED ONCE.

HWBUI0001627

TABLE B2. SUMMARY OF THE INCIDENCE OF NEOPLASMS IN FEMALE RATS IN THE LIFETIME FEED STUDY OF INTERMEDIATE-RANGE (IR) CHRYSOTILE ASBESTOS

	CONTROL (UNTR)	DMH	IR	IR + DMH	IR/PW
ANIMALS INITIALLY IN STUDY	88	125	250	175	100
ANIMALS NECROPSIED	88	125	250	175	100
ANIMALS EXAMINED HISTOPATHOLOGICALLY	87	125	250	175	100
INTEGUMENTARY SYSTEM					
*SKIN	(88)	(125)	(250)	(175)	(100)
SQUAMOUS CELL PAPILLOMA	3 (3%)		5 (2%)		
SQUAMOUS CELL CARCINOMA			1 (0%)		
BASAL-CELL TUMOR		1 (1%)		1 (1%)	
BASAL-CELL CARCINOMA			2 (1%)	1 (1%)	
KERATOACANTHOMA	1 (1%)		1 (0%)	2 (1%)	
*SUBCUT TISSUE	(88)	(125)	(250)	(175)	(100)
CARCINOMA, NOS				1 (1%)	
SQUAMOUS CELL CARCINOMA	1 (1%)		3 (1%)		
KERATOACANTHOMA				1 (1%)	
SARCOMA, NOS	1 (1%)				1 (1%)
FIBROMA	5 (6%)	2 (2%)	9 (4%)	1 (1%)	3 (3%)
FIBROSARCOMA	1 (1%)	1 (1%)	4 (2%)	1 (1%)	
FIBROUS HISTIOCYTOMA, MALIGNANT	2 (2%)				
LIPOMA			1 (0%)		
RESPIRATORY SYSTEM					
*NOSE	(88)	(125)	(250)	(175)	(100)
SQUAMOUS CELL CARCINOMA				1 (1%)	
*LARYNX	(88)	(125)	(250)	(175)	(100)
FOLLICULAR-CELL CARCINOMA, INVASIVE			1 (0%)		
C-CELL CARCINOMA, INVASIVE			1 (0%)		
#LUNG	(87)	(125)	(250)	(175)	(99)
SQUAMOUS CELL CARCINOMA, METASTATIC			1 (0%)	1 (1%)	
ADENOCARCINOMA, NOS, METASTATIC			2 (1%)		
ALVEOLAR/BRONCHIOLAR ADENOMA		1 (1%)	2 (1%)	1 (1%)	3 (3%)
ALVEOLAR/BRONCHIOLAR CARCINOMA	1 (1%)		1 (0%)		1 (1%)
PAPILLARY ADENOCARCINOMA, METASTATIC					1 (1%)
FOLLICULAR-CELL CARCINOMA, METASTATIC			1 (0%)		
C-CELL CARCINOMA, METASTATIC			4 (2%)		1 (1%)
PHEOCHROMOCYTOMA, METASTATIC	2 (2%)			1 (1%)	2 (2%)
SARCOMA, NOS, METASTATIC	1 (1%)				
FIBROUS HISTIOCYTOMA, METASTATIC	1 (1%)				
LIPOSARCOMA, METASTATIC				1 (1%)	
MIXED TUMOR, METASTATIC				5 (3%)	

HWBUI0001628

TABLE B2. SUMMARY OF THE INCIDENCE OF NEOPLASMS IN FEMALE RATS IN THE LIFETIME FEED STUDY OF INTERMEDIATE-RANGE (IR) CHRYSOTILE ASBESTOS (Continued)

	CONTROL (UNTR)	DMH	IR	IR + DMH	IR/PW
HEMATOPOIETIC SYSTEM					
*MULTIPLE ORGANS	(88)	(125)	(250)	(175)	(100)
MALIG. LYMPHOMA, UNDIFFER-TYPE				2 (1%)	
MYELOMONOCYTIC LEUKEMIA			2 (1%)	1 (1%)	
MONOCYTIC LEUKEMIA	33 (38%)	66 (53%)	76 (30%)	88 (50%)	26 (26%)
LEUKEMIA, MONONUCLEAR CELL	1 (1%)	4 (3%)	4 (2%)	4 (2%)	3 (3%)
#MANDIBULAR L. NODE	(87)	(125)	(250)	(175)	(99)
SQUAMOUS CELL CARCINOMA, METASTA			3 (1%)		
#CERVICAL LYMPH NODE	(87)	(125)	(250)	(175)	(99)
FOLLICULAR-CELL CARCINOMA, METAS			1 (0%)		
C-CELL CARCINOMA, METASTATIC			2 (1%)		
#MEDIASTINAL L. NODE	(87)	(125)	(250)	(175)	(99)
C-CELL CARCINOMA, METASTATIC		1 (1%)	1 (0%)		1 (1%)
MUCINOUS CYSTADENO-CARCINOMA, METASTATIC				1 (1%)	
#CELIAC LYMPH NODE	(87)	(125)	(250)	(175)	(99)
MUCINOUS CYSTADENO-CARCINOMA, METASTATIC				1 (1%)	
SIGNET RING CARCINOMA, METASTATIC				1 (1%)	
#MESENTERIC L. NODE	(87)	(125)	(250)	(175)	(99)
ADENOCARCINOMA, NOS, METASTATIC				1 (1%)	
MALIG.LYMPHOMA, HISTIOCYTIC TYPE			1 (0%)		
#ILEOCOLIC LYMPH NODE	(87)	(125)	(250)	(175)	(99)
MUCINOUS CYSTADENO-CARCINOMA, METASTATIC		3 (2%)			
#AXILLARY LYMPH NODE	(87)	(125)	(250)	(175)	(99)
ADENOCARCINOMA, NOS, METASTATIC			1 (0%)		
#LIVER	(87)	(125)	(250)	(175)	(99)
MALIG.LYMPHOMA, HISTIOCYTIC TYPE			1 (0%)		
CIRCULATORY SYSTEM					
#SPLEEN	(87)	(125)	(249)	(175)	(99)
HEMANGIOSARCOMA	1 (1%)				
#LUNG	(87)	(125)	(250)	(175)	(99)
HEMANGIOSARCOMA, METASTATIC				1 (1%)	
#HEART	(87)	(125)	(250)	(175)	(99)
ADENOCARCINOMA, NOS, METASTATIC			1 (0%)		
MIXED TUMOR, METASTATIC				1 (1%)	
NEURILEMOMA				1 (1%)	
#MYOCARDIUM	(87)	(125)	(250)	(175)	(99)
PHEOCHROMOCYTOMA, METASTATIC					1 (1%)
#LIVER	(87)	(125)	(250)	(175)	(99)
HEMANGIOSARCOMA				1 (1%)	
#PERIPANCREATIC TISSUE	(87)	(124)	(249)	(175)	(99)
HEMANGIOSARCOMA	1 (1%)				

HWBUI0001629

TABLE B2. SUMMARY OF THE INCIDENCE OF NEOPLASMS IN FEMALE RATS IN THE LIFETIME FEED STUDY OF INTERMEDIATE-RANGE (IR) CHRYSOTILE ASBESTOS (Continued)

	CONTROL (UNTR)	DMH	IR	IR + DMH	IR/PW
DIGESTIVE SYSTEM					
*MOUTH	(88)	(125)	(250)	(175)	(100)
SQUAMOUS CELL CARCINOMA			1 (0%)		
SQUAMOUS CELL CARCINOMA, INVASIVE		1 (1%)			
*HARD PALATE	(88)	(125)	(250)	(175)	(100)
SQUAMOUS CELL PAPILLOMA			1 (0%)		
SQUAMOUS CELL CARCINOMA					1 (1%)
*TONGUE	(88)	(125)	(250)	(175)	(100)
SQUAMOUS CELL PAPILLOMA	1 (1%)	1 (1%)			1 (1%)
SQUAMOUS CELL CARCINOMA		1 (1%)			
#SALIVARY GLAND	(87)	(122)	(248)	(173)	(99)
ADENOCARCINOMA, NOS			1 (0%)		
SARCOMA, NOS					1 (1%)
#LIVER	(87)	(125)	(250)	(175)	(99)
SQUAMOUS CELL CARCINOMA, INVASIVE	1 (1%)				
BILE DUCT ADENOMA				1 (1%)	
NEOPLASTIC NODULE	3 (3%)	12 (10%)	4 (2%)	21 (12%)	1 (1%)
HEPATOCELLULAR CARCINOMA	1 (1%)	12 (10%)	2 (1%)	19 (11%)	
CORTICAL CARCINOMA, METASTATIC			1 (0%)		
MIXED TUMOR, METASTATIC				1 (1%)	
#HEPATIC CAPSULE	(87)	(125)	(250)	(175)	(99)
MIXED TUMOR, METASTATIC				1 (1%)	
#PANCREAS	(87)	(124)	(249)	(175)	(99)
ACINAR-CELL ADENOMA	2 (2%)	1 (1%)	4 (2%)		2 (2%)
ACINAR-CELL CARCINOMA			1 (0%)		
MIXED TUMOR, INVASIVE				1 (1%)	
MIXED TUMOR, METASTATIC				1 (1%)	
#STOMACH	(87)	(124)	(250)	(174)	(99)
SQUAMOUS CELL PAPILLOMA					1 (1%)
SQUAMOUS CELL CARCINOMA	1 (1%)				1 (1%)
ADENOMATOUS POLYP, NOS			1 (0%)		
CARCINOID TUMOR, NOS			2 (1%)		
LEIOMYOSARCOMA			1 (0%)		
ENDOMETRIAL STROMAL SARCOMA, METASTATIC			1 (0%)		
#SMALL INTESTINE	(87)	(125)	(249)	(175)	(99)
MUCINOUS CYSTADENO-CARCINOMA				1 (1%)	
#DUODENUM	(87)	(125)	(249)	(175)	(99)
MUCINOUS CYSTADENO-CARCINOMA		2 (2%)		2 (1%)	
SIGNET RING CARCINOMA				2 (1%)	
LEIOMYOMA	1 (1%)				
#JEJUNUM	(87)	(125)	(249)	(175)	(99)
ADENOMATOUS POLYP, NOS				1 (1%)	
#ILEUM	(87)	(125)	(249)	(175)	(99)
ADENOCARCINOMA IN ADENOMATOUS POLYP				1 (1%)	
#COLON	(87)	(125)	(250)	(175)	(99)
ADENOMATOUS POLYP, NOS		2 (2%)		1 (1%)	
MUCINOUS CYSTADENO-CARCINOMA				1 (1%)	
#COLONIC SEROSA	(87)	(125)	(250)	(175)	(99)
MUCINOUS CYSTADENOCA, METASTATIC		1 (1%)			

HWBUI0001630

TABLE B2. SUMMARY OF THE INCIDENCE OF NEOPLASMS IN FEMALE RATS IN THE LIFETIME FEED STUDY OF INTERMEDIATE-RANGE (IR) CHRYSOTILE ASBESTOS (Continued)

	CONTROL (UNTR)	DMH	IR	IR + DMH	IR/PW
DIGESTIVE SYSTEM					
#CECUM	(87)	(125)	(250)	(175)	(99)
ADENOCARCINOMA, NOS		1 (1%)			
ADENOMATOUS POLYP, NOS				3 (2%)	
MUCINOUS CYSTADENO-CARCINOMA		8 (6%)		8 (5%)	
SIGNET RING CARCINOMA		1 (1%)			
#ASCENDING COLON	(87)	(125)	(250)	(175)	(99)
ADENOCARCINOMA, NOS				3 (2%)	
ADENOMATOUS POLYP, NOS		2 (2%)		6 (3%)	
MUCINOUS CYSTADENOCARCINOMA		5 (4%)		6 (3%)	
SIGNET RING CARCINOMA		1 (1%)		2 (1%)	
LEIOMYOMA					1 (1%)
LEIOMYOSARCOMA		1 (1%)			
#TRANSVERSE COLON	(87)	(125)	(250)	(175)	(99)
ADENOMATOUS POLYP, NOS		9 (7%)		8 (5%)	
ADENOCARCINOMA IN ADENOMATOUS POLYP				4 (2%)	
MUCINOUS CYSTADENO-CARCINOMA				1 (1%)	
#DESCENDING COLON	(87)	(125)	(250)	(175)	(99)
ADENOMATOUS POLYP, NOS		24 (19%)	1 (0%)	30 (17%)	
ADENOCARCINOMA IN ADENOMATOUS POLYP		2 (2%)		2 (1%)	
MUCINOUS CYSTADENO-CARCINOMA		1 (1%)			
LEIOMYOMA			1 (0%)		
URINARY SYSTEM					
#KIDNEY	(87)	(125)	(250)	(175)	(99)
CARCINOMA, NOS			1 (0%)		
TUBULAR-CELL ADENO-CARCINOMA	1 (1%)				1 (1%)
LIPOMA	1 (1%)				
LIPOSARCOMA			1 (0%)		
MIXED TUMOR, MALIGNANT		13 (10%)		34 (19%)	
CARCINOSARCOMA		1 (1%)			
#URINARY BLADDER	(85)	(125)	(247)	(175)	(98)
TRANSITIONAL-CELL PAPILLOMA			1 (0%)		2 (2%)
ENDOCRINE SYSTEM					
#PITUITARY	(87)	(124)	(249)	(173)	(100)
CARCINOMA, NOS	4 (5%)	1 (1%)	14 (6%)	1 (1%)	1 (1%)
ADENOMA, NOS	49 (56%)	31 (25%)	103 (41%)	51 (29%)	50 (50%)
#PITUITARY INTERMEDIATE	(87)	(124)	(249)	(173)	(100)
ADENOMA, NOS		1 (1%)			
#ADRENAL	(87)	(124)	(249)	(175)	(99)
CORTICAL ADENOMA	4 (5%)	1 (1%)	10 (4%)	6 (3%)	5 (5%)
CORTICAL CARCINOMA			5 (2%)	1 (1%)	
PHEOCHROMOCYTOMA	8 (9%)	6 (5%)	23 (9%)	8 (5%)	11 (11%)
PHEOCHROMOCYTOMA, MALIGNANT	2 (2%)			1 (1%)	2 (2%)
GANGLIONEUROMA					1 (1%)
#ADRENAL MEDULLA	(87)	(124)	(249)	(175)	(99)
PHEOCHROMOCYTOMA			2 (1%)		
PHEOCHROMOCYTOMA, MALIGNANT		1 (1%)			

HWBUI0001631

TABLE B2. SUMMARY OF THE INCIDENCE OF NEOPLASMS IN FEMALE RATS IN THE LIFETIME FEED STUDY OF INTERMEDIATE-RANGE (IR) CHRYSOTILE ASBESTOS (Continued)

	CONTROL (UNTR)	DMH	IR	IR + DMH	IR/PW
ENDOCRINE SYSTEM (Continued)					
#THYROID	(87)	(124)	(248)	(174)	(100)
FOLLICULAR-CELL ADENOMA	6 (7%)	7 (6%)	13 (5%)	9 (5%)	6 (6%)
FOLLICULAR-CELL CARCINOMA	1 (1%)	5 (4%)	14 (6%)	7 (4%)	7 (7%)
C-CELL ADENOMA	11 (13%)	9 (7%)	26 (10%)	18 (10%)	20 (20%)
C-CELL CARCINOMA	11 (13%)	9 (7%)	41 (17%)	12 (7%)	12 (12%)
#PARATHYROID	(73)	(119)	(235)	(164)	(97)
ADENOMA, NOS			1 (0%)		1 (1%)
C-CELL CARCINOMA, INVASIVE			3 (1%)		
#PANCREATIC ISLETS	(87)	(124)	(249)	(175)	(99)
ISLET-CELL ADENOMA	2 (2%)	1 (1%)	6 (2%)	1 (1%)	4 (4%)
ISLET-CELL CARCINOMA	4 (5%)	1 (1%)	7 (3%)	1 (1%)	3 (3%)
REPRODUCTIVE SYSTEM					
*MAMMARY GLAND	(88)	(125)	(250)	(175)	(100)
CARCINOMA, NOS	1 (1%)		3 (1%)		1 (1%)
ADENOMA, NOS	6 (7%)	2 (2%)	21 (8%)	5 (3%)	11 (11%)
ADENOCARCINOMA, NOS	5 (6%)		9 (4%)	1 (1%)	4 (4%)
FIBROADENOMA	49 (56%)	36 (29%)	128 (51%)	41 (23%)	58 (58%)
CHONDROMA					1 (1%)
*VULVA	(88)	(125)	(250)	(175)	(100)
FIBROSARCOMA, INVASIVE			1 (0%)		
*CLITORAL GLAND	(88)	(125)	(250)	(175)	(100)
CARCINOMA, NOS		5 (4%)	16 (6%)	4 (2%)	4 (4%)
SQUAMOUS CELL CARCINOMA	1 (1%)		2 (1%)		
*VAGINA	(88)	(125)	(250)	(175)	(100)
FIBROMA		1 (1%)			
FIBROSARCOMA			1 (0%)		
ENDOMETRIAL STROMAL POLYP					1 (1%)
ENDOMETRIAL STROMAL SARCOMA			2 (1%)		
ENDOMETRIAL STROMAL SARCOMA, INVASIVE				1 (1%)	
#UTERUS	(87)	(125)	(249)	(175)	(99)
PAPILLARY ADENOCARCINOMA					1 (1%)
PAPILLARY CYSTADENOMA, NOS					1 (1%)
LEIOMYOMA	2 (2%)		1 (0%)		
ENDOMETRIAL STROMAL POLYP	13 (15%)	7 (6%)	22 (9%)	15 (9%)	10 (10%)
ENDOMETRIAL STROMAL SARCOMA	1 (1%)	2 (2%)	2 (1%)	2 (1%)	1 (1%)
#CERVIX UTERI	(87)	(125)	(249)	(175)	(99)
FIBROMA			1 (0%)		
LEIOMYOSARCOMA				1 (1%)	
ENDOMETRIAL STROMAL POLYP	1 (1%)				1 (1%)
ENDOMETRIAL STROMAL SARCOMA			3 (1%)	1 (1%)	
ENDOMETRIAL STROMAL SARCOMA, INVASIVE				1 (1%)	1 (1%)
#UTERUS/ENDOMETRIUM	(87)	(125)	(249)	(175)	(99)
CARCINOMA, NOS			1 (0%)		
PAPILLARY CARCINOMA				1 (1%)	
ADENOMA, NOS			1 (0%)	4 (2%)	
PAPILLARY ADENOMA				1 (1%)	
#OVARY	(87)	(125)	(249)	(174)	(99)
PAPILLARY ADENOCARCINOMA			1 (0%)		
THECOMA	1 (1%)				
GRANULOSA-CELL TUMOR	1 (1%)		4 (2%)	1 (1%)	2 (2%)
NERVOUS SYSTEM					
#CEREBRUM	(87)	(125)	(250)	(175)	(100)
ASTROCYTOMA	1 (1%)				

HWBUI0001632

TABLE B2. SUMMARY OF THE INCIDENCE OF NEOPLASMS IN FEMALE RATS IN THE LIFETIME FEED STUDY OF INTERMEDIATE-RANGE (IR) CHRYSOTILE ASBESTOS (Continued)

	CONTROL (UNTR)	DMH	IR	IR + DMH	IR/PW
NERVOUS SYSTEM (Continued)					
#BRAIN	(87)	(125)	(250)	(175)	(100)
CARCINOMA, NOS, INVASIVE	4 (5%)	1 (1%)	13 (5%)	1 (1%)	1 (1%)
GRANULAR-CELL TUMOR, NOS					1 (1%)
GLIOMA, NOS					1 (1%)
ASTROCYTOMA	1 (1%)		5 (2%)	1 (1%)	1 (1%)
*SPINAL CORD	(88)	(125)	(250)	(175)	(100)
OLIGODENDROGLIOMA			1 (0%)		
SPECIAL SENSE ORGANS					
*EYE	(88)	(125)	(250)	(175)	(100)
FIBROMA			1 (0%)		
*EYELID	(88)	(125)	(250)	(175)	(100)
SQUAMOUS CELL CARCINOMA	1 (1%)				
*EAR	(88)	(125)	(250)	(175)	(100)
SQUAMOUS CELL CARCINOMA				1 (1%)	
*ZYMBAL GLAND	(88)	(125)	(250)	(175)	(100)
SQUAMOUS CELL PAPILLOMA		1 (1%)		2 (1%)	
SQUAMOUS CELL CARCINOMA	1 (1%)	14 (11%)	7 (3%)	26 (15%)	2 (2%)
ADENOMA, NOS				1 (1%)	
SARCOMA, NOS, INVASIVE					1 (1%)
MUSCULOSKELETAL SYSTEM					
*MAXILLA	(88)	(125)	(250)	(175)	(100)
SQUAMOUS CELL CARCINOMA			1 (0%)		
*FEMUR	(88)	(125)	(250)	(175)	(100)
OSTEOSARCOMA	1 (1%)				
*SKELETAL MUSCLE	(88)	(125)	(250)	(175)	(100)
RHABDOMYOSARCOMA					1 (1%)
*ABDOMINAL MUSCLE	(88)	(125)	(250)	(175)	(100)
MIXED TUMOR, INVASIVE				1 (1%)	
BODY CAVITIES					
*MEDIASTINUM	(88)	(125)	(250)	(175)	(100)
MUCINOUS CYSTADENO-CARCINOMA, METASTATIC				1 (1%)	
*ABDOMINAL CAVITY	(88)	(125)	(250)	(175)	(100)
LEIOMYOSARCOMA	1 (1%)				
*ABDOMINAL WALL	(88)	(125)	(250)	(175)	(100)
MIXED TUMOR, INVASIVE				1 (1%)	
*MESENTERY	(88)	(125)	(250)	(175)	(100)
SQUAMOUS CELL CARCINOMA, INVASIVE					1 (1%)
MIXED TUMOR, INVASIVE				1 (1%)	
ALL OTHER SYSTEMS					
*MULTIPLE ORGANS	(88)	(125)	(250)	(175)	(100)
ADENOCARCINOMA, NOS, METASTATIC		1 (1%)			
ALVEOLAR/BRONCHIOLAR CARCINOMA, METASTATIC			1 (0%)		
PAPILLARY ADENOCARCINOMA, METASTATIC			1 (0%)		
CORTICAL CARCINOMA, METASTATIC			2 (1%)		
C-CELL CARCINOMA, METASTATIC	1 (1%)				

HWBUI0001633

TABLE B2. SUMMARY OF THE INCIDENCE OF NEOPLASMS IN FEMALE RATS IN THE LIFETIME FEED STUDY OF INTERMEDIATE-RANGE (IR) CHRYSOTILE ASBESTOS (Continued)

	CONTROL (UNTR)	DMH	IR	IR + DMH	IR/PW
ALL OTHER SYSTEMS					
*MULTIPLE ORGANS (Continued)	(88)	(125)	(250)	(175)	(100)
MUCINOUS CYSTADENO-CARCINOMA, METASTATIC		6 (5%)		10 (6%)	
SIGNET RING CARCINOMA, METASTATIC		1 (1%)		4 (2%)	
SARCOMA, NOS		1 (1%)			
MIXED TUMOR, METASTATIC		1 (1%)			
CARCINOSARCOMA, METASTATIC		1 (1%)			
OSTEOSARCOMA, METASTATIC	1 (1%)				
THORACOLUMBAR REGION					
OSTEOSARCOMA	1				
PERINEUM					
FIBROSARCOMA			1		
LOWER LEG					
OSTEOSARCOMA	1				
FOOT					
FIBROMA			1		
ADIPOSE TISSUE					
MUCINOUS CYSTADENOCA, METASTATIC				1	
MIXED TUMOR, INVASIVE				3	
BROAD LIGAMENT					
LEIOMYOMA			1		
ANIMAL DISPOSITION SUMMARY					
ANIMALS INITIALLY IN STUDY	88	125	250	175	100
NATURAL DEATH	19	26	39	32	14
MORIBUND SACRIFICE	60	83	186	117	77
TERMINAL SACRIFICE	9	16	25	26	9
TUMOR SUMMARY					
TOTAL ANIMALS WITH PRIMARY TUMORS**	86	123	239	168	93
TOTAL PRIMARY TUMORS	253	317	637	488	274
TOTAL ANIMALS WITH BENIGN TUMORS	78	79	201	123	88
TOTAL BENIGN TUMORS	166	146	388	219	194
TOTAL ANIMALS WITH MALIGNANT TUMORS	64	108	172	157	56
TOTAL MALIGNANT TUMORS	83	159	239	247	76
TOTAL ANIMALS WITH SECONDARY TUMORS##	10	16	32	35	8
TOTAL SECONDARY TUMORS	11	17	42	43	10
TOTAL ANIMALS WITH TUMORS UNCERTAIN--BENIGN OR MALIGNANT	4	12	9	22	4
TOTAL UNCERTAIN TUMORS	4	12	10	22	4

* NUMBER OF ANIMALS NECROPSIED
** PRIMARY TUMORS: ALL TUMORS EXCEPT SECONDARY TUMORS
# NUMBER OF ANIMALS WITH TISSUE EXAMINED MICROSCOPICALLY
SECONDARY TUMORS: METASTATIC TUMORS OR TUMORS INVASIVE INTO AN ADJACENT ORGAN

HWBUI0001634

TABLE B3. INDIVIDUAL ANIMAL TUMOR PATHOLOGY OF MALE RATS IN THE LIFETIME FEED STUDY OF INTERMEDIATE-RANGE CHRYSOTILE ASBESTOS: UNTREATED CONTROL

ANIMAL NUMBER	27801	27711	27721	27731	27741	27751	27761	27771	27781	27791	28001	28011	28021	28031	28041	28051	28061	28071	28081	28091	28101	28121	28131	28141
WEEKS ON STUDY	114	117	139	168	120	139	118	128	127	128	144	139	135	139	098	119	084	118	127	094	085	124	106	112
INTEGUMENTARY SYSTEM																								
SKIN	+	+	+	+	+	+	+	+	+	N	+	+	+	+	+	+	+	+	+	+	+	+	+	+
PAPILLOMA, NOS											X													
BASAL-CELL CARCINOMA																								
KERATOACANTHOMA																								
SUBCUTANEOUS TISSUE	+	+	+	+	+	+	+	+	+	N	+	+	+	+	+	+	+	+	+	+	+	+	+	+
SQUAMOUS CELL CARCINOMA																			X					
BASAL-CELL TUMOR																							X	
SARCOMA, NOS															X									
FIBROMA	X			X	X		X	X												X				
FIBROSARCOMA								X														X		
RESPIRATORY SYSTEM																								
LUNGS AND BRONCHI	+	+	+	+	+	+	+	+	+	+	+	+	+	+	+	+	+	+	+	+	+	+	+	+
SQUAMOUS CELL CARCINOMA																								
ALVEOLAR/BRONCHIOLAR CARCINOMA																								
C-CELL CARCINOMA, METASTATIC																								
PHEOCHROMOCYTOMA, METASTATIC										X														
TRACHEA	+	+	+	+	+	+	+	+	+	+	+	+	+	+	+	+	+	+	+	+	+	+	+	+
FIBROSARCOMA, INVASIVE																					X			
HEMATOPOIETIC SYSTEM																								
BONE MARROW	+	+	+	+	-	+	+	+	+	+	+	+	+	+	+	+	+	+	+	+	+	+	+	+
SPLEEN	+	+	+	+	+	+	+	+	+	+	+	+	+	+	+	+	+	+	+	+	+	+	+	+
LYMPH NODES	+	+	+	+	+	+	+	+	+	+	+	+	+	+	+	+	+	+	+	+	+	+	+	+
THYMUS	-	+	+	-	+	+	+	+	+	-	-	-	+	-	-	+	+	+	+	-	-	-	+	+
CIRCULATORY SYSTEM																								
HEART	+	+	+	+	+	+	+	+	+	+	+	+	+	+	+	+	+	+	+	+	+	+	+	+
ADENOCARCINOMA, NOS, METASTATIC																						X		
DIGESTIVE SYSTEM																								
SALIVARY GLAND	+	+	+	+	+	+	+	+	+	+	+	+	+	+	+	+	+	+	+	+	+	+	+	+
FIBROSARCOMA		X																			X		X	
FIBROSARCOMA, INVASIVE																								
LIVER	+	+	+	+	+	+	+	+	+	+	+	+	+	+	+	+	+	+	+	+	+	+	+	+
NEOPLASTIC NODULE																			X			X		
HEPATOCELLULAR CARCINOMA								X																
BILE DUCT	+	+	+	+	+	+	+	+	+	+	+	+	+	+	+	+	+	+	+	+	+	+	+	+
GALLBLADDER & COMMON BILE DUCT	N	N	N	N	N	N	N	N	N	N	N	N	N	N	N	N	N	N	N	N	N	N	N	N
PANCREAS	+	+	+	+	+	+	+	+	+	+	+	+	+	+	+	+	+	+	+	+	+	+	+	+
ACINAR-CELL ADENOMA																								
ACINAR-CELL CARCINOMA																								
ESOPHAGUS	+	-	+	+	+	+	+	+	+	+	+	+	+	+	+	+	+	+	+	+	+	+	+	+
STOMACH	+	+	+	+	+	+	+	+	+	+	+	+	+	+	+	+	+	+	+	+	+	+	+	+
SMALL INTESTINE	+	+	+	+	+	+	+	+	+	+	+	+	+	+	+	+	+	+	+	+	+	+	+	+
LEIOMYOMA																								
LARGE INTESTINE	+	+	+	+	+	+	+	+	+	+	+	+	+	+	+	+	+	+	+	+	+	+	+	+
HEMANGIOSARCOMA																								
URINARY SYSTEM																								
KIDNEY	+	+	+	+	+	+	+	+	+	+	+	+	+	+	+	+	+	+	+	+	+	+	+	+
URINARY BLADDER	+	+	+	+	+	+	+	+	+	+	+	+	+	+	+	+	+	+	+	+	+	+	+	+

HWBUI0001635

TABLE B3. INDIVIDUAL ANIMAL TUMOR PATHOLOGY OF MALE RATS IN THE LIFETIME FEED STUDY OF INTERMEDIATE-RANGE CHRYSOTILE ASBESTOS: UNTREATED CONTROL (Continued)

ANIMAL NUMBER	21701	21711	21721	21731	21741	21751	21761	21771	21781	21791	21801	21811	21821	21831	21841	21851	21861	21871	21881	21891	21901	21911	21921	21931	21941
WEEKS ON STUDY	114	117	139	088	201	391	188	206	271	281	444	391	536	539	098	119	048	118	127	094	095	124	068	113	112
ENDOCRINE SYSTEM																									
PITUITARY	+	+	+	+	+	+	+	+	+	+	+	+	+	+	+	+	+	+	+	+	+	+	+	+	+
CARCINOMA, NOS									X									X					X		
ADENOMA, NOS			X	X								X	X												
ADRENAL	+	+	+	+	+	+	+	+	+	+	+	+	+	+	+	+	+	+	+	+	+	+	+	+	+
CORTICAL CARCINOMA																									
PHEOCHROMOCYTOMA												X													
PHEOCHROMOCYTOMA, MALIGNANT										X															X
THYROID	+	+	+	+	+	+	+	+	+	+	+	+	+	+	+	+	+	+	+	+	+	+	+	+	+
FOLLICULAR-CELL ADENOMA																									
FOLLICULAR-CELL CARCINOMA				X			X		X			X													
C-CELL ADENOMA	X											X	X	X									X		
C-CELL CARCINOMA								X	X	X				X										X	
FIBROSARCOMA, INVASIVE																					X				
PARATHYROID	+	+	+	+	+	+	−	+	−	+	+	+	+	+	+	+	+	+	+	+	+	+	+	+	+
ADENOMA, NOS			X																						
C-CELL CARCINOMA, INVASIVE																									
PANCREATIC ISLETS	+	+	+	+	+	+	+	+	+	+	+	+	+	+	+	+	+	+	+	+	+	+	+	+	+
ISLET-CELL ADENOMA																		X				X			
ISLET-CELL CARCINOMA																									
REPRODUCTIVE SYSTEM																									
MAMMARY GLAND	+	N	+	+	+	+	+	+	+	+	+	+	+	+	+	+	N	+	+	+	+	N	+	+	+	N
ADENOMA, NOS															X										
FIBROADENOMA														X										X	
TESTIS	+	+	+	+	+	+	+	+	+	+	+	+	+	+	+	+		+	+	+	+	+	+	+	+
INTERSTITIAL-CELL TUMOR	X		X	X	X	X	X	X	X	X	X	X	X	X	X	X		X	X	X	X	X	X	X	X
PROSTATE	+	+	+	+	+	+	+	+	+	+	+	+	+	+	+	+	+	+	+	+	+	+	+	+	+
MESOTHELIOMA, NOS			X																						
PREPUTIAL/CLITORAL GLAND	N	N	N	N	N	N	N	N	N	N	N	N	N	N	N	N	N	N	N	N	N	N	N	N	N
CARCINOMA, NOS																									
SQUAMOUS CELL CARCINOMA																									
ADENOMA, NOS																									
NERVOUS SYSTEM																									
BRAIN	+	+	+	+	+	+	+	+	+	+	+	+	+	+	+	+	+	+	+	+	+	+	+	+	+
CARCINOMA, NOS, INVASIVE																							X		
ASTROCYTOMA																X									
SPECIAL SENSE ORGANS																									
ZYMBAL GLAND	+	+	+	+	+	+	+	+	+	+	+	+	+	+	+	+	+	+	+	+	+	+	+	+	+
CARCINOMA, NOS					X																				
SQUAMOUS CELL CARCINOMA																									
MUSCULOSKELETAL SYSTEM																									
BONE	N	N	N	N	+	N	N	N	N	N	N	N	N	N	N	N	N	N	N	N	N	N	N	N	N
OSTEOSARCOMA																									
BODY CAVITIES																									
PERITONEUM	N	N	N	N	N	N	N	N	N	N	N	N	N	N	N	N	N	N	N	N	N	N	N	N	N
MESOTHELIOMA, INVASIVE																									
TUNICA VAGINALIS	+	+	+	+	+	+	+	+	+	+	+	+	+	+	+	+	+	+	+	+	+	+	+	+	+
MESOTHELIOMA, NOS																	X								
MESOTHELIOMA, MALIGNANT																									
MESENTERY	N	N	N	N	N	N	N	N	N	N	N	N	N	N	N	N	N	N	N	N	N	N	N	N	N
MESOTHELIOMA, INVASIVE																									
ALL OTHER SYSTEMS																									
MULTIPLE ORGANS NOS	N	N	N	N	N	N	N	N	N	N	N	N	N	N	N	N	N	N	N	N	N	N	N	N	N
C-CELL CARCINOMA, METASTATIC																									
SARCOMA, NOS, INVASIVE															X										
MESOTHELIOMA, INVASIVE																	X								
OSTEOSARCOMA, METASTATIC																									
MALIG.LYMPHOMA, HISTIOCYTIC TYPE																				X					
MONOCYTIC LEUKEMIA				X		X			X	X	X													X	X
LEUKEMIA, MONONUCLEAR CELL																						X			

+: TISSUE EXAMINED MICROSCOPICALLY
−: REQUIRED TISSUE NOT EXAMINED MICROSCOPICALLY
X: TUMOR INCIDENCE
N: NECROPSY, NO AUTOLYSIS, NO MICROSCOPIC EXAMINATION
S: ANIMAL MIS-SEXED
: NO TISSUE INFORMATION SUBMITTED
C: NECROPSY, NO HISTOLOGY DUE TO PROTOCOL
A: AUTOLYSIS
M: ANIMAL MISSING
B: NO NECROPSY PERFORMED

HWBUI0001636

TABLE B3. INDIVIDUAL ANIMAL TUMOR PATHOLOGY OF MALE RATS IN THE LIFETIME FEED STUDY OF INTERMEDIATE-RANGE CHRYSOTILE ASBESTOS: UNTREATED CONTROL (Continued)

ANIMAL NUMBER	2 9 3	2 9 6	2 9 7	2 9 8	2 9 9	3 0 0	3 0 1	3 0 2	3 0 3	3 0 4	3 0 5	3 0 6	3 0 7	3 0 8	3 0 9	3 1 0	3 1 1	3 1 2	3 1 3	3 1 4	3 1 5	3 1 6	3 1 7	3 1 8	3 1 9
WEEKS ON STUDY	1 4 4	1 0 9	1 2 1	1 0 4	1 4 8	1 1 9	1 8 9	1 1 3	1 2 9	1 3 4	1 4 4	1 1 8	1 2 7	1 2 0	1 3 8	1 0 5	1 3 5	1 0 9	1 0 9	1 2 6	1 2 1	1 1 9	1 0 3	1 0 6	1 1 4
INTEGUMENTARY SYSTEM																								
SKIN	+	+	+	+	+	+	+	+	+	+	+	+	+	+	+	+	+	+	+	+	+	+	M	+	+
PAPILLOMA, NOS	X										X														
BASAL-CELL CARCINOMA													X												
KERATOACANTHOMA																									
SUBCUTANEOUS TISSUE	+	+	+	+	+	+	+	+	+	+	+	+	+	+	+	+	+	+	+	+	+	+	M	+	+
SQUAMOUS CELL CARCINOMA														X											
BASAL-CELL TUMOR																									
SARCOMA, NOS																									
FIBROMA			X											X	X				X						
FIBROSARCOMA					X	X		X	*																
RESPIRATORY SYSTEM																									
LUNGS AND BRONCHI	+	+	+	+	+	+	+	+	+	+	+	+	+	+	+	+	+	+	+	+	+	+	C	+	+
SQUAMOUS CELL CARCINOMA										X															
ALVEOLAR/BRONCHIOLAR CARCINOMA																									
C-CELL CARCINOMA, METASTATIC																									
PHEOCHROMOCYTOMA, METASTATIC												X													
TRACHEA	+	+	+	+	+	+	+	+	+	+	+	+	+	+	+	+	+	+	+	+	+	+	C	+	+
FIBROSARCOMA, INVASIVE																									
HEMATOPOIETIC SYSTEM																									
BONE MARROW	+	+	+	+	+	+	+	+	+	+	+	+	+	+	+	+	+	+	+	+	+	+	C	+	+
SPLEEN	+	+	+	+	+	+	+	+	+	+	+	+	+	+	+	+	+	+	+	+	+	+	C	+	+
LYMPH NODES	+	+	+	+	+	+	+	+	+	+	+	+	+	+	+	+	+	+	+	+	+	+	C	+	+
THYMUS	+	-	+	-	+	+	+	+	+	+	-	+	+	+	+	-	+	+	+	+	-	+	C	-	+
CIRCULATORY SYSTEM																									
HEART	+	+	+	+	+	+	+	+	+	+	+	+	+	+	+	+	+	+	+	+	+	+	C	+	+
ADENOCARCINOMA, NOS, METASTATIC																									
DIGESTIVE SYSTEM																									
SALIVARY GLAND	+	+	+	+	+	+	+	+	+	+	+	+	+	+	+	+	+	+	+	+	+	+	C	-	+
FIBROSARCOMA									X																
FIBROSARCOMA, INVASIVE																									
LIVER	+	+	+	+	+	+	+	+	+	+	+	+	+	+	+	+	+	+	+	+	+	+	C	+	+
NEOPLASTIC NODULE					X																				
HEPATOCELLULAR CARCINOMA																									
BILE DUCT	+	+	+	+	+	+	+	+	+	+	+	+	+	+	+	+	+	+	+	+	+	+	C	+	+
GALLBLADDER & COMMON BILE DUCT	M	M	M	M	M	M	M	+	M	M	M	M	M	M	M	M	M	M	M	M	M	M	M	M	M
PANCREAS	+	+	+	+	+	+	+	+	+	+	+	+	+	+	+	+	+	+	+	+	+	+	C	+	+
ACINAR-CELL ADENOMA																									
ACINAR-CELL CARCINOMA																									
ESOPHAGUS	+	+	+	+	+	+	+	+	+	+	+	+	+	+	+	+	+	+	+	+	+	+	C	-	+
STOMACH	+	+	+	+	+	+	+	+	+	+	+	+	+	+	+	+	+	+	+	+	+	+	C	+	+
SMALL INTESTINE	+	+	+	+	+	+	+	+	+	+	+	+	+	+	+	+	+	+	+	+	+	+	C	+	+
LEIOMYOMA																									
LARGE INTESTINE	+	+	+	+	+	+	+	+	+	+	+	+	+	+	+	+	+	+	+	+	+	+	C	+	+
HEMANGIOSARCOMA																				X					
URINARY SYSTEM																									
KIDNEY	+	+	+	+	+	+	+	+	+	+	+	+	+	+	+	+	+	+	+	+	+	+	C	+	+
URINARY BLADDER	+	+	+	+	+	+	+	+	+	+	+	+	+	+	+	+	+	+	+	+	+	+	C	+	+

HWBUI0001637

TABLE B3. INDIVIDUAL ANIMAL TUMOR PATHOLOGY OF MALE RATS IN THE LIFETIME FEED STUDY OF INTERMEDIATE-RANGE CHRYSOTILE ASBESTOS: UNTREATED CONTROL (Continued)

ANIMAL NUMBER	29 5	29 6	29 7	29 8	29 9	30 0	30 1	30 2	30 3	30 4	30 5	30 6	30 7	30 8	30 9	31 0	31 1	31 2	31 3	31 4	31 5	31 6	31 7	31 8	31 9
WEEKS ON STUDY	146	109	121	094	140	119	089	131	129	126	144	118	127	120	130	105	155	091	094	126	121	119	103	069	114
ENDOCRINE SYSTEM																									
PITUITARY	+	+	+	+	+	+	+	+	+	+	+	+	+	+	+	+	+	+	+	+	+	+	C	+	+
CARCINOMA, NOS																									
ADENOMA, NOS			X						X			X					X	X						
ADRENAL	+	+	+	+	+	+	+	+	+	+	+	+	+	+	+	+	+	+	+	+	+	+	C	+	+
CORTICAL CARCINOMA															X										
PHEOCHROMOCYTOMA	X	X					X				X		X												
PHEOCHROMOCYTOMA, MALIGNANT																									
THYROID	+	+	+	+	+	+	+	+	+	+	+	+	+	+	+	+	+	+	+	+	+	+	C	-	+
FOLLICULAR-CELL ADENOMA					X																				
FOLLICULAR-CELL CARCINOMA														X		X					X				
C-CELL ADENOMA	X			X				X		X		X													
C-CELL CARCINOMA																									
FIBROSARCOMA, INVASIVE																									
PARATHYROID	+	+	+	+	-	+	+	+	+	+	+	-	+	+	+	+	+	-	+	+	+	+	C	-	+
ADENOMA, NOS	X		X																						
C-CELL CARCINOMA, INVASIVE										X															
PANCREATIC ISLETS	+	+	+	+	+	+	+	+	+	+	+	+	+	+	+	+	+	+	+	+	+	+	C	+	+
ISLET-CELL ADENOMA																									
ISLET-CELL CARCINOMA																									
REPRODUCTIVE SYSTEM																									
MAMMARY GLAND	+	+	+	+	+	+	+	+	+	+	+	+	+	+	+	+	+	+	+	+	+	+	N	+	N
ADENOMA, NOS																									
FIBROADENOMA																									
TESTIS	+	+	+	+	+	+	+	+	+	+	+	+	+	+	+	+	+	+	+	+	+	+	C	+	+
INTERSTITIAL-CELL TUMOR	X	X	X	X	X	X	X	X	X	X	X	X	X	X	X	X	X		X	X	X	X			X
PROSTATE	+	+	+	+	+	+	+	+	+	+	+	+	+	+	+	+	+	+	+	+	+	+	C	+	+
MESOTHELIOMA, NOS																									
PREPUTIAL/CLITORAL GLAND	N	N	N	N	N	N	N	N	N	N	N	N	N	N	N	N	N	N	N	N	N	N	N	N	N
CARCINOMA, NOS																									
SQUAMOUS CELL CARCINOMA																									
ADENOMA, NOS										X															
NERVOUS SYSTEM																									
BRAIN	+	+	+	+	+	+	+	+	+	+	+	+	+	+	+	+	+	+	+	+	+	+	C	+	+
CARCINOMA, NOS, INVASIVE																									
ASTROCYTOMA																									
SPECIAL SENSE ORGANS																									
ZYMBAL GLAND	+	+	+	+	+	+	+	+	+	+	+	+	+	+	+	+	+	+	+	N	+	+	N	+	+
CARCINOMA, NOS																									
SQUAMOUS CELL CARCINOMA																									
MUSCULOSKELETAL SYSTEM																									
BONE	N	N	N	N	N	N	N	N	N	N	N	N	N	N	N	N	N	N	N	N	N	N	N	+	N
OSTEOSARCOMA																								X	
BODY CAVITIES																									
PERITONEUM	N	N	N	N	N	N	N	N	N	N	N	N	N	N	N	N	N	N	N	N	N	N	N	N	N
MESOTHELIOMA, INVASIVE				X																					
TUNICA VAGINALIS	+	+	+	+	+	+	+	+	+	+	+	+	+	+	+	+	+	+	+	+	+	+	N	+	+
MESOTHELIOMA, NOS													X												
MESOTHELIOMA, MALIGNANT				X																					
MESENTERY	N	N	N	N	N	N	N	N	N	N	N	N	N	N	N	N	N	N	N	N	N	N	N	N	N
MESOTHELIOMA, INVASIVE				X																					
ALL OTHER SYSTEMS																									
MULTIPLE ORGANS NOS	N	N	N	N	N	N	N	N	N	N	N	N	N	N	N	N	N	N	N	N	N	N	N	N	N
C-CELL CARCINOMA, METASTATIC																									
SARCOMA, NOS, INVASIVE																									
MESOTHELIOMA, INVASIVE																								X	
OSTEOSARCOMA, METASTATIC																							X		
MALIG.LYMPHOMA, HISTIOCYTIC TYPE																									
MONOCYTIC LEUKEMIA										X			X			X	X								X
LEUKEMIA, MONONUCLEAR CELL																									

HWBUI0001638

TABLE B3. INDIVIDUAL ANIMAL TUMOR PATHOLOGY OF MALE RATS IN THE LIFETIME FEED STUDY OF INTERMEDIATE-RANGE CHRYSOTILE ASBESTOS: UNTREATED CONTROL (Continued)

ANIMAL NUMBER	32001	32002	32003	32004	32005	32006	32007	32008	32009	32010	32011	32012	32013	32014	32015	32016	32017	32018	32019	32020	32021	32022	32023	32024	32025
WEEKS ON STUDY	10 1	14 3	14 4	12 9	11 2	12 4	14 4	13 4	13 7	14 4	14 2	10 2	12 2	12 8	10 8	13 1	13 9	13 1	13 9	13 1	10 8	11 2	11 8	13 7	12 6	13 5	10 8
INTEGUMENTARY SYSTEM																									
SKIN	N	+	+	+	+	+	+	+	+	+	+	+	+	+	+	+	+	+	+	+	+	+	+	+	+
PAPILLOMA, NOS																									X
BASAL-CELL CARCINOMA							X																		
KERATOACANTHOMA				X																					
SUBCUTANEOUS TISSUE	N	+	+	+	+	+	+	+	+	+	+	+	+	+	+	+	+	+	+	+	+	+	+	+	+
SQUAMOUS CELL CARCINOMA																									X
BASAL-CELL TUMOR																									
SARCOMA, NOS																									
FIBROMA				X							X		X	X	X										
FIBROSARCOMA																						X			
RESPIRATORY SYSTEM																									
LUNGS AND BRONCHI	C	+	+	+	+	+	+	+	+	+	+	+	+	+	+	+	+	+	+	+	+	+	+	+	+
SQUAMOUS CELL CARCINOMA																									
ALVEOLAR/BRONCHIOLAR CARCINOMA											X														
C-CELL CARCINOMA, METASTATIC																									
PHEOCHROMOCYTOMA, METASTATIC																									
TRACHEA	C	+	+	+	+	+	+	+	+	+	+	+	+	+	+	+	+	+	+	+	+	+	+	+	+
FIBROSARCOMA, INVASIVE																									
HEMATOPOIETIC SYSTEM																									
BONE MARROW	C	+	+	+	+	+	+	+	+	+	+	+	+	+	+	+	+	+	+	+	+	+	+	+	+
SPLEEN	C	+	+	+	+	+	+	+	+	+	+	+	+	+	+	+	+	+	+	+	+	+	+	+	+
LYMPH NODES	C	+	+	+	+	+	+	+	+	+	+	+	+	+	+	+	+	+	+	+	+	+	+	+	+
THYMUS	C	-	+	+	+	+	-	+	+	+	+	+	+	+	+	-	+	+	+	+	+	+	+	+	+
CIRCULATORY SYSTEM																									
HEART	C	+	+	+	+	+	+	+	+	+	+	+	+	+	+	+	+	+	+	+	+	+	+	+	+
ADENOCARCINOMA, NOS, METASTATIC																									
DIGESTIVE SYSTEM																									
SALIVARY GLAND	C	+	+	+	+	+	+	+	+	+	+	+	+	+	+	+	+	+	+	+	+	+	+	+	+
FIBROSARCOMA																									
FIBROSARCOMA, INVASIVE																									
LIVER	C	+	+	+	+	+	+	+	+	+	+	+	+	+	+	+	+	+	+	+	+	+	+	+	+
NEOPLASTIC NODULE																						X		X	
HEPATOCELLULAR CARCINOMA																									
BILE DUCT	C	+	+	+	+	+	+	+	+	+	+	+	+	+	+	+	+	+	+	+	+	+	+	+	+
GALLBLADDER & COMMON BILE DUCT	N	N	N	N	N	N	N	N	N	N	N	N	N	N	N	N	N	N	N	N	N	N	N	N	N
PANCREAS	C	+	+	+	+	+	+	+	+	+	+	+	+	+	+	+	+	+	+	+	+	+	+	+	+
ACINAR-CELL ADENOMA																X						X			
ACINAR-CELL CARCINOMA						X																			
ESOPHAGUS	C	+	+	+	+	+	+	+	+	+	+	+	+	+	+	+	+	+	+	+	+	+	+	+	+
STOMACH	C	+	+	+	+	+	+	+	+	+	+	+	+	+	+	+	+	+	+	+	+	+	+	+	+
SMALL INTESTINE	C	+	+	+	+	+	+	+	+	+	+	+	+	+	+	+	+	+	+	+	+	+	+	+	+
LEIOMYOMA														X											
LARGE INTESTINE	C	+	+	+	+	+	+	+	+	+	+	+	+	+	+	+	+	+	+	+	+	+	+	+	+
HEMANGIOSARCOMA																									
URINARY SYSTEM																									
KIDNEY	C	+	+	+	+	+	+	+	+	+	+	+	+	+	+	+	+	+	+	+	+	+	+	+	+
URINARY BLADDER	C	+	+	+	+	+	+	+	+	+	+	+	+	+	+	+	+	+	+	+	+	+	+	+	+

HWBUI0001639

TABLE B3. INDIVIDUAL ANIMAL TUMOR PATHOLOGY OF MALE RATS IN THE LIFETIME FEED STUDY OF INTERMEDIATE-RANGE CHRYSOTILE ASBESTOS: UNTREATED CONTROL (Continued)

ANIMAL NUMBER	320	321	322	323	324	325	326	327	328	329	330	331	332	333	334	335	336	337	338	339	340	341	342	343	344
WEEKS ON STUDY	101	143	144	129	112	124	146	136	137	146	142	102	128	108	132	139	111	088	112	086	118	137	126	133	083
ENDOCRINE SYSTEM																									
PITUITARY	C	+	+	+	+	+	+	+	+	+	+	+	+	+	+	+	+	+	+	+	+	+	+	+	+
CARCINOMA, NOS																									
ADENOMA, NOS								X					X		X										
ADRENAL	C	+	+	+	+	+	+	+	+	+	+	+	+	+	+	+	+	+	+	+	+	+	+	+	+
CORTICAL CARCINOMA																								X	
PHEOCHROMOCYTOMA		X		X		X										X					X			X	
PHEOCHROMOCYTOMA, MALIGNANT																									
THYROID	C	+	+	+	+	+	+	+	+	+	+	+	+	+	+	+	+	+	+	+	+	+	+	+	+
FOLLICULAR-CELL ADENOMA																									
FOLLICULAR-CELL CARCINOMA						X	X	X	X																
C-CELL ADENOMA		X	X	X	X			X										X	X				X		
C-CELL CARCINOMA																									
FIBROSARCOMA, INVASIVE																									
PARATHYROID	C	+	+	+	+	+	+	+	+	+	+	+	-	+	+	+	+	+	+	+	+	+	+	+	+
ADENOMA, NOS																									
C-CELL CARCINOMA, INVASIVE																									
PANCREATIC ISLETS	C	+	+	+	+	+	+	+	+	+	+	+	+	+	+	+	+	+	+	+	+	+	+	+	+
ISLET-CELL ADENOMA		X	X																						
ISLET-CELL CARCINOMA														X											
REPRODUCTIVE SYSTEM																									
MAMMARY GLAND	N	+	+	+	+	+	+	+	+	+	+	+	+	N	+	+	+	+	+	+	+	+	+	+	+
ADENOMA, NOS																									
FIBROADENOMA																								X	
TESTIS	C	+	+	+	+	+	+	+	+	+	+	+	+	+	+	+	+	+	+	+	+	+	+	+	+
INTERSTITIAL-CELL TUMOR		X	X	X	X	X	X	X	X	X	X	X	X	X	X	X	X	X	X	X	X	X	X	X	X
PROSTATE	C	+	+	+	+	+	+	+	+	+	+	+	+	+	+	+	+	+	+	+	+	+	+	+	+
MESOTHELIOMA, NOS																									
PREPUTIAL/CLITORAL GLAND	N	N	N	N	N	N	N	N	N	N	N	N	N	N	N	N	N	N	N	N	N	N	N	N	N
CARCINOMA, NOS																					X				
SQUAMOUS CELL CARCINOMA													X												
ADENOMA, NOS																									
NERVOUS SYSTEM																									
BRAIN	C	+	+	+	+	+	+	+	+	+	+	+	+	+	+	+	+	+	+	+	+	+	+	+	+
CARCINOMA, NOS, INVASIVE																									
ASTROCYTOMA																									
SPECIAL SENSE ORGANS																									
ZYMBAL GLAND	N	+	+	+	+	+	+	+	+	+	+	+	+	+	+	+	+	+	+	+	+	+	+	+	+
CARCINOMA, NOS																									
SQUAMOUS CELL CARCINOMA						X																			
MUSCULOSKELETAL SYSTEM																									
BONE	N	N	N	N	N	N	N	N	N	N	N	N	N	N	N	N	N	N	N	N	N	N	N	N	N
OSTEOSARCOMA				X																					
BODY CAVITIES																									
PERITONEUM	N	N	N	N	N	N	N	N	N	N	N	N	N	N	N	N	N	N	N	N	N	N	N	N	N
MESOTHELIOMA, INVASIVE																									
TUNICA VAGINALIS	M	+	+	+	+	+	+	+	+	+	+	+	+	+	+	+	+	+	+	+	+	+	+	+	+
MESOTHELIOMA, NOS																							X		
MESOTHELIOMA, MALIGNANT																									
MESENTERY	N	N	N	N	N	N	N	N	N	N	N	N	N	N	N	N	N	N	N	N	N	N	N	N	N
MESOTHELIOMA, INVASIVE																									
ALL OTHER SYSTEMS																									
MULTIPLE ORGANS NOS	N	N	N	N	N	N	N	N	N	N	N	N	N	N	N	N	N	N	N	N	N	N	N	N	N
C-CELL CARCINOMA, METASTATIC																		X							
SARCOMA, NOS, INVASIVE																									
MESOTHELIOMA, INVASIVE																									
OSTEOSARCOMA, METASTATIC																									
MALIG.LYMPHOMA, HISTIOCYTIC TYPE																									
MONOCYTIC LEUKEMIA		X			X			X				X	X		X		X		X	X			X	X	X
LEUKEMIA, MONONUCLEAR CELL									X																

HWBUI0001640

TABLE B3. INDIVIDUAL ANIMAL TUMOR PATHOLOGY OF MALE RATS IN THE LIFETIME FEED STUDY OF INTERMEDIATE-RANGE CHRYSOTILE ASBESTOS: UNTREATED CONTROL (Continued)

ANIMAL NUMBER	345	346	347	348	349	350	351	352	353	354	355	356	357	TOTAL TISSUES TUMORS
WEEKS ON STUDY	101	117	140	203	241	311	312	313	316	341	414	423	430	
INTEGUMENTARY SYSTEM														
SKIN	N	+	+	+	+	+	+	+	+	+	+	+	+	88N
PAPILLOMA, NOS									X					5
BASAL-CELL CARCINOMA														2
KERATOACANTHOMA														1
SUBCUTANEOUS TISSUE	N	+	+	+	+	+	+	+	+	+	+	+	+	88N
SQUAMOUS CELL CARCINOMA														3
BASAL-CELL TUMOR														1
SARCOMA, NOS														1
FIBROMA					X	X								17
FIBROSARCOMA									X					7
RESPIRATORY SYSTEM														
LUNGS AND BRONCHI	C	+	+	+	+	+	+	+	+	+	+	+	+	85
SQUAMOUS CELL CARCINOMA														1
ALVEOLAR/BRONCHIOLAR CARCINOMA				X										2
C-CELL CARCINOMA, METASTATIC														1
PHEOCHROMOCYTOMA, METASTATIC														1
TRACHEA	C	+	+	+	+	+	+	+	+	+	+	+	+	85
FIBROSARCOMA, INVASIVE														1
HEMATOPOIETIC SYSTEM														
BONE MARROW	C	+	+	+	+	+	+	+	+	+	+	+	+	84
SPLEEN	C	+	+	+	+	+	+	+	+	+	+	+	+	85
LYMPH NODES	C	+	+	+	+	+	+	+	+	+	+	+	+	85
THYMUS	C	+	-	-	+	+	+	+	+	+	+	-	+	62
CIRCULATORY SYSTEM														
HEART	C	+	+	+	+	+	+	+	+	+	+	+	+	85
ADENOCARCINOMA, NOS, METASTATIC														1
DIGESTIVE SYSTEM														
SALIVARY GLAND	C	+	+	+	+	+	+	+	+	+	+	+	+	84
FIBROSARCOMA														3
FIBROSARCOMA, INVASIVE														1
LIVER	C	+	+	+	+	+	+	+	+	+	+	+	+	85
NEOPLASTIC NODULE											X			6
HEPATOCELLULAR CARCINOMA									X					2
BILE DUCT	C	+	+	+	+	+	+	+	+	+	+	+	+	85
GALLBLADDER & COMMON BILE DUCT	N	N	N	N	N	N	N	N	N	N	N	N	N	88N
PANCREAS	C	+	+	+	+	+	+	+	+	+	+	+	+	85
ACINAR-CELL ADENOMA			X											3
ACINAR-CELL CARCINOMA														1
ESOPHAGUS	C	+	+	+	+	+	+	+	+	+	+	+	+	85
STOMACH	C	+	+	+	+	+	+	+	+	+	+	+	+	85
SMALL INTESTINE	C	+	+	+	+	+	+	+	+	+	+	+	+	85
LEIOMYOMA														1
LARGE INTESTINE	C	+	+	+	+	+	+	+	+	+	+	+	+	85
HEMANGIOSARCOMA														1
URINARY SYSTEM														
KIDNEY	C	+	+	+	+	+	+	+	+	+	+	+	+	85
URINARY BLADDER	C	+	+	+	+	+	-	+	+	+	+	+	+	84

HWBUI0001641

TABLE B3. INDIVIDUAL ANIMAL TUMOR PATHOLOGY OF MALE RATS IN THE LIFETIME FEED STUDY OF INTERMEDIATE-RANGE CHRYSOTILE ASBESTOS: UNTREATED CONTROL (Continued)

ANIMAL NUMBER	345	346	347	348	349	350	351	352	353	354	355	356	357	TOTAL TISSUES TUMORS
WEEKS ON STUDY	101	117	140	223	246	311	312	313	316	334	344	423	420	
ENDOCRINE SYSTEM														
PITUITARY	C	+	+	+	+	+	+	+	+	+	+	+	+	85
CARCINOMA, NOS		X												4
ADENOMA, NOS									X			X		14
ADRENAL	C	+	+	+	+	+	+	+	+	+	+	+	+	85
CORTICAL CARCINOMA														2
PHEOCHROMOCYTOMA			X							X		X		16
PHEOCHROMOCYTOMA, MALIGNANT														1
THYROID	C	+	+	+	+	+	+	+	+	+	+	+	+	84
FOLLICULAR-CELL ADENOMA													X	1
FOLLICULAR-CELL CARCINOMA														5
C-CELL ADENOMA													X	13
C-CELL CARCINOMA												X		19
FIBROSARCOMA, INVASIVE														1
PARATHYROID	C	+	+	+	+	+	+	+	+	+	+	+	+	78
ADENOMA, NOS														3
C-CELL CARCINOMA, INVASIVE														1
PANCREATIC ISLETS	C	+	+	+	+	+	+	+	+	+	+	+	+	85
ISLET-CELL ADENOMA								X			X			5
ISLET-CELL CARCINOMA														3
REPRODUCTIVE SYSTEM														
MAMMARY GLAND	N	+	+	+	+	+	+	+	+	+	+	+	+	88*
ADENOMA, NOS														1
FIBROADENOMA														3
TESTIS	C	+	+	+	+	+	-	+	+	+	+	+	+	84
INTERSTITIAL-CELL TUMOR		X	X	X	X	X		X	X	X	X	X	X	79
PROSTATE	C	+	+	+	+	+	+	+	+	+	+	+	+	85
MESOTHELIOMA, NOS														1
PREPUTIAL/CLITORAL GLAND	N	N	N	N	N	N	N	N	N	N	N	N	N	88*
CARCINOMA, NOS												X		2
SQUAMOUS CELL CARCINOMA														1
ADENOMA, NOS														1
NERVOUS SYSTEM														
BRAIN	C	+	+	+	+	+	+	+	+	+	+	+	+	85
CARCINOMA, NOS, INVASIVE		X												2
ASTROCYTOMA														1
SPECIAL SENSE ORGANS														
ZYMBAL GLAND	N	+	+	+	+	+	+	+	+	+	+	+	+	88*
CARCINOMA, NOS														1
SQUAMOUS CELL CARCINOMA														1
MUSCULOSKELETAL SYSTEM														
BONE	N	N	N	N	N	N	N	N	N	N	N	N	N	88*
OSTEOSARCOMA														2
BODY CAVITIES														
PERITONEUM	N	N	N	N	N	N	N	N	N	N	N	N	N	88*
MESOTHELIOMA, INVASIVE														1
TUNICA VAGINALIS	N	+	+	+	+	+	N	+	+	+	+	+	+	88*
MESOTHELIOMA, NOS														2
MESOTHELIOMA, MALIGNANT														2
MESENTERY	N	N	N	N	N	N	N	N	N	N	N	N	N	88*
MESOTHELIOMA, INVASIVE														1
ALL OTHER SYSTEMS														
MULTIPLE ORGANS NOS	N	N	N	N	N	N	N	N	N	N	N	N	N	88*
C-CELL CARCINOMA, METASTATIC														1
SARCOMA, NOS, INVASIVE														1
MESOTHELIOMA, INVASIVE														1
OSTEOSARCOMA, METASTATIC														1
MALIG.LYMPHOMA, HISTIOCYTIC TYPE														1
MONOCYTIC LEUKEMIA				X			X				X	X		28
LEUKEMIA, MONONUCLEAR CELL														3

* ANIMALS NECROPSIED

HWBUI0001642

TABLE B3. INDIVIDUAL ANIMAL TUMOR PATHOLOGY OF MALE RATS IN THE LIFETIME FEED STUDY OF INTERMEDIATE-RANGE CHRYSOTILE ASBESTOS: 1,2-DIMETHYLHYDRAZINE DIHYDROCHLORIDE

ANIMAL NUMBER	44 46	44 47	44 48	44 49	45 50	45 51	45 52	45 53	45 54	45 55	45 56	45 57	45 58	45 59	46 60	46 61	46 62	46 63	46 64	46 65	46 66	46 67	46 68	46 69	47 70
WEEKS ON STUDY	112 8	122 2	122 9	111 1	065 5	095 2	099 2	127 9	077 1	041 1	122 4	122 9	121 9	117 1	128 9	085 2	092 2	088 1	081 1	122 9	129 1	118 9	099 0	088 0	091 1
INTEGUMENTARY SYSTEM																									
SKIN	+	+	+	+	+	+	+	+	N	+	+	+	+	+	+	+	+	+	+	+	+	+	+	+	+
SQUAMOUS CELL PAPILLOMA			X									X													
SQUAMOUS CELL CARCINOMA																									
TRICHOEPITHELIOMA						X					X		X												
KERATOACANTHOMA																				X	X				
SUBCUTANEOUS TISSUE	+	+	+	+	+	+	+	+	N	+	+	+	+	+	+	+	+	+	+	+	+	+	+	+	+
SQUAMOUS CELL CARCINOMA																									
TRICHOEPITHELIOMA																									
SARCOMA, NOS			X								X														
FIBROMA																									
FIBROSARCOMA																									
LIPOMA																									
RESPIRATORY SYSTEM																									
LUNGS AND BRONCHI	+	+	+	+	+	+	+	+	+	+	+	+	+	+	+	+	+	+	+	+	+	+	+	+	+
ADENOCARCINOMA, NOS, METASTATIC																									
ALVEOLAR/BRONCHIOLAR ADENOMA																									
C-CELL CARCINOMA, METASTATIC	X																								
FIBROSARCOMA, METASTATIC																	X								
HEMANGIOSARCOMA, METASTATIC																									
OSTEOSARCOMA, METASTATIC																									
TRACHEA	+	+	+	+	+	+	+	+	+	+	+	+	+	+	+	+	+	+	+	+	+	+	+	+	+
NASAL CAVITY	N	N	N	N	N	N	N	N	N	N	N	N	N	N	N	N	N	N	N	N	+	N	N	N	N
ADENOMA, NOS																					X				
HEMATOPOIETIC SYSTEM																									
BONE MARROW	+	+	+	+	+	+	+	+	+	+	+	+	+	+	+	+	+	+	+	+	+	–	+	+	+
SPLEEN	+	+	+	+	+	+	+	+	+	+	+	+	+	+	+	+	+	+	+	+	+	+	+	+	+
MALIG.LYMPHOMA, HISTIOCYTIC TYPE																									
LYMPH NODES	+	+	+	+	+	+	+	+	+	+	+	+	+	+	+	+	+	+	+	+	+	+	+	+	+
SQUAMOUS CELL CARCINOMA, METASTAT																									
MUCINOUS CYSTADENOCA, METASTATIC																									
SIGNET RING CARCINOMA, METASTATIC																									
SARCOMA, NOS																									
THYMUS	+	+	+	+	+	+	+	+	+	+	+	+	+	+	+	+	+	+	+	+	+	+	+	+	+
CIRCULATORY SYSTEM																									
HEART	+	+	+	+	+	+	+	+	+	+	+	+	+	+	+	+	+	+	+	+	+	+	+	+	+
DIGESTIVE SYSTEM																									
SALIVARY GLAND	+	+	+	+	+	+	+	+	+	+	+	+	+	+	+	+	+	+	+	+	+	+	+	+	+
SARCOMA, NOS																									
LIVER	+	+	+	+	+	+	+	+	+	+	+	+	+	+	+	+	+	+	+	+	+	+	+	+	+
NEOPLASTIC NODULE		X									X														
HEPATOCELLULAR CARCINOMA				X									X												
HEMANGIOSARCOMA																									
MALIG.LYMPHOMA, HISTIOCYTIC TYPE																									
BILE DUCT	+	+	+	+	+	+	+	+	+	+	+	+	+	+	+	+	+	+	+	+	+	+	+	+	+
GALLBLADDER & COMMON BILE DUCT	N	N	N	N	N	N	N	N	N	N	N	N	N	N	N	N	N	N	N	N	N	N	N	N	N
PANCREAS	+	+	+	+	+	+	+	+	+	+	+	+	+	+	+	+	+	+	+	+	+	+	+	+	+
ADENOCARCINOMA, NOS													X	X											
ACINAR-CELL ADENOMA																									
ESOPHAGUS	+	+	+	+	+	+	+	+	+	+	+	+	+	+	+	+	+	+	+	+	+	+	+	+	+
STOMACH	+	+	+	+	+	+	+	+	+	+	+	+	+	+	+	+	+	+	+	+	+	+	+	+	+
SMALL INTESTINE	+	+	+	+	+	+	+	+	+	+	+	+	+	+	+	+	+	+	+	+	+	+	+	+	+
LARGE INTESTINE	+	+	+	+	+	+	+	+	+	+	+	+	+	+	+	+	+	+	+	+	+	+	+	+	+
ADENOCARCINOMA, NOS																							X		
ADENOMATOUS POLYP, NOS		X		X											X		X							X	
MUCINOUS CYSTADENOCARCINOMA									X	X															
MUCINOUS CYSTADENOCA, METASTATIC																									
SIGNET RING CARCINOMA																									
RECTUM	+	+	+	+	+	+	+	N	+	+	+	+	+	+	+	+	+	+	+	+	+	+	+	+	+
ADENOMATOUS POLYP, NOS																									

HWBUI0001643

TABLE B3. INDIVIDUAL ANIMAL TUMOR PATHOLOGY OF MALE RATS IN THE LIFETIME FEED STUDY OF INTERMEDIATE-RANGE CHRYSOTILE ASBESTOS: 1,2-DIMETHYLHYDRAZINE DIHYDROCHLORIDE (Continued)

ANIMAL NUMBER	446	447	448	449	450	451	452	453	454	455	456	457	458	459	460	461	462	463	464	465	466	467	468	469	470
WEEKS ON STUDY	128	122	129	111	065	095	092	091	077	041	124	129	129	117	129	085	092	088	101	129	118	099	088	091
URINARY SYSTEM																									
KIDNEY	+	+	+	+	+	+	+	+	+	+	+	+	+	+	+	+	+	+	+	+	+	+	+	+	+
TUBULAR-CELL ADENOCARCINOMA																									
MIXED TUMOR, MALIGNANT																			X						
URETER	N	N	N	N	N	N	N	N	N	N	N	N	N	N	N	N	N	N	N	N	N	N	N	N	N
MIXED TUMOR, MALIGNANT																			X						
URINARY BLADDER	+	+	+	+	+	+	+	+	+	+	+	+	+	+	+	+	+	+	+	+	+	+	+	+	+
PAPILLOMA, NOS																									
TRANSITIONAL-CELL PAPILLOMA																									
ENDOCRINE SYSTEM																									
PITUITARY	+	+	+	+	+	+	+	+	+	+	+	+	+	+	+	+	+	+	+	+	+	+	+	+	+
CARCINOMA, NOS	X																								
ADENOMA, NOS																						X			
ADRENAL	+	+	+	+	+	+	+	+	+	+	+	+	+	+	+	+	+	+	+	+	+	+	+	+	+
PHEOCHROMOCYTOMA							X	X				X			X							X			X
THYROID	+	+	+	+	+	+	+	+	+	+	+	+	+	+	+	+	+	+	+	+	+	+	+	+	+
FOLLICULAR-CELL ADENOMA																									
FOLLICULAR-CELL CARCINOMA			X								X		X												
C-CELL ADENOMA															X										X
C-CELL CARCINOMA	X										X					X						X			
PARATHYROID	+	+	+	+	+	+	+	+	+	+	+	+	+	+	+	+	+	+	+	+	+	+	+	+	+
ADENOMA, NOS																									
PANCREATIC ISLETS	+	+	+	+	+	+	+	+	+	+	+	+	+	+	+	+	+	+	+	+	+	+	+	+	+
ISLET-CELL ADENOMA																									
ISLET-CELL CARCINOMA															X										
REPRODUCTIVE SYSTEM																									
MAMMARY GLAND	+	+	+	+	+	+	+	+	+	+	+	+	+	+	+	+	+	+	+	+	+	+	+	+	+
ADENOMA, NOS																									
ADENOCARCINOMA, NOS																									
FIBROADENOMA											X														
TESTIS	+	+	+	+	+	+	+	+	+	+	+	+	+	+	+	+	+	+	+	+	+	+	+	+	+
INTERSTITIAL-CELL TUMOR	X	X	X	X		X	X	X	X		X	X	X	X	X	X	X	X	X	X	X	X	X	X	X
INTERSTITIAL-CELL TUMOR, MALIGNAN																									
PROSTATE	+	+	+	+	+	+	+	+	+	+	+	+	+	+	+	+	+	+	+	+	+	+	+	+	+
ADENOMA, NOS																						X			
PREPUTIAL/CLITORAL GLAND	N	N	N	N	N	N	N	N	N	N	N	N	N	N	N	N	N	N	N	N	N	N	N	N	N
CARCINOMA, NOS		X																							X
SQUAMOUS CELL CARCINOMA																									
NERVOUS SYSTEM																									
BRAIN	+	+	+	+	+	+	+	+	+	+	+	+	+	+	+	+	+	+	+	+	+	+	+	+	+
CARCINOMA, NOS, INVASIVE																									
SPINAL CORD	N	N	N	N	N	N	N	N	N	N	N	N	N	N	N	+	N	N	N	N	N	N	N	N	N
NEURILEMOMA, MALIGNANT																X									
SPECIAL SENSE ORGANS																									
EAR	+	+	+	+	+	+	+	+	+	+	+	+	+	+	+	+	+	+	+	+	+	+	+	+	+
FIBROSARCOMA																	X								
ZYMBAL GLAND	+	+	+	+	+	+	+	+	+	+	+	+	+	+	+	+	+	+	+	+	+	+	+	+	+
CARCINOMA, NOS																			X						
SQUAMOUS CELL PAPILLOMA																X									
SQUAMOUS CELL CARCINOMA																						X			
BODY CAVITIES																									
TUNICA VAGINALIS	+	+	+	+	+	+	+	+	+	+	+	+	+	+	+	+	+	+	+	+	+	+	+	+	+
MESOTHELIOMA, NOS																									
MESOTHELIOMA, MALIGNANT						X																			
MESENTERY	N	N	N	N	N	N	N	N	N	N	N	N	N	N	N	N	N	N	N	N	N	N	N	N	N
SARCOMA, NOS																									
ALL OTHER SYSTEMS																									
MULTIPLE ORGANS NOS	N	N	N	N	N	N	N	N	N	N	N	N	N	N	N	N	N	N	N	N	N	N	N	N	N
ADENOCARCINOMA, NOS, INVASIVE																									
ADENOCARCINOMA, NOS, METASTATIC																							X		
MUCINOUS CYSTADENOCA, METASTATIC									X	X															
MESOTHELIOMA, METASTATIC						X																			
MALIG.LYMPHOMA, HISTIOCYTIC TYPE																									
MONOCYTIC LEUKEMIA			X									X						X			X				
LEUKEMIA, MONONUCLEAR CELL															X										
BASE OF TAIL																									
RHABDOMYOSARCOMA																									
SCROTUM NOS																									
FIBROMA																									
MESOTHELIOMA, METASTATIC																									

HWBUI0001644

TABLE B3. INDIVIDUAL ANIMAL TUMOR PATHOLOGY OF MALE RATS IN THE LIFETIME FEED STUDY OF INTERMEDIATE-RANGE CHRYSOTILE ASBESTOS: 1,2-DIMETHYLHYDRAZINE DIHYDROCHLORIDE (Continued)

ANIMAL NUMBER	47101	47102	47103	47104	47105	47106	47107	47108	47109	47110	47111	47112	47113	47114	47115	47116	47117	47118	47119	47120	47121	47122	47123	47124	47125
WEEKS ON STUDY	07 4	08 8	12 7	09 9	12 1	12 9	09 2	11 1	10 8	04 2	09 5	08 1	11 8	12 1	11 4	07 9	05 4	12 9	12 9	07 7	07 7	11 9	12 5	11 6	10 0
INTEGUMENTARY SYSTEM																									
SKIN	+	+	+	+	+	+	+	+	+	+	+	+	+	+	+	N	+	+	+	+	+	+	+	+	+
SQUAMOUS CELL PAPILLOMA																									
SQUAMOUS CELL CARCINOMA																		X							
TRICHOEPITHELIOMA																									
KERATOACANTHOMA																									
SUBCUTANEOUS TISSUE	+	+	+	+	+	+	+	+	+	+	+	+	+	+	+	N	+	+	+	+	+	+	+	+	+
SQUAMOUS CELL CARCINOMA																								X	
TRICHOEPITHELIOMA																									
SARCOMA, NOS			X			X													X						
FIBROMA							X																		
FIBROSARCOMA												X													
LIPOMA																									
RESPIRATORY SYSTEM																									
LUNGS AND BRONCHI	+	+	+	+	+	+	+	+	+	+	+	+	+	+	+	+	+	+	+	+	+	+	+	+	+
ADENOCARCINOMA, NOS, METASTATIC																									
ALVEOLAR/BRONCHIOLAR ADENOMA																									
C-CELL CARCINOMA, METASTATIC																									
FIBROSARCOMA, METASTATIC																									
HEMANGIOSARCOMA, METASTATIC																									
OSTEOSARCOMA, METASTATIC																									
TRACHEA	+	+	+	+	+	+	+	+	+	+	+	+	+	+	+	–	+	+	+	+	+	+	+	+	+
NASAL CAVITY	N	N	N	N	N	N	N	N	N	N	N	N	N	N	N	N	N	+	N	N	N	N	N	N	N
ADENOMA, NOS																		X							
HEMATOPOIETIC SYSTEM																									
BONE MARROW	+	+	+	+	+	+	+	+	+	+	+	+	+	+	+	–	+	+	+	+	+	+	+	+	+
SPLEEN	+	+	+	+	+	+	+	+	+	+	+	+	+	+	+	+	+	+	+	+	+	+	+	+	+
MALIG.LYMPHOMA, HISTIOCYTIC TYPE																									
LYMPH NODES	+	+	+	+	+	+	+	+	+	+	+	+	+	+	+	+	+	+	+	+	+	+	+	+	+
SQUAMOUS CELL CARCINOMA, METASTAT																				X					
MUCINOUS CYSTADENOCA, METASTATIC																									
SIGNET RING CARCINOMA, METASTATIC																									
SARCOMA, NOS																									
THYMUS	–	+	+	+	+	+	+	+	+	+	+	+	+	+	–	–	+	+	–	+	+	+	+	+	+
CIRCULATORY SYSTEM																									
HEART	+	+	+	+	+	+	+	+	+	+	+	+	+	+	+	+	+	+	+	+	+	+	+	+	+
DIGESTIVE SYSTEM																									
SALIVARY GLAND	+	+	+	+	+	+	+	+	+	+	+	+	+	–	+	+	+	+	+	+	+	+	+	+	+
SARCOMA, NOS				X	X			X																	
LIVER	+	+	+	+	+	+	+	+	+	+	+	+	+	+	+	+	+	+	+	+	+	+	+	+	+
NEOPLASTIC NODULE									+																
HEPATOCELLULAR CARCINOMA					X				X									X				X			
HEMANGIOSARCOMA																									
MALIG.LYMPHOMA, HISTIOCYTIC TYPE																							X		
BILE DUCT	+	+	+	+	+	+	+	+	+	+	+	+	+	+	+	+	+	+	+	+	+	+	+	+	+
GALLBLADDER & COMMON BILE DUCT	N	N	N	N	N	N	N	N	N	N	N	N	N	N	N	N	N	N	N	N	N	N	N	N	N
PANCREAS	+	+	+	+	+	+	+	+	+	+	+	+	+	+	+	+	+	+	+	+	+	+	+	+	+
ADENOCARCINOMA, NOS																			X				X		
ACINAR-CELL ADENOMA																									
ESOPHAGUS	+	+	+	+	+	+	+	+	+	+	+	+	+	+	+	+	+	+	+	+	+	+	+	+	+
STOMACH	+	+	+	+	+	+	+	+	+	+	+	+	+	+	+	+	+	+	+	+	+	+	+	+	+
SMALL INTESTINE	+	+	+	+	+	+	+	+	+	+	+	+	+	+	+	+	+	+	+	+	+	+	+	+	+
LARGE INTESTINE	+	+	+	+	+	+	+	+	+	+	+	+	+	+	+	+	+	+	+	+	+	+	+	+	+
ADENOCARCINOMA, NOS										X	X													X	
ADENOMATOUS POLYP, NOS																									
MUCINOUS CYSTADENOCARCINOMA																				X					
MUCINOUS CYSTADENOCA, METASTATIC																				X					
SIGNET RING CARCINOMA																									
RECTUM	+	+	+	+	+	+	+	+	+	+	+	+	+	+	+	+	+	+	+	+	+	+	+	+	+
ADENOMATOUS POLYP, NOS																							X		

HWBUI0001645

TABLE B3. INDIVIDUAL ANIMAL TUMOR PATHOLOGY OF MALE RATS IN THE LIFETIME FEED STUDY OF INTERMEDIATE-RANGE CHRYSOTILE ASBESTOS: 1,2-DIMETHYLHYDRAZINE DIHYDROCHLORIDE (Continued)

ANIMAL NUMBER	471	472	473	474	475	476	477	478	479	480	481	482	483	484	485	486	487	488	489	490	491	492	493	494	495
WEEKS ON STUDY	074	080	127	099	121	129	092	111	108	042	095	081	110	121	114	079	054	129	129	077	077	119	129	116	108
URINARY SYSTEM																									
KIDNEY	+	+	+	+	+	+	+	+	+	+	+	+	+	+	+	+	+	+	+	+	+	+	+	+	+
TUBULAR-CELL ADENOCARCINOMA																									
MIXED TUMOR, MALIGNANT																									
URETER	N	N	N	N	N	N	N	N	N	N	N	N	N	N	N	N	N	N	N	N	N	N	N	N	N
MIXED TUMOR, MALIGNANT																									
URINARY BLADDER	+	+	+	+	+	+	+	+	+	+	+	+	+	+	+	+	+	+	+	+	+	+	+	+	+
PAPILLOMA, NOS																									
TRANSITIONAL-CELL PAPILLOMA																									
ENDOCRINE SYSTEM																									
PITUITARY	+	+	+	+	+	+	+	+	+	+	+	+	+	+	+	+	-	+	+	+	+	+	+	+	+
CARCINOMA, NOS																									
ADENOMA, NOS						X									X			X	X				X		
ADRENAL	+	+	+	+	+	+	+	+	+	+	+	+	+	+	+	+	+	+	+	+	+	+	+	+	+
PHEOCHROMOCYTOMA						X			X						X			X	X					X	
THYROID	+	+	+	+	+	+	+	+	+	+	+	+	-	+	+	+	+	+	+	+	+	+	+	+	+
FOLLICULAR-CELL ADENOMA																									
FOLLICULAR-CELL CARCINOMA									X														X		
C-CELL ADENOMA						X	X																		X
C-CELL CARCINOMA														X	X										
PARATHYROID	+	-	+	+	+	+	+	+	-	+	+	+	-	-	+	+	+	+	+	+	+	+	+	+	+
ADENOMA, NOS																									
PANCREATIC ISLETS	+	+	+	+	+	+	+	+	+	+	+	+	+	+	+	+	+	+	+	+	+	+	+	+	+
ISLET-CELL ADENOMA						X																			
ISLET-CELL CARCINOMA																			X					X	
REPRODUCTIVE SYSTEM																									
MAMMARY GLAND	+	+	+	+	+	+	+	N	+	+	+	+	+	+	N	+	N	+	+	+	+	+	+	+	+
ADENOMA, NOS														X											
ADENOCARCINOMA, NOS																									
FIBROADENOMA																									
TESTIS	+	+	+	+	+	+	+	+	+	+	+	+	+	+	+	+	+	+	+	+	+	+	+	+	+
INTERSTITIAL-CELL TUMOR	X	X	X	X	X	X	X	X	X		X	X	X	X	X	X		X	X		X	X	X	X	X
INTERSTITIAL-CELL TUMOR, MALIGNAN																									
PROSTATE	+	+	+	+	+	+	+	+	+	+	+	+	+	+	+	+	+	+	+	+	+	+	+	+	+
ADENOMA, NOS																									
PREPUTIAL/CLITORAL GLAND	N	N	N	N	N	N	N	N	N	N	N	N	N	N	N	N	N	N	N	N	N	N	N	N	N
CARCINOMA, NOS											X														
SQUAMOUS CELL CARCINOMA																								X	
NERVOUS SYSTEM																									
BRAIN	+	+	+	+	+	+	+	+	+	+	+	+	+	+	+	+	+	+	+	+	+	+	+	+	+
CARCINOMA, NOS, INVASIVE																									
SPINAL CORD	N	N	N	N	N	N	N	N	N	N	N	N	N	N	N	N	N	N	N	N	N	N	N	N	N
NEURILEMOMA, MALIGNANT																									
SPECIAL SENSE ORGANS																									
EAR	+	+	+	+	+	+	+	+	+	+	+	+	+	+	+	+	+	+	+	+	+	+	+	+	+
FIBROSARCOMA																									
ZYMBAL GLAND	+	+	+	+	+	+	+	+	+	+	+	+	+	+	+	+	+	+	+	+	+	+	+	+	+
CARCINOMA, NOS																									
SQUAMOUS CELL PAPILLOMA																									
SQUAMOUS CELL CARCINOMA					X													X		X					
BODY CAVITIES																									
TUNICA VAGINALIS	+	+	+	+	+	+	+	+	+	+	+	+	+	+	+	+	+	+	+	+	+	+	+	+	+
/MESOTHELIOMA, NOS																									
MESOTHELIOMA, MALIGNANT																							X		
MESENTERY	N	N	N	N	N	N	N	N	N	N	N	N	N	N	N	N	N	N	N	N	N	N	N	N	N
SARCOMA, NOS																									
ALL OTHER SYSTEMS																									
MULTIPLE ORGANS NOS	N	N	N	N	N	N	N	N	N	N	N	N	N	N	N	N	N	N	N	N	N	N	N	N	N
ADENOCARCINOMA, NOS, INVASIVE																									
ADENOCARCINOMA, NOS, METASTATIC																									
MUCINOUS CYSTADENOCA, METASTATIC																									
MESOTHELIOMA, METASTATIC																									
MALIG.LYMPHOMA, HISTIOCYTIC TYPE																									
MONOCYTIC LEUKEMIA	X	X	X	X				X	X				X	X	X	X		X					X	X	X
LEUKEMIA, MONONUCLEAR CELL																									
BASE OF TAIL																									
RHABDOMYOSARCOMA																									
SCROTUM NOS																									
FIBROMA			X																						
MESOTHELIOMA, METASTATIC																							X		

HWBUI0001646

TABLE B3. INDIVIDUAL ANIMAL TUMOR PATHOLOGY OF MALE RATS IN THE LIFETIME FEED STUDY OF INTERMEDIATE-RANGE CHRYSOTILE ASBESTOS: 1,2-DIMETHYLHYDRAZINE DIHYDROCHLORIDE (Continued)

ANIMAL NUMBER	41 96	49 78	49 89	49 91	50 01	50 12	50 23	50 45	50 56	50 67	50 78	50 89	51 01	51 12	51 23	51 45	51 56	51 67	51 78	51 89	52 00
WEEKS ON STUDY	89 04	10 09	12 11	11 11	11 12	11 09	07 08	09 09	09 05	08 09	06 03	08 08	09 11	09 12	08 08	08 09	09 15	07 12	01 15	08 09	11 22
INTEGUMENTARY SYSTEM																					
SKIN	+	+	+	+	+	+	+	+	+	+	+	+	+	+	+	+	+	+	+	+	+
SQUAMOUS CELL PAPILLOMA				X																	
SQUAMOUS CELL CARCINOMA																					
TRICHOEPITHELIOMA			X									X									
KERATOACANTHOMA																					
SUBCUTANEOUS TISSUE	+	+	+	+	+	+	+	+	+	+	+	+	+	+	+	+	+	+	+	+	+
SQUAMOUS CELL CARCINOMA																					X
TRICHOEPITHELIOMA		X				X		X					X						X		
SARCOMA, NOS																					
FIBROMA																					
FIBROSARCOMA																					
LIPOMA																			X		
RESPIRATORY SYSTEM																					
LUNGS AND BRONCHI	+	+	+	+	+	+	+	+	+	+	+	+	+	+	+	+	+	+	+	+	+
ADENOCARCINOMA, NOS, METASTATIC												X									
ALVEOLAR/BRONCHIOLAR ADENOMA																					
C-CELL CARCINOMA, METASTATIC																					
FIBROSARCOMA, METASTATIC																					
HEMANGIOSARCOMA, METASTATIC						X															
OSTEOSARCOMA, METASTATIC																					
TRACHEA	+	+	+	+	+	+	+	+	+	+	+	+	+	+	+	+	+	+	+	+	+
NASAL CAVITY	N	N	N	N	N	N	N	N	+	N	N	N	N	N	N	N	N	N	N	N	N
ADENOMA, NOS																					
HEMATOPOIETIC SYSTEM																					
BONE MARROW	+	+	+	+	+	+	+	+	+	+	+	+	+	+	+	+	+	+	+	+	+
SPLEEN	+	+	+	+	+	+	+	+	+	+	+	+	+	+	+	+	+	+	+	+	+
MALIG.LYMPHOMA, HISTIOCYTIC TYPE																					
LYMPH NODES	+	+	+	+	+	+	+	+	+	+	+	+	+	+	+	+	+	+	+	+	+
SQUAMOUS CELL CARCINOMA, METASTAT				X																	
MUCINOUS CYSTADENOCA, METASTATIC												X									
SIGNET RING CARCINOMA, METASTATIC																					
SARCOMA, NOS		X																			
THYMUS	+	+	+	+	-	+	+	+	+	+	+	+	-	+	+	+	+	+	-	+	+
CIRCULATORY SYSTEM																					
HEART	+	+	+	+	+	+	+	+	+	+	+	+	+	+	+	+	+	+	+	+	+
DIGESTIVE SYSTEM																					
SALIVARY GLAND	+	+	+	+	+	+	+	+	+	+	+	+	+	+	+	+	+	+	+	+	+
SARCOMA, NOS		X				X														X	
LIVER	+	+	+	+	+	+	+	+	+	+	+	+	+	+	+	+	+	+	+	+	+
NEOPLASTIC NODULE	X																				
HEPATOCELLULAR CARCINOMA	X		X				X											X			X
HEMANGIOSARCOMA							X														
MALIG.LYMPHOMA, HISTIOCYTIC TYPE																					
BILE DUCT	+	+	+	+	+	+	+	+	+	+	+	+	+	+	+	+	+	+	+	+	+
GALLBLADDER & COMMON BILE DUCT	N	N	N	N	N	N	N	N	N	N	N	N	N	N	N	N	N	N	N	N	N
PANCREAS	+	+	+	+	+	+	+	+	+	+	-	+	+	+	+	+	+	+	+	+	+
ADENOCARCINOMA, NOS																X					
ACINAR-CELL ADENOMA																					
ESOPHAGUS	+	+	+	+	+	+	+	+	+	+	+	+	+	+	+	+	+	+	+	+	+
STOMACH	+	+	+	+	+	+	+	+	+	+	+	+	+	+	+	+	+	+	+	+	+
SMALL INTESTINE	+	+	+	+	+	+	+	+	+	+	+	+	+	+	+	+	+	+	+	+	+
LARGE INTESTINE	+	+	+	+	+	+	+	+	+	+	+	+	+	+	+	+	+	+	+	+	+
ADENOCARCINOMA, NOS																					
ADENOMATOUS POLYP, NOS		X			X		X			X	X					X			X		
MUCINOUS CYSTADENOCARCINOMA												X						X			
MUCINOUS CYSTADENOCA, METASTATIC																					
SIGNET RING CARCINOMA												X									
RECTUM	+	+	+	+	+	+	+	+	+	+	+	+	+	+	+	+	+	+	+	+	+
ADENOMATOUS POLYP, NOS																					

HWBUI0001647

TABLE B3. INDIVIDUAL ANIMAL TUMOR PATHOLOGY OF MALE RATS IN THE LIFETIME FEED STUDY OF INTERMEDIATE-RANGE CHRYSOTILE ASBESTOS: 1,2-DIMETHYLHYDRAZINE DIHYDROCHLORIDE (Continued)

ANIMAL NUMBER	496	497	498	499	500	501	502	503	504	505	506	507	508	509	510	511	512	513	514	515	516	517	518	519	520
WEEKS ON STUDY	094	100	129	111	111	129	119	078	094	095	089	063	091	088	091	119	082	080	106	095	087	092	125	095	122
URINARY SYSTEM																									
KIDNEY	+	+	+	+	+	+	+	+	+	+	+	+	+	+	+	+	+	+	+	+	+	+	+	+	+
TUBULAR-CELL ADENOCARCINOMA									X																
MIXED TUMOR, MALIGNANT																									
URETER	N	N	N	N	N	N	N	N	N	N	N	N	N	N	N	N	N	N	N	N	N	N	N	N	N
MIXED TUMOR, MALIGNANT																									
URINARY BLADDER	+	+	+	+	+	+	+	+	+	+	+	+	+	+	+	+	+	+	+	+	+	+	+	+	+
PAPILLOMA, NOS																									
TRANSITIONAL-CELL PAPILLOMA																									
ENDOCRINE SYSTEM																									
PITUITARY	+	+	+	+	+	+	+	+	+	+	+	+	+	+	+	+	+	+	+	+	+	+	+	+	+
CARCINOMA, NOS														X					X						
ADENOMA, NOS			X		X																		X		
ADRENAL	+	+	+	+	+	+	+	+	+	+	+	+	+	+	+	+	+	+	+	+	+	+	+	+	+
PHEOCHROMOCYTOMA				X																					
THYROID	+	+	+	+	+	+	+	+	+	+	+	+	+	+	+	+	+	+	+	+	+	+	+	+	+
FOLLICULAR-CELL ADENOMA							X																		
FOLLICULAR-CELL CARCINOMA			X																						
C-CELL ADENOMA				X							X				X										
C-CELL CARCINOMA				X																				X	
PARATHYROID	+	+	+	+	+	+	+	+	+	+	+	+	+	+	+	+	+	+	+	+	+	+	+	+	+
ADENOMA, NOS																							X		
PANCREATIC ISLETS	+	+	+	+	+	+	+	+	+	+	+	-	+	+	+	+	+	+	+	+	+	+	+	+	+
ISLET-CELL ADENOMA																									
ISLET-CELL CARCINOMA																									
REPRODUCTIVE SYSTEM																									
MAMMARY GLAND	+	+	+	+	+	+	+	+	+	+	+	+	+	+	N	+	+	+	+	+	+	+	+	+	+
ADENOMA, NOS																									
ADENOCARCINOMA, NOS																									
FIBROADENOMA																									
TESTIS	+	+	+	+	+	+	+	+	+	+	+	+	+	+	+	+	+	+	+	+	+	+	+	+	+
INTERSTITIAL-CELL TUMOR	X	X	X	X		X	X			X	X		X		X	X	X	X	X	X	X		X	X	X
INTERSTITIAL-CELL TUMOR, MALIGNAN									X																
PROSTATE	+	+	+	+	+	+	+	+	+	+	+	+	+	+	+	+	+	+	+	+	+	+	+	+	+
ADENOMA, NOS																									
PREPUTIAL/CLITORAL GLAND	N	N	N	N	N	N	N	N	N	N	N	N	N	N	N	N	N	N	N	N	N	N	N	N	N
CARCINOMA, NOS										X															
SQUAMOUS CELL CARCINOMA																									
NERVOUS SYSTEM																									
BRAIN	+	+	+	+	+	+	+	+	+	+	+	+	+	+	+	+	+	+	+	+	+	+	+	+	+
CARCINOMA, NOS, INVASIVE																			X						
SPINAL CORD	N	N	N	N	N	N	N	N	N	N	N	N	N	N	N	N	N	N	N	N	N	N	N	N	N
NEURILEMOMA, MALIGNANT																									
SPECIAL SENSE ORGANS																									
EAR	+	+	+	+	+	+	+	+	+	+	+	+	+	+	+	+	+	+	+	+	+	N	+	+	+
FIBROSARCOMA																									
ZYMBAL GLAND	+	+	+	+	+	+	+	+	+	+	+	+	+	+	+	+	+	+	+	+	+	N	+	+	+
CARCINOMA, NOS																									
SQUAMOUS CELL PAPILLOMA								X	X																
SQUAMOUS CELL CARCINOMA																							X		
BODY CAVITIES																									
TUNICA VAGINALIS	+	+	+	+	+	+	+	+	+	+	+	+	+	+	+	+	+	+	+	+	+	+	+	+	+
MESOTHELIOMA, NOS																									
MESOTHELIOMA, MALIGNANT							X																		
MESENTERY	N	N	N	N	N	N	N	N	N	N	N	N	N	N	N	N	N	N	N	N	N	N	N	N	N
SARCOMA, NOS																							X		
ALL OTHER SYSTEMS																									
MULTIPLE ORGANS NOS	N	N	N	N	N	N	N	N	N	N	N	N	N	N	N	N	N	N	N	N	N	N	N	N	N
ADENOCARCINOMA, NOS, INVASIVE																	X								
ADENOCARCINOMA, NOS, METASTATIC												X													
MUCINOUS CYSTADENOCA, METASTATIC																									
MESOTHELIOMA, METASTATIC							X																		
MALIG.LYMPHOMA, HISTIOCYTIC TYPE																									
MONOCYTIC LEUKEMIA	X	X			X														X	X				X	
LEUKEMIA, MONONUCLEAR CELL																									
BASE OF TAIL																									
RHABDOMYOSARCOMA																									
SCROTUM NOS																									
FIBROMA																									
MESOTHELIOMA, METASTATIC																									

HWBUI0001648

TABLE B3. INDIVIDUAL ANIMAL TUMOR PATHOLOGY OF MALE RATS IN THE LIFETIME FEED STUDY OF INTERMEDIATE-RANGE CHRYSOTILE ASBESTOS: 1,2-DIMETHYLHYDRAZINE DIHYDROCHLORIDE (Continued)

ANIMAL NUMBER	52 11	52 23	52 35	52 46	52 55	52 66	52 77	52 88	52 92	53 01	53 11	53 20	53 31	53 41	53 51	53 61	53 72	53 82	53 92	54 03	54 11	54 22	54 33	54 43	54 53	54 63
WEEKS ON STUDY	12 27	08 28	09 23	02 26	22 25	11 25	09 23	09 22	09 21	09 21	09 10	09 13	08 08	08 41	12 22	10 26	11 26	11 26	11 20	11 30	08 37	11 06	11 05	10 05	12 06	11 05
INTEGUMENTARY SYSTEM																										
SKIN	+	+	+	+	+	+	+	+	+	+	+	+	+	+	+	+	+	+	+	+	+	+	+	+	+	+
SQUAMOUS CELL PAPILLOMA																										
SQUAMOUS CELL CARCINOMA																										
TRICHOEPITHELIOMA																										
KERATOACANTHOMA																							X			
SUBCUTANEOUS TISSUE	+	+	+	+	+	+	+	+	+	+	+	+	+	+	+	+	+	+	+	+	+	+	+	+	+	+
SQUAMOUS CELL CARCINOMA																										
TRICHOEPITHELIOMA																										
SARCOMA, NOS																										
FIBROMA														X						X						
FIBROSARCOMA																										
LIPOMA																										
RESPIRATORY SYSTEM																										
LUNGS AND BRONCHI	+	+	+	+	+	+	+	+	+	+	+	+	+	+	+	+	+	+	+	+	+	+	+	+	+	+
ADENOCARCINOMA, NOS, METASTATIC				X																						
ALVEOLAR/BRONCHIOLAR ADENOMA																										
C-CELL CARCINOMA, METASTATIC																										
FIBROSARCOMA, METASTATIC																										
HEMANGIOSARCOMA, METASTATIC																										
OSTEOSARCOMA, METASTATIC																										
TRACHEA	+	+	+	+	+	+	+	+	+	+	+	+	+	+	+	+	+	+	+	+	+	+	+	+	+	+
NASAL CAVITY	M	M	M	M	M	M	M	M	M	M	M	M	M	M	M	M	M	M	M	M	M	M	M	M	M	M
ADENOMA, NOS																										
HEMATOPOIETIC SYSTEM																										
BONE MARROW	+	+	+	+	+	+	+	+	+	+	+	+	+	+	+	+	+	+	+	+	+	+	+	+	+	+
SPLEEN	+	+	+	+	+	+	+	+	+	+	+	+	+	+	+	+	+	+	+	+	+	+	+	+	+	+
MALIG.LYMPHOMA, HISTIOCYTIC TYPE																										
LYMPH NODES	+	+	+	+	+	+	+	+	+	+	+	+	+	+	+	+	+	+	+	+	+	+	+	+	+	+
SQUAMOUS CELL CARCINOMA, METASTAT																										
MUCINOUS CYSTADENOCA, METASTATIC																										
SIGNET RING CARCINOMA, METASTATIC																										
SARCOMA, NOS																										
THYMUS	+	+	+	-	+	-	+	+	+	+	+	+	+	+	-	+	-	+	+	-	+	-	+	+	+	+
CIRCULATORY SYSTEM																										
HEART	+	+	+	+	+	+	+	+	+	+	+	+	+	+	+	+	+	+	+	+	+	+	+	+	+	+
DIGESTIVE SYSTEM																										
SALIVARY GLAND	+	+	+	+	+	+	+	+	+	+	+	+	+	+	+	+	+	+	+	+	+	+	+	+	+	+
SARCOMA, NOS																										
LIVER	+	+	+	+	+	+	+	+	+	+	+	+	+	+	+	+	+	+	+	+	+	+	+	+	+	+
NEOPLASTIC NODULE															X											
HEPATOCELLULAR CARCINOMA																			X	X						
HEMANGIOSARCOMA																										
MALIG.LYMPHOMA, HISTIOCYTIC TYPE																										
BILE DUCT	+	+	+	+	+	+	+	+	+	+	+	+	+	+	+	+	+	+	+	+	+	+	+	+	+	+
GALLBLADDER & COMMON BILE DUCT	M	M	M	M	M	M	M	M	M	M	M	M	M	M	M	M	M	M	M	M	M	M	M	M	M	M
PANCREAS	+	+	+	+	+	+	+	+	+	+	+	+	+	+	+	+	+	+	+	+	+	+	+	+	+	+
ADENOCARCINOMA, NOS						X																		X		
ACINAR-CELL ADENOMA																										
ESOPHAGUS	+	+	+	+	+	+	+	+	+	+	+	+	+	+	+	+	+	+	+	+	+	+	+	+	+	+
STOMACH	+	+	+	+	+	+	+	+	+	+	+	+	+	+	+	+	+	+	+	+	+	+	+	+	+	+
SMALL INTESTINE	+	+	+	+	+	+	+	+	+	+	+	+	+	+	+	+	+	+	+	+	+	+	+	+	+	+
LARGE INTESTINE	+	+	+	+	+	+	+	+	+	+	+	+	+	+	+	+	+	+	+	+	+	+	+	+	+	+
ADENOCARCINOMA, NOS																										
ADENOMATOUS POLYP, NOS		X										X		X			X	X					X		X
MUCINOUS CYSTADENOCARCINOMA																										
MUCINOUS CYSTADENOCA, METASTATIC																										
SIGNET RING CARCINOMA																										
RECTUM	+	+	+	+	+	+	+	+	+	+	+	+	+	+	+	+	+	+	+	+	+	+	+	+	+	+
ADENOMATOUS POLYP, NOS																										

HWBUI0001649

TABLE B3. INDIVIDUAL ANIMAL TUMOR PATHOLOGY OF MALE RATS IN THE LIFETIME FEED STUDY OF INTERMEDIATE-RANGE CHRYSOTILE ASBESTOS: 1,2-DIMETHYLHYDRAZINE DIHYDROCHLORIDE (Continued)

ANIMAL NUMBER	52 52 52 52 52 52 52 52 52 53 53 53 53 53 53 53 53 53 53 53 54 54 54 54 54 54
WEEKS ON STUDY	10 20 01 11 11 09 09 09 09 10 10 10 10 10 10 11 11 11 11 11 11 11 11 11 11 11
	12 17 19 12 21 15 19 20 20 19 19 19 19 19 19 20 20 21 21 21 18 18 10 16 16 15
URINARY SYSTEM	
KIDNEY	+ +
TUBULAR-CELL ADENOCARCINOMA	
MIXED TUMOR, MALIGNANT	
URETER	N N N N N N N N N N N N N N N N N N N N N N N N N
MIXED TUMOR, MALIGNANT	
URINARY BLADDER	+ + + – +
PAPILLOMA, NOS	X
TRANSITIONAL-CELL PAPILLOMA	
ENDOCRINE SYSTEM	
PITUITARY	+ +
CARCINOMA, NOS	
ADENOMA, NOS	
ADRENAL	+ +
PHEOCHROMOCYTOMA	X
THYROID	+ +
FOLLICULAR-CELL ADENOMA	X
FOLLICULAR-CELL CARCINOMA	X X X X X
C-CELL ADENOMA	
C-CELL CARCINOMA	
PARATHYROID	+ + + + + + + + + + + + + – + + + + + + + + + + + +
ADENOMA, NOS	
PANCREATIC ISLETS	+ +
ISLET-CELL ADENOMA	
ISLET-CELL CARCINOMA	X
REPRODUCTIVE SYSTEM	
MAMMARY GLAND	+ +
ADENOMA, NOS	X
ADENOCARCINOMA, NOS	X
FIBROADENOMA	
TESTIS	+ +
INTERSTITIAL-CELL TUMOR	X X X X X X X X X X X X X X X X X X X X X X X X X
INTERSTITIAL-CELL TUMOR, MALIGNAN	
PROSTATE	+ +
ADENOMA, NOS	
PREPUTIAL/CLITORAL GLAND	N N N N N N N N N N N N N N N N N N N N N N N N N
CARCINOMA, NOS	
SQUAMOUS CELL CARCINOMA	
NERVOUS SYSTEM	
BRAIN	+ +
CARCINOMA, NOS, INVASIVE	
SPINAL CORD	N N N N N N N N N N N N N N N N N N N N N N N N N
NEURILEMOMA, MALIGNANT	
SPECIAL SENSE ORGANS	
EAR	+ N +
FIBROSARCOMA	
ZYMBAL GLAND	+ N +
CARCINOMA, NOS	
SQUAMOUS CELL PAPILLOMA	X
SQUAMOUS CELL CARCINOMA	X X X X
BODY CAVITIES	
TUNICA VAGINALIS	+ +
MESOTHELIOMA, NOS	X
MESOTHELIOMA, MALIGNANT	X
MESENTERY	N N N N N N N N N N N N N N N N N N N N N N N N N
SARCOMA, NOS	
ALL OTHER SYSTEMS	
MULTIPLE ORGANS NOS	N N N N N N N N N N N N N N N N N N N N N N N N N
ADENOCARCINOMA, NOS, INVASIVE	
ADENOCARCINOMA, NOS, METASTATIC	
MUCINOUS CYSTADENOCA, METASTATIC	
MESOTHELIOMA, METASTATIC	X X
MALIG.LYMPHOMA, HISTIOCYTIC TYPE	X X
MONOCYTIC LEUKEMIA	X X X X X X X X X
LEUKEMIA, MONONUCLEAR CELL	X
BASE OF TAIL	
RHABDOMYOSARCOMA	
SCROTUM NOS	
FIBROMA	
MESOTHELIOMA, METASTATIC	

HWBUI0001650

TABLE B3. INDIVIDUAL ANIMAL TUMOR PATHOLOGY OF MALE RATS IN THE LIFETIME FEED STUDY OF INTERMEDIATE-RANGE CHRYSOTILE ASBESTOS: 1,2-DIMETHYLHYDRAZINE DIHYDROCHLORIDE (Continued)

ANIMAL NUMBER	546	547	548	549	550	551	552	553	554	555	556	557	558	559	560	561	562	563	564	565	566	567	568	569	570	TOTAL
WEEKS ON STUDY	115	101	129	122	090	079	124	081	117	117	080	129	070	102	111	129	059	091	118	102	112	121	079	129	102	TISSUES TUMORS
INTEGUMENTARY SYSTEM																										
SKIN	+	+	+	+	+	+	+	+	+	+	+	+	+	+	+	+	+	+	+	+	+	+	+	+	+	125
SQUAMOUS CELL PAPILLOMA																										2
SQUAMOUS CELL CARCINOMA																										2
TRICHOEPITHELIOMA																										4
KERATOACANTHOMA		X																						X		6
SUBCUTANEOUS TISSUE	+	+	+	+	+	+	+	+	+	+	+	+	+	+	+	+	+	+	+	+	+	+	+	+	+	125
SQUAMOUS CELL CARCINOMA																										1
TRICHOEPITHELIOMA				X																						1
SARCOMA, NOS																										2
FIBROMA		X	X													X										13
FIBROSARCOMA				X																						3
LIPOMA																										1
RESPIRATORY SYSTEM																										
LUNGS AND BRONCHI	+	+	+	+	+	+	+	+	+	+	+	+	+	+	+	+	+	+	+	+	+	+	+	+	+	125
ADENOCARCINOMA, NOS, METASTATIC																										1
ALVEOLAR/BRONCHIOLAR ADENOMA																										1
C-CELL CARCINOMA, METASTATIC																										1
FIBROSARCOMA, METASTATIC																										1
HEMANGIOSARCOMA, METASTATIC									X																	1
OSTEOSARCOMA, METASTATIC																										1
TRACHEA	+	+	+	+	+	+	+	+	+	+	+	+	+	+	+	+	+	+	+	+	+	+	+	+	+	124
NASAL CAVITY	N	N	N	N	N	N	N	N	N	N	N	N	N	N	N	N	N	N	N	N	N	N	N	N	N	125
ADENOMA, NOS																										2
HEMATOPOIETIC SYSTEM																										
BONE MARROW	-	+	+	+	+	+	+	+	+	+	+	+	+	+	+	+	+	+	+	+	+	+	+	+	+	122
SPLEEN	+	+	+	+	+	+	+	+	+	+	+	+	+	+	+	+	+	+	+	+	+	+	+	+	+	125
MALIG.LYMPHOMA, HISTIOCYTIC TYPE									X																	1
LYMPH NODES	+	+	+	+	+	+	+	+	+	+	+	+	+	+	+	+	+	+	+	+	+	+	+	+	+	125
SQUAMOUS CELL CARCINOMA, METASTAT																										1
MUCINOUS CYSTADENOCA, METASTATIC																										1
SIGNET RING CARCINOMA, METASTATIC																										1
SARCOMA, NOS																										1
THYMUS	+	+	+	-	+	+	-	+	+	+	+	+	+	+	+	+	+	+	+	+	-	-	+	-	+	107
CIRCULATORY SYSTEM																										
HEART	+	+	+	+	+	+	+	+	+	+	+	+	+	+	+	+	+	+	+	+	+	+	+	+	+	125
DIGESTIVE SYSTEM																										
SALIVARY GLAND	+	+	+	+	+	+	+	+	+	+	+	+	+	+	+	+	+	+	+	+	+	+	+	+	+	124
SARCOMA, NOS																										6
LIVER	+	+	+	+	+	+	+	+	+	+	+	+	+	+	+	+	+	+	+	+	+	+	+	+	+	125
NEOPLASTIC NODULE													X				X			X	X	X		X		12
HEPATOCELLULAR CARCINOMA					X		X											X		X					X	17
HEMANGIOSARCOMA									X																	2
MALIG.LYMPHOMA, HISTIOCYTIC TYPE																										1
BILE DUCT	+	+	+	+	+	+	+	+	+	+	+	+	+	+	+	+	+	+	+	+	+	+	+	+	+	125
GALLBLADDER & COMMON BILE DUCT	N	N	N	+	N	N	N	N	N	N	N	N	N	N	N	N	N	N	N	N	N	N	N	N	N	125
PANCREAS	+	+	+	+	+	+	+	+	+	+	+	+	+	+	+	+	+	+	+	+	+	+	+	+	+	124
ADENOCARCINOMA, NOS																										1
ACINAR-CELL ADENOMA			X																							7
ESOPHAGUS	+	+	+	+	+	+	+	+	+	+	+	+	+	+	+	+	+	+	+	+	+	+	+	+	+	125
STOMACH	+	+	+	+	+	+	+	+	+	+	+	+	+	+	+	+	+	+	+	+	+	+	+	+	-	124
SMALL INTESTINE	+	+	+	+	+	+	+	+	+	+	+	+	+	+	+	+	+	+	+	+	+	+	+	+	+	125
LARGE INTESTINE	+	+	+	+	+	+	+	+	+	+	+	+	+	+	+	+	+	+	+	+	+	+	+	+	+	125
ADENOCARCINOMA, NOS								X																		2
ADENOMATOUS POLYP, NOS		X				X			X		X					X		X	X			X		X		31
MUCINOUS CYSTADENOCARCINOMA				X																	X					7
MUCINOUS CYSTADENOCA, METASTATIC																										1
SIGNET RING CARCINOMA																										1
RECTUM	+	+	+	+	+	+	+	+	+	+	+	+	+	+	+	+	+	+	+	+	+	+	+	+	+	125
ADENOMATOUS POLYP, NOS																										1

HWBUI0001651

TABLE B3. INDIVIDUAL ANIMAL TUMOR PATHOLOGY OF MALE RATS IN THE LIFETIME FEED STUDY OF INTERMEDIATE-RANGE CHRYSOTILE ASBESTOS: 1,2-DIMETHYLHYDRAZINE DIHYDROCHLORIDE (Continued)

ANIMAL NUMBER	54611 54718 54829 54922 55031 55132 55233 55334 55435 55536 55637 55738 55839 55940 56011 56123 56239 56341 56442 56543 56644 56745 56847 56946 57050	TOTAL TISSUES TUMORS
WEEKS ON STUDY	115 118 122 122 109 107 124 108 117 117 108 102 107 102 111 123 105 109 116 102 112 121 107 123 102	
URINARY SYSTEM		
KIDNEY	+ +	125
TUBULAR-CELL ADENOCARCINOMA		1
MIXED TUMOR, MALIGNANT		1
URETER	M M M M M M M M M M M M M M M M M M M M M M M M M	125M
MIXED TUMOR, MALIGNANT		1
URINARY BLADDER	+ +	124
PAPILLOMA, NOS		1
TRANSITIONAL-CELL PAPILLOMA	X	1
ENDOCRINE SYSTEM		
PITUITARY	+ +	124
CARCINOMA, NOS		3
ADENOMA, NOS	X X X	12
ADRENAL	+ +	125
PHEOCHROMOCYTOMA	X X X X X	20
THYROID	+ +	124
FOLLICULAR-CELL ADENOMA		1
FOLLICULAR-CELL CARCINOMA		8
C-CELL ADENOMA	X X X	11
C-CELL CARCINOMA	X X	15
PARATHYROID	+ + + + + + + + + + + + + + + + + - + + + + + + +	119
ADENOMA, NOS		1
PANCREATIC ISLETS	+ +	124
ISLET-CELL ADENOMA		1
ISLET-CELL CARCINOMA	X X	6
REPRODUCTIVE SYSTEM		
MAMMARY GLAND	M + + + + + + + + + + + + + + N + + + + + + + N + +	125M
ADENOMA, NOS	X	3
ADENOCARCINOMA, NOS		1
FIBROADENOMA		1
TESTIS	+ +	125
INTERSTITIAL-CELL TUMOR	X X X X X X X X X X X X X X X X X X X X X X X X X	112
INTERSTITIAL-CELL TUMOR, MALIGNAN		1
PROSTATE	+ +	125
ADENOMA, NOS		1
PREPUTIAL/CLITORAL GLAND	M M M M M M M M M M M M M M M M M M M M M M M M M	125M
CARCINOMA, NOS	X	6
SQUAMOUS CELL CARCINOMA		1
NERVOUS SYSTEM		
BRAIN	+ +	125
CARCINOMA, NOS, INVASIVE		1
SPINAL CORD	M M M M M M M M M M M M M M M M M M M M M M M M M	125M
NEURILEMOMA, MALIGNANT		1
SPECIAL SENSE ORGANS		
EAR	+ +	125M
FIBROSARCOMA		1
ZYMBAL GLAND	+ +	125M
CARCINOMA, NOS	X	3
SQUAMOUS CELL PAPILLOMA		1
SQUAMOUS CELL CARCINOMA	X X X	15
BODY CAVITIES		
TUNICA VAGINALIS	+ +	125M
MESOTHELIOMA, NOS	X	1
MESOTHELIOMA, MALIGNANT		5
MESENTERY	M M M M M M M M M M M M M M M M M M M M M M M M M	125M
SARCOMA, NOS		1
ALL OTHER SYSTEMS		
MULTIPLE ORGANS NOS	M M M M M M M M M M M M M M M M M M M M M M M M M	125M
ADENOCARCINOMA, NOS, INVASIVE		1
ADENOCARCINOMA, NOS, METASTATIC		1
MUCINOUS CYSTADENOCA, METASTATIC		3
MESOTHELIOMA, METASTATIC		4
MALIG.LYMPHOMA, HISTIOCYTIC TYPE		2
MONOCYTIC LEUKEMIA	X X X X X X X	40
LEUKEMIA, MONONUCLEAR CELL		2
BASE OF TAIL		
RHABDOMYOSARCOMA	X	1
SCROTUM NOS		
FIBROMA		1
MESOTHELIOMA, METASTATIC		1

* ANIMALS NECROPSIED

HWBUI0001652

TABLE B3. INDIVIDUAL ANIMAL TUMOR PATHOLOGY OF MALE RATS IN THE LIFETIME FEED STUDY OF INTERMEDIATE-RANGE CHRYSOTILE ASBESTOS: INTERMEDIATE-RANGE

ANIMAL NUMBER	6 9 6 7	6 9 6 8	6 9 6 9	6 9 7 0	7 0 0 1	7 0 0 2	7 0 0 3	7 0 0 4	7 0 0 5	7 0 0 6	7 0 0 7	7 0 0 8	7 0 0 9	7 0 1 0	7 0 1 1	7 0 1 2	7 0 1 3	7 0 1 4	7 0 1 5	7 0 1 6	7 0 1 7	7 0 1 8	7 0 1 9	7 0 2 0
WEEKS ON STUDY	1 3 5 1	1 3 9 6	1 4 0 6	1 4 6 2	1 4 7 2	1 4 7 8	1 4 9 1	1 4 9 4	1 5 0 1	1 5 0 4	1 5 0 6	1 5 1 1	1 5 2 1	1 5 2 8	1 5 3 1	1 5 3 4	1 5 4 1	1 5 4 8	1 5 5 1	1 5 5 5	1 5 5 8	1 5 5 8	1 5 5 8	1 5 7
INTEGUMENTARY SYSTEM																								
SKIN	+	+	+	+	+	+	+	+	+	+	+	+	+	+	+	+	+	+	+	+	+	+	+	+
SQUAMOUS CELL PAPILLOMA										X														
SQUAMOUS CELL CARCINOMA																								
BASAL-CELL TUMOR																			X					
BASAL-CELL CARCINOMA																								
SEBACEOUS ADENOMA																								
SEBACEOUS ADENOCARCINOMA																								
KERATOACANTHOMA																				X				
FIBROSARCOMA																								X
SUBCUTANEOUS TISSUE	+	+	+	+	+	+	+	+	+	+	+	+	+	+	+	+	+	+	+	+	+	+	+	+
CARCINOMA, NOS																								
SQUAMOUS CELL CARCINOMA																								
BASAL-CELL CARCINOMA																								
SARCOMA, NOS																								
FIBROMA				X		X													X					X
FIBROSARCOMA																								
FIBROUS HISTIOCYTOMA, MALIGNANT																								
LIPOMA																								
OSTEOSARCOMA		X																				X		
NEUROFIBROSARCOMA																								
RESPIRATORY SYSTEM																								
LUNGS AND BRONCHI	+	+	+	+	+	+	+	+	+	+	+	+	+	+	+	+	+	+	+	+	+	+	+	+
SQUAMOUS CELL CARCINOMA, METASTAT																								
ADENOCARCINOMA, NOS, METASTATIC																								
ALVEOLAR/BRONCHIOLAR ADENOMA																								
ALVEOLAR/BRONCHIOLAR CARCINOMA																								
PHEOCHROMOCYTOMA, METASTATIC																								
FIBROSARCOMA, METASTATIC																								
FIBROUS HISTIOCYTOMA, METASTATIC																								
LIPOSARCOMA, METASTATIC																								
MESOTHELIOMA, NOS																								
OSTEOSARCOMA, METASTATIC		X																						
MENINGIOMA, METASTATIC																								
TRACHEA	+	+	+	+	+	+	+	+	+	+	+	+	+	+	+	+	+	+	+	+	+	+	+	+
HEMATOPOIETIC SYSTEM																								
BONE MARROW	+	+	+	+	+	+	+	+	+	+	+	+	+	+	+	+	+	+	+	+	+	+	+	+
SPLEEN	+	+	+	+	+	+	+	+	+	+	+	+	+	+	+	+	+	+	+	+	+	+	+	+
INTERSTITIAL-CELL TUMOR, METASTAT																								
SARCOMA, NOS																								
HEMANGIOSARCOMA																								
MONOCYTIC LEUKEMIA																								
LYMPH NODES	+	+	+	+	+	+	+	+	+	+	+	+	+	+	+	+	+	+	+	+	+	+	+	+
SQUAMOUS CELL CARCINOMA, METASTAT																								
SARCOMA, NOS, INVASIVE																						X		
FIBROUS HISTIOCYTOMA, METASTATIC																								
THYMUS	+	+	+	+	+	+	+	+	+	+	-	-	+	+	+	+	+	+	+	+	+	+	+	+
CIRCULATORY SYSTEM																								
HEART	+	+	+	+	+	+	+	+	+	+	+	+	+	+	+	+	+	+	+	+	+	+	+	+
ADENOCARCINOMA, NOS, METASTATIC																								
DIGESTIVE SYSTEM																								
ORAL CAVITY	M	M	M	M	M	M	M	M	M	M	M	M	M	M	M	M	M	M	M	M	M	M	M	M
SQUAMOUS CELL PAPILLOMA																								
SQUAMOUS CELL CARCINOMA																								
KERATOACANTHOMA																								
SALIVARY GLAND	+	+	+	+	+	+	+	+	+	+	+	+	+	+	+	+	+	+	+	+	+	+	+	+
SARCOMA, NOS																					X			
FIBROSARCOMA																								
FIBROSARCOMA, INVASIVE																								
LIVER	+	+	+	+	+	+	+	+	+	+	+	+	+	+	+	+	+	+	+	+	+	+	+	+
NEOPLASTIC NODULE																								
HEPATOCELLULAR CARCINOMA																								
FIBROSARCOMA, METASTATIC																								
LIPOSARCOMA, METASTATIC																								
BILE DUCT	+	+	+	+	+	+	+	+	+	+	+	+	+	+	+	+	+	+	+	+	+	+	+	+
GALLBLADDER & COMMON BILE DUCT	M	M	M	M	M	M	M	M	M	M	M	M	M	M	M	M	M	M	M	M	M	M	M	M
PANCREAS	+	+	+	+	+	+	+	+	+	+	+	+	+	+	+	+	+	+	+	+	+	+	+	+
ACINAR-CELL ADENOMA					X				X													X		
ACINAR-CELL CARCINOMA																								
ESOPHAGUS	+	+	+	+	+	+	+	+	+	+	+	+	+	+	+	+	+	+	+	+	+	+	+	+
STOMACH	+	+	+	+	+	+	+	+	+	+	+	+	+	+	+	+	+	+	+	+	+	+	+	+
ADENOCARCINOMA, NOS																								
SMALL INTESTINE	+	+	+	+	+	+	+	+	+	+	+	+	+	+	+	+	+	+	+	+	+	+	+	+
ADENOMATOUS POLYP, NOS																								X
MUCINOUS CYSTADENOCARCINOMA																								
SIGNET RING CARCINOMA																								
LEIOMYOMA																								
LEIOMYOSARCOMA																								
LARGE INTESTINE	+	+	+	+	+	+	+	+	+	+	+	+	+	+	+	+	+	+	+	+	+	+	+	+
ADENOMATOUS POLYP, NOS																								
URINARY SYSTEM																								
KIDNEY	+	+	+	+	+	+	+	+	+	+	+	+	+	+	+	+	+	+	+	+	+	+	+	+
TUBULAR-CELL ADENOCARCINOMA																								
TUBULAR ADENOCARCINOMA																								
LIPOMA																								
LIPOSARCOMA, INVASIVE																								
MIXED TUMOR, MALIGNANT																								
URINARY BLADDER	+	+	+	+	+	+	+	+	+	+	+	+	+	+	+	+	+	+	+	+	+	+	+	+
TRANSITIONAL-CELL PAPILLOMA																								
TRANSITIONAL-CELL CARCINOMA																								

HWBUI0001653

TABLE B3. INDIVIDUAL ANIMAL TUMOR PATHOLOGY OF MALE RATS IN THE LIFETIME FEED STUDY OF INTERMEDIATE-RANGE CHRYSOTILE ASBESTOS: INTERMEDIATE-RANGE (Continued)

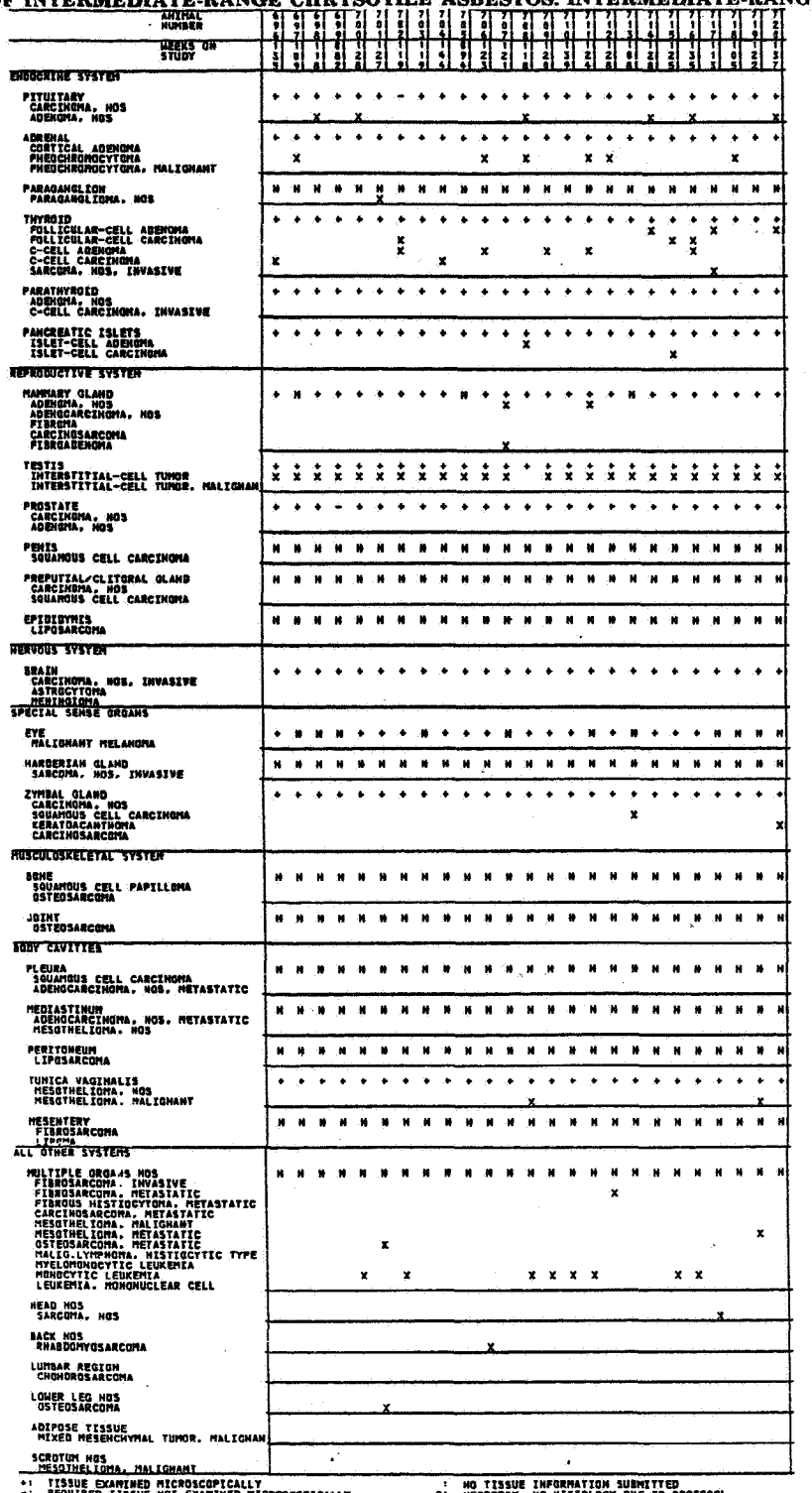

+: TISSUE EXAMINED MICROSCOPICALLY
-: REQUIRED TISSUE NOT EXAMINED MICROSCOPICALLY
X: TUMOR INCIDENCE
N: NECROPSY, NO AUTOLYSIS, NO MICROSCOPIC EXAMINATION
S: ANIMAL MIS-SEXED
I: NO TISSUE INFORMATION SUBMITTED
C: NECROPSY, NO HISTOLOGY DUE TO PROTOCOL
A: AUTOLYSIS
M: ANIMAL MISSING
B: NO NECROPSY PERFORMED

HWBUI0001654

TABLE B3. INDIVIDUAL ANIMAL TUMOR PATHOLOGY OF MALE RATS IN THE LIFETIME FEED STUDY OF INTERMEDIATE-RANGE CHRYSOTILE ASBESTOS: INTERMEDIATE-RANGE (Continued)

ANIMAL NUMBER	72 1	72 2	72 3	72 4	72 5	72 6	72 7	72 8	72 9	73 0	73 1	73 2	73 3	73 4	73 5	73 6	73 7	73 8	73 9	74 0	74 1	74 2	74 3	74 4	74 5	74 6
WEEKS ON STUDY	0 9 2	1 4 4	1 1 8	1 2 5	1 2 5	1 2 7	1 2 8	1 4 0	1 4 5	1 5 0	1 5 6	1 6 7	1 6 7	1 7 4	1 8 8	1 8 8	1 8 8	1 8 8	1 9 1	1 9 1	1 9 1	1 9 1	1 9 1	1 9 1	1 9 1	1 9 1
INTEGUMENTARY SYSTEM																										
SKIN	+	+	+	+	+	+	+	N	+	+	+	+	+	+	+	+	X	+	+	+	+	+	+	+	+	+
SQUAMOUS CELL PAPILLOMA																										
SQUAMOUS CELL CARCINOMA																										
BASAL-CELL TUMOR																										
BASAL-CELL CARCINOMA																										
SEBACEOUS ADENOMA																										
SEBACEOUS ADENOCARCINOMA																										
KERATOACANTHOMA																								X		
FIBROSARCOMA																										
SUBCUTANEOUS TISSUE	+	+	+	+	+	+	+	N	+	+	+	+	+	+	+	+	+	+	+	+	+	+	+	+	+	+
CARCINOMA, NOS																										
SQUAMOUS CELL CARCINOMA																										
BASAL-CELL CARCINOMA																										
SARCOMA, NOS		X																								
FIBROMA						X		X																X	X	
FIBROSARCOMA																				X	X					
FIBROUS HISTIOCYTOMA, MALIGNANT																										
LIPOMA																										
OSTEOSARCOMA																										
NEUROFIBROSARCOMA						X																				
RESPIRATORY SYSTEM																										
LUNGS AND BRONCHI	+	+	+	+	+	+	+	+	+	+	+	+	+	+	+	+	+	+	+	+	+	+	+	+	+	+
SQUAMOUS CELL CARCINOMA, METASTAT																										
ADENOCARCINOMA, NOS, METASTATIC																										
ALVEOLAR/BRONCHIOLAR ADENOMA																										
ALVEOLAR/BRONCHIOLAR CARCINOMA																										
PHEOCHROMOCYTOMA, METASTATIC																										
FIBROSARCOMA, METASTATIC																										
FIBROUS HISTIOCYTOMA, METASTATIC																										
LIPOSARCOMA, METASTATIC																										
MESOTHELIOMA, NOS																										
OSTEOSARCOMA, METASTATIC																										
MENINGIOMA, METASTATIC																										
TRACHEA	+	+	+	+	+	+	+	+	+	+	+	+	+	+	+	+	+	+	+	+	+	+	+	+	+	+
HEMATOPOIETIC SYSTEM																										
BONE MARROW	+	+	+	+	+	+	+	+	+	+	+	+	+	+	+	+	+	+	+	+	+	+	+	+	+	+
SPLEEN	+	+	+	+	+	+	+	+	+	+	+	+	+	+	+	+	+	+	+	+	+	+	+	+	+	+
INTERSTITIAL-CELL TUMOR, METASTAT																										
SARCOMA, NOS																										
HEMANGIOSARCOMA								X																		
MONOCYTIC LEUKEMIA																										
LYMPH NODES	+	+	+	+	+	+	+	+	+	+	+	+	+	+	+	+	+	+	+	+	+	+	+	+	+	+
SQUAMOUS CELL CARCINOMA, METASTAT																										
SARCOMA, NOS, INVASIVE																										
FIBROUS HISTIOCYTOMA, METASTATIC																										
THYMUS	+	-	+	+	+	+	+	-	+	+	+	-	+	+	+	+	+	+	+	-	-	+	-	+	+	
CIRCULATORY SYSTEM																										
HEART	+	+	+	+	+	+	+	+	+	+	+	+	+	+	+	+	+	+	+	+	+	+	+	+	+	+
ADENOCARCINOMA, NOS, METASTATIC																										
DIGESTIVE SYSTEM																										
ORAL CAVITY	M	M	M	M	M	M	M	M	M	M	M	M	M	M	M	M	M	M	M	M	M	M	M	M	M	M
SQUAMOUS CELL PAPILLOMA																										
SQUAMOUS CELL CARCINOMA																										
KERATOACANTHOMA																										
SALIVARY GLAND	+	+	+	+	+	+	+	+	+	+	+	+	+	+	+	+	+	+	+	+	+	+	+	+	+	+
SARCOMA, NOS																										
FIBROSARCOMA																										
FIBROSARCOMA, INVASIVE																										
LIVER	+	+	+	+	+	+	+	+	+	+	+	+	+	+	+	+	+	+	+	+	+	+	+	+	+	+
NEOPLASTIC NODULE																			X	X		X				
HEPATOCELLULAR CARCINOMA																		X								
FIBROSARCOMA, METASTATIC																										
LIPOSARCOMA, METASTATIC																										
BILE DUCT	+	+	+	+	+	+	+	+	+	+	+	+	+	+	+	+	+	+	+	+	+	+	+	+	+	+
GALLBLADDER & COMMON BILE DUCT	M	M	M	M	M	M	M	M	M	M	M	M	M	M	M	M	M	M	M	M	M	M	M	M	M	M
PANCREAS	+	+	+	+	+	+	+	+	+	+	+	+	+	+	+	+	+	+	+	+	+	+	+	+	+	+
ACINAR-CELL ADENOMA				X													X		X	X		X				X
ACINAR-CELL CARCINOMA											X															
ESOPHAGUS	+	+	+	+	+	+	+	+	+	+	+	+	+	+	+	+	+	+	+	+	+	+	+	+	+	+
STOMACH	+	+	+	+	+	+	+	+	+	+	+	+	+	+	+	+	+	+	+	+	+	+	+	+	+	+
ADENOCARCINOMA, NOS																										
SMALL INTESTINE	+	+	+	+	+	+	+	+	+	+	+	+	+	+	+	+	+	+	+	+	+	+	+	+	+	+
ADENOMATOUS POLYP, NOS																										
MUCINOUS CYSTADENOCARCINOMA																										
SIGNET RING CARCINOMA																										
LEIOMYOMA																										
LEIOMYOSARCOMA																										
LARGE INTESTINE	+	+	+	+	+	+	+	+	+	+	+	+	+	+	+	+	+	+	+	+	+	+	+	+	+	+
ADENOMATOUS POLYP, NOS																										
URINARY SYSTEM																										
KIDNEY	+	+	+	+	+	+	+	+	+	+	+	+	+	+	+	+	+	+	+	+	+	+	+	+	+	+
TUBULAR-CELL ADENOCARCINOMA		X																								
TUBULAR ADENOCARCINOMA																										
LIPOMA																										
LIPOSARCOMA, INVASIVE																										
MIXED TUMOR, MALIGNANT																										
URINARY BLADDER	+	+	+	+	+	+	+	+	+	+	+	+	+	+	+	+	+	+	+	+	+	+	+	+	+	+
TRANSITIONAL-CELL PAPILLOMA																										
TRANSITIONAL-CELL CARCINOMA																										

HWBUI0001655

TABLE B3. INDIVIDUAL ANIMAL TUMOR PATHOLOGY OF MALE RATS IN THE LIFETIME FEED STUDY OF INTERMEDIATE-RANGE CHRYSOTILE ASBESTOS: INTERMEDIATE-RANGE (Continued)

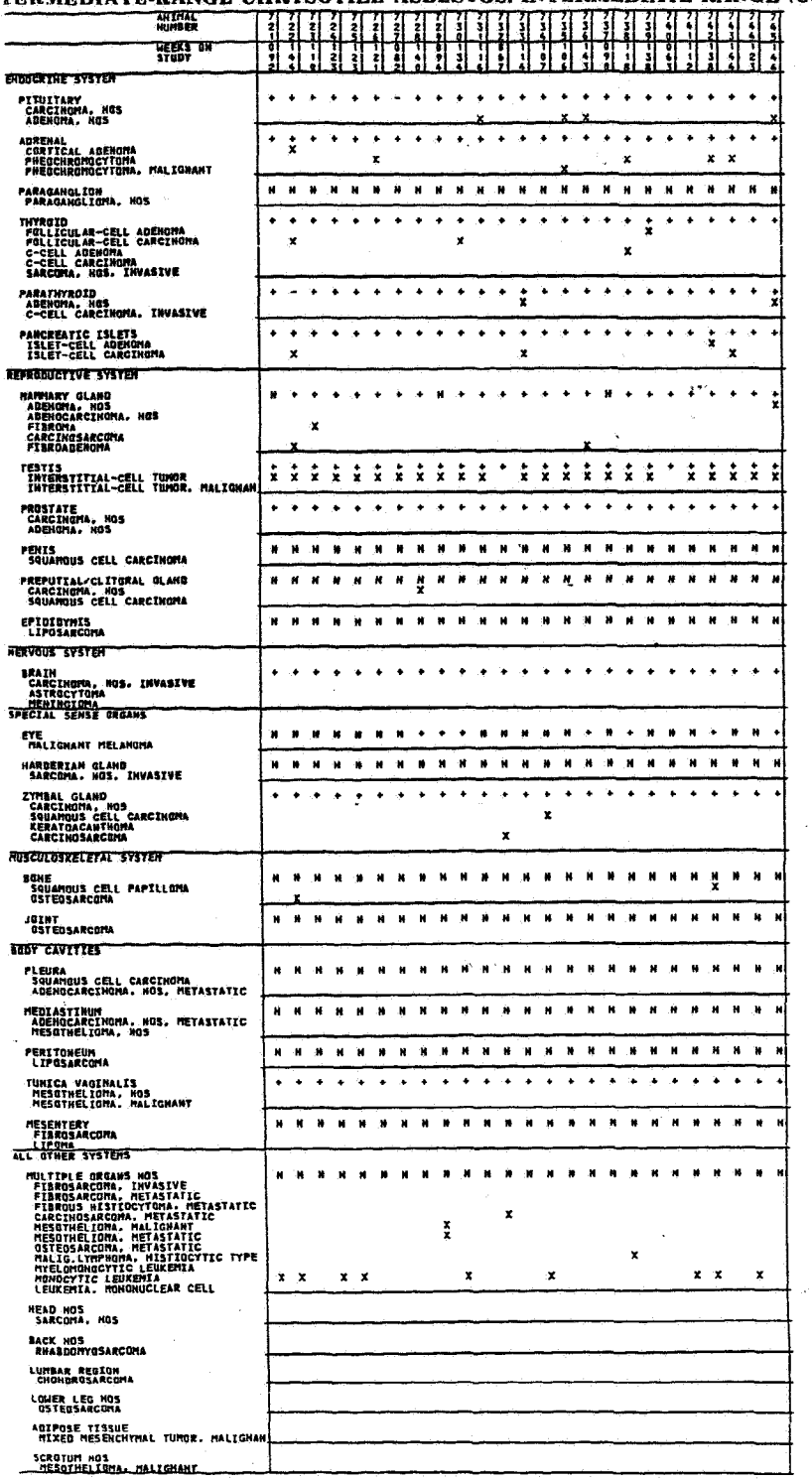

HWBUI0001656

TABLE B3. INDIVIDUAL ANIMAL TUMOR PATHOLOGY OF MALE RATS IN THE LIFETIME FEED STUDY OF INTERMEDIATE-RANGE CHRYSOTILE ASBESTOS: INTERMEDIATE-RANGE (Continued)

ANIMAL NUMBER	74061	74071	74081	74091	74101	74111	74121	74131	74141	74151	74161	74171	74181	74191	74201	74211	74221	74231	74241	74251	74261	74271	74281	74291	74301
WEEKS ON STUDY	106	104	131	118	119	144	124	147	108	101	108	108	108	103	132	108	125	108	118	108	118	111	108	151	108
INTEGUMENTARY SYSTEM																									
SKIN	+	+	+	+	+	+	+	+	+	+	+	+	+	+	+	+	+	+	+	+	+	+	+	+	+
SQUAMOUS CELL PAPILLOMA															X										
SQUAMOUS CELL CARCINOMA																									
BASAL-CELL TUMOR																									
BASAL-CELL CARCINOMA																									
SEBACEOUS ADENOMA																									
SEBACEOUS ADENOCARCINOMA																									
KERATOACANTHOMA																									X
FIBROSARCOMA																									
SUBCUTANEOUS TISSUE	+	+	+	+	+	+	+	+	+	+	+	+	+	+	+	+	+	+	+	+	+	+	+	+	+
CARCINOMA, NOS																									
SQUAMOUS CELL CARCINOMA																									
BASAL-CELL CARCINOMA																									
SARCOMA, NOS																									
FIBROMA	X																				X				
FIBROSARCOMA																					X				
FIBROUS HISTIOCYTOMA, MALIGNANT							X																		
LIPOMA																									
OSTEOSARCOMA																									
NEUROFIBROSARCOMA																									
RESPIRATORY SYSTEM																									
LUNGS AND BRONCHI	+	+	+	+	+	+	+	+	+	+	+	+	+	+	+	+	+	+	+	+	+	+	+	+	+
SQUAMOUS CELL CARCINOMA, METASTAT																									
ADENOCARCINOMA, NOS, METASTATIC																									
ALVEOLAR/BRONCHIOLAR ADENOMA												X													
ALVEOLAR/BRONCHIOLAR CARCINOMA																									
PHEOCHROMOCYTOMA, METASTATIC					X																				
FIBROSARCOMA, METASTATIC																									
FIBROUS HISTIOCYTOMA, METASTATIC																									
LIPOSARCOMA, METASTATIC																									
MESOTHELIOMA, NOS																									
OSTEOSARCOMA, METASTATIC																									
MENINGIOMA, METASTATIC																									
TRACHEA	+	+	+	+	+	+	+	+	+	+	+	+	+	+	+	+	+	+	+	+	+	+	+	+	+
HEMATOPOIETIC SYSTEM																									
BONE MARROW	+	+	+	+	+	+	+	+	+	+	+	+	+	+	+	+	+	+	+	+	+	+	+	+	+
SPLEEN	+	+	+	+	+	+	+	+	+	+	+	+	+	+	+	+	+	+	+	+	+	+	+	+	+
INTERSTITIAL-CELL TUMOR, METASTAT																									
SARCOMA, NOS																									
HEMANGIOSARCOMA				X																					
MONOCYTIC LEUKEMIA																									
LYMPH NODES	+	+	+	+	+	+	+	+	+	+	+	+	+	+	+	+	+	+	+	+	+	+	+	+	+
SQUAMOUS CELL CARCINOMA, METASTAT																									
SARCOMA, NOS, INVASIVE				X																					
FIBROUS HISTIOCYTOMA, METASTATIC																									
THYMUS	+	+	+	+	+	+	+	-	+	+	+	+	+	+	+	+	+	+	+	+	+	+	+	+	-
CIRCULATORY SYSTEM																									
HEART	+	+	+	+	+	+	+	+	+	+	+	+	+	+	+	+	+	+	+	+	+	+	+	+	+
ADENOCARCINOMA, NOS, METASTATIC																									
DIGESTIVE SYSTEM																									
ORAL CAVITY	M	M	M	M	M	M	M	M	M	M	M	M	M	M	M	M	M	M	M	M	M	M	M	M	M
SQUAMOUS CELL PAPILLOMA																									
SQUAMOUS CELL CARCINOMA																									
KERATOACANTHOMA																									
SALIVARY GLAND	+	+	+	+	+	+	+	+	+	+	+	+	+	+	+	+	+	+	+	+	+	+	+	+	+
SARCOMA, NOS				X																					
FIBROSARCOMA																									
FIBROSARCOMA, INVASIVE																									
LIVER	+	+	+	+	+	+	+	+	+	+	+	+	+	+	+	+	+	+	+	+	+	+	+	+	+
NEOPLASTIC NODULE					X				X																
HEPATOCELLULAR CARCINOMA																									
FIBROSARCOMA, METASTATIC																									
LIPOSARCOMA, METASTATIC																									
BILE DUCT	+	+	+	+	+	+	+	+	+	+	+	+	+	+	+	+	+	+	+	+	+	+	+	+	+
GALLBLADDER & COMMON BILE DUCT	M	M	M	M	M	M	M	M	M	M	M	M	M	M	M	M	M	M	M	M	M	M	M	M	M
PANCREAS	+	+	+	+	+	+	+	+	+	+	+	+	+	+	+	+	+	+	+	+	+	+	+	+	+
ACINAR-CELL ADENOMA									X		X														
ACINAR-CELL CARCINOMA																									
ESOPHAGUS	+	+	+	+	+	+	+	+	+	+	+	+	+	+	+	+	+	+	+	+	+	+	+	+	+
STOMACH	+	+	+	+	+	+	+	+	+	+	+	+	+	+	+	+	+	+	+	+	+	+	+	+	+
ADENOCARCINOMA, NOS																									
SMALL INTESTINE	+	+	+	+	+	+	+	+	+	+	+	+	+	+	+	+	+	+	+	+	+	+	+	+	+
ADENOMATOUS POLYP, NOS																									
MUCINOUS CYSTADENOCARCINOMA					X																				
SIGNET RING CARCINOMA																									
LEIOMYOMA																									
LEIOMYOSARCOMA																									
LARGE INTESTINE	+	+	+	+	+	+	+	+	+	+	+	+	+	+	+	+	+	+	+	+	+	+	+	+	+
ADENOMATOUS POLYP, NOS																					X				X
URINARY SYSTEM																									
KIDNEY	+	+	+	+	+	+	+	+	+	+	+	+	+	+	+	+	+	+	+	+	+	+	+	+	+
TUBULAR-CELL ADENOCARCINOMA																									
TUBULAR ADENOCARCINOMA																									
LIPOMA																									
LIPOSARCOMA, INVASIVE																									
MIXED TUMOR, MALIGNANT																									
URINARY BLADDER	+	+	+	+	+	+	+	+	+	+	+	+	+	+	+	+	+	+	+	+	+	+	+	+	+
TRANSITIONAL-CELL PAPILLOMA																									
TRANSITIONAL-CELL CARCINOMA																									

HWBUI0001657

TABLE B3. INDIVIDUAL ANIMAL TUMOR PATHOLOGY OF MALE RATS IN THE LIFETIME FEED STUDY OF INTERMEDIATE-RANGE CHRYSOTILE ASBESTOS: INTERMEDIATE-RANGE (Continued)

ANIMAL NUMBER	74	74	74	74	74	74	74	74	74	74	74	74	74	74	74	74	74	74	74	74	74	74	74	74	74
WEEKS ON STUDY	16	17	31	31	39	41	27	41	48	50	51	52	57	58	59	60	62	62	62	62	62	63	64	64	72
ENDOCRINE SYSTEM																									
PITUITARY	+	+	+	+	+	+	+	+	+	+	+	+	+	+	+	+	+	+	+	+	+	+	+	+	+
CARCINOMA, NOS																								X	
ADENOMA, NOS															X		X							X	
ADRENAL	+	+	+	+	+	+	+	+	+	+	+	+	+	+	+	+	+	+	+	+	+	+	+	+	+
CORTICAL ADENOMA				X			X							X											
PHEOCHROMOCYTOMA						X																			
PHEOCHROMOCYTOMA, MALIGNANT																									
PARAGANGLION	N	N	N	N	N	N	N	N	N	N	N	N	N	N	N	N	N	N	N	N	N	N	N	N	N
PARAGANGLIOMA, NOS																									
THYROID	+	+	+	+	+	+	+	+	+	+	+	+	+	+	+	+	+	+	+	+	+	+	+	+	+
FOLLICULAR-CELL ADENOMA													X												
FOLLICULAR-CELL CARCINOMA																									
C-CELL ADENOMA																									
C-CELL CARCINOMA																X		X		X					
SARCOMA, NOS, INVASIVE																									
PARATHYROID	+	+	+	+	+	+	+	+	+	+	+	+	-	+	+	+	+	+	+	+	+	+	+	+	+
ADENOMA, NOS										X															
C-CELL CARCINOMA, INVASIVE																									
PANCREATIC ISLETS	+	+	+	+	+	+	+	+	+	+	+	+	+	+	+	+	+	+	+	+	+	+	+	+	+
ISLET-CELL ADENOMA						X																			
ISLET-CELL CARCINOMA																									
REPRODUCTIVE SYSTEM																									
MAMMARY GLAND	+	+	+	+	+	+	+	+	+	N	N	N	+	+	+	+	+	+	+	+	+	+	+	+	+
ADENOMA, NOS																X					X				
ADENOCARCINOMA, NOS																									
FIBROMA																									
CARCINOSARCOMA																									
FIBROADENOMA								X																	
TESTIS	+	+	+	+	+	+	+	+	+	+	+	+	+	+	+	+	+	+	+	+	+	+	+	+	+
INTERSTITIAL-CELL TUMOR	X	X	X	X	X	X	X	X	X	X	X	X	X	X	X	X	X	X	X	X	X	X	X	X	X
INTERSTITIAL-CELL TUMOR, MALIGNANT																									
PROSTATE	+	+	+	+	+	+	+	+	+	+	+	+	+	+	+	+	+	+	+	+	+	+	+	+	+
CARCINOMA, NOS																X									
ADENOMA, NOS																									
PENIS	N	N	N	N	N	N	N	N	N	N	N	N	N	N	N	N	N	N	N	N	N	N	N	N	N
SQUAMOUS CELL CARCINOMA																									
PREPUTIAL/CLITORAL GLAND	N	N	N	N	N	N	N	N	N	N	N	N	N	N	N	N	N	N	N	N	N	N	N	N	N
CARCINOMA, NOS													X												
SQUAMOUS CELL CARCINOMA																									
EPIDIDYMIS	N	N	N	N	N	N	N	N	N	N	N	N	N	N	N	N	N	N	N	N	N	N	N	N	N
LIPOSARCOMA																									
NERVOUS SYSTEM																									
BRAIN	+	+	+	+	+	+	+	+	+	+	+	+	+	+	+	+	+	+	+	+	+	+	+	+	+
CARCINOMA, NOS, INVASIVE																						X			
ASTROCYTOMA																									
MENINGIOMA																									
SPECIAL SENSE ORGANS																									
EYE	N	N	N	N	N	+	N	+	N	N	N	N	N	N	N	N	N	N	N	N	N	N	N	N	N
MALIGNANT MELANOMA																									
HARDERIAN GLAND	N	N	N	N	N	N	N	N	N	N	N	N	N	N	N	N	N	N	N	N	N	N	N	N	N
SARCOMA, NOS, INVASIVE																									
ZYMBAL GLAND	+	+	+	+	+	+	+	+	+	N	+	+	+	+	+	+	+	+	+	+	+	+	+	+	N
CARCINOMA, NOS														X											
SQUAMOUS CELL CARCINOMA																									
KERATOACANTHOMA																									
CARCINOSARCOMA																									
MUSCULOSKELETAL SYSTEM																									
BONE	N	N	N	N	N	N	N	N	N	N	N	N	N	N	N	N	N	N	N	N	N	N	N	N	N
SQUAMOUS CELL PAPILLOMA																									
OSTEOSARCOMA																									
JOINT	N	N	N	N	N	N	N	N	N	N	N	N	N	N	N	N	N	N	N	N	N	N	N	N	N
OSTEOSARCOMA																					X				
BODY CAVITIES																									
PLEURA	N	N	N	N	N	N	N	N	N	N	N	N	N	N	N	N	N	N	N	N	N	N	N	N	N
SQUAMOUS CELL CARCINOMA																									
ADENOCARCINOMA, NOS, METASTATIC																									
MEDIASTINUM	N	N	N	N	N	N	N	N	N	N	N	N	N	N	N	N	N	N	N	N	N	N	N	N	N
ADENOCARCINOMA, NOS, METASTATIC																									
MESOTHELIOMA, NOS																									
PERITONEUM	N	N	N	N	N	N	N	N	N	N	N	N	N	N	N	N	N	N	N	N	N	N	N	N	N
LIPOSARCOMA																									
TUNICA VAGINALIS	+	+	+	+	+	+	+	+	+	+	+	+	+	+	+	+	+	+	+	+	+	+	+	+	+
MESOTHELIOMA, NOS																	X								
MESOTHELIOMA, MALIGNANT																									
MESENTERY	N	N	N	N	N	N	N	N	N	N	N	N	N	N	N	N	N	N	N	N	N	N	N	N	N
FIBROSARCOMA																									
LIPOMA																									
ALL OTHER SYSTEMS																									
MULTIPLE ORGANS NOS	N	N	N	N	N	N	N	N	N	N	N	N	N	N	N	N	N	N	N	N	N	N	N	N	N
FIBROSARCOMA, INVASIVE																									
FIBROSARCOMA, METASTATIC																									
FIBROUS HISTIOCYTOMA, METASTATIC							X																		
CARCINOSARCOMA, METASTATIC																									
MESOTHELIOMA, MALIGNANT																									
MESOTHELIOMA, METASTATIC																	X								
OSTEOSARCOMA, METASTATIC																				X					
MALIG. LYMPHOMA, HISTIOCYTIC TYPE																									
MYELOMONOCYTIC LEUKEMIA																									
MONOCYTIC LEUKEMIA	X	X			X			X			X			X			X				X	X	X	X
LEUKEMIA, MONONUCLEAR CELL									X																
HEAD NOS																									
SARCOMA, NOS																									
BACK NOS																									
RHABDOMYOSARCOMA																									
LUMBAR REGION																									
CHONDROSARCOMA																									
LOWER LEG NOS																									
OSTEOSARCOMA																									
ADIPOSE TISSUE																									
MIXED MESENCHYMAL TUMOR, MALIGNAN																									
SCROTUM NOS																									
MESOTHELIOMA, MALIGNANT																									

HWBUI0001658

TABLE B3. INDIVIDUAL ANIMAL TUMOR PATHOLOGY OF MALE RATS IN THE LIFETIME FEED STUDY OF INTERMEDIATE-RANGE CHRYSOTILE ASBESTOS: INTERMEDIATE-RANGE (Continued)

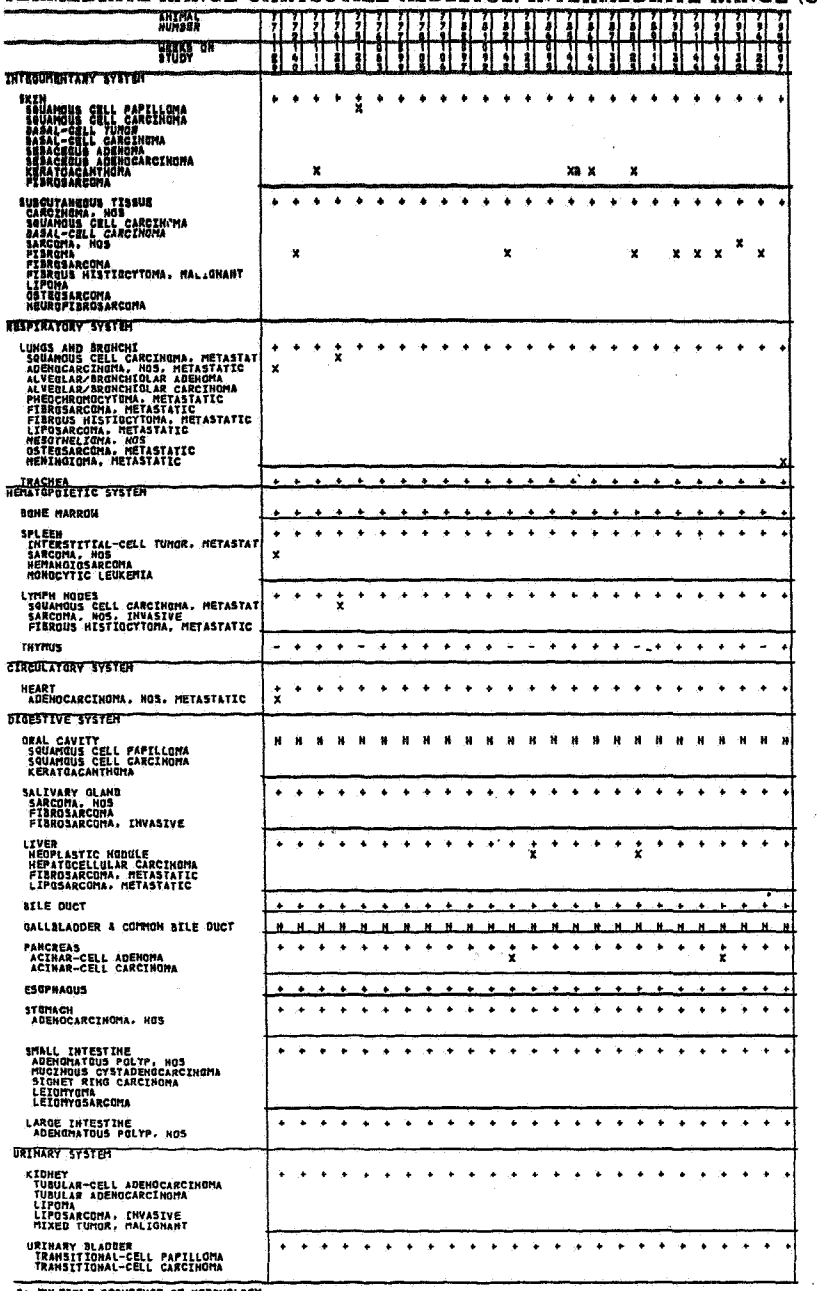

a: MULTIPLE OCCURENCE OF MORPHOLOGY

HWBUI0001659

TABLE B3. INDIVIDUAL ANIMAL TUMOR PATHOLOGY OF MALE RATS IN THE LIFETIME FEED STUDY OF INTERMEDIATE-RANGE CHRYSOTILE ASBESTOS: INTERMEDIATE-RANGE (Continued)

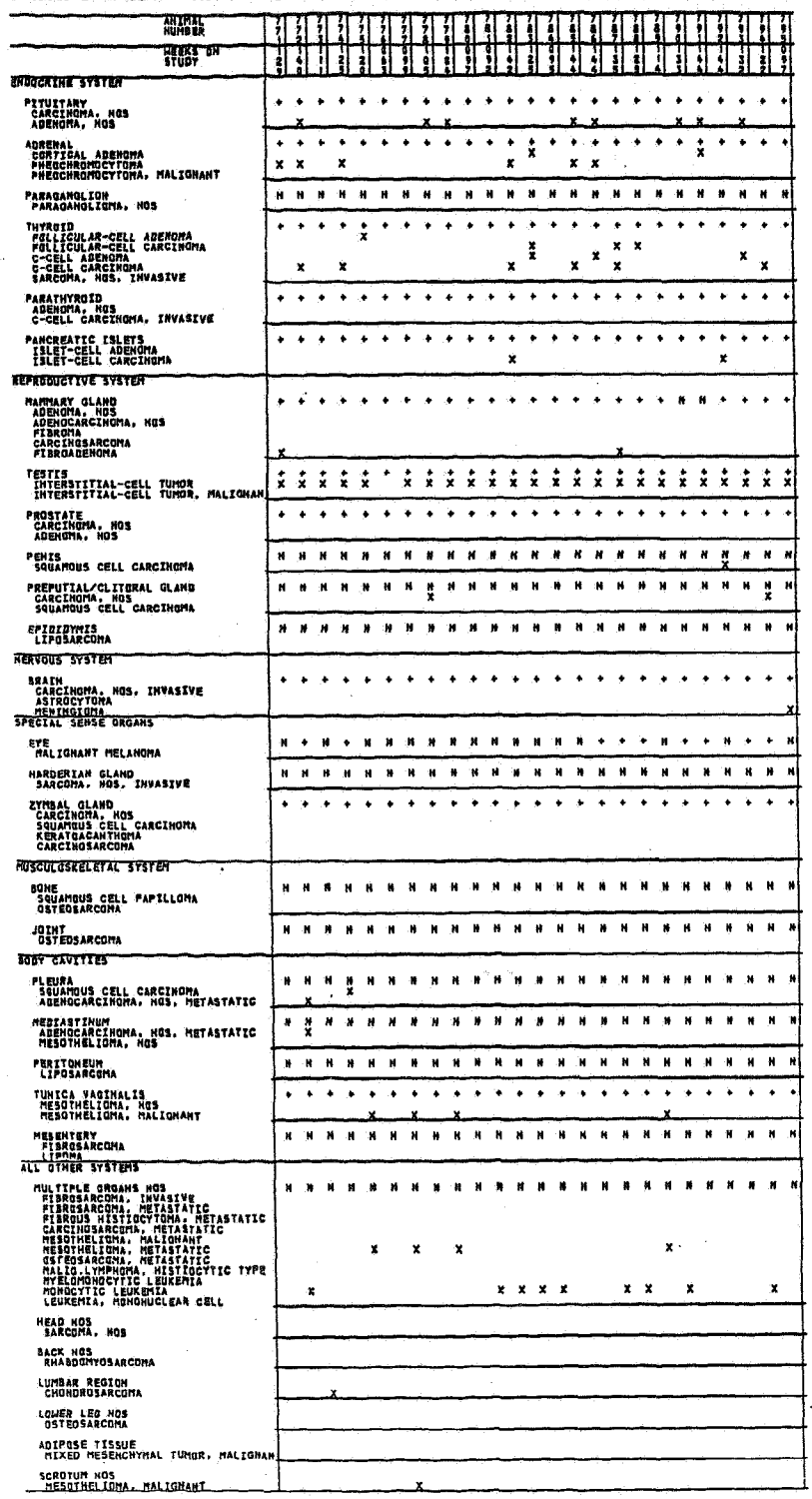

HWBUI0001660

TABLE B3. INDIVIDUAL ANIMAL TUMOR PATHOLOGY OF MALE RATS IN THE LIFETIME FEED STUDY OF INTERMEDIATE-RANGE CHRYSOTILE ASBESTOS: INTERMEDIATE-RANGE (Continued)

ANIMAL NUMBER	7 9 6	7 9 7	7 9 8	7 9 9	8 0 0	8 0 1	8 0 2	8 0 3	8 0 4	8 0 5	8 0 6	8 0 7	8 0 8	8 0 9	8 1 0	8 1 1	8 1 2	8 1 3	8 1 4	8 1 5	8 1 6	8 1 7	8 1 8	8 1 9	8 2 0
WEEKS ON STUDY	1 2 0	1 9 1	1 3 2	1 3 7	1 8 4	1 3 8	1 3 6	1 2 9	1 4 4	1 0 8	1 3 5	1 2 1	1 4 1	1 1 7	1 1 1	1 3 0	1 3 9	1 0 7	1 4 0	1 3 1	1 1 0	1 2 0	1 1 6	0 5
INTEGUMENTARY SYSTEM																									
SKIN	+	+	+	+	+	+	+	+	+	+	+	+	+	+	+	+	+	+	+	+	+	+	+	+	+
SQUAMOUS CELL PAPILLOMA									X																
SQUAMOUS CELL CARCINOMA															X										
BASAL-CELL TUMOR																									
BASAL-CELL CARCINOMA																									
SEBACEOUS ADENOMA										X															
SEBACEOUS ADENOCARCINOMA																X					X				
KERATOACANTHOMA																									
FIBROSARCOMA																									
SUBCUTANEOUS TISSUE	+	+	+	+	+	+	+	+	+	+	+	+	+	+	+	+	+	+	+	+	+	+	+	+	+
CARCINOMA, NOS																	X								
SQUAMOUS CELL CARCINOMA																									
BASAL-CELL CARCINOMA																									
SARCOMA, NOS																									
FIBROMA	X			X									X								X				X
FIBROSARCOMA																									
FIBROUS HISTIOCYTOMA, MALIGNANT																									
LIPOMA																									
OSTEOSARCOMA																									
NEUROFIBROSARCOMA																									
RESPIRATORY SYSTEM																									
LUNGS AND BRONCHI	+	+	+	+	+	+	+	+	+	+	+	+	+	+	+	+	+	+	+	+	+	+	+	+	+
SQUAMOUS CELL CARCINOMA, METASTAT																									
ADENOCARCINOMA, NOS, METASTATIC																									
ALVEOLAR/BRONCHIOLAR ADENOMA																									
ALVEOLAR/BRONCHIOLAR CARCINOMA																									
PHEOCHROMOCYTOMA, METASTATIC																									
FIBROSARCOMA, METASTATIC																									X
FIBROUS HISTIOCYTOMA, METASTATIC																									
LIPOSARCOMA, METASTATIC																									
MESOTHELIOMA, NOS																									
OSTEOSARCOMA, METASTATIC																									
MENINGIOMA, METASTATIC																									
TRACHEA	+	+	+	+	+	+	+	+	+	+	+	+	+	+	+	+	+	+	+	+	+	+	+	+	+
HEMATOPOIETIC SYSTEM																									
BONE MARROW	+	+	+	+	+	+	+	+	+	+	+	+	+	+	+	+	+	+	+	+	+	+	+	+	-
SPLEEN	+	+	+	+	+	+	+	+	+	+	+	+	X	+	+	+	+	+	+	+	+	+	+	+	+
INTERSTITIAL-CELL TUMOR, METASTAT																									
SARCOMA, NOS																									
HEMANGIOSARCOMA																									
MONOCYTIC LEUKEMIA																									
LYMPH NODES	+	+	+	+	+	+	+	+	+	+	+	+	+	+	+	+	+	+	+	+	+	+	+	+	+
SQUAMOUS CELL CARCINOMA, METASTAT																									
SARCOMA, NOS, INVASIVE																									
FIBROUS HISTIOCYTOMA, METASTATIC																									
THYMUS	+	+	+	-	+	+	+	+	+	+	+	+	+	-	+	+	+	+	+	-	+	+	+	+	+
CIRCULATORY SYSTEM																									
HEART	+	+	+	+	+	+	+	+	+	+	+	+	+	+	+	+	+	+	+	+	+	+	+	+	+
ADENOCARCINOMA, NOS, METASTATIC																									
DIGESTIVE SYSTEM																									
ORAL CAVITY	M	M	M	M	M	M	M	M	M	M	M	M	M	M	M	M	M	M	M	M	M	M	M	M	M
SQUAMOUS CELL PAPILLOMA																									
SQUAMOUS CELL CARCINOMA																									
KERATOACANTHOMA																									
SALIVARY GLAND	+	+	+	+	+	+	+	+	+	+	+	+	+	+	+	+	+	+	+	+	+	X	+	+	+
SARCOMA, NOS																									
FIBROSARCOMA																									
FIBROSARCOMA, INVASIVE																									X
LIVER	+	+	+	+	+	+	+	+	+	+	+	+	+	+	+	+	+	+	+	+	+	+	+	+	+
NEOPLASTIC NODULE																								X	
HEPATOCELLULAR CARCINOMA															X									X	
FIBROSARCOMA, METASTATIC																									
LIPOSARCOMA, METASTATIC																									
BILE DUCT	+	+	+	+	+	+	+	+	+	+	+	+	+	+	+	+	+	+	+	+	+	+	+	+	+
GALLBLADDER & COMMON BILE DUCT	M	M	M	M	M	M	M	M	M	M	M	M	M	M	M	M	M	M	M	M	M	M	M	M	M
PANCREAS	+	+	+	+	+	+	+	+	+	+	+	+	+	+	+	+	+	+	+	+	+	+	+	+	+
ACINAR-CELL ADENOMA	X				X		X								X										
ACINAR-CELL CARCINOMA																									
ESOPHAGUS	+	+	+	+	+	+	+	+	+	+	+	+	+	+	+	+	+	+	+	+	+	+	+	+	+
STOMACH	+	+	+	+	+	+	+	+	+	+	+	+	+	+	+	+	+	+	+	+	+	+	+	+	+
ADENOCARCINOMA, NOS		X																							
SMALL INTESTINE	+	+	+	+	+	+	+	+	+	+	+	+	+	+	+	+	+	+	+	+	+	+	+	+	+
ADENOMATOUS POLYP, NOS																									
MUCINOUS CYSTADENOCARCINOMA																									
SIGNET RING CARCINOMA																									
LEIOMYOMA																									
LEIOMYOSARCOMA																									
LARGE INTESTINE	+	+	+	+	+	+	+	+	+	+	+	+	+	+	+	+	+	+	+	+	+	+	+	+	+
ADENOMATOUS POLYP, NOS																									
URINARY SYSTEM																									
KIDNEY	+	+	+	+	+	+	+	+	+	+	+	+	+	+	+	+	+	+	+	+	+	+	+	+	+
TUBULAR-CELL ADENOCARCINOMA										X															
TUBULAR ADENOCARCINOMA																									
LIPOMA																									
LIPOSARCOMA, INVASIVE																									
MIXED TUMOR, MALIGNANT																									
URINARY BLADDER	+	+	+	+	+	+	+	+	+	+	+	+	+	+	+	+	+	+	+	+	+	+	+	+	+
TRANSITIONAL-CELL PAPILLOMA																									
TRANSITIONAL-CELL CARCINOMA																									

HWBUI0001661

TABLE B3. INDIVIDUAL ANIMAL TUMOR PATHOLOGY OF MALE RATS IN THE LIFETIME FEED STUDY OF INTERMEDIATE-RANGE CHRYSOTILE ASBESTOS: INTERMEDIATE-RANGE (Continued)

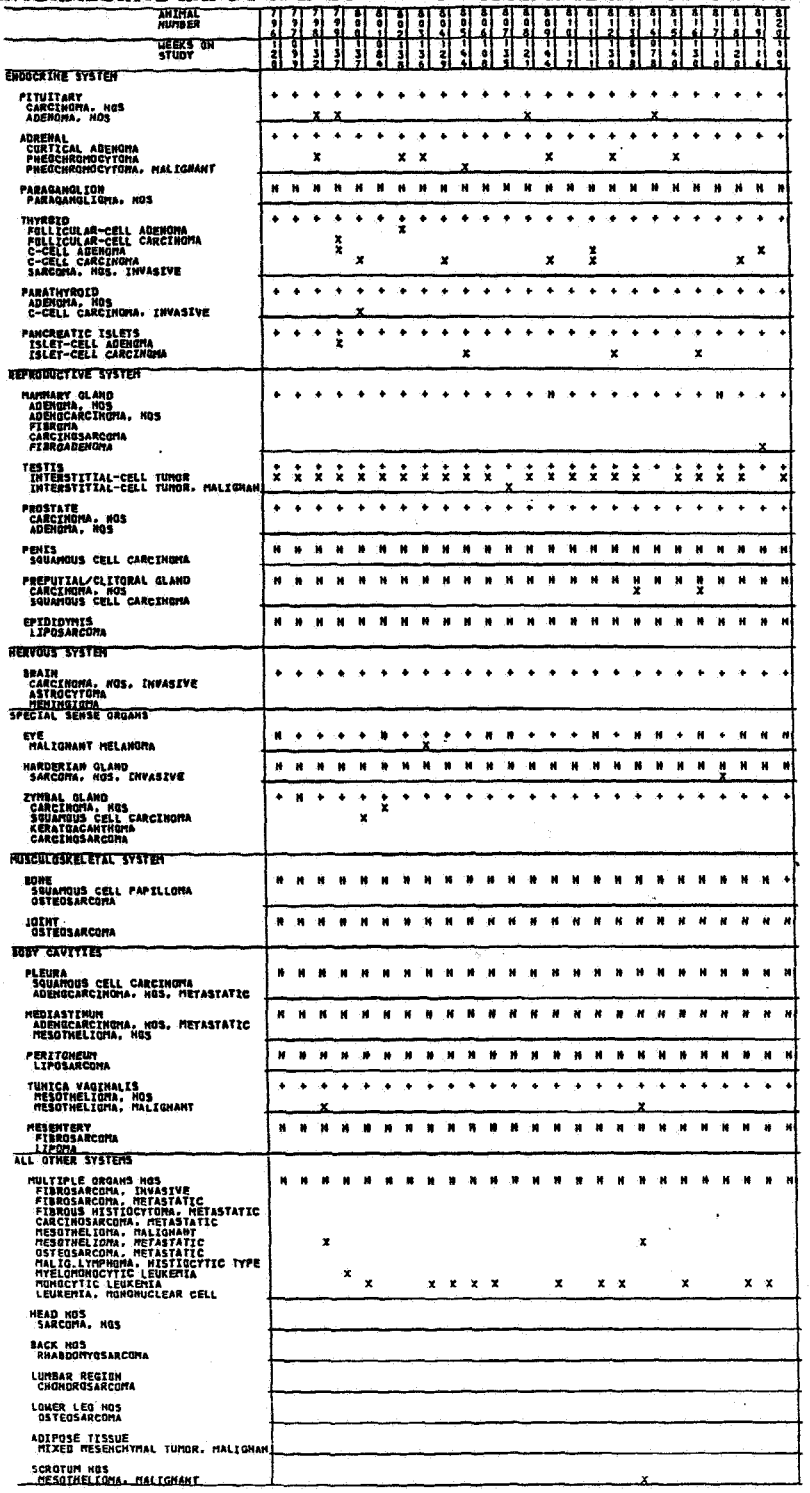

HWBUI0001662

TABLE B3. INDIVIDUAL ANIMAL TUMOR PATHOLOGY OF MALE RATS IN THE LIFETIME FEED STUDY OF INTERMEDIATE-RANGE CHRYSOTILE ASBESTOS: INTERMEDIATE-RANGE (Continued)

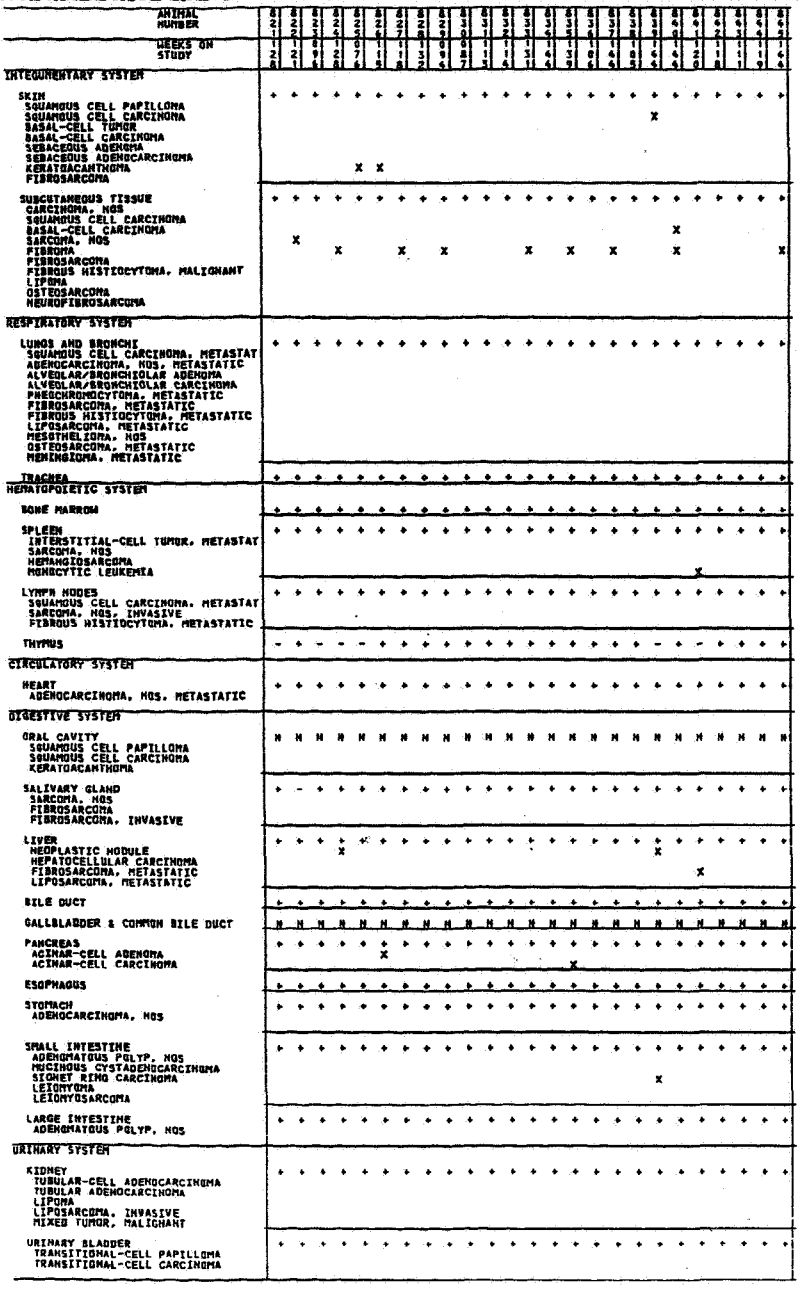

HWBUI0001663

TABLE B3. INDIVIDUAL ANIMAL TUMOR PATHOLOGY OF MALE RATS IN THE LIFETIME FEED STUDY OF INTERMEDIATE-RANGE CHRYSOTILE ASBESTOS: INTERMEDIATE-RANGE (*Continued*)

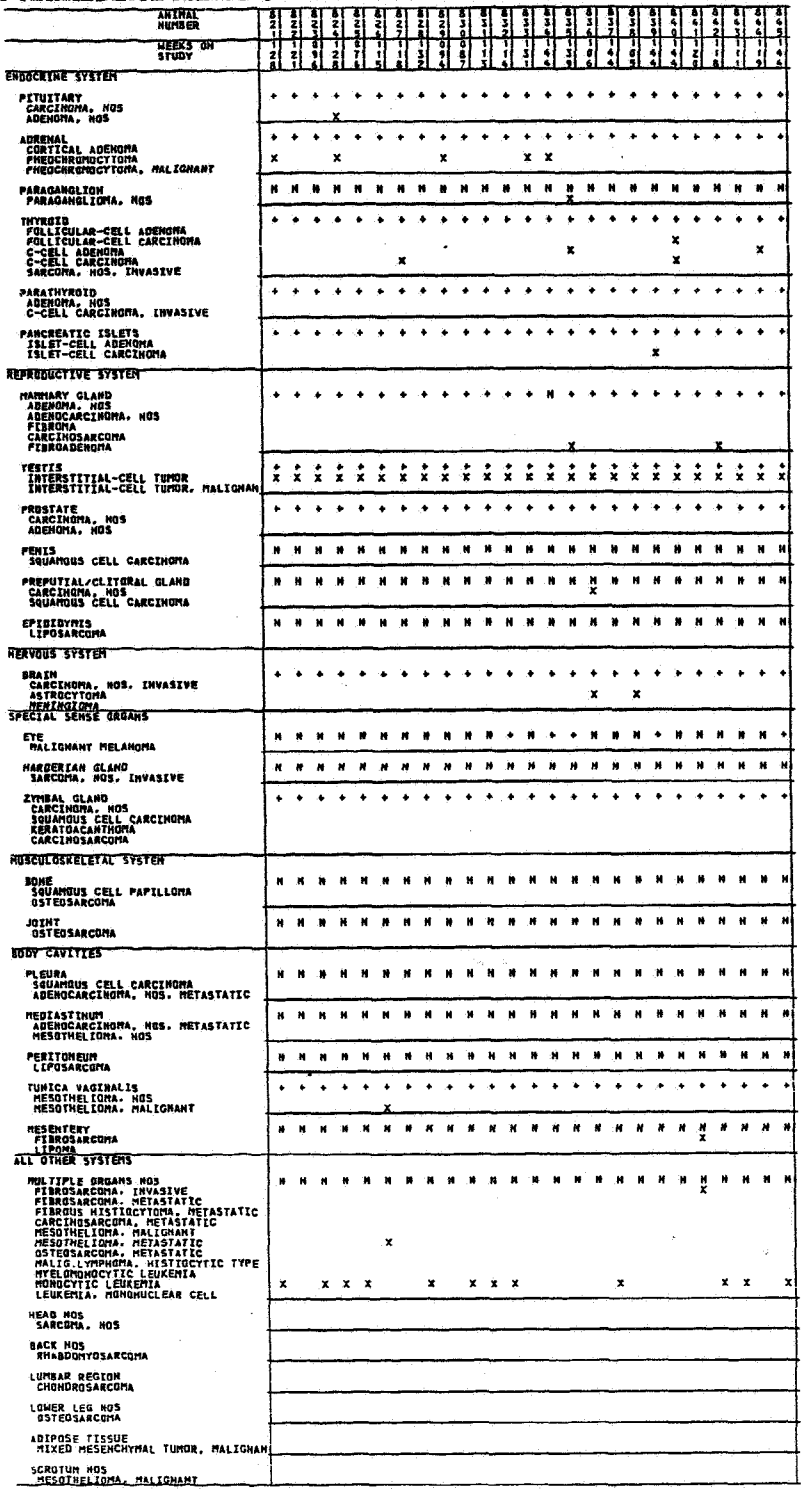

HWBUI0001664

TABLE B3. INDIVIDUAL ANIMAL TUMOR PATHOLOGY OF MALE RATS IN THE LIFETIME FEED STUDY OF INTERMEDIATE-RANGE CHRYSOTILE ASBESTOS: INTERMEDIATE-RANGE (Continued)

ANIMAL NUMBER	0 4 0 1	0 4 0 2	0 4 0 3	0 4 0 4	0 4 0 5	0 4 0 6	0 4 0 7	0 4 0 8	0 4 0 9	0 4 1 0	0 4 1 1	0 4 1 2	0 4 1 3	0 4 1 4	0 4 1 5	0 4 1 6	0 4 1 7	0 4 1 8	0 4 1 9	0 4 2 0	0 4 2 1	0 4 2 2	0 4 2 3	0 4 2 4	0 4 2 5	0 4 2 6	0 4 2 7	0 4 2 8	0 4 2 9	0 4 3 0
WEEKS ON STUDY	0 1 9	3 4 4	4 4 4	4 4 6	4 5 1	5 1 1	5 1 2	5 2 3	5 3 6	5 4 1	5 4 1	5 4 1	5 4 8	5 5 1	5 5 1	5 5 1	5 5 1	5 5 1	5 5 1	5 5 1	5 5 1	5 5 1	5 5 1	5 5 1	5 5 1	5 5 1	5 5 1	5 5 1	5 5 1	5 5 1
INTEGUMENTARY SYSTEM																														
SKIN	+	+	+	+	+	+	+	+	+	+	+	+	+	+	+	+	X	+	+	+	+	+	+	+	+	+	+	+	+	+
SQUAMOUS CELL PAPILLOMA																														
SQUAMOUS CELL CARCINOMA																														
BASAL-CELL TUMOR																														
BASAL-CELL CARCINOMA																														
SEBACEOUS ADENOMA										X																				
SEBACEOUS ADENOCARCINOMA											X																			
KERATOACANTHOMA								X																						
FIBROSARCOMA																														
SUBCUTANEOUS TISSUE	+	+	+	+	+	+	+	+	+	+	+	+	+	+	+	+	+	+	+	+	+	+	+	+	+	+	+	+	+	+
CARCINOMA, NOS																														
SQUAMOUS CELL CARCINOMA																														
BASAL-CELL CARCINOMA																														
SARCOMA, NOS																														
FIBROMA	X	X			X			X			X	X			X											X				
FIBROSARCOMA																														
FIBROUS HISTIOCYTOMA, MALIGNANT		X																												
LIPOMA																														
OSTEOSARCOMA																														
NEUROFIBROSARCOMA																														
RESPIRATORY SYSTEM																														
LUNGS AND BRONCHI	+	+	+	+	+	+	+	+	+	+	+	+	+	+	+	+	+	+	+	+	+	+	+	+	+	+	+	+	+	+
SQUAMOUS CELL CARCINOMA, METASTAT																														
ADENOCARCINOMA, NOS, METASTATIC																														
ALVEOLAR/BRONCHIOLAR ADENOMA																														
ALVEOLAR/BRONCHIOLAR CARCINOMA																														
PHEOCHROMOCYTOMA, METASTATIC																														
FIBROSARCOMA, METASTATIC																														
FIBROUS HISTIOCYTOMA, METASTATIC		X																												
LIPOSARCOMA, METASTATIC								X																						
MESOTHELIOMA, NOS																														
OSTEOSARCOMA, METASTATIC																														
MENINGIOMA, METASTATIC																														
TRACHEA	+	+	+	+	+	+	+	+	+	+	+	+	+	+	+	+	+	+	+	+	+	+	+	+	+	+	+	+	+	+
HEMATOPOIETIC SYSTEM																														
BONE MARROW	+	+	+	+	+	+	+	+	+	+	+	+	+	+	+	+	+	+	+	+	+	+	+	+	+	+	+	+	+	+
SPLEEN	+	+	+	+	+	+	+	+	+	+	+	+	+	+	+	+	+	+	+	+	+	+	+	+	+	+	+	+	+	+
INTERSTITIAL-CELL TUMOR, METASTAT																														
SARCOMA, NOS																														
HEMANGIOSARCOMA																														
MONOCYTIC LEUKEMIA																														
LYMPH NODES	+	+	+	+	+	+	+	+	+	+	+	+	+	+	+	+	+	+	+	+	+	+	+	+	+	+	+	+	+	+
SQUAMOUS CELL CARCINOMA, METASTAT																														
SARCOMA, NOS, INVASIVE																														
FIBROUS HISTIOCYTOMA, METASTATIC		X																												
THYMUS	+	+	-	+	+	-	+	+	+	+	+	+	+	+	+	+	+	+	-	-	+	+	+	+	+	+	-			
CIRCULATORY SYSTEM																														
HEART	+	+	+	+	+	+	+	+	+	+	+	+	+	+	+	+	+	+	+	+	+	+	+	+	+	+	+	+	+	+
ADENOCARCINOMA, NOS, METASTATIC																														
DIGESTIVE SYSTEM																														
ORAL CAVITY	M	M	M	M	M	M	M	M	M	M	M	M	M	M	M	M	M	M	M	M	M	M	M	M	M	X	M	M	M	M
SQUAMOUS CELL PAPILLOMA																														
SQUAMOUS CELL CARCINOMA																														
KERATOACANTHOMA																														
SALIVARY GLAND	+	+	+	+	+	+	+	+	+	+	+	+	-	+	+	+	+	+	+	+	+	+	+	+	+	+	+	+	+	+
SARCOMA, NOS																														
FIBROSARCOMA																														
FIBROSARCOMA, INVASIVE																														
LIVER	+	+	+	+	+	+	+	+	+	+	+	+	+	+	+	+	+	+	+	+	+	+	+	+	+	+	+	+	+	+
NEOPLASTIC NODULE																														
HEPATOCELLULAR CARCINOMA																														
FIBROSARCOMA, METASTATIC																														
LIPOSARCOMA, METASTATIC																										X				
BILE DUCT	+	+	+	+	+	+	+	+	+	+	+	+	+	+	+	+	+	+	+	+	+	+	+	+	+	+	+	+	+	+
GALLBLADDER & COMMON BILE DUCT	M	M	M	M	M	M	M	M	M	M	M	A	M	M	M	M	M	M	M	M	M	M	M	M	M	M	M	M	M	M
PANCREAS	+	+	-	+	+	+	+	+	+	+	+	+	+	+	+	+	+	+	+	+	+	+	+	+	+	+	+	+	+	+
ACINAR-CELL ADENOMA		X																										X		
ACINAR-CELL CARCINOMA																														
ESOPHAGUS	+	+	+	+	+	+	+	+	+	+	+	+	+	+	+	+	+	+	+	+	+	+	+	+	+	+	+	+	+	+
STOMACH	+	+	+	+	+	+	+	+	+	+	+	+	+	+	+	+	+	+	+	+	+	+	+	+	+	+	+	+	+	+
ADENOCARCINOMA, NOS																														
SMALL INTESTINE	+	+	+	+	+	+	+	+	+	+	+	+	+	+	+	+	+	+	+	+	+	+	+	+	+	+	+	+	+	+
ADENOMATOUS POLYP, NOS																														
MUCINOUS CYSTADENOCARCINOMA																														
SIGNET RING CARCINOMA																														
LEIOMYOMA																														
LEIOMYOSARCOMA																														
LARGE INTESTINE	+	+	+	+	+	+	+	+	+	+	+	+	+	+	+	+	X	+	+	+	+	+	+	+	+	+	+	+	+	+
ADENOMATOUS POLYP, NOS																														
URINARY SYSTEM																														
KIDNEY	+	+	+	+	+	+	+	+	+	+	+	+	+	+	+	+	+	+	+	+	+	+	+	+	+	+	+	+	+	+
TUBULAR-CELL ADENOCARCINOMA																														
TUBULAR ADENOCARCINOMA																														
LIPOMA																														
LIPOSARCOMA, INVASIVE																														
MIXED TUMOR, MALIGNANT																										X				
URINARY BLADDER	+	+	-	+	+	+	+	+	+	+	+	+	+	+	+	+	+	+	+	+	-	+	+	+	+	+	+			
TRANSITIONAL-CELL PAPILLOMA																														
TRANSITIONAL-CELL CARCINOMA																														

HWBUI0001665

TABLE B3. INDIVIDUAL ANIMAL TUMOR PATHOLOGY OF MALE RATS IN THE LIFETIME FEED STUDY OF INTERMEDIATE-RANGE CHRYSOTILE ASBESTOS: INTERMEDIATE-RANGE (Continued)

ANIMAL NUMBER	0 4 4 1	0 4 4 7	0 4 4 8	0 4 4 9	0 5 0 1	0 5 1 1	0 5 1 2	0 5 1 3	0 5 1 4	0 5 1 5	0 5 5 1	0 5 5 3	0 5 5 4	0 5 5 5	0 5 5 6	0 5 5 7	0 5 5 8	0 5 5 9	0 5 6 0	0 5 6 1	0 5 6 2	0 5 6 3	0 5 6 4	0 5 6 5	0 5 6 6	0 5 6 7	0 5 6 8	0 5 6 9	0 5 7 0
WEEKS ON STUDY	1 2 1	1 3 9	1 6 4	1 1 4	1 1 9	1 2 3	1 3 4	1 3 5	1 4 1	1 4 5	1 5 1	1 5 3	1 5 4	1 5 5	1 5 6	1 5 7	1 5 8	1 5 9	2 1 1	2 2 7	2 2 7	2 3 1	2 3 1	2 4 4	2 4 5	2 4 6	2 4 8	2 4 9	2 5 0	2 5 0
ENDOCRINE SYSTEM																														
PITUITARY	+	+	+	+	+	+	+	+	+	+	+	+	+	+	+	+	+	+	+	+	+	+	+	+	+	+	+	+	+	+
CARCINOMA, NOS								X				X				X	X				X		X			X				
ADENOMA, NOS																														
ADRENAL	+	+	+	+	+	+	+	+	+	+	+	+	+	+	+	+	+	+	+	+	+	+	+	+	+	+	+	+	+	+
CORTICAL ADENOMA																	X													
PHEOCHROMOCYTOMA		X		X	X								X									X		X					X
PHEOCHROMOCYTOMA, MALIGNANT																														
PARAGANGLION	M	M	M	M	M	M	M	M	M	M	M	M	M	M	M	M	M	M	M	M	M	M	M	M	M	M	M	M	M	M
PARAGANGLIOMA, NOS																														
THYROID	+	+	+	+	+	+	+	+	+	+	+	+	+	+	+	+	+	+	+	+	+	+	+	+	+	+	+	+	+	+
FOLLICULAR-CELL ADENOMA																							X							
FOLLICULAR-CELL CARCINOMA																							X							
C-CELL ADENOMA														X					X				X							
C-CELL CARCINOMA													X									X								
SARCOMA, NOS, INVASIVE																														
PARATHYROID	+	+	-	+	+	+	+	+	+	+	+	+	+	+	+	+	+	+	+	+	+	+	+	+	+	+	+	+	+	+
ADENOMA, NOS																														
C-CELL CARCINOMA, INVASIVE																														
PANCREATIC ISLETS	+	+	-	+	+	+	+	+	+	+	+	+	+	+	+	+	+	+	+	+	+	+	+	+	+	+	+	+	+	+
ISLET-CELL ADENOMA					X																									
ISLET-CELL CARCINOMA																														
REPRODUCTIVE SYSTEM																														
MAMMARY GLAND	+	+	N	+	+	+	+	+	+	+	+	+	+	+	+	+	+	+	+	+	N	+	+	+	+	+	+	+	+	N
ADENOMA, NOS																														
ADENOCARCINOMA, NOS																														
FIBROMA																														
CARCINOSARCOMA																														
FIBROADENOMA																					X				X					
TESTIS	+	+	+	+	+	+	+	+	+	+	+	+	+	+	+	+	+	+	+	+	+	+	+	+	+	+	+	+	+	+
INTERSTITIAL-CELL TUMOR	X	X		X	X	X	X	X	X	X	X	X	X	X	X	X	X	X	X	X	X	X	X	X	X		X	X	X	X
INTERSTITIAL-CELL TUMOR, MALIGNAN																														
PROSTATE	+	+	+	+	+	+	+	+	+	+	+	+	+	+	+	+	+	+	+	+	+	+	+	+	+	+	+	+	+	+
CARCINOMA, NOS																								X						
ADENOMA, NOS																														
PENIS	M	M	M	M	M	M	M	M	M	M	M	M	M	M	M	M	M	M	M	M	M	M	M	M	M	M	M	M	M	M
SQUAMOUS CELL CARCINOMA																														
PREPUTIAL/CLITORAL GLAND	M	M	M	M	M	M	M	M	M	M	M	M	M	M	M	M	M	M	M	M	M	M	M	M	M	M	M	M	M	M
CARCINOMA, NOS																													X	
SQUAMOUS CELL CARCINOMA																														
EPIDIDYMIS	M	M	M	M	M	M	M	M	M	M	M	M	M	M	M	M	M	M	M	M	M	M	M	M	M	M	M	M	M	M
LIPOSARCOMA																														
NERVOUS SYSTEM																														
BRAIN	+	+	+	+	+	+	+	+	+	+	+	+	+	+	+	+	+	+	+	+	+	+	+	+	+	+	+	+	+	+
CARCINOMA, NOS, INVASIVE																														
ASTROCYTOMA																														
MENINGIOMA																														
SPECIAL SENSE ORGANS																														
EYE	M	+	M	M	M	M	M	M	M	M	M	M	M	M	M	M	M	M	M	M	M	M	+	M	M	M	M	M	M	M
MALIGNANT MELANOMA																														
HARDERIAN GLAND	M	M	M	M	M	M	M	M	M	M	M	M	M	M	M	M	M	M	M	M	M	M	M	M	M	M	M	M	M	M
SARCOMA, NOS, INVASIVE																														
ZYMBAL GLAND	+	+	N	+	+	+	+	+	+	+	+	+	+	+	+	+	+	+	+	+	+	+	+	+	N	+	+	+	+	+
CARCINOMA, NOS																														
SQUAMOUS CELL CARCINOMA								X													X								X	
KERATOACANTHOMA																														
CARCINOSARCOMA																														
MUSCULOSKELETAL SYSTEM																														
BONE	M	M	M	M	M	M	M	M	M	M	M	M	M	M	M	M	M	M	M	M	M	M	M	M	M	M	M	M	M	M
SQUAMOUS CELL PAPILLOMA																														
OSTEOSARCOMA																														
JOINT	M	M	M	M	M	M	M	M	M	M	M	M	M	M	M	M	M	M	M	M	M	M	M	M	M	M	M	M	M	M
OSTEOSARCOMA																														
BODY CAVITIES																														
PLEURA	M	M	M	M	M	M	M	M	M	M	M	M	M	M	M	M	M	M	M	M	M	M	M	M	M	M	M	M	M	M
SQUAMOUS CELL CARCINOMA																														
ADENOCARCINOMA, NOS, METASTATIC																														
MEDIASTINUM	M	M	M	M	M	M	M	M	M	M	M	M	M	M	M	M	M	M	M	M	M	M	M	M	M	M	M	M	M	M
ADENOCARCINOMA, NOS, METASTATIC																														
MESOTHELIOMA, NOS																														
PERITONEUM	M	M	M	M	M	M	M	M	M	M	M	M	M	M	M	M	M	M	M	M	M	M	M	M	M	M	M	M	M	M
LIPOSARCOMA																						X								
TUNICA VAGINALIS	+	+	+	+	+	+	+	+	+	+	+	+	+	+	+	+	+	+	+	+	+	+	+	+	+	+	+	+	+	+
MESOTHELIOMA, NOS																														
MESOTHELIOMA, MALIGNANT																														
MESENTERY	M	M	M	M	M	M	M	M	M	M	M	M	M	M	M	M	M	M	M	M	M	M	M	M	M	M	M	M	M	M
FIBROSARCOMA																														
LIPOMA																														
ALL OTHER SYSTEMS																														
MULTIPLE ORGANS NOS	M	M	M	M	M	M	M	M	M	M	M	M	M	M	M	M	M	M	M	M	M	M	M	M	M	M	M	M	M	M
FIBROSARCOMA, INVASIVE																														
FIBROSARCOMA, METASTATIC																														
FIBROUS HISTIOCYTOMA, METASTATIC																														
CARCINOSARCOMA, METASTATIC																														
MESOTHELIOMA, MALIGNANT																														
MESOTHELIOMA, METASTATIC																														
OSTEOSARCOMA, METASTATIC																														
MALIG.LYMPHOMA, HISTIOCYTIC TYPE																														
MYELOMONOCYTIC LEUKEMIA																														
MONOCYTIC LEUKEMIA																														
LEUKEMIA, MONONUCLEAR CELL			X				X				X	X			X				X					X				X		
HEAD NOS																														
SARCOMA, NOS																														
BACK NOS																														
RHABDOMYOSARCOMA																														
LUMBAR REGION																														
CHONDROSARCOMA																														
LOWER LEG NOS																														
OSTEOSARCOMA																														
ADIPOSE TISSUE																														
MIXED MESENCHYMAL TUMOR, MALIGNAN																														
SCROTUM NOS																														
MESOTHELIOMA, MALIGNANT																														

HWBUI0001666

TABLE B3. INDIVIDUAL ANIMAL TUMOR PATHOLOGY OF MALE RATS IN THE LIFETIME FEED STUDY OF INTERMEDIATE-RANGE CHRYSOTILE ASBESTOS: INTERMEDIATE-RANGE (Continued)



HWBUI0001667

TABLE B3. INDIVIDUAL ANIMAL TUMOR PATHOLOGY OF MALE RATS IN THE LIFETIME FEED STUDY OF INTERMEDIATE-RANGE CHRYSOTILE ASBESTOS: INTERMEDIATE-RANGE (Continued)

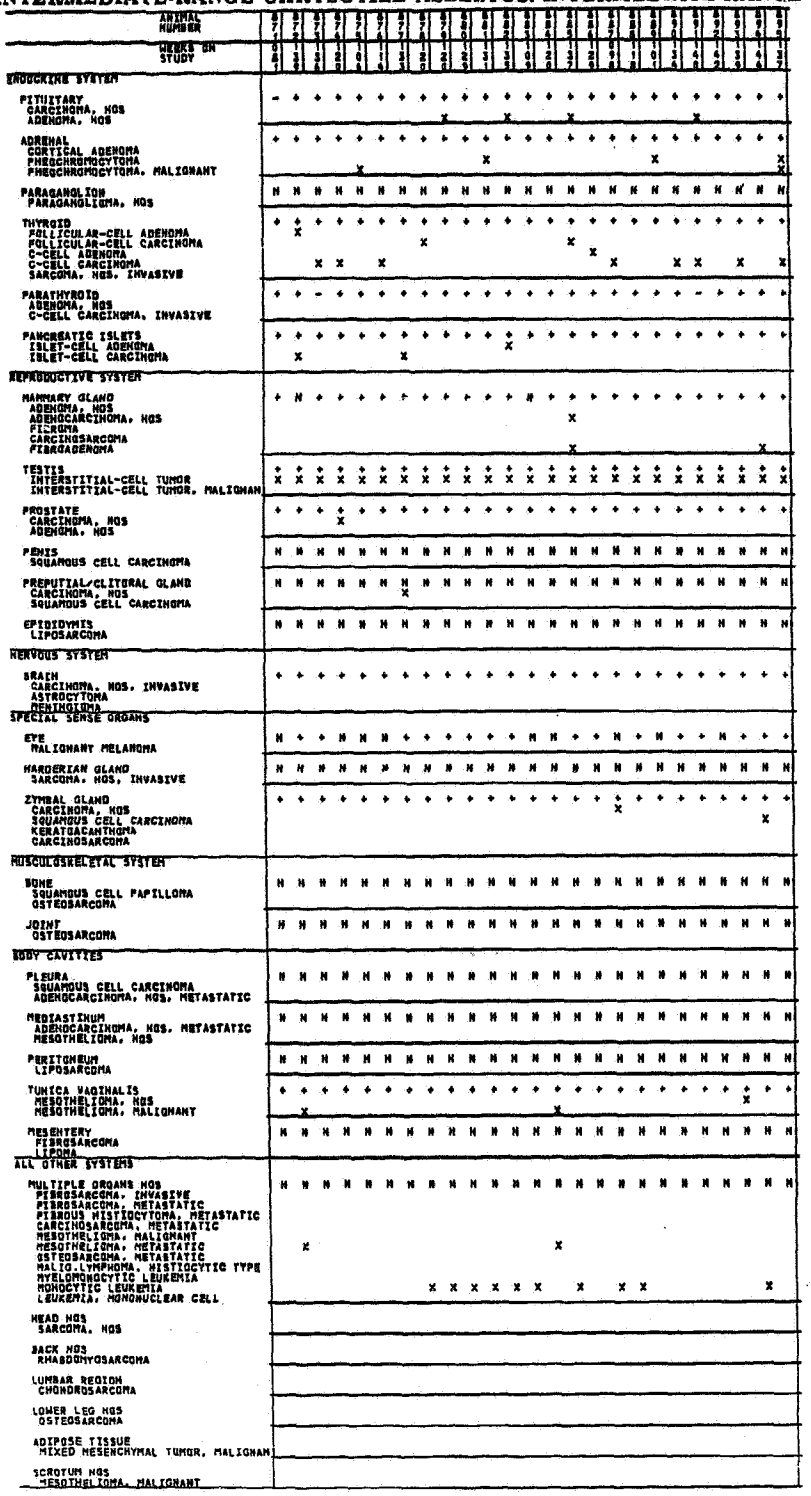

HWBUI0001668

TABLE B3. INDIVIDUAL ANIMAL TUMOR PATHOLOGY OF MALE RATS IN THE LIFETIME FEED STUDY OF INTERMEDIATE-RANGE CHRYSOTILE ASBESTOS: INTERMEDIATE-RANGE (Continued)

ANIMAL NUMBER	6 9 6 7	6 9 7 8	6 9 8 1	6 9 8 2	6 9 8 3	6 9 8 4	6 9 8 5	6 9 8 6	6 9 8 7	6 9 8 8	6 9 8 9	6 9 9 0	6 9 9 1	6 9 9 2	6 9 9 3	6 9 9 4	6 9 9 5	6 9 9 6	6 9 9 7	6 9 9 8	6 9 9 9	6 9 9 10	6 9 9 11	6 9 9 12	6 9 9 13	6 9 9 14	6 9 9 15	6 9 9 16	6 9 9 17	6 9 9 18	6 9 9 19	6 9 10 0
WEEKS ON STUDY	1 3 7	1 5 1	2 0 3	3 7 3	3 9 3	3 9 5	3 9 6	3 9 6	3 9 7	3 9 8	3 9 8	3 9 8	3 9 8	3 9 8	3 9 8	3 9 8	3 9 8	3 9 8	3 9 8	3 9 8	3 9 8	3 9 8	3 9 8	3 9 8	3 9 8	3 9 8	3 9 8	3 9 8	3 9 8	3 9 8	3 9 8	3 9 8
INTEGUMENTARY SYSTEM																																
SKIN	+	+	+	+	+	+	+	M	+	+	+	+	+	+	+	+	+	+	+	+	+	+	+	+	+	+	+	+	+	+	+	+
SQUAMOUS CELL PAPILLOMA																														X		
SQUAMOUS CELL CARCINOMA																															X	
BASAL-CELL TUMOR																																
BASAL-CELL CARCINOMA																																
SEBACEOUS ADENOMA																																
SEBACEOUS ADENOCARCINOMA																																
KERATOACANTHOMA		X																													X	X
FIBROSARCOMA																																
SUBCUTANEOUS TISSUE	+	+	+	+	+	+	+	M	+	+	+	+	+	+	+	+	+	+	+	+	+	+	+	+	+	+	+	+	+	+	+	+
CARCINOMA, NOS																																
SQUAMOUS CELL CARCINOMA																																
BASAL-CELL CARCINOMA																																
SARCOMA, NOS																																
FIBROMA	X								X														X		X						
FIBROSARCOMA																																
FIBROUS HISTIOCYTOMA, MALIGNANT																																
LIPOMA																														X		
OSTEOSARCOMA																																
NEUROFIBROSARCOMA																																
RESPIRATORY SYSTEM																																
LUNGS AND BRONCHI	+	+	+	+	+	+	+	+	+	+	+	+	+	+	+	+	+	+	+	+	+	+	+	+	+	+	+	+	+	+	+	+
SQUAMOUS CELL CARCINOMA, METASTAT																																
ADENOCARCINOMA, NOS, METASTATIC																																
ALVEOLAR/BRONCHIOLAR ADENOMA	X	X																														
ALVEOLAR/BRONCHIOLAR CARCINOMA																																
PHEOCHROMOCYTOMA, METASTATIC																																
FIBROSARCOMA, METASTATIC																																
FIBROUS HISTIOCYTOMA, METASTATIC																																
LIPOSARCOMA, METASTATIC																																
MESOTHELIOMA, NOS																														X		
OSTEOSARCOMA, METASTATIC																																
MENINGIOMA, METASTATIC																																
TRACHEA	+	+	+	+	+	+	+	+	+	+	+	+	+	+	+	+	+	+	+	+	+	+	+	+	+	+	+	+	+	+	+	+
HEMATOPOIETIC SYSTEM																																
BONE MARROW	+	+	+	+	+	+	+	+	+	+	+	+	+	+	+	+	+	+	+	+	+	+	+	+	+	+	+	+	+	+	+	+
SPLEEN	+	+	+	+	+	+	+	+	+	+	+	+	+	+	+	+	+	+	+	+	+	+	+	+	+	+	+	+	+	+	+	+
INTERSTITIAL-CELL TUMOR, METASTAT																																
SARCOMA, NOS																																
HEMANGIOSARCOMA																																
MONOCYTIC LEUKEMIA																																
LYMPH NODES	+	+	+	+	+	+	+	+	+	+	+	+	+	+	+	+	+	+	+	+	+	+	+	+	+	+	+	+	+	+	+	+
SQUAMOUS CELL CARCINOMA, METASTAT																																
SARCOMA, NOS, INVASIVE																																
FIBROUS HISTIOCYTOMA, METASTATIC																																
THYMUS	+	-	-	+	-	+	-	+	+	+	+	+	+	+	+	+	+	+	-	+	+	+	-	+	+	+	-	+	+	+	+	+
CIRCULATORY SYSTEM																																
HEART	+	+	+	+	+	+	+	+	+	+	+	+	+	+	+	+	+	+	+	+	+	+	+	+	+	+	+	+	+	+	+	+
ADENOCARCINOMA, NOS, METASTATIC																																
DIGESTIVE SYSTEM																																
ORAL CAVITY	M	M	M	M	M	M	M	M	M	M	M	M	M	M	M	M	M	M	M	M	M	M	M	M	M	M	M	M	M	M	M	M
SQUAMOUS CELL PAPILLOMA																																
SQUAMOUS CELL CARCINOMA																														X		
KERATOACANTHOMA																																
SALIVARY GLAND	+	+	+	+	+	+	+	+	+	+	+	+	+	+	+	+	+	+	+	+	+	+	+	+	+	+	+	+	+	+	+	+
SARCOMA, NOS																																
FIBROSARCOMA																																
FIBROSARCOMA, INVASIVE																																
LIVER	+	+	+	+	+	+	+	+	+	+	+	+	+	+	+	+	+	+	+	+	+	+	+	+	+	+	+	+	+	+	+	+
NEOPLASTIC NODULE																																
HEPATOCELLULAR CARCINOMA																						X						X				X
FIBROSARCOMA, METASTATIC																																
LIPOSARCOMA, METASTATIC																																
BILE DUCT	+	+	+	+	+	+	+	+	+	+	+	+	+	+	+	+	+	+	+	+	+	+	+	+	+	+	+	+	+	+	+	+
GALLBLADDER & COMMON BILE DUCT	M	M	M	M	M	M	M	M	M	M	M	M	M	M	M	M	M	M	M	M	M	M	M	M	M	M	M	M	M	M	M	M
PANCREAS	+	+	+	+	+	+	+	+	+	+	+	+	+	+	+	+	+	+	+	+	+	+	+	+	+	+	+	+	+	+	+	+
ACINAR-CELL ADENOMA																																
ACINAR-CELL CARCINOMA																																
ESOPHAGUS	+	+	+	+	+	+	+	+	+	+	+	+	+	+	+	+	+	+	+	+	+	+	+	+	+	+	+	+	+	+	+	+
STOMACH	+	+	+	+	+	+	+	+	+	+	+	+	+	+	+	+	+	+	+	+	+	+	+	+	+	+	+	+	+	+	+	+
ADENOCARCINOMA, NOS																																
SMALL INTESTINE	+	+	+	+	+	+	+	+	+	+	+	+	+	+	+	+	+	+	+	+	+	+	+	+	+	+	+	+	+	+	+	+
ADENOMATOUS POLYP, NOS																																
MUCINOUS CYSTADENOCARCINOMA																																
SIGNET RING CARCINOMA																																
LEIOMYOMA																																
LEIOMYOSARCOMA																																
LARGE INTESTINE	+	+	+	+	+	+	+	+	+	+	+	+	+	+	+	+	+	+	+	+	+	+	+	+	+	+	+	+	+	+	+	+
ADENOMATOUS POLYP, NOS			X								X		X																			
URINARY SYSTEM																																
KIDNEY	+	+	+	+	+	+	+	+	+	+	+	+	+	+	+	+	+	+	+	+	+	+	+	+	+	+	+	+	+	+	+	+
TUBULAR-CELL ADENOCARCINOMA																																
TUBULAR ADENOCARCINOMA																																
LIPOMA																																
LIPOSARCOMA, INVASIVE																																
MIXED TUMOR, MALIGNANT																																
URINARY BLADDER	+	+	+	+	+	+	+	+	+	+	+	+	+	+	+	+	+	+	+	+	+	+	+	+	+	+	+	+	+	+	+	+
TRANSITIONAL-CELL PAPILLOMA																																
TRANSITIONAL-CELL CARCINOMA																							X									

HWBUI0001669

TABLE B3. INDIVIDUAL ANIMAL TUMOR PATHOLOGY OF MALE RATS IN THE LIFETIME FEED STUDY OF INTERMEDIATE-RANGE CHRYSOTILE ASBESTOS: INTERMEDIATE-RANGE (Continued)

ANIMAL NUMBER	4 9 6	4 9 7	4 9 8	4 9 9	5 0 0	5 0 1	5 0 2	5 0 3	5 0 4	5 0 5	5 0 6	5 0 7	5 0 8	5 0 9	5 1 0	5 1 1	5 1 2	5 1 3	5 1 4	5 1 5	5 1 6	5 1 7	5 1 8	5 1 9	5 2 0
WEEKS ON STUDY	1 3 7	1 3 1	1 2 6	1 2 5	0 8 8	1 1 2	0 2 7	0 6 5	0 2 8	0 0 6	0 2 5	0 3 9	1 2 5	0 2 5	0 4 4	0 9 4	0 4 4	1 4 4	0 8 5	0 4 4	0 4 4	0 8 4	1 4 4	1 3 1
ENDOCRINE SYSTEM																									
PITUITARY	+	+	+	+	+	+	+	+	-	+	+	+	+	+	+	+	+	+	+	+	+	+	+	+	+
CARCINOMA, NOS		X	X							X							X	X			X				
ADENOMA, NOS																									
ADRENAL	+	+	+	+	+	+	+	+	+	+	+	+	+	+	+	+	+	+	+	+	+	+	+	+	+
CORTICAL ADENOMA	X			X						X	X	X	X	X	X			X							X
PHEOCHROMOCYTOMA																									
PHEOCHROMOCYTOMA, MALIGNANT																									
PARAGANGLION	N	N	N	N	N	N	N	N	N	N	N	N	N	N	N	N	N	N	N	N	N	N	N	N	N
PARAGANGLIOMA, NOS																									
THYROID	+	+	+	+	+	+	+	+	+	+	+	+	+	+	+	+	+	+	+	+	+	+	+	+	+
FOLLICULAR-CELL ADENOMA																							X		
FOLLICULAR-CELL CARCINOMA																									
C-CELL ADENOMA	X										X						X		X						
C-CELL CARCINOMA		X			X							X									X				X
SARCOMA, NOS, INVASIVE																									
PARATHYROID	+	-	+	+	+	+	+	+	+	+	+	+	+	+	+	+	+	+	+	+	+	+	+	+	+
ADENOMA, NOS																									
C-CELL CARCINOMA, INVASIVE																									
PANCREATIC ISLETS	+	+	+	+	+	+	+	+	+	+	+	+	+	+	+	+	+	+	+	+	+	+	+	+	+
ISLET-CELL ADENOMA																			X		X			X	X
ISLET-CELL CARCINOMA																									
REPRODUCTIVE SYSTEM																									
MAMMARY GLAND	+	+	+	+	+	+	+	+	H	+	H	+	+	+	+	+	+	+	+	+	+	+	+	+	+
ADENOMA, NOS																									
ADENOCARCINOMA, NOS																									
FIBROMA																									
CARCINOSARCOMA		X																							
FIBROADENOMA						X																		X	X
TESTIS	+	+	+	+	+	+	+	+	+	+	+	+	+	+	+	+	+	+	+	+	+	+	+	+	+
INTERSTITIAL-CELL TUMOR	X	X	X	X	X	X	X		X	X	X	X	X	X	X	X	X	X	X		X	X	X	X	X
INTERSTITIAL-CELL TUMOR, MALIGNANT																									
PROSTATE	+	+	+	+	+	+	+	+	+	+	+	+	+	+	+	+	+	+	+	+	+	+	+	+	+
CARCINOMA, NOS										X															
ADENOMA, NOS																									
PENIS	N	N	N	N	N	N	N	N	N	N	N	N	N	N	N	N	N	N	N	N	N	N	N	N	N
SQUAMOUS CELL CARCINOMA																									
PREPUTIAL/CLITORAL GLAND	N	N	N	N	N	N	N	N	N	N	N	N	N	N	N	N	N	N	N	N	N	N	N	N	N
CARCINOMA, NOS																									
SQUAMOUS CELL CARCINOMA			X																						
EPIDIDYMIS	N	N	N	N	N	N	N	N	N	N	N	N	X	N	N	N	N	N	N	N	N	N	N	N	N
LIPOSARCOMA																									
NERVOUS SYSTEM																									
BRAIN	+	+	+	+	+	+	+	+	+	+	+	+	+	+	+	+	+	+	+	+	+	+	+	+	+
CARCINOMA, NOS, INVASIVE																									
ASTROCYTOMA																									
MENINGIOMA																									
SPECIAL SENSE ORGANS																									
EYE	+	N	+	N	N	N	+	N	N	N	N	N	N	N	+	N	N	+	+	N	+	N	N	+	N
MALIGNANT MELANOMA																									
HARDERIAN GLAND	N	N	N	N	N	N	N	N	N	N	N	N	N	N	N	N	N	N	N	N	N	N	N	N	N
SARCOMA, NOS, INVASIVE																									
ZYMBAL GLAND	+	+	+	+	+	+	+	+	+	+	+	+	+	+	+	+	+	+	+	+	+	+	+	+	+
CARCINOMA, NOS																									
SQUAMOUS CELL CARCINOMA																									
KERATOACANTHOMA																									
CARCINOSARCOMA																									
MUSCULOSKELETAL SYSTEM																									
BONE	N	N	N	N	N	N	N	N	N	N	N	N	N	N	N	N	N	N	N	N	N	N	N	N	N
SQUAMOUS CELL PAPILLOMA																									
OSTEOSARCOMA																									
JOINT	N	N	N	N	N	N	N	N	N	N	N	N	N	N	N	N	N	N	N	N	N	N	N	N	N
OSTEOSARCOMA																									
BODY CAVITIES																									
PLEURA	N	N	N	N	N	N	N	N	N	N	N	N	N	N	N	N	N	N	N	N	N	N	N	N	N
SQUAMOUS CELL CARCINOMA																									
ADENOCARCINOMA, NOS, METASTATIC																									
MEDIASTINUM	N	N	N	N	N	N	N	N	N	N	N	N	N	N	N	N	N	N	N	N	N	N	N	N	N
ADENOCARCINOMA, NOS, METASTATIC																									
MESOTHELIOMA, NOS																						X			
PERITONEUM	N	N	N	N	N	N	N	N	N	N	N	N	N	N	N	N	N	N	N	N	N	N	N	N	N
LIPOSARCOMA																									
TUNICA VAGINALIS	+	+	+	+	+	+	+	+	+	+	+	+	+	+	+	+	+	+	+	+	+	+	+	+	+
MESOTHELIOMA, NOS																									
MESOTHELIOMA, MALIGNANT																									
MESENTERY	N	N	N	N	N	N	N	N	N	N	N	N	N	N	N	N	N	N	N	N	N	N	N	N	N
FIBROSARCOMA																									
LIPOMA																									X
ALL OTHER SYSTEMS																									
MULTIPLE ORGANS NOS	N	N	N	N	N	N	N	N	N	N	N	N	N	N	N	N	N	N	N	N	N	N	N	N	N
FIBROSARCOMA, INVASIVE																									
FIBROSARCOMA, METASTATIC																									
FIBROUS HISTIOCYTOMA, METASTATIC																									
CARCINOSARCOMA, METASTATIC																									
MESOTHELIOMA, MALIGNANT																									
MESOTHELIOMA, METASTATIC																									
OSTEOSARCOMA, METASTATIC																									
MALIG.LYMPHOMA, HISTIOCYTIC TYPE																									
MYELOMONOCYTIC LEUKEMIA										X															
MONOCYTIC LEUKEMIA												X			X	X			X	X	X				
LEUKEMIA, MONONUCLEAR CELL																									
HEAD NOS																									
SARCOMA, NOS																									
BACK NOS																									
RHABDOMYOSARCOMA																									
LUMBAR REGION																									
CHONDROSARCOMA																									
LOWER LEG NOS																									
OSTEOSARCOMA																									
ADIPOSE TISSUE																									
MIXED MESENCHYMAL TUMOR, MALIGNAN																									
SCROTUM NOS																									
MESOTHELIOMA, MALIGNANT																									

HWBUI0001670

TABLE B3. INDIVIDUAL ANIMAL TUMOR PATHOLOGY OF MALE RATS IN THE LIFETIME FEED STUDY OF INTERMEDIATE-RANGE CHRYSOTILE ASBESTOS: INTERMEDIATE-RANGE (Continued)

ANIMAL NUMBER	92111	92124	92131	92146	92153	92167	92178	92182	92195	92206	92211	92230	92241	92254	92267	92271	92285	92291	92303	92314	92325	92331	92346	92354	92365	TOTAL TISSUES TUMORS
WEEKS ON STUDY	21 5	14 0	11 1	16 2	13 4	11 8	10 5	08 2	13 9	09 2	10 6	12 0	09 2	11 0	11 7	11 5	11 5	11 7	11 2	11 6	11 4	11 3	11 8	11 5	11 4	01 2
INTEGUMENTARY SYSTEM																										
SKIN	+	+	+	+	+	+	+	+	+	+	+	+	+	+	+	+	+	+	+	+	+	+	+	+	+	250
SQUAMOUS CELL PAPILLOMA																										8
SQUAMOUS CELL CARCINOMA																										3
BASAL-CELL TUMOR																										2
BASAL-CELL CARCINOMA																										1
SEBACEOUS ADENOMA																										2
SEBACEOUS ADENOCARCINOMA																										1
KERATOACANTHOMA		X												X												19
FIBROSARCOMA																										1
SUBCUTANEOUS TISSUE	+	+	+	+	+	+	+	+	+	+	+	+	+	+	+	+	+	+	+	+	+	+	+	+	+	250
CARCINOMA, NOS																										1
SQUAMOUS CELL CARCINOMA																										1
BASAL-CELL CARCINOMA																										1
SARCOMA, NOS				X			X				X								X			X			5
FIBROMA																										1
FIBROSARCOMA																										5
FIBROUS HISTIOCYTOMA, MALIGNANT																										2
LIPOMA																										1
OSTEOSARCOMA																										2
NEUROFIBROSARCOMA																										1
RESPIRATORY SYSTEM																										
LUNGS AND BRONCHI	+	+	+	+	+	+	+	+	+	+	+	+	+	+	+	+	+	+	+	+	+	+	+	+	+	250
SQUAMOUS CELL CARCINOMA, METASTAT																										1
ADENOCARCINOMA, NOS, METASTATIC																										2
ALVEOLAR/BRONCHIOLAR ADENOMA			X																							4
ALVEOLAR/BRONCHIOLAR CARCINOMA																										1
PHEOCHROMOCYTOMA, METASTATIC																										4
FIBROSARCOMA, METASTATIC																										1
FIBROUS HISTIOCYTOMA, METASTATIC																										1
LIPOSARCOMA, METASTATIC																										1
MESOTHELIOMA, NOS																										1
OSTEOSARCOMA, METASTATIC																										1
MENINGIOMA, METASTATIC																										1
TRACHEA	+	+	+	+	+	+	+	+	+	+	+	+	+	+	+	+	+	+	+	+	+	+	+	+	+	250
HEMATOPOIETIC SYSTEM																										
BONE MARROW	+	+	+	+	+	+	+	–	+	+	+	+	+	+	+	+	+	+	+	+	+	+	+	+	+	248
SPLEEN	+	+	+	+	+	+	+	+	+	+	+	+	+	+	+	+	+	+	+	+	+	+	+	+	+	250
INTERSTITIAL-CELL TUMOR, METASTAT																										1
SARCOMA, NOS																										1
HEMANGIOSARCOMA																							X			3
MONOCYTIC LEUKEMIA																										2
LYMPH NODES	+	+	+	+	+	+	+	+	+	+	+	+	+	+	+	+	+	+	+	+	+	+	+	+	+	250
SQUAMOUS CELL CARCINOMA, METASTAT																										1
SARCOMA, NOS, INVASIVE																										2
FIBROUS HISTIOCYTOMA, METASTATIC																										1
THYMUS	+	–	+	+	+	+	+	+	+	+	+	+	+	+	+	+	+	+	+	+	+	+	+	+	+	212
CIRCULATORY SYSTEM																										
HEART	+	+	+	+	+	+	+	+	+	+	+	+	+	+	+	+	+	+	+	+	+	+	+	+	+	250
ADENOCARCINOMA, NOS, METASTATIC																										1
DIGESTIVE SYSTEM																										
ORAL CAVITY	M	M	M	M	M	M	M	M	M	M	M	M	M	M	M	M	M	M	M	M	M	M	M	M	M	250
SQUAMOUS CELL PAPILLOMA																										1
SQUAMOUS CELL CARCINOMA																										1
KERATOACANTHOMA																										1
SALIVARY GLAND	+	+	+	+	+	+	+	+	+	+	+	+	+	+	+	+	–	+	+	+	+	+	+	+	+	247
SARCOMA, NOS																										3
FIBROSARCOMA								X																		2
FIBROSARCOMA, INVASIVE																										1
LIVER	+	+	+	+	+	+	+	+	+	+	+	+	+	+	+	+	+	+	+	+	+	+	+	+	+	250
NEOPLASTIC NODULE	X						X																			13
HEPATOCELLULAR CARCINOMA																										7
FIBROSARCOMA, METASTATIC																										1
LIPOSARCOMA, METASTATIC																										1
BILE DUCT	+	+	+	+	+	+	+	+	+	+	+	+	+	+	+	+	+	+	+	+	+	+	+	+	+	250
GALLBLADDER & COMMON BILE DUCT	M	M	M	M	M	M	M	M	M	M	M	M	M	M	M	M	M	M	M	M	M	M	M	M	M	250
PANCREAS	+	+	+	+	+	+	+	+	+	+	+	+	+	+	+	+	+	+	+	+	+	+	+	+	+	249
ACINAR-CELL ADENOMA			X																				X			23
ACINAR-CELL CARCINOMA																										2
ESOPHAGUS	+	+	+	+	+	+	+	+	+	+	+	+	+	+	+	+	+	+	+	+	+	+	+	+	+	250
STOMACH	+	+	+	+	+	+	+	+	+	+	+	+	+	+	+	+	+	+	+	+	+	+	+	+	+	250
ADENOCARCINOMA, NOS																										1
SMALL INTESTINE	+	+	+	+	+	+	+	+	+	+	+	+	+	+	+	+	+	+	+	+	+	+	+	+	+	250
ADENOMATOUS POLYP, NOS																										1
MUCINOUS CYSTADENOCARCINOMA																										1
SIGNET RING CARCINOMA																										1
LEIOMYOMA				X																						1
LEIOMYOSARCOMA																										2
LARGE INTESTINE	+	+	+	+	+	+	+	+	+	+	+	+	+	+	+	+	+	+	+	+	+	+	+	+	+	250
ADENOMATOUS POLYP, NOS																							X			9
URINARY SYSTEM																										
KIDNEY	+	+	+	+	+	+	+	+	+	+	+	+	+	+	+	+	+	+	+	+	+	+	+	+	+	250
TUBULAR-CELL ADENOCARCINOMA																										1
TUBULAR ADENOCARCINOMA				X																						1
LIPOMA																										1
LIPOSARCOMA, INVASIVE																										1
MIXED TUMOR, MALIGNANT																										1
URINARY BLADDER	+	+	+	+	+	+	+	+	+	+	+	+	+	+	+	+	+	+	+	+	+	+	+	+	+	249
TRANSITIONAL-CELL PAPILLOMA																										1
TRANSITIONAL-CELL CARCINOMA																										1

HWBUI0001671

TABLE B3. INDIVIDUAL ANIMAL TUMOR PATHOLOGY OF MALE RATS IN THE LIFETIME FEED STUDY OF INTERMEDIATE-RANGE CHRYSOTILE ASBESTOS: INTERMEDIATE-RANGE (Continued)

ANIMAL NUMBER / WEEKS ON STUDY	TOTAL TISSUES / TUMORS
ENDOCRINE SYSTEM	
PITUITARY	246
CARCINOMA, NOS	3
ADENOMA, NOS	49
ADRENAL	250
CORTICAL ADENOMA	6
PHEOCHROMOCYTOMA	59
PHEOCHROMOCYTOMA, MALIGNANT	5
PARAGANGLION	250M
PARAGANGLIOMA, NOS	2
THYROID	250
FOLLICULAR-CELL ADENOMA	12
FOLLICULAR-CELL CARCINOMA	13
C-CELL ADENOMA	29
C-CELL CARCINOMA	38
SARCOMA, NOS, INVASIVE	1
PARATHYROID	243
ADENOMA, NOS	4
C-CELL CARCINOMA, INVASIVE	1
PANCREATIC ISLETS	249
ISLET-CELL ADENOMA	6
ISLET-CELL CARCINOMA	17
REPRODUCTIVE SYSTEM	
MAMMARY GLAND	250M
ADENOMA, NOS	6
ADENOCARCINOMA, NOS	1
FIBROMA	1
CARCINOSARCOMA	1
FIBROADENOMA	16
TESTIS	250
INTERSTITIAL-CELL TUMOR	237
INTERSTITIAL-CELL TUMOR, MALIGNAN	1
PROSTATE	249
CARCINOMA, NOS	2
ADENOMA, NOS	3
PENIS	250M
SQUAMOUS CELL CARCINOMA	1
PREPUTIAL/CLITORAL GLAND	250M
CARCINOMA, NOS	10
SQUAMOUS CELL CARCINOMA	1
EPIDIDYMIS	250M
LIPOSARCOMA	1
NERVOUS SYSTEM	
BRAIN	250
CARCINOMA, NOS, INVASIVE	1
ASTROCYTOMA	3
MENINGIOMA	1
SPECIAL SENSE ORGANS	
EYE	250M
MALIGNANT MELANOMA	1
HARDERIAN GLAND	250M
SARCOMA, NOS, INVASIVE	1
ZYMBAL GLAND	250M
CARCINOMA, NOS	2
SQUAMOUS CELL CARCINOMA	8
KERATOACANTHOMA	1
CARCINOSARCOMA	1
MUSCULOSKELETAL SYSTEM	
BONE	250M
SQUAMOUS CELL PAPILLOMA	1
OSTEOSARCOMA	1
JOINT	250M
OSTEOSARCOMA	1
BODY CAVITIES	
PLEURA	250M
SQUAMOUS CELL CARCINOMA	1
ADENOCARCINOMA, NOS, METASTATIC	1
MEDIASTINUM	250M
ADENOCARCINOMA, NOS, METASTATIC	1
MESOTHELIOMA, NOS	1
PERITONEUM	250M
LIPOSARCOMA	1
TUNICA VAGINALIS	250M
MESOTHELIOMA, NOS	1
MESOTHELIOMA, MALIGNANT	13
MESENTERY	250M
FIBROSARCOMA	1
LIPOMA	1
ALL OTHER SYSTEMS	
MULTIPLE ORGANS NOS	250M
FIBROSARCOMA, INVASIVE	1
FIBROSARCOMA, METASTATIC	1
FIBROUS HISTIOCYTOMA, METASTATIC	1
CARCINOSARCOMA, METASTATIC	1
MESOTHELIOMA, MALIGNANT	1
MESOTHELIOMA, METASTATIC	13
OSTEOSARCOMA, METASTATIC	2
MALIG.LYMPHOMA, HISTIOCYTIC TYPE	1
MYELOMONOCYTIC LEUKEMIA	3
MONOCYTIC LEUKEMIA	90
LEUKEMIA, MONONUCLEAR CELL	1
HEAD NOS	1
SARCOMA, NOS	
BACK NOS	1
RHABDOMYOSARCOMA	
LUMBAR REGION	1
CHONDROSARCOMA	
LOWER LEG NOS	1
OSTEOSARCOMA	
ADIPOSE TISSUE	1
MIXED MESENCHYMAL TUMOR, MALIGNAN	
SCROTUM NOS	2
MESOTHELIOMA, MALIGNANT	

M ANIMALS NECROPSIED

HWBUI0001672

TABLE B3. INDIVIDUAL ANIMAL TUMOR PATHOLOGY OF MALE RATS IN THE LIFETIME FEED STUDY OF INTERMEDIATE-RANGE CHRYSOTILE ASBESTOS: INTERMEDIATE-RANGE PLUS 1,2-DIMETHYLHYDRAZINE DIHYDROCHLORIDE

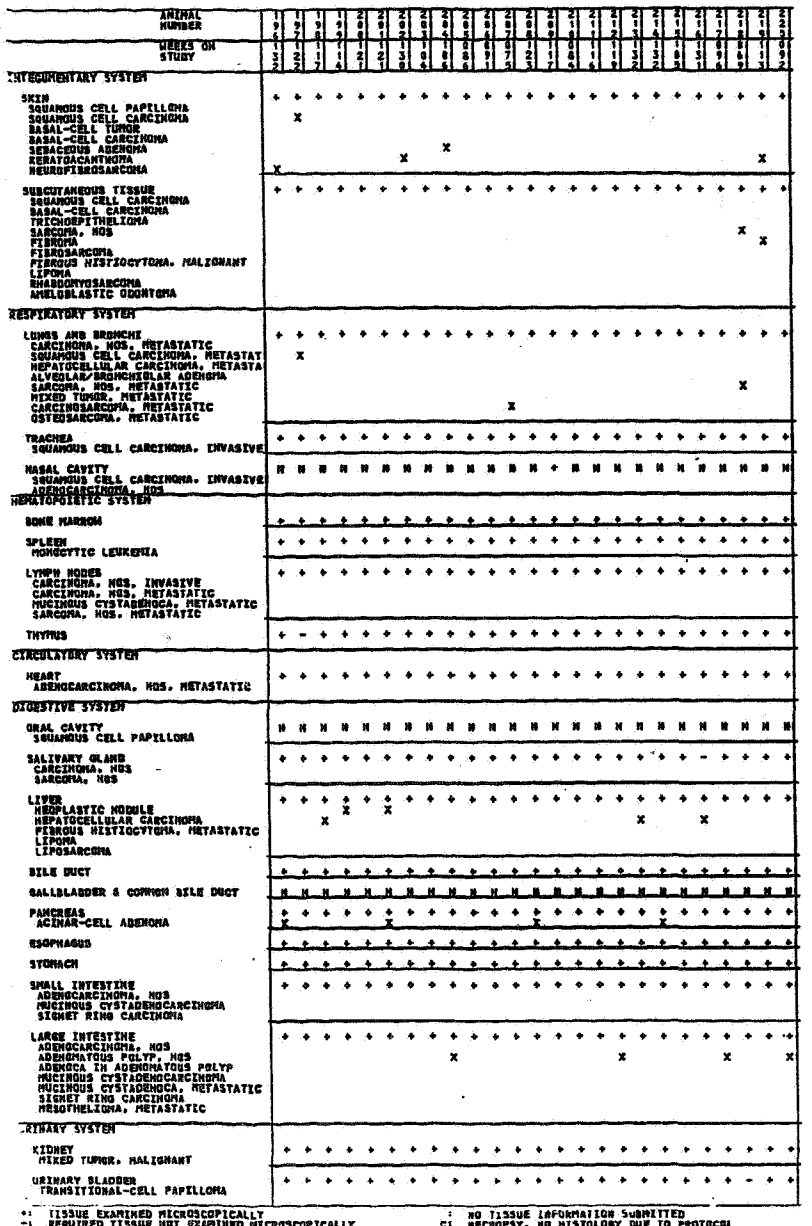

+: TISSUE EXAMINED MICROSCOPICALLY
-: REQUIRED TISSUE NOT EXAMINED MICROSCOPICALLY
X: TUMOR INCIDENCE
M: NECROPSY, NO AUTOLYSIS, NO MICROSCOPIC EXAMINATION
S: ANIMAL MIS-SEXED
I: NO TISSUE INFORMATION SUBMITTED
C: NECROPSY, NO HISTOLOGY DUE TO PROTOCOL
A: AUTOLYSIS
N: ANIMAL MISSING
B: NO NECROPSY PERFORMED

HWBUI0001673

TABLE B3. INDIVIDUAL ANIMAL TUMOR PATHOLOGY OF MALE RATS IN THE LIFETIME FEED STUDY OF INTERMEDIATE-RANGE CHRYSOTILE ASBESTOS: INTERMEDIATE-RANGE PLUS 1,2-DIMETHYLHYDRAZINE DIHYDROCHLORIDE (Continued)

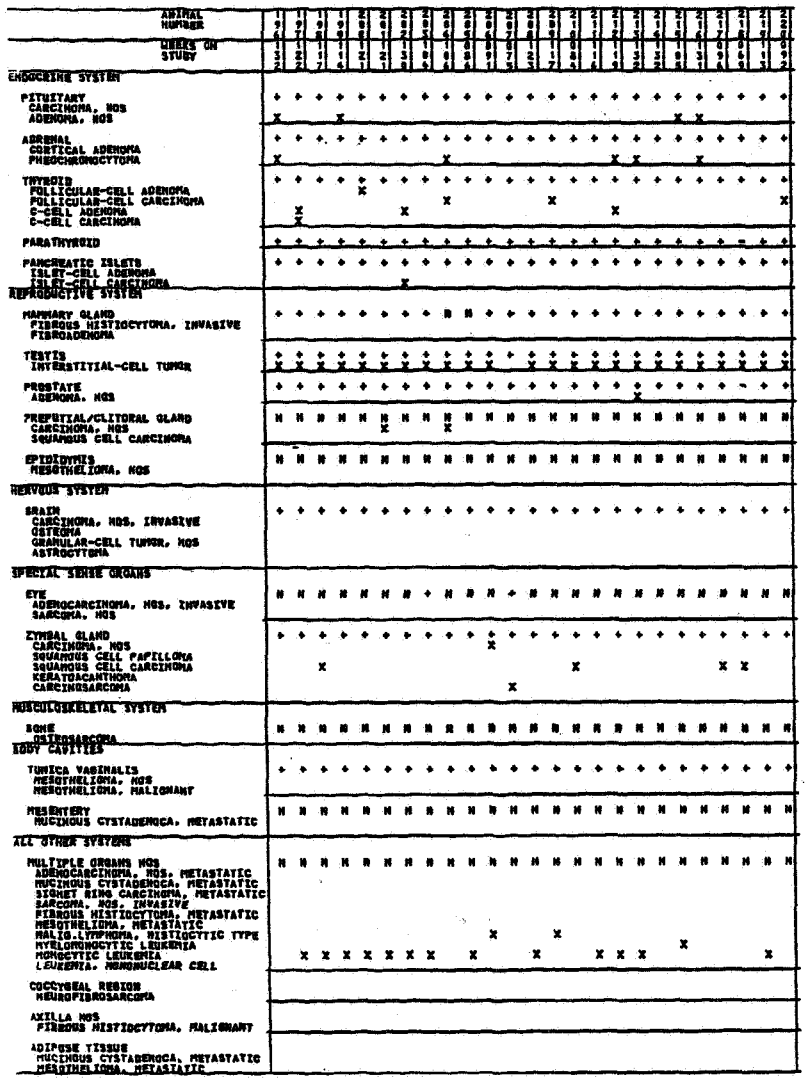

HWBUI0001674

TABLE B3. INDIVIDUAL ANIMAL TUMOR PATHOLOGY OF MALE RATS IN THE LIFETIME FEED STUDY OF INTERMEDIATE-RANGE CHRYSOTILE ASBESTOS: INTERMEDIATE-RANGE PLUS 1,2-DIMETHYLHYDRAZINE DIHYDROCHLORIDE (Continued)

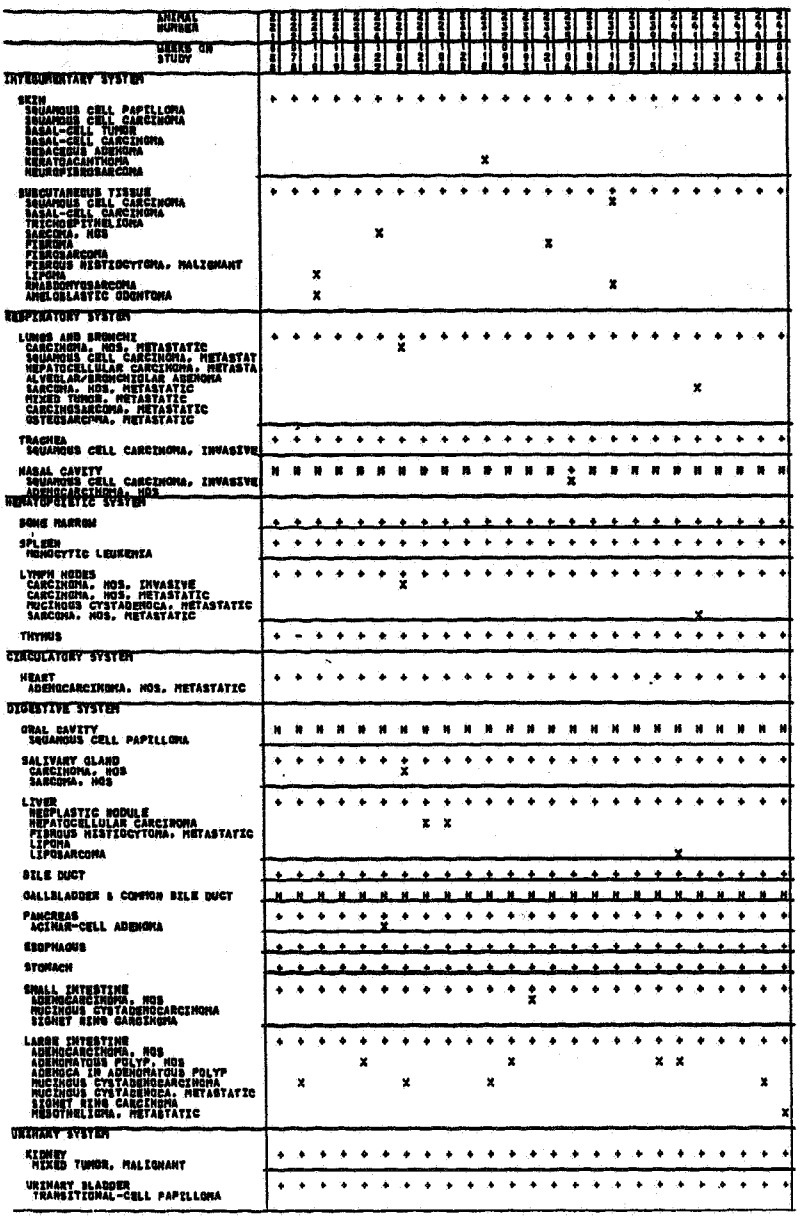

HWBUI0001675

TABLE B3. INDIVIDUAL ANIMAL TUMOR PATHOLOGY OF MALE RATS IN THE LIFETIME FEED STUDY OF INTERMEDIATE-RANGE CHRYSOTILE ASBESTOS: INTERMEDIATE-RANGE PLUS 1,2-DIMETHYLHYDRAZINE DIHYDROCHLORIDE (Continued)

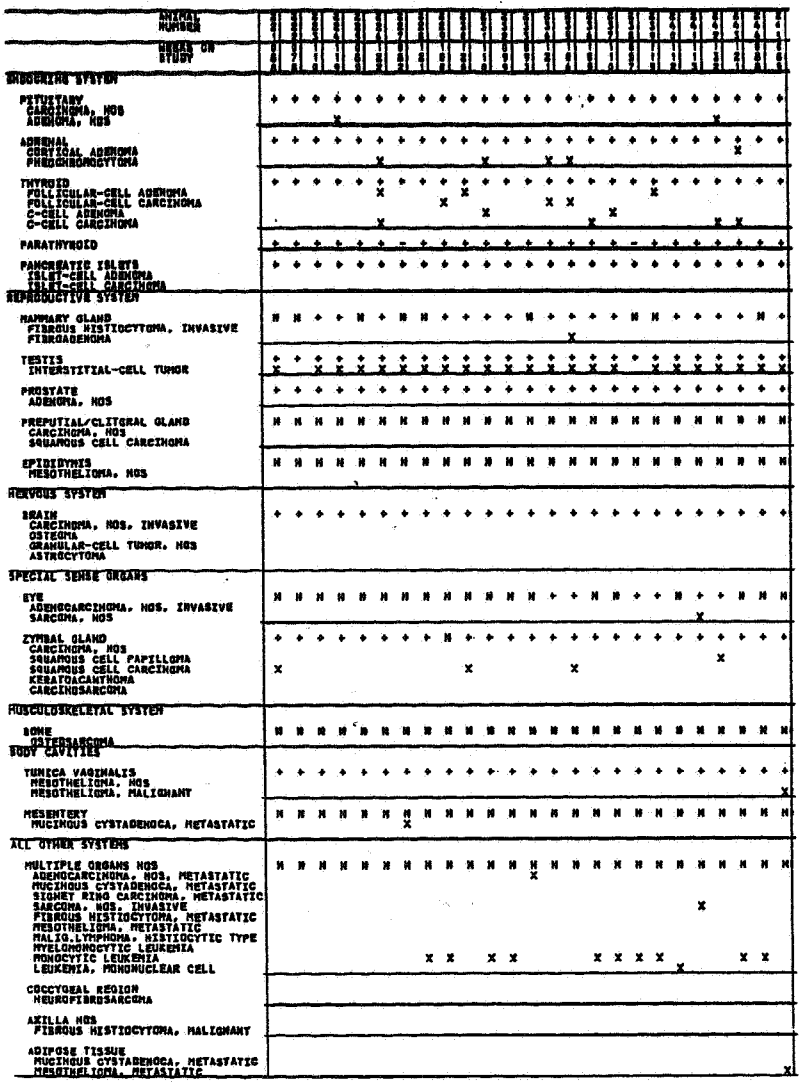

HWBUI0001676

TABLE B3. INDIVIDUAL ANIMAL TUMOR PATHOLOGY OF MALE RATS IN THE LIFETIME FEED STUDY OF INTERMEDIATE-RANGE CHRYSOTILE ASBESTOS: INTERMEDIATE-RANGE PLUS 1,2-DIMETHYLHYDRAZINE DIHYDROCHLORIDE (Continued)

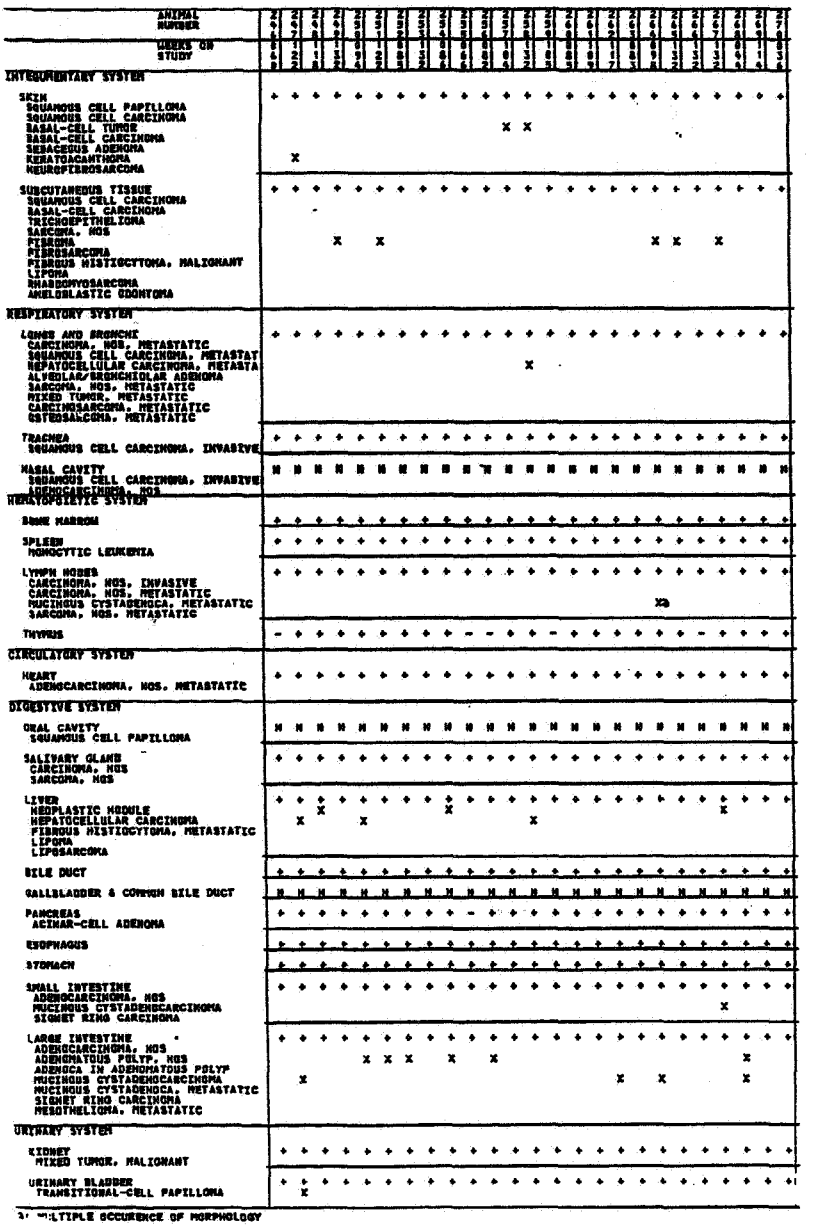

a) MULTIPLE OCCURENCE OF MORPHOLOGY

HWBUI0001677

TABLE B3. INDIVIDUAL ANIMAL TUMOR PATHOLOGY OF MALE RATS IN THE LIFETIME FEED STUDY OF INTERMEDIATE-RANGE CHRYSOTILE ASBESTOS: INTERMEDIATE-RANGE PLUS 1,2-DIMETHYLHYDRAZINE DIHYDROCHLORIDE (Continued)

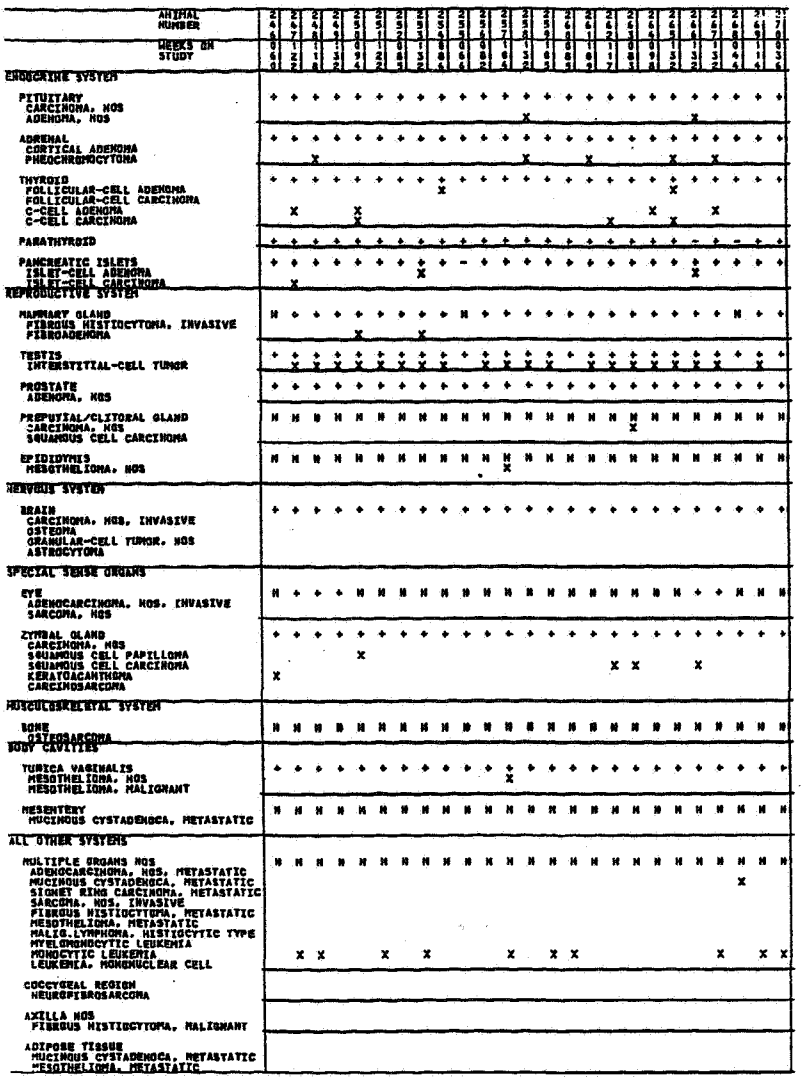

HWBUI0001678

TABLE B3. INDIVIDUAL ANIMAL TUMOR PATHOLOGY OF MALE RATS IN THE LIFETIME FEED STUDY OF INTERMEDIATE-RANGE CHRYSOTILE ASBESTOS: INTERMEDIATE-RANGE PLUS 1,2-DIMETHYLHYDRAZINE DIHYDROCHLORIDE (Continued)

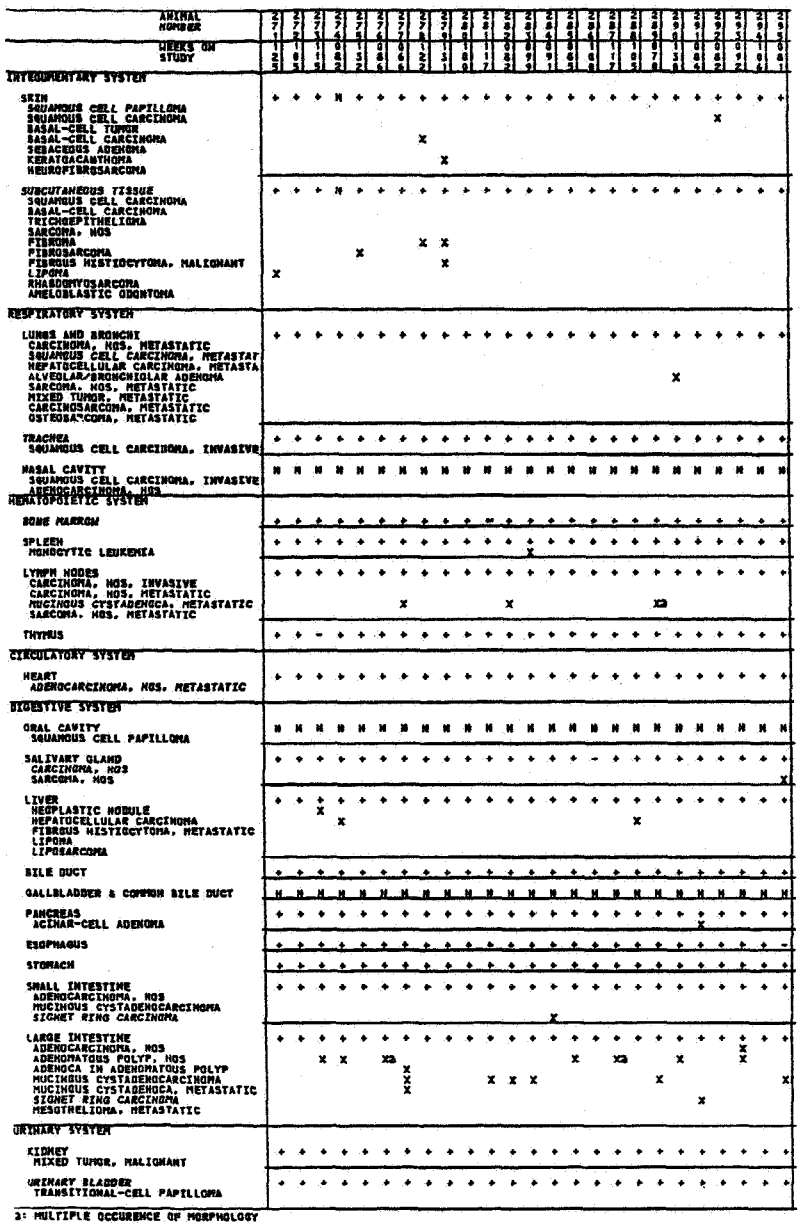

HWBUI0001679

TABLE B3. INDIVIDUAL ANIMAL TUMOR PATHOLOGY OF MALE RATS IN THE LIFETIME FEED STUDY OF INTERMEDIATE-RANGE CHRYSOTILE ASBESTOS: INTERMEDIATE-RANGE PLUS 1,2-DIMETHYLHYDRAZINE DIHYDROCHLORIDE (Continued)

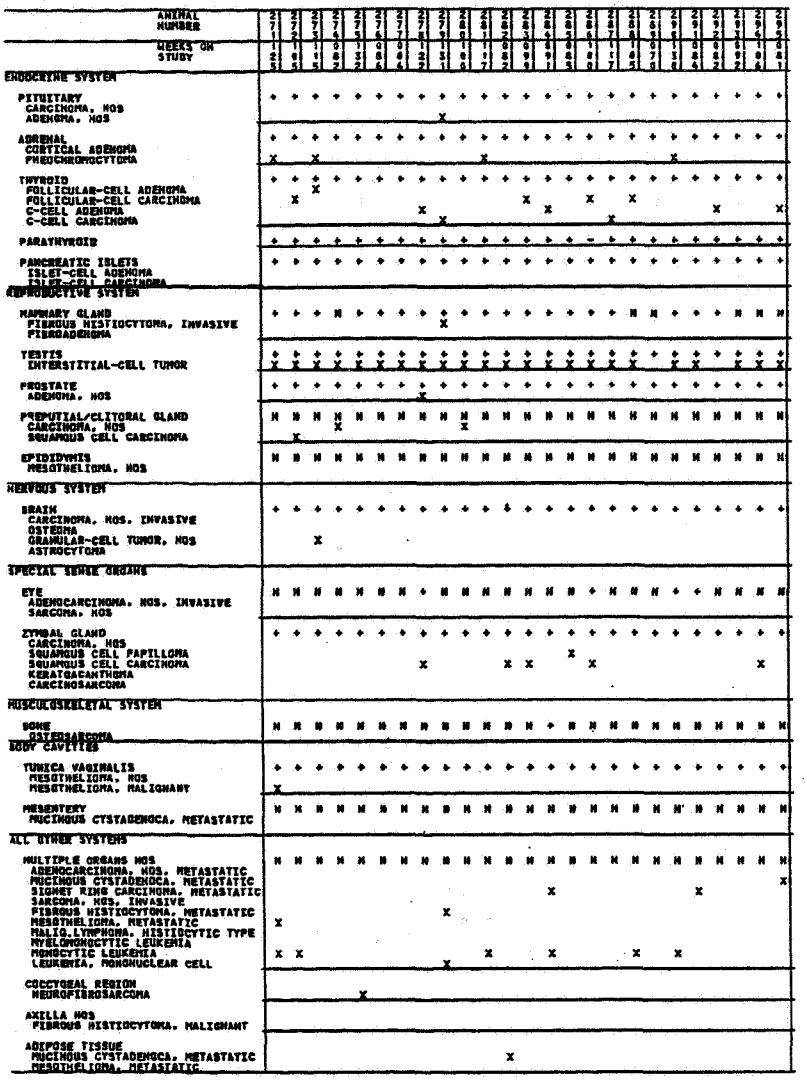

HWBUI0001680

TABLE B3. INDIVIDUAL ANIMAL TUMOR PATHOLOGY OF MALE RATS IN THE LIFETIME FEED STUDY OF INTERMEDIATE-RANGE CHRYSOTILE ASBESTOS: INTERMEDIATE-RANGE PLUS 1,2-DIMETHYLHYDRAZINE DIHYDROCHLORIDE (Continued)

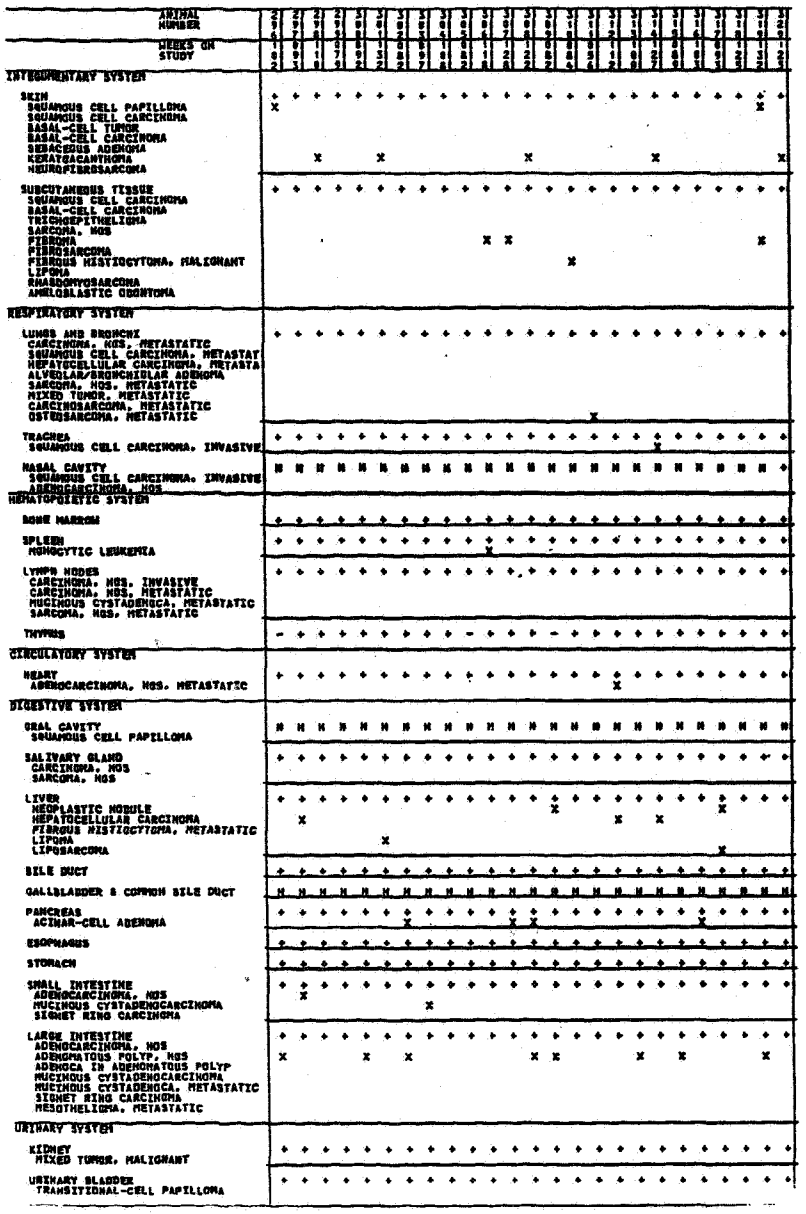

HWBUI0001681

TABLE B3. INDIVIDUAL ANIMAL TUMOR PATHOLOGY OF MALE RATS IN THE LIFETIME FEED STUDY OF INTERMEDIATE-RANGE CHRYSOTILE ASBESTOS: INTERMEDIATE-RANGE PLUS 1,2-DIMETHYLHYDRAZINE DIHYDROCHLORIDE (Continued)

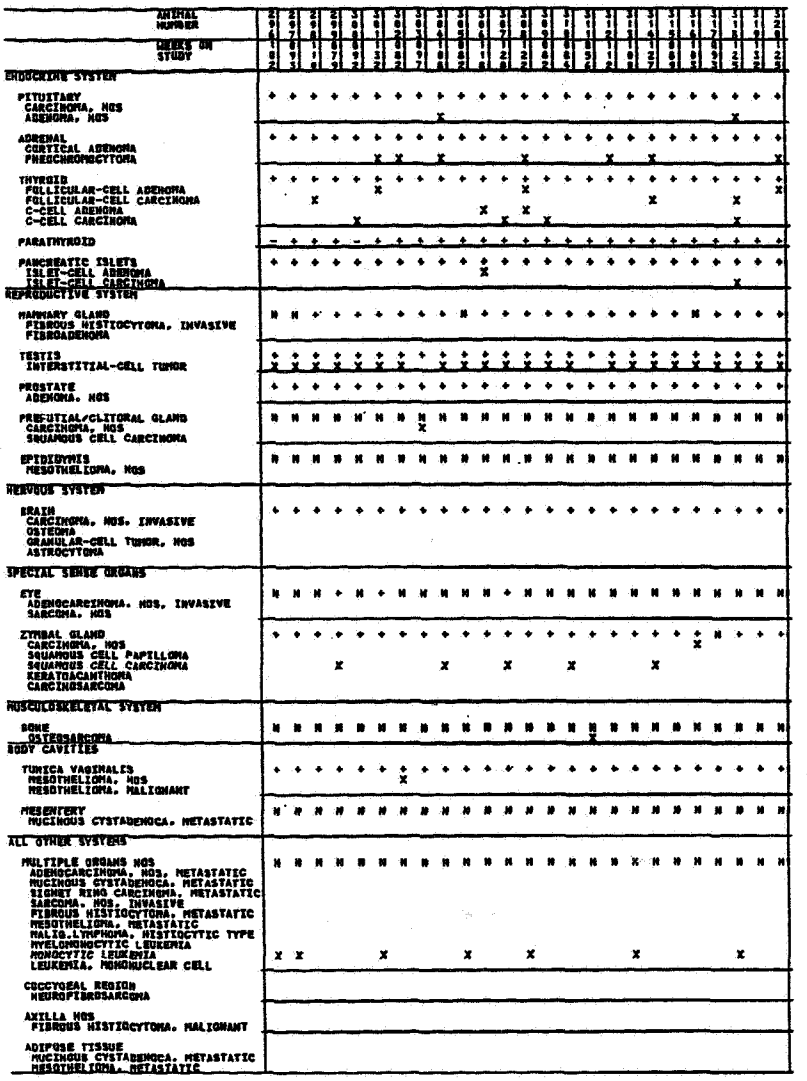

HWBUI0001682

TABLE B3. INDIVIDUAL ANIMAL TUMOR PATHOLOGY OF MALE RATS IN THE LIFETIME FEED STUDY OF INTERMEDIATE-RANGE CHRYSOTILE ASBESTOS: INTERMEDIATE-RANGE PLUS 1,2-DIMETHYLHYDRAZINE DIHYDROCHLORIDE (Continued)

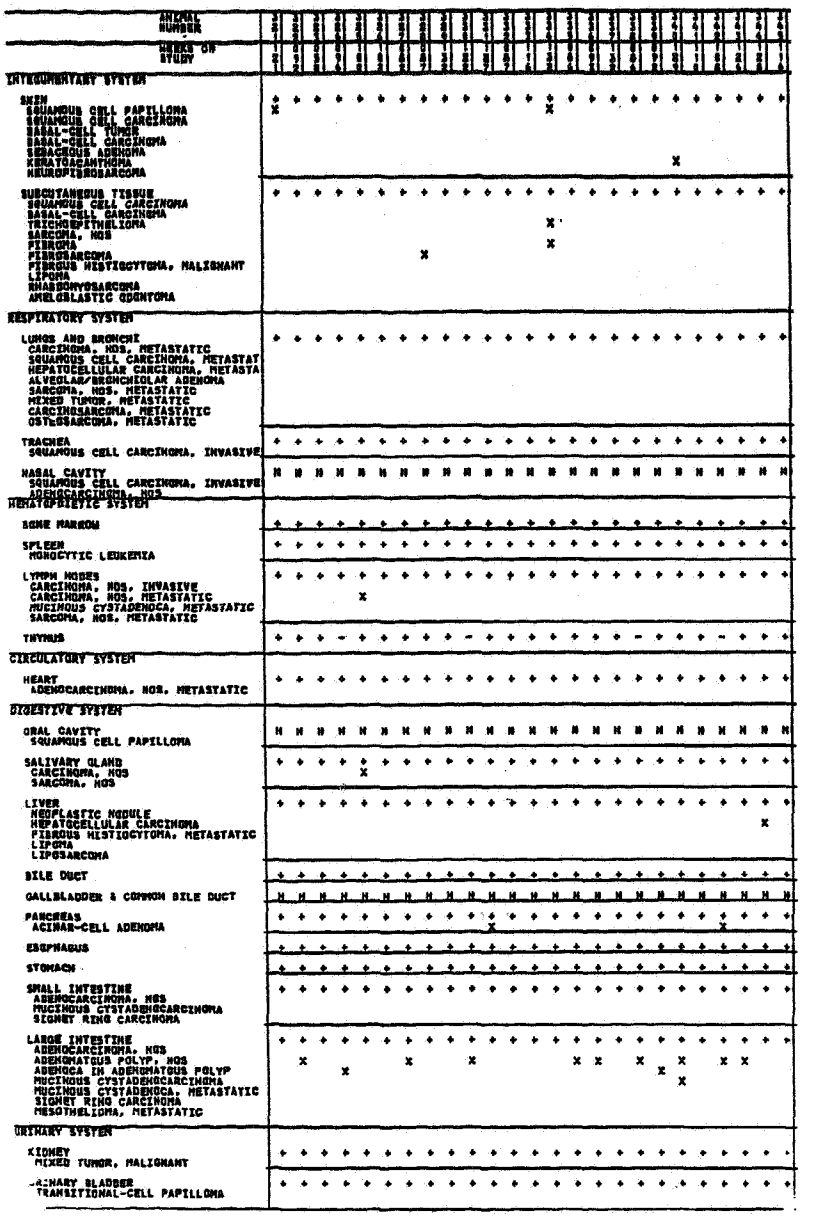

HWBUI0001683

TABLE B3. INDIVIDUAL ANIMAL TUMOR PATHOLOGY OF MALE RATS IN THE LIFETIME FEED STUDY OF INTERMEDIATE-RANGE CHRYSOTILE ASBESTOS: INTERMEDIATE-RANGE PLUS 1,2-DIMETHYLHYDRAZINE DIHYDROCHLORIDE (Continued)

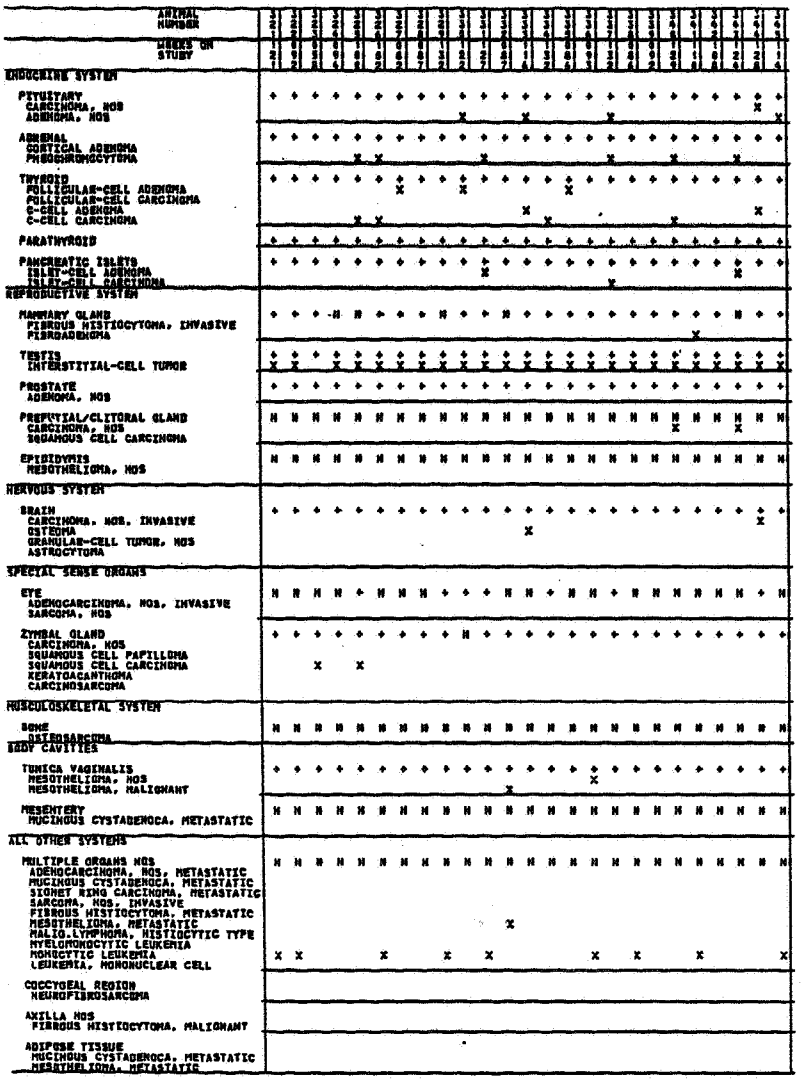

HWBUI0001684

TABLE B3. INDIVIDUAL ANIMAL TUMOR PATHOLOGY OF MALE RATS IN THE LIFETIME FEED STUDY OF INTERMEDIATE-RANGE CHRYSOTILE ASBESTOS: INTERMEDIATE-RANGE PLUS 1,2-DIMETHYLHYDRAZINE DIHYDROCHLORIDE (Continued)

ANIMAL NUMBER / WEEKS ON STUDY	TOTAL TISSUES TUMORS
INTEGUMENTARY SYSTEM	
SKIN	175M
SQUAMOUS CELL PAPILLOMA	4
SQUAMOUS CELL CARCINOMA	3
BASAL-CELL TUMOR	2
BASAL-CELL CARCINOMA	1
SEBACEOUS ADENOMA	1
KERATOACANTHOMA	11
NEUROFIBROSARCOMA	1
SUBCUTANEOUS TISSUE	175M
SQUAMOUS CELL CARCINOMA	1
BASAL-CELL CARCINOMA	1
TRICHOEPITHELIOMA	1
SARCOMA, NOS	2
FIBROMA	15
FIBROSARCOMA	2
FIBROUS HISTIOCYTOMA, MALIGNANT	2
LIPOMA	2
RHABDOMYOSARCOMA	1
AMELOBLASTIC ODONTOMA	1
RESPIRATORY SYSTEM	
LUNGS AND BRONCHI	175
CARCINOMA, NOS, METASTATIC	1
SQUAMOUS CELL CARCINOMA, METASTAT	1
HEPATOCELLULAR CARCINOMA, METASTA	1
ALVEOLAR/BRONCHIOLAR ADENOMA	1
SARCOMA, NOS, METASTATIC	2
MIXED TUMOR, METASTATIC	1
CARCINOSARCOMA, METASTATIC	1
OSTEOSARCOMA, METASTATIC	1
TRACHEA	175
SQUAMOUS CELL CARCINOMA, INVASIVE	1
NASAL CAVITY	175M
SQUAMOUS CELL CARCINOMA, INVASIVE	1
ADENOCARCINOMA, NOS	1
HEMATOPOIETIC SYSTEM	
BONE MARROW	175
SPLEEN	175
MONOCYTIC LEUKEMIA	2
LYMPH NODES	175
CARCINOMA, NOS, INVASIVE	1
CARCINOMA, NOS, METASTATIC	1
MUCINOUS CYSTADENOCA, METASTATIC	2
SARCOMA, NOS, METASTATIC	1
THYMUS	156
CIRCULATORY SYSTEM	
HEART	175
ADENOCARCINOMA, NOS, METASTATIC	1
DIGESTIVE SYSTEM	
ORAL CAVITY	175M
SQUAMOUS CELL PAPILLOMA	1
SALIVARY GLAND	173
CARCINOMA, NOS	2
SARCOMA, NOS	2
LIVER	175
NEOPLASTIC NODULE	18
HEPATOCELLULAR CARCINOMA	28
FIBROUS HISTIOCYTOMA, METASTATIC	1
LIPOMA	1
LIPOSARCOMA	2
BILE DUCT	175
GALLBLADDER & COMMON BILE DUCT	175M
PANCREAS	174
ACINAR-CELL ADENOMA	16
ESOPHAGUS	174
STOMACH	175
SMALL INTESTINE	173
ADENOCARCINOMA, NOS	2
MUCINOUS CYSTADENOCARCINOMA	2
SIGNET RING CARCINOMA	1
LARGE INTESTINE	173
ADENOCARCINOMA, NOS	1
ADENOMATOUS POLYP, NOS	95
ADENOCA IN ADENOMATOUS POLYP	3
MUCINOUS CYSTADENOCARCINOMA	19
MUCINOUS CYSTADENOCA, METASTATIC	1
SIGNET RING CARCINOMA	1
MESOTHELIOMA, METASTATIC	1
URINARY SYSTEM	
KIDNEY	175
MIXED TUMOR, MALIGNANT	1
URINARY BLADDER	174
TRANSITIONAL-CELL PAPILLOMA	1

HWBUI0001685

TABLE B3. INDIVIDUAL ANIMAL TUMOR PATHOLOGY OF MALE RATS IN THE LIFETIME FEED STUDY OF INTERMEDIATE-RANGE CHRYSOTILE ASBESTOS: INTERMEDIATE-RANGE PLUS 1,2-DIMETHYLHYDRAZINE DIHYDROCHLORIDE (Continued)

ANIMAL NUMBER	TOTAL TISSUES TUMORS
WEEKS ON STUDY	
ENDOCRINE SYSTEM	
PITUITARY	173
CARCINOMA, NOS	1
ADENOMA, NOS	16
ADRENAL	175
CORTICAL ADENOMA	1
PHEOCHROMOCYTOMA	25
THYROID	175
FOLLICULAR-CELL ADENOMA	14
FOLLICULAR-CELL CARCINOMA	14
C-CELL ADENOMA	18
C-CELL CARCINOMA	21
PARATHYROID	166
PANCREATIC ISLETS	174
ISLET-CELL ADENOMA	5
ISLET-CELL CARCINOMA	4
REPRODUCTIVE SYSTEM	
MAMMARY GLAND	175M
FIBROUS HISTIOCYTOMA, INVASIVE	1
FIBROADENOMA	4
TESTIS	175
INTERSTITIAL-CELL TUMOR	168
PROSTATE	174
ADENOMA, NOS	2
PREPUTIAL/CLITORAL GLAND	175M
CARCINOMA, NOS	9
SQUAMOUS CELL CARCINOMA	1
EPIDIDYMIS	175M
MESOTHELIOMA, NOS	1
NERVOUS SYSTEM	
BRAIN	175
CARCINOMA, NOS, INVASIVE	1
OSTEOMA	1
GRANULAR-CELL TUMOR, NOS	1
ASTROCYTOMA	1
SPECIAL SENSE ORGANS	
EYE	175M
ADENOCARCINOMA, NOS, INVASIVE	1
SARCOMA, NOS	1
ZYMBAL GLAND	175M
CARCINOMA, NOS	2
SQUAMOUS CELL PAPILLOMA	3
SQUAMOUS CELL CARCINOMA	22
KERATOACANTHOMA	1
CARCINOSARCOMA	1
MUSCULOSKELETAL SYSTEM	
BONE	175M
OSTEOSARCOMA	1
BODY CAVITIES	
TUNICA VAGINALIS	175M
MESOTHELIOMA, NOS	3
MESOTHELIOMA, MALIGNANT	6
MESENTERY	175M
MUCINOUS CYSTADENOCA, METASTATIC	1
ALL OTHER SYSTEMS	
MULTIPLE ORGANS NOS	175M
ADENOCARCINOMA, NOS, METASTATIC	2
MUCINOUS CYSTADENOCA, METASTATIC	1
SIGNET RING CARCINOMA, METASTATIC	2
SARCOMA, NOS, INVASIVE	1
FIBROUS HISTIOCYTOMA, METASTATIC	1
MESOTHELIOMA, METASTATIC	3
MALIG.LYMPHOMA, HISTIOCYTIC TYPE	2
MYELOMONOCYTIC LEUKEMIA	2
MONOCYTIC LEUKEMIA	65
LEUKEMIA, MONONUCLEAR CELL	2
COCCYGEAL REGION	
NEUROFIBROSARCOMA	1
AXILLA NOS	
FIBROUS HISTIOCYTOMA, MALIGNANT	1
ADIPOSE TISSUE	
MUCINOUS CYSTADENOCA, METASTATIC	1
MESOTHELIOMA, METASTATIC	1

a ANIMALS NECROPSIED

HWBUI0001686

TABLE B3. INDIVIDUAL ANIMAL TUMOR PATHOLOGY OF MALE RATS IN THE LIFETIME FEED STUDY OF INTERMEDIATE-RANGE CHRYSOTILE ASBESTOS:

ANIMAL NUMBER	54601	54702	54802	54903	55004	55101	55204	55304	55404	55505	55602	55702	55803	55904	56004	56104	56204	56304	56404	56504	56604	56704	56804	56904	57008
WEEKS ON STUDY	128	121	127	138	088	118	144	433	134	222	422	188	090	114	119	118	116	129	001	011	011	004	341	118	078
INTEGUMENTARY SYSTEM																									
SKIN	+	+	+	+	+	+	+	+	+	+	+	+	+	+	+	+	+	+	+	+	+	+	+	+	+
SQUAMOUS CELL PAPILLOMA																									
SQUAMOUS CELL CARCINOMA					X																				
KERATOACANTHOMA		X																				X			
FIBROMA																									
SUBCUTANEOUS TISSUE	+	+	+	+	+	+	+	+	+	+	+	+	+	+	+	+	+	+	+	+	+	+	+	+	+
SQUAMOUS CELL CARCINOMA																									
TRICHOEPITHELIOMA														X											
KERATOACANTHOMA																									
SARCOMA, NOS							X																		X
FIBROMA				X							X														
FIBROSARCOMA																									
RHABDOMYOSARCOMA																									
OSTEOSARCOMA																									
NEUROFIBROMA								X																	
RESPIRATORY SYSTEM																									
LUNGS AND BRONCHI	+	+	+	+	+	+	+	+	+	+	+	+	+	+	+	+	+	+	+	+	+	+	+	+	+
SQUAMOUS CELL CARCINOMA									X																
SQUAMOUS CELL CARCINOMA, METASTAT																									
TRACHEA	+	+	+	+	+	+	+	+	+	+	+	+	+	+	+	+	+	+	+	+	+	+	+	+	+
HEMATOPOIETIC SYSTEM																									
BONE MARROW	+	-	+	+	+	+	+	+	+	+	+	+	+	+	+	+	+	+	+	+	+	+	+	+	+
SPLEEN	+	+	+	+	+	+	+	+	+	+	+	+	+	+	+	+	+	+	+	+	+	+	+	+	+
LYMPH NODES	+	+	+	+	+	+	+	+	+	+	+	+	+	+	+	+	+	+	+	+	+	+	+	+	+
C-CELL CARCINOMA, METASTATIC																									
THYMUS	+	+	+	+	+	-	+	+	+	+	+	+	+	+	+	+	-	+	+	+	-	+	+	+	+
CIRCULATORY SYSTEM																									
HEART	+	+	+	+	+	+	+	+	+	+	+	+	+	+	+	+	+	+	+	+	+	+	+	+	+
DIGESTIVE SYSTEM																									
ORAL CAVITY	N	N	N	N	N	N	N	N	N	N	N	N	N	N	N	N	N	N	N	N	N	N	N	N	N
SQUAMOUS CELL PAPILLOMA																									
SALIVARY GLAND	+	+	+	+	+	+	+	+	+	+	+	+	+	+	+	+	+	+	+	+	+	+	+	+	+
LIVER	+	+	+	+	+	+	+	+	+	+	+	+	+	+	+	+	+	+	+	+	+	+	+	+	+
NEOPLASTIC NODULE		X																							
HEPATOCELLULAR CARCINOMA																									
MONOCYTIC LEUKEMIA																									
BILE DUCT	+	+	+	+	+	+	+	+	+	+	+	+	+	+	+	+	+	+	+	+	+	+	+	+	+
GALLBLADDER & COMMON BILE DUCT	N	N	N	N	N	N	N	N	N	N	N	N	N	N	N	N	N	N	N	N	N	N	N	N	N
PANCREAS	+	+	+	+	+	+	+	+	+	+	+	+	+	+	+	+	+	+	+	+	+	+	+	+	+
ACINAR-CELL ADENOMA																							X		
MESOTHELIOMA, METASTATIC							X																		
ESOPHAGUS	+	+	+	+	+	+	+	+	+	+	+	+	+	+	+	+	+	+	+	+	+	+	+	+	+
FIBROSARCOMA																									
STOMACH	+	+	+	+	+	+	+	+	+	+	+	+	+	+	+	+	+	+	+	+	+	+	+	+	+
MESOTHELIOMA, METASTATIC							X																		
SMALL INTESTINE	+	+	+	+	+	+	+	+	+	+	+	+	+	+	+	+	+	+	+	+	+	+	+	+	+
LEIOMYOMA																									
LEIOMYOSARCOMA																									
LARGE INTESTINE	+	+	+	+	+	+	+	+	+	+	+	+	+	+	+	+	+	+	+	+	+	+	+	+	+
ADENOMATOUS POLYP, NOS											X											X			
LEIOMYOSARCOMA																									
URINARY SYSTEM																									
KIDNEY	+	+	+	+	+	+	+	+	+	+	+	+	+	+	+	+	+	+	+	+	+	+	+	+	+
URINARY BLADDER	+	+	+	+	+	+	+	+	+	+	+	+	+	+	+	+	+	+	+	+	+	+	+	+	+

+: TISSUE EXAMINED MICROSCOPICALLY
-: REQUIRED TISSUE NOT EXAMINED MICROSCOPICALLY
X: TUMOR INCIDENCE
N: NECROPSY, NO AUTOLYSIS, NO MICROSCOPIC EXAMINATION
S: ANIMAL MIS-SEXED
: NO TISSUE INFORMATION SUBMITTED
C: NECROPSY, NO HISTOLOGY DUE TO PROTOCOL
A: AUTOLYSIS
M: ANIMAL MISSING
B: NO NECROPSY PERFORMED

HWBUI0001687

TABLE B3. INDIVIDUAL ANIMAL TUMOR PATHOLOGY OF MALE RATS IN THE LIFETIME FEED STUDY OF INTERMEDIATE-RANGE CHRYSOTILE ASBESTOS: INTERMEDIATE-RANGE AND PREWEANING GAVAGE (Continued)

ANIMAL NUMBER	546	547	548	549	550	551	552	553	554	555	556	557	558	559	560	561	562	563	564	565	566	567	568	569	570
WEEKS ON STUDY	128	121	127	138	108	118	144	143	134	122	142	118	090	114	119	118	116	129	118	101	101	104	134	118	078
ENDOCRINE SYSTEM																									
PITUITARY	+	+	+	+	+	+	+	+	+	+	+	+	+	+	+	+	+	+	+	+	+	+	+	+	+
CARCINOMA, NOS																									
ADENOMA, NOS						X	X		X									X			X	X			
ADRENAL	+	+	+	+	+	+	+	+	+	+	+	+	+	+	+	+	+	+	+	+	+	+	+	+	+
CORTICAL ADENOMA																									
PHEOCHROMOCYTOMA			X		X		X	X	X			X		X		X									
THYROID	+	+	+	+	+	+	+	+	+	+	+	+	+	+	+	+	+	+	+	+	+	+	+	+	+
FOLLICULAR-CELL ADENOMA																		X							
FOLLICULAR-CELL CARCINOMA																									
C-CELL ADENOMA												X		X											
C-CELL CARCINOMA				X		X	X		X		X				X		X		X		X				
PARATHYROID	+	+	+	+	+	+	–	+	+	+	+	+	+	+	+	+	+	+	+	+	+	+	+	–	+
PANCREATIC ISLETS	+	+	+	+	+	+	+	+	+	+	+	+	+	+	+	+	+	+	+	+	+	+	+	+	+
ISLET-CELL ADENOMA																						X			
ISLET-CELL CARCINOMA							X																		
REPRODUCTIVE SYSTEM																									
MAMMARY GLAND	+	+	+	+	+	+	+	+	+	+	+	+	N	+	N	+	+	+	+	+	N	+	N	+	+
ADENOMA, NOS																									
FIBROADENOMA																									
TESTIS	+	+	+	+	+	+	+	+	+	+	+	+	+	+	+	+	+	+	+	+	+	+	+	+	+
INTERSTITIAL-CELL TUMOR	X	X	X	X	X	X	X	X	X	X	X	X	X	X	X	X	X	X	X	X	X	X	X		
PROSTATE	+	+	+	+	+	+	+	+	+	+	+	+	+	+	+	+	+	+	+	+	+	+	+	+	+
SQUAMOUS CELL CARCINOMA																									
SEMINAL VESICLE	+	N	+	+	N	N	+	N	+	+	+	+	N	N	+	N	N	+	N	N	N	N	+	N	N
SQUAMOUS CELL CARCINOMA, INVASIVE																									
PREPUTIAL/CLITORAL GLAND	N	N	N	N	N	N	N	N	N	N	N	N	N	N	N	N	N	N	N	N	N	N	N	N	N
CARCINOMA, NOS															X										
NERVOUS SYSTEM																									
BRAIN	+	+	+	+	+	+	+	+	+	+	+	+	+	+	+	+	+	+	+	+	+	+	+	+	+
CARCINOMA, NOS, INVASIVE																									
GRANULAR-CELL TUMOR, NOS																									
ASTROCYTOMA																									
SPECIAL SENSE ORGANS																									
ZYMBAL GLAND	+	+	+	+	+	+	+	+	+	+	+	+	+	+	+	+	+	+	+	+	+	+	+	+	+
SQUAMOUS CELL CARCINOMA																									
MUSCULOSKELETAL SYSTEM																									
BONE	N	N	N	N	N	N	N	N	N	N	N	N	N	N	N	N	N	N	N	N	N	N	N	N	N
SQUAMOUS CELL CARCINOMA																									
SARCOMA, NOS																									
MUSCLE	N	N	N	N	N	N	N	N	N	N	+	N	N	N	N	N	N	N	N	N	N	N	N	N	N
RHABDOMYOSARCOMA																									
BODY CAVITIES																									
PERITONEUM	N	N	N	N	N	N	N	N	N	N	N	N	N	N	N	N	N	N	N	N	N	N	N	N	N
OSTEOSARCOMA																									
CHONDROMA																									
TUNICA VAGINALIS	+	+	+	+	+	+	+	+	+	+	+	+	+	+	+	+	+	+	+	+	+	+	+	+	+
MESOTHELIOMA, NOS																									
MESOTHELIOMA, MALIGNANT							X				X		X												
ALL OTHER SYSTEMS																									
MULTIPLE ORGANS NOS	N	N	N	N	N	N	N	N	N	N	N	N	N	N	N	N	N	N	N	N	N	N	N	N	N
MESOTHELIOMA, METASTATIC											X		X												
OSTEOSARCOMA, METASTATIC																									
MALIG.LYMPHOMA, HISTIOCYTIC TYPE	X																X								
MONOCYTIC LEUKEMIA		X	X				X	X	X	X	X	X			X	X		X							
HEAD NOS																									
FIBROUS HISTIOCYTOMA, MALIGNANT																									
ORBITAL REGION																									
OSTEOSARCOMA																									
AXILLA NOS																									
FIBROMA																									

HWBUI0001688

TABLE B3. INDIVIDUAL ANIMAL TUMOR PATHOLOGY OF MALE RATS IN THE LIFETIME FEED STUDY OF INTERMEDIATE-RANGE CHRYSOTILE ASBESTOS: INTERMEDIATE-RANGE AND PREWEANING GAVAGE (Continued)

ANIMAL NUMBER	57101	57102	57103	57104	57105	57106	57107	57108	57109	57110	57111	57112	57113	57114	57115	57116	57117	57118	57119	57120	57121	57122	57123	57124	57125
WEEKS ON STUDY	143	112	122	124	134	144	119	144	124	148	119	130	111	106	145	092	124	157	132	129	131	121	121	148	130
INTEGUMENTARY SYSTEM																									
SKIN	+	+	+	+	+	+	+	+	+	+	+	+	+	+	+	+	+	+	+	+	+	+	+	+	+
SQUAMOUS CELL PAPILLOMA					X										X	X									
SQUAMOUS CELL CARCINOMA															X										
KERATOACANTHOMA																									
FIBROMA																									
SUBCUTANEOUS TISSUE	+	+	+	+	+	+	+	+	+	+	+	+	+	+	+	+	+	+	+	+	+	+	+	+	+
SQUAMOUS CELL CARCINOMA																									
TRICHOEPITHELIOMA																									
KERATOACANTHOMA																									
SARCOMA, NOS																									
FIBROMA							X					X							X						
FIBROSARCOMA																			X						
RHABDOMYOSARCOMA																									
OSTEOSARCOMA																									
NEUROFIBROMA																					X				
RESPIRATORY SYSTEM																									
LUNGS AND BRONCHI	+	+	+	+	+	+	+	+	+	+	+	+	+	+	+	+	+	+	+	+	+	+	+	+	+
SQUAMOUS CELL CARCINOMA																									
SQUAMOUS CELL CARCINOMA, METASTAT																									
TRACHEA	+	+	+	+	+	+	+	+	+	+	+	+	+	+	+	+	+	+	+	+	+	+	+	+	+
HEMATOPOIETIC SYSTEM																									
BONE MARROW	+	+	+	+	+	+	+	+	+	+	+	+	+	+	+	+	+	+	+	+	+	+	+	+	+
SPLEEN	+	+	+	+	+	+	+	+	+	+	+	+	+	+	+	+	+	+	+	+	+	+	+	+	+
LYMPH NODES	+	+	+	+	+	+	+	+	+	+	+	+	+	+	+	+	+	+	+	+	+	+	+	+	+
C-CELL CARCINOMA, METASTATIC			X																						
THYMUS	+	+	+	+	+	+	+	+	+	+	–	+	+	+	+	–	+	+	+	+	+	+	+	+	+
CIRCULATORY SYSTEM																									
HEART	+	+	+	+	+	+	+	+	+	+	+	+	+	+	+	+	+	+	+	+	+	+	+	+	+
DIGESTIVE SYSTEM																									
ORAL CAVITY	N	N	N	N	N	N	N	N	N	N	N	N	N	N	N	N	N	N	N	N	N	N	N	N	N
SQUAMOUS CELL PAPILLOMA																									
SALIVARY GLAND	+	+	+	+	+	+	+	+	+	+	+	+	+	+	+	+	+	+	+	+	+	+	+	+	+
LIVER	+	+	+	+	+	+	+	+	+	+	+	+	+	+	+	+	+	+	+	+	+	+	+	+	+
NEOPLASTIC NODULE																							X		
HEPATOCELLULAR CARCINOMA													X												
MONOCYTIC LEUKEMIA																									
BILE DUCT	+	+	+	+	+	+	+	+	+	+	+	+	+	+	+	+	+	+	+	+	+	+	+	+	+
GALLBLADDER & COMMON BILE DUCT	N	N	N	N	N	N	N	N	N	N	N	N	N	N	N	N	N	N	N	N	N	N	N	N	N
PANCREAS	+	+	+	+	+	+	+	+	+	+	+	+	+	+	+	+	+	+	+	+	+	+	+	+	+
ACINAR-CELL ADENOMA				X	X										X		X							X	
MESOTHELIOMA, METASTATIC																									
ESOPHAGUS	+	+	+	+	+	+	+	+	+	+	+	+	+	+	+	+	+	+	+	+	+	+	+	+	+
FIBROSARCOMA																									
STOMACH	+	+	+	+	+	+	+	+	+	+	+	+	+	+	+	+	+	+	+	+	+	+	+	+	+
MESOTHELIOMA, METASTATIC																									
SMALL INTESTINE	+	+	+	+	+	+	+	+	+	+	+	+	+	+	+	+	+	+	+	+	+	+	+	+	+
LEIOMYOMA																									
LEIOMYOSARCOMA																							X		
LARGE INTESTINE	+	+	+	+	+	+	+	+	+	+	+	+	+	+	+	+	+	+	+	+	+	+	+	+	+
ADENOMATOUS POLYP, NOS																									
LEIOMYOSARCOMA								X																	
URINARY SYSTEM																									
KIDNEY	+	+	+	+	+	+	+	+	+	+	+	+	+	+	+	+	+	+	+	+	+	+	+	+	+
URINARY BLADDER	+	+	+	+	+	+	+	+	+	+	+	+	+	+	+	–	+	+	+	+	+	+	+	+	+

HWBUI0001689

TABLE B3. INDIVIDUAL ANIMAL TUMOR PATHOLOGY OF MALE RATS IN THE LIFETIME FEED STUDY OF INTERMEDIATE-RANGE CHRYSOTILE ASBESTOS: INTERMEDIATE-RANGE AND PREWEANING GAVAGE (Continued)

ANIMAL NUMBER	571	572	573	574	575	576	577	578	579	580	581	582	583	584	585	586	587	588	589	590	591	592	593	594	595
WEEKS ON STUDY	143	112	122	124	134	144	119	145	249	043	199	130	111	104	144	092	124	057	133	129	130	112	122	084	130
ENDOCRINE SYSTEM																									
PITUITARY	+	+	+	+	+	+	+	+	+	+	+	+	+	+	+	+	+	+	+	+	+	+	+	+	+
CARCINOMA, NOS																									
ADENOMA, NOS									X		X			X			X		X						X
ADRENAL	+	+	+	+	+	+	+	+	+	+	+	+	+	+	+	+	+	+	+	+	+	+	+	+	+
CORTICAL ADENOMA																									
PHEOCHROMOCYTOMA	X		X		X			X				X	X		X										
THYROID	+	+	+	+	+	+	+	+	+	+	+	+	+	+	+	+	+	+	+	+	+	+	+	+	+
FOLLICULAR-CELL ADENOMA																									
FOLLICULAR-CELL CARCINOMA						X																			
C-CELL ADENOMA												X			X										
C-CELL CARCINOMA		X	X	X									X												
PARATHYROID	+	+	+	+	+	+	+	+	+	+	–	+	+	+	+	+	+	+	+	+	+	+	+	+	+
PANCREATIC ISLETS	+	+	+	+	+	+	+	+	+	+	+	+	+	+	+	+	+	+	+	+	+	+	+	+	+
ISLET-CELL ADENOMA																	X								
ISLET-CELL CARCINOMA							X												X						X
REPRODUCTIVE SYSTEM																									
MAMMARY GLAND	N	+	+	+	+	+	N	+	+	+	+	+	+	+	+	N	+	+	+	+	+	+	+	+	+
ADENOMA, NOS														X											
FIBROADENOMA																			X						
TESTIS	+	+	+	+	+	+	+	+	+	+	+	+	+	+	+	+	+	+	+	+	+	+	+	+	+
INTERSTITIAL-CELL TUMOR	X	X	X	X	X	X	X	X	X		X	X	X	X	X	X	X		X	X	X	X	X	X	X
PROSTATE	+	+	+	+	+	+	+	+	+	+	+	+	+	+	+	+	+	+	+	+	+	+	+	+	+
SQUAMOUS CELL CARCINOMA																									
SEMINAL VESICLE	N	N	+	N	+	+	+	+	+	N	+	+	+	N	+	N	+	N	+	+	+	+	+	N	+
SQUAMOUS CELL CARCINOMA, INVASIVE																									
PREPUTIAL/CLITORAL GLAND	N	N	N	N	N	N	N	N	N	N	N	N	N	N	N	N	N	N	N	N	N	N	N	N	N
CARCINOMA, NOS																									
NERVOUS SYSTEM																									
BRAIN	+	+	+	+	+	+	+	+	+	+	+	+	+	+	+	+	+	+	+	+	+	+	+	+	+
CARCINOMA, NOS, INVASIVE																									
GRANULAR-CELL TUMOR, NOS																									
ASTROCYTOMA																									
SPECIAL SENSE ORGANS																									
ZYMBAL GLAND	+	+	+	+	+	+	+	+	+	+	+	+	+	+	+	+	+	+	+	+	+	+	+	+	+
SQUAMOUS CELL CARCINOMA											X													X	
MUSCULOSKELETAL SYSTEM																									
BONE	N	N	N	N	N	N	N	N	N	N	N	N	N	N	N	N	N	N	N	N	N	N	N	N	N
SQUAMOUS CELL CARCINOMA					X																				
SARCOMA, NOS																									
MUSCLE	N	N	N	N	N	N	N	N	N	N	N	N	N	N	N	N	N	N	N	N	N	N	N	N	N
RHABDOMYOSARCOMA																									
BODY CAVITIES																									
PERITONEUM	N	N	N	N	N	N	N	N	N	N	N	N	N	N	N	N	N	N	N	N	N	N	N	N	N
OSTEOSARCOMA																									
CHONDROMA							X																		
TUNICA VAGINALIS	+	+	+	+	+	+	+	+	+	+	+	+	+	+	+	+	+	+	+	+	+	+	+	+	+
MESOTHELIOMA, NOS							X																		
MESOTHELIOMA, MALIGNANT														X											
ALL OTHER SYSTEMS																									
MULTIPLE ORGANS NOS	N	N	N	N	N	N	N	N	N	N	N	N	N	N	N	N	N	N	N	N	N	N	N	N	N
MESOTHELIOMA, METASTATIC														X											
OSTEOSARCOMA, METASTATIC																					X				
MALIG.LYMPHOMA, HISTIOCYTIC TYPE											X														
MONOCYTIC LEUKEMIA		X				X	X	X	X				X				X			X			X		
HEAD NOS																									
FIBROUS HISTIOCYTOMA, MALIGNANT				X																					
ORBITAL REGION																									
OSTEOSARCOMA																									
AXILLA NOS																									
FIBROMA																									

HWBUI0001690

TABLE B3. INDIVIDUAL ANIMAL TUMOR PATHOLOGY OF MALE RATS IN THE LIFETIME FEED STUDY OF INTERMEDIATE-RANGE CHRYSOTILE ASBESTOS: INTERMEDIATE-RANGE AND PREWEANING GAVAGE (Continued)

ANIMAL NUMBER	596	597	598	599	600	601	602	603	604	605	606	607	608	609	610	611	612	613	614	615	616	617	618	619	620
WEEKS ON STUDY	135	117	111	134	045	119	124	144	142	126	144	144	123	144	143	118	121	119	121	072	127	131	144	117	114
INTEGUMENTARY SYSTEM																									
SKIN	+	+	+	+	+	+	+	+	+	+	+	+	+	+	+	+	+	+	+	+	+	+	+	+	+
SQUAMOUS CELL PAPILLOMA																									
SQUAMOUS CELL CARCINOMA																									
KERATOACANTHOMA												X				X	X								
FIBROMA																									
SUBCUTANEOUS TISSUE	+	+	+	+	+	+	+	+	+	+	+	+	+	+	+	+	+	+	+	+	+	+	+	+	+
SQUAMOUS CELL CARCINOMA									X																
TRICHOEPITHELIOMA																									
KERATOACANTHOMA																									
SARCOMA, NOS		X							X																
FIBROMA				X							X	X		X							X				
FIBROSARCOMA																									
RHABDOMYOSARCOMA																									
OSTEOSARCOMA																									
NEUROFIBROMA																									
RESPIRATORY SYSTEM																									
LUNGS AND BRONCHI	+	+	+	+	+	+	+	+	+	+	+	+	+	+	+	+	+	+	+	+	+	+	+	+	+
SQUAMOUS CELL CARCINOMA																									
SQUAMOUS CELL CARCINOMA, METASTAT																									
TRACHEA	+	+	+	+	+	+	+	+	+	+	+	+	+	+	+	+	+	+	+	+	+	+	+	+	+
HEMATOPOIETIC SYSTEM																									
BONE MARROW	+	+	+	+	+	+	+	+	+	+	+	+	+	+	+	+	+	+	+	+	+	+	+	+	+
SPLEEN	+	+	+	+	+	+	+	+	+	+	+	+	+	+	+	+	+	+	+	+	+	+	+	+	+
LYMPH NODES	+	+	+	+	+	+	+	+	+	+	+	+	+	+	+	+	+	+	+	+	+	+	+	+	+
C-CELL CARCINOMA, METASTATIC																									
THYMUS	+	+	+	+	+	+	+	+	+	+	+	+	+	+	-	+	+	+	+	+	+	+	+	+	-
CIRCULATORY SYSTEM																									
HEART	+	+	+	+	+	+	+	+	+	+	+	+	+	+	+	+	+	+	+	+	+	+	+	+	+
DIGESTIVE SYSTEM																									
ORAL CAVITY	N	N	N	N	N	N	N	N	N	N	N	N	N	N	N	N	N	N	N	N	N	N	N	N	N
SQUAMOUS CELL PAPILLOMA																					X				
SALIVARY GLAND	+	+	+	+	+	+	+	+	+	+	+	+	+	+	+	+	+	+	+	+	+	+	+	+	+
LIVER	+	+	+	+	+	+	+	+	+	+	+	+	+	+	+	+	+	+	+	+	+	+	+	+	+
NEOPLASTIC NODULE							X																		
HEPATOCELLULAR CARCINOMA																									
MONOCYTIC LEUKEMIA																									
BILE DUCT	+	+	+	+	+	+	+	+	+	+	+	+	+	+	+	+	+	+	+	+	+	+	+	+	+
GALLBLADDER & COMMON BILE DUCT	N	N	N	N	N	N	N	N	N	N	N	N	N	N	N	N	N	N	N	N	N	N	N	N	N
PANCREAS	+	+	+	+	+	+	+	+	+	+	+	+	+	+	+	+	+	+	+	+	+	+	+	+	+
ACINAR-CELL ADENOMA																					X				
MESOTHELIOMA, METASTATIC																									
ESOPHAGUS	+	+	+	+	-	+	+	+	+	+	+	+	+	+	+	+	+	+	+	+	+	+	+	+	+
FIBROSARCOMA										X															
STOMACH	+	+	+	+	+	+	+	+	+	+	+	+	+	+	+	+	+	+	+	+	+	+	+	+	+
MESOTHELIOMA, METASTATIC																									
SMALL INTESTINE	+	+	+	+	+	+	+	+	+	+	+	+	+	+	+	+	+	+	+	+	+	+	+	+	+
LEIOMYOMA																									
LEIOMYOSARCOMA																									
LARGE INTESTINE	+	+	+	+	+	+	+	+	+	+	+	+	+	+	+	+	+	+	+	+	+	+	+	+	+
ADENOMATOUS POLYP, NOS																									
LEIOMYOSARCOMA																									
URINARY SYSTEM																									
KIDNEY	+	+	+	+	+	+	+	+	+	+	+	+	+	+	+	+	+	+	+	+	+	+	+	+	+
URINARY BLADDER	+	+	+	+	+	+	+	+	+	+	+	+	+	+	+	-	+	+	+	+	+	+	+	+	+

HWBUI0001691

TABLE B3. INDIVIDUAL ANIMAL TUMOR PATHOLOGY OF MALE RATS IN THE LIFETIME FEED STUDY OF INTERMEDIATE-RANGE CHRYSOTILE ASBESTOS: INTERMEDIATE-RANGE AND PREWEANING GAVAGE (Continued)

ANIMAL NUMBER	596	597	598	599	600	601	602	603	604	605	606	607	608	609	610	611	612	613	614	615	616	617	618	619	620
WEEKS ON STUDY	135	117	111	134	045	119	129	144	142	126	146	146	123	144	143	118	121	119	121	072	127	131	144	117	116
ENDOCRINE SYSTEM																									
PITUITARY	+	+	+	+	+	+	+	+	+	+	+	+	+	+	+	+	+	+	+	+	+	+	+	+	+
CARCINOMA, NOS																	X								
ADENOMA, NOS											X														X
ADRENAL	+	+	+	+	+	+	+	+	+	+	+	+	+	+	+	+	+	+	+	+	+	+	+	+	+
CORTICAL ADENOMA	X							X		X	X	X		X					X						
PHEOCHROMOCYTOMA																			X			X			
THYROID	+	+	+	+	+	+	+	+	+	+	+	+	+	+	+	+	+	+	+	+	+	+	+	+	+
FOLLICULAR-CELL ADENOMA									X								X								
FOLLICULAR-CELL CARCINOMA																									
C-CELL ADENOMA												X							X						X
C-CELL CARCINOMA		X		X		X		X		X											X		X		
PARATHYROID	+	+	+	+	+	+	+	+	+	+	+	+	+	+	+	+	+	+	+	+	+	+	-	+	+
PANCREATIC ISLETS	+	+	+	+	+	+	+	+	+	+	+	+	+	+	+	+	+	+	+	+	+	+	+	+	+
ISLET-CELL ADENOMA	X								X								X								
ISLET-CELL CARCINOMA																								X	
REPRODUCTIVE SYSTEM																									
MAMMARY GLAND	+	+	+	+	+	+	+	+	+	+	+	+	+	+	+	+	+	+	+	N	+	+	+	+	+
ADENOMA, NOS											X		X		X				X			X			
FIBROADENOMA	X																								
TESTIS	+	+	+	+		+	+	+	+	+	+	+	+	+	+	+	+	+	+	+	+	+	+	+	+
INTERSTITIAL-CELL TUMOR	X	X	X	X		X	X	X	X	X	X	X	X	X	X	X	X	X	X		X	X	X	X	X
PROSTATE	+	+	-	+	+	+	+	+	+	+	+	+	+	+	+	+	+	+	+	+	+	+	+	+	+
SQUAMOUS CELL CARCINOMA																									
SEMINAL VESICLE	+	+	N	+	N	N	+	+	+	+	+	+	+	+	N	N	+	+	N	N	+	+	+	+	N
SQUAMOUS CELL CARCINOMA, INVASIVE																									
PREPUTIAL/CLITORAL GLAND	N	N	N	N	N	N	N	N	N	N	N	N	N	N	N	N	N	N	N	N	N	N	N	N	N
CARCINOMA, NOS				X																					
NERVOUS SYSTEM																									
BRAIN	+	+	+	+	+	+	+	+	+	+	+	+	+	+	+	+	+	+	+	+	+	+	+	+	+
CARCINOMA, NOS, INVASIVE																	X								
GRANULAR-CELL TUMOR, NOS																									
ASTROCYTOMA																									
SPECIAL SENSE ORGANS																									
ZYMBAL GLAND	+	+	+	+	+	+	+	+	+	+	+	+	+	+	+	+	+	+	+	+	+	+	+	+	+
SQUAMOUS CELL CARCINOMA																									
MUSCULOSKELETAL SYSTEM																									
BONE	N	N	N	N	N	N	N	N	N	N	N	N	N	N	N	N	N	N	N	N	N	N	N	N	N
SQUAMOUS CELL CARCINOMA																			X						
SARCOMA, NOS	X																								
MUSCLE	N	N	N	N	N	N	N	N	N	N	N	N	N	N	N	N	N	N	N	N	N	N	N	N	N
RHABDOMYOSARCOMA																			X						
BODY CAVITIES																									
PERITONEUM	N	N	N	N	N	N	N	N	N	N	N	N	N	N	N	N	N	N	N	N	N	N	N	N	N
OSTEOSARCOMA																									
CHONDROMA																									
TUNICA VAGINALIS	+	+	+	+	+	+	+	+	+	+	+	+	+	+	+	+	+	+	+	+	+	+	+	+	+
MESOTHELIOMA, NOS																	X								
MESOTHELIOMA, MALIGNANT																									
ALL OTHER SYSTEMS																									
MULTIPLE ORGANS NOS	N	N	N	N	N	N	N	N	N	N	N	N	N	N	N	N	N	N	N	N	N	N	N	N	N
MESOTHELIOMA, METASTATIC																	X								
OSTEOSARCOMA, METASTATIC			X																						
MALIG.LYMPHOMA, HISTIOCYTIC TYPE							X			X											X		X		
MONOCYTIC LEUKEMIA																									X
HEAD NOS																									
FIBROUS HISTIOCYTOMA, MALIGNANT																									
ORBITAL REGION																									
OSTEOSARCOMA			X																						
AXILLA NOS																									
FIBROMA																					X				

HWBUI0001692

TABLE B3. INDIVIDUAL ANIMAL TUMOR PATHOLOGY OF MALE RATS IN THE LIFETIME FEED STUDY OF INTERMEDIATE-RANGE CHRYSOTILE ASBESTOS: INTERMEDIATE-RANGE AND PREWEANING GAVAGE (Continued)

ANIMAL NUMBER	6211	6223	6225	6243	6252	6266	6277	6288	6291	6301	6311	6312	6313	6314	6315	6316	6317	6318	6319	6320	6321	6322	6323	6324	6325	TOTAL TISSUES TUMORS
WEEKS ON STUDY	12 25	10 33	08 35	07 36	13 32	12 36	11 35	13 35	13 33	13 38	12 27	08 35	09 39	14 41	11 41	12 40	11 35	12 38	10 30	11 36	12 34	14 44	12 42	11 45	10 38	
INTEGUMENTARY SYSTEM																										
SKIN	+	+	+	+	+	+	+	+	+	+	+	+	+	+	+	+	+	+	+	+	+	+	+	+	+	100M
SQUAMOUS CELL PAPILLOMA																										3
SQUAMOUS CELL CARCINOMA																										1
KERATOACANTHOMA																						X				7
FIBROMA											X															1
SUBCUTANEOUS TISSUE	+	+	+	+	+	+	+	+	+	+	+	+	+	+	+	+	+	+	+	+	+	+	+	+	+	100M
SQUAMOUS CELL CARCINOMA							X																			2
TRICHOEPITHELIOMA																										1
KERATOACANTHOMA															X											1
SARCOMA, NOS							X																			5
FIBROMA								X																		11
FIBROSARCOMA																										1
RHABDOMYOSARCOMA			X																							1
OSTEOSARCOMA																										1
NEUROFIBROMA																										1
RESPIRATORY SYSTEM																										
LUNGS AND BRONCHI	+	+	+	+	+	+	+	+	+	+	+	+	+	+	+	+	+	+	+	+	+	+	-	+	+	99
SQUAMOUS CELL CARCINOMA																										1
SQUAMOUS CELL CARCINOMA, METASTAT				X								X														2
TRACHEA	+	+	+	+	+	+	+	+	+	+	+	+	+	+	+	+	+	+	+	+	+	+	-	+	+	99
HEMATOPOIETIC SYSTEM																										
BONE MARROW	+	+	+	+	+	+	+	+	+	+	+	+	+	+	+	+	+	+	+	+	+	+	-	+	+	98
SPLEEN	+	+	+	+	+	+	+	+	+	+	+	+	+	+	+	+	+	+	+	+	+	+	-	+	+	99
LYMPH NODES	+	+	+	+	+	+	+	+	+	+	+	+	+	+	+	+	+	+	+	+	+	+	+	+	+	100
C-CELL CARCINOMA, METASTATIC																										1
THYMUS	+	-	+	+	+	+	-	+	+	+	+	-	+	+	+	-	+	-	+	+	+	+	-	+	+	87
CIRCULATORY SYSTEM																										
HEART	+	+	+	+	+	+	+	+	+	+	+	+	+	+	+	+	+	+	+	+	+	+	-	+	+	99
DIGESTIVE SYSTEM																										
ORAL CAVITY	N	N	N	N	N	N	N	N	N	N	N	N	N	N	N	N	N	N	N	N	N	N	N	N	N	100M
SQUAMOUS CELL PAPILLOMA																										1
SALIVARY GLAND	+	+	+	+	+	+	+	-	+	+	+	+	+	+	+	+	+	+	+	+	+	+	-	+	+	98
LIVER	+	+	+	+	+	+	+	+	+	+	+	+	+	+	+	+	+	+	+	+	+	+	+	+	+	100
NEOPLASTIC NODULE						X					X															5
HEPATOCELLULAR CARCINOMA																										1
MONOCYTIC LEUKEMIA																							X			1
BILE DUCT	+	+	+	+	+	+	+	+	+	+	+	+	+	+	+	+	+	+	+	+	+	+	+	+	+	100
GALLBLADDER & COMMON BILE DUCT	N	N	N	N	N	N	N	N	N	N	N	N	N	N	N	N	N	N	N	N	N	N	N	N	N	100M
PANCREAS	+	+	+	+	+	+	+	+	+	+	+	+	+	+	+	+	+	+	+	+	+	+	-	+	+	99
ACINAR-CELL ADENOMA						X														X						9
MESOTHELIOMA, METASTATIC																										1
ESOPHAGUS	+	+	+	+	+	+	+	+	+	+	+	+	+	+	+	+	+	+	+	+	+	+	-	+	+	98
FIBROSARCOMA																										1
STOMACH	+	+	+	+	+	+	+	+	+	+	+	+	+	+	+	+	+	+	+	+	+	+	+	+	+	100
MESOTHELIOMA, METASTATIC																										1
SMALL INTESTINE	+	+	+	+	+	+	+	+	+	+	+	+	+	+	+	+	+	+	+	+	+	+	+	+	+	100
LEIOMYOMA					X																					1
LEIOMYOSARCOMA																										1
LARGE INTESTINE	+	+	+	+	+	+	+	+	+	+	+	+	+	+	+	+	+	+	+	+	+	+	+	+	+	100
ADENOMATOUS POLYP, NOS																										2
LEIOMYOSARCOMA																										1
URINARY SYSTEM																										
KIDNEY	+	+	+	+	+	+	+	+	+	+	+	+	+	+	+	+	+	+	+	+	+	+	+	+	+	100
URINARY BLADDER	+	+	+	+	+	+	+	+	+	+	+	+	+	+	+	+	+	+	+	+	+	+	+	+	+	98

HWBUI0001693

TABLE B3. INDIVIDUAL ANIMAL TUMOR PATHOLOGY OF MALE RATS IN THE LIFETIME FEED STUDY OF INTERMEDIATE-RANGE CHRYSOTILE ASBESTOS: INTERMEDIATE-RANGE AND PREWEANING GAVAGE (Continued)

ANIMAL NUMBER	621	621	621	621	622	622	622	622	622	630	631	632	633	634	635	636	637	638	639	640	641	642	643	644	645	TOTAL
WEEKS ON STUDY	112	133	085	076	132	266	115	135	133	130	227	085	039	144	111	120	115	100	106	123	144	126	115	130	088	TISSUES TUMORS
ENDOCRINE SYSTEM																										
PITUITARY	+	+	+	+	+	+	+	+	+	+	+	+	+	+	+	+	+	+	+	+	+	+	+	+	+	100
CARCINOMA, NOS																										1
ADENOMA, NOS							X									X					X	X				18
ADRENAL	+	+	+	+	+	+	+	+	+	+	+	+	+	+	+	+	+	+	+	+	+	+	+	+	+	100
CORTICAL ADENOMA																										1
PHEOCHROMOCYTOMA		X				X			X	X				X	X						X		X		X	32
THYROID	+	+	+	+	+	+	+	+	+	+	+	+	+	+	+	+	+	+	+	+	+	+	–	+	+	99
FOLLICULAR-CELL ADENOMA																										3
FOLLICULAR-CELL CARCINOMA									X																	2
C-CELL ADENOMA														X				X								9
C-CELL CARCINOMA					X	X					X															23
PARATHYROID	+	+	+	+	+	+	+	+	+	+	+	+	+	+	–	+	+	–	+	+	+	+	–	+	+	93
PANCREATIC ISLETS	+	+	+	+	+	+	+	+	+	+	+	+	+	+	+	+	+	+	+	+	+	+	–	+	+	99
ISLET-CELL ADENOMA																										5
ISLET-CELL CARCINOMA																								X		6
REPRODUCTIVE SYSTEM																										
MAMMARY GLAND	+	+	+	+	+	M	+	+	+	+	+	+	N	+	+	+	+	+	+	+	+	+	+	+	+	100M
ADENOMA, NOS																										1
FIBROADENOMA																										7
TESTIS	+	+	+	+	+	+	+	+	+	+	+	+	+	+	+	+	+	+	+	+	+	+	+	+	+	100
INTERSTITIAL-CELL TUMOR	X	X	X		X	X	X	X	X	X	X			X	X	X	X	X	X	X	X		X	X	X	89
PROSTATE	+	+	+	+	+	+	+	+	+	+	+	+	+	+	+	+	+	+	+	+	+	+	+	+	+	99
SQUAMOUS CELL CARCINOMA											X															1
SEMINAL VESICLE	+	+	N	N	+	N	+	+	+	+	+	+	N	+	+	N	N	+	+	+	+	+	+	N	N	100M
SQUAMOUS CELL CARCINOMA, INVASIVE											X															1
PREPUTIAL/CLITORAL GLAND	N	N	N	N	N	N	N	N	N	N	N	N	N	N	N	N	N	N	N	N	N	N	N	N	N	100M
CARCINOMA, NOS		X																								3
NERVOUS SYSTEM																										
BRAIN	+	+	+	+	+	+	+	+	+	+	+	+	+	+	+	+	+	+	+	+	+	+	+	+	+	100
CARCINOMA, NOS, INVASIVE																										1
GRANULAR-CELL TUMOR, NOS																X										1
ASTROCYTOMA																									X	1
SPECIAL SENSE ORGANS																										
ZYMBAL GLAND	+	+	+	+	+	+	+	+	+	+	+	+	+	+	+	+	+	+	+	+	+	+	+	+	+	100M
SQUAMOUS CELL CARCINOMA				X																						3
MUSCULOSKELETAL SYSTEM																										
BONE	N	N	N	N	N	N	N	N	N	N	N	N	N	N	N	N	N	N	N	N	N	N	+	N	N	100M
SQUAMOUS CELL CARCINOMA																										2
SARCOMA, NOS																										1
MUSCLE	N	N	N	N	N	N	N	N	N	N	N	N	N	N	N	N	N	N	N	N	N	N	N	N	+	100M
RHABDOMYOSARCOMA																										1
BODY CAVITIES																										
PERITONEUM	N	N	N	N	N	N	N	N	N	N	N	N	N	N	N	N	N	N	N	N	N	N	N	N	N	100M
OSTEOSARCOMA																			X							1
CHONDROMA																										1
TUNICA VAGINALIS	+	+	+	+	+	+	+	+	+	+	+	+	+	+	+	+	+	+	+	+	+	+	+	+	+	100M
MESOTHELIOMA, NOS																										1
MESOTHELIOMA, MALIGNANT																										5
ALL OTHER SYSTEMS																										
MULTIPLE ORGANS NOS	N	N	N	N	N	N	N	N	N	N	N	N	N	N	N	N	N	N	N	N	N	N	N	N	N	100M
MESOTHELIOMA, METASTATIC																										4
OSTEOSARCOMA, METASTATIC																			X							3
MALIG.LYMPHOMA, HISTIOCYTIC TYPE																										3
MONOCYTIC LEUKEMIA					X	X				X	X			X	X	X	X	X		X				X		36
HEAD NOS																										
FIBROUS HISTIOCYTOMA, MALIGNANT																										1
ORBITAL REGION																										
OSTEOSARCOMA																										1
AXILLA NOS																										
FIBROMA																										1

M ANIMALS NECROPSIED

HWBUI0001694

TABLE B4. INDIVIDUAL ANIMAL TUMOR PATHOLOGY OF FEMALE RATS IN THE LIFETIME FEED STUDY OF INTERMEDIATE-RANGE CHRYSOTILE ASBESTOS: UNTREATED CONTROL

ANIMAL NUMBER	351801	351901	360101	360201	360301	360401	360501	360601	360701	360801	360901	361001	361101	361201	361301	361401	361501	361601	361701	361801	361901	362001	362101	362201	362301	362401	362501	362601
WEEKS ON STUDY	112	146	131	125	133	135	088	126	103	146	128	140	136	130	083	120	131	146	109	109	121	121	092	136				
INTEGUMENTARY SYSTEM																												
SKIN	+	+	+	+	+	+	+	+	+	+	+	+	+	+	+	+	+	+	+	+	+	+	+	+	+	+	+	+
SQUAMOUS CELL PAPILLOMA																												X
KERATOACANTHOMA															X													
SUBCUTANEOUS TISSUE	+	+	+	+	+	+	+	+	+	+	+	+	+	+	+	+	+	+	+	+	+	+	+	+	+	+	+	+
SQUAMOUS CELL CARCINOMA																												
SARCOMA, NOS																												
FIBROMA	X					X																						
FIBROSARCOMA																												
FIBROUS HISTIOCYTOMA, MALIGNANT							X																					
RESPIRATORY SYSTEM																												
LUNGS AND BRONCHI	+	+	+	+	+	+	+	+	+	+	+	+	+	+	+	+	+	+	+	+	+	+	+	+	+	+	+	+
ALVEOLAR/BRONCHIOLAR CARCINOMA																												
PHEOCHROMOCYTOMA, METASTATIC																												
SARCOMA, NOS, METASTATIC																												
FIBROUS HISTIOCYTOMA, METASTATIC																												
TRACHEA	+	+	+	+	+	+	+	+	+	+	+	+	+	+	+	+	+	+	+	+	+	+	+	+	+	+	+	+
HEMATOPOIETIC SYSTEM																												
BONE MARROW	+	+	+	+	+	+	+	+	+	+	+	+	+	+	+	+	+	+	+	+	+	+	+	+	+	+	+	+
SPLEEN	+	+	+	+	+	+	+	+	+	+	+	+	+	+	+	+	+	+	+	+	+	+	+	+	+	+	+	+
HEMANGIOSARCOMA								X																				
LYMPH NODES	+	+	+	+	+	+	+	+	+	+	+	+	+	+	+	+	+	+	+	+	+	+	+	+	+	+	+	+
THYMUS	+	+	+	+	-	+	+	+	-	+	+	-	+	+	+	+	+	+	+	+	+	+	+	+	+	+	+	+
CIRCULATORY SYSTEM																												
HEART	+	+	+	+	+	+	+	+	+	+	+	+	+	+	+	+	+	+	+	+	+	+	+	+	+	+	+	+
DIGESTIVE SYSTEM																												
ORAL CAVITY	N	N	N	N	N	N	N	N	N	N	N	N	N	N	N	N	N	N	N	N	N	N	N	N	N	N	N	N
SQUAMOUS CELL PAPILLOMA																												
SALIVARY GLAND	+	+	+	+	+	+	+	+	+	+	+	+	+	+	+	+	+	+	+	+	+	+	+	+	+	+	+	+
LIVER	+	+	+	+	+	+	+	+	+	+	+	+	+	+	+	+	+	+	+	+	+	+	+	+	+	+	+	+
SQUAMOUS CELL CARCINOMA, INVASIVE			X																									
NEOPLASTIC NODULE																												
HEPATOCELLULAR CARCINOMA																		X										
BILE DUCT	+	+	+	+	+	+	+	+	+	+	+	+	+	+	+	+	+	+	+	+	+	+	+	+	+	+	+	+
GALLBLADDER & COMMON BILE DUCT	N	N	N	N	N	N	N	N	N	N	N	N	N	N	N	N	N	N	N	N	N	N	N	N	N	N	N	N
PANCREAS	+	+	+	+	+	+	+	+	+	+	+	+	+	+	+	+	+	+	+	+	+	+	+	+	+	+	+	+
ACINAR-CELL ADENOMA																		X										
HEMANGIOSARCOMA																												
ESOPHAGUS	+	+	+	+	+	+	+	+	+	+	+	+	+	+	+	+	+	+	+	+	+	+	+	+	+	+	+	+
STOMACH	+	+	+	+	+	+	+	+	+	+	+	+	+	+	+	+	+	+	+	+	+	+	+	+	+	+	+	+
SQUAMOUS CELL CARCINOMA			X																									
SMALL INTESTINE	+	+	+	+	+	+	+	+	+	+	+	+	+	+	+	+	+	+	+	+	+	+	+	+	+	+	+	+
LEIOMYOMA																												
LARGE INTESTINE	+	+	+	+	+	+	+	+	+	+	+	+	+	+	+	+	+	+	+	+	+	+	+	+	+	+	+	+
URINARY SYSTEM																												
KIDNEY	+	+	+	+	+	+	+	+	+	+	+	+	+	+	+	+	+	+	+	+	+	+	+	+	+	+	+	+
TUBULAR-CELL ADENOCARCINOMA			X																									
LIPOMA																												
URINARY BLADDER	+	+	+	+	+	+	+	+	+	+	+	+	+	+	+	+	+	+	+	+	+	+	+	+	+	+	+	+

+: TISSUE EXAMINED MICROSCOPICALLY
-: REQUIRED TISSUE NOT EXAMINED MICROSCOPICALLY
X: TUMOR INCIDENCE
N: NECROPSY, NO AUTOLYSIS, NO MICROSCOPIC EXAMINATION
S: ANIMAL MIS-SEXED
: NO TISSUE INFORMATION SUBMITTED
C: NECROPSY, NO HISTOLOGY DUE TO PROTOCOL
A: AUTOLYSIS
M: ANIMAL MISSING
B: NO NECROPSY PERFORMED

HWBUI0001695

TABLE B4. INDIVIDUAL ANIMAL TUMOR PATHOLOGY OF FEMALE RATS IN THE LIFETIME FEED STUDY OF INTERMEDIATE-RANGE CHRYSOTILE ASBESTOS: UNTREATED CONTROL (Continued)

ANIMAL NUMBER	358	359	360	361	362	363	364	365	366	367	368	369	370	371	372	373	374	375	376	377	378	379	380	381	382
WEEKS ON STUDY	126	146	113	125	113	135	085	126	103	146	120	140	133	146	130	083	120	131	146	109	109	121	121	092	136
ENDOCRINE SYSTEM																									
PITUITARY	+	+	+	+	+	+	+	+	+	+	+	+	+	+	+	+	+	+	+	+	+	+	+	+	+
CARCINOMA, NOS																									
ADENOMA, NOS		X	X	X						X	X			X	X	X	X				X	X	X	X	
ADRENAL	+	+	+	+	+	+	+	+	+	+	+	+	+	+	+	+	+	+	+	+	+	+	+	+	+
CORTICAL ADENOMA	X																						X		
PHEOCHROMOCYTOMA		X										X													
PHEOCHROMOCYTOMA, MALIGNANT																									
THYROID	+	+	+	+	+	+	+	+	+	+	+	+	+	+	+	+	+	+	+	+	+	+	+	+	+
FOLLICULAR-CELL ADENOMA								X											X						
FOLLICULAR-CELL CARCINOMA																									
C-CELL ADENOMA		X											X	X					X				X		
C-CELL CARCINOMA		X			X	X					X									X		X			
PARATHYROID	+	+	+	−	+	−	+	+	−	−	−	+	+	+	+	−	−	+	+	+	+	+	−	+	+
PANCREATIC ISLETS	+	+	+	+	+	+	+	+	+	+	+	+	+	+	+	+	+	+	+	+	+	+	+	+	+
ISLET-CELL ADENOMA																									
ISLET-CELL CARCINOMA								X																	
REPRODUCTIVE SYSTEM																									
MAMMARY GLAND	+	+	+	+	+	+	+	+	+	+	+	+	+	+	+	+	+	+	+	+	+	+	+	+	+
CARCINOMA, NOS																									
ADENOMA, NOS													X		X								X		X
ADENOCARCINOMA, NOS												X													
FIBROADENOMA	X	X				X		X		X	X		X	X			X	X	X	X		X	X		
PREPUTIAL/CLITORAL GLAND	N	N	N	N	N	N	N	N	N	N	N	N	N	N	N	N	N	N	N	N	N	N	N	N	N
SQUAMOUS CELL CARCINOMA																									
UTERUS	+	+	+	+	+	+	+	+	+	+	+	+	+	+	+	+	+	+	+	+	+	+	+	+	+
LEIOMYOMA																									
ENDOMETRIAL STROMAL POLYP				X																					X
ENDOMETRIAL STROMAL SARCOMA																									
OVARY	+	+	+	+	+	+	+	+	+	+	+	+	+	+	+	+	+	+	+	+	+	+	+	+	+
THECOMA																									
GRANULOSA-CELL TUMOR																									
NERVOUS SYSTEM																									
BRAIN	+	+	+	+	+	+	+	+	+	+	+	+	+	+	+	+	+	+	+	+	+	+	+	+	+
CARCINOMA, NOS, INVASIVE																									
ASTROCYTOMA																			X						X
SPECIAL SENSE ORGANS																									
EYE APPENDAGES	N	N	N	N	N	N	N	N	N	N	N	N	N	N	N	N	N	N	N	N	N	N	N	N	N
SQUAMOUS CELL CARCINOMA						X																			
ZYMBAL GLAND	+	+	+	+	+	+	+	+	+	+	+	+	+	+	+	N	+	+	+	+	+	+	+	+	+
SQUAMOUS CELL CARCINOMA																					X				
MUSCULOSKELETAL SYSTEM																									
BONE	N	N	N	N	N	N	N	N	N	N	N	N	N	N	N	N	N	N	N	N	N	N	N	N	N
OSTEOSARCOMA																									
BODY CAVITIES																									
PERITONEUM	N	N	N	N	N	N	N	N	N	N	N	N	N	N	N	N	N	N	N	N	N	N	N	N	N
LEIOMYOSARCOMA																									
ALL OTHER SYSTEMS																									
MULTIPLE ORGANS NOS	N	N	N	N	N	N	N	N	N	N	N	N	N	N	N	N	N	N	N	N	N	N	N	N	N
C-CELL CARCINOMA, METASTATIC						X																			
OSTEOSARCOMA, METASTATIC																					X				
MONOCYTIC LEUKEMIA				X	X				X		X	X	X			X	X		X						
LEUKEMIA, MONONUCLEAR CELL																									
THORACOLUMBAR REGION																									
OSTEOSARCOMA																									
LOWER LEG NOS																									
OSTEOSARCOMA																					X				

HWBUI0001696

TABLE B4. INDIVIDUAL ANIMAL TUMOR PATHOLOGY OF FEMALE RATS IN THE LIFETIME FEED STUDY OF INTERMEDIATE-RANGE CHRYSOTILE ASBESTOS: UNTREATED CONTROL (Continued)

ANIMAL NUMBER	385	384	385	386	387	388	389	390	391	392	393	394	395	396	397	398	399	400	401	402	403	404	405	406	407
WEEKS ON STUDY	079	091	117	120	133	132	114	109	146	087	120	145	130	061	110	136	094	138	130	229	226	223	087	136	079
INTEGUMENTARY SYSTEM																									
SKIN	+	+	+	+	+	+	+	+	+	+	+	+	+	+	+	+	+	+	+	+	+	+	+	+	+
SQUAMOUS CELL PAPILLOMA																									
KERATOACANTHOMA																									
SUBCUTANEOUS TISSUE	+	+	+	+	+	+	+	+	+	+	+	+	+	+	+	+	+	+	+	+	+	+	+	+	+
SQUAMOUS CELL CARCINOMA			X																						
SARCOMA, NOS																									
FIBROMA									X			X													
FIBROSARCOMA																		X							
FIBROUS HISTIOCYTOMA, MALIGNANT																									
RESPIRATORY SYSTEM																									
LUNGS AND BRONCHI	+	+	+	+	+	+	+	+	+	+	+	+	+	+	+	+	+	+	+	+	+	+	+	+	+
ALVEOLAR/BRONCHIOLAR CARCINOMA																									
PHEOCHROMOCYTOMA, METASTATIC																									
SARCOMA, NOS, METASTATIC																									
FIBROUS HISTIOCYTOMA, METASTATIC																									
TRACHEA	+	+	+	+	+	+	+	+	+	+	+	+	+	+	+	+	+	+	+	+	+	+	+	+	+
HEMATOPOIETIC SYSTEM																									
BONE MARROW	+	+	+	+	+	+	+	+	+	+	+	+	+	+	+	+	+	+	+	+	+	+	+	+	+
SPLEEN	+	+	+	+	+	+	+	+	+	+	+	+	+	+	+	+	+	+	+	+	+	+	+	+	+
HEMANGIOSARCOMA																									
LYMPH NODES	+	+	+	+	+	+	+	+	+	+	+	+	+	+	+	+	+	+	+	+	+	+	+	+	+
THYMUS	-	+	-	-	+	+	+	+	+	+	+	+	-	-	+	+	-	+	-	+	+	+	+	+	+
CIRCULATORY SYSTEM																									
HEART	+	+	+	+	+	+	+	+	+	+	+	+	+	+	+	+	+	+	+	+	+	+	+	+	+
DIGESTIVE SYSTEM																									
ORAL CAVITY	M	M	M	M	M	M	M	M	M	M	M	M	M	M	M	M	M	M	M	M	M	M	M	M	M
SQUAMOUS CELL PAPILLOMA																X									
SALIVARY GLAND	+	+	+	+	+	+	+	+	+	+	+	+	+	+	+	+	+	+	+	+	+	+	+	+	+
LIVER	+	+	+	+	+	+	+	+	+	+	+	+	+	+	+	+	+	+	+	+	+	+	+	+	+
SQUAMOUS CELL CARCINOMA, INVASIVE																									
NEOPLASTIC NODULE							X						X												
HEPATOCELLULAR CARCINOMA																									
BILE DUCT	+	+	+	+	+	+	+	+	+	+	+	+	+	+	+	+	+	+	+	+	+	+	+	+	+
GALLBLADDER & COMMON BILE DUCT	M	M	M	M	M	M	M	M	M	M	M	M	M	M	M	M	M	M	M	M	M	M	M	M	M
PANCREAS	+	+	+	+	+	+	+	+	+	+	+	+	+	+	+	+	+	+	+	+	+	+	+	+	+
ACINAR-CELL ADENOMA									X																
HEMANGIOSARCOMA																									
ESOPHAGUS	-	+	+	+	+	+	+	+	+	+	+	+	+	+	+	+	+	+	+	+	+	+	+	+	+
STOMACH	+	+	+	+	+	+	+	+	+	+	+	+	+	+	+	+	+	+	+	+	+	+	+	+	+
SQUAMOUS CELL CARCINOMA																									
SMALL INTESTINE	+	+	+	+	+	+	+	+	+	+	+	+	+	+	+	+	+	+	+	+	+	+	+	+	+
LEIOMYOMA												X													
LARGE INTESTINE	+	+	+	+	+	+	+	+	+	+	+	+	+	+	+	+	+	+	+	+	+	+	+	+	+
URINARY SYSTEM																									
KIDNEY	+	+	+	+	+	+	+	+	+	+	+	+	+	+	+	+	+	+	+	+	+	+	+	+	+
TUBULAR-CELL ADENOCARCINOMA																									
LIPOMA											X														
URINARY BLADDER	+	+	+	+	+	+	+	+	+	+	+	+	+	+	+	+	+	+	+	+	+	+	+	+	+

HWBUI0001697

TABLE B4. INDIVIDUAL ANIMAL TUMOR PATHOLOGY OF FEMALE RATS IN THE LIFETIME FEED STUDY OF INTERMEDIATE-RANGE CHRYSOTILE ASBESTOS: UNTREATED CONTROL (Continued)

ANIMAL NUMBER	383	384	385	386	387	388	389	390	391	392	393	394	395	396	397	398	399	400	401	402	403	404	405	406	407
WEEKS ON STUDY	079	091	117	201	331	321	141	091	461	087	201	455	310	086	110	136	094	138	130	129	126	123	087	130	079
ENDOCRINE SYSTEM																									
PITUITARY	+	+	+	+	+	+	+	+	+	+	+	+	+	+	+	+	+	+	+	+	+	+	+	+	+
CARCINOMA, NOS																X									
ADENOMA, NOS		X		X	X	X	X	X			X	X	X	X	X			X	X	X					
ADRENAL	+	+	+	+	+	+	+	+	+	+	+	+	+	+	+	+	+	+	+	+	+	+	+	+	+
CORTICAL ADENOMA							X																		
PHEOCHROMOCYTOMA																					X				
PHEOCHROMOCYTOMA, MALIGNANT																									
THYROID	+	+	+	+	+	+	+	+	+	+	+	+	+	+	+	+	+	+	+	+	+	+	+	+	+
FOLLICULAR-CELL ADENOMA					X																				
FOLLICULAR-CELL CARCINOMA																		X							
C-CELL ADENOMA																									
C-CELL CARCINOMA	X				X																		X		
PARATHYROID	+	+	-	+	+	+	+	+	+	+	+	+	+	+	+	-	+	+	+	+	+	+	+	+	+
PANCREATIC ISLETS	+	+	+	+	+	+	+	+	+	+	+	+	+	+	+	+	+	+	+	+	+	+	+	+	+
ISLET-CELL ADENOMA																					X				
ISLET-CELL CARCINOMA											X									X					
REPRODUCTIVE SYSTEM																									
MAMMARY GLAND	+	+	+	+	+	+	+	+	+	+	+	+	+	+	+	+	+	+	+	+	+	+	+	+	+
CARCINOMA, NOS																									
ADENOMA, NOS																									
ADENOCARCINOMA, NOS										X															
FIBROADENOMA			X		X	X	X	X	X		X	X			X	X	X	X	X		X		X		
PREPUTIAL/CLITORAL GLAND	N	N	N	N	N	N	N	N	N	N	N	N	N	N	N	N	N	N	N	X	N	N	N	N	N
SQUAMOUS CELL CARCINOMA																									
UTERUS	+	+	+	+	+	+	+	+	+	+	+	+	+	+	+	+	+	+	+	+	+	+	+	+	+
LEIOMYOMA																									
ENDOMETRIAL STROMAL POLYP				X					X									X		X		X		X	X
ENDOMETRIAL STROMAL SARCOMA																									
OVARY	+	+	+	+	+	+	+	+	+	+	+	+	+	+	+	+	+	+	+	+	+	+	+	+	+
THECOMA																									
GRANULOSA-CELL TUMOR																		X							
NERVOUS SYSTEM																									
BRAIN	+	+	+	+	+	+	+	+	+	+	+	+	+	+	+	+	+	+	+	+	+	+	+	+	+
CARCINOMA, NOS, INVASIVE																X									
ASTROCYTOMA																									
SPECIAL SENSE ORGANS																									
EYE APPENDAGES	N	N	N	N	N	N	N	N	N	N	N	N	N	N	N	N	N	N	N	N	N	N	N	N	N
SQUAMOUS CELL CARCINOMA																									
ZYMBAL GLAND	+	+	+	+	+	+	+	+	+	+	+	+	+	+	+	+	+	+	+	+	+	+	+	+	+
SQUAMOUS CELL CARCINOMA																									
MUSCULOSKELETAL SYSTEM																									
BONE	N	N	N	N	N	N	N	N	N	N	N	N	N	N	N	N	N	N	N	N	N	N	N	N	N
OSTEOSARCOMA						X																			
BODY CAVITIES																									
PERITONEUM	N	N	N	N	N	N	N	N	N	N	N	N	N	N	N	N	N	N	N	N	N	N	N	N	N
LEIOMYOSARCOMA									X																
ALL OTHER SYSTEMS																									
MULTIPLE ORGANS NOS	N	N	N	N	N	N	N	N	N	N	N	N	N	N	N	N	N	N	N	N	N	N	N	N	N
C-CELL CARCINOMA, METASTATIC																									
OSTEOSARCOMA, METASTATIC																									
MONOCYTIC LEUKEMIA					X	X	X					X	X						X		X			X	X
LEUKEMIA, MONONUCLEAR CELL																									
THORACOLUMBAR REGION																									
OSTEOSARCOMA	X																								
LOWER LEG NOS																									
OSTEOSARCOMA																									

HWBUI0001698

TABLE B4. INDIVIDUAL ANIMAL TUMOR PATHOLOGY OF FEMALE RATS IN THE LIFETIME FEED STUDY OF INTERMEDIATE-RANGE CHRYSOTILE ASBESTOS: UNTREATED CONTROL (Continued)

ANIMAL NUMBER	40808	40909	41011	41112	41213	41316	41415	41516	41617	41718	41819	41919	42020	42121	42222	42323	42424	42525	42626	42727	42828	42929	43030	43131	43232
WEEKS ON STUDY	123	146	146	235	241	277	336	456	088	089	446	093	107	131	220	215	110	127	135	228	220	144	209	231	232
INTEGUMENTARY SYSTEM																									
SKIN	+	+	+	+	+	+	+	+	+	+	+	+	+	+	+	+	+	+	+	+	+	+	+	+	+
SQUAMOUS CELL PAPILLOMA													X												
KERATOACANTHOMA																									
SUBCUTANEOUS TISSUE	+	+	+	+	+	+	+	+	+	+	+	+	+	+	+	+	+	+	+	+	+	+	+	+	+
SQUAMOUS CELL CARCINOMA																									
SARCOMA, NOS																				X					
FIBROMA																								X	
FIBROSARCOMA																									
FIBROUS HISTIOCYTOMA, MALIGNANT											X														
RESPIRATORY SYSTEM																									
LUNGS AND BRONCHI	+	+	+	+	+	+	+	+	+	+	+	+	+	+	+	+	+	+	+	+	+	+	+	+	+
ALVEOLAR/BRONCHIOLAR CARCINOMA																						X			
PHEOCHROMOCYTOMA, METASTATIC															X					X					
SARCOMA, NOS, METASTATIC																				X					
FIBROUS HISTIOCYTOMA, METASTATIC											X														
TRACHEA	+	+	+	+	+	+	+	+	+	+	+	+	+	+	+	+	+	+	+	+	+	+	+	+	+
HEMATOPOIETIC SYSTEM																									
BONE MARROW	+	+	+	+	+	+	+	+	+	+	+	+	+	+	+	+	+	+	+	+	+	+	+	+	+
SPLEEN	+	+	+	+	+	+	+	+	+	+	+	+	+	+	+	+	+	+	+	+	+	+	+	+	+
HEMANGIOSARCOMA																									
LYMPH NODES	+	+	+	+	+	+	+	+	+	+	+	+	+	+	+	+	+	+	+	+	+	+	+	+	+
THYMUS	+	+	+	+	-	+	+	+	-	-	+	+	+	-	+	+	-	+	+	+	+	-	+	+	+
CIRCULATORY SYSTEM																									
HEART	+	+	+	+	+	+	+	+	+	+	+	+	+	+	+	+	+	+	+	+	+	+	+	+	+
DIGESTIVE SYSTEM																									
ORAL CAVITY	N	N	N	N	N	N	N	N	N	N	N	N	N	N	N	N	N	N	N	N	N	N	N	N	N
SQUAMOUS CELL PAPILLOMA																									
SALIVARY GLAND	+	+	+	+	+	+	+	+	+	+	+	+	+	+	+	+	+	+	+	+	+	+	+	+	+
LIVER	+	+	+	+	+	+	+	+	+	+	+	+	+	+	+	+	+	+	+	+	+	+	+	+	+
SQUAMOUS CELL CARCINOMA, INVASIVE																									
NEOPLASTIC NODULE																						X			
HEPATOCELLULAR CARCINOMA																									
BILE DUCT	+	+	+	+	+	+	+	+	+	+	+	+	+	+	+	+	+	+	+	+	+	+	+	+	+
GALLBLADDER & COMMON BILE DUCT	N	N	N	N	N	N	N	N	N	N	N	N	N	N	N	N	N	N	N	N	N	N	N	N	N
PANCREAS	+	+	+	+	+	+	+	+	+	+	+	+	+	+	+	+	+	+	+	+	+	+	+	+	+
ACINAR-CELL ADENOMA																									
HEMANGIOSARCOMA																									X
ESOPHAGUS	+	+	+	+	+	+	+	+	+	+	+	+	+	+	+	+	+	+	+	+	+	+	+	+	+
STOMACH	+	+	+	+	+	+	+	+	+	+	+	+	+	+	+	+	+	+	+	+	+	+	+	+	+
SQUAMOUS CELL CARCINOMA																									
SMALL INTESTINE	+	+	+	+	+	+	+	+	+	+	+	+	+	+	+	+	+	+	+	+	+	+	+	+	+
LEIOMYOMA																									
LARGE INTESTINE	+	+	+	+	+	+	+	+	+	+	+	+	+	+	+	+	+	+	+	+	+	+	+	+	+
URINARY SYSTEM																									
KIDNEY	+	+	+	+	+	+	+	+	+	+	+	+	+	+	+	+	+	+	+	+	+	+	+	+	+
TUBULAR-CELL ADENOCARCINOMA																									
LIPOMA																									
URINARY BLADDER	+	+	-	+	+	+	+	+	+	+	+	+	-	+	+	+	+	+	+	+	+	+	+	+	+

HWBUI0001699

TABLE B4. INDIVIDUAL ANIMAL TUMOR PATHOLOGY OF FEMALE RATS IN THE LIFETIME FEED STUDY OF INTERMEDIATE-RANGE CHRYSOTILE ASBESTOS: UNTREATED CONTROL (Continued)

ANIMAL NUMBER	408	409	410	411	412	413	414	415	416	417	418	419	420	421	422	423	424	425	426	427	428	429	430	431	432
WEEKS ON STUDY	125	146	146	123	141	127	136	146	108	109	146	131	107	131	120	115	110	127	135	128	120	141	129	131	132
ENDOCRINE SYSTEM																									
PITUITARY	+	+	+	+	+	+	+	+	+	+	+	+	+	+	+	+	+	+	+	+	+	+	+	+	+
CARCINOMA, NOS																			X						
ADENOMA, NOS	X	X	X	X	X			X			X		X		X	X	X	X		X	X		X		
ADRENAL	+	+	+	+	+	+	+	+	+	+	+	+	+	+	+	+	+	+	+	+	+	+	+	+	+
CORTICAL ADENOMA																									
PHEOCHROMOCYTOMA		X			X						X					X			X						
PHEOCHROMOCYTOMA, MALIGNANT															X					X					
THYROID	+	+	+	+	+	+	+	+	+	+	+	+	+	+	+	+	+	+	+	+	+	+	+	+	+
FOLLICULAR-CELL ADENOMA		X									X													X	
FOLLICULAR-CELL CARCINOMA																									
C-CELL ADENOMA									X		X														X
C-CELL CARCINOMA		X																							
PARATHYROID	+	+	+	+	+	+	+	+	+	+	–	+	+	+	+	+	+	+	+	+	+	+	–	+	+
PANCREATIC ISLETS	+	+	+	+	+	+	+	+	+	+	+	+	+	+	+	+	+	+	+	+	+	+	+	+	+
ISLET-CELL ADENOMA																							X		
ISLET-CELL CARCINOMA																									
REPRODUCTIVE SYSTEM																									
MAMMARY GLAND	+	+	+	+	+	+	+	+	+	+	+	+	+	+	+	+	+	+	+	+	+	+	+	+	+
CARCINOMA, NOS					X			X																	
ADENOMA, NOS																									
ADENOCARCINOMA, NOS	X			X										X											
FIBROADENOMA		X	X			X	X	X			X			X	X		X	X		X	X	X	X	X	
PREPUTIAL/CLITORAL GLAND	N	N	N	N	N	N	N	N	N	N	N	N	N	N	N	N	N	N	N	N	N	N	N	N	N
SQUAMOUS CELL CARCINOMA																									
UTERUS	+	+	+	+	+	+	+	+	+	+	+	+	+	+	+	+	+	+	+	+	+	+	+	+	+
LEIOMYOMA						X		X																	
ENDOMETRIAL STROMAL POLYP							X		X																
ENDOMETRIAL STROMAL SARCOMA			X																						
OVARY	+	+	+	+	+	+	+	+	+	+	+	+	+	+	+	+	+	+	+	+	+	+	+	+	+
THECOMA																									
GRANULOSA-CELL TUMOR																									
NERVOUS SYSTEM																									
BRAIN	+	+	+	+	+	+	+	+	+	+	+	+	+	+	+	+	+	+	+	+	+	+	+	+	+
CARCINOMA, NOS, INVASIVE																			X						
ASTROCYTOMA																									
SPECIAL SENSE ORGANS																									
EYE APPENDAGES	N	N	N	N	N	N	N	N	N	N	N	N	N	N	N	N	N	N	N	N	N	N	N	N	N
SQUAMOUS CELL CARCINOMA																									
ZYMBAL GLAND	+	+	+	+	+	+	+	+	+	+	+	+	+	+	+	+	+	+	+	N	+	+	+	+	+
SQUAMOUS CELL CARCINOMA																									
MUSCULOSKELETAL SYSTEM																									
BONE	N	N	N	N	N	N	N	N	N	N	N	N	N	N	N	N	N	N	N	N	N	N	N	N	N
OSTEOSARCOMA																									
BODY CAVITIES																									
PERITONEUM	N	N	N	N	N	N	N	N	N	N	N	N	N	N	N	N	N	N	N	N	N	N	N	N	N
LEIOMYOSARCOMA																									
ALL OTHER SYSTEMS																									
MULTIPLE ORGANS NOS	N	N	N	N	N	N	N	N	N	N	N	N	N	N	N	N	N	N	N	N	N	N	N	N	N
C-CELL CARCINOMA, METASTATIC																									
OSTEOSARCOMA, METASTATIC																									
MONOCYTIC LEUKEMIA				X	X		X				X	X		X		X		X						X	X
LEUKEMIA, MONONUCLEAR CELL																									
THORACOLUMBAR REGION																									
OSTEOSARCOMA																									
LOWER LEG NOS																									
OSTEOSARCOMA																									

HWBUI0001700

TABLE B4. INDIVIDUAL ANIMAL TUMOR PATHOLOGY OF FEMALE RATS IN THE LIFETIME FEED STUDY OF INTERMEDIATE-RANGE CHRYSOTILE ASBESTOS: UNTREATED CONTROL (Continued)

ANIMAL NUMBER	43301	43402	43503	43604	43705	43806	43907	44008	44109	44210	44311	44412	44513	TOTAL TISSUES TUMORS
WEEKS ON STUDY	10 1	14 6	12 3	11 7	13 9	11 4	09 0	09 9	11 4	12 5	10 8	12 1	10 4	
INTEGUMENTARY SYSTEM														
SKIN	N	+	+	+	+	+	+	+	+	+	+	+	+	88
SQUAMOUS CELL PAPILLOMA					X									3
KERATOACANTHOMA														1
SUBCUTANEOUS TISSUE	N	+	+	+	+	+	+	+	+	+	+	+	+	88
SQUAMOUS CELL CARCINOMA														1
SARCOMA, NOS														1
FIBROMA														5
FIBROSARCOMA														1
FIBROUS HISTIOCYTOMA, MALIGNANT														2
RESPIRATORY SYSTEM														
LUNGS AND BRONCHI	C	+	+	+	+	+	+	+	+	+	+	+	+	87
ALVEOLAR/BRONCHIOLAR CARCINOMA														1
PHEOCHROMOCYTOMA, METASTATIC														2
SARCOMA, NOS, METASTATIC														1
FIBROUS HISTIOCYTOMA, METASTATIC														1
TRACHEA	C	+	+	+	+	+	+	+	+	+	+	+	+	87
HEMATOPOIETIC SYSTEM														
BONE MARROW	C	+	+	+	+	+	+	+	+	+	+	+	+	87
SPLEEN	C	+	+	+	+	+	+	+	+	+	+	+	+	87
HEMANGIOSARCOMA														1
LYMPH NODES	C	+	+	+	+	+	+	+	+	+	+	+	+	87
THYMUS	C	+	+	-	+	+	+	+	+	+	+	+	+	70
CIRCULATORY SYSTEM														
HEART	C	+	+	+	+	+	+	+	+	+	+	+	+	87
DIGESTIVE SYSTEM														
ORAL CAVITY	N	N	N	N	N	N	N	N	N	N	N	N	N	88
SQUAMOUS CELL PAPILLOMA														1
SALIVARY GLAND	C	+	+	+	+	+	+	+	+	+	+	+	+	87
LIVER	C	+	+	+	+	+	+	+	+	+	+	+	+	87
SQUAMOUS CELL CARCINOMA, INVASIVE														1
NEOPLASTIC NODULE														3
HEPATOCELLULAR CARCINOMA														1
BILE DUCT	C	+	+	+	+	+	+	+	+	+	+	+	+	87
GALLBLADDER & COMMON BILE DUCT	N	N	N	N	N	N	N	N	N	N	N	N	N	88
PANCREAS	C	+	+	+	+	+	+	+	+	+	+	+	+	87
ACINAR-CELL ADENOMA														2
HEMANGIOSARCOMA														1
ESOPHAGUS	C	+	+	+	+	+	+	+	+	+	+	+	+	86
STOMACH	C	+	+	+	+	+	+	+	+	+	+	+	+	87
SQUAMOUS CELL CARCINOMA														1
SMALL INTESTINE	C	+	+	+	+	+	+	+	+	+	+	+	+	87
LEIOMYOMA														1
LARGE INTESTINE	C	+	+	+	+	+	+	+	+	+	+	+	+	87
URINARY SYSTEM														
KIDNEY	C	+	+	+	+	+	+	+	+	+	+	+	+	87
TUBULAR-CELL ADENOCARCINOMA														1
LIPOMA														1
URINARY BLADDER	C	+	+	+	+	+	+	+	+	+	+	+	+	85

HWBUI0001701

TABLE B4. INDIVIDUAL ANIMAL TUMOR PATHOLOGY OF FEMALE RATS IN THE LIFETIME FEED STUDY OF INTERMEDIATE-RANGE CHRYSOTILE ASBESTOS: UNTREATED CONTROL (Continued)

ANIMAL NUMBER	43334	43335	43336	43337	43338	43339	44340	44341	44342	44343	44344	44345	TOTAL TISSUES TUMORS
WEEKS ON STUDY	101	146	213	117	139	114	089	099	114	125	081	104	
ENDOCRINE SYSTEM													
PITUITARY	C +	+	+	+	+	+	+	+	+	+	+	+	87
CARCINOMA, NOS										X		X	6
ADENOMA, NOS		X		X	X	X	X		X		X		49
ADRENAL	C +	+	+	+	+	+	+	+	+	+	+	+	87
CORTICAL ADENOMA		X											4
PHEOCHROMOCYTOMA													8
PHEOCHROMOCYTOMA, MALIGNANT													2
THYROID	C +	+	+	+	+	+	+	+	+	+	+	+	87
FOLLICULAR-CELL ADENOMA													6
FOLLICULAR-CELL CARCINOMA													1
C-CELL ADENOMA		X			X		X						11
C-CELL CARCINOMA						X							11
PARATHYROID	C +	-	+	+	+	-	+	+	+	+	+	+	73
PANCREATIC ISLETS	C +	+	+	+	+	+	+	+	+	+	+	+	87
ISLET-CELL ADENOMA									X				2
ISLET-CELL CARCINOMA													4
REPRODUCTIVE SYSTEM													
MAMMARY GLAND	N +	+	+	+	+	+	+	+	+	+	+	+	88M
CARCINOMA, NOS													1
ADENOMA, NOS										X			6
ADENOCARCINOMA, NOS													5
FIBROADENOMA		X	X		X						X	X	49
PREPUTIAL/CLITORAL GLAND	N N	N	N	N	N	N	N	N	N	N	N	N	88M
SQUAMOUS CELL CARCINOMA													1
UTERUS	C +	+	+	+	+	+	+	+	+	+	+	+	87
LEIOMYOMA													2
ENDOMETRIAL STROMAL POLYP					X	X			X				14
ENDOMETRIAL STROMAL SARCOMA													1
OVARY	C +	+	+	+	+	+	+	+	+	+	+	+	87
THECOMA						X							1
GRANULOSA-CELL TUMOR													1
NERVOUS SYSTEM													
BRAIN	C +	+	+	+	+	+	+	+	+	+	+	+	87
CARCINOMA, NOS, INVASIVE										X		X	4
ASTROCYTOMA													2
SPECIAL SENSE ORGANS													
EYE APPENDAGES	N N	N	N	N	N	N	N	N	N	N	N	N	88M
SQUAMOUS CELL CARCINOMA													1
ZYMBAL GLAND	N +	+	+	+	+	+	+	+	+	+	+	+	88M
SQUAMOUS CELL CARCINOMA													1
MUSCULOSKELETAL SYSTEM													
BONE	N N	N	N	N	N	N	N	N	N	N	N	N	88M
OSTEOSARCOMA													1
BODY CAVITIES													
PERITONEUM	N N	N	N	N	N	N	N	N	N	N	N	N	88M
LEIOMYOSARCOMA													1
ALL OTHER SYSTEMS													
MULTIPLE ORGANS NOS	N N	N	N	N	N	N	N	N	N	N	N	N	88M
C-CELL CARCINOMA, METASTATIC													1
OSTEOSARCOMA, METASTATIC													1
MONOCYTIC LEUKEMIA		X		X	X			X					33
LEUKEMIA, MONONUCLEAR CELL									X				1
THORACOLUMBAR REGION													
OSTEOSARCOMA													1
LOWER LEG NOS													
OSTEOSARCOMA													1

M ANIMALS NECROPSIED

HWBUI0001702

TABLE B4. INDIVIDUAL ANIMAL TUMOR PATHOLOGY OF FEMALE RATS IN THE LIFETIME FEED STUDY OF INTERMEDIATE-RANGE CHRYSOTILE ASBESTOS: 1,2-DIMETHYLHYDRAZINE DIHYDROCHLORIDE

ANIMAL NUMBER	51	57	37	57	57	57	57	57	57	58	58	58	58	58	58	58	58	58	59	59	59	59	59	59
	1	2	3	4	5	6	7	8	9	0	1	2	3	4	5	6	7	8	9	0	1	2	3	4	5
WEEKS ON STUDY	08	11	08	10	11	11	08	07	11	09	13	08	08	11	10	07	06	09	09	11	08	09	16	09	09
	51	61	61	01	11	61	61	71	11	01	31	01	86	66	51	41	66	51	11	81	11	01	61	11	01
INTEGUMENTARY SYSTEM																									
SKIN	+	+	+	+	+	+	N	+	+	+	+	+	+	+	+	+	N	+	+	+	+	+	+	+	+
BASAL-CELL TUMOR																									
SUBCUTANEOUS TISSUE	+	+	+	+	+	+	N	+	+	+	+	+	+	+	+	+	N	+	+	+	+	+	+	+	+
FIBROMA											X														
FIBROSARCOMA																									
RESPIRATORY SYSTEM																									
LUNGS AND BRONCHI	+	+	+	+	+	+	+	+	+	+	+	+	+	+	+	+	+	+	+	+	+	+	+	+	+
ALVEOLAR/BRONCHIOLAR ADENOMA																									
TRACHEA	+	+	+	+	+	+	+	+	+	+	+	+	+	+	+	+	+	+	+	+	+	+	+	+	+
HEMATOPOIETIC SYSTEM																									
BONE MARROW	+	+	+	+	+	+	+	+	+	+	+	+	+	+	+	+	+	+	+	+	+	+	+	+	+
SPLEEN	+	+	+	+	+	+	+	+	+	+	+	+	+	+	+	+	+	+	+	+	+	+	+	+	+
LYMPH NODES	+	+	+	+	+	+	+	+	+	+	+	+	+	+	+	+	+	+	+	+	+	+	+	+	+
C-CELL CARCINOMA, METASTATIC																									
MUCINOUS CYSTADENOCA, METASTATIC																									
THYMUS	+	+	+	+	+	+	+	+	+	+	-	+	+	+	+	+	+	+	+	+	+	+	+	+	+
CIRCULATORY SYSTEM																									
HEART	+	+	+	+	+	+	+	+	+	+	+	+	+	+	+	+	+	+	+	+	+	+	+	+	+
DIGESTIVE SYSTEM																									
ORAL CAVITY	N	N	N	N	N	N	N	N	N	N	N	N	N	N	N	N	N	N	N	N	N	N	N	N	N
SQUAMOUS CELL PAPILLOMA																									
SQUAMOUS CELL CARCINOMA																									
SQUAMOUS CELL CARCINOMA, INVASIVE																									
SALIVARY GLAND	+	+	+	+	+	+	+	+	+	+	+	+	+	-	+	+	+	+	+	+	+	+	+	+	+
LIVER	+	+	+	+	+	+	+	+	+	+	+	+	+	+	+	+	+	+	+	+	+	+	+	+	+
NEOPLASTIC NODULE	X																								
HEPATOCELLULAR CARCINOMA								X													X	X	X		
BILE DUCT	+	+	+	+	+	+	+	+	+	+	+	+	+	+	+	+	+	+	+	+	+	+	+	+	+
GALLBLADDER & COMMON BILE DUCT	N	N	N	N	N	N	N	N	N	N	N	N	N	N	N	N	N	N	N	N	N	N	N	N	N
PANCREAS	+	+	+	+	+	+	+	+	+	+	+	+	+	+	+	+	+	+	+	+	+	+	+	+	+
ACINAR-CELL ADENOMA																									
ESOPHAGUS	+	+	+	+	+	+	+	+	+	+	+	+	+	+	+	+	+	+	+	+	+	+	+	+	+
STOMACH	+	+	+	+	+	+	+	+	+	+	+	+	+	+	+	+	+	+	+	+	+	+	+	+	+
SMALL INTESTINE	+	+	+	+	+	+	+	+	+	+	+	+	+	+	+	+	+	+	+	+	+	+	+	+	+
MUCINOUS CYSTADENOCARCINOMA											X														
LARGE INTESTINE	+	+	+	+	+	+	+	+	+	+	+	+	+	+	+	+	+	+	+	+	+	+	+	+	+
ADENOCARCINOMA, NOS								X																	
ADENOMATOUS POLYP, NOS		Xa			X	X												X							X
ADENOCA IN ADENOMATOUS POLYP											X														
MUCINOUS CYSTADENOCARCINOMA		X																						X	
MUCINOUS CYSTADENOCA, METASTATIC																									
SIGNET RING CARCINOMA																									
LEIOMYOSARCOMA																									
URINARY SYSTEM																									
KIDNEY	+	+	+	+	+	+	+	+	+	+	+	+	+	+	+	+	+	+	+	+	+	+	+	+	+
MIXED TUMOR, MALIGNANT				X		X											X	X	X						
CARCINOSARCOMA																									
URINARY BLADDER	+	+	+	+	+	+	+	+	+	+	+	+	+	+	+	+	+	+	+	+	+	+	+	+	+

a: MULTIPLE OCCURENCE OF MORPHOLOGY

HWBUI0001703

TABLE B4. INDIVIDUAL ANIMAL TUMOR PATHOLOGY OF FEMALE RATS IN THE LIFETIME FEED STUDY OF INTERMEDIATE-RANGE CHRYSOTILE ASBESTOS: 1,2-DIMETHYLHYDRAZINE DIHYDROCHLORIDE (Continued)

ANIMAL NUMBER	57131	57232	57333	57434	57535	57636	57737	57838	57939	58040	58141	58242	58343	58444	58545	58646	58747	58848	58949	59050	59151	59252	59353	59454	59555
WEEKS ON STUDY	085	116	086	110	111	116	084	071	111	090	130	080	086	116	115	104	064	095	091	080	111	090	116	091	090
ENDOCRINE SYSTEM																									
PITUITARY	+	+	+	+	+	+	+	+	+	+	+	+	+	+	+	+	+	+	+	+	+	+	+	+	+
CARCINOMA, NOS																									
ADENOMA, NOS				X					X						X			X		X		X			
ADRENAL	+	+	+	+	+	+	+	+	+	+	+	+	+	+	+	+	+	+	+	+	+	+	+	+	+
CORTICAL ADENOMA																									
PHEOCHROMOCYTOMA																							X		
PHEOCHROMOCYTOMA, MALIGNANT																									
THYROID	+	+	+	+	+	+	+	+	+	+	+	+	+	+	+	+	+	+	+	+	+	+	+	+	+
FOLLICULAR-CELL ADENOMA																									X
FOLLICULAR-CELL CARCINOMA																	X								
C-CELL ADENOMA		X			X																				
C-CELL CARCINOMA																									
PARATHYROID	+	+	+	+	+	+	+	–	+	+	+	+	+	+	+	+	+	+	+	+	+	+	+	+	+
PANCREATIC ISLETS	+	+	+	+	+	+	+	+	+	+	+	+	+	+	+	+	+	+	+	+	+	+	+	+	+
ISLET-CELL ADENOMA																									
ISLET-CELL CARCINOMA																									
REPRODUCTIVE SYSTEM																									
MAMMARY GLAND	+	+	+	+	+	+	+	+	+	+	+	+	+	+	+	+	+	+	+	+	+	+	+	+	+
ADENOMA, NOS																									
FIBROADENOMA		X		X		X			X		X			X	X					X	X	X			
PREPUTIAL/CLITORAL GLAND	N	N	N	N	N	N	N	N	N	N	N	N	N	N	N	N	N	N	N	N	N	N	N	N	N
CARCINOMA, NOS			X		X																		X		
VAGINA	N	N	N	N	N	N	N	N	N	N	N	N	N	N	N	N	N	N	N	N	N	N	N	N	N
FIBROMA																									
UTERUS	+	+	+	+	+	+	+	+	+	+	+	+	+	+	+	+	+	+	+	+	+	+	+	+	+
ENDOMETRIAL STROMAL POLYP																							X		
ENDOMETRIAL STROMAL SARCOMA													X												
OVARY	+	+	+	+	+	+	+	+	+	+	+	+	+	+	+	+	+	+	+	+	+	+	+	+	+
NERVOUS SYSTEM																									
BRAIN	+	+	+	+	+	+	+	+	+	+	+	+	+	+	+	+	+	+	+	+	+	+	+	+	+
CARCINOMA, NOS, INVASIVE																									
SPECIAL SENSE ORGANS																									
ZYMBAL GLAND	+	+	+	+	+	+	+	N	+	+	+	+	+	+	+	+	+	+	+	+	+	+	+	+	+
SQUAMOUS CELL PAPILLOMA															X										
SQUAMOUS CELL CARCINOMA	X																								
ALL OTHER SYSTEMS																									
MULTIPLE ORGANS NOS	N	N	N	N	N	N	N	N	N	N	N	N	N	N	N	N	N	N	N	N	N	N	N	N	N
ADENOCARCINOMA, NOS, METASTATIC								X																	
MUCINOUS CYSTADENOCA, METASTATIC																									
SIGNET RING CARCINOMA, METASTATIC																									
SARCOMA, NOS																									
MIXED TUMOR, METASTATIC																									
CARCINOSARCOMA, METASTATIC																									
MONOCYTIC LEUKEMIA	X				X		X				X			X	X		X	X	X	X		X	X	X	X
LEUKEMIA, MONONUCLEAR CELL						X						X									X				

+: TISSUE EXAMINED MICROSCOPICALLY
–: REQUIRED TISSUE NOT EXAMINED MICROSCOPICALLY
X: TUMOR INCIDENCE
N: NECROPSY, NO AUTOLYSIS, NO MICROSCOPIC EXAMINATION
S: ANIMAL MIS-SEXED
: NO TISSUE INFORMATION SUBMITTED
C: NECROPSY, NO HISTOLOGY DUE TO PROTOCOL
A: AUTOLYSIS
M: ANIMAL MISSING
B: NO NECROPSY PERFORMED

HWBUI0001704

TABLE B4. INDIVIDUAL ANIMAL TUMOR PATHOLOGY OF FEMALE RATS IN THE LIFETIME FEED STUDY OF INTERMEDIATE-RANGE CHRYSOTILE ASBESTOS: 1,2-DIMETHYLHYDRAZINE DIHYDROCHLORIDE (Continued)

ANIMAL NUMBER	596	597	598	599	600	601	602	603	604	605	606	607	608	609	611	611	612	613	614	615	616	617	618	619	620
WEEKS ON STUDY	101	080	116	116	060	111	081	047	085	084	089	093	103	084	067	090	101	116	088	110	088	035	089	090	116
INTEGUMENTARY SYSTEM																									
SKIN	+	+	+	+	N	+	+	N	+	+	+	+	+	+	+	+	+	+	+	+	+	+	+	+	+
BASAL-CELL TUMOR																									
SUBCUTANEOUS TISSUE	+	+	+	+	N	+	+	N	+	+	+	+	+	+	+	+	+	+	+	+	+	+	+	+	+
FIBROMA																	X								
FIBROSARCOMA																									
RESPIRATORY SYSTEM																									
LUNGS AND BRONCHI	+	+	+	+	+	+	+	+	+	+	+	+	+	+	+	+	+	+	+	+	+	+	+	+	+
ALVEOLAR/BRONCHIOLAR ADENOMA																									
TRACHEA	+	+	+	+	+	+	+	+	+	+	+	+	+	+	+	+	+	+	+	+	+	+	+	+	+
HEMATOPOIETIC SYSTEM																									
BONE MARROW	+	+	+	+	+	+	+	+	+	+	+	+	+	+	+	+	+	+	+	+	+	+	+	+	+
SPLEEN	+	+	+	+	+	+	+	+	+	+	+	+	+	+	+	+	+	+	+	+	+	+	+	+	+
LYMPH NODES	+	+	+	+	+	+	+	+	+	+	+	+	+	+	+	+	+	+	+	+	+	+	+	+	+
C-CELL CARCINOMA, METASTATIC																									
MUCINOUS CYSTADENOCA, METASTATIC																									
THYMUS	+	+	-	+	-	-	+	+	+	+	-	-	-	+	+	+	-	-	-	+	+	-	+	+	+
CIRCULATORY SYSTEM																									
HEART	+	+	+	+	+	+	+	+	+	+	+	+	+	+	+	+	+	+	+	+	+	+	+	+	+
DIGESTIVE SYSTEM																									
ORAL CAVITY	N	N	N	N	N	N	N	N	N	N	N	N	N	N	N	N	N	N	N	N	N	N	N	N	N
SQUAMOUS CELL PAPILLOMA																									
SQUAMOUS CELL CARCINOMA																									
SQUAMOUS CELL CARCINOMA, INVASIVE																									
SALIVARY GLAND	+	+	+	+	+	+	+	+	+	+	+	+	+	+	+	+	+	+	+	+	+	+	+	+	+
LIVER	+	+	+	+	+	+	+	+	+	+	+	+	+	+	+	+	+	+	+	+	+	+	+	+	+
NEOPLASTIC NODULE									X																
HEPATOCELLULAR CARCINOMA																		X							X
BILE DUCT	+	+	+	+	+	+	+	+	+	+	+	+	+	+	+	+	+	+	+	+	+	+	+	+	+
GALLBLADDER & COMMON BILE DUCT	N	N	N	N	N	N	N	N	N	N	N	N	N	N	N	N	N	N	N	N	N	N	N	N	N
PANCREAS	+	+	+	+	+	+	+	+	+	+	+	+	+	+	+	+	+	+	+	+	+	+	+	+	+
ACINAR-CELL ADENOMA																									
ESOPHAGUS	+	+	+	+	+	+	+	+	+	+	-	+	+	+	+	+	+	+	+	+	+	+	+	+	+
STOMACH	+	+	+	+	+	+	+	+	+	+	+	+	+	+	+	+	+	+	+	+	+	+	+	+	+
SMALL INTESTINE	+	+	+	+	+	+	+	+	+	+	+	+	+	+	+	+	+	+	+	+	+	+	+	+	+
MUCINOUS CYSTADENOCARCINOMA																									
LARGE INTESTINE	+	+	+	+	+	+	+	+	+	+	+	+	+	+	+	+	+	+	+	+	+	+	+	+	+
ADENOCARCINOMA, NOS																									
ADENOMATOUS POLYP, NOS			X						X										X	X			X		X
ADENOCA IN ADENOMATOUS POLYP																									
MUCINOUS CYSTADENOCARCINOMA								X				X										X			
MUCINOUS CYSTADENOCA, METASTATIC																									
SIGNET RING CARCINOMA																									
LEIOMYOSARCOMA																									
URINARY SYSTEM																									
KIDNEY	+	+	+	+	+	+	+	+	+	+	+	+	+	+	+	+	+	+	+	+	+	+	+	+	+
MIXED TUMOR, MALIGNANT					X			X		X								X							
CARCINOSARCOMA															X										
URINARY BLADDER	+	+	+	+	+	+	+	+	+	+	+	+	+	+	+	+	+	+	+	+	+	+	+	+	+

HWBUI0001705

TABLE B4. INDIVIDUAL ANIMAL TUMOR PATHOLOGY OF FEMALE RATS IN THE LIFETIME FEED STUDY OF INTERMEDIATE-RANGE CHRYSOTILE ASBESTOS: 1,2-DIMETHYLHYDRAZINE DIHYDROCHLORIDE (Continued)

ANIMAL NUMBER	59 16	59 17	59 18	59 19	60 00	60 01	60 02	60 03	60 04	60 05	60 06	60 07	60 08	60 09	61 10	61 11	61 12	61 13	61 14	61 15	61 16	61 17	61 18	61 19	61 20
WEEKS ON STUDY	10 01	08 10	11 16	11 16	06 00	10 11	08 11	04 07	08 05	08 04	09 00	03 09	10 03	08 05	06 07	09 01	11 01	11 14	08 11	10 11	08 08	03 05	08 09	01 01	11 16
ENDOCRINE SYSTEM																									
PITUITARY	+	+	+	+	+	+	+	+	+	+	+	+	+	+	+	+	+	+	+	+	+	+	+	+	+
CARCINOMA, NOS																									
ADENOMA, NOS								X						X		X	X			X	X	X			X
ADRENAL	+	+	+	+	+	+	+	+	+	+	+	+	+	+	–	+	+	+	+	+	+	+	+	+	+
CORTICAL ADENOMA																									
PHEOCHROMOCYTOMA																		X							
PHEOCHROMOCYTOMA, MALIGNANT																									
THYROID	+	+	+	+	+	+	+	+	+	+	+	+	+	+	+	+	+	+	+	+	+	+	+	+	+
FOLLICULAR-CELL ADENOMA			X																	X					
FOLLICULAR-CELL CARCINOMA				X		X																			
C-CELL ADENOMA																									
C-CELL CARCINOMA																									
PARATHYROID	+	+	+	+	+	+	+	+	+	+	+	+	+	+	–	+	+	+	+	+	+	+	+	+	+
PANCREATIC ISLETS	+	+	+	+	+	+	+	+	+	+	+	+	+	+	+	+	+	+	+	+	+	+	+	+	+
ISLET-CELL ADENOMA																									
ISLET-CELL CARCINOMA																									
REPRODUCTIVE SYSTEM																									
MAMMARY GLAND	+	+	+	+	+	+	+	+	+	+	+	+	+	+	+	+	+	+	+	+	+	+	+	+	+
ADENOMA, NOS																									
FIBROADENOMA		X	X											X						X					
PREPUTIAL/CLITORAL GLAND	N	N	N	N	N	N	N	N	N	N	N	N	N	N	N	N	N	N	N	N	N	N	N	N	N
CARCINOMA, NOS																									
VAGINA	N	N	N	N	N	N	N	N	N	N	N	N	N	N	N	N	N	N	N	N	N	N	N	N	N
FIBROMA																									
UTERUS	+	+	+	+	+	+	+	+	+	+	+	+	+	+	+	+	+	+	+	+	+	+	+	+	+
ENDOMETRIAL STROMAL POLYP										X										X					
ENDOMETRIAL STROMAL SARCOMA							X																		
OVARY	+	+	+	+	+	+	+	+	+	+	+	+	+	+	+	+	+	+	+	+	+	+	+	+	+
NERVOUS SYSTEM																									
BRAIN	+	+	+	+	+	+	+	+	+	+	+	+	+	+	+	+	+	+	+	+	+	+	+	+	+
CARCINOMA, NOS, INVASIVE																									
SPECIAL SENSE ORGANS																									
ZYMBAL GLAND	+	+	+	+	+	+	+	+	+	+	+	+	+	+	N	+	+	+	+	+	+	+	+	+	+
SQUAMOUS CELL PAPILLOMA																									
SQUAMOUS CELL CARCINOMA	X																	X							
ALL OTHER SYSTEMS																									
MULTIPLE ORGANS NOS	N	N	N	N	N	N	N	N	N	N	N	N	N	N	N	N	N	N	N	N	N	N	N	N	N
ADENOCARCINOMA, NOS, METASTATIC																									
MUCINOUS CYSTADENOCA, METASTATIC								X				X										X			
SIGNET RING CARCINOMA, METASTATIC											X														
SARCOMA, NOS															X										
MIXED TUMOR, METASTATIC																									
CARCINOSARCOMA, METASTATIC																									
MONOCYTIC LEUKEMIA			X	X		X	X		X				X			X		X			X			X	
LEUKEMIA, MONONUCLEAR CELL																									

HWBUI0001706

TABLE B4. INDIVIDUAL ANIMAL TUMOR PATHOLOGY OF FEMALE RATS IN THE LIFETIME FEED STUDY OF INTERMEDIATE-RANGE CHRYSOTILE ASBESTOS: 1,2-DIMETHYLHYDRAZINE DIHYDROCHLORIDE (Continued)

ANIMAL NUMBER	62121	62122	62123	62124	62125	62126	62127	62128	62129	62130	62131	62132	62133	62134	62135	62136	62137	62138	62139	62140	62141	62142	62143	62144	62145
WEEKS ON STUDY	007	060	116	082	116	090	079	091	111	118	068	080	091	088	098	078	086	088	081	091	093	091	091	094	083
INTEGUMENTARY SYSTEM																									
SKIN	+	M	+	+	+	+	+	+	+	+	+	+	+	+	+	+	+	+	+	+	+	+	+	+	+
BASAL-CELL TUMOR																									
SUBCUTANEOUS TISSUE	+	M	+	+	+	+	+	+	+	+	+	+	+	+	+	+	+	+	+	+	+	+	+	+	+
FIBROMA																									
FIBROSARCOMA																									
RESPIRATORY SYSTEM																									
LUNGS AND BRONCHI	+	+	+	+	+	+	+	+	+	+	+	+	+	+	+	+	+	+	+	+	+	+	+	+	+
ALVEOLAR/BRONCHIOLAR ADENOMA									X																
TRACHEA	+	+	+	+	+	+	+	+	+	+	+	+	+	+	+	+	+	+	+	+	+	+	+	+	+
HEMATOPOIETIC SYSTEM																									
BONE MARROW	+	+	+	+	+	+	+	+	+	+	+	+	+	+	+	+	+	+	+	+	+	+	+	+	+
SPLEEN	+	+	+	+	+	+	+	+	+	+	+	+	+	+	+	+	+	+	+	+	+	+	+	+	+
LYMPH NODES	+	+	+	+	+	+	+	+	+	+	+	+	+	+	+	+	+	+	+	+	+	+	+	+	+
C-CELL CARCINOMA, METASTATIC																									
MUCINOUS CYSTADENOCA, METASTATIC									X							X									
THYMUS	+	+	+	+	+	+	+	+	-	+	+	+	+	+	+	+	+	+	+	+	-	+	+	+	+
CIRCULATORY SYSTEM																									
HEART	+	+	+	+	+	+	+	+	+	+	+	+	+	+	+	+	+	+	+	+	+	+	+	+	+
DIGESTIVE SYSTEM																									
ORAL CAVITY	M	M	M	M	M	M	M	M	M	M	M	M	M	M	M	M	M	M	M	M	M	M	M	M	M
SQUAMOUS CELL PAPILLOMA																									
SQUAMOUS CELL CARCINOMA								X																	
SQUAMOUS CELL CARCINOMA, INVASIVE										X															
SALIVARY GLAND	+	+	+	+	+	+	+	+	+	+	+	+	+	+	+	+	+	+	+	+	+	+	+	+	+
LIVER	+	+	+	+	+	+	+	+	+	+	+	+	+	+	+	+	+	+	+	+	+	+	+	+	+
NEOPLASTIC NODULE																		X							
HEPATOCELLULAR CARCINOMA																		X		X					
BILE DUCT	+	+	+	+	+	+	+	+	+	+	+	+	+	+	+	+	+	+	+	+	+	+	+	+	+
GALLBLADDER & COMMON BILE DUCT	M	M	M	M	M	M	M	M	M	M	M	M	M	M	M	M	M	M	M	M	M	M	M	M	M
PANCREAS	+	+	+	+	+	+	+	+	+	+	+	+	+	+	+	+	+	+	+	+	+	+	+	+	+
ACINAR-CELL ADENOMA																								X	
ESOPHAGUS	+	+	+	+	+	+	+	+	+	+	+	-	+	+	+	+	+	+	+	+	+	+	+	+	+
STOMACH	+	+	+	+	+	+	+	+	+	+	+	+	+	+	+	+	+	+	+	+	+	+	+	+	+
SMALL INTESTINE	+	+	+	+	+	+	+	+	+	+	+	+	+	+	+	+	+	+	+	+	+	+	+	+	+
MUCINOUS CYSTADENOCARCINOMA																									
LARGE INTESTINE	+	+	+	+	+	+	+	+	+	+	+	+	+	+	+	+	+	+	+	+	+	+	+	+	+
ADENOCARCINOMA, NOS																									
ADENOMATOUS POLYP, NOS				X					X						X		X	X	X	Xa			Xa		
ADENOCA IN ADENOMATOUS POLYP																									
MUCINOUS CYSTADENOCARCINOMA						X			X					X		X									
MUCINOUS CYSTADENOCA, METASTATIC																									
SIGNET RING CARCINOMA													X												X
LEIOMYOSARCOMA		X																							
URINARY SYSTEM																									
KIDNEY	+	+	+	+	+	+	+	+	+	+	+	+	+	+	+	+	+	+	+	+	+	+	+	+	+
MIXED TUMOR, MALIGNANT				X																					
CARCINOSARCOMA																									
URINARY BLADDER	+	+	+	+	+	+	+	+	+	+	+	+	+	+	+	+	+	+	+	+	+	+	+	+	+

a: MULTIPLE OCCURENCE OF MORPHOLOGY

HWBUI0001707

TABLE B4. INDIVIDUAL ANIMAL TUMOR PATHOLOGY OF FEMALE RATS IN THE LIFETIME FEED STUDY OF INTERMEDIATE-RANGE CHRYSOTILE ASBESTOS: 1,2-DIMETHYLHYDRAZINE DIHYDROCHLORIDE (Continued)

ANIMAL NUMBER	621	622	623	624	625	626	627	628	629	630	631	632	633	634	635	636	637	638	639	640	641	642	643	644	645
WEEKS ON STUDY	070	060	116	082	116	090	079	091	111	081	068	080	091	080	098	078	084	108	088	111	093	091	091	104	118
ENDOCRINE SYSTEM																									
PITUITARY	+	+	+	-	+	+	+	+	+	+	+	+	+	+	+	+	+	+	+	+	+	+	+	+	+
CARCINOMA, NOS																									
ADENOMA, NOS					X				X								X	X						
ADRENAL	+	+	+	+	+	+	+	+	+	+	+	+	+	+	+	+	+	+	+	+	+	+	+	+	+
CORTICAL ADENOMA																			X						
PHEOCHROMOCYTOMA						X																			
PHEOCHROMOCYTOMA, MALIGNANT																						X			
THYROID	+	+	+	+	+	+	+	+	+	+	+	+	+	+	+	+	+	+	+	+	+	+	+	+	+
FOLLICULAR-CELL ADENOMA			X																X		X				
FOLLICULAR-CELL CARCINOMA																	X								
C-CELL ADENOMA			X															X						X	
C-CELL CARCINOMA					X				X											X					
PARATHYROID	+	+	+	+	+	+	+	+	+	+	+	+	+	+	+	+	+	+	+	+	+	+	+	+	-
PANCREATIC ISLETS	+	+	+	+	+	+	+	+	+	+	+	+	+	+	+	+	+	+	+	+	+	+	+	+	+
ISLET-CELL ADENOMA				X																					
ISLET-CELL CARCINOMA																									
REPRODUCTIVE SYSTEM																									
MAMMARY GLAND	+	+	+	+	+	+	+	+	+	+	+	+	+	+	+	+	+	+	+	+	+	+	+	+	+
ADENOMA, NOS								X												X					
FIBROADENOMA			X		X		X		X						X			X		X				X	
PREPUTIAL/CLITORAL GLAND	N	N	N	N	N	N	N	N	N	N	N	N	N	N	N	N	N	N	N	N	N	N	N	N	N
CARCINOMA, NOS																					X				
VAGINA	N	N	N	N	N	N	N	N	N	N	N	N	N	N	N	N	N	N	N	N	N	N	N	N	N
FIBROMA																									
UTERUS	+	+	+	+	+	+	+	+	+	+	+	+	+	+	+	+	+	+	+	+	+	+	+	+	+
ENDOMETRIAL STROMAL POLYP																	X					X			
ENDOMETRIAL STROMAL SARCOMA																									
OVARY	+	+	+	+	+	+	+	+	+	+	+	+	+	+	+	+	+	+	+	+	+	+	+	+	+
NERVOUS SYSTEM																									
BRAIN	+	+	+	+	+	+	+	+	+	+	+	+	+	+	+	+	+	+	+	+	+	+	+	+	+
CARCINOMA, NOS, INVASIVE																									
SPECIAL SENSE ORGANS																									
ZYMBAL GLAND	+	+	+	N	+	+	+	+	+	+	+	N	+	+	+	+	+	+	+	+	+	+	+	+	+
SQUAMOUS CELL PAPILLOMA																									
SQUAMOUS CELL CARCINOMA										X					X		X	X	X	X					
ALL OTHER SYSTEMS																									
MULTIPLE ORGANS NOS	N	N	N	N	N	N	N	N	N	N	N	N	N	N	N	N	N	N	N	N	N	N	N	N	N
ADENOCARCINOMA, NOS, METASTATIC																									
MUCINOUS CYSTADENOCA, METASTATIC																									
SIGNET RING CARCINOMA, METASTATIC																									X
SARCOMA, NOS																									
MIXED TUMOR, METASTATIC																									
CARCINOSARCOMA, METASTATIC																									
MONOCYTIC LEUKEMIA		X		X	X	X			X		X	X	X		X		X		X		X		X	X	
LEUKEMIA, MONONUCLEAR CELL																				X					

HWBUI0001708

TABLE B4. INDIVIDUAL ANIMAL TUMOR PATHOLOGY OF FEMALE RATS IN THE LIFETIME FEED STUDY OF INTERMEDIATE-RANGE CHRYSOTILE ASBESTOS: 1,2-DIMETHYLHYDRAZINE DIHYDROCHLORIDE (Continued)

ANIMAL NUMBER	64 06	64 07	64 08	64 09	65 00	65 01	65 02	65 03	65 04	65 05	65 06	65 07	65 08	65 09	65 10	66 01	66 02	66 03	66 04	66 05	66 06	66 07	66 08	66 09	67 00
WEEKS ON STUDY	08 9	08 5	08 5	08 8	08 6	06 6	09 5	09 1	05 8	08 5	11 8	06 9	09 5	09 1	05 9	07 0	11 6	10 8	10 6	11 6	09 1	06 5	09 1	10 0	09 4
INTEGUMENTARY SYSTEM																									
SKIN	+	+	+	+	+	N	+	+	+	+	+	+	+	+	+	+	+	+	+	+	+	N	+	+	+
BASAL-CELL TUMOR																				X					
SUBCUTANEOUS TISSUE	+	+	+	+	+	N	+	+	+	+	+	+	+	+	+	+	+	+	+	+	+	N	+	+	+
FIBROMA																			X						
FIBROSARCOMA																									
RESPIRATORY SYSTEM																									
LUNGS AND BRONCHI	+	+	+	+	+	+	+	+	+	+	+	+	+	+	+	+	+	+	+	+	+	+	+	+	+
ALVEOLAR/BRONCHIOLAR ADENOMA																									
TRACHEA	+	+	+	+	+	+	+	+	+	+	+	+	+	+	+	+	+	+	+	+	+	+	+	+	+
HEMATOPOIETIC SYSTEM																									
BONE MARROW	+	+	+	+	+	+	+	+	+	+	+	+	+	+	+	+	+	+	+	+	+	+	+	+	+
SPLEEN	+	+	+	+	+	+	+	+	+	+	+	+	+	+	+	+	+	+	+	+	+	+	+	+	+
LYMPH NODES	+	+	+	+	+	+	+	+	+	+	+	+	+	+	+	+	+	+	+	+	+	+	+	+	+
C-CELL CARCINOMA, METASTATIC																									
MUCINOUS CYSTADENOCA, METASTATIC																X									
THYMUS	+	+	+	+	+	+	+	+	-	+	+	+	+	+	+	+	+	+	-	+	+	+	+	+	+
CIRCULATORY SYSTEM																									
HEART	+	+	+	+	+	+	+	+	+	+	+	+	+	+	+	+	+	+	+	+	+	+	+	+	+
DIGESTIVE SYSTEM																									
ORAL CAVITY	N	N	N	N	N	N	N	N	N	N	N	N	N	N	N	N	N	N	N	N	N	N	N	N	N
SQUAMOUS CELL PAPILLOMA																									
SQUAMOUS CELL CARCINOMA																							X		
SQUAMOUS CELL CARCINOMA, INVASIVE																									
SALIVARY GLAND	+	+	+	+	+	+	+	+	-	+	+	+	+	+	+	+	+	+	+	+	+	+	+	+	+
LIVER	+	+	+	+	+	+	+	+	+	+	+	+	+	+	+	+	+	+	+	+	+	+	+	+	+
NEOPLASTIC NODULE				X						X			X				X								
HEPATOCELLULAR CARCINOMA		X																							
BILE DUCT	+	+	+	+	+	+	+	+	+	+	+	+	+	+	+	+	+	+	+	+	+	+	+	+	+
GALLBLADDER & COMMON BILE DUCT	N	N	N	N	N	N	N	N	N	N	N	N	N	N	N	N	N	N	N	N	N	N	N	N	N
PANCREAS	+	+	+	+	+	+	+	+	+	+	+	+	+	+	+	+	+	+	+	+	+	+	+	+	+
ACINAR-CELL ADENOMA																									
ESOPHAGUS	+	+	+	+	+	+	+	+	-	+	+	+	+	+	+	+	+	+	+	+	+	+	+	+	+
STOMACH	+	+	+	+	+	+	+	+	+	+	+	+	+	+	+	+	+	+	+	+	+	+	+	+	+
SMALL INTESTINE	+	+	+	+	+	+	+	+	+	+	+	+	+	+	+	+	+	+	+	+	+	+	+	+	+
MUCINOUS CYSTADENOCARCINOMA														X											
LARGE INTESTINE	+	+	+	+	+	+	+	+	+	+	+	+	+	+	+	+	+	+	+	+	+	+	+	+	+
ADENOCARCINOMA, NOS																									
ADENOMATOUS POLYP, NOS							X						X				X						X		X
ADENOCA IN ADENOMATOUS POLYP												X													
MUCINOUS CYSTADENOCARCINOMA						X										X									
MUCINOUS CYSTADENOCA, METASTATIC																X									
SIGNET RING CARCINOMA																									
LEIOMYOSARCOMA																									
URINARY SYSTEM																									
KIDNEY	+	+	+	+	+	+	+	+	+	+	+	+	+	+	+	+	+	+	+	+	+	+	+	+	+
MIXED TUMOR, MALIGNANT									X							X									
CARCINOSARCOMA																									
URINARY BLADDER	+	+	+	+	+	+	+	+	+	+	+	+	+	+	+	+	+	+	+	+	+	+	+	+	+

HWBUI0001709

TABLE B4. INDIVIDUAL ANIMAL TUMOR PATHOLOGY OF FEMALE RATS IN THE LIFETIME FEED STUDY OF INTERMEDIATE-RANGE CHRYSOTILE ASBESTOS: 1,2-DIMETHYLHYDRAZINE DIHYDROCHLORIDE (Continued)

ANIMAL NUMBER	64 6	64 7	64 8	64 9	65 0	65 1	65 2	65 3	65 4	65 5	65 6	65 7	65 8	65 9	66 0	66 1	66 2	66 3	66 4	66 5	66 6	66 7	66 8	66 9	67 0
WEEKS ON STUDY	089	085	085	088	086	066	095	091	058	085	108	069	095	091	059	070	116	110	106	116	091	065	091	101	094
ENDOCRINE SYSTEM																									
PITUITARY	+	+	+	+	+	+	+	+	+	+	+	+	+	+	+	+	+	+	+	+	+	+	+	+	+
CARCINOMA, NOS																									
ADENOMA, NOS	X		X					X			X							X		X			X	
ADRENAL	+	+	+	+	+	+	+	+	+	+	+	+	+	+	+	+	+	+	+	+	+	+	+	+	+
CORTICAL ADENOMA																									
PHEOCHROMOCYTOMA											X														
PHEOCHROMOCYTOMA, MALIGNANT																									X
THYROID	+	+	+	+	+	+	+	+	−	+	+	+	+	+	+	+	+	+	+	+	+	+	+	+	+
FOLLICULAR-CELL ADENOMA																									
FOLLICULAR-CELL CARCINOMA																									
C-CELL ADENOMA							X											X							
C-CELL CARCINOMA																	X	X							
PARATHYROID	+	+	+	+	+	+	+	+	−	+	+	−	+	+	+	−	+	+	+	+	+	+	+	+	+
PANCREATIC ISLETS	+	+	+	+	+	+	+	+	+	+	+	+	+	+	+	+	+	+	+	+	+	+	+	+	+
ISLET-CELL ADENOMA																									
ISLET-CELL CARCINOMA																	X								
REPRODUCTIVE SYSTEM																									
MAMMARY GLAND	+	+	+	+	+	+	+	+	+	+	+	+	+	+	+	+	+	+	+	+	+	+	+	+	+
ADENOMA, NOS																									
FIBROADENOMA								X			X						X				X			
PREPUTIAL/CLITORAL GLAND	N	N	N	N	N	N	N	N	N	N	N	N	N	N	N	N	N	N	N	N	N	N	N	N	N
CARCINOMA, NOS																									
VAGINA	N	N	N	N	N	N	N	N	N	N	N	N	N	N	N	N	N	N	N	N	N	N	N	N	N
FIBROMA								X																	
UTERUS	+	+	+	+	+	+	+	+	+	+	+	+	+	+	+	+	+	+	+	+	+	+	+	+	+
ENDOMETRIAL STROMAL POLYP																									
ENDOMETRIAL STROMAL SARCOMA																									
OVARY	+	+	+	+	+	+	+	+	+	+	+	+	+	+	+	+	+	+	+	+	+	+	+	+	+
NERVOUS SYSTEM																									
BRAIN	+	+	+	+	+	+	+	+	+	+	+	+	+	+	+	+	+	+	+	+	+	+	+	+	+
CARCINOMA, NOS, INVASIVE																									
SPECIAL SENSE ORGANS																									
ZYMBAL GLAND	+	+	N	+	+	N	+	+	N	+	+	+	+	+	+	+	+	+	+	+	+	N	+	+	+
SQUAMOUS CELL PAPILLOMA																									
SQUAMOUS CELL CARCINOMA										X														X	
ALL OTHER SYSTEMS																									
MULTIPLE ORGANS NOS	N	N	N	N	N	N	N	N	N	N	N	N	N	N	N	N	N	N	N	N	N	N	N	N	N
ADENOCARCINOMA, NOS, METASTATIC																									
MUCINOUS CYSTADENOCA, METASTATIC						X																			
SIGNET RING CARCINOMA, METASTATIC																									
SARCOMA, NOS																									
MIXED TUMOR, METASTATIC															X										
CARCINOSARCOMA, METASTATIC																									
MONOCYTIC LEUKEMIA	X	X	X	X	X			X		X		X	X	X				X	X		X	X	X		X
LEUKEMIA, MONONUCLEAR CELL																									

HWBUI0001710

TABLE B4. INDIVIDUAL ANIMAL TUMOR PATHOLOGY OF FEMALE RATS IN THE LIFETIME FEED STUDY OF INTERMEDIATE-RANGE CHRYSOTILE ASBESTOS: 1,2-DIMETHYLHYDRAZINE DIHYDROCHLORIDE (Continued)

ANIMAL NUMBER	67 71	67 72	67 73	67 74	67 75	67 76	67 77	67 78	67 79	68 80	68 81	68 82	68 83	68 84	68 85	68 86	68 87	68 88	68 89	69 90	69 91	69 92	69 93	69 94	69 95	TOTAL
WEEKS ON STUDY	051	116	096	092	091	116	111	080	055	111	095	081	116	080	088	098	116	076	116	115	081	102	083	091	082	TISSUES TUMORS
INTEGUMENTARY SYSTEM																										
SKIN	+	+	+	+	+	+	+	+	+	+	+	+	+	+	+	+	+	+	+	+	+	+	N	+	+	125x
BASAL-CELL TUMOR																										1
SUBCUTANEOUS TISSUE	+	+	+	+	+	+	+	+	+	+	+	+	+	+	+	+	+	+	+	+	+	+	N	+	+	125x
FIBROMA																										2
FIBROSARCOMA																										1
RESPIRATORY SYSTEM																										
LUNGS AND BRONCHI	+	+	+	+	+	+	+	+	+	+	+	+	+	+	+	+	+	+	+	+	+	+	+	+	+	125
ALVEOLAR/BRONCHIOLAR ADENOMA																										1
TRACHEA	+	+	+	+	+	+	+	+	+	+	+	+	+	+	+	+	+	+	+	+	+	+	+	+	+	125
HEMATOPOIETIC SYSTEM																										
BONE MARROW	+	+	+	+	+	+	+	+	+	+	+	+	+	+	+	+	+	+	+	+	+	+	+	+	+	125
SPLEEN	+	+	+	+	+	+	+	+	+	+	+	+	+	+	+	+	+	+	+	+	+	+	+	+	+	125
LYMPH NODES	+	+	+	+	+	+	+	+	+	+	+	+	+	+	+	+	+	+	+	+	+	+	+	+	+	125
C-CELL CARCINOMA, METASTATIC																	X									1
MUCINOUS CYSTADENOCA, METASTATIC																										3
THYMUS	+	-	+	+	+	+	+	+	-	+	-	+	+	+	+	+	+	+	+	+	+	+	-	+	+	106
CIRCULATORY SYSTEM																										
HEART	+	+	+	+	+	+	+	+	+	+	+	+	+	+	+	+	+	+	+	+	+	+	+	+	+	125
DIGESTIVE SYSTEM																										
ORAL CAVITY	N	N	N	N	N	N	N	N	N	N	N	N	N	N	N	N	N	N	N	N	N	N	N	N	N	125x
SQUAMOUS CELL PAPILLOMA																										1
SQUAMOUS CELL CARCINOMA																										1
SQUAMOUS CELL CARCINOMA, INVASIVE																										1
SALIVARY GLAND	+	+	+	+	+	+	+	+	+	+	+	+	-	+	+	+	+	+	+	+	+	+	+	+	+	122
LIVER	+	+	+	+	+	+	+	+	+	+	+	+	+	+	+	+	+	+	+	+	+	+	+	+	+	125
NEOPLASTIC NODULE		X															X	X		X	X					12
HEPATOCELLULAR CARCINOMA		X		X																					X	12
BILE DUCT	+	+	+	+	+	+	+	+	+	+	+	+	+	+	+	+	+	+	+	+	+	+	+	+	+	125
GALLBLADDER & COMMON BILE DUCT	N	N	N	N	N	N	N	N	N	N	N	N	N	N	N	N	N	N	N	N	N	N	N	N	N	125x
PANCREAS	+	+	+	-	+	+	+	+	+	+	+	+	+	+	+	+	+	+	+	+	+	+	+	+	+	124
ACINAR-CELL ADENOMA																										1
ESOPHAGUS	+	+	+	+	+	+	+	+	+	+	+	+	-	+	+	+	+	+	+	+	+	+	+	+	+	121
STOMACH	+	+	+	+	+	+	+	+	+	+	+	+	+	+	+	+	+	+	+	+	+	-	+	+	+	124
SMALL INTESTINE	+	+	+	+	+	+	+	+	+	+	+	+	+	+	+	+	+	+	+	+	+	+	+	+	+	125
MUCINOUS CYSTADENOCARCINOMA																										2
LARGE INTESTINE	+	+	+	+	+	+	+	+	+	+	+	+	+	+	+	+	+	+	+	+	+	+	+	+	+	125
ADENOCARCINOMA, NOS																										1
ADENOMATOUS POLYP, NOS		X	X[a]			X	X	X									X				X	X		X		33
ADENOCA IN ADENOMATOUS POLYP																										2
MUCINOUS CYSTADENOCARCINOMA																X		X					X			14
MUCINOUS CYSTADENOCA, METASTATIC																										1
SIGNET RING CARCINOMA																										2
LEIOMYOSARCOMA																										1
URINARY SYSTEM																										
KIDNEY	+	+	+	+	+	+	+	+	+	+	+	+	+	+	+	+	+	+	+	+	+	+	+	+	+	125
MIXED TUMOR, MALIGNANT	X																									13
CARCINOSARCOMA																										1
URINARY BLADDER	+	+	+	+	+	+	+	+	+	+	+	+	+	+	+	+	+	+	+	+	+	+	+	+	+	125

a: MULTIPLE OCCURENCE OF MORPHOLOGY

HWBUI0001711

TABLE B4. INDIVIDUAL ANIMAL TUMOR PATHOLOGY OF FEMALE RATS IN THE LIFETIME FEED STUDY OF INTERMEDIATE-RANGE CHRYSOTILE ASBESTOS: 1,2-DIMETHYLHYDRAZINE DIHYDROCHLORIDE (Continued)

ANIMAL NUMBER	67 1	67 2	67 3	67 4	67 5	67 6	67 7	67 8	67 9	68 0	68 1	68 2	68 3	68 4	68 5	68 6	68 7	68 8	68 9	69 0	69 1	69 2	69 3	69 4	69 5	TOTAL
WEEKS ON STUDY	0 7 5	1 1 6	1 0 6	1 0 2	0 9 1	1 1 6	1 1 1	0 8 0	1 0 5	1 1 1	0 9 5	0 8 1	1 1 6	1 0 0	0 8 8	0 9 8	1 1 6	0 7 6	1 1 6	1 1 5	0 8 1	1 0 2	0 3 8	0 9 1	0 8 2	TISSUES TUMORS
ENDOCRINE SYSTEM																										
PITUITARY	+	+	+	+	+	+	+	+	+	+	+	+	+	+	+	+	+	+	+	+	+	+	+	+	+	124
CARCINOMA, NOS		X																								1
ADENOMA, NOS						X	X				X							X	X	X		X				32
ADRENAL	+	+	+	+	+	+	+	+	+	+	+	+	+	+	+	+	+	+	+	+	+	+	+	+	+	124
CORTICAL ADENOMA																										1
PHEOCHROMOCYTOMA				X																						6
PHEOCHROMOCYTOMA, MALIGNANT																										1
THYROID	+	+	+	+	+	+	+	+	+	+	+	+	+	+	+	+	+	+	+	+	+	+	+	+	+	124
FOLLICULAR-CELL ADENOMA						X																				7
FOLLICULAR-CELL CARCINOMA																										5
C-CELL ADENOMA				X			X																	X		9
C-CELL CARCINOMA		X			X											X	X									9
PARATHYROID	+	+	+	+	+	+	+	+	+	+	+	+	+	+	+	+	+	+	+	+	+	+	+	+	+	119
PANCREATIC ISLETS	+	+	+	–	+	+	+	+	+	+	+	+	+	+	+	+	+	+	+	+	+	+	+	+	+	124
ISLET-CELL ADENOMA																										1
ISLET-CELL CARCINOMA																										1
REPRODUCTIVE SYSTEM																										
MAMMARY GLAND	+	+	+	+	+	+	+	+	+	+	+	+	+	+	+	+	+	+	+	+	+	+	N	+	+	125*
ADENOMA, NOS																										2
FIBROADENOMA		X		X		X	X		X	X				X	X				X			X			36
PREPUTIAL/CLITORAL GLAND	N	N	N	N	N	N	N	N	N	N	N	N	N	N	N	N	N	N	N	N	N	N	N	N	N	125*
CARCINOMA, NOS																								X		5
VAGINA	N	N	N	N	N	N	N	N	N	N	N	N	N	N	N	N	N	N	N	N	N	N	N	N	N	125*
FIBROMA																										1
UTERUS	+	+	+	+	+	+	+	+	+	+	+	+	+	+	+	+	+	+	+	+	+	+	+	+	+	125
ENDOMETRIAL STROMAL POLYP																X			X							7
ENDOMETRIAL STROMAL SARCOMA																										2
OVARY	+	+	+	+	+	+	+	+	+	+	+	+	+	+	+	+	+	+	+	+	+	+	+	+	+	125
NERVOUS SYSTEM																										
BRAIN	+	+	+	+	+	+	+	+	+	+	+	+	+	+	+	+	+	+	+	+	+	+	+	+	+	125
CARCINOMA, NOS, INVASIVE		X																								1
SPECIAL SENSE ORGANS																										
ZYMBAL GLAND	+	+	+	+	+	+	+	+	+	+	+	N	+	+	+	+	+	+	+	+	+	+	+	+	+	125*
SQUAMOUS CELL PAPILLOMA																										1
SQUAMOUS CELL CARCINOMA					X					X											X					14
ALL OTHER SYSTEMS																										
MULTIPLE ORGANS NOS	N	N	N	N	N	N	N	N	N	N	N	N	N	N	N	N	N	N	N	N	N	N	N	N	N	125*
ADENOCARCINOMA, NOS, METASTATIC																										1
MUCINOUS CYSTADENOCA, METASTATIC																		X					X			6
SIGNET RING CARCINOMA, METASTATIC																										1
SARCOMA, NOS																										1
MIXED TUMOR, METASTATIC																										1
CARCINOSARCOMA, METASTATIC																										1
MONOCYTIC LEUKEMIA				X		X				X	X	X	X			X	X			X	X	X			X	66
LEUKEMIA, MONONUCLEAR CELL																										4

* ANIMALS NECROPSIED

HWBUI0001712

TABLE B4. INDIVIDUAL ANIMAL TUMOR PATHOLOGY OF FEMALE RATS IN THE LIFETIME FEED STUDY OF INTERMEDIATE-RANGE CHRYSOTILE ASBESTOS: INTERMEDIATE-RANGE

ANIMAL NUMBER	0 0 0	0 0 1	0 0 2	0 0 3	0 0 4	0 0 5	0 0 6	0 0 7	0 0 8	0 0 9	0 1 0	0 1 1	0 1 2	0 1 3	0 1 4	0 1 5	0 1 6	0 1 7	0 1 8	0 1 9	0 2 0	0 2 1	0 2 2	0 2 3	0 2 4
WEEKS ON STUDY	1 4 0	1 0 8	1 4 5	1 5 5	1 0 9	1 2 7	1 3 1	1 3 9	1 0 7	1 4 4	1 4 8	1 0 1	1 3 4	1 0 4	1 0 6	0 8 0	2 1 0	2 3 0	2 3 4	2 2 9	2 2 4	2 0 9	2 1 4	1 1 8	1 4 6
INTEGUMENTARY SYSTEM																									
SKIN	+	+	+	+	+	+	+	+	+	+	+	+	+	+	+	+	+	+	+	+	+	+	+	+	+
SQUAMOUS CELL PAPILLOMA																									
SQUAMOUS CELL CARCINOMA																									
BASAL-CELL CARCINOMA																									
KERATOACANTHOMA																									
SUBCUTANEOUS TISSUE	+	+	+	+	+	+	+	+	+	+	+	+	+	+	+	+	+	+	+	+	+	+	+	+	+
SQUAMOUS CELL CARCINOMA									X																
FIBROMA																									
FIBROSARCOMA																									
LIPOMA																									
RESPIRATORY SYSTEM																									
LUNGS AND BRONCHI	+	+	+	+	+	+	+	+	+	+	+	+	+	+	+	+	+	+	+	+	+	+	+	+	+
SQUAMOUS CELL CARCINOMA, METASTAT															X										
ADENOCARCINOMA, NOS, METASTATIC																									
ALVEOLAR/BRONCHIOLAR ADENOMA																									
ALVEOLAR/BRONCHIOLAR CARCINOMA																									
FOLLICULAR-CELL CARCINOMA, METAST																									
C-CELL CARCINOMA, METASTATIC																									
TRACHEA	+	+	+	+	+	+	+	+	+	+	+	+	+	+	+	+	+	+	+	+	+	+	+	+	+
LARYNX	N	N	N	N	N	N	N	N	N	N	N	N	N	N	N	N	N	N	N	N	N	N	N	N	N
FOLLICULAR-CELL CARCINOMA, INVASI																									
C-CELL CARCINOMA, INVASIVE																									
HEMATOPOIETIC SYSTEM																									
BONE MARROW	+	+	+	+	+	+	+	+	+	+	+	+	+	+	+	+	+	+	+	+	+	+	+	+	+
SPLEEN	+	+	+	+	+	+	+	+	+	+	+	+	+	+	+	+	+	+	+	+	+	+	+	+	+
LYMPH NODES	+	+	+	+	+	+	+	+	+	+	+	+	+	+	+	+	+	+	+	+	+	+	+	+	+
SQUAMOUS CELL CARCINOMA, METASTAT															X										
ADENOCARCINOMA, NOS, METASTATIC																									
FOLLICULAR-CELL CARCINOMA, METAST																									
C-CELL CARCINOMA, METASTATIC																									
MALIG.LYMPHOMA, HISTIOCYTIC TYPE																									X
THYMUS	+	+	+	+	+	+	+	-	-	+	+	+	-	+	+	+	+	+	+	+	-	+	+	+	+
CIRCULATORY SYSTEM																									
HEART	+	+	+	+	+	+	+	+	+	+	+	+	+	+	+	+	+	+	+	+	+	+	+	+	+
ADENOCARCINOMA, NOS, METASTATIC																									
DIGESTIVE SYSTEM																									
ORAL CAVITY	N	N	N	N	N	N	N	N	N	N	N	N	N	N	N	N	N	N	N	N	N	N	N	N	N
SQUAMOUS CELL PAPILLOMA																									
SQUAMOUS CELL CARCINOMA																									
SALIVARY GLAND	+	+	+	+	+	+	+	+	+	+	+	+	+	+	+	+	+	+	+	+	+	+	+	+	+
ADENOCARCINOMA, NOS																									
LIVER	+	+	+	+	+	+	+	+	+	+	+	+	+	+	+	+	+	+	+	+	+	+	+	+	+
NEOPLASTIC NODULE																									
HEPATOCELLULAR CARCINOMA																									
CORTICAL CARCINOMA, METASTATIC																									
MALIG.LYMPHOMA, HISTIOCYTIC TYPE																							X		
BILE DUCT	+	+	+	+	+	+	+	+	+	+	+	+	+	+	+	+	+	+	+	+	+	+	+	+	+
GALLBLADDER & COMMON BILE DUCT	N	N	N	N	N	N	N	N	N	N	N	N	N	N	N	N	N	N	N	N	N	N	N	N	N
PANCREAS	+	+	+	+	+	+	+	+	+	+	+	+	+	+	+	+	+	+	+	+	+	+	+	+	+
ACINAR-CELL ADENOMA									X																
ACINAR-CELL CARCINOMA																									
ESOPHAGUS	+	+	+	+	+	+	+	+	+	+	+	+	+	+	+	+	+	+	+	+	+	+	+	+	+
STOMACH	+	+	+	+	+	+	+	+	+	+	+	+	+	+	+	+	+	+	+	+	+	+	+	+	+
ADENOMATOUS POLYP, NOS																									
CARCINOID TUMOR, NOS																									
LEIOMYOSARCOMA											X														
ENDOMETRIAL STROMAL SARCOMA, META																									
SMALL INTESTINE	+	+	+	+	+	+	+	+	+	+	+	+	+	+	+	+	+	+	+	+	+	+	+	+	+
LARGE INTESTINE	+	+	+	+	+	+	+	+	+	+	+	+	+	+	+	+	+	+	+	+	+	+	+	+	+
ADENOMATOUS POLYP, NOS																									
LEIOMYOMA																									

+: TISSUE EXAMINED MICROSCOPICALLY
-: REQUIRED TISSUE NOT EXAMINED MICROSCOPICALLY
X: TUMOR INCIDENCE
N: NECROPSY, NO AUTOLYSIS, NO MICROSCOPIC EXAMINATION
S: ANIMAL MIS-SEXED
: NO TISSUE INFORMATION SUBMITTED
C: NECROPSY, NO HISTOLOGY DUE TO PROTOCOL
A: AUTOLYSIS
M: ANIMAL MISSING
B: NO NECROPSY PERFORMED

HWBUI0001713

TABLE B4. INDIVIDUAL ANIMAL TUMOR PATHOLOGY OF FEMALE RATS IN THE LIFETIME FEED STUDY OF INTERMEDIATE-RANGE CHRYSOTILE ASBESTOS: INTERMEDIATE-RANGE (Continued)

ANIMAL NUMBER	0 0 0	0 0 1	0 0 2	0 0 3	0 0 4	0 0 5	0 0 6	0 0 7	0 0 8	0 0 9	0 1 0	0 1 1	0 1 2	0 1 3	0 1 4	0 1 5	0 1 6	0 1 7	0 1 8	0 1 9	0 2 0	0 2 1	0 2 2	0 2 3	0 2 4
WEEKS ON STUDY	1 4 0	1 0 8	1 4 5	1 1 5	1 0 9	1 2 7	1 3 1	1 3 9	1 0 7	1 4 4	1 6 1	1 6 3	1 3 4	1 0 4	1 1 0	1 2 1	1 3 0	1 3 4	1 2 9	1 2 2	1 0 4	1 2 9	1 1 6	1 0 8	1 4 6
URINARY SYSTEM																									
KIDNEY	+	+	+	+	+	+	+	+	+	+	+	+	+	+	+	+	+	+	+	+	+	+	+	+	+
CARCINOMA, NOS																									
LIPOSARCOMA																									
URINARY BLADDER	+	+	+	+	+	+	+	+	+	+	+	+	+	+	+	+	+	+	+	+	+	+	+	+	+
TRANSITIONAL-CELL PAPILLOMA																									
ENDOCRINE SYSTEM																									
PITUITARY	+	+	+	+	+	+	+	+	+	+	+	+	+	+	+	+	+	+	+	+	+	+	+	+	+
CARCINOMA, NOS	X			X															X	X		X			
ADENOMA, NOS		X			X			X		X			X								X		X		
ADRENAL	+	+	+	+	+	+	+	+	+	+	+	+	+	+	+	+	+	+	+	+	+	+	+	+	+
CORTICAL ADENOMA	X																								
CORTICAL CARCINOMA																								X	
PHEOCHROMOCYTOMA										X								X					X		
THYROID	+	+	-	+	+	+	+	+	+	+	+	+	+	+	+	+	+	+	+	+	+	+	+	+	+
FOLLICULAR-CELL ADENOMA																									
FOLLICULAR-CELL CARCINOMA				X	X			X																	
C-CELL ADENOMA					X																				
C-CELL CARCINOMA								X		X														X	
PARATHYROID	+	-	-	+	+	+	+	+	+	+	+	+	+	+	+	+	+	+	+	+	+	+	+	+	+
ADENOMA, NOS																									
C-CELL CARCINOMA, INVASIVE																									
PANCREATIC ISLETS	+	+	+	+	+	+	+	+	+	+	+	+	+	+	+	+	+	+	+	+	+	+	+	+	+
ISLET-CELL ADENOMA								X																	
ISLET-CELL CARCINOMA																									
REPRODUCTIVE SYSTEM																									
MAMMARY GLAND	+	+	+	+	+	+	+	+	+	+	+	+	+	+	+	+	+	+	+	+	+	+	+	+	+
CARCINOMA, NOS																									
ADENOMA, NOS																					X				X
ADENOCARCINOMA, NOS							X						X												
FIBROADENOMA	X	X	X	X		X		X				X			X	X	X	X	X	X		X		X	X
PREPUTIAL/CLITORAL GLAND	N	N	N	N	N	N	N	N	N	N	N	N	N	N	N	N	N	N	N	N	N	N	N	N	N
CARCINOMA, NOS							X			X															
SQUAMOUS CELL CARCINOMA																									
FEMALE EXTERNAL GENITALIA	N	N	N	N	N	N	N	N	N	N	N	N	N	N	N	N	N	N	N	N	N	N	N	N	N
FIBROSARCOMA, INVASIVE																									
VAGINA	N	N	N	N	N	N	N	N	N	N	N	N	N	N	N	N	N	N	N	N	N	N	N	N	N
FIBROSARCOMA																									
ENDOMETRIAL STROMAL SARCOMA																									
UTERUS	+	+	+	+	+	+	+	+	+	+	+	+	+	+	+	+	+	+	+	+	+	+	+	+	+
CARCINOMA, NOS																									
ADENOMA, NOS																									
FIBROMA																									
LEIOMYOMA																									
ENDOMETRIAL STROMAL POLYP					X				X																X
ENDOMETRIAL STROMAL SARCOMA																									
OVARY	+	+	+	+	+	+	+	+	+	+	+	+	+	+	+	+	+	+	+	+	+	+	+	+	+
PAPILLARY ADENOCARCINOMA																									
GRANULOSA-CELL TUMOR					X								X												
NERVOUS SYSTEM																									
BRAIN	+	+	+	+	+	+	+	+	+	+	+	+	+	+	+	+	+	+	+	+	+	+	+	+	+
CARCINOMA, NOS, INVASIVE				X																					
ASTROCYTOMA																									
SPINAL CORD	N	N	N	N	N	N	N	N	N	N	N	N	N	N	N	N	N	N	N	N	N	N	N	N	N
OLIGODENDROGLIOMA																									
SPECIAL SENSE ORGANS																									
EYE	+	N	+	N	N	N	N	N	N	+	N	N	+	N	N	+	N	+	N	N	N	N	+	N	+
FIBROMA																									
ZYMBAL GLAND	+	+	+	+	+	+	+	+	+	+	+	+	+	+	+	+	+	+	+	+	+	+	+	+	+
SQUAMOUS CELL CARCINOMA															X										
MUSCULOSKELETAL SYSTEM																									
BONE	N	N	N	N	N	N	N	N	N	N	N	N	N	N	N	N	N	N	N	N	N	N	N	N	N
SQUAMOUS CELL CARCINOMA																									
ALL OTHER SYSTEMS																									
MULTIPLE ORGANS NOS	N	N	N	N	N	N	N	N	N	N	N	N	N	N	N	N	N	N	N	N	N	N	N	N	N
ALVEOLAR/BRONCHIOLAR CA, METASTAT																									
PAPILLARY ADENOCARCINOMA, METASTA																									
CORTICAL CARCINOMA, METASTATIC																								X	
MYELOMONOCYTIC LEUKEMIA																						X			
MONOCYTIC LEUKEMIA		X		X		X									X			X					X		
LEUKEMIA, MONONUCLEAR CELL																									
PERINEUM NOS																									
FIBROSARCOMA																									
FOOT NOS																									
FIBROMA																									X

HWBUI0001714

TABLE B4. INDIVIDUAL ANIMAL TUMOR PATHOLOGY OF FEMALE RATS IN THE LIFETIME FEED STUDY OF INTERMEDIATE-RANGE CHRYSOTILE ASBESTOS: INTERMEDIATE-RANGE (Continued)

ANIMAL NUMBER	0 2 1	0 2 2	0 2 3	0 2 4	0 2 5	0 2 6	0 2 7	0 2 8	0 2 9	0 3 0	0 3 1	0 3 2	0 3 3	0 3 4	0 3 5	0 3 6	0 3 7	0 3 8	0 3 9	0 4 0	0 4 1	0 4 2	0 4 3	0 4 4	0 4 5	0 4 6	0 4 7	0 4 8	0 4 9
WEEKS ON STUDY	3 3 2	3 3 1	3 3 1	4 4 6	2 1 1	1 1 1	0 0 9	0 3 5	3 3 7	3 3 6	1 1 4	1 4 3	3 3 7	1 1 9	1 4 6	1 1 9	1 3 5	0 8 0	1 2 9	1 2 1	0 8 3	1 3 2	1 4 0	0 3 5	0 4 6				
INTEGUMENTARY SYSTEM																													
SKIN	+	+	+	+	+	+	+	+	+	+	+	+	+	+	+	+	+	+	+	+	+	+	+	+	+	+	+	+	+
SQUAMOUS CELL PAPILLOMA																											X		
SQUAMOUS CELL CARCINOMA																													
BASAL-CELL CARCINOMA																													
KERATOACANTHOMA				X																									
SUBCUTANEOUS TISSUE	+	+	+	+	+	+	+	+	+	+	+	+	+	+	+	+	+	+	+	+	+	+	+	+	+	+	+	+	+
SQUAMOUS CELL CARCINOMA																													
FIBROMA																					X								
FIBROSARCOMA													X																
LIPOMA																													
RESPIRATORY SYSTEM																													
LUNGS AND BRONCHI	+	+	+	+	+	+	+	+	+	+	+	+	+	+	+	+	+	+	+	+	+	+	+	+	+	+	+	+	+
SQUAMOUS CELL CARCINOMA, METASTAT																													
ADENOCARCINOMA, NOS, METASTATIC																													
ALVEOLAR/BRONCHIOLAR ADENOMA													X																
ALVEOLAR/BRONCHIOLAR CARCINOMA																													
FOLLICULAR-CELL CARCINOMA, METAST																													
C-CELL CARCINOMA, METASTATIC														X															
TRACHEA	+	+	+	+	+	+	+	+	+	+	+	+	+	+	+	+	+	+	+	+	+	+	+	+	+	+	+	+	+
LARYNX	N	N	N	N	N	N	N	N	N	N	N	N	N	N	N	N	N	N	N	N	N	N	N	N	N	N	N	N	N
FOLLICULAR-CELL CARCINOMA, INVASI																													
C-CELL CARCINOMA, INVASIVE																													
HEMATOPOIETIC SYSTEM																													
BONE MARROW	+	+	+	+	+	+	+	+	+	+	+	+	+	+	+	+	+	+	+	+	+	+	+	+	+	+	+	+	+
SPLEEN	+	+	+	+	+	+	+	+	+	+	+	+	+	+	+	+	+	+	+	+	+	+	+	+	+	+	+	+	+
LYMPH NODES	+	+	+	+	+	+	+	+	+	+	+	+	+	+	+	+	+	+	+	+	+	+	+	+	+	+	+	+	+
SQUAMOUS CELL CARCINOMA, METASTAT																													
ADENOCARCINOMA, NOS, METASTATIC																													
FOLLICULAR-CELL CARCINOMA, METAST																													
C-CELL CARCINOMA, METASTATIC																													
MALIG.LYMPHOMA, HISTIOCYTIC TYPE																													
THYMUS	+	-	+	+	+	+	+	-	+	+	+	+	+	-	+	+	+	+	+	+	+	+	+	+	+	+	+	+	+
CIRCULATORY SYSTEM																													
HEART	+	+	+	+	+	+	+	+	+	+	+	+	+	+	+	+	+	+	+	+	+	+	+	+	+	+	+	+	+
ADENOCARCINOMA, NOS, METASTATIC																													
DIGESTIVE SYSTEM																													
ORAL CAVITY	N	N	N	N	N	N	N	N	N	N	N	N	N	N	N	N	N	N	N	N	N	N	N	N	N	N	N	N	N
SQUAMOUS CELL PAPILLOMA																							X						
SQUAMOUS CELL CARCINOMA		X																											
SALIVARY GLAND	+	+	+	+	+	+	+	+	+	+	+	+	+	+	+	+	+	+	+	+	+	+	+	+	+	+	+	+	+
ADENOCARCINOMA, NOS																													
LIVER	+	+	+	+	+	+	+	+	+	+	+	+	+	+	+	+	+	+	+	+	+	+	+	+	+	+	+	+	+
NEOPLASTIC NODULE								X																					
HEPATOCELLULAR CARCINOMA	X																												
CORTICAL CARCINOMA, METASTATIC																													
MALIG.LYMPHOMA, HISTIOCYTIC TYPE																													
BILE DUCT	+	+	+	+	+	+	+	+	+	+	+	+	+	+	+	+	+	+	+	+	+	+	+	+	+	+	+	+	+
GALLBLADDER & COMMON BILE DUCT	N	N	N	N	N	N	N	N	N	N	N	N	N	N	N	N	N	N	N	N	N	N	N	N	N	N	N	N	N
PANCREAS	+	+	+	+	+	+	+	+	+	+	+	+	+	+	+	+	+	+	+	+	+	+	+	+	+	+	+	+	+
ACINAR-CELL ADENOMA													X																
ACINAR-CELL CARCINOMA																													
ESOPHAGUS	+	+	+	+	+	+	+	+	+	+	+	+	+	+	+	+	+	+	+	+	+	+	+	+	+	+	+	+	+
STOMACH	+	+	+	+	+	+	+	+	+	+	+	+	+	+	+	+	+	+	+	+	+	+	+	+	+	+	+	+	+
ADENOMATOUS POLYP, NOS																													
CARCINOID TUMOR, NOS																													
LEIOMYOSARCOMA																													
ENDOMETRIAL STROMAL SARCOMA, META																													
SMALL INTESTINE	+	+	+	+	+	+	+	+	+	+	+	+	+	+	+	+	+	+	+	+	+	+	+	+	+	+	+	+	+
LARGE INTESTINE	+	+	+	+	+	+	+	+	+	+	+	+	+	+	+	+	+	+	+	+	+	+	+	+	+	+	+	+	+
ADENOMATOUS POLYP, NOS																													
LEIOMYOMA																													

HWBUI0001715

TABLE B4. INDIVIDUAL ANIMAL TUMOR PATHOLOGY OF FEMALE RATS IN THE LIFETIME FEED STUDY OF INTERMEDIATE-RANGE CHRYSOTILE ASBESTOS: INTERMEDIATE-RANGE (Continued)

ANIMAL NUMBER	0252	0257	0258	0259	0260	0331	0332	0333	0334	0335	0336	0337	0338	0339	0340	0341	0342	0343	0344	0345	0346	0347	0348	0349
WEEKS ON STUDY	1132	1131	1156	1161	1211	1101	0991	0935	1037	0941	1131	1146	1137	1119	1146	1119	1135	0880	1229	1121	0883	1132	1140	1046
URINARY SYSTEM																								
KIDNEY	+	+	+	+	+	+	+	+	+	+	+	+	+	+	+	+	+	+	+	+	+	+	+	+
CARCINOMA, NOS																								
LIPOSARCOMA																								
URINARY BLADDER	+	+	+	+	+	+	+	+	+	+	+	+	+	+	+	+	+	+	+	+	+	+	+	+
TRANSITIONAL-CELL PAPILLOMA																								
ENDOCRINE SYSTEM																								
PITUITARY	+	+	+	+	+	+	+	+	+	+	+	+	+	+	+	+	+	+	+	+	+	+	+	+
CARCINOMA, NOS													X										X	
ADENOMA, NOS	X						X		X	X					X		X	X		X	X	X	X	X
ADRENAL	+	+	+	+	+	+	+	+	+	+	+	+	+	+	+	+	+	+	+	+	+	+	+	+
CORTICAL ADENOMA																X								
CORTICAL CARCINOMA																								
PHEOCHROMOCYTOMA									X														X	X
THYROID	+	+	+	+	+	+	+	+	+	+	+	+	+	+	+	+	+	+	+	+	+	+	+	+
FOLLICULAR-CELL ADENOMA			X															X						
FOLLICULAR-CELL CARCINOMA																X							X	X
C-CELL ADENOMA		X							X												X	X		
C-CELL CARCINOMA									X			X	X					X						
PARATHYROID	+	+	+	+	+	+	+	+	+	+	+	+	+	+	+	+	+	+	+	+	+	+	+	+
ADENOMA, NOS																								
C-CELL CARCINOMA, INVASIVE																								
PANCREATIC ISLETS	+	+	+	+	+	+	+	+	+	+	+	+	+	+	+	+	+	+	+	+	+	+	+	+
ISLET-CELL ADENOMA																								
ISLET-CELL CARCINOMA												X		X										
REPRODUCTIVE SYSTEM																								
MAMMARY GLAND	+	+	+	+	+	+	+	+	+	+	+	+	+	+	+	+	+	+	+	+	+	+	+	+
CARCINOMA, NOS																								
ADENOMA, NOS					X							X												
ADENOCARCINOMA, NOS															X									
FIBROADENOMA	X			X	X			X				X	X	X	X		X		X		X	X		
PREPUTIAL/CLITORAL GLAND	N	N	N	N	N	N	N	N	N	N	N	N	N	N	N	N	N	N	N	N	N	N	N	N
CARCINOMA, NOS																								
SQUAMOUS CELL CARCINOMA																								
FEMALE EXTERNAL GENITALIA	N	N	N	N	N	N	N	N	N	N	N	N	N	N	N	N	N	N	N	N	N	N	N	N
FIBROSARCOMA, INVASIVE																								
VAGINA	N	N	N	N	N	N	N	N	N	N	N	N	N	N	N	N	N	N	N	N	N	N	N	N
FIBROSARCOMA																								
ENDOMETRIAL STROMAL SARCOMA																								
UTERUS	+	+	+	+	+	+	+	+	+	+	+	+	+	+	+	+	+	+	+	+	+	+	+	+
CARCINOMA, NOS																								
ADENOMA, NOS																								
FIBROMA																								
LEIOMYOMA																								
ENDOMETRIAL STROMAL POLYP																								
ENDOMETRIAL STROMAL SARCOMA																								
OVARY	+	+	+	+	+	+	+	+	+	+	+	+	+	+	+	+	+	+	+	+	+	+	+	+
PAPILLARY ADENOCARCINOMA																								
GRANULOSA-CELL TUMOR																								
NERVOUS SYSTEM																								
BRAIN	+	+	+	+	+	+	+	+	+	+	+	+	+	+	+	+	+	+	+	+	+	+	+	+
CARCINOMA, NOS, INVASIVE													X										X	
ASTROCYTOMA																								
SPINAL CORD	N	N	N	N	N	N	N	N	N	N	N	N	N	N	N	N	N	N	N	N	N	+	N	N
OLIGODENDROGLIOMA																								
SPECIAL SENSE ORGANS																								
EYE	N	N	N	+	N	N	N	N	N	+	N	N	+	+	+	N	N	N	N	N	N	N	N	+
FIBROMA																								
ZYMBAL GLAND	+	+	+	+	+	+	+	+	+	+	+	+	+	+	+	+	+	+	+	+	+	+	+	+
SQUAMOUS CELL CARCINOMA																								
MUSCULOSKELETAL SYSTEM																								
BONE	N	N	N	N	N	N	N	N	N	N	N	N	N	N	N	N	N	N	N	N	N	N	N	N
SQUAMOUS CELL CARCINOMA																								
ALL OTHER SYSTEMS																								
MULTIPLE ORGANS NOS	N	N	N	N	N	N	N	N	N	N	N	N	N	N	N	N	N	N	N	N	N	N	N	N
ALVEOLAR/BRONCHIOLAR CA, METASTAT																								
PAPILLARY ADENOCARCINOMA, METASTA																X								
CORTICAL CARCINOMA, METASTATIC																								
MYELOMONOCYTIC LEUKEMIA			X		X	X		X	X	X	X	X				X						X		
MONOCYTIC LEUKEMIA															X									
LEUKEMIA, MONONUCLEAR CELL																								
PERINEUM NOS																								
FIBROSARCOMA																								
FOOT NOS																								
FIBROMA																								

HWBUI0001716

TABLE B4. INDIVIDUAL ANIMAL TUMOR PATHOLOGY OF FEMALE RATS IN THE LIFETIME FEED STUDY OF INTERMEDIATE-RANGE CHRYSOTILE ASBESTOS: INTERMEDIATE-RANGE (Continued)

ANIMAL NUMBER	050	051	052	053	054	055	056	057	058	059	060	061	062	063	064	065	066	067	068	069	070	071	072	073	074
WEEKS ON STUDY	108	101	128	146	121	134	140	146	108	083	146	118	131	155	089	142	146	138	132	139	135	024	093	134	144
INTEGUMENTARY SYSTEM																									
SKIN	+	+	+	+	+	+	+	+	+	+	+	+	+	+	+	+	+	+	+	+	+	+	+	+	+
SQUAMOUS CELL PAPILLOMA																									
SQUAMOUS CELL CARCINOMA			X														X	X							
BASAL-CELL CARCINOMA																									
KERATOACANTHOMA																									
SUBCUTANEOUS TISSUE	+	+	+	+	+	+	+	+	+	+	+	+	+	+	+	+	+	+	+	+	+	+	+	+	+
SQUAMOUS CELL CARCINOMA						X																			
FIBROMA																									
FIBROSARCOMA																									
LIPOMA																				X					
RESPIRATORY SYSTEM																									
LUNGS AND BRONCHI	+	+	+	+	+	+	+	+	+	+	+	+	+	+	+	+	+	+	+	+	+	+	+	+	+
SQUAMOUS CELL CARCINOMA, METASTAT																									
ADENOCARCINOMA, NOS, METASTATIC																			X						
ALVEOLAR/BRONCHIOLAR ADENOMA																									
ALVEOLAR/BRONCHIOLAR CARCINOMA																									
FOLLICULAR-CELL CARCINOMA, METAST																									
C-CELL CARCINOMA, METASTATIC																					X				
TRACHEA	+	+	+	+	+	+	+	+	+	+	+	+	+	+	+	+	+	+	+	+	+	+	+	+	+
LARYNX	M	M	M	M	M	M	M	M	M	M	M	M	M	M	M	M	M	M	M	M	M	M	M	M	M
FOLLICULAR-CELL CARCINOMA, INVASI																									
C-CELL CARCINOMA, INVASIVE																									
HEMATOPOIETIC SYSTEM																									
BONE MARROW	+	+	+	+	+	+	+	+	+	+	+	+	+	+	+	+	+	+	+	+	+	+	+	+	+
SPLEEN	+	+	+	+	+	+	+	+	+	+	+	+	+	+	+	+	+	+	+	+	+	+	+	+	+
LYMPH NODES	+	+	+	+	+	+	+	+	+	+	+	+	+	+	+	+	+	+	+	+	+	+	+	+	+
SQUAMOUS CELL CARCINOMA, METASTAT																									
ADENOCARCINOMA, NOS, METASTATIC																			X						
FOLLICULAR-CELL CARCINOMA, METAST																									
C-CELL CARCINOMA, METASTATIC																					X				
MALIG.LYMPHOMA, HISTIOCYTIC TYPE																									
THYMUS	+	+	+	+	+	+	+	-	+	+	+	+	-	+	+	-	+	+	+	+	-	+	+	+	+
CIRCULATORY SYSTEM																									
HEART	+	+	+	+	+	+	+	+	+	+	+	+	+	+	+	+	+	+	+	+	+	+	+	+	+
ADENOCARCINOMA, NOS, METASTATIC																			X						
DIGESTIVE SYSTEM																									
ORAL CAVITY	M	M	M	M	M	M	M	M	M	M	M	M	M	M	M	M	M	M	M	M	M	M	M	M	M
SQUAMOUS CELL PAPILLOMA																									
SQUAMOUS CELL CARCINOMA																									
SALIVARY GLAND	+	+	+	+	+	+	+	+	+	+	+	+	+	+	+	+	+	+	+	+	+	+	+	+	+
ADENOCARCINOMA, NOS																									
LIVER	+	+	+	+	+	+	+	+	+	+	+	+	+	+	+	+	+	+	+	+	+	+	+	+	+
NEOPLASTIC NODULE															X										
HEPATOCELLULAR CARCINOMA																									
CORTICAL CARCINOMA, METASTATIC							X																		
MALIG.LYMPHOMA, HISTIOCYTIC TYPE																									
BILE DUCT	+	+	+	+	+	+	+	+	+	+	+	+	+	+	+	+	+	+	+	+	+	+	+	+	+
GALLBLADDER & COMMON BILE DUCT	N	N	N	N	N	N	N	N	N	N	N	N	N	N	N	N	N	N	N	N	N	N	N	N	N
PANCREAS	+	+	+	+	+	+	+	+	+	+	+	+	+	+	+	+	+	+	+	+	+	+	+	+	+
ACINAR-CELL ADENOMA																		X							
ACINAR-CELL CARCINOMA								X																	
ESOPHAGUS	+	+	+	+	+	+	+	+	+	+	+	+	+	+	+	+	+	+	+	+	+	+	+	+	+
STOMACH	+	+	+	+	+	+	+	+	+	+	+	+	+	+	+	+	+	+	+	+	+	+	+	+	+
ADENOMATOUS POLYP, NOS																									
CARCINOID TUMOR, NOS				X																					
LEIOMYOSARCOMA																									
ENDOMETRIAL STROMAL SARCOMA, META																									
SMALL INTESTINE	+	+	+	+	+	+	+	+	+	+	+	+	+	+	+	+	+	+	+	+	+	+	+	+	+
LARGE INTESTINE	+	+	+	+	+	+	+	+	+	+	+	+	+	+	+	+	+	+	+	+	+	+	+	+	+
ADENOMATOUS POLYP, NOS																									
LEIOMYOMA																									

HWBUI0001717

TABLE B4. INDIVIDUAL ANIMAL TUMOR PATHOLOGY OF FEMALE RATS IN THE LIFETIME FEED STUDY OF INTERMEDIATE-RANGE CHRYSOTILE ASBESTOS: INTERMEDIATE-RANGE (Continued)

ANIMAL NUMBER	0 3 0 1	0 3 1 2	0 3 2 3	0 3 3 4	0 3 4 5	0 3 5 6	0 3 6 7	0 3 7 8	0 3 8 9	0 3 9 0	0 4 0 1	0 4 1 2	0 4 2 3	0 4 3 4	0 4 4 5	0 4 5 6	0 4 6 7	0 4 7 8	0 4 8 9	0 4 9 0	0 5 0 1	0 5 1 2	0 5 2 3	0 5 3 4
WEEKS ON STUDY	1 0 0	1 0 2	1 4 4	1 2 3	1 3 4	1 4 5	1 4 6	0 8 5	0 6 5	1 4 4	1 1 8	1 3 4	1 4 5	1 4 6	0 6 2	1 4 4	1 3 8	1 3 3	1 3 3	1 3 5	0 8 4	0 9 1	1 3 4	1 4 4
URINARY SYSTEM																								
KIDNEY	+	+	+	+	+	+	+	+	+	+	+	+	+	+	+	+	+	+	+	+	+	+	+	+
CARCINOMA, NOS																								
LIPOSARCOMA																								
URINARY BLADDER	+	+	+	+	+	+	+	+	+	+	+	+	+	+	+	+	+	+	+	+	+	+	-	+
TRANSITIONAL-CELL PAPILLOMA																								
ENDOCRINE SYSTEM																								
PITUITARY	+	+	+	+	+	+	+	+	+	+	+	+	+	+	+	+	+	+	+	+	+	+	+	+
CARCINOMA, NOS											X													
ADENOMA, NOS		X		X	X			X			X			X		X	X	X	X	X				
ADRENAL	+	+	+	+	+	+	+	+	+	+	+	+	+	+	+	+	+	+	+	+	-	+	+	+
CORTICAL ADENOMA							X																	
CORTICAL CARCINOMA													X					X						X
PHEOCHROMOCYTOMA																								
THYROID	+	+	+	+	+	+	+	+	+	+	+	+	+	+	+	+	+	+	+	+	+	+	+	+
FOLLICULAR-CELL ADENOMA																		X		X			X	
FOLLICULAR-CELL CARCINOMA						X					X			X		X			X					
C-CELL ADENOMA							X	X				X		X			X				X		X	
C-CELL CARCINOMA																								
PARATHYROID	+	+	+	+	+	+	+	+	+	+	+	+	+	+	-	+	+	+	+	-	+	+	+	+
ADENOMA, NOS											X													
C-CELL CARCINOMA, INVASIVE																							X	
PANCREATIC ISLETS	+	+	+	+	+	+	+	+	+	+	+	+	+	+	+	+	+	+	+	+	+	+	+	+
ISLET-CELL ADENOMA																								
ISLET-CELL CARCINOMA														X	X					X				
REPRODUCTIVE SYSTEM																								
MAMMARY GLAND	+	+	+	+	+	+	+	+	+	+	+	+	+	+	+	+	+	+	+	+	+	+	+	+
CARCINOMA, NOS											X													
ADENOMA, NOS		X	X		X						X		X						X					
ADENOCARCINOMA, NOS														X				X						
FIBROADENOMA			X					X		X	X	X	X	X		X						X	X	X
PREPUTIAL/CLITORAL GLAND	N	N	N	N	N	N	N	N	N	N	N	N	N	N	N	N	N	N	N	N	N	N	N	N
CARCINOMA, NOS				X														X						
SQUAMOUS CELL CARCINOMA																								
FEMALE EXTERNAL GENITALIA	N	N	N	N	N	N	N	N	N	N	N	N	N	N	N	N	N	N	N	N	N	N	N	N
FIBROSARCOMA, INVASIVE				X																				
VAGINA	N	N	N	N	N	N	N	N	N	N	N	N	N	N	N	N	N	N	N	N	N	N	N	N
FIBROSARCOMA				X																				
ENDOMETRIAL STROMAL SARCOMA																								
UTERUS	+	+	+	+	+	+	+	+	+	+	+	+	+	+	+	+	+	+	+	+	+	+	+	+
CARCINOMA, NOS																								
ADENOMA, NOS																								
FIBROMA																								
LEIOMYOMA																								
ENDOMETRIAL STROMAL POLYP							X																	
ENDOMETRIAL STROMAL SARCOMA																								
OVARY	+	+	+	+	+	+	+	+	+	+	+	+	+	+	+	+	+	+	+	+	+	+	+	+
PAPILLARY ADENOCARCINOMA																								
GRANULOSA-CELL TUMOR				X																				
NERVOUS SYSTEM																								
BRAIN	+	+	+	+	+	+	+	+	+	+	+	+	+	+	+	+	+	+	+	+	+	+	+	+
CARCINOMA, NOS, INVASIVE											X													
ASTROCYTOMA																								
SPINAL CORD	N	N	N	+	N	N	N	N	N	N	N	N	N	N	N	N	N	N	N	N	N	N	N	N
OLIGODENDROGLIOMA																								
SPECIAL SENSE ORGANS																								
EYE	N	N	N	+	N	+	+	+	N	+	+	N	+	+	N	+	+	+	+	+	+	N	N	+
FIBROMA																								
ZYMBAL GLAND	+	+	+	+	+	+	+	+	+	+	+	+	+	+	+	+	+	+	+	+	+	+	+	+
SQUAMOUS CELL CARCINOMA				X																				
MUSCULOSKELETAL SYSTEM																								
BONE	N	N	N	N	N	N	N	N	N	N	N	N	N	N	X	N	N	N	N	N	N	N	N	N
SQUAMOUS CELL CARCINOMA																								
ALL OTHER SYSTEMS																								
MULTIPLE ORGANS NOS	N	N	N	N	N	N	N	N	N	N	N	N	N	N	N	N	N	N	N	N	N	N	N	N
ALVEOLAR/BRONCHIOLAR CA, METASTAT																								
PAPILLARY ADENOCARCINOMA, METASTA																								
CORTICAL CARCINOMA, METASTATIC																								
MYELOMONOCYTIC LEUKEMIA																								
MONOCYTIC LEUKEMIA	X	X												X	X				X			X		
LEUKEMIA, MONONUCLEAR CELL				X																				
PERINEUM NOS																								
FIBROSARCOMA																	X							
FOOT NOS																								
FIBROMA																								

HWBUI0001718

TABLE B4. INDIVIDUAL ANIMAL TUMOR PATHOLOGY OF FEMALE RATS IN THE LIFETIME FEED STUDY OF INTERMEDIATE-RANGE CHRYSOTILE ASBESTOS: INTERMEDIATE-RANGE (Continued)

ANIMAL NUMBER	075	076	077	078	079	080	081	082	083	084	085	086	087	088	089	090	091	092	093	094	095	096	097	098	099
WEEKS ON STUDY	108	112	120	146	094	132	138	101	096	100	108	145	139	146	125	136	137	111	094	113	100	112	146	137	112
INTEGUMENTARY SYSTEM																									
SKIN	+	+	+	+	+	+	+	+	+	+	+	+	+	+	+	+	+	+	+	+	+	+	+	+	+
SQUAMOUS CELL PAPILLOMA																									
SQUAMOUS CELL CARCINOMA																									
BASAL-CELL CARCINOMA																									
KERATOACANTHOMA																									
SUBCUTANEOUS TISSUE	+	+	+	+	+	+	+	+	+	+	+	+	+	+	+	+	+	+	+	+	+	+	+	+	+
SQUAMOUS CELL CARCINOMA																									
FIBROMA			X																						
FIBROSARCOMA																									
LIPOMA																									
RESPIRATORY SYSTEM																									
LUNGS AND BRONCHI	+	+	+	+	+	+	+	+	+	+	+	+	+	+	+	+	+	+	+	+	+	+	+	+	+
SQUAMOUS CELL CARCINOMA, METASTAT																									
ADENOCARCINOMA, NOS, METASTATIC																									
ALVEOLAR/BRONCHIOLAR ADENOMA																									
ALVEOLAR/BRONCHIOLAR CARCINOMA																									
FOLLICULAR-CELL CARCINOMA, METAST																									
C-CELL CARCINOMA, METASTATIC																									
TRACHEA	+	+	+	+	+	+	+	+	+	+	+	+	+	+	+	+	+	+	+	+	+	+	+	+	+
LARYNX	N	N	N	N	N	N	N	N	N	N	N	N	N	N	N	N	N	N	N	N	N	N	N	N	N
FOLLICULAR-CELL CARCINOMA, INVASI																									
C-CELL CARCINOMA, INVASIVE																									
HEMATOPOIETIC SYSTEM																									
BONE MARROW	+	+	+	+	+	+	+	+	+	+	+	+	+	+	+	+	+	+	+	+	+	+	+	+	+
SPLEEN	+	+	+	+	+	+	+	+	+	+	+	+	+	+	+	+	+	+	+	+	+	+	+	+	+
LYMPH NODES	+	+	+	+	+	+	+	+	+	+	+	+	+	+	+	+	+	+	+	+	+	+	+	+	+
SQUAMOUS CELL CARCINOMA, METASTAT																									
ADENOCARCINOMA, NOS, METASTATIC																									
FOLLICULAR-CELL CARCINOMA, METAST																									
C-CELL CARCINOMA, METASTATIC																									
MALIG.LYMPHOMA, HISTIOCYTIC TYPE																									
THYMUS	+	+	+	+	-	+	-	+	+	+	+	+	-	+	+	+	-	+	+	+	-	-	+	-	-
CIRCULATORY SYSTEM																									
HEART	+	+	+	+	+	+	+	+	+	+	+	+	+	+	+	+	+	+	+	+	+	+	+	+	+
ADENOCARCINOMA, NOS, METASTATIC																									
DIGESTIVE SYSTEM																									
ORAL CAVITY	N	N	N	N	N	N	N	N	N	N	N	N	N	N	N	N	N	N	N	N	N	N	N	N	N
SQUAMOUS CELL PAPILLOMA																									
SQUAMOUS CELL CARCINOMA																									
SALIVARY GLAND	+	+	+	+	+	+	+	+	+	+	+	+	+	+	+	+	+	+	+	+	+	+	+	+	+
ADENOCARCINOMA, NOS																									
LIVER	+	+	+	+	+	+	+	+	+	+	+	+	+	+	+	+	+	+	+	+	+	+	+	+	+
NEOPLASTIC NODULE																									
HEPATOCELLULAR CARCINOMA																									
CORTICAL CARCINOMA, METASTATIC																									
MALIG.LYMPHOMA, HISTIOCYTIC TYPE																									
BILE DUCT	+	+	+	+	+	+	+	+	+	+	+	+	+	+	+	+	+	+	+	+	+	+	+	+	+
GALLBLADDER & COMMON BILE DUCT	N	N	N	N	N	N	N	N	N	N	N	N	N	N	N	N	N	N	N	N	N	N	N	N	N
PANCREAS	+	+	+	+	+	+	+	+	+	+	+	+	+	+	+	+	+	+	+	+	+	+	+	+	+
ACINAR-CELL ADENOMA																									
ACINAR-CELL CARCINOMA																									
ESOPHAGUS	+	+	+	+	+	+	+	+	+	+	+	+	+	+	+	+	+	+	+	+	+	+	+	+	+
STOMACH	+	+	+	+	+	+	+	+	+	+	+	+	+	+	+	+	+	+	+	+	+	+	+	+	+
ADENOMATOUS POLYP, NOS																									
CARCINOID TUMOR, NOS																									
LEIOMYOSARCOMA																									
ENDOMETRIAL STROMAL SARCOMA, META																									
SMALL INTESTINE	+	+	+	+	+	+	+	+	+	+	+	+	+	+	+	+	+	+	+	+	+	+	+	+	+
LARGE INTESTINE	+	+	+	+	+	+	+	+	+	+	+	+	+	+	+	+	+	+	+	+	+	+	+	+	+
ADENOMATOUS POLYP, NOS																									
LEIOMYOMA																									

HWBUI0001719

TABLE B4. INDIVIDUAL ANIMAL TUMOR PATHOLOGY OF FEMALE RATS IN THE LIFETIME FEED STUDY OF INTERMEDIATE-RANGE CHRYSOTILE ASBESTOS: INTERMEDIATE-RANGE (Continued)

ANIMAL NUMBER	07558	07661	07812	07944	08041	08163	08211	08301	08419	08514	08618	08746	08833	08941	09046	09125	09233	09361	09411	09519	09630	09741	09843	09912
WEEKS ON STUDY	100	112	101	116	104	123	136	100	106	101	108	116	109	116	115	112	113	116	111	110	102	114	113	112
URINARY SYSTEM																								
KIDNEY	+	+	+	+	+	+	+	+	+	+	+	+	+	+	+	+	+	+	+	+	+	+	+	+
CARCINOMA, NOS																								
LIPOSARCOMA																								
URINARY BLADDER	+	+	+	+	–	+	+	+	+	+	+	+	+	+	+	+	+	+	+	+	+	+	+	+
TRANSITIONAL-CELL PAPILLOMA																								
ENDOCRINE SYSTEM																								
PITUITARY	+	+	+	+	+	+	+	+	+	+	+	+	+	+	+	+	+	+	+	+	+	+	+	+
CARCINOMA, NOS														X			X							X
ADENOMA, NOS	X			X	X				X				X			X				X			X	
ADRENAL	+	+	+	+	+	+	+	+	+	+	+	+	+	+	+	+	+	+	+	+	+	+	+	+
CORTICAL ADENOMA																							X	
CORTICAL CARCINOMA																								
PHEOCHROMOCYTOMA												X												
THYROID	+	+	+	+	+	+	+	+	+	+	+	+	+	+	+	+	+	+	+	+	+	+	+	+
FOLLICULAR-CELL ADENOMA							X																	
FOLLICULAR-CELL CARCINOMA																								
C-CELL ADENOMA			X						X							X		X						
C-CELL CARCINOMA																								
PARATHYROID	+	+	+	+	+	+	+	+	–	+	+	+	+	+	+	+	+	+	–	+	+	+	+	+
ADENOMA, NOS																								
C-CELL CARCINOMA, INVASIVE																								
PANCREATIC ISLETS	+	+	+	+	+	+	+	+	+	+	+	+	+	+	+	+	+	+	+	+	+	+	+	+
ISLET-CELL ADENOMA																						X	X	
ISLET-CELL CARCINOMA																								
REPRODUCTIVE SYSTEM																								
MAMMARY GLAND	+	+	+	+	+	+	+	+	+	+	+	+	+	+	+	+	+	+	+	+	+	+	+	+
CARCINOMA, NOS					X																			
ADENOMA, NOS																						X		
ADENOCARCINOMA, NOS																								
FIBROADENOMA		X	X			X	X					X	X		X	X	X	X		X		X	X	
PREPUTIAL/CLITORAL GLAND	N	N	N	N	N	N	N	N	N	N	N	N	N	N	N	N	N	N	N	N	N	N	N	N
CARCINOMA, NOS		X		X		X												X						
SQUAMOUS CELL CARCINOMA																								
FEMALE EXTERNAL GENITALIA	N	N	N	N	N	N	N	N	N	N	N	N	N	N	N	N	N	N	N	N	N	N	N	N
FIBROSARCOMA, INVASIVE																								
VAGINA	N	N	N	N	N	N	N	N	N	N	N	N	N	N	N	N	N	N	N	N	N	N	N	N
FIBROSARCOMA																								
ENDOMETRIAL STROMAL SARCOMA																								
UTERUS	+	+	+	+	+	+	+	+	+	+	+	+	+	+	+	+	+	+	+	+	+	+	+	+
CARCINOMA, NOS																								
ADENOMA, NOS																								
FIBROMA					X																			
LEIOMYOMA																								
ENDOMETRIAL STROMAL POLYP				X																	X		X	
ENDOMETRIAL STROMAL SARCOMA																								
OVARY	+	+	+	+	+	+	+	+	+	+	+	+	+	+	+	+	+	+	+	+	+	+	+	+
PAPILLARY ADENOCARCINOMA																								
GRANULOSA-CELL TUMOR																								
NERVOUS SYSTEM																								
BRAIN	+	+	+	+	+	+	+	+	+	+	+	+	+	+	X	+	+	X	+	+	+	+	+	X
CARCINOMA, NOS, INVASIVE																								
ASTROCYTOMA																								
SPINAL CORD	N	N	N	N	N	N	N	N	N	N	N	N	N	N	N	N	N	N	N	N	N	N	N	N
OLIGODENDROGLIOMA																								
SPECIAL SENSE ORGANS																								
EYE	N	N	N	N	+	N	N	N	N	N	N	N	+	+	+	N	N	N	+	N	N	N	+	+
FIBROMA																								N
ZYMBAL GLAND	+	+	+	+	+	+	+	+	+	+	+	+	+	+	+	+	+	+	+	+	+	+	+	+
SQUAMOUS CELL CARCINOMA																								
MUSCULOSKELETAL SYSTEM																								
BONE	N	N	N	N	N	N	N	N	N	N	N	N	N	N	N	N	N	N	N	N	N	N	N	N
SQUAMOUS CELL CARCINOMA																								
ALL OTHER SYSTEMS																								
MULTIPLE ORGANS NOS	N	N	N	N	N	N	N	N	N	N	N	N	N	N	N	N	N	N	N	N	N	N	N	N
ALVEOLAR/BRONCHIOLAR CA, METASTAT																								
PAPILLARY ADENOCARCINOMA, METASTA																								
CORTICAL CARCINOMA, METASTATIC																								
MYELOMONOCYTIC LEUKEMIA																								
MONOCYTIC LEUKEMIA	X						X	X		X							X						
LEUKEMIA, MONONUCLEAR CELL																								
PERINEUM NOS																								
FIBROSARCOMA																								
FOOT NOS																								
FIBROMA																								

HWBUI0001720

TABLE B4. INDIVIDUAL ANIMAL TUMOR PATHOLOGY OF FEMALE RATS IN THE LIFETIME FEED STUDY OF INTERMEDIATE-RANGE CHRYSOTILE ASBESTOS: INTERMEDIATE-RANGE (Continued)

ANIMAL NUMBER	001	011	021	031	041	051	061	071	081	091	101	111	121	131	141	151	161	171	181	191	201	211	221	231	241
WEEKS ON STUDY	122	128	142	144	147	150	157	160	163	165	166	170	170	171	174	174	174	175	175	176	176	176	176	176	177
INTEGUMENTARY SYSTEM																									
SKIN	+	+	+	+	+	+	+	+	+	+	+	+	+	+	+	+	+	+	+	+	+	+	+	+	+
SQUAMOUS CELL PAPILLOMA																									
SQUAMOUS CELL CARCINOMA																									
BASAL-CELL CARCINOMA																									
KERATOACANTHOMA																									
SUBCUTANEOUS TISSUE	+	+	+	+	+	+	+	+	+	+	+	+	+	+	+	+	+	+	+	+	+	+	+	+	+
SQUAMOUS CELL CARCINOMA																				X					
FIBROMA																									
FIBROSARCOMA																									
LIPOMA																									
RESPIRATORY SYSTEM																									
LUNGS AND BRONCHI	+	+	+	+	+	+	+	+	+	+	+	+	+	+	+	+	+	+	+	+	+	+	+	+	+
SQUAMOUS CELL CARCINOMA, METASTAT																									
ADENOCARCINOMA, NOS, METASTATIC																									
ALVEOLAR/BRONCHIOLAR ADENOMA																									
ALVEOLAR/BRONCHIOLAR CARCINOMA																									
FOLLICULAR-CELL CARCINOMA, METAST																									
C-CELL CARCINOMA, METASTATIC																									
TRACHEA	+	+	+	+	+	+	+	+	+	+	+	+	+	+	+	+	+	+	+	+	+	+	+	+	+
LARYNX	N	N	N	N	N	N	N	N	N	N	N	N	N	N	N	N	N	N	N	N	N	N	N	N	N
FOLLICULAR-CELL CARCINOMA, INVASI																									
C-CELL CARCINOMA, INVASIVE																									
HEMATOPOIETIC SYSTEM																									
BONE MARROW	+	+	+	+	+	+	+	+	+	+	+	+	+	+	+	+	+	+	+	+	+	+	+	+	+
SPLEEN	+	+	+	+	+	+	+	+	+	+	+	+	+	+	+	+	+	+	+	+	+	+	+	+	+
LYMPH NODES	+	+	+	+	+	+	+	+	+	+	+	+	+	+	+	+	+	+	+	+	+	+	+	+	+
SQUAMOUS CELL CARCINOMA, METASTAT										X															
ADENOCARCINOMA, NOS, METASTATIC																									
FOLLICULAR-CELL CARCINOMA, METAST																									
C-CELL CARCINOMA, METASTATIC																									
MALIG.LYMPHOMA, HISTIOCYTIC TYPE																									
THYMUS	+	+	+	-	+	+	+	+	-	-	+	+	+	-	+	-	+	+	+	+	+	+	+	+	+
CIRCULATORY SYSTEM																									
HEART	+	+	+	+	+	+	+	+	+	+	+	+	+	+	+	+	+	+	+	+	+	+	+	+	+
ADENOCARCINOMA, NOS, METASTATIC																									
DIGESTIVE SYSTEM																									
ORAL CAVITY	N	N	N	N	N	N	N	N	N	N	N	N	N	N	N	N	N	N	N	N	N	N	N	N	N
SQUAMOUS CELL PAPILLOMA																									
SQUAMOUS CELL CARCINOMA																									
SALIVARY GLAND	+	+	+	+	+	+	+	+	+	+	+	+	+	+	+	+	+	+	+	+	+	+	+	+	+
ADENOCARCINOMA, NOS											X														
LIVER	+	+	+	+	+	+	+	+	+	+	+	+	+	+	+	+	+	+	+	+	+	+	+	+	+
NEOPLASTIC NODULE																									
HEPATOCELLULAR CARCINOMA																									
CORTICAL CARCINOMA, METASTATIC																									
MALIG.LYMPHOMA, HISTIOCYTIC TYPE																									
BILE DUCT	+	+	+	+	+	+	+	+	+	+	+	+	+	+	+	+	+	+	+	+	+	+	+	+	+
GALLBLADDER & COMMON BILE DUCT	N	N	N	N	N	N	N	N	N	N	N	N	N	N	N	N	N	N	N	N	N	N	N	N	N
PANCREAS	+	+	+	+	+	+	+	+	+	+	+	+	+	+	+	+	+	+	+	+	+	+	+	+	+
ACINAR-CELL ADENOMA																									
ACINAR-CELL CARCINOMA																									
ESOPHAGUS	+	+	+	+	+	+	+	+	+	+	+	+	+	+	+	+	+	+	+	+	+	+	+	+	+
STOMACH	+	+	+	+	+	+	+	+	+	+	+	+	+	+	+	+	+	+	+	+	+	+	+	+	+
ADENOMATOUS POLYP, NOS				X																					
CARCINOID TUMOR, NOS																		X							
LEIOMYOSARCOMA																									
ENDOMETRIAL STROMAL SARCOMA, META																									
SMALL INTESTINE	+	+	+	+	+	+	+	+	+	+	+	+	+	+	+	+	+	+	+	+	+	+	+	+	+
LARGE INTESTINE	+	+	+	+	+	+	+	+	+	+	+	+	+	+	+	+	+	+	+	+	+	+	+	+	+
ADENOMATOUS POLYP, NOS																									
LEIOMYOMA																									

HWBUI0001721

TABLE B4. INDIVIDUAL ANIMAL TUMOR PATHOLOGY OF FEMALE RATS IN THE LIFETIME FEED STUDY OF INTERMEDIATE-RANGE CHRYSOTILE ASBESTOS: INTERMEDIATE-RANGE (Continued)

ANIMAL NUMBER	100	101	102	103	105	105	106	107	108	109	110	111	112	113	114	115	116	117	118	119	120	121	122	123	124
WEEKS ON STUDY	112	122	042	146	117	130	137	130	132	138	139	116	118	107	144	140	146	130	136	134	144	035	146	161	111
URINARY SYSTEM																									
KIDNEY	+	+	+	+	+	+	+	+	+	+	+	+	+	+	+	+	+	+	+	+	+	+	+	+	+
CARCINOMA, NOS																									
LIPOSARCOMA																									
URINARY BLADDER	+	+	+	+	+	+	+	+	+	+	+	+	+	+	+	+	+	+	+	+	+	+	+	+	+
TRANSITIONAL-CELL PAPILLOMA																									
ENDOCRINE SYSTEM																									
PITUITARY	+	+	+	+	+	+	+	+	+	+	+	+	+	+	+	+	+	+	+	+	+	+	+	+	+
CARCINOMA, NOS						X			X	X	X			X	X		X		X				X	X	
ADENOMA, NOS																									
ADRENAL	+	+	+	+	+	+	+	+	+	+	+	+	+	+	+	+	+	+	+	+	+	+	+	+	+
CORTICAL ADENOMA									X									X							
CORTICAL CARCINOMA											X														
PHEOCHROMOCYTOMA				X															X					X	
THYROID	+	+	+	+	+	+	+	+	+	+	+	+	+	+	+	+	+	+	+	+	+	+	+	+	+
FOLLICULAR-CELL ADENOMA																					X				
FOLLICULAR-CELL CARCINOMA						X											X								
C-CELL ADENOMA							X		X														X		
C-CELL CARCINOMA				X	X			X	X	X									X						
PARATHYROID	+	+	+	+	+	+	+	+	-	+	+	+	+	+	+	+	+	-	+	+	+	+	+	+	+
ADENOMA, NOS																									
C-CELL CARCINOMA, INVASIVE																									
PANCREATIC ISLETS	+	+	+	+	+	+	+	+	+	+	+	+	+	+	+	+	+	+	+	+	+	+	+	+	+
ISLET-CELL ADENOMA																		X	X						
ISLET-CELL CARCINOMA																									
REPRODUCTIVE SYSTEM																									
MAMMARY GLAND	+	+	+	+	+	+	+	+	+	+	+	+	+	+	+	+	+	+	+	+	+	N	+	+	+
CARCINOMA, NOS									X																
ADENOMA, NOS																									
ADENOCARCINOMA, NOS																									
FIBROADENOMA	X					X	X			X	X				X		X	X	X		X		X		X
PREPUTIAL/CLITORAL GLAND	N	N	N	N	N	N	N	N	N	N	N	N	N	N	N	N	N	N	N	N	N	N	N	N	N
CARCINOMA, NOS																								X	
SQUAMOUS CELL CARCINOMA																									
FEMALE EXTERNAL GENITALIA	N	N	N	N	N	N	N	N	N	N	N	N	N	N	N	N	N	N	N	N	N	N	N	N	N
FIBROSARCOMA, INVASIVE																									
VAGINA	N	N	N	N	N	N	N	N	N	N	N	N	N	N	N	N	N	N	N	N	N	N	N	N	N
FIBROSARCOMA																									
ENDOMETRIAL STROMAL SARCOMA																									
UTERUS	+	-	+	+	+	+	+	+	+	+	+	+	+	+	+	+	+	+	+	+	+	+	+	+	+
CARCINOMA, NOS																									
ADENOMA, NOS																									
FIBROMA																									
LEIOMYOMA																					X				
ENDOMETRIAL STROMAL POLYP																		X					X		
ENDOMETRIAL STROMAL SARCOMA																									
OVARY	+	-	+	+	+	+	+	+	+	+	+	+	+	+	+	+	+	+	+	+	+	+	+	+	+
PAPILLARY ADENOCARCINOMA																									
GRANULOSA-CELL TUMOR																									
NERVOUS SYSTEM																									
BRAIN	+	+	+	+	+	+	+	+	+	+	+	+	+	+	+	+	+	+	+	+	+	+	+	+	+
CARCINOMA, NOS, INVASIVE																								X	
ASTROCYTOMA																									
SPINAL CORD	N	N	+	N	N	N	N	N	N	N	N	N	N	N	N	N	N	N	N	N	N	N	N	N	N
OLIGODENDROGLIOMA			X																						
SPECIAL SENSE ORGANS																									
EYE	N	N	N	+	N	N	N	+	+	+	N	N	+	N	+	N	+	N	N	+	+	N	N	N	N
FIBROMA								X																	
ZYMBAL GLAND	+	+	+	+	+	+	+	+	+	+	+	+	+	+	+	+	+	+	+	+	+	+	+	+	+
SQUAMOUS CELL CARCINOMA															X										
MUSCULOSKELETAL SYSTEM																									
BONE	N	N	N	N	N	N	N	N	N	N	N	N	N	N	N	N	N	N	N	N	N	N	N	N	N
SQUAMOUS CELL CARCINOMA																									
ALL OTHER SYSTEMS																									
MULTIPLE ORGANS NOS	N	N	N	N	N	N	N	N	N	N	N	N	N	N	N	N	N	N	N	N	N	N	N	N	N
ALVEOLAR/BRONCHIOLAR CA, METASTAT																									
PAPILLARY ADENOCARCINOMA, METASTA																									
CORTICAL CARCINOMA, METASTATIC																									
MYELOMONOCYTIC LEUKEMIA																									
MONOCYTIC LEUKEMIA	X	X			X			X		X	X	X							X				X		
LEUKEMIA, MONONUCLEAR CELL																				X					
PERINEUM NOS																									
FIBROSARCOMA																									
FOOT NOS																									
FIBROMA																									

HWBUI0001722

TABLE B4. INDIVIDUAL ANIMAL TUMOR PATHOLOGY OF FEMALE RATS IN THE LIFETIME FEED STUDY OF INTERMEDIATE-RANGE CHRYSOTILE ASBESTOS: INTERMEDIATE-RANGE (Continued)

ANIMAL NUMBER	125	126	127	128	129	130	131	132	133	134	135	136	137	138	139	140	141	142	143	144	145	146	147	148	149
WEEKS ON STUDY	146	146	119	120	136	097	119	166	069	140	082	145	146	141	137	161	120	096	118	113	145	129	118	130	115
INTEGUMENTARY SYSTEM																									
SKIN	+	+	+	+	+	+	+	+	+	+	+	+	+	+	+	+	+	+	+	+	+	+	+	+	+
SQUAMOUS CELL PAPILLOMA																									
SQUAMOUS CELL CARCINOMA																									
BASAL-CELL CARCINOMA																									
KERATOACANTHOMA																									
SUBCUTANEOUS TISSUE	+	+	+	+	+	+	+	+	+	+	+	+	+	+	+	+	+	+	+	+	+	+	+	+	+
SQUAMOUS CELL CARCINOMA																X	X								
FIBROMA																									
FIBROSARCOMA																									
LIPOMA																									
RESPIRATORY SYSTEM																									
LUNGS AND BRONCHI	+	+	+	+	+	+	+	+	+	+	+	+	+	+	+	+	+	+	+	+	+	+	+	+	+
SQUAMOUS CELL CARCINOMA, METASTAT																									
ADENOCARCINOMA, NOS, METASTATIC																									
ALVEOLAR/BRONCHIOLAR ADENOMA																									
ALVEOLAR/BRONCHIOLAR CARCINOMA						X																			
FOLLICULAR-CELL CARCINOMA, METAST																									
C-CELL CARCINOMA, METASTATIC																									
TRACHEA	+	+	+	+	+	+	+	+	+	+	+	+	+	+	+	+	+	+	+	+	+	+	+	+	+
LARYNX	N	N	N	N	N	N	N	N	N	N	N	N	N	N	N	N	N	N	N	N	N	N	N	N	N
FOLLICULAR-CELL CARCINOMA, INVASI																									
C-CELL CARCINOMA, INVASIVE																									
HEMATOPOIETIC SYSTEM																									
BONE MARROW	+	+	+	+	+	+	+	+	+	+	+	+	+	+	+	+	+	+	+	+	+	+	+	+	+
SPLEEN	+	+	+	+	+	+	+	+	+	+	+	+	+	+	+	+	+	+	+	+	+	+	+	+	+
LYMPH NODES	+	+	+	+	+	+	+	+	+	+	+	+	+	+	+	+	+	+	+	+	+	+	+	+	+
SQUAMOUS CELL CARCINOMA, METASTAT					X																				
ADENOCARCINOMA, NOS, METASTATIC																									
FOLLICULAR-CELL CARCINOMA, METAST																									
C-CELL CARCINOMA, METASTATIC																									
MALIG.LYMPHOMA, HISTIOCYTIC TYPE																									
THYMUS	-	+	+	+	-	-	+	+	+	+	+	+	+	-	+	+	+	+	+	-	+	-	+	+	+
CIRCULATORY SYSTEM																									
HEART	+	+	+	+	+	+	+	+	+	+	+	+	+	+	+	+	+	+	+	+	+	+	+	+	+
ADENOCARCINOMA, NOS, METASTATIC																									
DIGESTIVE SYSTEM																									
ORAL CAVITY	N	N	N	N	N	N	N	N	N	N	N	N	N	N	N	N	N	N	N	N	N	N	N	N	N
SQUAMOUS CELL PAPILLOMA																									
SQUAMOUS CELL CARCINOMA																									
SALIVARY GLAND	+	+	+	+	+	+	+	+	+	+	-	+	+	+	+	+	+	+	+	+	+	+	+	+	+
ADENOCARCINOMA, NOS																									
LIVER	+	+	+	+	+	+	+	+	+	+	+	+	+	+	+	+	+	+	+	+	+	+	+	+	+
NEOPLASTIC NODULE																									
HEPATOCELLULAR CARCINOMA																									
CORTICAL CARCINOMA, METASTATIC																									
MALIG.LYMPHOMA, HISTIOCYTIC TYPE																									
BILE DUCT	+	+	+	+	+	+	+	+	+	+	+	+	+	+	+	+	+	+	+	+	+	+	+	+	+
GALLBLADDER & COMMON BILE DUCT	N	N	N	N	N	N	N	N	N	N	N	N	N	N	N	N	N	N	N	N	N	N	N	N	N
PANCREAS	+	+	+	+	+	+	+	+	+	+	+	+	+	+	+	+	+	+	+	+	+	+	+	+	+
ACINAR-CELL ADENOMA		X																							
ACINAR-CELL CARCINOMA																									
ESOPHAGUS	+	+	+	+	+	+	+	+	+	+	+	+	+	+	+	+	+	+	+	+	+	+	+	+	+
STOMACH	+	+	+	+	+	+	+	+	+	+	+	+	+	+	+	+	+	+	+	+	+	+	+	+	+
ADENOMATOUS POLYP, NOS																									
CARCINOID TUMOR, NOS																									
LEIOMYOSARCOMA																									
ENDOMETRIAL STROMAL SARCOMA, META																									
SMALL INTESTINE	+	+	+	+	+	+	+	+	+	+	+	+	+	+	+	+	+	+	+	+	+	+	+	+	+
LARGE INTESTINE	+	+	+	+	+	+	+	+	+	+	+	+	+	+	+	+	+	+	+	+	+	+	+	+	+
ADENOMATOUS POLYP, NOS																									
LEIOMYOMA																									

HWBUI0001723

TABLE B4. INDIVIDUAL ANIMAL TUMOR PATHOLOGY OF FEMALE RATS IN THE LIFETIME FEED STUDY OF INTERMEDIATE-RANGE CHRYSOTILE ASBESTOS: INTERMEDIATE-RANGE (Continued)

ANIMAL NUMBER	1 2 5	1 2 6	1 2 7	1 2 8	1 2 9	1 3 0	1 3 1	1 3 2	1 3 3	1 3 4	1 3 5	1 3 6	1 3 7	1 3 8	1 3 9	1 4 0	1 4 1	1 4 2	1 4 3	1 4 4	1 4 5	1 4 6	1 4 7	1 4 8	1 4 9
WEEKS ON STUDY	1 4 6	1 4 6	1 1 9	1 2 0	1 3 6	0 9 7	1 1 9	1 1 6	0 6 9	1 4 0	0 8 2	1 4 5	1 4 6	1 1 6	1 3 7	1 1 6	1 2 0	0 9 6	1 1 8	1 1 3	1 4 5	1 2 9	1 1 0	1 3 0	1 1 5
URINARY SYSTEM																									
KIDNEY	+	+	+	+	+	+	+	+	+	+	+	+	+	+	+	+	+	+	+	+	+	+	+	+	+
CARCINOMA, NOS																									
LIPOSARCOMA																									
URINARY BLADDER	+	+	+	+	+	+	+	+	+	+	+	+	+	+	+	+	+	+	+	+	+	+	+	+	+
TRANSITIONAL-CELL PAPILLOMA																									
ENDOCRINE SYSTEM																									
PITUITARY	+	+	+	+	+	+	+	+	+	+	+	+	+	+	+	+	+	+	+	+	+	+	+	+	+
CARCINOMA, NOS																	X		X						
ADENOMA, NOS	X				X		X	X		X		X	X	X	X							X		X	
ADRENAL	+	+	+	+	+	+	+	+	+	+	+	+	+	+	+	+	+	+	+	+	+	+	+	+	+
CORTICAL ADENOMA																									
CORTICAL CARCINOMA																						X			
PHEOCHROMOCYTOMA													X			X					X				
THYROID	+	+	+	+	+	+	+	+	+	+	+	+	+	+	+	+	+	+	+	+	+	+	+	+	+
FOLLICULAR-CELL ADENOMA					X							X					X								
FOLLICULAR-CELL CARCINOMA								X																	
C-CELL ADENOMA		X																							
C-CELL CARCINOMA								X					X		X		X			X					
PARATHYROID	+	+	-	+	+	+	+	-	+	+	+	+	+	+	+	+	+	+	+	+	+	+	+	+	+
ADENOMA, NOS																									
C-CELL CARCINOMA, INVASIVE																									
PANCREATIC ISLETS	+	+	+	+	+	+	+	+	+	+	+	+	+	+	+	+	+	+	+	+	+	+	+	+	+
ISLET-CELL ADENOMA																									
ISLET-CELL CARCINOMA																									
REPRODUCTIVE SYSTEM																									
MAMMARY GLAND	+	+	+	+	+	+	+	+	+	+	+	+	+	+	+	+	+	+	+	+	+	+	+	+	+
CARCINOMA, NOS																			X						
ADENOMA, NOS	X				X																				
ADENOCARCINOMA, NOS																									
FIBROADENOMA	X	X		X	X		X	X		X		X			X	X	X	X		X	X	X		X	X
PREPUTIAL/CLITORAL GLAND	N	N	N	N	N	N	N	N	N	N	N	N	N	N	N	N	N	N	N	N	N	N	N	N	N
CARCINOMA, NOS													X			X									
SQUAMOUS CELL CARCINOMA																									X
FEMALE EXTERNAL GENITALIA	N	N	N	N	N	N	N	N	N	N	N	N	N	N	N	N	N	N	N	N	N	N	N	N	N
FIBROSARCOMA, INVASIVE																									
VAGINA	N	N	N	N	N	N	N	N	N	N	N	N	N	N	N	N	N	N	N	N	N	N	N	N	N
FIBROSARCOMA																									
ENDOMETRIAL STROMAL SARCOMA																									
UTERUS	+	+	+	+	+	+	+	+	+	+	+	+	+	+	+	+	+	+	+	+	+	+	+	+	+
CARCINOMA, NOS																									
ADENOMA, NOS																									
FIBROMA																									
LEIOMYOMA																									
ENDOMETRIAL STROMAL POLYP						X		X			X				X			X							
ENDOMETRIAL STROMAL SARCOMA																									
OVARY	+	+	+	+	+	+	+	+	+	+	+	+	+	+	+	+	+	+	+	+	+	+	+	+	+
PAPILLARY ADENOCARCINOMA									X																
GRANULOSA-CELL TUMOR																									
NERVOUS SYSTEM																									
BRAIN	+	+	+	+	+	+	+	+	+	+	+	+	+	+	+	+	+	+	+	+	+	+	+	+	+
CARCINOMA, NOS, INVASIVE																	X		X						
ASTROCYTOMA			X																						
SPINAL CORD	N	N	N	N	N	N	N	N	N	N	N	N	N	N	N	N	N	N	N	N	N	N	N	N	N
OLIGODENDROGLIOMA																									
SPECIAL SENSE ORGANS																									
EYE	+	+	N	N	N	N	N	N	N	+	N	+	N	N	+	N	N	N	N	N	+	+	N	+	N
FIBROMA																									
ZYMBAL GLAND	+	+	+	+	+	+	+	+	+	+	+	+	+	+	+	+	+	+	+	+	+	+	+	+	+
SQUAMOUS CELL CARCINOMA																									
MUSCULOSKELETAL SYSTEM																									
BONE	N	N	N	N	N	N	N	N	N	N	N	N	N	N	N	N	N	N	N	N	N	N	N	N	N
SQUAMOUS CELL CARCINOMA																									
ALL OTHER SYSTEMS																									
MULTIPLE ORGANS NOS	N	N	N	N	N	N	N	N	N	N	N	N	N	N	N	N	N	N	N	N	N	N	N	N	N
ALVEOLAR/BRONCHIOLAR CA, METASTAT						X																			
PAPILLARY ADENOCARCINOMA, METASTA										X															
CORTICAL CARCINOMA, METASTATIC																									
MYELOMONOCYTIC LEUKEMIA											X	X		X						X			X		X
MONOCYTIC LEUKEMIA																									
LEUKEMIA, MONONUCLEAR CELL																									
PERINEUM NOS																									
FIBROSARCOMA																									
FOOT NOS																									
FIBROMA																									

HWBUI0001724

TABLE B4. INDIVIDUAL ANIMAL TUMOR PATHOLOGY OF FEMALE RATS IN THE LIFETIME FEED STUDY OF INTERMEDIATE-RANGE CHRYSOTILE ASBESTOS: INTERMEDIATE-RANGE (Continued)

ANIMAL NUMBER	150	151	152	153	154	155	156	157	158	159	160	161	162	163	164	165	166	167	168	169	170	171	172	173	174
WEEKS ON STUDY	136	122	127	121	118	119	103	138	129	108	108	094	103	115	111	143	134	146	132	116	136	136	115	110	105
INTEGUMENTARY SYSTEM																									
SKIN	+	+	+	+	+	+	+	+	+	+	+	+	+	+	+	+	+	+ X	+	+ X	+	+	+	+	+
SQUAMOUS CELL PAPILLOMA																									
SQUAMOUS CELL CARCINOMA																									
BASAL-CELL CARCINOMA																									
KERATOACANTHOMA																									
SUBCUTANEOUS TISSUE	+	+	+	+	+	+	+	+	+	+	+	+	+	+	+	+	+	+	+	+	+	+	+	+	+
SQUAMOUS CELL CARCINOMA									+ X																
FIBROMA						+ X																			
FIBROSARCOMA																									
LIPOMA																									
RESPIRATORY SYSTEM																									
LUNGS AND BRONCHI	+	+	+	+	+	+	+	+	+	+	+	+	+	+	+	+	+	+	+	+	+	+	+	+	+
SQUAMOUS CELL CARCINOMA, METASTAT																									
ADENOCARCINOMA, NOS, METASTATIC																									
ALVEOLAR/BRONCHIOLAR ADENOMA																									
ALVEOLAR/BRONCHIOLAR CARCINOMA																									
FOLLICULAR-CELL CARCINOMA, METAST																									
C-CELL CARCINOMA, METASTATIC																					X				
TRACHEA	+	+	+	+	+	+	+	+	+	+	+	+	+	+	+	+	+	+	+	+	+	+	+	+	+
LARYNX	N	N	N	N	N	N	N	N	N	N	N	N	N	N	N	N	N	N	N	N	N	N	N	N	N
FOLLICULAR-CELL CARCINOMA, INVASI																									
C-CELL CARCINOMA, INVASIVE																									
HEMATOPOIETIC SYSTEM																									
BONE MARROW	+	+	+	+	+	+	+	+	+	+	+	+	+	+	+	+	+	+	+	+	-	+	+	+	+
SPLEEN	+	+	+	+	+	+	+	+	+	+	+	+	+	+	+	+	+	+	+	+	+	+	+	+	+
LYMPH NODES	+	+	+	+	+	+	+	+	+	+	+	+	+	+	+	+	+	+	+	+	+	+	+	+	+
SQUAMOUS CELL CARCINOMA, METASTAT																									
ADENOCARCINOMA, NOS, METASTATIC																									
FOLLICULAR-CELL CARCINOMA, METAST																									
C-CELL CARCINOMA, METASTATIC																					X				
MALIG.LYMPHOMA, HISTIOCYTIC TYPE																									
THYMUS	+	+	-	+	+	+	-	+	+	+	+	+	+	+	+	-	+	+	+	+	-	+	-	+	+
CIRCULATORY SYSTEM																									
HEART	+	+	+	+	+	+	+	+	+	+	+	+	+	+	+	+	+	+	+	+	+	+	+	+	+
ADENOCARCINOMA, NOS, METASTATIC																									
DIGESTIVE SYSTEM																									
ORAL CAVITY	N	N	N	N	N	N	N	N	N	N	N	N	N	N	N	N	N	N	N	N	N	N	N	N	N
SQUAMOUS CELL PAPILLOMA																									
SQUAMOUS CELL CARCINOMA																									
SALIVARY GLAND	+	+	+	+	+	+	+	+	+	+	+	+	+	+	+	+	+	+	+	+	+	+	+	+	+
ADENOCARCINOMA, NOS																									
LIVER	+	+	+	+	+	+	+	+	+	+	+	+	+	+	+	+	+	+	+	+	+	+	+	+	+
NEOPLASTIC NODULE																									
HEPATOCELLULAR CARCINOMA																									
CORTICAL CARCINOMA, METASTATIC																									
MALIG.LYMPHOMA, HISTIOCYTIC TYPE																									
BILE DUCT	+	+	+	+	+	+	+	+	+	+	+	+	+	+	+	+	+	+	+	+	+	+	+	+	+
GALLBLADDER & COMMON BILE DUCT	N	N	N	N	N	N	N	N	N	N	N	N	N	N	N	N	N	N	N	N	N	N	N	N	N
PANCREAS	+	+	+	+	+	+	+	+	+	+	+	+	+	+	+	+	+	+	+	+	+	+	+	+	+
ACINAR-CELL ADENOMA																									
ACINAR-CELL CARCINOMA																									
ESOPHAGUS	+	+	+	+	+	+	+	+	+	+	+	+	+	+	+	+	+	+	+	+	+	+	+	+	+
STOMACH	+	+	+	+	+	+	+	+	+	+	+	+	+	+	+	+	+	+	+	+	+	+	+	+	+
ADENOMATOUS POLYP, NOS																									
CARCINOID TUMOR, NOS																									
LEIOMYOSARCOMA																									
ENDOMETRIAL STROMAL SARCOMA, META																									
SMALL INTESTINE	+	+	+	+	+	+	+	+	+	+	+	+	+	+	+	+	+	+	+	+	+	+	+	+	+
LARGE INTESTINE	+	+	+	+	+	+	+	+	+	+	+	+	+	+	+	+	+	+	+	+	+	+	+	+	+
ADENOMATOUS POLYP, NOS																									
LEIOMYOMA																							X		

HWBUI0001725

TABLE B4. INDIVIDUAL ANIMAL TUMOR PATHOLOGY OF FEMALE RATS IN THE LIFETIME FEED STUDY OF INTERMEDIATE-RANGE CHRYSOTILE ASBESTOS: INTERMEDIATE-RANGE (Continued)

ANIMAL NUMBER	50	51	52	53	54	55	56	57	58	59	60	61	62	63	64	65	66	67	68	69	70	71	72	73	74
WEEKS ON STUDY	136	122	077	121	118	119	103	138	125	108	108	045	083	130	136	111	143	134	146	135	126	085	136	118	095
URINARY SYSTEM																									
KIDNEY	+	+	+	+	+	+	+	+	+	+	+	+	+	+	+	+	+	+	+	+	+	+	+	+	+
CARCINOMA, NOS			X																						
LIPOSARCOMA																									
URINARY BLADDER	+	+	+	+	+	+	+	+	+	+	+	+	+	+	+	+	+	+	+	+	+	+	+	+	+
TRANSITIONAL-CELL PAPILLOMA																									
ENDOCRINE SYSTEM																									
PITUITARY	+	+	+	+	+	+	+	+	+	+	+	-	+	+	+	+	+	+	+	+	+	+	+	+	+
CARCINOMA, NOS																									
ADENOMA, NOS		X		X			X										X	X	X				X		
ADRENAL	+	+	+	+	+	+	+	+	+	+	+	+	+	+	+	+	+	+	+	+	+	+	+	+	+
CORTICAL ADENOMA								X		X				X											
CORTICAL CARCINOMA																									
PHEOCHROMOCYTOMA																			X				X		
THYROID	+	+	+	+	+	+	+	+	+	+	+	+	+	+	+	+	+	+	+	+	+	+	+	+	+
FOLLICULAR-CELL ADENOMA																									X
FOLLICULAR-CELL CARCINOMA								X																	
C-CELL ADENOMA									X																
C-CELL CARCINOMA						X								X	X					X					
PARATHYROID	+	+	+	+	+	+	+	-	+	+	+	+	+	+	+	+	+	+	+	+	+	+	+	+	+
ADENOMA, NOS																									
C-CELL CARCINOMA, INVASIVE																									
PANCREATIC ISLETS	+	+	+	+	+	+	+	+	+	+	+	+	+	+	+	+	+	+	+	+	+	+	+	+	+
ISLET-CELL ADENOMA																									
ISLET-CELL CARCINOMA																									
REPRODUCTIVE SYSTEM																									
MAMMARY GLAND	+	+	+	+	+	+	+	+	+	+	+	+	+	+	+	+	+	+	+	+	+	+	+	+	+
CARCINOMA, NOS																									
ADENOMA, NOS																									
ADENOCARCINOMA, NOS																									
FIBROADENOMA	X					X		X			X						X				X		X	X
PREPUTIAL/CLITORAL GLAND	M	M	M	M	M	M	M	M	M	M	M	M	M	M	M	M	M	M	M	M	M	M	M	M	M
CARCINOMA, NOS																			X						
SQUAMOUS CELL CARCINOMA														X											
FEMALE EXTERNAL GENITALIA	M	M	M	M	M	M	M	M	M	M	M	M	M	M	M	M	M	M	M	M	M	M	M	M	M
FIBROSARCOMA, INVASIVE																									
VAGINA	M	M	M	M	M	M	M	M	M	M	M	M	M	M	M	M	M	M	M	M	M	M	M	M	M
FIBROSARCOMA																									
ENDOMETRIAL STROMAL SARCOMA											X						X								
UTERUS	+	+	+	+	+	+	+	+	+	+	+	+	+	+	+	+	+	+	+	+	+	+	+	+	+
CARCINOMA, NOS																									
ADENOMA, NOS				X																					
FIBROMA																									
LEIOMYOMA																	X								
ENDOMETRIAL STROMAL POLYP															X										
ENDOMETRIAL STROMAL SARCOMA																	X								
OVARY	+	+	+	+	+	+	+	+	+	+	+	+	+	+	+	+	+	+	+	+	+	+	+	+	+
PAPILLARY ADENOCARCINOMA																									
GRANULOSA-CELL TUMOR																									
NERVOUS SYSTEM																									
BRAIN	+	+	+	+	+	+	+	+	+	+	+	+	+	+	+	+	+	+	+	+	+	+	+	+	+
CARCINOMA, NOS, INVASIVE																									
ASTROCYTOMA				X						X															
SPINAL CORD	M	M	M	M	M	M	M	M	M	M	M	M	M	M	M	M	M	M	M	M	M	M	M	M	M
OLIGODENDROGLIOMA																									
SPECIAL SENSE ORGANS																									
EYE	+	+	+	+	M	+	M	+	+	+	M	+	M	M	+	M	M	M	+	M	M	M	M	M	M
FIBROMA																									
ZYMBAL GLAND	+	+	+	+	+	+	+	+	+	+	+	+	+	+	+	+	+	+	+	+	+	+	+	+	+
SQUAMOUS CELL CARCINOMA																									
MUSCULOSKELETAL SYSTEM																									
BONE	M	M	M	M	M	M	M	M	M	M	M	M	M	M	M	M	M	M	M	M	M	M	M	M	M
SQUAMOUS CELL CARCINOMA																									
ALL OTHER SYSTEMS																									
MULTIPLE ORGANS NOS	M	M	M	M	M	M	M	M	M	M	M	M	M	M	M	M	M	M	M	M	M	M	M	M	M
ALVEOLAR/BRONCHIOLAR CA, METASTAT																									
PAPILLARY ADENOCARCINOMA, METASTA																									
CORTICAL CARCINOMA, METASTATIC																									
MYELOMONOCYTIC LEUKEMIA																		X							
MONOCYTIC LEUKEMIA				X								X	X		X							X	X	X	X
LEUKEMIA, MONONUCLEAR CELL																									
PERINEUM NOS																									
FIBROSARCOMA																									
FOOT NOS																									
FIBROMA																									

HWBUI0001726

TABLE B4. INDIVIDUAL ANIMAL TUMOR PATHOLOGY OF FEMALE RATS IN THE LIFETIME FEED STUDY OF INTERMEDIATE-RANGE CHRYSOTILE ASBESTOS: INTERMEDIATE-RANGE (Continued)

ANIMAL NUMBER	175	176	177	178	179	180	181	182	183	184	185	186	187	188	189	190	191	192	193	194	195	196	197	198	199
WEEKS ON STUDY	104	124	121	146	116	142	99	126	137	121	97	117	118	113	115	085	097	146	140	125	098	142	114	133	118
INTEGUMENTARY SYSTEM																									
SKIN	+	+	+	+	+	+	+	+	+	+	+	+	+	+	+	+	+	+	+	+	+	+	+	+	+
SQUAMOUS CELL PAPILLOMA																									
SQUAMOUS CELL CARCINOMA																									
BASAL-CELL CARCINOMA									X																
KERATOACANTHOMA																									
SUBCUTANEOUS TISSUE	+	+	+	+	+	+	+	+	+	+	+	+	+	+	+	+	+	+	+	+	+	+	+	+	+
SQUAMOUS CELL CARCINOMA																	X								
FIBROMA																									
FIBROSARCOMA															X										
LIPOMA																									
RESPIRATORY SYSTEM																									
LUNGS AND BRONCHI	+	+	+	+	+	+	+	+	+	+	+	+	+	+	+	+	+	+	+	+	+	+	+	+	+
SQUAMOUS CELL CARCINOMA, METASTAT																									
ADENOCARCINOMA, NOS, METASTATIC																									
ALVEOLAR/BRONCHIOLAR ADENOMA																									
ALVEOLAR/BRONCHIOLAR CARCINOMA																									
FOLLICULAR-CELL CARCINOMA, METAST																									
C-CELL CARCINOMA, METASTATIC																									
TRACHEA	+	+	+	+	+	+	+	+	+	+	+	+	+	+	+	+	+	+	+	+	+	+	+	+	+
LARYNX	M	M	M	M	M	M	M	M	M	M	M	M	M	M	M	M	M	M	M	M	M	M	M	M	M
FOLLICULAR-CELL CARCINOMA, INVASI																									
C-CELL CARCINOMA, INVASIVE																									
HEMATOPOIETIC SYSTEM																									
BONE MARROW	+	+	+	+	+	+	+	+	+	+	+	+	+	+	+	+	+	+	+	+	+	+	+	+	+
SPLEEN	+	+	+	+	+	+	+	+	+	+	+	+	+	+	+	+	+	+	+	+	+	+	+	+	+
LYMPH NODES	+	+	+	+	+	+	+	+	+	+	+	+	+	+	+	+	+	+	+	+	+	+	+	+	+
SQUAMOUS CELL CARCINOMA, METASTAT																									
ADENOCARCINOMA, NOS, METASTATIC																									
FOLLICULAR-CELL CARCINOMA, METAST																									
C-CELL CARCINOMA, METASTATIC																									
MALIG.LYMPHOMA, HISTIOCYTIC TYPE																									
THYMUS	+	+	+	-	+	+	+	+	-	+	+	+	-	-	+	+	+	-	+	+	+	+	+	+	-
CIRCULATORY SYSTEM																									
HEART	+	+	+	+	+	+	+	+	+	+	+	+	+	+	+	+	+	+	+	+	+	+	+	+	+
ADENOCARCINOMA, NOS, METASTATIC																									
DIGESTIVE SYSTEM																									
ORAL CAVITY	M	M	M	M	M	M	M	M	M	M	M	M	M	M	M	M	M	M	M	M	M	M	M	M	M
SQUAMOUS CELL PAPILLOMA																									
SQUAMOUS CELL CARCINOMA																									
SALIVARY GLAND	+	+	+	+	+	+	+	+	+	+	+	+	+	+	+	+	+	+	+	+	+	+	+	+	+
ADENOCARCINOMA, NOS																									
LIVER	+	+	+	+	+	+	+	+	+	+	+	+	+	+	+	+	+	+	+	+	+	+	+	+	+
NEOPLASTIC NODULE																				X					
HEPATOCELLULAR CARCINOMA																									
CORTICAL CARCINOMA, METASTATIC																									
MALIG.LYMPHOMA, HISTIOCYTIC TYPE																									
BILE DUCT	+	+	+	+	+	+	+	+	+	+	+	+	+	+	+	+	+	+	+	+	+	+	+	+	+
GALLBLADDER & COMMON BILE DUCT	M	M	M	M	M	M	M	M	M	M	M	M	M	M	M	M	M	M	M	M	M	M	M	M	M
PANCREAS	+	+	+	+	+	+	+	+	+	+	+	+	+	+	+	+	+	+	+	+	+	+	+	+	+
ACINAR-CELL ADENOMA																									
ACINAR-CELL CARCINOMA																									
ESOPHAGUS	+	+	+	+	+	+	+	+	+	+	+	+	+	+	+	+	+	+	+	+	+	+	+	+	+
STOMACH	+	+	+	+	+	+	+	+	+	+	+	+	+	+	+	+	+	+	+	+	+	+	+	+	+
ADENOMATOUS POLYP, NOS																									
CARCINOID TUMOR, NOS																									
LEIOMYOSARCOMA																									
ENDOMETRIAL STROMAL SARCOMA, META																									
SMALL INTESTINE	+	+	+	+	+	+	+	+	+	+	+	+	+	+	+	+	+	+	+	+	+	+	+	+	+
LARGE INTESTINE	+	+	+	+	+	+	+	+	+	+	+	+	+	+	+	+	+	+	+	+	+	+	+	+	+
ADENOMATOUS POLYP, NOS																									
LEIOMYOMA																									

HWBUI0001727

TABLE B4. INDIVIDUAL ANIMAL TUMOR PATHOLOGY OF FEMALE RATS IN THE LIFETIME FEED STUDY OF INTERMEDIATE-RANGE CHRYSOTILE ASBESTOS: INTERMEDIATE-RANGE (Continued)

ANIMAL NUMBER	17504	17606	17721	17846	17916	18042	18109	18226	18337	18421	18507	18617	18718	18813	18885	18915	19041	19112	19246	19340	19425	19585	19647	19814	19949
WEEKS ON STUDY	104	126	121	146	116	142	099	126	137	121	097	117	118	113	115	085	097	146	140	125	098	142	114	133	118
URINARY SYSTEM																									
KIDNEY	+	+	+	+	+	+	+	+	+	+	+	+	+	+	+	+	+	+	+	+	+	+	+	+	+
CARCINOMA, NOS					X								X							X					
LIPOSARCOMA																									X
URINARY BLADDER	+	+	+	+	+	+	+	+	+	+	+	+	+	+	+	+	+	+	+	+	+	+	+	+	+
TRANSITIONAL-CELL PAPILLOMA																									
ENDOCRINE SYSTEM																									
PITUITARY	+	+	+	+	+	+	+	+	+	+	+	+	+	+	+	+	+	+	+	+	+	+	+	+	+
CARCINOMA, NOS					X								X							X					
ADENOMA, NOS	X	X		X		X			X					X			X		X				X	X
ADRENAL	+	+	+	+	+	+	+	+	+	+	+	+	+	+	+	+	+	+	+	+	+	+	+	+	+
CORTICAL ADENOMA													X												
CORTICAL CARCINOMA																									
PHEOCHROMOCYTOMA									X															X	
THYROID	+	+	+	+	+	+	+	+	+	+	+	+	+	+	+	+	+	+	+	+	+	+	+	+	+
FOLLICULAR-CELL ADENOMA																									
FOLLICULAR-CELL CARCINOMA																									
C-CELL ADENOMA		X		X			X																		
C-CELL CARCINOMA									X										X						X
PARATHYROID	+	+	+	+	+	+	+	+	+	+	+	+	+	+	+	+	+	+	+	+	+	+	+	+	+
ADENOMA, NOS																									
C-CELL CARCINOMA, INVASIVE									X																X
PANCREATIC ISLETS	+	+	+	+	+	+	+	+	+	+	+	+	+	+	+	+	+	+	+	+	+	+	+	+	+
ISLET-CELL ADENOMA																									
ISLET-CELL CARCINOMA																									
REPRODUCTIVE SYSTEM																									
MAMMARY GLAND	+	+	+	+	+	+	+	+	+	+	+	+	+	+	+	+	+	+	+	+	+	+	+	+	+
CARCINOMA, NOS																									
ADENOMA, NOS									X																
ADENOCARCINOMA, NOS				X																	X				
FIBROADENOMA		X	X	X				X		X	X		X	X				X	X	X	X	X	X		
PREPUTIAL/CLITORAL GLAND	N	N	N	N	N	N	N	N	N	N	N	N	N	N	N	N	N	N	N	N	N	N	N	N	N
CARCINOMA, NOS												X													
SQUAMOUS CELL CARCINOMA																									
FEMALE EXTERNAL GENITALIA	N	N	N	N	N	N	N	N	N	N	N	N	N	N	N	N	N	N	N	N	N	N	N	N	N
FIBROSARCOMA, INVASIVE																									
VAGINA	N	N	N	N	N	N	N	N	N	N	N	N	N	N	N	N	N	N	N	N	N	N	N	N	N
FIBROSARCOMA																									
ENDOMETRIAL STROMAL SARCOMA																									
UTERUS	+	+	+	+	+	+	+	+	+	+	+	+	+	+	+	+	+	+	+	+	+	+	+	+	+
CARCINOMA, NOS																									
ADENOMA, NOS																									
FIBROMA																									
LEIOMYOMA																									
ENDOMETRIAL STROMAL POLYP						X			X																
ENDOMETRIAL STROMAL SARCOMA																									
OVARY	+	+	+	+	+	+	+	+	+	+	+	+	+	+	+	+	+	+	+	+	+	+	+	+	+
PAPILLARY ADENOCARCINOMA																									
GRANULOSA-CELL TUMOR																									
NERVOUS SYSTEM																									
BRAIN	+	+	+	+	+	+	+	+	+	+	+	+	+	+	+	+	+	+	+	+	+	+	+	+	+
CARCINOMA, NOS, INVASIVE					X								X							X					
ASTROCYTOMA		X																							
SPINAL CORD	N	N	N	N	N	N	N	N	N	N	N	N	N	N	N	N	N	N	N	N	N	N	N	N	N
OLIGODENDROGLIOMA																									
SPECIAL SENSE ORGANS																									
EYE	N	N	N	+	N	+	N	N	N	N	N	N	N	N	N	N	N	+	N	N	N	+	N	N	N
FIBROMA																									
ZYMBAL GLAND	+	+	+	+	+	+	+	+	+	+	+	+	+	+	+	+	+	+	+	+	+	+	+	+	+
SQUAMOUS CELL CARCINOMA																				X	X				
MUSCULOSKELETAL SYSTEM																									
BONE	N	N	N	N	N	N	N	N	N	N	N	N	N	N	N	N	N	N	N	N	N	N	N	N	N
SQUAMOUS CELL CARCINOMA																									
ALL OTHER SYSTEMS																									
MULTIPLE ORGANS NOS	N	N	N	N	N	N	N	N	N	N	N	N	N	N	N	N	N	N	N	N	N	N	N	N	N
ALVEOLAR/BRONCHIOLAR CA, METASTAT																									
PAPILLARY ADENOCARCINOMA, METASTA																									
CORTICAL CARCINOMA, METASTATIC																									
MYELOMONOCYTIC LEUKEMIA																									
MONOCYTIC LEUKEMIA			X		X		X			X		X				X		X				X	X		
LEUKEMIA, MONONUCLEAR CELL																				X					
PERINEUM NOS																									
FIBROSARCOMA																									
FOOT NOS																									
FIBROMA																									

HWBUI0001728

TABLE B4. INDIVIDUAL ANIMAL TUMOR PATHOLOGY OF FEMALE RATS IN THE LIFETIME FEED STUDY OF INTERMEDIATE-RANGE CHRYSOTILE ASBESTOS: INTERMEDIATE-RANGE (Continued)

| ANIMAL NUMBER | 3 3 3

TABLE B4. INDIVIDUAL ANIMAL TUMOR PATHOLOGY OF FEMALE RATS IN THE LIFETIME FEED STUDY OF INTERMEDIATE-RANGE CHRYSOTILE ASBESTOS: INTERMEDIATE-RANGE (Continued)

ANIMAL NUMBER	95060	95121	95220	95346	95422	95585	95646	95721	95884	95932	96083	96137	96291	96325	96510	96644	96705	96867	96911	97025	97134	97232	97330	97418
WEEKS ON STUDY	096	121	120	146	122	105	146	121	084	132	083	137	091	125	110	291	084	088	671	118	125	134	123	130	118
URINARY SYSTEM																									
KIDNEY	+	+	+	+	+	+	+	+	+	+	+	+	+	+	+	+	+	+	+	+	+	+	+	+	+
CARCINOMA, NOS																									
LIPOSARCOMA																									
URINARY BLADDER	+	+	+	+	+	+	+	+	-	+	+	+	+	+	+	+	+	+	+	+	+	+	+	+	+
TRANSITIONAL-CELL PAPILLOMA																				X					
ENDOCRINE SYSTEM																									
PITUITARY	+	+	+	+	+	+	+	+	+	+	+	+	+	+	+	+	+	+	+	+	+	+	+	+	+
CARCINOMA, NOS																									
ADENOMA, NOS	X	X	X	X		X	X	X				X		X					X	X	X		X		
ADRENAL	+	+	+	+	+	+	+	+	+	+	+	+	+	+	+	+	+	+	+	+	+	+	+	+	+
CORTICAL ADENOMA																			X		X				
CORTICAL CARCINOMA																									
PHEOCHROMOCYTOMA	X											X										X			
THYROID	+	+	+	+	+	+	+	+	+	+	+	+	+	+	+	+	+	+	+	+	+	+	+	+	+
FOLLICULAR-CELL ADENOMA				X					X			X							X						
FOLLICULAR-CELL CARCINOMA																									
C-CELL ADENOMA										X		X		-						X		X			
C-CELL CARCINOMA				X																					X
PARATHYROID	+	+	-	+	+	+	+	+	+	+	+	-	+	+	+	+	+	+	+	+	+	+	+	+	+
ADENOMA, NOS																									
C-CELL CARCINOMA, INVASIVE																									
PANCREATIC ISLETS	+	+	+	+	+	+	+	+	+	+	+	+	+	+	+	+	+	+	+	+	+	+	+	+	+
ISLET-CELL ADENOMA																									
ISLET-CELL CARCINOMA																									
REPRODUCTIVE SYSTEM																									
MAMMARY GLAND	+	+	+	+	+	+	+	+	+	+	+	+	+	+	+	+	+	+	+	+	+	+	+	+	+
CARCINOMA, NOS																									
ADENOMA, NOS				X				X				X										X			
ADENOCARCINOMA, NOS																									
FIBROADENOMA	X	X	X	X			X	X		X	X			X		X					X	X	X	X	X
PREPUTIAL/CLITORAL GLAND	N	N	N	N	N	N	N	N	N	N	N	N	N	N	N	N	N	N	N	N	N	N	N	N	N
CARCINOMA, NOS			X														X								
SQUAMOUS CELL CARCINOMA																									
FEMALE EXTERNAL GENITALIA	N	N	N	N	N	N	N	N	N	N	N	N	N	N	N	N	N	N	N	N	N	N	N	N	N
FIBROSARCOMA, INVASIVE																									
VAGINA	N	N	N	N	N	N	N	N	N	N	N	N	N	N	N	N	N	N	N	N	N	N	N	N	N
FIBROSARCOMA																									
ENDOMETRIAL STROMAL SARCOMA																									
UTERUS	+	+	+	+	+	+	+	+	+	+	+	+	+	+	+	+	+	+	+	+	+	+	+	+	+
CARCINOMA, NOS			X																						
ADENOMA, NOS																									
FIBROMA																									
LEIOMYOMA																									
ENDOMETRIAL STROMAL POLYP					X	X										X									
ENDOMETRIAL STROMAL SARCOMA									xa																
OVARY	+	+	+	+	+	+	+	+	+	+	+	+	+	+	+	+	+	+	+	+	+	+	+	+	+
PAPILLARY ADENOCARCINOMA																									
GRANULOSA-CELL TUMOR																									
NERVOUS SYSTEM																									
BRAIN	+	+	+	+	+	+	+	+	+	+	+	+	+	+	+	+	+	+	+	+	+	+	+	+	+
CARCINOMA, NOS, INVASIVE																									
ASTROCYTOMA																									
SPINAL CORD	N	N	N	N	N	N	N	N	N	N	N	N	N	N	+	N	N	N	N	N	N	N	N	N	N
OLIGODENDROGLIOMA																									
SPECIAL SENSE ORGANS																									
EYE	N	N	N	N	N	N	+	N	N	N	N	N	N	N	+	+	N	N	N	+	+	+	+	+	N
FIBROMA																									
ZYMBAL GLAND	+	+	+	+	+	+	+	+	+	+	+	+	+	+	+	+	+	+	+	+	+	+	+	+	+
SQUAMOUS CELL CARCINOMA																									
MUSCULOSKELETAL SYSTEM																									
BONE	N	N	N	N	N	N	N	N	N	N	N	N	N	N	N	N	N	N	N	N	N	N	N	N	N
SQUAMOUS CELL CARCINOMA																									
ALL OTHER SYSTEMS																									
MULTIPLE ORGANS NOS	N	N	N	N	N	N	N	N	N	N	N	N	N	N	N	N	N	N	N	N	N	N	N	N	N
ALVEOLAR/BRONCHIOLAR CA, METASTAT																									
PAPILLARY ADENOCARCINOMA, METASTA																									
CORTICAL CARCINOMA, METASTATIC																									
MYELOMONOCYTIC LEUKEMIA																									
MONOCYTIC LEUKEMIA	X					X						X	X			X		X					X	X	
LEUKEMIA, MONONUCLEAR CELL																									
PERINEUM NOS																									
FIBROSARCOMA																									
FOOT NOS																									
FIBROMA																									

a: MULTIPLE OCCURENCE OF MORPHOLOGY

HWBUI0001730

TABLE B4. INDIVIDUAL ANIMAL TUMOR PATHOLOGY OF FEMALE RATS IN THE LIFETIME FEED STUDY OF INTERMEDIATE-RANGE CHRYSOTILE ASBESTOS: INTERMEDIATE-RANGE (Continued)

ANIMAL NUMBER	97154	97176	97178	97189	97190	98011	98012	98013	98014	98015	98016	98017	98018	98019	99010	99011	99012	99013	99014	99015	99016	99017	99018	99019	TOTAL TISSUES TUMORS
WEEKS ON STUDY	112	108	096	094	146	116	116	129	123	103	139	116	146	125	112	114	107	123	093	139	146	108	083	090	
INTEGUMENTARY SYSTEM																									
SKIN	+	+	+	+	+	+	+	+	+	+	+	+	+	+	+	+	+	+	+	+	+	+	+	+	250M
SQUAMOUS CELL PAPILLOMA											X														5
SQUAMOUS CELL CARCINOMA																									1
BASAL-CELL CARCINOMA																									2
KERATOACANTHOMA																									1
SUBCUTANEOUS TISSUE	+	+	+	+	+	+	+	+	+	+	+	+	+	+	+	+	+	+	+	+	+	+	+	+	250M
SQUAMOUS CELL CARCINOMA																									3
FIBROMA																					X				9
FIBROSARCOMA												X													4
LIPOMA																									1
RESPIRATORY SYSTEM																									
LUNGS AND BRONCHI	+	+	+	+	+	+	+	+	+	+	+	+	+	+	+	+	+	+	+	+	+	+	+	+	250
SQUAMOUS CELL CARCINOMA, METASTAT																									1
ADENOCARCINOMA, NOS, METASTATIC					X																				2
ALVEOLAR/BRONCHIOLAR ADENOMA																		X							2
ALVEOLAR/BRONCHIOLAR CARCINOMA																									1
FOLLICULAR-CELL CARCINOMA, METAST																			X						1
C-CELL CARCINOMA, METASTATIC																			X						4
TRACHEA	+	+	+	+	+	+	+	+	+	+	+	+	+	+	+	+	+	–	+	+	+	+	+	+	249
LARYNX	N	N	N	N	N	N	N	N	N	N	N	N	N	N	N	N	N	N	+	N	N	N	N	N	250M
FOLLICULAR-CELL CARCINOMA, INVASI																			X						1
C-CELL CARCINOMA, INVASIVE																			X						1
HEMATOPOIETIC SYSTEM																									
BONE MARROW	+	+	+	+	+	+	+	+	+	+	+	+	+	+	+	+	+	+	+	+	+	+	+	+	248
SPLEEN	+	+	+	+	+	+	+	+	+	+	+	+	+	+	+	+	+	–	+	+	+	+	+	+	249
LYMPH NODES	+	+	+	+	+	+	+	+	+	+	+	+	+	+	+	+	+	+	+	+	+	+	+	+	250
SQUAMOUS CELL CARCINOMA, METASTAT																									3
ADENOCARCINOMA, NOS, METASTATIC																									1
FOLLICULAR-CELL CARCINOMA, METAST																			X						1
C-CELL CARCINOMA, METASTATIC																			X						3
MALIG.LYMPHOMA, HISTIOCYTIC TYPE																									1
THYMUS	+	+	+	+	+	+	–	+	+	+	+	+	+	–	+	+	–	+	–	+	–	+	+	–	199
CIRCULATORY SYSTEM																									
HEART	+	+	+	+	+	+	+	+	+	+	+	+	+	+	+	+	+	+	+	+	+	+	+	+	250
ADENOCARCINOMA, NOS, METASTATIC																									1
DIGESTIVE SYSTEM																									
ORAL CAVITY	N	N	N	N	N	N	N	N	N	N	N	N	N	N	N	N	N	N	N	N	N	N	N	N	250M
SQUAMOUS CELL PAPILLOMA																									1
SQUAMOUS CELL CARCINOMA																									1
SALIVARY GLAND	+	+	+	+	+	+	+	+	+	+	+	+	–	+	+	+	+	+	+	+	+	+	+	+	248
ADENOCARCINOMA, NOS																									1
LIVER	+	+	+	+	+	+	+	+	+	+	+	+	+	+	+	+	+	+	+	+	+	+	+	+	250
NEOPLASTIC NODULE																									4
HEPATOCELLULAR CARCINOMA																									2
CORTICAL CARCINOMA, METASTATIC																									1
MALIG.LYMPHOMA, HISTIOCYTIC TYPE																									1
BILE DUCT	+	+	+	+	+	+	+	+	+	+	+	+	+	+	+	+	+	+	+	+	+	+	+	+	250
GALLBLADDER & COMMON BILE DUCT	N	N	N	N	N	N	N	N	N	N	N	N	N	N	N	N	N	N	N	N	N	N	N	N	250M
PANCREAS	+	+	+	+	+	+	+	+	+	+	+	+	+	+	+	+	+	–	+	+	+	+	+	+	249
ACINAR-CELL ADENOMA																									4
ACINAR-CELL CARCINOMA																									1
ESOPHAGUS	+	+	+	+	+	+	+	+	+	+	+	+	+	+	+	+	+	+	+	+	+	+	+	+	250
STOMACH	+	+	+	+	+	+	+	+	+	+	+	+	+	+	+	+	+	+	+	+	+	+	+	+	250
ADENOMATOUS POLYP, NOS																									1
CARCINOID TUMOR, NOS																									2
LEIOMYOSARCOMA																									1
ENDOMETRIAL STROMAL SARCOMA, META										X															1
SMALL INTESTINE	+	+	+	+	+	+	+	+	+	+	+	+	+	+	+	+	+	–	+	+	+	+	+	+	249
LARGE INTESTINE	+	+	+	+	+	+	+	+	+	+	+	+	+	+	+	+	+	+	+	+	+	+	+	+	250
ADENOMATOUS POLYP, NOS																					X				1
LEIOMYOMA																									1

HWBUI0001731

TABLE B4. INDIVIDUAL ANIMAL TUMOR PATHOLOGY OF FEMALE RATS IN THE LIFETIME FEED STUDY OF INTERMEDIATE-RANGE CHRYSOTILE ASBESTOS: INTERMEDIATE-RANGE (Continued)

ANIMAL NUMBER	97150	97160	97178	97189	97190	98041	98161	98229	98323	98403	98515	98566	98674	98685	98915	99021	99111	99204	99307	99404	99505	99616	99717	99803	99909	TOTAL TISSUES TUMORS
WEEKS ON STUDY	128	107	084	096	046	416	166	129	532	033	991	136	465	155	212	111	114	078	232	093	139	146	188	093	090	
URINARY SYSTEM																										
KIDNEY	+	+	+	+	+	+	+	+	+	+	+	+	+	+	+	+	+	+	+	+	+	+	+	+	+	250
CARCINOMA, NOS																										1
LIPOSARCOMA																										1
URINARY BLADDER	+	+	+	+	+	+	+	+	+	+	+	+	+	+	+	+	+	+	+	+	+	+	+	+	+	247
TRANSITIONAL-CELL PAPILLOMA																										1
ENDOCRINE SYSTEM																										
PITUITARY	+	+	+	+	+	+	+	+	+	+	+	+	+	+	+	+	+	+	+	+	+	+	+	+	+	249
CARCINOMA, NOS																										14
ADENOMA, NOS	X			X	X	X	X	X			X		X	X	X				X					X		103
ADRENAL	+	+	+	+	+	+	+	+	+	+	+	+	+	+	+	+	+	+	+	+	+	+	+	+	+	249
CORTICAL ADENOMA																										18
CORTICAL CARCINOMA																										5
PHEOCHROMOCYTOMA									X				X													25
THYROID	+	+	+	+	+	+	+	+	+	+	+	+	+	+	+	+	-	+	+	+	+	+	+	+	+	248
FOLLICULAR-CELL ADENOMA													X													13
FOLLICULAR-CELL CARCINOMA																			X							14
C-CELL ADENOMA					X	X			X		X					X					X					26
C-CELL CARCINOMA	X							X											X							41
PARATHYROID	+	+	+	+	+	+	+	+	+	+	+	+	+	+	+	+	-	+	+	-	+	+	+	+	+	235
ADENOMA, NOS																										1
C-CELL CARCINOMA, INVASIVE																										3
PANCREATIC ISLETS	+	+	+	+	+	+	+	+	+	+	+	+	+	+	+	+	-	+	+	+	+	+	+	+	+	249
ISLET-CELL ADENOMA				X																						6
ISLET-CELL CARCINOMA					X																X					7
REPRODUCTIVE SYSTEM																										
MAMMARY GLAND	+	+	+	+	+	+	+	+	+	+	+	+	+	+	+	+	+	+	+	+	+	+	+	+	+	250M
CARCINOMA, NOS																										3
ADENOMA, NOS														X										X		21
ADENOCARCINOMA, NOS					X	X																				9
FIBROADENOMA	X				X	X					X	X	X	X		X					X		X			128
PREPUTIAL/CLITORAL GLAND	N	N	N	N	N	N	N	N	N	N	N	N	N	N	N	N	N	N	N	N	N	N	N	N	N	250M
CARCINOMA, NOS																								X		16
SQUAMOUS CELL CARCINOMA																										2
FEMALE EXTERNAL GENITALIA	N	N	N	N	N	N	N	N	N	N	N	N	N	N	N	N	N	N	N	N	N	N	N	N	N	250M
FIBROSARCOMA, INVASIVE																										1
VAGINA	N	N	N	N	N	N	N	N	N	N	N	N	N	N	N	N	N	N	N	N	N	N	N	N	N	250M
FIBROSARCOMA																										1
ENDOMETRIAL STROMAL SARCOMA																										2
UTERUS	+	+	+	+	+	+	+	+	+	+	+	+	+	+	+	+	+	+	+	+	+	+	+	+	+	249
CARCINOMA, NOS																										1
ADENOMA, NOS																										1
FIBROMA																										1
LEIOMYOMA																										2
ENDOMETRIAL STROMAL POLYP		X																	X							22
ENDOMETRIAL STROMAL SARCOMA										X																4
OVARY	+	+	+	+	+	+	+	+	+	+	+	+	+	+	+	+	+	+	+	+	+	+	+	+	+	249
PAPILLARY ADENOCARCINOMA																										1
GRANULOSA-CELL TUMOR																					X					4
NERVOUS SYSTEM																										
BRAIN	+	+	+	+	+	+	+	+	+	+	+	+	+	+	+	+	+	+	+	+	+	+	+	+	+	250
CARCINOMA, NOS, INVASIVE																										13
ASTROCYTOMA				X																						3
SPINAL CORD	N	N	N	N	N	N	N	N	N	N	N	N	N	N	N	N	N	N	N	N	N	N	N	N	N	250M
OLIGODENDROGLIOMA																										1
SPECIAL SENSE ORGANS																										
EYE	N	N	N	N	+	+	+	N	N	N	N	N	+	N	N	N	N	N	N	N	+	N	N	N	N	250M
FIBROMA																										1
ZYMBAL GLAND	+	+	+	N	+	+	+	+	+	+	+	+	+	+	+	+	+	+	+	+	+	+	+	+	+	250M
SQUAMOUS CELL CARCINOMA															X						X					7
MUSCULOSKELETAL SYSTEM																										
BONE	N	N	N	N	N	N	N	N	N	N	N	N	N	N	N	N	N	N	N	N	N	N	N	N	N	250M
SQUAMOUS CELL CARCINOMA																										1
ALL OTHER SYSTEMS																										
MULTIPLE ORGANS NOS	N	N	N	N	N	N	N	N	N	N	N	N	N	N	N	N	N	N	N	N	N	N	N	N	N	250M
ALVEOLAR/BRONCHIOLAR CA, METASTAT																										1
PAPILLARY ADENOCARCINOMA, METASTA																										1
CORTICAL CARCINOMA, METASTATIC																										2
MYELOMONOCYTIC LEUKEMIA																										2
MONOCYTIC LEUKEMIA	X	X	X												X	X	X	X					X		X	76
LEUKEMIA, MONONUCLEAR CELL																										4
PERINEUM NOS																										
FIBROSARCOMA																										1
FOOT NOS																										
FIBROMA																										1

M ANIMALS NECROPSIED

HWBUI0001732

TABLE B4. INDIVIDUAL ANIMAL TUMOR PATHOLOGY OF FEMALE RATS IN THE LIFETIME FEED STUDY OF INTERMEDIATE-RANGE CHRYSOTILE ASBESTOS: INTERMEDIATE-RANGE PLUS 1,2-DIMETHYLHYDRAZINE DIHYDROCHLORIDE

ANIMAL NUMBER	37171	37172	37173	37174	37175	37176	37177	37178	37179	37180	38181	38182	38183	38184	38185	38186	38187	38188	38189	38190	39191	39192	39193	39194	39195
WEEKS ON STUDY	09931	09931	18921	09951	09951	08921	09941	07931	10908	09941	06931	11918	10933	08841	08021	11919	10921	10900	11901	11909	10918	10885	11866	11919	09945
INTEGUMENTARY SYSTEM																									
SKIN	+	+	+	+	+	+	+	+	+	+	+	+	+	+	+	+	+	+	+	+	+	+	+	+	+
BASAL-CELL TUMOR																									
BASAL-CELL CARCINOMA																									
KERATOACANTHOMA																									
SUBCUTANEOUS TISSUE	+	+	+	+	+	+	+	+	+	+	+	+	+	+	+	+	+	+	+	+	+	+	+	+	+
CARCINOMA, NOS																									
KERATOACANTHOMA																									
FIBROMA																									
FIBROSARCOMA																									
RESPIRATORY SYSTEM																									
LUNGS AND BRONCHI	+	+	+	+	+	+	+	+	+	+	+	+	+	+	+	+	+	+	+	+	+	+	+	+	+
SQUAMOUS CELL CARCINOMA, METASTAT																									
ALVEOLAR/BRONCHIOLAR ADENOMA											X														
PHEOCHROMOCYTOMA, METASTATIC																									
LIPOSARCOMA, METASTATIC																									
MIXED TUMOR, METASTATIC						X																			
HEMANGIOSARCOMA, METASTATIC																									
TRACHEA	+	+	+	+	+	+	+	+	+	+	+	+	+	+	+	+	+	+	+	+	+	+	+	+	+
NASAL CAVITY	N	N	N	N	N	N	N	N	N	N	N	N	N	N	N	N	N	N	N	N	N	N	N	N	N
SQUAMOUS CELL CARCINOMA																									
HEMATOPOIETIC SYSTEM																									
BONE MARROW	+	+	+	+	+	+	+	+	+	+	+	+	+	+	+	+	+	+	+	+	+	+	+	+	+
SPLEEN	+	+	+	+	+	+	+	+	+	+	+	+	+	+	+	+	+	+	+	+	+	+	+	+	+
LYMPH NODES	+	+	+	+	+	+	+	+	+	+	+	+	+	+	+	+	+	+	+	+	+	+	+	+	+
ADENOCARCINOMA, NOS, METASTATIC																									
MUCINOUS CYSTADENOCA, METASTATIC																									
SIGNET RING CARCINOMA, METASTATIC																									
THYMUS	-	+	+	+	+	+	+	-	+	+	+	+	+	+	+	-	+	+	+	-	+	+	+	+	+
CIRCULATORY SYSTEM																									
HEART	+	+	+	+	+	+	+	+	+	+	+	+	+	+	+	+	+	+	+	+	+	+	+	+	+
MIXED TUMOR, METASTATIC						X																			
NEURILEMOMA																									
DIGESTIVE SYSTEM																									
SALIVARY GLAND	+	+	+	+	+	+	+	+	+	+	+	+	+	+	+	+	+	+	+	+	+	+	+	+	+
LIVER	+	+	+	+	+	+	+	+	+	+	+	+	+	+	+	+	+	+	+	+	+	+	+	+	+
BILE DUCT ADENOMA																									
NEOPLASTIC NODULE	X						X						X		X										
HEPATOCELLULAR CARCINOMA			X																	X					
MIXED TUMOR, METASTATIC																									
HEMANGIOSARCOMA																									
BILE DUCT	+	+	+	+	+	+	+	+	+	+	+	+	+	+	+	+	+	+	+	+	+	+	+	+	+
GALLBLADDER & COMMON BILE DUCT	N	N	N	N	N	N	N	N	N	N	N	N	N	N	N	N	N	N	N	N	N	N	N	N	N
PANCREAS	+	+	+	+	+	+	+	+	+	+	+	+	+	+	+	+	+	+	+	+	+	+	+	+	+
MIXED TUMOR, INVASIVE											X														
MIXED TUMOR, METASTATIC																									
ESOPHAGUS	+	+	+	+	+	+	+	+	+	+	+	+	+	+	+	+	+	+	+	+	+	+	+	+	+
STOMACH	+	+	+	+	+	+	+	+	+	+	+	+	+	+	+	+	+	+	+	+	+	+	+	+	+
SMALL INTESTINE	+	+	+	+	+	+	+	+	+	+	+	+	+	+	+	+	+	+	+	+	+	+	+	+	+
ADENOMATOUS POLYP, NOS																									
ADENOCA IN ADENOMATOUS POLYP			X																						
MUCINOUS CYSTADENOCARCINOMA																									
SIGNET RING CARCINOMA																									
LARGE INTESTINE	+	+	+	+	+	+	+	+	+	+	+	+	+	+	+	+	+	+	+	+	+	+	+	+	+
ADENOCARCINOMA, NOS																									
ADENOMATOUS POLYP, NOS			X	X	X					X	X				X					X		X	X	X	
ADENOCA IN ADENOMATOUS POLYP																						X			X
MUCINOUS CYSTADENOCARCINOMA																	X								
SIGNET RING CARCINOMA																									
URINARY SYSTEM																									
KIDNEY	+	+	+	+	+	+	+	+	+	+	+	+	+	+	+	+	+	+	+	+	+	+	+	+	+
MIXED TUMOR, MALIGNANT			X			X		X	X		X						X			X				
URINARY BLADDER	+	+	+	+	+	+	+	+	+	+	+	+	+	+	+	+	+	+	+	+	+	+	+	+	+

+: TISSUE EXAMINED MICROSCOPICALLY
-: REQUIRED TISSUE NOT EXAMINED MICROSCOPICALLY
X: TUMOR INCIDENCE
N: NECROPSY, NO AUTOLYSIS, NO MICROSCOPIC EXAMINATION
S: ANIMAL MIS-SEXED
: NO TISSUE INFORMATION SUBMITTED
C: NECROPSY, NO HISTOLOGY DUE TO PROTOCOL
A: AUTOLYSIS
M: ANIMAL MISSING
B: NO NECROPSY PERFORMED

HWBUI0001733

TABLE B4. INDIVIDUAL ANIMAL TUMOR PATHOLOGY OF FEMALE RATS IN THE LIFETIME FEED STUDY OF INTERMEDIATE-RANGE CHRYSOTILE ASBESTOS: INTERMEDIATE-RANGE PLUS 1,2-DIMETHYLHYDRAZINE DIHYDROCHLORIDE (Continued)

ANIMAL NUMBER	371 372 373 374 375 376 377 378 379 380 381 382 383 384 385 386 387 388 389 390 391 392 393 394 395
WEEKS ON STUDY	093 093 102 097 093 082 094 087 108 094 063 118 110 093 088 082 119 092 100 099 118 085 061 119 094
ENDOCRINE SYSTEM	
PITUITARY	+ +
CARCINOMA, NOS	X
ADENOMA, NOS	X X X X X X X X X X X
ADRENAL	+ +
CORTICAL ADENOMA	X
CORTICAL CARCINOMA	
PHEOCHROMOCYTOMA	X X
PHEOCHROMOCYTOMA, MALIGNANT	
THYROID	+ +
FOLLICULAR-CELL ADENOMA	X
FOLLICULAR-CELL CARCINOMA	X X
C-CELL ADENOMA	X X
C-CELL CARCINOMA	X
PARATHYROID	+ + + + + + + - + + + + + - + + + + + + + + + + +
PANCREATIC ISLETS	+ +
ISLET-CELL ADENOMA	
ISLET-CELL CARCINOMA	
REPRODUCTIVE SYSTEM	
MAMMARY GLAND	+ +
ADENOMA, NOS	X
ADENOCARCINOMA, NOS	X X X X X
FIBROADENOMA	
PREPUTIAL/CLITORAL GLAND	N N N N N N N N N N N N N N N N N N N N N N N N N
CARCINOMA, NOS	X X
VAGINA	N N N N N N N N N N N N N N N N N N N N N N N N N
ENDOMETRIAL STROMAL SARCOMA, INVA	
UTERUS	+ +
PAPILLARY CARCINOMA	
ADENOMA, NOS	X X
PAPILLARY ADENOMA	
LEIOMYOSARCOMA	
ENDOMETRIAL STROMAL POLYP	X X X
ENDOMETRIAL STROMAL SARCOMA	X X
ENDOMETRIAL STROMAL SARCOMA, INVA	
OVARY	+ +
GRANULOSA-CELL TUMOR	
NERVOUS SYSTEM	
BRAIN	+ +
CARCINOMA, NOS, INVASIVE	X
ASTROCYTOMA	
SPECIAL SENSE ORGANS	
EAR	+ +
SQUAMOUS CELL CARCINOMA	
ZYMBAL GLAND	+ +
SQUAMOUS CELL PAPILLOMA	
SQUAMOUS CELL CARCINOMA	X X X
ADENOMA, NOS	
MUSCULOSKELETAL SYSTEM	
MUSCLE	N N N N N N N N N N N N N N N N N N N N N N N N N
MIXED TUMOR, INVASIVE	
BODY CAVITIES	
MEDIASTINUM	N N N N N N N N N N N N N N N N N N N N N N N N N
MUCINOUS CYSTADENOCA, METASTATIC	
PERITONEUM	N N N N N N N N N N N N N N N N N N N N N N N N N
MIXED TUMOR, INVASIVE	
MESENTERY	N N N N N N N N N N N N N N N N N N N N N N N N N
MIXED TUMOR, INVASIVE	X
ALL OTHER SYSTEMS	
MULTIPLE ORGANS NOS	N N N N N N N N N N N N N N N N N N N N N N N N N
MUCINOUS CYSTADENOCA, METASTATIC	
SIGNET RING CARCINOMA, METASTATIC	
MALIG.LYMPHOMA, UNDIFFER-TYPE	
MYELOMONOCYTIC LEUKEMIA	
MONOCYTIC LEUKEMIA	X X X X X X X X X X X X X X X X X X X
LEUKEMIA, MONONUCLEAR CELL	X X X
ADIPOSE TISSUE	
MUCINOUS CYSTADENOCA, METASTATIC	
MIXED TUMOR, INVASIVE	

HWBUI0001734

TABLE B4. INDIVIDUAL ANIMAL TUMOR PATHOLOGY OF FEMALE RATS IN THE LIFETIME FEED STUDY OF INTERMEDIATE-RANGE CHRYSOTILE ASBESTOS: INTERMEDIATE-RANGE PLUS 1,2-DIMETHYLHYDRAZINE DIHYDROCHLORIDE (Continued)

ANIMAL NUMBER	396	397	398	399	401	402	403	404	405	406	407	408	409	410	411	412	413	414	415	416	417	418	419	420
WEEKS ON STUDY	119	082	052	119	113	108	000	074	108	089	110	101	036	114	119	119	119	084	093	086	068	085	061	098	097
INTEGUMENTARY SYSTEM																									
SKIN	+	+	+	+	+	+	+	+	+	+	+	+	+	+	+	+	+	+	+	+	+	+	+	+	+
BASAL-CELL TUMOR														X											
BASAL-CELL CARCINOMA																									
KERATOACANTHOMA																									
SUBCUTANEOUS TISSUE	+	+	+	+	+	+	+	+	+	+	+	+	+	+	+	+	+	+	+	+	+	+	+	+	+
CARCINOMA, NOS																									
KERATOACANTHOMA																									
FIBROMA																			X						
FIBROSARCOMA																		X							
RESPIRATORY SYSTEM																									
LUNGS AND BRONCHI	+	+	+	+	+	+	+	+	+	+	+	+	+	+	+	+	+	+	+	+	+	+	+	+	+
SQUAMOUS CELL CARCINOMA, METASTAT																									
ALVEOLAR/BRONCHIOLAR ADENOMA																									
PHEOCHROMOCYTOMA, METASTATIC														X											
LIPOSARCOMA, METASTATIC																									
MIXED TUMOR, METASTATIC																									
HEMANGIOSARCOMA, METASTATIC																									
TRACHEA	+	+	+	+	+	+	+	+	+	+	+	+	+	+	+	+	+	+	+	+	+	+	+	+	+
NASAL CAVITY	N	N	N	N	N	N	N	N	N	N	N	N	N	N	N	N	N	N	N	N	N	N	N	N	N
SQUAMOUS CELL CARCINOMA																									
HEMATOPOIETIC SYSTEM																									
BONE MARROW	+	+	+	+	+	+	+	+	+	+	+	+	+	+	+	+	+	+	+	+	+	-	+	+	
SPLEEN	+	+	+	+	+	+	+	+	+	+	+	+	+	+	+	+	+	+	+	+	+	+	+	+	
LYMPH NODES	+	+	+	+	+	+	+	+	+	+	+	+	+	+	+	+	+	+	+	+	+	+	+	+	+
ADENOCARCINOMA, NOS, METASTATIC																									
MUCINOUS CYSTADENOCA, METASTATIC																									
SIGNET RING CARCINOMA, METASTATIC		X																							
THYMUS	+	+	+	+	+	+	+	+	+	+	-	+	+	+	+	-	+	+	+	+	+	+	+	+	
CIRCULATORY SYSTEM																									
HEART	+	+	+	+	+	+	+	+	+	+	+	+	+	+	+	+	+	+	+	+	+	+	+	+	+
MIXED TUMOR, METASTATIC																									
NEURILEMOMA																									
DIGESTIVE SYSTEM																									
SALIVARY GLAND	+	+	+	+	+	+	+	+	+	+	+	+	+	+	+	+	+	+	+	+	+	+	+	+	+
LIVER	+	+	+	+	+	+	+	+	+	+	+	+	+	+	+	+	+	+	+	+	+	+	+	+	+
BILE DUCT ADENOMA				X																					
NEOPLASTIC NODULE										X						X									
HEPATOCELLULAR CARCINOMA				X			X																		
MIXED TUMOR, METASTATIC																									
HEMANGIOSARCOMA																									
BILE DUCT	+	+	+	+	+	+	+	+	+	+	+	+	+	+	+	+	+	+	+	+	+	+	+	+	+
GALLBLADDER & COMMON BILE DUCT	N	N	N	N	N	N	N	N	N	N	N	N	N	N	N	N	N	N	N	N	N	N	N	N	N
PANCREAS	+	+	+	+	+	+	+	+	+	+	+	+	+	+	+	+	+	+	+	+	+	+	+	+	+
MIXED TUMOR, INVASIVE																									
MIXED TUMOR, METASTATIC																									
ESOPHAGUS	+	+	+	+	+	+	+	+	+	+	+	+	+	+	+	+	+	+	+	+	+	+	+	+	+
STOMACH	+	+	+	+	+	+	+	+	+	+	+	+	+	+	+	+	+	+	+	+	+	+	+	+	+
SMALL INTESTINE	+	+	+	+	+	+	+	+	+	+	+	+	+	+	+	+	+	+	+	+	+	+	+	+	+
ADENOMATOUS POLYP, NOS																									
ADENOCA IN ADENOMATOUS POLYP																									
MUCINOUS CYSTADENOCARCINOMA																									
SIGNET RING CARCINOMA																									
LARGE INTESTINE	+	+	+	+	+	+	+	+	+	+	+	+	+	+	+	+	+	+	+	+	+	+	+	+	+
ADENOCARCINOMA, NOS															X										
ADENOMATOUS POLYP, NOS								X						X			X			X			X			X
ADENOCA IN ADENOMATOUS POLYP																									
MUCINOUS CYSTADENOCARCINOMA														X							X				
SIGNET RING CARCINOMA																									
URINARY SYSTEM																									
KIDNEY	+	+	+	+	+	+	+	+	+	+	+	+	+	+	+	+	+	+	+	+	+	+	+	+	+
MIXED TUMOR, MALIGNANT										X								X							X
URINARY BLADDER	+	+	+	+	+	+	+	+	+	+	+	+	+	+	+	+	+	+	+	+	+	+	+	+	+

HWBUI0001735

TABLE B4. INDIVIDUAL ANIMAL TUMOR PATHOLOGY OF FEMALE RATS IN THE LIFETIME FEED STUDY OF INTERMEDIATE-RANGE CHRYSOTILE ASBESTOS: INTERMEDIATE-RANGE PLUS 1,2-DIMETHYLHYDRAZINE DIHYDROCHLORIDE (Continued)

ANIMAL NUMBER	396	397	398	399	400	401	402	403	404	405	406	407	408	409	410	411	412	413	414	415	416	417	418	419	420
WEEKS ON STUDY	119	082	052	119	1-13	188	100	074	108	089	110	101	036	114	119	119	119	084	093	086	060	085	061	098	097
ENDOCRINE SYSTEM																									
PITUITARY	+	+	+	+	+	+	+	+	+	+	+	+	+	+	+	+	+	+	+	+	+	+	+	+	+
CARCINOMA, NOS																									
ADENOMA, NOS		X		X		X				X				X	X	X	X								
ADRENAL	+	+	+	+	+	+	+	+	+	+	+	+	+	+	+	+	+	+	+	+	+	+	+	+	+
CORTICAL ADENOMA																									
CORTICAL CARCINOMA															X										
PHEOCHROMOCYTOMA																									
PHEOCHROMOCYTOMA, MALIGNANT															X										
THYROID	+	+	+	+	+	+	+	+	+	+	+	+	+	+	+	+	+	+	+	+	+	+	+	+	+
FOLLICULAR-CELL ADENOMA																									
FOLLICULAR-CELL CARCINOMA																									
C-CELL ADENOMA	X																								
C-CELL CARCINOMA																									
PARATHYROID	+	+	+	+	+	+	+	+	+	+	+	+	+	+	+	+	+	+	+	+	-	+	+	+	+
PANCREATIC ISLETS	+	+	+	+	+	+	+	+	+	+	+	+	+	+	+	+	+	+	+	+	+	+	+	+	+
ISLET-CELL ADENOMA																									
ISLET-CELL CARCINOMA																									
REPRODUCTIVE SYSTEM																									
MAMMARY GLAND	+	+	+	+	+	+	+	+	+	+	+	+	N	+	+	+	+	+	+	+	+	+	+	+	+
ADENOMA, NOS						X																			
ADENOCARCINOMA, NOS																									X
FIBROADENOMA	X				X	X			X		X				X										
PREPUTIAL/CLITORAL GLAND	N	N	N	N	N	N	N	N	N	N	N	N	N	N	N	N	N	N	N	N	N	N	N	N	N
CARCINOMA, NOS							X																		
VAGINA	N	N	N	N	N	N	N	N	N	N	N	N	N	N	N	N	N	N	N	N	N	N	N	N	N
ENDOMETRIAL STROMAL SARCOMA, INVA																									
UTERUS	+	+	+	+	+	+	+	+	+	+	+	+	+	+	+	+	+	+	+	+	+	+	+	+	+
PAPILLARY CARCINOMA																									
ADENOMA, NOS																									
PAPILLARY ADENOMA																									
LEIOMYOSARCOMA										X															
ENDOMETRIAL STROMAL POLYP																	X								
ENDOMETRIAL STROMAL SARCOMA																									
ENDOMETRIAL STROMAL SARCOMA, INVA																									
OVARY	+	+	+	+	+	+	+	+	+	+	+	+	+	+	+	+	+	+	+	+	+	+	+	+	+
GRANULOSA-CELL TUMOR																									
NERVOUS SYSTEM																									
BRAIN	+	+	+	+	+	+	+	+	+	+	+	+	+	+	+	+	+	+	+	+	+	+	+	+	+
CARCINOMA, NOS, INVASIVE																									
ASTROCYTOMA						X																			
SPECIAL SENSE ORGANS																									
EAR	+	+	+	+	+	+	+	N	+	+	+	+	+	+	+	+	+	+	+	+	+	+	+	+	+
SQUAMOUS CELL CARCINOMA																									
ZYMBAL GLAND	+	+	+	+	+	+	+	N	+	+	+	+	+	+	+	+	+	+	+	+	+	+	+	+	+
SQUAMOUS CELL PAPILLOMA																									
SQUAMOUS CELL CARCINOMA																	X								
ADENOMA, NOS																									
MUSCULOSKELETAL SYSTEM																									
MUSCLE	N	N	N	N	N	N	N	N	N	N	N	N	N	N	N	N	N	N	N	N	N	N	N	N	N
MIXED TUMOR, INVASIVE																									
BODY CAVITIES																									
MEDIASTINUM	N	N	N	N	N	N	N	N	N	N	N	N	N	N	N	N	N	N	N	N	N	N	N	N	N
MUCINOUS CYSTADENOCA, METASTATIC																									
PERITONEUM	N	N	N	N	N	N	N	N	N	N	N	N	N	N	N	N	N	N	N	N	N	N	N	N	N
MIXED TUMOR, INVASIVE																									
MESENTERY	N	N	N	N	N	N	N	N	N	N	N	N	N	N	N	N	N	N	N	N	N	N	N	N	N
MIXED TUMOR, INVASIVE																									
ALL OTHER SYSTEMS																									
MULTIPLE ORGANS NOS	N	N	N	N	N	N	N	N	N	N	N	N	N	N	N	N	N	N	N	N	N	N	N	N	N
MUCINOUS CYSTADENOCA, METASTATIC														X							X				
SIGNET RING CARCINOMA, METASTATIC					X																				
MALIG.LYMPHOMA, UNDIFFER-TYPE																									
MYELOMONOCYTIC LEUKEMIA				X				X	X		X	X	X		X	X	X			X			X		X
MONOCYTIC LEUKEMIA																									
LEUKEMIA, MONONUCLEAR CELL																									
ADIPOSE TISSUE																									
MUCINOUS CYSTADENOCA, METASTATIC																									
MIXED TUMOR, INVASIVE																									

HWBUI0001736

TABLE B4. INDIVIDUAL ANIMAL TUMOR PATHOLOGY OF FEMALE RATS IN THE LIFETIME FEED STUDY OF INTERMEDIATE-RANGE CHRYSOTILE ASBESTOS: INTERMEDIATE-RANGE PLUS 1,2-DIMETHYLHYDRAZINE DIHYDROCHLORIDE (Continued)

ANIMAL NUMBER	412	413	414	415	416	417	418	419	420	421	422	423	424	425	426	427	428	429	430	431	432	433	434	435	436	437	438	439	440	441	442	443	444	445
WEEKS ON STUDY	092	115	119	100	119	110	110	093	062	103	087	119	096	064	092	000	088	097	073	079	115	110	119	095	076	056								
INTEGUMENTARY SYSTEM																																		
SKIN	+	+	+	+	N	+	+	+	+	+	+	+	+	+	+	+	+	+	+	+	+	+	+	+	+	+	+	+	+	+	+	+	+	+
BASAL-CELL TUMOR																																		
BASAL-CELL CARCINOMA																																		
KERATOACANTHOMA																																		
SUBCUTANEOUS TISSUE	+	+	+	+	N	+	+	+	+	+	+	X	+	+	+	+	+	+	+	+	+	+	+	+	+	+	+	+	+	+	+	+	+	+
CARCINOMA, NOS																																		
KERATOACANTHOMA																																		
FIBROMA																																		
FIBROSARCOMA																																		
RESPIRATORY SYSTEM																																		
LUNGS AND BRONCHI	+	+	+	+	+	+	+	+	+	+	+	+	+	+	+	+	+	+	+	+	+	+	+	+	+	+	+	+	+	+	+	+	+	+
SQUAMOUS CELL CARCINOMA, METASTAT																																		
ALVEOLAR/BRONCHIOLAR ADENOMA																																		
PHEOCHROMOCYTOMA, METASTATIC																																		
LIPOSARCOMA, METASTATIC																																		
MIXED TUMOR, METASTATIC																																		
HEMANGIOSARCOMA, METASTATIC																																		
TRACHEA	+	+	+	+	+	+	+	+	+	+	+	+	+	+	+	+	+	+	+	+	+	+	+	+	+	+	+	+	+	+	+	+	+	+
NASAL CAVITY	N	N	N	N	N	N	N	N	N	N	N	N	N	N	N	N	N	N	N	N	N	N	N	N	N	N	N	N	N	N	N	N	N	N
SQUAMOUS CELL CARCINOMA																																		
HEMATOPOIETIC SYSTEM																																		
BONE MARROW	+	+	+	+	+	+	+	+	+	+	+	+	+	+	+	+	+	+	+	+	+	+	+	+	+	+	+	+	+	+	+	+	+	+
SPLEEN	+	+	+	+	+	+	+	+	+	+	+	+	+	+	+	+	+	+	+	+	+	+	+	+	+	+	+	+	+	+	+	+	+	+
LYMPH NODES	+	+	+	+	+	+	+	+	+	+	+	+	+	+	+	+	+	+	+	+	+	+	+	+	+	+	+	+	+	+	+	+	+	+
ADENOCARCINOMA, NOS, METASTATIC																																		
MUCINOUS CYSTADENOCA, METASTATIC																																		
SIGNET RING CARCINOMA, METASTATIC																																		
THYMUS	+	-	+	+	+	+	+	-	+	+	+	-	+	+	+	-	+	+	+	-	+	+	+	+	+	+	+	+	+	+	+	+	+	+
CIRCULATORY SYSTEM																																		
HEART	+	+	+	+	+	+	+	+	+	+	+	+	+	+	+	+	+	+	+	+	+	+	+	+	+	+	+	+	+	+	+	+	+	+
MIXED TUMOR, METASTATIC																																		
NEURILEMOMA																																		
DIGESTIVE SYSTEM																																		
SALIVARY GLAND	+	+	+	+	+	+	+	+	+	+	+	+	+	+	+	+	+	+	+	+	+	+	+	+	+	+	+	+	+	+	+	+	+	+
LIVER	+	+	+	+	+	+	+	+	+	+	+	+	+	+	+	+	+	+	+	+	+	+	+	+	+	+	+	+	+	+	+	+	+	+
BILE DUCT ADENOMA																																		
NEOPLASTIC NODULE								X																					X	X				
HEPATOCELLULAR CARCINOMA				X			X							X																				
MIXED TUMOR, METASTATIC																																		
HEMANGIOSARCOMA																																		
BILE DUCT	+	+	+	+	+	+	+	+	+	+	+	+	+	+	+	+	+	+	+	+	+	+	+	+	+	+	+	+	+	+	+	+	+	+
GALLBLADDER & COMMON BILE DUCT	N	N	N	N	N	N	N	N	N	N	N	N	N	N	N	N	N	N	N	N	N	N	N	N	N	N	N	N	N	N	N	N	N	N
PANCREAS	+	+	+	+	+	+	+	+	+	+	+	+	+	+	+	+	+	+	+	+	+	+	+	+	+	+	+	+	+	+	+	+	+	+
MIXED TUMOR, INVASIVE																																		
MIXED TUMOR, METASTATIC																																		
ESOPHAGUS	+	+	+	+	+	+	+	+	+	+	+	+	+	+	+	+	+	+	+	+	+	+	+	+	+	+	+	+	+	+	+	+	+	+
STOMACH	+	+	+	+	+	+	+	+	+	+	+	+	+	+	+	+	+	+	+	+	+	+	+	+	+	+	+	+	+	+	+	+	+	+
SMALL INTESTINE	+	+	+	+	+	+	+	+	+	+	+	+	+	+	+	+	+	+	+	+	+	+	+	+	+	+	+	+	+	+	+	+	+	+
ADENOMATOUS POLYP, NOS																																		
ADENOCA IN ADENOMATOUS POLYP																																		
MUCINOUS CYSTADENOCARCINOMA										X																								
SIGNET RING CARCINOMA								X																										X
LARGE INTESTINE	+	+	+	+	+	+	+	+	+	+	+	+	+	+	+	+	+	+	+	+	+	+	+	+	+	+	+	+	+	+	+	+	+	+
ADENOCARCINOMA, NOS																																		
ADENOMATOUS POLYP, NOS			X			X	X	X						X	X	X							X										
ADENOCA IN ADENOMATOUS POLYP																																		
MUCINOUS CYSTADENOCARCINOMA															X														X	X				
SIGNET RING CARCINOMA																																		
URINARY SYSTEM																																		
KIDNEY	+	+	+	+	+	+	+	+	+	X	+	+	+	+	X	+	+	+	+	+	+	+	+	+	+	+	+	+	+	+	+	+	X	+
MIXED TUMOR, MALIGNANT																																		
URINARY BLADDER	+	+	+	+	+	+	+	+	+	+	+	+	+	+	+	+	+	+	+	+	+	+	+	+	+	+	+	+	+	+	+	+	+	+

HWBUI0001737

TABLE B4. INDIVIDUAL ANIMAL TUMOR PATHOLOGY OF FEMALE RATS IN THE LIFETIME FEED STUDY OF INTERMEDIATE-RANGE CHRYSOTILE ASBESTOS: INTERMEDIATE-RANGE PLUS 1,2-DIMETHYLHYDRAZINE DIHYDROCHLORIDE (Continued)

ANIMAL NUMBER	421	422	423	424	425	426	427	428	429	430	431	432	433	434	435	436	437	438	439	440	441	442	443	444	445
WEEKS ON STUDY	092	115	119	130	119	110	110	095	062	105	087	119	094	066	092	100	068	089	073	079	115	110	119	075	066
ENDOCRINE SYSTEM																									
PITUITARY	+	+	+	+	+	+	+	+	+	+	+	+	+	+	+	+	+	+	+	+	+	+	+	+	+
CARCINOMA, NOS																									
ADENOMA, NOS						X		X			X	X				X	X				X		X		
ADRENAL	+	+	+	+	+	+	+	+	+	+	+	+	+	+	+	+	+	+	+	+	+	+	+	+	+
CORTICAL ADENOMA						X																			
CORTICAL CARCINOMA																									
PHEOCHROMOCYTOMA		X																			X				
PHEOCHROMOCYTOMA, MALIGNANT																									
THYROID	+	+	+	+	+	+	+	+	+	+	+	+	+	+	+	+	+	+	+	+	+	+	+	+	+
FOLLICULAR-CELL ADENOMA																	X								
FOLLICULAR-CELL CARCINOMA																		X							
C-CELL ADENOMA	X									X											X				
C-CELL CARCINOMA								X									X								
PARATHYROID	+	+	+	+	+	+	+	+	+	+	+	+	+	+	+	+	+	+	+	+	+	+	+	+	+
PANCREATIC ISLETS	+	+	+	+	+	+	+	+	+	+	+	+	+	+	+	+	+	+	+	+	+	+	+	+	+
ISLET-CELL ADENOMA																									
ISLET-CELL CARCINOMA																									
REPRODUCTIVE SYSTEM																									
MAMMARY GLAND	+	+	+	+	+	+	+	+	+	+	+	+	+	+	+	+	+	+	N	+	+	+	+	+	+
ADENOMA, NOS																									
ADENOCARCINOMA, NOS																									
FIBROADENOMA		X			X	X				X		X		X			X					X	X		
PREPUTIAL/CLITORAL GLAND	N	N	N	N	N	N	N	N	N	N	N	N	N	N	N	N	N	N	N	N	N	N	N	N	N
CARCINOMA, NOS																									
VAGINA	N	N	N	N	N	N	N	N	N	N	N	N	N	N	N	N	N	N	N	N	N	N	N	N	N
ENDOMETRIAL STROMAL SARCOMA, INVA																			X						
UTERUS	+	+	+	+	+	+	+	+	+	+	+	+	+	+	+	+	+	+	+	+	+	+	+	+	+
PAPILLARY CARCINOMA																									
ADENOMA, NOS																									
PAPILLARY ADENOMA																									
LEIOMYOSARCOMA																									
ENDOMETRIAL STROMAL POLYP		X																						X	
ENDOMETRIAL STROMAL SARCOMA																			X						
ENDOMETRIAL STROMAL SARCOMA, INVA																									
OVARY	+	+	+	+	+	+	+	+	+	+	+	+	+	-	+	+	+	+	+	+	+	+	+	+	+
GRANULOSA-CELL TUMOR																									
NERVOUS SYSTEM																									
BRAIN	+	+	+	+	+	+	+	+	+	+	+	+	+	+	+	+	+	+	+	+	+	+	+	+	+
CARCINOMA, NOS, INVASIVE																									
ASTROCYTOMA																									
SPECIAL SENSE ORGANS																									
EAR	+	+	+	+	+	+	+	+	+	+	+	+	+	+	+	+	+	+	+	+	+	+	+	+	+
SQUAMOUS CELL CARCINOMA																									
ZYMBAL GLAND	+	+	+	+	+	+	+	+	+	+	+	+	+	+	+	+	+	+	+	+	+	+	+	+	+
SQUAMOUS CELL PAPILLOMA																									
SQUAMOUS CELL CARCINOMA						X					X						X								
ADENOMA, NOS																									
MUSCULOSKELETAL SYSTEM																									
MUSCLE	N	N	N	N	+	N	N	N	N	N	N	N	N	N	N	N	N	N	N	N	N	N	N	N	N
MIXED TUMOR, INVASIVE																									
BODY CAVITIES																									
MEDIASTINUM	N	N	N	N	N	N	N	N	N	N	N	N	N	N	N	N	N	N	N	N	N	N	N	N	N
MUCINOUS CYSTADENOCA, METASTATIC																									
PERITONEUM	N	N	N	N	N	N	N	N	N	X	N	N	N	N	N	N	N	N	N	N	N	N	N	N	N
MIXED TUMOR, INVASIVE																									
MESENTERY	N	N	N	N	N	N	N	N	N	N	N	N	N	N	N	N	N	N	N	N	N	N	N	N	N
MIXED TUMOR, INVASIVE																									
ALL OTHER SYSTEMS																									
MULTIPLE ORGANS NOS	N	N	N	N	N	N	N	N	N	N	N	N	N	N	X	N	N	N	N	N	N	X	N	N	N	X
MUCINOUS CYSTADENOCA, METASTATIC															X							X				X
SIGNET RING CARCINOMA, METASTATIC								X											X							
MALIG.LYMPHOMA, UNDIFFER-TYPE																									
MYELOMONOCYTIC LEUKEMIA																									
MONOCYTIC LEUKEMIA	X	X		X	X	X	X		X	X						X	X	X		X	X	X	X	X	
LEUKEMIA, MONONUCLEAR CELL																									
ADIPOSE TISSUE																									
MUCINOUS CYSTADENOCA, METASTATIC																									
MIXED TUMOR, INVASIVE																									

HWBUI0001738

TABLE B4. INDIVIDUAL ANIMAL TUMOR PATHOLOGY OF FEMALE RATS IN THE LIFETIME FEED STUDY OF INTERMEDIATE-RANGE CHRYSOTILE ASBESTOS: INTERMEDIATE-RANGE PLUS 1,2-DIMETHYLHYDRAZINE DIHYDROCHLORIDE (Continued)

ANIMAL NUMBER	446	447	448	449	450	451	452	453	454	455	456	457	458	459	460	461	462	463	464	465	466	467	468	469	470
WEEKS ON STUDY	073	119	075	093	105	040	113	109	108	110	091	119	093	081	102	088	119	054	116	061	093	011	088	119	119
INTEGUMENTARY SYSTEM																									
SKIN	+	+	+	+	+	N	+	+	+	+	+	N	+	+	+	+	+	+	+	+	+	+	+	+	+
BASAL-CELL TUMOR																									
BASAL-CELL CARCINOMA																									
KERATOACANTHOMA																	X								X
SUBCUTANEOUS TISSUE	+	+	+	+	+	N	+	+	+	+	+	N	+	+	+	+	+	+	+	+	+	+	+	+	+
CARCINOMA, NOS																									
KERATOACANTHOMA																									
FIBROMA																									
FIBROSARCOMA																									
RESPIRATORY SYSTEM																									
LUNGS AND BRONCHI	+	+	+	+	+	+	+	+	+	+	+	+	+	+	+	+	+	+	+	+	+	+	+	+	+
SQUAMOUS CELL CARCINOMA, METASTAT																									
ALVEOLAR/BRONCHIOLAR ADENOMA																									
PHEOCHROMOCYTOMA, METASTATIC																									
LIPOSARCOMA, METASTATIC																									
MIXED TUMOR, METASTATIC														X											
HEMANGIOSARCOMA, METASTATIC																									
TRACHEA	+	+	+	+	+	+	+	+	+	+	+	+	+	+	+	+	+	+	+	+	+	+	+	+	+
NASAL CAVITY	N	N	N	N	N	N	N	N	N	N	N	N	N	N	N	N	N	N	N	N	N	N	N	N	N
SQUAMOUS CELL CARCINOMA																									
HEMATOPOIETIC SYSTEM																									
BONE MARROW	+	+	+	+	+	+	+	+	+	+	+	+	+	+	+	+	+	+	+	+	+	+	+	+	+
SPLEEN	+	+	+	+	+	+	+	+	+	+	+	+	+	+	+	+	+	+	+	+	+	+	+	+	+
LYMPH NODES	+	+	+	+	+	+	+	+	+	+	+	+	+	+	+	+	+	+	+	+	+	+	+	+	+
ADENOCARCINOMA, NOS, METASTATIC																									
MUCINOUS CYSTADENOCA, METASTATIC			X																	X					
SIGNET RING CARCINOMA, METASTATIC																									
THYMUS	-	+	-	+	-	-	+	+	+	+	+	-	+	-	+	+	+	+	+	+	+	+	+	-	-
CIRCULATORY SYSTEM																									
HEART	+	+	+	+	+	+	+	+	+	+	+	+	+	+	+	+	+	+	+	+	+	+	+	+	+
MIXED TUMOR, METASTATIC											X														
NEURILEMOMA																									
DIGESTIVE SYSTEM																									
SALIVARY GLAND	+	+	+	+	+	+	+	-	+	+	+	+	+	+	+	+	+	+	+	+	+	+	+	+	+
LIVER	+	+	+	+	+	+	+	+	+	+	+	+	+	+	+	+	+	+	+	+	+	+	+	+	+
BILE DUCT ADENOMA																									
NEOPLASTIC NODULE							X	X			X				X										
HEPATOCELLULAR CARCINOMA		X									X						X		X						X
MIXED TUMOR, METASTATIC																									
HEMANGIOSARCOMA																									
BILE DUCT	+	+	+	+	+	+	+	+	+	+	+	+	+	+	+	+	+	+	+	+	+	+	+	+	+
GALLBLADDER & COMMON BILE DUCT	N	N	N	N	N	N	N	N	N	N	N	N	N	N	N	N	N	N	N	N	N	N	N	N	N
PANCREAS	+	+	+	+	+	+	+	+	+	+	+	+	+	+	+	+	+	+	+	+	+	+	+	+	+
MIXED TUMOR, INVASIVE																									
MIXED TUMOR, METASTATIC																									
ESOPHAGUS	+	+	+	+	+	+	+	-	+	+	+	+	+	+	+	+	+	+	+	+	+	+	+	+	+
STOMACH	+	+	+	+	+	+	+	-	+	+	+	+	+	+	+	+	+	+	+	+	+	+	+	+	+
SMALL INTESTINE	+	+	+	+	+	+	+	+	+	+	+	+	+	+	+	+	+	+	+	+	+	+	+	+	+
ADENOMATOUS POLYP, NOS																									
ADENOCA IN ADENOMATOUS POLYP																									
MUCINOUS CYSTADENOCARCINOMA																						X			
SIGNET RING CARCINOMA																									
LARGE INTESTINE	+	+	+	+	+	+	+	+	+	X	+	+	+	+	+	+	+	+	+	+	+	+	+	+	+
ADENOCARCINOMA, NOS																									
ADENOMATOUS POLYP, NOS											X				X				X			X			X
ADENOCA IN ADENOMATOUS POLYP																							X		
MUCINOUS CYSTADENOCARCINOMA			X			X						X								X					X
SIGNET RING CARCINOMA																									
URINARY SYSTEM																									
KIDNEY	+	+	+	+	+	+	+	+	+	+	+	+	+	+	+	+	+	+	+	+	+	+	+	+	+
MIXED TUMOR, MALIGNANT	X		X											X					X						
URINARY BLADDER	+	+	+	+	+	+	+	+	+	+	+	+	+	+	+	+	+	+	+	+	+	+	+	+	+

HWBUI0001739

TABLE B4. INDIVIDUAL ANIMAL TUMOR PATHOLOGY OF FEMALE RATS IN THE LIFETIME FEED STUDY OF INTERMEDIATE-RANGE CHRYSOTILE ASBESTOS: INTERMEDIATE-RANGE PLUS 1,2-DIMETHYLHYDRAZINE DIHYDROCHLORIDE (Continued)

ANIMAL NUMBER	446	447	448	449	458	451	452	453	454	455	456	457	458	459	460	461	462	463	464	465	466	467	468	469	470
WEEKS ON STUDY	073	119	075	093	159	040	113	109	108	110	091	119	193	080	102	085	119	054	116	061	093	101	088	119	119
ENDOCRINE SYSTEM																									
PITUITARY	+	+	+	+	+	+	+	+	+	+	+	+	+	+	+	+	+	+	+	+	+	+	+	+	+
CARCINOMA, NOS																									
ADENOMA, NOS		X			X							X					X								X
ADRENAL	+	+	+	+	+	+	+	+	+	+	+	+	+	+	+	+	+	+	+	+	+	+	+	+	+
CORTICAL ADENOMA		X														X									
CORTICAL CARCINOMA																									
PHEOCHROMOCYTOMA																	X								
PHEOCHROMOCYTOMA, MALIGNANT																									
THYROID	+	+	+	+	+	+	+	+	+	+	+	+	+	+	+	+	+	+	+	+	+	+	+	+	+
FOLLICULAR-CELL ADENOMA													X												X
FOLLICULAR-CELL CARCINOMA					X																				
C-CELL ADENOMA											X	X							X			X			
C-CELL CARCINOMA					X																				
PARATHYROID	+	+	+	–	+	+	+	+	+	+	+	+	+	+	+	+	+	+	+	–	+	+	+	+	+
PANCREATIC ISLETS	+	+	+	+	+	+	+	+	+	+	+	+	+	+	+	+	+	+	+	+	+	+	+	+	+
ISLET-CELL ADENOMA																									
ISLET-CELL CARCINOMA																									
REPRODUCTIVE SYSTEM																									
MAMMARY GLAND	+	+	+	+	+	N	+	+	+	+	+	+	+	+	+	+	+	+	+	+	+	+	+	+	+
ADENOMA, NOS																									
ADENOCARCINOMA, NOS																									
FIBROADENOMA							X					X				X	X								X
PREPUTIAL/CLITORAL GLAND	N	N	N	N	N	N	N	N	N	N	N	N	N	N	N	N	N	N	N	N	N	N	N	N	N
CARCINOMA, NOS																									
VAGINA	N	N	N	N	N	N	N	N	N	N	N	N	N	N	N	N	N	N	N	N	N	N	N	N	N
ENDOMETRIAL STROMAL SARCOMA, INVA																									
UTERUS	+	+	+	+	+	+	+	+	+	+	+	+	+	+	+	+	+	+	+	+	+	+	+	+	+
PAPILLARY CARCINOMA																									
ADENOMA, NOS																									
PAPILLARY ADENOMA																									
LEIOMYOSARCOMA																									
ENDOMETRIAL STROMAL POLYP																		X					X		
ENDOMETRIAL STROMAL SARCOMA										X															
ENDOMETRIAL STROMAL SARCOMA, INVA																									
OVARY	+	+	+	+	+	+	+	+	+	+	+	+	+	+	+	+	+	+	+	+	+	+	+	+	+
GRANULOSA-CELL TUMOR																									
NERVOUS SYSTEM																									
BRAIN	+	+	+	+	+	+	+	+	+	+	+	+	+	+	+	+	+	+	+	+	+	+	+	+	+
CARCINOMA, NOS, INVASIVE																									
ASTROCYTOMA																									
SPECIAL SENSE ORGANS																									
EAR	+	+	+	+	+	N	+	+	+	+	+	+	+	+	+	+	+	+	+	+	+	+	+	+	+
SQUAMOUS CELL CARCINOMA																									
ZYMBAL GLAND	+	+	+	+	+	N	+	+	+	+	+	+	+	+	+	+	+	+	+	+	+	+	+	+	+
SQUAMOUS CELL PAPILLOMA							X						X				X			X	X	X		X	
SQUAMOUS CELL CARCINOMA																									
ADENOMA, NOS																									
MUSCULOSKELETAL SYSTEM																									
MUSCLE	N	N	N	N	N	N	N	N	N	N	N	N	N	N	N	N	N	N	N	N	N	N	N	N	N
MIXED TUMOR, INVASIVE																									
BODY CAVITIES																									
MEDIASTINUM	N	N	N	N	N	N	N	N	N	N	N	N	N	N	N	N	N	N	N	N	N	N	N	N	N
MUCINOUS CYSTADENOCA, METASTATIC																				X					
PERITONEUM	N	N	N	N	N	N	N	N	N	N	N	N	N	N	N	N	N	N	N	N	N	N	N	N	N
MIXED TUMOR, INVASIVE																									
MESENTERY	N	N	N	N	N	N	N	N	N	N	N	N	N	N	N	N	N	N	N	N	N	N	N	N	N
MIXED TUMOR, INVASIVE																									
ALL OTHER SYSTEMS																									
MULTIPLE ORGANS NOS	N	N	N	N	N	N	N	N	N	N	N	N	N	N	N	N	N	N	N	N	N	N	N	N	N
MUCINOUS CYSTADENOCA, METASTATIC						X																			
SIGNET RING CARCINOMA, METASTATIC																									
MALIG.LYMPHOMA, UNDIFFER-TYPE																									
MYELOMONOCYTIC LEUKEMIA																									
MONOCYTIC LEUKEMIA		X		X	X		X	X	X	X	X				X		X				X				X
LEUKEMIA, MONONUCLEAR CELL																									
ADIPOSE TISSUE																									
MUCINOUS CYSTADENOCA, METASTATIC			X																						
MIXED TUMOR, INVASIVE	X																	X							

HWBUI0001740

TABLE B4. INDIVIDUAL ANIMAL TUMOR PATHOLOGY OF FEMALE RATS IN THE LIFETIME FEED STUDY OF INTERMEDIATE-RANGE CHRYSOTILE ASBESTOS: INTERMEDIATE-RANGE PLUS 1,2-DIMETHYLHYDRAZINE DIHYDROCHLORIDE (Continued)

ANIMAL NUMBER	47712	47723	47734	47745	47756	47767	47778	47789	48001	48012	48023	48034	48045	48056	48067	48078	48089	48091	48102	48113	48124	48135
WEEKS ON STUDY	10117	10185	10116	11148	00407	07414	11419	00793	00984	01190	10990	11099	11195	11195	08516	10162	08898	10862	08921	08111	09193	09353
INTEGUMENTARY SYSTEM																						
SKIN	+	+	+	+	+	+	+	+	+	+	+	+	+	+	+	+	+	+	+	+	+	+
BASAL-CELL TUMOR																						
BASAL-CELL CARCINOMA																						
KERATOACANTHOMA																						
SUBCUTANEOUS TISSUE	+	+	+	+	+	+	+	+	+	+	+	+	+	+	+	+	+	+	+	+	+	+
CARCINOMA, NOS																						
KERATOACANTHOMA																						
FIBROMA																						
FIBROSARCOMA																						
RESPIRATORY SYSTEM																						
LUNGS AND BRONCHI	+	+	+	+	+	+	+	+	+	+	+	+	+	+	+	+	+	+	+	+	+	+
SQUAMOUS CELL CARCINOMA, METASTAT																						
ALVEOLAR/BRONCHIOLAR ADENOMA																						
PHEOCHROMOCYTOMA, METASTATIC																						
LIPOSARCOMA, METASTATIC																						
MIXED TUMOR, METASTATIC																						
HEMANGIOSARCOMA, METASTATIC																						
TRACHEA	+	+	+	+	+	+	+	+	+	+	+	+	+	+	+	+	+	+	+	+	+	+
NASAL CAVITY	N	N	N	N	N	N	N	N	N	N	N	N	N	N	N	N	N	N	N	N	N	N
SQUAMOUS CELL CARCINOMA																						
HEMATOPOIETIC SYSTEM																						
BONE MARROW	+	+	+	+	+	+	+	+	+	+	+	+	+	+	+	+	+	+	+	+	+	+
SPLEEN	+	+	+	+	+	+	+	+	+	+	+	+	+	+	+	+	+	+	+	+	+	+
LYMPH NODES	+	+	+	+	+	+	+	+	+	+	+	+	+	+	+	+	+	+	+	+	+	+
ADENOCARCINOMA, NOS, METASTATIC																						
MUCINOUS CYSTADENOCA, METASTATIC																						
SIGNET RING CARCINOMA, METASTATIC																						
THYMUS	+	+	+	+	+	–	–	+	+	+	+	–	+	+	+	+	+	+	+	+	+	+
CIRCULATORY SYSTEM																						
HEART	+	+	+	+	+	+	+	+	+	+	+	+	+	+	+	+	+	+	+	+	+	+
MIXED TUMOR, METASTATIC																						
NEURILEMOMA																						
DIGESTIVE SYSTEM																						
SALIVARY GLAND	+	+	+	+	+	+	+	+	+	+	+	+	+	+	+	+	+	+	+	+	+	+
LIVER	+	+	+	+	+	+	+	+	+	+	+	+	+	+	+	+	+	+	+	+	+	+
BILE DUCT ADENOMA																						
NEOPLASTIC NODULE								X			X						X		X			
HEPATOCELLULAR CARCINOMA		X									X			X				X				X
MIXED TUMOR, METASTATIC								X														
HEMANGIOSARCOMA																						
BILE DUCT	+	+	+	+	+	+	+	+	+	+	+	+	+	+	+	+	+	+	+	+	+	+
GALLBLADDER & COMMON BILE DUCT	N	N	N	N	N	N	N	N	N	N	N	N	N	N	N	N	N	N	N	N	N	N
PANCREAS	+	+	+	+	+	+	+	+	+	+	+	+	+	+	+	+	+	+	+	+	+	+
MIXED TUMOR, INVASIVE									X													
MIXED TUMOR, METASTATIC																						
ESOPHAGUS	+	+	+	+	+	+	+	+	+	+	+	+	+	+	+	–	+	+	+	+	+	+
STOMACH	+	+	+	+	+	+	+	+	+	+	+	+	+	+	+	+	+	+	+	+	+	+
SMALL INTESTINE	+	+	+	+	+	+	+	+	+	+	+	+	+	+	+	+	+	+	+	+	+	+
ADENOMATOUS POLYP, NOS																						
ADENOCA IN ADENOMATOUS POLYP																						
MUCINOUS CYSTADENOCARCINOMA																						
SIGNET RING CARCINOMA																		X				
LARGE INTESTINE	+	+	+	+	+	+	+	+	+	+	+	+	+	+	+	+	+	+	+	+	+	+
ADENOCARCINOMA, NOS																						
ADENOMATOUS POLYP, NOS										X			X				X					
ADENOCA IN ADENOMATOUS POLYP																	X				X	
MUCINOUS CYSTADENOCARCINOMA											X											
SIGNET RING CARCINOMA				X																		
URINARY SYSTEM																						
KIDNEY	+	+	+	+	+	+	+	+	+	+	+	+	+	+	+	+	+	+	+	+	+	+
MIXED TUMOR, MALIGNANT					X	X			X							X						
URINARY BLADDER	+	+	+	+	+	+	+	+	+	+	+	+	+	+	+	+	+	+	+	+	+	+

HWBUI0001741

TABLE B4. INDIVIDUAL ANIMAL TUMOR PATHOLOGY OF FEMALE RATS IN THE LIFETIME FEED STUDY OF INTERMEDIATE-RANGE CHRYSOTILE ASBESTOS: INTERMEDIATE-RANGE PLUS 1,2-DIMETHYLHYDRAZINE DIHYDROCHLORIDE (Continued)

ANIMAL NUMBER	71	72	73	74	75	76	77	78	79	80	81	82	83	84	85	86	87	88	89	90	91	92	93	94	95
WEEKS ON STUDY	117	083	104	117	046	070	074	114	073	093	086	112	090	119	119	116	065	142	082	096	046	082	110	119	093
ENDOCRINE SYSTEM																									
PITUITARY	+	+	+	+	+	-	+	+	+	+	+	+	+	+	+	+	+	+	+	+	+	+	+	+	+
CARCINOMA, NOS																									
ADENOMA, NOS	X		X	X							X	X		X	X					X	X		X	X	
ADRENAL	+	+	+	+	+	+	+	+	+	+	+	+	+	+	+	+	+	+	+	+	+	+	+	+	+
CORTICAL ADENOMA																									
CORTICAL CARCINOMA																									
PHEOCHROMOCYTOMA																					X		X		
PHEOCHROMOCYTOMA, MALIGNANT																									
THYROID	+	+	+	+	+	+	+	+	+	+	+	+	+	+	+	+	+	+	+	+	+	+	+	+	+
FOLLICULAR-CELL ADENOMA		X								X				X											
FOLLICULAR-CELL CARCINOMA			X												X										
C-CELL ADENOMA								X				X													
C-CELL CARCINOMA	X																								
PARATHYROID	+	+	-	+	+	-	+	+	+	+	+	+	+	+	+	-	+	+	-	+	+	+	+	+	-
PANCREATIC ISLETS	+	+	+	+	+	+	+	+	+	+	+	+	+	+	+	+	+	+	+	+	+	+	+	+	+
ISLET-CELL ADENOMA																									
ISLET-CELL CARCINOMA																									
REPRODUCTIVE SYSTEM																									
MAMMARY GLAND	+	+	+	+	+	+	+	+	+	+	+	+	+	+	+	+	+	+	+	+	+	+	+	+	+
ADENOMA, NOS															X										
ADENOCARCINOMA, NOS																									
FIBROADENOMA				X				X				X												X	
PREPUTIAL/CLITORAL GLAND	N	N	N	N	N	N	N	N	N	N	N	N	N	N	N	N	N	N	N	N	N	N	N	N	N
CARCINOMA, NOS																									
VAGINA	N	N	N	N	N	N	N	N	N	N	N	N	N	N	N	N	N	N	N	N	N	N	N	N	N
ENDOMETRIAL STROMAL SARCOMA, INVA																									
UTERUS	+	+	+	+	+	+	+	+	+	+	+	+	+	+	+	+	+	+	+	+	+	+	+	+	+
PAPILLARY CARCINOMA																									
ADENOMA, NOS																								X	
PAPILLARY ADENOMA																		X							
LEIOMYOSARCOMA																									
ENDOMETRIAL STROMAL POLYP													X							X		X			
ENDOMETRIAL STROMAL SARCOMA																									
ENDOMETRIAL STROMAL SARCOMA, INVA																									
OVARY	+	+	+	+	+	+	+	+	+	+	+	+	+	+	+	+	+	+	+	+	+	+	+	+	+
GRANULOSA-CELL TUMOR																									
NERVOUS SYSTEM																									
BRAIN	+	+	+	+	+	+	+	+	+	+	+	+	+	+	+	+	+	+	+	+	+	+	+	+	+
CARCINOMA, NOS, INVASIVE																									
ASTROCYTOMA																									
SPECIAL SENSE ORGANS																									
EAR	+	+	+	+	+	+	+	+	+	+	+	+	+	+	+	+	N	+	+	+	+	+	+	+	+
SQUAMOUS CELL CARCINOMA																									
ZYMBAL GLAND	+	+	+	+	+	+	+	+	+	+	+	+	+	+	+	+	N	+	+	+	+	+	+	+	+
SQUAMOUS CELL PAPILLOMA																									X
SQUAMOUS CELL CARCINOMA			X	X		X		X														X			
ADENOMA, NOS																									
MUSCULOSKELETAL SYSTEM																									
MUSCLE	N	N	N	N	N	N	N	N	N	N	N	N	N	N	N	N	+	N	N	N	N	N	N	N	N
MIXED TUMOR, INVASIVE																									
BODY CAVITIES																									
MEDIASTINUM	N	N	N	N	N	N	N	N	N	N	N	N	N	N	N	N	N	N	N	N	N	N	N	N	N
MUCINOUS CYSTADENOCA, METASTATIC																									
PERITONEUM	N	N	N	N	N	N	N	N	N	N	N	N	N	N	N	N	N	N	N	N	N	N	N	N	N
MIXED TUMOR, INVASIVE																									
MESENTERY	N	N	N	N	N	N	N	N	N	N	N	N	N	N	N	N	N	N	N	N	N	N	N	N	N
MIXED TUMOR, INVASIVE																									
ALL OTHER SYSTEMS																									
MULTIPLE ORGANS NOS	N	N	N	N	N	N	N	N	N	N	N	N	N	N	N	N	N	N	N	N	N	N	N	N	N
MUCINOUS CYSTADENOCA, METASTATIC											X														
SIGNET RING CARCINOMA, METASTATIC																					X				
MALIG.LYMPHOMA, UNDIFFER-TYPE																									
MYELOMONOCYTIC LEUKEMIA																									
MONOCYTIC LEUKEMIA	X	X		X				X		X		X	X	X				X		X	X				X
LEUKEMIA, MONONUCLEAR CELL																									
ADIPOSE TISSUE																									
MUCINOUS CYSTADENOCA, METASTATIC																									
MIXED TUMOR, INVASIVE																									

HWBUI0001742

TABLE B4. INDIVIDUAL ANIMAL TUMOR PATHOLOGY OF FEMALE RATS IN THE LIFETIME FEED STUDY OF INTERMEDIATE-RANGE CHRYSOTILE ASBESTOS: INTERMEDIATE-RANGE PLUS 1,2-DIMETHYLHYDRAZINE DIHYDROCHLORIDE (Continued)

ANIMAL NUMBER	49 96	49 97	49 98	49 99	50 00	50 01	50 02	50 03	50 04	50 05	50 06	50 07	50 08	50 09	51 10	51 11	51 12	51 13	51 14	51 15	51 16	51 17	51 18	51 19	52 00
WEEKS ON STUDY	111 9	111 6	111 8	108	087 3	082	086	109	085	112	092	067	084	093	117	111 4	111 9	099 8	055 8	068 8	070 1	085 1	066 1	068 2	112
INTEGUMENTARY SYSTEM																									
SKIN	+	+	+	+	+	+	+	+	+	+	+	+	+	+	+	+	+	+	+	+	+	+	+	+	+
BASAL-CELL TUMOR																									
BASAL-CELL CARCINOMA																									
KERATOACANTHOMA																									
SUBCUTANEOUS TISSUE	+	+	+	+	+	+	+	+	+	+	+	+	+	+	+	+	+	+	+	+	+	+	+	+	+
CARCINOMA, NOS																									
KERATOACANTHOMA								X																	
FIBROMA																									
FIBROSARCOMA																									
RESPIRATORY SYSTEM																									
LUNGS AND BRONCHI	+	+	+	+	+	+	+	+	+	+	+	+	+	+	+	+	+	+	+	+	+	+	+	+	+
SQUAMOUS CELL CARCINOMA, METASTAT																	X								
ALVEOLAR/BRONCHIOLAR ADENOMA																									
PHEOCHROMOCYTOMA, METASTATIC																									
LIPOSARCOMA, METASTATIC																									
MIXED TUMOR, METASTATIC		X																					X		
HEMANGIOSARCOMA, METASTATIC								X																	
TRACHEA	+	+	+	+	+	+	+	+	+	+	+	+	+	+	+	+	+	+	+	+	+	+	+	+	+
NASAL CAVITY	N	N	N	N	N	N	N	+	N	N	N	N	N	N	N	N	N	N	N	N	N	N	N	N	N
SQUAMOUS CELL CARCINOMA								X																	
HEMATOPOIETIC SYSTEM																									
BONE MARROW	+	+	+	+	+	+	+	+	+	+	+	+	+	+	+	+	+	+	+	+	+	+	+	+	+
SPLEEN	+	+	+	+	+	+	+	+	+	+	+	+	+	+	+	+	+	+	+	+	+	+	+	+	+
LYMPH NODES	+	+	+	+	+	+	+	+	+	+	+	+	+	+	+	+	+	+	+	+	+	+	+	+	+
ADENOCARCINOMA, NOS, METASTATIC											X														
MUCINOUS CYSTADENOCA, METASTATIC																									
SIGNET RING CARCINOMA, METASTATIC																									
THYMUS	-	+	+	+	-	+	+	+	+	+	+	+	+	-	+	+	+	-	+	+	-	-	+	+	+
CIRCULATORY SYSTEM																									
HEART	+	+	+	+	+	+	+	+	+	+	+	+	+	+	+	+	+	+	+	+	+	+	+	+	+
MIXED TUMOR, METASTATIC																									
NEURILEMOMA																									
DIGESTIVE SYSTEM																									
SALIVARY GLAND	+	+	+	+	+	+	+	-	+	+	+	+	+	+	+	+	+	+	+	+	+	+	+	+	+
LIVER	+	+	+	+	+	+	+	+	+	+	+	+	+	+	+	+	+	+	+	+	+	+	+	+	+
BILE DUCT ADENOMA																									
NEOPLASTIC NODULE																									X
HEPATOCELLULAR CARCINOMA																X									
MIXED TUMOR, METASTATIC																									
HEMANGIOSARCOMA								X																	
BILE DUCT	+	+	+	+	+	+	+	+	+	+	+	+	+	+	+	+	+	+	+	+	+	+	+	+	+
GALLBLADDER & COMMON BILE DUCT	N	N	N	N	N	N	N	N	N	N	N	N	N	N	N	N	N	N	N	N	N	N	N	N	N
PANCREAS	+	+	+	+	+	+	+	+	+	+	+	+	+	+	+	+	+	+	+	+	+	+	+	+	+
MIXED TUMOR, INVASIVE																									
MIXED TUMOR, METASTATIC																									
ESOPHAGUS	+	+	+	+	+	+	+	+	+	+	+	+	+	+	+	+	+	+	+	+	+	+	+	+	+
STOMACH	+	+	+	+	+	+	+	+	+	+	+	+	+	+	+	+	+	+	+	+	+	+	+	+	+
SMALL INTESTINE	+	+	+	+	+	+	+	+	+	+	+	+	+	+	+	+	+	+	+	+	+	+	+	+	+
ADENOMATOUS POLYP, NOS																									
ADENOCA IN ADENOMATOUS POLYP																									
MUCINOUS CYSTADENOCARCINOMA																									
SIGNET RING CARCINOMA																									
LARGE INTESTINE	+	+	+	+	+	+	+	+	+	+	+	+	+	+	+	+	+	+	+	+	+	+	+	+	+
ADENOCARCINOMA, NOS											X														
ADENOMATOUS POLYP, NOS		X				xa	xa		X			X	X			X	X					X			
ADENOCA IN ADENOMATOUS POLYP						X																			
MUCINOUS CYSTADENOCARCINOMA					X																X				
SIGNET RING CARCINOMA									X																
URINARY SYSTEM																									
KIDNEY	+	+	+	+	+	+	+	+	+	+	+	+	+	+	+	+	+	+	+	+	+	+	+	+	+
MIXED TUMOR, MALIGNANT		X	X				X								X				X	X		X	X		
URINARY BLADDER	+	+	+	+	+	+	+	+	+	+	+	+	+	+	+	+	+	+	+	+	+	+	+	+	+

a: MULTIPLE OCCURENCE OF MORPHOLOGY

HWBUI0001743

TABLE B4. INDIVIDUAL ANIMAL TUMOR PATHOLOGY OF FEMALE RATS IN THE LIFETIME FEED STUDY OF INTERMEDIATE-RANGE CHRYSOTILE ASBESTOS: INTERMEDIATE-RANGE PLUS 1,2-DIMETHYLHYDRAZINE DIHYDROCHLORIDE (Continued)

ANIMAL NUMBER	4 9 6	4 9 7	4 9 8	4 9 9	5 0 1	5 0 1	5 0 2	5 0 3	5 0 4	5 0 5	5 0 6	5 0 7	5 0 8	5 0 9	5 1 0	5 1 1	5 1 2	5 1 3	5 1 4	5 1 5	5 1 6	5 1 7	5 1 8	5 1 9	5 2 0
WEEKS ON STUDY	1 1 9	1 1 6	1 1 8	1 0 8	0 7 3	0 8 2	0 8 6	1 0 9	0 8 5	1 1 2	0 9 2	0 6 7	0 8 4	0 9 3	1 1 7	1 1 4	1 1 9	0 9 8	0 5 8	0 8 8	0 7 0	0 8 5	0 6 6	0 8 2	1 1 2
ENDOCRINE SYSTEM																									
PITUITARY	+	+	+	+	–	+	+	+	+	+	+	+	+	+	+	+	+	+	+	+	+	+	+	+	+
CARCINOMA, NOS																									
ADENOMA, NOS				X										X	X	X									
ADRENAL	+	+	+	+	+	+	+	+	+	+	+	+	+	+	+	+	+	+	+	+	+	+	+	+	+
CORTICAL ADENOMA														X											
CORTICAL CARCINOMA																									
PHEOCHROMOCYTOMA																									X
PHEOCHROMOCYTOMA, MALIGNANT																									
THYROID	+	+	+	+	+	+	+	+	+	+	+	+	+	+	+	+	+	+	–	+	+	+	+	+	+
FOLLICULAR-CELL ADENOMA		X																							
FOLLICULAR-CELL CARCINOMA																X									
C-CELL ADENOMA			X						X												X			X	
C-CELL CARCINOMA			X																						X
PARATHYROID	+	+	+	+	+	+	+	+	+	+	+	+	+	+	+	+	+	+	–	+	+	+	+	+	+
PANCREATIC ISLETS	+	+	+	+	+	+	+	+	+	+	+	+	+	+	+	+	+	+	+	+	+	+	+	+	+
ISLET-CELL ADENOMA																									
ISLET-CELL CARCINOMA																									
REPRODUCTIVE SYSTEM																									
MAMMARY GLAND	+	+	+	+	+	+	+	+	+	+	+	+	+	+	+	+	+	+	+	+	+	+	+	+	+
ADENOMA, NOS								X																	
ADENOCARCINOMA, NOS																									
FIBROADENOMA		X	X	X											X							X			X
PREPUTIAL/CLITORAL GLAND	N	N	N	N	N	N	N	N	N	N	N	N	N	N	N	N	N	N	N	N	N	N	N	N	N
CARCINOMA, NOS								X																	
VAGINA	N	N	N	N	N	N	N	N	N	N	N	N	N	N	N	N	N	N	N	N	N	N	N	N	N
ENDOMETRIAL STROMAL SARCOMA, INVA																									
UTERUS	+	+	+	+	+	+	+	+	+	+	+	+	+	+	+	+	+	+	+	+	+	+	+	+	+
PAPILLARY CARCINOMA									X																
ADENOMA, NOS																									
PAPILLARY ADENOMA																									
LEIOMYOSARCOMA																									
ENDOMETRIAL STROMAL POLYP									X						X										
ENDOMETRIAL STROMAL SARCOMA																									
ENDOMETRIAL STROMAL SARCOMA, INVA																									
OVARY	+	+	+	+	+	+	+	+	+	+	+	+	+	+	+	+	+	+	+	+	+	+	+	+	+
GRANULOSA-CELL TUMOR				X																					
NERVOUS SYSTEM																									
BRAIN	+	+	+	+	+	+	+	+	+	+	+	+	+	+	+	+	+	+	+	+	+	+	+	+	+
CARCINOMA, NOS, INVASIVE																									
ASTROCYTOMA																									
SPECIAL SENSE ORGANS																									
EAR	+	+	+	+	+	+	+	+	+	+	+	N	+	+	+	+	+	+	+	+	+	+	+	+	+
SQUAMOUS CELL CARCINOMA																	X								
ZYMBAL GLAND	+	+	+	+	+	+	+	+	+	+	+	N	+	+	+	+	+	+	+	+	+	+	+	+	+
SQUAMOUS CELL PAPILLOMA								X																	
SQUAMOUS CELL CARCINOMA				X							X			X	X										
ADENOMA, NOS					X																				
MUSCULOSKELETAL SYSTEM																									
MUSCLE	N	N	N	N	N	N	N	N	N	N	N	N	N	N	N	N	N	N	N	N	N	N	N	N	N
MIXED TUMOR, INVASIVE																							X		
BODY CAVITIES																									
MEDIASTINUM	N	N	N	N	N	N	N	N	N	N	N	N	N	N	N	N	N	N	N	N	N	N	N	N	N
MUCINOUS CYSTADENOCA, METASTATIC																									
PERITONEUM	N	N	N	N	N	N	N	N	N	N	N	N	N	N	N	N	N	N	N	N	N	N	N	N	N
MIXED TUMOR, INVASIVE																									
MESENTERY	N	N	N	N	N	N	N	N	N	N	N	N	N	N	N	N	N	N	N	N	N	N	N	N	N
MIXED TUMOR, INVASIVE																									
ALL OTHER SYSTEMS																									
MULTIPLE ORGANS NOS	N	N	N	N	N	N	N	N	N	N	N	N	N	N	N	N	N	N	N	N	N	N	N	N	N
MUCINOUS CYSTADENOCA, METASTATIC					X																X				
SIGNET RING CARCINOMA, METASTATIC									X																
MALIG.LYMPHOMA, UNDIFFER-TYPE																									
MYELOMONOCYTIC LEUKEMIA																									
MONOCYTIC LEUKEMIA			X	X							X		X	X	X		X	X					X	X	
LEUKEMIA, MONONUCLEAR CELL																					X				
ADIPOSE TISSUE																									
MUCINOUS CYSTADENOCA, METASTATIC																									
MIXED TUMOR, INVASIVE																							X		

HWBUI0001744

TABLE B4. INDIVIDUAL ANIMAL TUMOR PATHOLOGY OF FEMALE RATS IN THE LIFETIME FEED STUDY OF INTERMEDIATE-RANGE CHRYSOTILE ASBESTOS: INTERMEDIATE-RANGE PLUS 1,2-DIMETHYLHYDRAZINE DIHYDROCHLORIDE (Continued)

ANIMAL NUMBER / WEEKS ON STUDY	TOTAL TISSUES TUMORS
INTEGUMENTARY SYSTEM	
SKIN	175M
BASAL-CELL TUMOR	1
BASAL-CELL CARCINOMA	1
KERATOACANTHOMA	2
SUBCUTANEOUS TISSUE	175M
CARCINOMA, NOS	1
KERATOACANTHOMA	1
FIBROMA	1
FIBROSARCOMA	1
RESPIRATORY SYSTEM	
LUNGS AND BRONCHI	175
SQUAMOUS CELL CARCINOMA, METASTAT	1
ALVEOLAR/BRONCHIOLAR ADENOMA	1
PHEOCHROMOCYTOMA, METASTATIC	1
LIPOSARCOMA, METASTATIC	1
MIXED TUMOR, METASTATIC	5
HEMANGIOSARCOMA, METASTATIC	1
TRACHEA	175
NASAL CAVITY	175M
SQUAMOUS CELL CARCINOMA	1
HEMATOPOIETIC SYSTEM	
BONE MARROW	174
SPLEEN	175
LYMPH NODES	175
ADENOCARCINOMA, NOS, METASTATIC	1
MUCINOUS CYSTADENOCA, METASTATIC	2
SIGNET RING CARCINOMA, METASTATIC	1
THYMUS	166
CIRCULATORY SYSTEM	
HEART	175
MIXED TUMOR, METASTATIC	1
NEURILEMOMA	1
DIGESTIVE SYSTEM	
SALIVARY GLAND	173
LIVER	175
BILE DUCT ADENOMA	1
NEOPLASTIC NODULE	21
HEPATOCELLULAR CARCINOMA	19
MIXED TUMOR, METASTATIC	2
HEMANGIOSARCOMA	1
BILE DUCT	175
GALLBLADDER & COMMON BILE DUCT	175M
PANCREAS	175
MIXED TUMOR, INVASIVE	1
MIXED TUMOR, METASTATIC	1
ESOPHAGUS	173
STOMACH	174
SMALL INTESTINE	175
ADENOMATOUS POLYP, NOS	1
ADENOCA IN ADENOMATOUS POLYP	1
MUCINOUS CYSTADENOCARCINOMA	3
SIGNET RING CARCINOMA	2
LARGE INTESTINE	175
ADENOCARCINOMA, NOS	3
ADENOMATOUS POLYP, NOS	46
ADENOCA IN ADENOMATOUS POLYP	6
MUCINOUS CYSTADENOCARCINOMA	16
SIGNET RING CARCINOMA	2
URINARY SYSTEM	
KIDNEY	175
MIXED TUMOR, MALIGNANT	34
URINARY BLADDER	175

HWBUI0001745

TABLE B4. INDIVIDUAL ANIMAL TUMOR PATHOLOGY OF FEMALE RATS IN THE LIFETIME FEED STUDY OF INTERMEDIATE-RANGE CHRYSOTILE ASBESTOS: INTERMEDIATE-RANGE PLUS 1,2-DIMETHYLHYDRAZINE DIHYDROCHLORIDE (Continued)

ANIMAL NUMBER	52101	52102	52103	52104	52105	52106	52107	52108	52109	52110	52111	52112	52113	52114	52115	52116	52117	52118	52119	52120	52121	52122	52123	52124	52125	TOTAL TISSUES TUMORS
WEEKS ON STUDY	09 3	08 2	02 2	11 8	09 3	09 3	10 4	08 5	09 4	10 1	08 6	06 1	09 3	07 3	09 0	11 9	11 9	07 9	09 2	08 9	09 3	07 8	07 9	11 9	11 5	
ENDOCRINE SYSTEM																										
PITUITARY	+	+	+	+	+	+	+	+	+	+	+	+	+	+	+	+	+	+	+	+	+	+	+	+	+	173
CARCINOMA, NOS																										1
ADENOMA, NOS									X						X							X		X	X	51
ADRENAL	+	+	+	+	+	+	+	+	+	+	+	+	+	+	+	+	+	+	+	+	+	+	+	+	+	175
CORTICAL ADENOMA																X										6
CORTICAL CARCINOMA																										1
PHEOCHROMOCYTOMA																										8
PHEOCHROMOCYTOMA, MALIGNANT																										1
THYROID	+	+	+	+	+	+	+	+	+	+	+	+	+	+	+	+	+	+	+	+	+	+	+	+	+	174
FOLLICULAR-CELL ADENOMA																X										9
FOLLICULAR-CELL CARCINOMA																						X				7
C-CELL ADENOMA							X												X							18
C-CELL CARCINOMA				X	X				X	X																12
PARATHYROID	+	+	+	+	+	+	+	+	+	+	+	+	+	+	+	+	+	+	+	+	+	+	+	+	+	164
PANCREATIC ISLETS	+	+	+	+	+	+	+	+	+	+	+	+	+	+	+	+	+	+	+	+	+	+	+	+	+	175
ISLET-CELL ADENOMA																X										1
ISLET-CELL CARCINOMA																			X							1
REPRODUCTIVE SYSTEM																										
MAMMARY GLAND	+	+	+	+	+	+	+	+	+	+	+	+	+	+	+	+	+	+	+	+	+	+	+	+	+	175M
ADENOMA, NOS					X																					5
ADENOCARCINOMA, NOS																										1
FIBROADENOMA				X					X				X											X	X	41
PREPUTIAL/CLITORAL GLAND	N	N	N	N	N	N	N	N	N	N	N	N	N	N	N	N	N	N	N	N	N	N	N	N	N	175M
CARCINOMA, NOS																										4
VAGINA	N	N	N	N	N	N	N	N	N	N	N	N	N	N	N	N	N	N	N	N	N	N	N	N	N	175M
ENDOMETRIAL STROMAL SARCOMA, INVA																										1
UTERUS	+	+	+	+	+	+	+	+	+	+	+	+	+	+	+	+	+	+	+	+	+	+	+	+	+	175
PAPILLARY CARCINOMA																										1
ADENOMA, NOS																					X					4
PAPILLARY ADENOMA																										1
LEIOMYOSARCOMA																										1
ENDOMETRIAL STROMAL POLYP						X																		X		15
ENDOMETRIAL STROMAL SARCOMA																										3
ENDOMETRIAL STROMAL SARCOMA, INVA																										1
OVARY	+	+	+	+	+	+	+	+	+	+	+	+	+	+	+	+	+	+	+	+	+	+	+	+	+	174
GRANULOSA-CELL TUMOR																										1
NERVOUS SYSTEM																										
BRAIN	+	+	+	+	+	+	+	+	+	+	+	+	+	+	+	+	+	+	+	+	+	+	+	+	+	175
CARCINOMA, NOS, INVASIVE																										1
ASTROCYTOMA																										1
SPECIAL SENSE ORGANS																										
EAR	+	+	N	+	+	+	+	+	+	+	+	+	+	N	+	+	+	+	+	+	+	+	+	+	+	175M
SQUAMOUS CELL CARCINOMA																										1
ZYMBAL GLAND	+	+	N	+	+	+	+	+	+	+	+	+	+	N	+	+	+	+	+	+	+	+	+	+	+	175M
SQUAMOUS CELL PAPILLOMA																										2
SQUAMOUS CELL CARCINOMA							X		X				X													26
ADENOMA, NOS																										1
MUSCULOSKELETAL SYSTEM																										
MUSCLE	N	N	N	N	N	N	N	N	N	N	N	N	N	N	N	N	N	N	N	N	N	N	N	N	N	175M
MIXED TUMOR, INVASIVE																										1
BODY CAVITIES																										
MEDIASTINUM	N	N	N	N	N	N	N	N	N	N	N	N	N	N	N	N	N	N	N	N	N	N	N	N	N	175M
MUCINOUS CYSTADENOCA, METASTATIC																										1
PERITONEUM	N	N	N	N	N	N	N	N	N	N	N	N	N	N	N	N	N	N	N	N	N	N	N	N	N	175M
MIXED TUMOR, INVASIVE																										1
MESENTERY	N	N	N	N	N	N	N	N	N	N	N	N	N	N	N	N	N	N	N	N	N	N	N	N	N	175M
MIXED TUMOR, INVASIVE																										1
ALL OTHER SYSTEMS																										
MULTIPLE ORGANS NOS	N	N	N	N	N	N	N	N	N	N	N	N	N	N	N	N	N	N	N	N	N	N	N	N	N	175M
MUCINOUS CYSTADENOCA, METASTATIC								X																		10
SIGNET RING CARCINOMA, METASTATIC		X																								4
MALIG.LYMPHOMA, UNDIFFER-TYPE																										2
MYELOMONOCYTIC LEUKEMIA																										1
MONOCYTIC LEUKEMIA	X			X	X	X	X			X	X			X	X				X	X			X		X	88
LEUKEMIA, MONONUCLEAR CELL									X																	4
ADIPOSE TISSUE																										
MUCINOUS CYSTADENOCA, METASTATIC																										1
MIXED TUMOR, INVASIVE																										3

M ANIMALS NECROPSIED

HWBUI0001746

TABLE B4. INDIVIDUAL ANIMAL TUMOR PATHOLOGY OF FEMALE RATS IN THE LIFETIME FEED STUDY OF INTERMEDIATE-RANGE CHRYSOTILE ASBESTOS: INTERMEDIATE-RANGE AND PREWEANING GAVAGE

ANIMAL NUMBER	64046	64047	64048	64049	64050	64051	64052	64053	64054	64055	64056	64057	64058	64059	64060	64061	64062	64063	64064	64065	64066	64067	64068	64069	64070
WEEKS ON STUDY	111977	114090	115091	122111	122110	111110	112197	123127	114094	110883	119080	111012	112205	122929	114343	114416	111463	110053	122727	123134	122525	123434	123535	123535	123535
INTEGUMENTARY SYSTEM																									
SUBCUTANEOUS TISSUE	+	+	+	+	+	+	+	+	+	+	+	+	+	+	+	+	+	+	+	+	+	+	+	+	+
SARCOMA, NOS				X																					
FIBROMA																									
RESPIRATORY SYSTEM																									
LUNGS AND BRONCHI	+	+	+	+	+	+	+	+	+	+	+	+	+	+	+	+	+	+	+	+	+	+	+	+	+
ALVEOLAR/BRONCHIOLAR ADENOMA																									
ALVEOLAR/BRONCHIOLAR CARCINOMA																									
PAPILLARY ADENOCARCINOMA, METASTA																									
C-CELL CARCINOMA, METASTATIC					X					X															
PHEOCHROMOCYTOMA, METASTATIC																									
TRACHEA	+	+	+	+	+	+	+	+	+	+	+	+	+	+	+	+	+	+	+	+	+	+	+	+	+
HEMATOPOIETIC SYSTEM																									
BONE MARROW	+	+	+	+	+	+	+	+	+	+	+	+	+	+	+	+	+	+	+	+	+	+	+	+	+
SPLEEN	+	+	+	+	+	+	+	+	+	+	+	+	+	+	+	+	+	+	+	+	+	+	+	+	+
LYMPH NODES	+	+	+	+	+	+	+	+	+	+	+	+	+	+	+	+	+	+	+	+	+	+	+	+	+
C-CELL CARCINOMA, METASTATIC					X																				
THYMUS	+	+	+	+	+	+	+	+	+	+	+	+	+	+	+	+	+	+	+	+	+	+	+	+	+
CIRCULATORY SYSTEM																									
HEART	+	+	+	+	+	+	+	+	+	+	+	+	+	+	+	+	+	+	+	+	+	+	+	+	+
PHEOCHROMOCYTOMA, METASTATIC																									
DIGESTIVE SYSTEM																									
ORAL CAVITY	N	N	N	N	N	N	N	N	N	N	N	N	N	N	N	N	N	N	N	N	N	N	N	N	N
SQUAMOUS CELL PAPILLOMA																		X							
SQUAMOUS CELL CARCINOMA																									
SALIVARY GLAND	+	+	+	+	+	+	+	+	+	+	+	+	+	+	+	+	+	+	+	+	+	+	+	+	+
SARCOMA, NOS																									
LIVER	+	+	+	+	+	+	+	+	+	+	+	+	+	+	+	+	+	+	+	+	+	+	+	+	+
NEOPLASTIC NODULE				X																					
BILE DUCT	+	+	+	+	+	+	+	+	+	+	+	+	+	+	+	+	+	+	+	+	+	+	+	+	+
GALLBLADDER & COMMON BILE DUCT	N	N	N	N	N	N	N	N	N	N	N	N	N	N	N	N	N	N	N	N	N	N	N	N	N
PANCREAS	+	+	+	+	+	+	+	+	+	+	+	+	+	+	+	+	+	+	+	+	+	+	+	+	+
ACINAR-CELL ADENOMA																									
ESOPHAGUS	+	+	+	+	+	+	+	+	+	+	+	+	+	+	+	+	+	+	+	+	+	+	+	+	+
STOMACH	+	+	+	+	+	+	+	+	+	+	+	+	+	+	+	+	+	+	+	+	+	+	+	+	+
SQUAMOUS CELL PAPILLOMA																									
SQUAMOUS CELL CARCINOMA																									
SMALL INTESTINE	+	+	+	+	+	+	+	+	+	+	+	+	+	+	+	+	+	+	+	+	+	+	+	+	+
LARGE INTESTINE	+	+	+	+	+	+	+	+	+	+	+	+	+	+	+	+	+	+	+	+	+	+	+	+	+
LEIOMYOMA																									
URINARY SYSTEM																									
KIDNEY	+	+	+	+	+	+	+	+	+	+	+	+	+	+	+	+	+	+	+	+	+	+	+	+	+
TUBULAR-CELL ADENOCARCINOMA							X																		
URINARY BLADDER	+	+	+	+	+	+	+	+	+	+	+	+	+	+	+	+	+	+	+	+	+	-	+	+	+
TRANSITIONAL-CELL PAPILLOMA																	X								

+: TISSUE EXAMINED MICROSCOPICALLY
-: REQUIRED TISSUE NOT EXAMINED MICROSCOPICALLY
X: TUMOR INCIDENCE
N: NECROPSY, NO AUTOLYSIS, NO MICROSCOPIC EXAMINATION
S: ANIMAL MIS-SEXED
I: NO TISSUE INFORMATION SUBMITTED
C: NECROPSY, NO HISTOLOGY DUE TO PROTOCOL
A: AUTOLYSIS
M: ANIMAL MISSING
B: NO NECROPSY PERFORMED

HWBUI0001747

TABLE B4. INDIVIDUAL ANIMAL TUMOR PATHOLOGY OF FEMALE RATS IN THE LIFETIME FEED STUDY OF INTERMEDIATE-RANGE CHRYSOTILE ASBESTOS: INTERMEDIATE-RANGE AND PREWEANING GAVAGE (Continued)

ANIMAL NUMBER	6 4 6	6 4 7	6 4 8	6 4 9	6 5 0	6 5 1	6 5 2	6 5 3	6 5 4	6 5 5	6 5 6	6 5 7	6 5 8	6 5 9	6 6 0	6 6 1	6 6 2	6 6 3	6 6 4	6 6 5	6 6 6	6 6 7	6 6 8	6 6 9	6 7 0
WEEKS ON STUDY	1 1 7	1 4 9	1 0 9	1 2 1	1 2 1	1 1 0	1 1 9	1 2 7	1 4 4	1 8 5	0 9 0	1 1 2	1 0 5	1 2 2	1 2 9	1 4 3	1 4 6	1 1 5	1 4 6	1 0 3	1 2 7	1 3 4	1 2 5	1 3 4	1 3 5
ENDOCRINE SYSTEM																									
PITUITARY	+	+	+	+	+	+	+	+	+	+	+	+	+	+	+	+	+	+	+	+	+	+	+	+	+
CARCINOMA, NOS																									
ADENOMA, NOS	X	X					X			X	X	X				X	X	X			X	X	X	X	X
ADRENAL	+	+	+	+	+	+	+	+	+	+	+	+	+	+	+	+	+	+	+	+	+	+	+	+	+
CORTICAL ADENOMA				X																					
PHEOCHROMOCYTOMA		X															X								
PHEOCHROMOCYTOMA, MALIGNANT																									
GANGLIONEUROMA																									
THYROID	+	+	+	+	+	+	+	+	+	+	+	+	+	+	+	+	+	+	+	+	+	+	+	+	+
FOLLICULAR-CELL ADENOMA						X																			
FOLLICULAR-CELL CARCINOMA		X																							
C-CELL ADENOMA					X				X						X	X			X				X	X	
C-CELL CARCINOMA		X			X												X								
PARATHYROID	+	+	+	+	+	+	+	+	+	+	-	+	+	+	+	+	+	+	+	+	+	+	+	+	+
ADENOMA, NOS																X									
PANCREATIC ISLETS	+	+	+	+	+	+	+	+	+	+	+	+	+	+	+	+	+	+	+	+	+	+	+	+	+
ISLET-CELL ADENOMA																									
ISLET-CELL CARCINOMA																					X				
REPRODUCTIVE SYSTEM																									
MAMMARY GLAND	+	+	+	+	+	+	+	+	+	+	+	+	+	+	+	+	+	+	+	+	+	+	+	+	+
CARCINOMA, NOS																									
ADENOMA, NOS							X														X		X		X
ADENOCARCINOMA, NOS						X																			
FIBROADENOMA	X	X		X	X	X	X	X	X	X			X	X	X	X				X	X	X		X	X
CHONDROMA																						X			
PREPUTIAL/CLITORAL GLAND	N	N	N	N	N	N	N	N	N	N	N	N	N	N	N	N	N	N	N	N	N	N	N	N	N
CARCINOMA, NOS									X																
VAGINA	N	N	N	N	N	N	N	N	N	N	N	N	N	N	N	N	N	N	N	N	N	N	N	N	N
ENDOMETRIAL STROMAL POLYP																									
UTERUS	+	+	+	+	+	+	+	+	+	+	+	+	+	+	+	+	+	+	+	+	+	+	+	+	+
PAPILLARY ADENOCARCINOMA									X																
PAPILLARY CYSTADENOMA, NOS																									
ENDOMETRIAL STROMAL POLYP															X	X									
ENDOMETRIAL STROMAL SARCOMA								X																	
ENDOMETRIAL STROMAL SARCOMA, INVA								X																	
OVARY	+	+	+	+	+	+	+	+	+	+	+	+	+	+	+	+	+	+	+	+	+	+	+	+	+
GRANULOSA-CELL TUMOR																									
NERVOUS SYSTEM																									
BRAIN	+	+	+	+	+	+	+	+	+	+	+	+	+	+	+	+	+	+	+	+	+	+	+	+	+
CARCINOMA, NOS, INVASIVE																									
GRANULAR-CELL TUMOR, NOS																						X			
GLIOMA, NOS														X											
ASTROCYTOMA																				X					
SPECIAL SENSE ORGANS																									
ZYMBAL GLAND	+	+	+	+	+	+	+	+	+	+	+	+	+	+	+	+	+	+	+	+	+	+	+	+	+
SQUAMOUS CELL CARCINOMA																									
SARCOMA, NOS, INVASIVE																									
MUSCULOSKELETAL SYSTEM																									
MUSCLE	N	N	N	N	N	N	N	N	N	N	N	N	N	N	N	N	N	N	N	N	N	N	N	N	N
RHABDOMYOSARCOMA																									
BODY CAVITIES																									
MESENTERY	N	N	N	N	N	N	N	N	N	N	N	N	N	N	N	N	N	N	N	N	N	N	N	N	N
SQUAMOUS CELL CARCINOMA, INVASIVE																									
ALL OTHER SYSTEMS																									
MULTIPLE ORGANS NOS	N	N	N	N	N	N	N	N	N	N	N	N	N	N	N	N	N	N	N	N	N	N	N	N	N
MONOCYTIC LEUKEMIA	X		X		X																			X	
LEUKEMIA, MONONUCLEAR CELL																	X	X							

HWBUI0001748

TABLE B4. INDIVIDUAL ANIMAL TUMOR PATHOLOGY OF FEMALE RATS IN THE LIFETIME FEED STUDY OF INTERMEDIATE-RANGE CHRYSOTILE ASBESTOS: INTERMEDIATE-RANGE AND PREWEANING GAVAGE (Continued)

ANIMAL NUMBER	671	672	673	674	675	676	677	678	679	680	681	682	683	684	685	686	687	688	689	690	691	692	693	694	695
WEEKS ON STUDY	121	133	144	085	118	133	121	251	229	118	146	105	096	115	222	221	111	246	335	100	025	058	090	111	146
INTEGUMENTARY SYSTEM																									
SUBCUTANEOUS TISSUE	+	+	+	+	+	+	+	+	+	+	+	+	+	+	+	+	+	+	+	+	+	+	+	+	+
SARCOMA, NOS																									
FIBROMA																									
RESPIRATORY SYSTEM																									
LUNGS AND BRONCHI	+	+	+	+	+	+	+	+	+	+	+	+	+	+	+	+	+	+	+	+	+	+	+	+	+
ALVEOLAR/BRONCHIOLAR ADENOMA															X										
ALVEOLAR/BRONCHIOLAR CARCINOMA																									
PAPILLARY ADENOCARCINOMA, METASTA																									
C-CELL CARCINOMA, METASTATIC																									
PHEOCHROMOCYTOMA, METASTATIC																									
TRACHEA	+	+	+	+	+	+	+	+	+	+	+	+	+	+	+	+	+	+	+	+	+	+	+	+	+
HEMATOPOIETIC SYSTEM																									
BONE MARROW	+	+	+	+	+	+	+	+	+	+	+	+	+	+	+	+	+	+	+	+	+	+	+	+	+
SPLEEN	+	+	+	+	+	+	+	+	+	+	+	+	+	+	+	+	+	+	+	+	+	+	+	+	+
LYMPH NODES	+	+	+	+	+	+	+	+	+	+	+	+	+	+	+	+	+	+	+	+	+	+	+	+	+
C-CELL CARCINOMA, METASTATIC																									
THYMUS	+	+	+	+	+	-	+	+	+	+	+	+	+	+	+	-	+	+	-	+	+	+	+	+	+
CIRCULATORY SYSTEM																									
HEART	+	+	+	+	+	+	+	+	+	+	+	+	+	+	+	+	+	+	+	+	+	+	+	+	+
PHEOCHROMOCYTOMA, METASTATIC																									
DIGESTIVE SYSTEM																									
ORAL CAVITY	N	N	N	N	N	N	N	N	N	N	N	N	N	N	N	N	N	N	N	N	N	N	N	N	N
SQUAMOUS CELL PAPILLOMA																									
SQUAMOUS CELL CARCINOMA		X																							
SALIVARY GLAND	+	+	+	+	+	+	+	+	+	+	+	+	+	+	+	+	+	+	+	+	+	+	+	+	+
SARCOMA, NOS																									
LIVER	+	+	+	+	+	+	+	+	+	+	+	+	+	+	+	+	+	+	+	+	+	+	+	+	+
NEOPLASTIC NODULE																									
BILE DUCT	+	+	+	+	+	+	+	+	+	+	+	+	+	+	+	+	+	+	+	+	+	+	+	+	+
GALLBLADDER & COMMON BILE DUCT	N	N	N	N	N	N	N	N	N	N	N	N	N	N	N	N	N	N	N	N	N	N	N	N	N
PANCREAS	+	+	+	+	+	+	+	+	+	+	+	+	+	+	+	+	+	+	+	+	+	+	+	+	+
ACINAR-CELL ADENOMA																									
ESOPHAGUS	+	+	+	+	+	+	+	+	+	+	+	+	+	+	+	+	+	+	+	+	+	+	+	+	+
STOMACH	+	+	+	+	+	+	+	+	+	+	+	+	+	+	+	+	+	+	+	+	+	+	+	+	+
SQUAMOUS CELL PAPILLOMA								X																	
SQUAMOUS CELL CARCINOMA																						X			
SMALL INTESTINE	+	+	+	+	+	+	+	+	+	+	+	+	+	+	+	+	+	+	+	+	+	+	+	+	+
LARGE INTESTINE	+	+	+	+	+	+	+	+	+	+	+	+	+	+	+	+	+	+	+	+	+	+	+	+	+
LEIOMYOMA																									
URINARY SYSTEM																									
KIDNEY	+	+	+	+	+	+	+	+	+	+	+	+	+	+	+	+	+	+	+	+	+	+	+	+	+
TUBULAR-CELL ADENOCARCINOMA																									
URINARY BLADDER	+	+	+	+	+	+	+	+	+	+	+	+	+	+	+	+	+	+	+	+	+	+	+	+	+
TRANSITIONAL-CELL PAPILLOMA																									

HWBUI0001749

TABLE B4. INDIVIDUAL ANIMAL TUMOR PATHOLOGY OF FEMALE RATS IN THE LIFETIME FEED STUDY OF INTERMEDIATE-RANGE CHRYSOTILE ASBESTOS: INTERMEDIATE-RANGE AND PREWEANING GAVAGE (Continued)

ANIMAL NUMBER	67112	67123	67134	67145	67156	67167	67178	67189	67199	67208	67216	67226	67236	67246	67256	67266	67276	67286	67296	67301	67312	67325	67331	67341	67351
WEEKS ON STUDY	12 1	13 3	14 6	08 9	11 8	13 5	12 1	12 5	12 9	11 8	14 6	10 5	09 6	11 3	12 2	12 2	11 1	12 4	13 1	13 5	10 1	11 2	08 5	09 0	11 1	11 4
ENDOCRINE SYSTEM																										
PITUITARY	+	+	+	+	+	+	+	+	+	+	+	+	+	+	+	+	+	+	+	X	+	+	+	+	+	+
CARCINOMA, NOS																										
ADENOMA, NOS						X		X		X	X			X								X				X
ADRENAL	+	+	+	+	+	+	+	+	+	+	+	+	+	+	+	+	+	+	+	X	+	+	+	+	+	+
CORTICAL ADENOMA																				X						
PHEOCHROMOCYTOMA																				X					X	
PHEOCHROMOCYTOMA, MALIGNANT																										
GANGLIONEUROMA				X																						
THYROID	+	+	+	+	+	+	+	+	+	+	+	+	+	+	+	+	+	+	+	+	+	+	+	+	+	+
FOLLICULAR-CELL ADENOMA					X			X																		
FOLLICULAR-CELL CARCINOMA		X																								
C-CELL ADENOMA	X				X		X											X								
C-CELL CARCINOMA																										
PARATHYROID	+	+	+	+	+	+	+	+	+	+	+	+	+	+	+	+	+	+	+	+	+	+	+	+	+	+
ADENOMA, NOS																										
PANCREATIC ISLETS	+	+	+	+	+	+	+	+	+	+	+	+	+	+	+	+	+	+	+	+	+	+	+	+	+	+
ISLET-CELL ADENOMA																										
ISLET-CELL CARCINOMA																										
REPRODUCTIVE SYSTEM																										
MAMMARY GLAND	+	+	+	+	+	+	+	+	+	+	+	+	+	+	+	+	+	+	+	+	+	+	+	+	+	+
CARCINOMA, NOS									X																	
ADENOMA, NOS																										
ADENOCARCINOMA, NOS																										
FIBROADENOMA	X	X	X		X	X	X	X			X				X	X	X			X						
CHONDROMA																										
PREPUTIAL/CLITORAL GLAND	N	N	N	N	N	N	N	N	N	N	N	N	N	N	N	N	N	N	N	N	N	N	N	N	N	N
CARCINOMA, NOS				X											X											
VAGINA	N	N	N	N	N	N	N	N	N	N	N	N	N	N	N	N	N	N	N	N	N	N	N	N	N	N
ENDOMETRIAL STROMAL POLYP																						X				
UTERUS	+	+	+	+	+	+	+	+	+	+	+	+	+	+	+	+	+	+	+	+	+	+	+	+	+	+
PAPILLARY ADENOCARCINOMA																										
PAPILLARY CYSTADENOMA, NOS							X																			
ENDOMETRIAL STROMAL POLYP		X				X																X				
ENDOMETRIAL STROMAL SARCOMA																										
ENDOMETRIAL STROMAL SARCOMA, INVA																										
OVARY	+	+	+	+	+	+	+	+	+	+	+	+	+	+	+	+	+	+	+	+	+	+	+	+	+	+
GRANULOSA-CELL TUMOR								X																		
NERVOUS SYSTEM																										
BRAIN	+	+	+	+	+	+	+	+	+	+	+	+	+	+	+	+	+	+	+	X	+	+	+	+	+	+
CARCINOMA, NOS, INVASIVE																										
GRANULAR-CELL TUMOR, NOS																										
GLIOMA, NOS																										
ASTROCYTOMA																										
SPECIAL SENSE ORGANS																										
ZYMBAL GLAND	+	+	+	+	+	+	+	+	+	+	+	+	+	+	+	+	X	+	+	+	+	+	+	+	+	+
SQUAMOUS CELL CARCINOMA																										
SARCOMA, NOS, INVASIVE																										
MUSCULOSKELETAL SYSTEM																										
MUSCLE	N	N	N	N	N	N	N	N	N	N	N	N	N	N	N	N	N	N	N	N	N	N	N	N	N	N
RHABDOMYOSARCOMA						X																				
BODY CAVITIES																										
MESENTERY	N	N	N	N	N	N	N	N	N	N	N	N	N	N	N	N	N	N	N	N	N	N	N	N	N	N
SQUAMOUS CELL CARCINOMA, INVASIVE																						X				
ALL OTHER SYSTEMS																										
MULTIPLE ORGANS NOS	N	N	N	N	N	N	N	N	N	N	N	N	N	N	N	N	N	N	N	N	N	N	N	N	N	N
MONOCYTIC LEUKEMIA					X	X	X			X			X	X						X	X	X				
LEUKEMIA, MONONUCLEAR CELL																										

HWBUI0001750

TABLE B4. INDIVIDUAL ANIMAL TUMOR PATHOLOGY OF FEMALE RATS IN THE LIFETIME FEED STUDY OF INTERMEDIATE-RANGE CHRYSOTILE ASBESTOS: INTERMEDIATE-RANGE AND PREWEANING GAVAGE (Continued)

ANIMAL NUMBER	61 91 6	61 91 7	61 91 8	61 91 9	71 01 0	71 01 1	71 02 2	71 03 3	71 03 4	71 03 5	71 03 6	71 03 7	71 03 8	71 03 9	71 04 0	71 04 1	71 04 2	71 04 3	71 04 4	71 04 5	71 04 6	71 04 7	71 04 8	71 04 9	72 05 0
WEEKS ON STUDY	1 1 9	0 8 8	1 2 7	1 3 6	1 2 9	1 0 6	1 3 0	1 3 3	1 1 4	1 3 9	1 3 0	1 0 3	1 4 6	1 2 4	1 4 6	1 4 6	1 9 3	1 4 6	1 3 0	1 7 3	1 0 7	1 1 1	1 3 8	1 4 0	0 8 4
INTEGUMENTARY SYSTEM																									
SUBCUTANEOUS TISSUE	+	+	+	+	+	+	+	+	+	+	+	+	+	+	+	+	+	+	+	N	+	+	+	+	+
SARCOMA, NOS				X																					
FIBROMA																									
RESPIRATORY SYSTEM																									
LUNGS AND BRONCHI	+	+	+	+	+	+	+	+	+	+	+	+	+	+	+	+	+	+	+	A	+	+	+	+	+
ALVEOLAR/BRONCHIOLAR ADENOMA			X											X											
ALVEOLAR/BRONCHIOLAR CARCINOMA															X										
PAPILLARY ADENOCARCINOMA, METASTA																									
C-CELL CARCINOMA, METASTATIC																									
PHEOCHROMOCYTOMA, METASTATIC										X													X		
TRACHEA	+	+	+	+	+	+	+	+	+	+	+	+	+	+	+	+	+	+	+	+	+	+	+	+	+
HEMATOPOIETIC SYSTEM																									
BONE MARROW	+	+	+	+	+	+	+	+	+	+	-	+	+	+	+	+	+	+	+	A	+	+	+	+	+
SPLEEN	+	+	+	+	+	+	+	+	+	+	+	+	+	+	+	+	+	+	+	A	+	+	+	+	+
LYMPH NODES	+	+	+	+	+	+	+	+	+	+	+	+	+	+	+	+	+	+	+	A	+	+	+	+	+
C-CELL CARCINOMA, METASTATIC																									
THYMUS	+	+	+	+	+	+	+	+	+	+	+	+	+	+	+	+	+	+	+	A	+	+	+	+	+
CIRCULATORY SYSTEM																									
HEART	+	+	+	+	+	+	+	+	+	+	+	+	+	+	+	+	+	+	+	A	+	+	+	+	+
PHEOCHROMOCYTOMA, METASTATIC																							X		
DIGESTIVE SYSTEM																									
ORAL CAVITY	N	N	N	N	N	N	N	N	N	N	N	N	N	N	N	N	N	N	N	N	N	N	N	N	N
SQUAMOUS CELL PAPILLOMA																									
SQUAMOUS CELL CARCINOMA																									
SALIVARY GLAND	+	+	+	+	+	+	+	+	+	+	+	+	+	+	+	+	+	+	+	A	+	+	+	+	+
SARCOMA, NOS																									
LIVER	+	+	+	+	+	+	+	+	+	+	+	+	+	+	+	+	+	+	+	A	+	+	+	+	+
NEOPLASTIC NODULE																									
BILE DUCT	+	+	+	+	+	+	+	+	+	+	+	+	+	+	+	+	+	+	+	A	+	+	+	+	+
GALLBLADDER & COMMON BILE DUCT	N	N	N	N	N	N	N	N	N	N	N	N	N	N	N	N	N	N	N	N	N	N	N	N	N
PANCREAS	+	+	+	+	+	+	+	+	+	+	+	+	+	+	+	+	+	+	+	A	+	+	+	+	+
ACINAR-CELL ADENOMA															X										
ESOPHAGUS	+	+	+	+	+	+	+	+	+	+	+	+	+	+	+	+	+	+	+	+	+	+	+	+	+
STOMACH	+	+	+	+	+	+	+	+	+	+	+	+	+	+	+	+	+	+	+	A	+	+	+	+	+
SQUAMOUS CELL PAPILLOMA																									
SQUAMOUS CELL CARCINOMA																									
SMALL INTESTINE	+	+	+	+	+	+	+	+	+	+	+	+	+	+	+	+	+	+	+	A	+	+	+	+	+
LARGE INTESTINE	+	+	+	+	+	+	+	+	+	+	+	+	+	+	+	+	+	+	+	A	+	+	+	+	+
LEIOMYOMA																									
URINARY SYSTEM																									
KIDNEY	+	+	+	+	+	+	+	+	+	+	+	+	+	+	+	+	+	+	+	A	+	+	+	+	+
TUBULAR-CELL ADENOCARCINOMA																									
URINARY BLADDER	+	+	+	+	+	+	+	+	+	+	+	+	+	+	+	+	+	+	+	A	+	+	+	+	+
TRANSITIONAL-CELL PAPILLOMA																									

HWBUI0001751

TABLE B4. INDIVIDUAL ANIMAL TUMOR PATHOLOGY OF FEMALE RATS IN THE LIFETIME FEED STUDY OF INTERMEDIATE-RANGE CHRYSOTILE ASBESTOS: INTERMEDIATE-RANGE AND PREWEANING GAVAGE (Continued)

ANIMAL NUMBER	69964	69967	69968	69969	70001	70012	70031	70041	70051	70064	70071	70081	70091	71101	71112	71131	71141	71151	71161	71171	71181	71191	72001
WEEKS ON STUDY	119	168	127	134	129	106	133	131	139	138	135	146	124	146	146	143	136	130	137	111	138	140	144
ENDOCRINE SYSTEM																							
PITUITARY	+	+	+	+	+	+	+	+	+	+	+	+	+	+	+	+	+	+	+	+	+	+	+
CARCINOMA, NOS																							
ADENOMA, NOS	X		X	X	X			X		X	X		X	X		X	X	X	X			X	X	X	X
ADRENAL	+	+	+	+	+	+	+	+	+	+	+	+	+	+	+	+	+	+	+	A	+	+	+	+	+
CORTICAL ADENOMA																							X		
PHEOCHROMOCYTOMA													X								X	X		X	X
PHEOCHROMOCYTOMA, MALIGNANT										X													X		
GANGLIONEUROMA																									
THYROID	+	+	+	+	+	+	+	+	+	+	+	+	+	+	+	+	+	+	+	+	+	+	+	+	+
FOLLICULAR-CELL ADENOMA														X							X				
FOLLICULAR-CELL CARCINOMA			X							X												X	X		
C-CELL ADENOMA										X				X							X				
C-CELL CARCINOMA			X		X								X					X	X					X	
PARATHYROID	+	+	+	+	+	+	+	+	+	+	+	-	+	+	+	+	+	+	+	A	+	+	+	+	+
ADENOMA, NOS																									
PANCREATIC ISLETS	+	+	+	+	+	+	+	+	+	+	+	+	+	+	+	+	+	+	+	A	+	+	+	+	+
ISLET-CELL ADENOMA								X	X																
ISLET-CELL CARCINOMA																							X	X	
REPRODUCTIVE SYSTEM																									
MAMMARY GLAND	+	+	+	+	+	+	+	+	+	+	+	+	+	+	+	+	+	+	+	N	+	+	+	+	+
CARCINOMA, NOS							X																		
ADENOMA, NOS																						X			
ADENOCARCINOMA, NOS	X																								
FIBROADENOMA			X		X		X	X		X	X	X	X		X	X		X					X	X	
CHONDROMA																									
PREPUTIAL/CLITORAL GLAND	N	N	N	N	N	N	N	N	N	N	N	N	N	N	N	N	N	N	N	N	N	N	N	N	N
CARCINOMA, NOS																									
VAGINA	N	N	N	N	N	N	N	N	N	N	N	N	N	N	N	N	N	N	N	N	N	N	N	N	N
ENDOMETRIAL STROMAL POLYP																									
UTERUS	+	+	+	+	+	+	+	+	+	+	+	+	+	+	+	+	+	+	+	A	+	+	+	+	+
PAPILLARY ADENOCARCINOMA																									
PAPILLARY CYSTADENOMA, NOS																									
ENDOMETRIAL STROMAL POLYP					X		X				X														
ENDOMETRIAL STROMAL SARCOMA																									
ENDOMETRIAL STROMAL SARCOMA, INVA																									
OVARY	+	+	+	+	+	+	+	+	+	+	+	+	+	+	+	+	+	+	+	A	+	+	+	+	+
GRANULOSA-CELL TUMOR																									
NERVOUS SYSTEM																									
BRAIN	+	+	+	+	+	+	+	+	+	+	+	+	+	+	+	+	+	+	+	+	+	+	+	+	+
CARCINOMA, NOS, INVASIVE																									
GRANULAR-CELL TUMOR, NOS																									
GLIOMA, NOS																									
ASTROCYTOMA																									
SPECIAL SENSE ORGANS																									
ZYMBAL GLAND	+	+	+	+	+	+	+	+	+	+	+	+	+	+	+	+	+	+	+	+	+	+	+	+	+
SQUAMOUS CELL CARCINOMA				X																					
SARCOMA, NOS, INVASIVE																									
MUSCULOSKELETAL SYSTEM																									
MUSCLE	N	N	N	N	N	N	N	N	N	N	N	N	N	N	N	N	N	N	N	N	N	N	N	N	N
RHABDOMYOSARCOMA																									
BODY CAVITIES																									
MESENTERY	N	N	N	N	N	N	N	N	N	N	N	N	N	N	N	N	N	N	N	N	N	N	N	N	N
SQUAMOUS CELL CARCINOMA, INVASIVE																									
ALL OTHER SYSTEMS																									
MULTIPLE ORGANS NOS	N	N	N	N	N	N	N	N	N	N	N	N	N	N	N	N	N	N	N	N	N	N	N	N	N
MONOCYTIC LEUKEMIA			X			X	X			X			X								X	X			
LEUKEMIA, MONONUCLEAR CELL				X																					

HWBUI0001752

TABLE B4. INDIVIDUAL ANIMAL TUMOR PATHOLOGY OF FEMALE RATS IN THE LIFETIME FEED STUDY OF INTERMEDIATE-RANGE CHRYSOTILE ASBESTOS: INTERMEDIATE-RANGE AND PREWEANING GAVAGE (Continued)

ANIMAL NUMBER	72125	72225	72345	72455	72556	72617	72807	72809	73001	73112	73213	73514	73546	73617	73718	73819	74001	74112	74263	74316	74596	74653	TOTAL TISSUES TUMORS
WEEKS ON STUDY	130	122	122	122	115	137	143	073	136	118	146	105	140	820	201	161	153	141	092	066	261	096	083	
INTEGUMENTARY SYSTEM																							
SUBCUTANEOUS TISSUE	+	+	+	+	+	+	+	+	+	+	+	+	+	+	+	+	+	+	+	+	+	+	+	100M
SARCOMA, NOS						X																		1
FIBROMA						X																		3
RESPIRATORY SYSTEM																							
LUNGS AND BRONCHI	+	+	+	+	+	+	+	+	+	+	+	+	+	+	+	+	+	+	+	+	+	+	+	99
ALVEOLAR/BRONCHIOLAR ADENOMA																								3
ALVEOLAR/BRONCHIOLAR CARCINOMA																								1
PAPILLARY ADENOCARCINOMA, METASTA																								1
C-CELL CARCINOMA, METASTATIC																								1
PHEOCHROMOCYTOMA, METASTATIC																								2
TRACHEA	+	+	-	+	+	+	+	+	+	+	+	+	+	+	+	+	+	+	+	+	+	+	+	99
HEMATOPOIETIC SYSTEM																							
BONE MARROW	+	+	+	+	+	+	+	+	+	+	+	+	+	+	+	+	+	+	+	+	+	+	+	98
SPLEEN	+	+	+	+	+	+	+	+	+	+	+	+	+	+	+	+	+	+	+	+	+	+	+	99
LYMPH NODES	+	+	+	+	+	+	+	+	+	+	+	+	+	+	+	+	+	+	+	+	+	+	+	99
C-CELL CARCINOMA, METASTATIC																								1
THYMUS	+	+	-	+	+	+	+	+	+	+	+	+	+	+	+	+	+	+	+	+	+	+	+	95
CIRCULATORY SYSTEM																							
HEART	+	+	+	+	+	+	+	+	+	+	+	+	+	+	+	+	+	+	+	+	+	+	+	99
PHEOCHROMOCYTOMA, METASTATIC																								1
DIGESTIVE SYSTEM																							
ORAL CAVITY	N	N	N	N	N	N	N	N	N	N	N	N	N	N	N	N	N	N	N	N	N	N	N	100M
SQUAMOUS CELL PAPILLOMA																								1
SQUAMOUS CELL CARCINOMA																								1
SALIVARY GLAND	+	+	+	+	+	+	+	+	+	+	+	+	+	+	+	+	+	+	+	+	+	+	+	99
SARCOMA, NOS																	X							1
LIVER	+	+	+	+	+	+	+	+	+	+	+	+	+	+	+	+	+	+	+	+	+	+	+	99
NEOPLASTIC NODULE																								1
BILE DUCT	+	+	+	+	+	+	+	+	+	+	+	+	+	+	+	+	+	+	+	+	+	+	+	99
GALLBLADDER & COMMON BILE DUCT	N	N	N	N	N	N	N	N	N	N	N	N	N	N	N	N	N	N	N	N	N	N	N	100M
PANCREAS	+	+	+	+	+	+	+	+	+	+	+	+	+	+	+	+	+	+	+	+	+	+	+	99
ACINAR-CELL ADENOMA														X										2
ESOPHAGUS	+	+	-	+	+	+	+	+	+	+	+	+	+	+	+	+	+	+	+	+	+	+	+	99
STOMACH	+	+	+	+	+	+	+	+	+	+	+	+	+	+	+	+	+	+	+	+	+	+	+	99
SQUAMOUS CELL PAPILLOMA																								1
SQUAMOUS CELL CARCINOMA																								1
SMALL INTESTINE	+	+	+	+	+	+	+	+	+	+	+	+	+	+	+	+	+	+	+	+	+	+	+	99
LARGE INTESTINE	+	+	+	+	+	+	+	+	+	+	+	+	+	+	+	+	+	+	+	+	+	+	+	99
LEIOMYOMA				X																				1
URINARY SYSTEM																							
KIDNEY	+	+	+	+	+	+	+	+	+	+	+	+	+	+	+	+	+	+	+	+	+	+	+	99
TUBULAR-CELL ADENOCARCINOMA																								1
URINARY BLADDER	+	+	+	+	+	+	+	+	+	+	+	+	+	+	+	+	+	+	+	+	+	+	+	98
TRANSITIONAL-CELL PAPILLOMA									X															2

HWBUI0001753

TABLE B4. INDIVIDUAL ANIMAL TUMOR PATHOLOGY OF FEMALE RATS IN THE LIFETIME FEED STUDY OF INTERMEDIATE-RANGE CHRYSOTILE ASBESTOS: INTERMEDIATE-RANGE AND PREWEANING GAVAGE (Continued)

ANIMAL NUMBER	72 12 50	72 23 02	72 30 22	72 41 22	72 51 15	72 61 17	72 71 13	72 81 07	72 91 36	73 01 46	73 11 18	73 21 46	73 31 65	73 41 40	73 51 80	73 61 20	73 71 81	73 81 46	73 91 33	74 01 14	74 11 92	74 21 06	74 31 28	74 41 96	74 51 83	TOTAL TISSUES TUMORS
WEEKS ON STUDY																										
ENDOCRINE SYSTEM																										
PITUITARY	+	+	+	+	+	+	+	+	+	+	+	+	+	+	+	+	+	+	+	+	+	+	+	+	+	100
CARCINOMA, NOS																										1
ADENOMA, NOS	X	X		X		X	X		X		X	X		X		X			X	X					50
ADRENAL	+	+	+	+	+	+	+	+	+	+	+	+	+	+	+	+	+	+	+	+	+	+	+	+	+	99
CORTICAL ADENOMA				X			X																			5
PHEOCHROMOCYTOMA									X	X									X							11
PHEOCHROMOCYTOMA, MALIGNANT																										2
GANGLIONEUROMA																										1
THYROID	+	+	+	+	+	+	+	+	+	+	+	+	+	+	+	+	+	+	+	+	+	+	+	+	+	100
FOLLICULAR-CELL ADENOMA					X																					6
FOLLICULAR-CELL CARCINOMA							X																			7
C-CELL ADENOMA	X									X	X								X				X	X		20
C-CELL CARCINOMA											X	X		X												12
PARATHYROID	+	+	+	+	+	+	+	+	+	+	+	+	+	+	+	+	+	+	+	+	+	+	+	+	+	97
ADENOMA, NOS																										1
PANCREATIC ISLETS	+	+	+	+	+	+	+	+	+	+	+	+	+	+	+	+	+	+	+	+	+	+	+	+	+	99
ISLET-CELL ADENOMA		X					X																			4
ISLET-CELL CARCINOMA																										3
REPRODUCTIVE SYSTEM																										
MAMMARY GLAND	+	+	+	+	+	+	+	+	+	+	+	+	+	+	+	+	+	+	+	+	+	+	+	+	+	100*
CARCINOMA, NOS																										1
ADENOMA, NOS		X				X				X	X			X					X							11
ADENOCARCINOMA, NOS															X											4
FIBROADENOMA	X			X		X			X	X	X	X	X	X		X			X	X		X		X	X	58
CHONDROMA																										1
PREPUTIAL/CLITORAL GLAND	N	N	N	N	N	N	N	N	N	N	N	N	N	N	N	N	N	N	N	N	N	N	N	N	N	100*
CARCINOMA, NOS																							X			4
VAGINA	N	N	N	N	N	N	N	N	N	N	N	N	N	N	N	N	N	N	N	N	N	N	N	N	N	100*
ENDOMETRIAL STROMAL POLYP																										1
UTERUS	+	+	+	+	+	+	+	+	+	+	+	+	+	+	+	+	+	+	+	+	+	+	+	+	+	99
PAPILLARY ADENOCARCINOMA																										1
PAPILLARY CYSTADENOMA, NOS																										1
ENDOMETRIAL STROMAL POLYP							X					X											X			11
ENDOMETRIAL STROMAL SARCOMA																										1
ENDOMETRIAL STROMAL SARCOMA, INVA																										1
OVARY	+	+	+	+	+	+	+	+	+	+	+	+	+	+	+	+	+	+	+	+	+	+	+	+	+	99
GRANULOSA-CELL TUMOR												X														2
NERVOUS SYSTEM																										
BRAIN	+	+	+	+	+	+	+	+	+	+	+	+	+	+	+	+	+	+	+	+	+	+	+	+	+	100
CARCINOMA, NOS, INVASIVE																										1
GRANULAR-CELL TUMOR, NOS																										1
GLIOMA, NOS																										1
ASTROCYTOMA																										1
SPECIAL SENSE ORGANS																										
ZYMBAL GLAND	+	+	N	+	+	+	+	+	+	+	+	+	+	+	+	+	+	+	+	+	+	+	+	+	+	100*
SQUAMOUS CELL CARCINOMA																										2
SARCOMA, NOS, INVASIVE						X																				1
MUSCULOSKELETAL SYSTEM																										
MUSCLE	N	N	N	N	N	N	N	N	N	N	N	+	N	N	N	N	N	N	N	N	N	N	N	N	N	100*
RHABDOMYOSARCOMA																										1
BODY CAVITIES																										
MESENTERY	N	N	N	N	N	N	N	N	N	N	N	N	N	N	N	N	N	N	N	N	N	N	N	N	N	100*
SQUAMOUS CELL CARCINOMA, INVASIVE																										1
ALL OTHER SYSTEMS																										
MULTIPLE ORGANS NOS	N	N	N	N	N	N	N	N	N	N	N	N	N	N	N	N	N	N	N	N	N	N	N	N	N	100*
MONOCYTIC LEUKEMIA					X					X						X	X	X		X						26
LEUKEMIA, MONONUCLEAR CELL																										3

* ANIMALS NECROPSIED

HWBUI0001754

HWBUI0001755

APPENDIX C

SUMMARY OF THE INCIDENCE OF NONNEOPLASTIC LESIONS IN RATS IN THE LIFETIME FEED STUDIES OF SHORT-RANGE CHRYSOTILE ASBESTOS

HWBUI0001756

TABLE C1. SUMMARY OF THE INCIDENCE OF NONNEOPLASTIC LESIONS IN MALE RATS IN THE LIFETIME FEED STUDY OF SHORT-RANGE CHRYSOTILE ASBESTOS

	CONTROL (UNTR)	SHORT RANGE
ANIMALS INITIALLY IN STUDY	88	250
ANIMALS NECROPSIED	88	250
ANIMALS EXAMINED HISTOPATHOLOGICALLY	88	248
INTEGUMENTARY SYSTEM		
*SKIN	(88)	(250)
CYST, NOS		1 (0%)
EPIDERMAL INCLUSION CYST	4 (5%)	5 (2%)
ABSCESS, NOS	2 (2%)	1 (0%)
GRANULOMA, NOS	1 (1%)	
FIBROSIS, FOCAL		1 (0%)
HYPERKERATOSIS		4 (2%)
ACANTHOSIS	1 (1%)	5 (2%)
*SUBCUT TISSUE	(88)	(250)
HEMORRHAGIC CYST		2 (1%)
ABSCESS, NOS	2 (2%)	1 (0%)
RESPIRATORY SYSTEM		
*NASAL TURBINATE	(88)	(250)
INFLAMMATION, ACUTE		1 (0%)
INFLAMMATION, ACUTE DIFFUSE		1 (0%)
HYPERKERATOSIS		1 (0%)
METAPLASIA, SQUAMOUS		1 (0%)
#TRACHEA	(87)	(248)
FIBROSIS, DIFFUSE		1 (0%)
#LUNG	(88)	(247)
MINERALIZATION		1 (0%)
CONGESTION, NOS	2 (2%)	4 (2%)
EDEMA, NOS	1 (1%)	2 (1%)
HEMORRHAGE	6 (7%)	13 (5%)
INFLAMMATION, INTERSTITIAL	1 (1%)	10 (4%)
INFLAMMATION, ACUTE FOCAL	1 (1%)	1 (0%)
INFLAMMATION, ACUTE DIFFUSE		1 (0%)
INFLAMMATION, CHRONIC	80 (91%)	208 (84%)
GRANULOMA, NOS		6 (2%)
FIBROSIS, DIFFUSE	2 (2%)	
NECROSIS, FOCAL		1 (0%)
PIGMENTATION, NOS	3 (3%)	7 (3%)
HYPERPLASIA, ALVEOLAR EPITHELIUM	1 (1%)	10 (4%)
#LUNG/ALVEOLI	(88)	(247)
HISTIOCYTOSIS		5 (2%)
HEMATOPOIETIC SYSTEM		
*MULTIPLE ORGANS	(88)	(250)
HEMATOPOIESIS	1 (1%)	
#BONE MARROW	(88)	(247)
HEMORRHAGE	1 (1%)	
NECROSIS, DIFFUSE	1 (1%)	
HYPOPLASIA, NOS	4 (5%)	3 (1%)
HYPERPLASIA, NOS	3 (3%)	6 (2%)
MYELOFIBROSIS	1 (1%)	
#SPLEEN	(88)	(247)
CONGESTION, NOS		1 (0%)
HEMORRHAGE	3 (3%)	3 (1%)
FIBROSIS, FOCAL	3 (3%)	16 (6%)
FIBROSIS, MULTIFOCAL	2 (2%)	7 (3%)
FIBROSIS, DIFFUSE	1 (1%)	4 (2%)
NECROSIS, NOS		1 (0%)
NECROSIS, FOCAL	3 (3%)	6 (2%)
METAMORPHOSIS FATTY		1 (0%)
PIGMENTATION, NOS	3 (3%)	2 (1%)

HWBUI0001757

TABLE C1. SUMMARY OF THE INCIDENCE OF NONNEOPLASTIC LESIONS IN MALE RATS IN THF LIFETIME FEED STUDY OF SHORT-RANGE CHRYSOTILE ASBESTOS (Continued)

	CONTROL (UNTR)	SHORT RANGE
HEMATOPOIETIC SYSTEM		
#SPLEEN (Continued)		
HEMOSIDEROSIS	11 (13%)	34 (14%)
ANGIECTASIS		2 (1%)
HEMATOPOIESIS	19 (22%)	41 (17%)
#SPLENIC CAPSULE	(88)	(247)
FIBROSIS, FOCAL	1 (1%)	
#SPLENIC FOLLICLES	(88)	(247)
ATROPHY, NOS	1 (1%)	5 (2%)
#LYMPH NODE	(88)	(248)
INFLAMMATION, CHRONIC		1 (0%)
#MANDIBULAR L. NODE	(88)	(248)
CONGESTION, NOS		1 (0%)
HEMORRHAGE	3 (3%)	
FIBROSIS, FOCAL	1 (1%)	
PIGMENTATION, NOS		1 (0%)
HYPERPLASIA, RETICULUM CELL		1 (0%)
HYPERPLASIA, LYMPHOID	4 (5%)	34 (14%)
#CERVICAL LYMPH NODE	(88)	(248)
PIGMENTATION, NOS		1 (0%)
ERYTHROPHAGOCYTOSIS		1 (0%)
#MEDIASTINAL L.NODE	(88)	(248)
CONGESTION, NOS	2 (2%)	1 (0%)
HEMORRHAGE	3 (3%)	11 (4%)
INFLAMMATION, ACUTE DIFFUSE		1 (0%)
NECROSIS, FOCAL	1 (1%)	1 (0%)
PIGMENTATION, NOS	10 (11%)	32 (13%)
ERYTHROPHAGOCYTOSIS	2 (2%)	4 (2%)
HYPERPLASIA, RETICULUM CELL		1 (0%)
HYPERPLASIA, LYMPHOID		4 (2%)
#PANCREATIC L.NODE	(88)	(248)
PIGMENTATION, NOS	3 (3%)	4 (2%)
HYPERPLASIA, RETICULUM CELL	3 (3%)	8 (3%)
HYPERPLASIA, LYMPHOID		1 (0%)
#MESENTERIC L. NODE	(88)	(248)
INFLAMMATION, ACUTE DIFFUSE		2 (1%)
ABSCESS, NOS		1 (0%)
NECROSIS, FOCAL	1 (1%)	1 (0%)
PIGMENTATION, NOS		1 (0%)
ERYTHROPHAGOCYTOSIS		5 (2%)
HYPERPLASIA, RETICULUM CELL	38 (43%)	81 (33%)
HYPERPLASIA, LYMPHOID	1 (1%)	2 (1%)
#ILEOCOLIC LYMPH NODE	(88)	(248)
HYPERPLASIA, LYMPHOID		1 (0%)
#RENAL LYMPH NODE	(88)	(248)
PIGMENTATION, NOS	2 (2%)	2 (1%)
#LIVER	(88)	(248)
LEUKOCYTOSIS, NOS	2 (2%)	6 (2%)
HEMATOPOIESIS	1 (1%)	
#PANCREAS	(86)	(247)
HYPERPLASIA, RETICULUM CELL		1 (0%)
#THYMUS	(76)	(197)
CYST, NOS		1 (1%)
HEMORRHAGE		1 (1%)
CIRCULATORY SYSTEM		
#MANDIBULAR LYMPH NODE	(88)	(248)
LYMPHANGIECTASIS		3 (1%)
#MEDIASTINAL LYMPH NODE	(88)	(248)
LYMPHANGIECTASIS		1 (0%)
#MESENTERIC LYMPH NODE	(88)	(248)
LYMPHANGIECTASIS	1 (1%)	5 (2%)
#ILEOCOLIC LYMPH NODE	(88)	(248)
LYMPHANGIECTASIS		6 (2%)

HWBUI0001758

TABLE C1. SUMMARY OF THE INCIDENCE OF NONNEOPLASTIC LESIONS IN MALE RATS IN THE LIFETIME FEED STUDY OF SHORT-RANGE CHRYSOTILE ASBESTOS (Continued)

	CONTROL (UNTR)	SHORT RANGE
CIRCULATORY SYSTEM (Continued)		
#RENAL LYMPH NODE	(88)	(248)
LYMPHANGIECTASIS	1 (1%)	1 (0%)
#HEART	(88)	(247)
THROMBOSIS, NOS		2 (1%)
INFLAMMATION, CHRONIC DIFFUSE		1 (0%)
#HEART/ATRIUM	(88)	(247)
THROMBOSIS, NOS	1 (1%)	
#MYOCARDIUM	(88)	(247)
MINERALIZATION	1 (1%)	3 (1%)
INFLAMMATION, CHRONIC	1 (1%)	
INFLAMMATION, CHRONIC FOCAL	38 (43%)	91 (37%)
INFLAMMATION, CHRONIC DIFFUSE	32 (36%)	86 (35%)
FIBROSIS, FOCAL	1 (1%)	
PIGMENTATION, NOS		1 (0%)
#CARDIAC VALVE	(88)	(247)
INFLAMMATION, CHRONIC FOCAL	1 (1%)	
*AORTA	(88)	(250)
MINERALIZATION	2 (2%)	
#SALIVARY GLAND	(87)	(243)
LYMPHANGIECTASIS		1 (0%)
#LIVER	(88)	(248)
THROMBOSIS, NOS	1 (1%)	2 (1%)
THROMBUS, ORGANIZED		1 (0%)
#PANCREAS	(86)	(247)
PERIARTERITIS	4 (5%)	2 (1%)
#TESTIS	(87)	(246)
PERIARTERITIS	1 (1%)	2 (1%)
#ADRENAL	(88)	(248)
THROMBOSIS, NOS	1 (1%)	2 (1%)
DIGESTIVE SYSTEM		
*TONGUE	(88)	(250)
EDEMA, NOS		2 (1%)
#SALIVARY GLAND	(87)	(243)
FIBROSIS, DIFFUSE		2 (1%)
NECROSIS, FOCAL		1 (0%)
ATROPHY, DIFFUSE		1 (0%)
HYPERPLASIA, DIFFUSE		1 (0%)
#LIVER	(88)	(248)
CONGESTION, NOS	1 (1%)	1 (0%)
HEMORRHAGE	2 (2%)	
INFLAMMATION, ACUTE FOCAL		1 (0%)
GRANULOMA, NOS	8 (9%)	15 (6%)
CHOLANGIOFIBROSIS	3 (3%)	
ADHESION, NOS		2 (1%)
HEPATITIS, TOXIC	12 (14%)	36 (15%)
DEGENERATION, NOS	18 (20%)	42 (17%)
NECROSIS, FOCAL	7 (8%)	22 (9%)
NECROSIS, DIFFUSE	1 (1%)	
METAMORPHOSIS FATTY	14 (16%)	44 (18%)
PIGMENTATION, NOS	11 (13%)	29 (12%)
FOCAL CELLULAR CHANGE	29 (33%)	74 (30%)
ANGIECTASIS	2 (2%)	4 (2%)
#HEPATIC CAPSULE	(88)	(248)
FIBROSIS		1 (0%)
#LIVER/CENTRILOBULAR	(88)	(248)
NECROSIS, NOS		2 (1%)
#BILE DUCT	(88)	(248)
INFLAMMATION, CHRONIC	11 (13%)	47 (19%)
GRANULOMA, NOS		1 (0%)
FIBROSIS	1 (1%)	4 (2%)
HYPERPLASIA, NOS	26 (30%)	53 (21%)

HWBUI0001759

TABLE C1. SUMMARY OF THE INCIDENCE OF NONNEOPLASTIC LESIONS IN MALE RATS IN THE LIFETIME FEED STUDY OF SHORT-RANGE CHRYSOTILE ASBESTOS (Continued)

	CONTROL (UNTR)	SHORT RANGE
DIGESTIVE SYSTEM (Continued)		
#PANCREAS	(86)	(247)
ECTOPIA	1 (1%)	5 (2%)
HEMORRHAGE		1 (0%)
INFLAMMATION, CHRONIC FOCAL		1 (0%)
INFLAMMATION, CHRONIC DIFFUSE	1 (1%)	
FIBROSIS, FOCAL		1 (0%)
ATROPHY, NOS	1 (1%)	
ATROPHY, FOCAL	8 (9%)	24 (10%)
ATROPHY, DIFFUSE	3 (3%)	10 (4%)
#PANCREATIC DUCT	(86)	(247)
HYPERPLASIA, NOS		1 (0%)
#PANCREATIC ACINUS	(86)	(247)
HYPERPLASIA, FOCAL	6 (7%)	8 (3%)
#ESOPHAGUS	(86)	(247)
INFLAMMATION, ACUTE DIFFUSE	1 (1%)	
NECROSIS, FOCAL	1 (1%)	
HYPERKERATOSIS	6 (7%)	16 (6%)
#STOMACH	(88)	(248)
MINERALIZATION	3 (3%)	2 (1%)
EDEMA, NOS		1 (0%)
HEMORRHAGE		2 (1%)
INFLAMMATION, ACUTE FOCAL	1 (1%)	3 (1%)
INFLAMMATION, ACUTE DIFFUSE	1 (1%)	1 (0%)
INFLAMMATION, CHRONIC FOCAL	4 (5%)	6 (2%)
INFLAMMATION, CHRONIC DIFFUSE	6 (7%)	25 (10%)
ULCER, PERFORATED	4 (5%)	10 (4%)
FIBROSIS, FOCAL		1 (0%)
ADHESION, NOS	1 (1%)	1 (0%)
NECROSIS, FOCAL	13 (15%)	35 (14%)
NECROSIS, DIFFUSE		5 (2%)
CALCIFICATION, NOS	1 (1%)	
HYPERPLASIA, EPITHELIAL	3 (3%)	
HYPERKERATOSIS	8 (9%)	29 (12%)
ACANTHOSIS	11 (13%)	36 (15%)
#GASTRIC MUCOSA	(88)	(248)
HYPERTROPHY, NOS	1 (1%)	
HYPERPLASIA, DIFFUSE	1 (1%)	
#GASTRIC MUSCULARIS	(88)	(248)
DEGENERATION, NOS	2 (2%)	
#GASTRIC FUNDUS	(88)	(248)
HYPERPLASIA, EPITHELIAL		1 (0%)
#DUODENUM	(88)	(248)
HEMORRHAGE		1 (0%)
INFLAMMATION, ACUTE FOCAL		1 (0%)
NECROSIS, FOCAL		2 (1%)
#JEJUNUM	(88)	(248)
CYST, NOS	1 (1%)	
INFLAMMATION, ACUTE DIFFUSE		1 (0%)
NECROSIS, FOCAL		1 (0%)
#COLON	(87)	(248)
INFLAMMATION, CHRONIC DIFFUSE		1 (0%)
PARASITISM	13 (15%)	22 (9%)
NECROSIS, FOCAL		1 (0%)
NECROSIS, DIFFUSE		1 (0%)
#COLONIC MUSCULARIS PROPRIA	(87)	(248)
DEGENERATION, NOS		1 (0%)
#CECUM	(87)	(248)
MINERALIZATION	1 (1%)	
CYST, NOS		1 (0%)
INFLAMMATION, ACUTE FOCAL		2 (1%)
INFLAMMATION, CHRONIC FOCAL		2 (1%)
INFLAMMATION, CHRONIC DIFFUSE		2 (1%)

HWBUI0001760

TABLE C1. SUMMARY OF THE INCIDENCE OF NONNEOPLASTIC LESIONS IN MALE RATS IN THE LIFETIME FEED STUDY OF SHORT-RANGE CHRYSOTILE ASBESTOS (Continued)

	CONTROL (UNTR)	SHORT RANGE
DIGESTIVE SYSTEM		
#CECUM (Continued)	(87)	(248)
PARASITISM		2 (1%)
NECROSIS, NOS		1 (0%)
NECROSIS, FOCAL		4 (2%)
#TRANSVERSE COLON	(87)	(248)
CYST, NOS		1 (0%)
URINARY SYSTEM		
#KIDNEY	(88)	(248)
HAMARTOMA		1 (0%)
MINERALIZATION	5 (6%)	13 (5%)
HYDRONEPHROSIS	1 (1%)	3 (1%)
ABSCESS, NOS	1 (1%)	3 (1%)
INFLAMMATION, CHRONIC	77 (88%)	237 (96%)
INFLAMMATION, CHRONIC DIFFUSE	1 (1%)	
INFARCT, NOS		1 (0%)
INFARCT, HEALED	2 (2%)	1 (0%)
HYPERPLASIA, TUBULAR CELL		4 (2%)
METAPLASIA, OSSEOUS		1 (0%)
#KIDNEY/CORTEX	(88)	(248)
CYST, NOS	4 (5%)	15 (6%)
#RENAL PAPILLA	(88)	(248)
INFLAMMATION, ACUTE FOCAL		1 (0%)
NECROSIS, NOS		1 (0%)
NECROSIS, FOCAL		3 (1%)
#KIDNEY/TUBULE	(88)	(248)
CYST, NOS	1 (1%)	
PIGMENTATION, NOS	25 (28%)	74 (30%)
#KIDNEY/PELVIS	(88)	(248)
HEMORRHAGE		1 (0%)
INFLAMMATION, ACUTE FOCAL		1 (0%)
NECROSIS, FOCAL		1 (0%)
#URINARY BLADDER	(85)	(247)
HEMORRHAGE	2 (2%)	5 (2%)
INFLAMMATION, ACUTE FOCAL		2 (1%)
INFLAMMATION, ACUTE DIFFUSE	2 (2%)	3 (1%)
INFLAMMATION, ACUTE/CHRONIC		1 (0%)
INFLAMMATION, CHRONIC FOCAL	1 (1%)	1 (0%)
INFLAMMATION, CHRONIC DIFFUSE	2 (2%)	2 (1%)
NECROSIS, FOCAL		3 (1%)
NECROSIS, DIFFUSE	1 (1%)	3 (1%)
HYPERPLASIA, EPITHELIAL		1 (0%)
HYPERPLASIA, DIFFUSE	1 (1%)	3 (1%)
HYPERPLASIA, PAPILLARY		1 (0%)
POLYP, INFLAMMATORY		1 (0%)
#U. BLADDER/MUCOSA	(85)	(247)
HYPERPLASIA, PAPILLARY		1 (0%)
ENDOCRINE SYSTEM		
#PITUITARY	(87)	(247)
CYST, NOS		10 (4%)
HEMORRHAGE	2 (2%)	1 (0%)
HEMORRHAGIC CYST		1 (0%)
PIGMENTATION, NOS		1 (0%)
HYPERPLASIA, FOCAL	10 (11%)	13 (5%)
ANGIECTASIS	9 (10%)	14 (6%)
#ADRENAL	(88)	(248)
HEMORRHAGE	1 (1%)	1 (0%)
NECROSIS, FOCAL	1 (1%)	
PIGMENTATION, NOS	2 (2%)	

HWBUI0001761

TABLE C1. SUMMARY OF THE INCIDENCE OF NONNEOPLASTIC LESIONS IN MALE RATS IN THE LIFETIME FEED STUDY OF SHORT-RANGE CHRYSOTILE ASBESTOS (Continued)

	CONTROL (UNTR)	SHORT RANGE
ENDOCRINE SYSTEM		
#ADRENAL (Continued)	(88)	(248)
ATROPHY, NOS	1 (1%)	
HYPERPLASIA, FOCAL		1 (0%)
ANGIECTASIS		7 (3%)
#ADRENAL/CAPSULE	(88)	(248)
FIBROSIS, DIFFUSE		1 (0%)
#ADRENAL CORTEX	(88)	(248)
CONGESTION, NOS	1 (1%)	
DEGENERATION, NOS		2 (1%)
NECROSIS, FOCAL	2 (2%)	
METAMORPHOSIS FATTY	18 (20%)	42 (17%)
HYPERTROPHY, FOCAL	1 (1%)	
HYPERPLASIA, FOCAL	1 (1%)	10 (4%)
#ADRENAL MEDULLA	(88)	(248)
HYPERPLASIA, FOCAL	32 (36%)	74 (30%)
#THYROID	(86)	(246)
CYST, NOS	1 (1%)	
CYSTIC FOLLICLES	1 (1%)	5 (2%)
FOLLICULAR CYST, NOS	5 (6%)	27 (11%)
PIGMENTATION, NOS		1 (0%)
HYPERPLASIA, C-CELL	16 (19%)	45 (18%)
#PARATHYROID	(83)	(229)
HYPERPLASIA, NOS	8 (10%)	16 (7%)
#PANCREATIC ISLETS	(86)	(247)
HYPERPLASIA, FOCAL	4 (5%)	4 (2%)
HYPERPLASIA, DIFFUSE	1 (1%)	
REPRODUCTIVE SYSTEM		
*MAMMARY GLAND	(88)	(250)
GALACTOCELE		5 (2%)
CYST, NOS	1 (1%)	
CYSTIC DUCTS	7 (8%)	9 (4%)
FIBROSIS, DIFFUSE		1 (0%)
HYPERPLASIA, NOS		3 (1%)
HYPERPLASIA, FOCAL	1 (1%)	1 (0%)
HYPERPLASIA, DIFFUSE	5 (6%)	13 (5%)
*PREPUTIAL GLAND	(88)	(250)
CYSTIC DUCTS	6 (7%)	7 (3%)
INFLAMMATION, ACUTE		1 (0%)
INFLAMMATION, ACUTE DIFFUSE		2 (1%)
ABSCESS, NOS	2 (2%)	5 (2%)
INFLAMMATION, CHRONIC		1 (0%)
INFLAMMATION, CHRONIC FOCAL		1 (0%)
INFLAMMATION, CHRONIC DIFFUSE		1 (0%)
NECROSIS, NOS		1 (0%)
HYPERPLASIA, FOCAL		1 (0%)
HYPERPLASIA, DIFFUSE		1 (0%)
HYPERKERATOSIS	4 (5%)	2 (1%)
#PROSTATE	(87)	(247)
CYST, NOS	1 (1%)	4 (2%)
CYSTIC DUCTS	1 (1%)	
HEMORRHAGE	1 (1%)	1 (0%)
INFLAMMATION, DIFFUSE	1 (1%)	
INFLAMMATION, ACUTE DIFFUSE		5 (2%)
ABSCESS, NOS	8 (9%)	19 (8%)
INFLAMMATION, ACUTE/CHRONIC	1 (1%)	1 (0%)
INFLAMMATION, CHRONIC FOCAL	21 (24%)	55 (22%)
INFLAMMATION, CHRONIC DIFFUSE	6 (7%)	15 (6%)
HYPERPLASIA, FOCAL	11 (13%)	28 (11%)
HYPERPLASIA, DIFFUSE		2 (1%)
HYPERKERATOSIS		1 (0%)
METAPLASIA, SQUAMOUS		1 (0%)

HWBUI0001762

TABLE C1. SUMMARY OF THE INCIDENCE OF NONNEOPLASTIC LESIONS IN MALE RATS IN THE LIFETIME FEED STUDY OF SHORT-RANGE CHRYSOTILE ASBESTOS (Continued)

	CONTROL (UNTR)	SHORT RANGE
REPRODUCTIVE SYSTEM (Continued)		
*SEMINAL VESICLE	(88)	(250)
CYST, NOS	1 (1%)	12 (5%)
INFLAMMATION, ACUTE DIFFUSE	1 (1%)	1 (0%)
ABSCESS, NOS	2 (2%)	1 (0%)
INFLAMMATION, CHRONIC FOCAL	1 (1%)	
HYPERPLASIA, FOCAL	1 (1%)	1 (0%)
HYPERPLASIA, DIFFUSE	2 (2%)	9 (4%)
HYPERPLASIA, PAPILLARY		1 (0%)
#TESTIS	(87)	(246)
CYST, NOS		1 (0%)
DEGENERATION, NOS	10 (11%)	26 (11%)
HYPERPLASIA, INTERSTITIAL CELL	32 (37%)	92 (37%)
*EPIDIDYMIS	(88)	(250)
HEMORRHAGE		1 (0%)
INFLAMMATION, ACUTE DIFFUSE	1 (1%)	
GRANULOMA, SPERMATIC		1 (0%)
FIBROSIS, FOCAL		1 (0%)
NECROSIS, FAT	2 (2%)	3 (1%)
NERVOUS SYSTEM		
#BRAIN/MENINGES	(88)	(248)
INFLAMMATION, ACUTE DIFFUSE	1 (1%)	
#CEREBRUM	(88)	(248)
HEMORRHAGE		3 (1%)
GLIOSIS		1 (0%)
NECROSIS, FOCAL	1 (1%)	
#BRAIN	(88)	(248)
HEMORRHAGE		3 (1%)
NECROSIS, FOCAL		1 (0%)
#CEREBELLUM	(88)	(248)
HEMORRHAGE	2 (2%)	2 (1%)
NECROSIS, FOCAL	2 (2%)	
#MEDULLA OBLONGATA	(88)	(248)
NECROSIS, FOCAL		1 (0%)
*SPINAL CORD	(88)	(250)
DEGENERATION, NOS	1 (1%)	
SPECIAL SENSE ORGANS		
*EYE	(88)	(250)
HEMORRHAGE	3 (3%)	4 (2%)
EMPYEMA	1 (1%)	1 (0%)
SYNECHIA, ANTERIOR		1 (0%)
SYNECHIA, POSTERIOR	1 (1%)	2 (1%)
CATARACT	7 (8%)	11 (4%)
*VITREOUS BODY	(88)	(250)
VASCULARIZATION		1 (0%)
*EYE/CORNEA	(88)	(250)
INFLAMMATION, ACUTE FOCAL	2 (2%)	1 (0%)
INFLAMMATION, CHRONIC FOCAL	1 (1%)	1 (0%)
NECROSIS, FOCAL	2 (2%)	1 (0%)
*EYE/IRIS	(88)	(250)
INFLAMMATION, CHRONIC FOCAL	1 (1%)	
*EYE/RETINA	(88)	(250)
DEGENERATION, NOS	18 (20%)	47 (19%)
*HARDERIAN GLAND	(88)	(250)
INFLAMMATION, ACUTE/CHRONIC		1 (0%)
INFLAMMATION, CHRONIC DIFFUSE		1 (0%)

HWBUI0001763

TABLE C1. SUMMARY OF THE INCIDENCE OF NONNEOPLASTIC LESIONS IN MALE RATS IN THE LIFETIME FEED STUDY OF SHORT-RANGE CHRYSOTILE ASBESTOS (Continued)

	CONTROL (UNTR)	SHORT RANGE
SPECIAL SENSE ORGANS (Continued)		
*ZYMBAL GLAND	(88)	(250)
CYST, NOS		1 (0%)
CYSTIC DUCTS	9 (10%)	20 (8%)
ABSCESS, NOS	1 (1%)	
INFLAMMATION, CHRONIC DIFFUSE	1 (1%)	
HYPERKERATOSIS	1 (1%)	5 (2%)
MUSCULOSKELETAL SYSTEM		
*SKULL	(88)	(250)
OSTEOPETROSIS	2 (2%)	2 (1%)
FIBROUS OSTEODYSTROPHY	1 (1%)	
*STERNUM	(88)	(250)
FIBROUS OSTEODYSTROPHY	1 (1%)	
*RIB	(88)	(250)
DEGENERATION, NOS		3 (1%)
BODY CAVITIES		
*MEDIASTINUM	(88)	(250)
ECTOPIA	1 (1%)	
INFLAMMATION, ACUTE DIFFUSE	1 (1%)	
*ABDOMINAL CAVITY	(88)	(250)
CONGESTION, NOS		1 (0%)
HEMORRHAGE		1 (0%)
INFLAMMATION, CHRONIC		1 (0%)
NECROSIS, FAT	2 (2%)	9 (4%)
*PLEURA	(88)	(250)
INFLAMMATION, FIBRINOUS		1 (0%)
INFLAMMATION, CHRONIC DIFFUSE		1 (0%)
*PERICARDIUM	(88)	(250)
INFLAMMATION, FIBRINOUS		1 (0%)
*MESENTERY	(88)	(250)
INFLAMMATION, ACUTE FOCAL		1 (0%)
INFLAMMATION, CHRONIC FOCAL		1 (0%)
INFLAMMATION, CHRONIC DIFFUSE		1 (0%)
ALL OTHER SYSTEMS		
*MULTIPLE ORGANS	(88)	(250)
MINERALIZATION	5 (6%)	1 (0%)
CYST, NOS	1 (1%)	
HEMORRHAGE		1 (0%)
INFLAMMATION, ACUTE DIFFUSE		1 (0%)
INFLAMMATION, CHRONIC	3 (3%)	8 (3%)
PIGMENTATION, NOS		1 (0%)
DIAPHRAGM		
HERNIA, NOS		3
HEMORRHAGE		1
INFLAMMATION, ACUTE DIFFUSE		1
INFLAMMATION, CHRONIC FOCAL	1	
NECROSIS, DIFFUSE		1
MESENTERY OF COLON		
INFLAMMATION, FIBRINOUS		1
SPECIAL MORPHOLOGY SUMMARY		
NECROPSY PERF/NO HISTO PERFORMED		2

NUMBER OF ANIMALS WITH TISSUE EXAMINED MICROSCOPICALLY
* NUMBER OF ANIMALS NECROPSIED

HWBUI0001764

TABLE C2. SUMMARY OF THE INCIDENCE OF NONNEOPLASTIC LESIONS IN FEMALE RATS IN THE LIFETIME FEED STUDY OF SHORT-RANGE CHRYSOTILE ASBESTOS

	CONTROL (UNTR)	SHORT RANGE
ANIMALS INITIALLY IN STUDY	88	250
ANIMALS NECROPSIED	88	250
ANIMALS EXAMINED HISTOPATHOLOGICALLY	88	248
INTEGUMENTARY SYSTEM		
*SKIN	(88)	(250)
EPIDERMAL INCLUSION CYST	1 (1%)	1 (0%)
ULCER, NOS		1 (0%)
ABSCESS, NOS		4 (2%)
INFLAMMATION, CHRONIC FOCAL		1 (0%)
FIBROSIS, FOCAL	1 (1%)	
HYPERKERATOSIS		1 (0%)
ACANTHOSIS		3 (1%)
*SUBCUT TISSUE	(88)	(250)
ABSCESS, NOS		1 (0%)
INFLAMMATION, CHRONIC FOCAL		1 (0%)
RESPIRATORY SYSTEM		
#LUNG/BRONCHUS	(87)	(245)
BRONCHIECTASIS		1 (0%)
#LUNG	(87)	(245)
CONGESTION, NOS	2 (2%)	5 (2%)
HEMORRHAGE	1 (1%)	3 (1%)
INFLAMMATION, INTERSTITIAL	1 (1%)	3 (1%)
PNEUMONIA, ASPIRATION		2 (1%)
INFLAMMATION, ACUTE FOCAL	1 (1%)	2 (1%)
INFLAMMATION, CHRONIC	79 (91%)	229 (93%)
PNEUMONIA INTERSTITIAL CHRONIC	1 (1%)	
GRANULOMA, NOS		2 (1%)
NECROSIS, FOCAL	1 (1%)	
PIGMENTATION, NOS		4 (2%)
HYPERPLASIA, ALVEOLAR EPITHELIUM	5 (6%)	3 (1%)
#LUNG/ALVEOLI	(87)	(245)
HISTIOCYTOSIS		3 (1%)
HEMATOPOIETIC SYSTEM		
#BONE MARROW	(84)	(241)
HYPOPLASIA, NOS	1 (1%)	8 (3%)
HYPERPLASIA, NOS	1 (1%)	1 (0%)
MYELOPOIESIS		1 (0%)
#SPLEEN	(87)	(245)
HEMORRHAGE	2 (2%)	4 (2%)
INFLAMMATION, CHRONIC FOCAL		1 (0%)
FIBROSIS, FOCAL	4 (5%)	7 (3%)
FIBROSIS, MULTIFOCAL	1 (1%)	
FIBROSIS, DIFFUSE	1 (1%)	4 (2%)
NECROSIS, NOS		1 (0%)
NECROSIS, FOCAL	2 (2%)	5 (2%)
NECROSIS, DIFFUSE	1 (1%)	
METAMORPHOSIS FATTY		1 (0%)
HEMOSIDEROSIS	27 (31%)	65 (27%)
METAPLASIA, OSSEOUS		1 (0%)
HYPERPLASIA, MEGAKARYOCYTIC		1 (0%)
HEMATOPOIESIS	24 (28%)	72 (29%)
#SPLENIC CAPSULE	(87)	(245)
FIBROSIS, FOCAL		1 (0%)
FIBROSIS, MULTIFOCAL		2 (1%)
#SPLENIC FOLLICLES	(87)	(245)
ATROPHY, NOS	2 (2%)	3 (1%)

HWBUI0001765

TABLE C2. SUMMARY OF THE INCIDENCE OF NONNEOPLASTIC LESIONS IN FEMALE RATS IN THE LIFETIME FEED STUDY OF SHORT-RANGE CHRYSOTILE ASBESTOS (Continued)

	CONTROL (UNTR)	SHORT RANGE
HEMATOPOIETIC SYSTEM (Continued)		
#LYMPH NODE	(87)	(245)
INFLAMMATION, ACUTE FIBRINOUS		1 (0%)
NECROSIS, DIFFUSE		1 (0%)
HYPERPLASIA, LYMPHOID		2 (1%)
#MANDIBULAR L. NODE	(87)	(245)
HEMORRHAGE	1 (1%)	1 (0%)
INFLAMMATION, FIBRINOUS		1 (0%)
PIGMENTATION, NOS	1 (1%)	
ERYTHROPHAGOCYTOSIS		3 (1%)
HYPERPLASIA, LYMPHOID	15 (17%)	38 (16%)
#CERVICAL LYMPH NODE	(87)	(245)
HYPERPLASIA, LYMPHOID		2 (1%)
#MEDIASTINAL LYMPH NODE	(87)	(245)
CONGESTION, NOS		3 (1%)
HEMORRHAGE	2 (2%)	3 (1%)
INFLAMMATION, FIBRINOUS		1 (0%)
INFLAMMATION, ACUTE		1 (0%)
PIGMENTATION, NOS	3 (3%)	26 (11%)
ERYTHROPHAGOCYTOSIS	2 (2%)	5 (2%)
HYPERPLASIA, RETICULUM CELL	1 (1%)	2 (1%)
HYPERPLASIA, LYMPHOID	1 (1%)	10 (4%)
#HEPATIC LYMPH NODE	(87)	(245)
PIGMENTATION, NOS		1 (0%)
HYPERPLASIA, RETICULUM CELL		1 (0%)
#PANCREATIC LYMPH NODE	(87)	(245)
INFLAMMATION, ACUTE DIFFUSE		1 (0%)
PIGMENTATION, NOS	2 (2%)	12 (5%)
ATROPHY, NOS	1 (1%)	
HYPERPLASIA, RETICULUM CELL	4 (5%)	13 (5%)
HYPERPLASIA, LYMPHOID		2 (1%)
#MESENTERIC LYMPH NODE	(87)	(245)
HEMORRHAGE	2 (2%)	
INFLAMMATION, ACUTE		1 (0%)
PIGMENTATION, NOS	2 (2%)	3 (1%)
ATROPHY, NOS		1 (0%)
ERYTHROPHAGOCYTOSIS		3 (1%)
HYPERPLASIA, RETICULUM CELL	43 (49%)	90 (37%)
HYPERPLASIA, LYMPHOID	4 (5%)	4 (2%)
#ILEOCOLIC LYMPH NODE	(87)	(245)
HYPERPLASIA, RETICULUM CELL	1 (1%)	
#RENAL LYMPH NODE	(87)	(245)
INFLAMMATION, ACUTE DIFFUSE		1 (0%)
#ILIAC LYMPH NODE	(87)	(245)
HYPERPLASIA, LYMPHOID	1 (1%)	
#LIVER	(87)	(244)
LEUKOCYTOSIS, NOS		2 (1%)
HEMATOPOIESIS		3 (1%)
#CECUM	(87)	(244)
HEMATOPOIESIS		1 (0%)
CIRCULATORY SYSTEM		
*MEDIASTINUM	(88)	(250)
PERIARTERITIS		1 (0%)
#LYMPH NODE	(87)	(245)
LYMPHANGIECTASIS		1 (0%)
#MEDIASTINAL L. NODE	(87)	(245)
LYMPHANGIECTASIS		1 (0%)
#HEPATIC LYMPH NODE	(87)	(245)
LYMPHANGIECTASIS	1 (1%)	
#PANCREATIC L. NODE	(87)	(245)
LYMPHANGIECTASIS		1 (0%)

HWBUI0001766

TABLE C2. SUMMARY OF THE INCIDENCE OF NONNEOPLASTIC LESIONS IN FEMALE RATS IN THE LIFETIME FEED STUDY OF SHORT-RANGE CHRYSOTILE ASBESTOS (Continued)

	CONTROL (UNTR)	SHORT RANGE
CIRCULATORY SYSTEM (Continued)		
#MESENTERIC L. NODE	(87)	(245)
LYMPHANGIECTASIS	1 (1%)	1 (0%)
#ILEOCOLIC LYMPH NODE	(87)	(245)
LYMPHANGIECTASIS	1 (1%)	1 (0%)
#ILIAC LYMPH NODE	(87)	(245)
LYMPHANGIECTASIS	1 (1%)	
*ADIPOSE TISSUE	(88)	(250)
PERIARTERITIS		1 (0%)
#HEART	(87)	(245)
THROMBOSIS, NOS		1 (0%)
INFLAMMATION, CHRONIC FOCAL	1 (1%)	
#HEART/ATRIUM	(87)	(245)
THROMBOSIS, NOS	1 (1%)	1 (0%)
#MYOCARDIUM	(87)	(245)
INFLAMMATION, CHRONIC FOCAL	33 (38%)	72 (29%)
INFLAMMATION, CHRONIC DIFFUSE	22 (25%)	65 (27%)
DEGENERATION, NOS		1 (0%)
#PANCREAS	(86)	(245)
PERIARTERITIS		1 (0%)
*MESENTERY	(88)	(250)
PERIARTERITIS		2 (1%)
#UTERUS	(87)	(245)
THROMBOSIS, NOS		1 (0%)
#PITUITARY	(87)	(244)
THROMBOSIS, NOS	1 (1%)	
DIGESTIVE SYSTEM		
*TONGUE	(88)	(250)
ABSCESS, NOS		1 (0%)
ACANTHOSIS		2 (1%)
#SALIVARY GLAND	(87)	(243)
ABSCESS, NOS		1 (0%)
INFLAMMATION, CHRONIC DIFFUSE		1 (0%)
ATROPHY, FOCAL	1 (1%)	
#LIVER	(87)	(244)
HEMORRHAGE	2 (2%)	6 (2%)
INFLAMMATION, FIBRINOUS	1 (1%)	
INFLAMMATION, ACUTE FOCAL		1 (0%)
INFLAMMATION, CHRONIC		1 (0%)
GRANULOMA, NOS	26 (30%)	49 (20%)
HEPATITIS, TOXIC	12 (14%)	37 (15%)
NECROSIS, FOCAL	4 (5%)	33 (14%)
INFARCT, NOS		1 (0%)
METAMORPHOSIS FATTY	30 (34%)	75 (31%)
PIGMENTATION, NOS	12 (14%)	56 (23%)
MITOTIC ALTERATION		2 (1%)
FOCAL CELLULAR CHANGE	42 (48%)	84 (34%)
HEPATOCYTOMEGALY		2 (1%)
ANGIECTASIS	6 (7%)	3 (1%)
#BILE DUCT	(87)	(244)
DILATATION, NOS		1 (0%)
CYST, NOS		1 (0%)
INFLAMMATION, CHRONIC	11 (13%)	28 (11%)
FIBROSIS	1 (1%)	2 (1%)
FIBROSIS, FOCAL		1 (0%)
HYPERPLASIA, NOS	3 (3%)	16 (7%)
HYPERPLASIA, FOCAL		1 (0%)
#PANCREAS	(86)	(245)
ECTOPIA	3 (3%)	5 (2%)
INFLAMMATION, CHRONIC DIFFUSE	1 (1%)	1 (0%)
ATROPHY, FOCAL	4 (5%)	8 (3%)
ATROPHY, DIFFUSE	2 (2%)	5 (2%)

HWBUI0001767

TABLE C2. SUMMARY OF THE INCIDENCE OF NONNEOPLASTIC LESIONS IN FEMALE RATS IN THE LIFETIME FEED STUDY OF SHORT-RANGE CHRYSOTILE ASBESTOS (Continued)

	CONTROL (UNTR)	SHORT RANGE
DIGESTIVE SYSTEM (Continued)		
#PANCREATIC ACINUS	(86)	(245)
HYPERPLASIA, FOCAL	1 (1%)	3 (1%)
*PHARYNGEAL MUCOSA	(88)	(250)
HYPERKERATOSIS		1 (0%)
#ESOPHAGUS	(87)	(244)
HYPERKERATOSIS	4 (5%)	8 (3%)
#STOMACH	(87)	(245)
HEMORRHAGE		2 (1%)
INFLAMMATION, ACUTE FOCAL	2 (2%)	2 (1%)
INFLAMMATION, ACUTE DIFFUSE	1 (1%)	
INFLAMMATION, CHRONIC FOCAL	4 (5%)	9 (4%)
INFLAMMATION, CHRONIC DIFFUSE	9 (10%)	35 (14%)
ULCER, PERFORATED	7 (8%)	21 (9%)
ADHESION, NOS	2 (2%)	1 (0%)
NECROSIS, FOCAL	12 (14%)	33 (13%)
NECROSIS, DIFFUSE	2 (2%)	2 (1%)
HYPERKERATOSIS	21 (24%)	59 (24%)
ACANTHOSIS	19 (22%)	59 (24%)
#GASTRIC SUBMUCOSA	(87)	(245)
EDEMA, NOS		1 (0%)
#GASTRIC MUSCULARIS	(87)	(245)
DEGENERATION, NOS		1 (0%)
#GASTRIC FUNDUS	(87)	(245)
HYPERPLASIA, EPITHELIAL		1 (0%)
#SMALL INTESTINE	(87)	(244)
PARASITISM		1 (0%)
#DUODENUM	(87)	(244)
ULCER, PERFORATED		1 (0%)
#COLON	(87)	(244)
EDEMA, NOS		1 (0%)
INFLAMMATION, ACUTE FOCAL		1 (0%)
INFLAMMATION, CHRONIC FOCAL	2 (2%)	1 (0%)
PARASITISM	8 (9%)	13 (5%)
NECROSIS, FOCAL	1 (1%)	2 (1%)
#COLONIC SUBMUCOSA	(87)	(244)
FIBROSIS, FOCAL		1 (0%)
#CECUM	(87)	(244)
HEMORRHAGE	1 (1%)	
INFLAMMATION, ACUTE FOCAL	1 (1%)	
INFLAMMATION, ACUTE DIFFUSE		1 (0%)
INFLAMMATION, CHRONIC FOCAL	1 (1%)	3 (1%)
INFLAMMATION, CHRONIC DIFFUSE		1 (0%)
GRANULOMA, NOS		1 (0%)
FIBROSIS, FOCAL		1 (0%)
NECROSIS, FOCAL	2 (2%)	3 (1%)
HYPERPLASIA, EPITHELIAL	1 (1%)	
#DESCENDING COLON	(87)	(244)
PARASITISM		1 (0%)
URINARY SYSTEM		
#KIDNEY	(87)	(245)
MINERALIZATION	63 (72%)	208 (85%)
INFLAMMATION, ACUTE FOCAL		1 (0%)
INFLAMMATION, CHRONIC	84 (97%)	231 (94%)
NEPHROSIS, NOS		1 (0%)
METAMORPHOSIS FATTY		2 (1%)
PIGMENTATION, NOS		1 (0%)
HYPERPLASIA, TUBULAR CELL		1 (0%)

HWBUI0001768

TABLE C2. SUMMARY OF THE INCIDENCE OF NONNEOPLASTIC LESIONS IN FEMALE RATS IN THE LIFETIME FEED STUDY OF SHORT-RANGE CHRYSOTILE ASBESTOS (Continued)

	CONTROL (UNTR)	SHORT RANGE
URINARY SYSTEM (Continued)		
#KIDNEY/TUBULE	(87)	(245)
DEGENERATION, NOS	1 (1%)	
NECROSIS, DIFFUSE		1 (0%)
PIGMENTATION, NOS	57 (66%)	198 (81%)
#URINARY BLADDER	(87)	(242)
HEMORRHAGE	1 (1%)	
INFLAMMATION, CHRONIC FOCAL	1 (1%)	
HYPERPLASIA, EPITHELIAL	1 (1%)	
HYPERPLASIA, DIFFUSE	1 (1%)	
HYPERPLASIA, PAPILLARY		1 (0%)
ENDOCRINE SYSTEM		
#PITUITARY	(87)	(244)
CYST, NOS	6 (7%)	21 (9%)
HEMORRHAGE	3 (3%)	4 (2%)
HEMORRHAGIC CYST		2 (1%)
GLIOSIS		1 (0%)
NECROSIS, FOCAL	1 (1%)	
PIGMENTATION, NOS		2 (1%)
HYPERPLASIA, FOCAL	6 (7%)	19 (8%)
HYPERPLASIA, DIFFUSE	1 (1%)	1 (0%)
ANGIECTASIS	15 (17%)	42 (17%)
METAPLASIA, OSSEOUS		1 (0%)
#ADRENAL	(87)	(245)
ATROPHY, NOS		1 (0%)
HYPERPLASIA, FOCAL		1 (0%)
ANGIECTASIS		1 (0%)
#ADRENAL CORTEX	(87)	(245)
DEGENERATION, NOS	2 (2%)	4 (2%)
NECROSIS, FOCAL	1 (1%)	1 (0%)
METAMORPHOSIS FATTY	32 (37%)	96 (39%)
HYPERPLASIA, FOCAL	8 (9%)	11 (4%)
ANGIECTASIS	1 (1%)	2 (1%)
#ADRENAL MEDULLA	(87)	(245)
HYPERPLASIA, NOS	1 (1%)	
HYPERPLASIA, FOCAL	16 (18%)	47 (19%)
#THYROID	(87)	(244)
CYSTIC FOLLICLES	1 (1%)	3 (1%)
FOLLICULAR CYST, NOS	4 (5%)	10 (4%)
HYPERPLASIA, C-CELL	20 (23%)	58 (24%)
ANGIECTASIS		1 (0%)
#PARATHYROID	(85)	(222)
HYPERPLASIA, NOS	1 (1%)	7 (3%)
#PANCREATIC ISLETS	(86)	(245)
HYPERPLASIA, FOCAL	1 (1%)	1 (0%)
REPRODUCTIVE SYSTEM		
*MAMMARY GLAND	(88)	(250)
GALACTOCELE	7 (8%)	39 (16%)
CYST, NOS		1 (0%)
CYSTIC DUCTS	46 (52%)	116 (46%)
INFLAMMATION, ACUTE DIFFUSE	1 (1%)	
ABSCESS, NOS		1 (0%)
HYPERPLASIA, NOS	8 (9%)	23 (9%)
HYPERPLASIA, FOCAL	1 (1%)	1 (0%)
HYPERPLASIA, DIFFUSE	2 (2%)	8 (3%)

HWBUI0001769

TABLE C2. SUMMARY OF THE INCIDENCE OF NONNEOPLASTIC LESIONS IN FEMALE RATS IN THE LIFETIME FEED STUDY OF SHORT-RANGE CHRYSOTILE ASBESTOS (Continued)

	CONTROL (UNTR)	SHORT RANGE
REPRODUCTIVE SYSTEM (Continued)		
*PREPUTIAL GLAND	(88)	(250)
CYSTIC DUCTS	3 (3%)	5 (2%)
INFLAMMATION, ACUTE	1 (1%)	
ABSCESS, NOS		4 (2%)
HYPERPLASIA, FOCAL		1 (0%)
HYPERKERATOSIS	1 (1%)	3 (1%)
*VAGINA	(88)	(250)
HYPERKERATOSIS	1 (1%)	
ACANTHOSIS	1 (1%)	
#UTERUS	(87)	(245)
HYDROMETRA	2 (2%)	9 (4%)
HEMORRHAGE	1 (1%)	1 (0%)
INFLAMMATION, ACUTE		1 (0%)
INFLAMMATION, ACUTE FOCAL	1 (1%)	
INFLAMMATION, CHRONIC FOCAL		1 (0%)
INFLAMMATION, CHRONIC DIFFUSE	1 (1%)	
NECROSIS, FOCAL		1 (0%)
NECROSIS, FAT	1 (1%)	
HYPERPLASIA, PAPILLARY	1 (1%)	
ANGIECTASIS		1 (0%)
#CERVIX UTERI	(87)	(245)
ABSCESS, NOS		2 (1%)
INFLAMMATION, CHRONIC DIFFUSE		1 (0%)
FIBROSIS	1 (1%)	3 (1%)
HYPERKERATOSIS		2 (1%)
ACANTHOSIS		4 (2%)
#UTERUS/ENDOMETRIUM	(87)	(245)
CYST, NOS	3 (3%)	6 (2%)
HYPERPLASIA, FOCAL	1 (1%)	1 (0%)
HYPERPLASIA, PAPILLARY		2 (1%)
#FALLOPIAN TUBE	(87)	(245)
RETENTION FLUID	1 (1%)	
#OVARY	(87)	(245)
CYST, NOS	2 (2%)	16 (7%)
FOLLICULAR CYST, NOS	1 (1%)	3 (1%)
PAROVARIAN CYST		2 (1%)
HEMORRHAGE		1 (0%)
INFLAMMATION, ACUTE DIFFUSE		1 (0%)
ABSCESS, NOS	1 (1%)	
NERVOUS SYSTEM		
#BRAIN/MENINGES	(87)	(245)
INFLAMMATION, ACUTE DIFFUSE		1 (0%)
#CEREBRUM	(87)	(245)
HEMORRHAGE	3 (3%)	3 (1%)
GLIOSIS	1 (1%)	2 (1%)
NECROSIS, FOCAL	1 (1%)	
#BRAIN	(87)	(245)
HEMORRHAGE		2 (1%)
#CEREBELLUM	(87)	(245)
HEMORRHAGE	1 (1%)	1 (0%)
NECROSIS, FOCAL		1 (0%)
SPECIAL SENSE ORGANS		
*EYE	(88)	(250)
HEMORRHAGE	4 (5%)	2 (1%)
EMPYEMA		1 (0%)
SYNECHIA, POSTERIOR	3 (3%)	4 (2%)
CATARACT	11 (13%)	21 (8%)
PHTHISIS BULBI		2 (1%)

HWBUI0001770

TABLE C2. SUMMARY OF THE INCIDENCE OF NONNEOPLASTIC LESIONS IN FEMALE RATS IN THE LIFETIME FEED STUDY OF SHORT-RANGE CHRYSOTILE ASBESTOS (Continued)

	CONTROL (UNTR)	SHORT RANGE
SPECIAL SENSE ORGANS (Continued)		
*EYE/CORNEA	(88)	(250)
INFLAMMATION, ACUTE FOCAL		1 (0%)
INFLAMMATION, CHRONIC FOCAL		2 (1%)
INFLAMMATION, CHRONIC DIFFUSE	1 (1%)	
*EYE/RETINA	(88)	(250)
DEGENERATION, NOS	26 (30%)	71 (28%)
*EYELID	(88)	(250)
ACANTHOSIS		1 (0%)
*HARDERIAN GLAND	(88)	(250)
INFLAMMATION, ACUTE DIFFUSE		2 (1%)
*ZYMBAL GLAND	(88)	(250)
CYSTIC DUCTS	2 (2%)	9 (4%)
ABSCESS, NOS		1 (0%)
MUSCULOSKELETAL SYSTEM		
*SKULL	(88)	(250)
OSTEOPETROSIS	3 (3%)	9 (4%)
FIBROUS OSTEODYSTROPHY		1 (0%)
*STERNUM	(88)	(250)
OSTEOPETROSIS	5 (6%)	13 (5%)
DEGENERATION, NOS		1 (0%)
*RIB	(88)	(250)
DEGENERATION, NOS	2 (2%)	
*FEMUR	(88)	(250)
OSTEOPETROSIS		1 (0%)
BODY CAVITIES		
*MEDIASTINUM	(88)	(250)
INFLAMMATION, FIBRINOUS	1 (1%)	
INFLAMMATION, ACUTE DIFFUSE		1 (0%)
*ABDOMINAL CAVITY	(88)	(250)
NECROSIS, FAT	2 (2%)	5 (2%)
*PERITONEUM	(88)	(250)
INFLAMMATION, NOS		1 (0%)
*PLEURA	(88)	(250)
INFLAMMATION, ACUTE FOCAL		1 (0%)
INFLAMMATION, CHRONIC FOCAL		1 (0%)
*MESENTERY	(88)	(250)
INFLAMMATION, ACUTE DIFFUSE		1 (0%)
INFLAMMATION, CHRONIC FOCAL	2 (2%)	2 (1%)
ALL OTHER SYSTEMS		
*MULTIPLE ORGANS	(88)	(250)
MINERALIZATION		2 (1%)
INFLAMMATION, CHRONIC	1 (1%)	1 (0%)
PIGMENTATION, NOS	2 (2%)	1 (0%)
DIAPHRAGM		
HERNIA, NOS	7	8
SPECIAL MORPHOLOGY SUMMARY		
NECROPSY PERF/NO HISTO PERFORMED		5
AUTO/NECROPSY/HISTO PERFORMED		1
AUTO/NECROPSY/NO HISTO	1	

NUMBER OF ANIMALS WITH TISSUE EXAMINED MICROSCOPICALLY
* NUMBER OF ANIMALS NECROPSIED

HWBUI0001771

APPENDIX D

SUMMARY OF THE INCIDENCE OF NONNEOPLASTIC LESIONS IN RATS IN THE LIFETIME FEED STUDIES OF INTERMEDIATE-RANGE CHRYSOTILE ASBESTOS

HWBUI0001772

TABLE D1. SUMMARY OF THE INCIDENCE OF NONNEOPLASTIC LESIONS IN MALE RATS IN THE LIFETIME FEED STUDY OF INTERMEDIATE-RANGE (IR) CHRYSOTILE ASBESTOS

	CONTROL (UNTR)	DMH	IR	IR + DMH	IR/PW
ANIMALS INITIALLY IN STUDY	88	125	250	175	100
ANIMALS NECROPSIED	88	125	250	175	100
ANIMALS EXAMINED HISTOPATHOLOGICALLY	85	125	250	175	100
INTEGUMENTARY SYSTEM					
*SKIN	(88)	(125)	(250)	(175)	(100)
CYST, NOS			3 (1%)		
EPIDERMAL INCLUSION CYST	1 (1%)	3 (2%)	1 (0%)		
DERMAL INCLUSION CYST			1 (0%)	1 (1%)	
EDEMA, NOS			2 (1%)		
INFLAMMATION, ACUTE		1 (1%)			
INFLAMMATION, ACUTE/CHRONIC		1 (1%)			
HYPERPLASIA, NOS			1 (0%)		
HYPERKERATOSIS		1 (1%)			
ACANTHOSIS		1 (1%)	2 (1%)		
*SUBCUT TISSUE	(88)	(125)	(250)	(175)	(100)
MINERALIZATION					1 (1%)
MULTILOCULAR CYST	1 (1%)				
STEATITIS			1 (0%)		
INFLAMMATION, SUPPURATIVE		1 (1%)	3 (1%)		
INFLAMMATION, ACUTE					1 (1%)
ABSCESS, NOS				1 (1%)	
INFLAMMATION, ACUTE/CHRONIC	1 (1%)				
INFLAMMATION, CHRONIC			1 (0%)		
NECROSIS, FAT	1 (1%)		1 (0%)		
HYPERPLASIA, FOCAL					1 (1%)
HYPERKERATOSIS			1 (0%)		
RESPIRATORY SYSTEM					
*NASAL CAVITY	(88)	(125)	(250)	(175)	(100)
HEMORRHAGE					1 (1%)
INFLAMMATION, SUPPURATIVE				1 (1%)	
INFLAMMATION, ACUTE					1 (1%)
*NASAL TURBINATE	(88)	(125)	(250)	(175)	(100)
CONGESTION, NOS			1 (0%)		
INFLAMMATION, SUPPURATIVE			1 (0%)		
#TRACHEA	(85)	(124)	(250)	(175)	(99)
CYST, NOS			1 (0%)		
#LUNG	(85)	(125)	(250)	(175)	(99)
BRONCHIECTASIS					2 (2%)
CONGESTION, NOS	11 (13%)	7 (6%)	8 (3%)	3 (2%)	7 (7%)
HEMORRHAGE	3 (4%)	1 (1%)	1 (0%)	2 (1%)	
INFLAMMATION, INTERSTITIAL	4 (5%)	2 (2%)	9 (4%)	4 (2%)	4 (4%)
PNEUMONIA, ASPIRATION	1 (1%)				
INFLAMMATION, SUPPURATIVE		1 (1%)	1 (0%)	1 (1%)	2 (2%)
BRONCHOPNEUMONIA, ACUTE	1 (1%)				
INFLAMMATION, ACUTE				1 (1%)	
INFLAMMATION, ACUTE/CHRONIC			1 (0%)	1 (1%)	
INFLAMMATION, CHRONIC	45 (53%)	86 (69%)	98 (39%)	60 (34%)	51 (52%)
INFLAMMATION, CHRONIC FOCAL			1 (0%)		
ABSCESS, CHRONIC					3 (3%)

HWBUI0001773

TABLE D1. SUMMARY OF THE INCIDENCE OF NONNEOPLASTIC LESIONS IN MALE RATS IN THE LIFETIME FEED STUDY OF INTERMEDIATE-RANGE (IR) CHRYSOTILE ASBESTOS (Continued)

	CONTROL (UNTR)	DMH	IR	IR + DMH	IR/PW
RESPIRATORY SYSTEM					
#LUNG (Continued)					
INFLAMMATION, GRANULOMATOUS			1 (0%)		
INFLAMMATION GRANULOMATOUS FOCAL			3 (1%)		1 (1%)
NECROSIS, FOCAL			1 (0%)		
HYPERPLASIA, ALVEOLAR EPITHELIUM	5 (6%)	3 (2%)	13 (5%)	5 (3%)	4 (4%)
METAPLASIA, OSSEOUS				1 (1%)	
#LUNG/ALVEOLI	(85)	(125)	(250)	(175)	(99)
EDEMA, NOS			1 (0%)		
HISTIOCYTOSIS			10 (4%)		
HEMATOPOIETIC SYSTEM					
*MULTIPLE ORGANS	(88)	(125)	(250)	(175)	(100)
HYPERPLASIA, LYMPHOID			1 (0%)		
#BONE MARROW	(84)	(122)	(248)	(175)	(98)
HYPERPLASIA, NOS				1 (1%)	
#SPLEEN	(85)	(125)	(250)	(175)	(99)
ECTOPIA			1 (0%)		
CONGESTION, NOS	1 (1%)		1 (0%)		1 (1%)
INFLAMMATION, CHRONIC			1 (0%)		
FIBROSIS	1 (1%)	2 (2%)	22 (9%)	5 (3%)	3 (3%)
FIBROSIS, FOCAL	2 (2%)		5 (2%)	1 (1%)	3 (3%)
NECROSIS, NOS		2 (2%)			
NECROSIS, FOCAL					1 (1%)
NECROSIS, ISCHEMIC					1 (1%)
INFARCT, NOS			6 (2%)	8 (5%)	
INFARCT, HEALED				1 (1%)	
PIGMENTATION, NOS	1 (1%)				
HEMOSIDEROSIS	13 (15%)	10 (8%)	46 (18%)	18 (10%)	16 (16%)
ATROPHY, NOS	7 (8%)	1 (1%)	1 (0%)		
HYPERPLASIA, STROMAL	1 (1%)				
ANGIECTASIS	1 (1%)		1 (0%)		
HYPERPLASIA, RETICULUM CELL	1 (1%)				
HEMATOPOIESIS	7 (8%)	9 (7%)	24 (10%)	13 (7%)	6 (6%)
#SPLENIC CAPSULE	(85)	(125)	(250)	(175)	(99)
INFLAMMATION, CHRONIC	1 (1%)				
FIBROSIS			1 (0%)		
#SPLENIC FOLLICLES	(85)	(125)	(250)	(175)	(99)
ATROPHY, NOS		2 (2%)			1 (1%)
#MANDIBULAR L. NODE	(85)	(125)	(250)	(175)	(100)
CONGESTION, NOS	1 (1%)	2 (2%)	3 (1%)		1 (1%)
HEMORRHAGE			2 (1%)	2 (1%)	2 (2%)
INFLAMMATION, SUPPURATIVE				1 (1%)	
INFLAMMATION, ACUTE			1 (0%)		
NECROSIS, NOS			1 (0%)		
PIGMENTATION, NOS	1 (1%)	1 (1%)	3 (1%)		2 (2%)
HYPERPLASIA, PLASMA CELL		13 (10%)	46 (18%)	40 (23%)	38 (38%)
HYPERPLASIA, RETICULUM CELL			1 (0%)	1 (1%)	
HYPERPLASIA, LYMPHOID	12 (14%)	12 (10%)	10 (4%)	2 (1%)	9 (9%)
#CERVICAL LYMPH NODE	(85)	(125)	(250)	(175)	(100)
CONGESTION, NOS	1 (1%)	1 (1%)			
HEMORRHAGE	1 (1%)				
PIGMENTATION, NOS			1 (0%)		
HYPERPLASIA, PLASMA CELL		3 (2%)	1 (0%)		3 (3%)
HYPERPLASIA, LYMPHOID	1 (1%)	2 (2%)	1 (0%)	1 (1%)	

HWBUI0001774

TABLE D1. SUMMARY OF THE INCIDENCE OF NONNEOPLASTIC LESIONS IN MALE RATS IN THE LIFETIME FEED STUDY OF INTERMEDIATE-RANGE (IR) CHRYSOTILE ASBESTOS (Continued)

	CONTROL (UNTR)	DMH	IR	IR + DMH	IR/PW
HEMATOPOIETIC SYSTEM (Continued)					
#MEDIASTINAL L. NODE	(85)	(125)	(250)	(175)	(100)
CONGESTION, NOS	3 (4%)		4 (2%)	3 (2%)	1 (1%)
HEMORRHAGE	1 (1%)	9 (7%)	18 (7%)	12 (7%)	14 (14%)
INFLAMMATION, SUPPURATIVE				1 (1%)	1 (1%)
NECROSIS, NOS			1 (0%)		
PIGMENTATION, NOS	5 (6%)	15 (12%)	58 (23%)	41 (23%)	41 (41%)
HYPERPLASIA, PLASMA CELL			3 (1%)	11 (6%)	9 (9%)
HYPERPLASIA, RETICULUM CELL	1 (1%)	1 (1%)	3 (1%)	4 (2%)	1 (1%)
HYPERPLASIA, LYMPHOID	2 (2%)	1 (1%)	1 (0%)		
#CELIAC LYMPH NODE	(85)	(125)	(250)	(175)	(100)
HYPERPLASIA, RETICULUM CELL				1 (1%)	
#PANCREATIC L. NODE	(85)	(125)	(250)	(175)	(100)
HEMORRHAGE			3 (1%)		
INFLAMMATION, ACUTE			1 (0%)		
NECROSIS, NOS	1 (1%)				
PIGMENTATION, NOS		2 (2%)	14 (6%)	7 (4%)	6 (6%)
HEMOSIDEROSIS	1 (1%)				
HYPERPLASIA, PLASMA CELL					1 (1%)
HYPERPLASIA, RETICULUM CELL			1 (0%)	1 (1%)	1 (1%)
HYPERPLASIA, LYMPHOID	3 (4%)	1 (1%)		1 (1%)	2 (2%)
HEMATOPOIESIS				1 (1%)	
#MESENTERIC L. NODE	(85)	(125)	(250)	(175)	(100)
HEMORRHAGE	1 (1%)		2 (1%)	1 (1%)	2 (2%)
INFLAMMATION, SUPPURATIVE	1 (1%)				
PIGMENTATION, NOS		25 (20%)	28 (11%)	7 (4%)	28 (28%)
ANGIECTASIS	1 (1%)				
ERYTHROPHAGOCYTOSIS	1 (1%)				
HYPERPLASIA, PLASMA CELL		1 (1%)			1 (1%)
HYPERPLASIA, RETICULUM CELL	1 (1%)	4 (3%)	12 (5%)	2 (1%)	
HYPERPLASIA, LYMPHOID	6 (7%)	8 (6%)	7 (3%)		3 (3%)
#ILEOCOLIC LYMPH NODE	(85)	(125)	(250)	(175)	(100)
HYPERPLASIA, LYMPHOID		1 (1%)			
#RENAL LYMPH NODE	(85)	(125)	(250)	(175)	(100)
HEMORRHAGE	1 (1%)		2 (1%)		
INFLAMMATION, ACUTE			1 (0%)		
NECROSIS, NOS			1 (0%)		
PIGMENTATION, NOS		1 (1%)	5 (2%)		1 (1%)
HYPERPLASIA, LYMPHOID	1 (1%)		1 (0%)		
#ILIAC LYMPH NODE	(85)	(125)	(250)	(175)	(100)
HYPERPLASIA, PLASMA CELL			1 (0%)		
HYPERPLASIA, LYMPHOID	2 (2%)				
#AXILLARY LYMPH NODE	(85)	(125)	(250)	(175)	(100)
HEMORRHAGE			1 (0%)		
PIGMENTATION, NOS			1 (0%)		
#BRACHIAL LYMPH NODE	(85)	(125)	(250)	(175)	(100)
PIGMENTATION, NOS				1 (1%)	
#POPLITEAL LYMPH NODE	(85)	(125)	(250)	(175)	(100)
HYPERPLASIA, PLASMA CELL				1 (1%)	
*STERNUM	(88)	(125)	(250)	(175)	(100)
MYELOFIBROSIS			3 (1%)		
MYELOSCLEROSIS					2 (2%)
HEMATOPOIESIS	1 (1%)				
*FEMUR	(88)	(125)	(250)	(175)	(100)
MYELOSCLEROSIS					1 (1%)
#LUNG	(85)	(125)	(250)	(175)	(99)
LEUKOCYTOSIS, NOS	3 (4%)	2 (2%)	1 (0%)		

HWBUI0001775

TABLE D1. SUMMARY OF THE INCIDENCE OF NONNEOPLASTIC LESIONS IN MALE RATS IN THE LIFETIME FEED STUDY OF INTERMEDIATE-RANGE (IR) CHRYSOTILE ASBESTOS (Continued)

	CONTROL (UNTR)	DMH	IR	IR + DMH	IR/PW
HEMATOPOIETIC SYSTEM (Continued)					
#LIVER	(85)	(125)	(250)	(175)	(100)
LEUKOCYTOSIS, NOS	2 (2%)	1 (1%)			
MEGAKARYOCYTOSIS			1 (0%)		
HEMATOPOIESIS		1 (1%)			
#HEPATIC SINUSOID	(85)	(125)	(250)	(175)	(100)
LEUKOCYTOSIS, NOS			3 (1%)		
#COLON	(85)	(125)	(250)	(175)	(100)
HYPERPLASIA, LYMPHOID					10 (10%)
#CECUM	(85)	(125)	(250)	(175)	(100)
HYPERPLASIA, LYMPHOID					1 (1%)
#ASCENDING COLON	(85)	(125)	(250)	(175)	(100)
HYPERPLASIA, LYMPHOID		1 (1%)			
#ADRENAL	(85)	(125)	(250)	(175)	(100)
HEMATOPOIESIS					1 (1%)
#THYMUS	(62)	(107)	(212)	(156)	(87)
ECTOPIA			1 (0%)		
THYROGLOSSAL DUCT CYST				1 (1%)	
CONGESTION, NOS		1 (1%)	1 (0%)		
CIRCULATORY SYSTEM					
#LYMPH NODE	(85)	(125)	(250)	(175)	(100)
LYMPHANGIECTASIS		1 (1%)	1 (0%)		
#MANDIBULAR L. NODE	(85)	(125)	(250)	(175)	(100)
LYMPHANGIECTASIS	9 (11%)	12 (10%)	23 (9%)	11 (6%)	13 (13%)
#CERVICAL LYMPH NODE	(85)	(125)	(250)	(175)	(100)
LYMPHANGIECTASIS		1 (1%)	1 (0%)		
#MEDIASTINAL L. NODE	(85)	(125)	(250)	(175)	(100)
LYMPHANGIECTASIS	1 (1%)	1 (1%)	5 (2%)	2 (1%)	1 (1%)
#CELIAC LYMPH NODE	(85)	(125)	(250)	(175)	(100)
LYMPHANGIECTASIS			1 (0%)	5 (3%)	2 (2%)
#PANCREATIC L. NODE	(85)	(125)	(250)	(175)	(100)
LYMPHANGIECTASIS			1 (0%)		
#MESENTERIC L. NODE	(85)	(125)	(250)	(175)	(100)
LYMPHANGIECTASIS	5 (6%)	6 (5%)	16 (6%)	6 (3%)	11 (11%)
#ILEOCOLIC LYMPH NODE	(85)	(125)	(250)	(175)	(100)
LYMPHANGIECTASIS	1 (1%)	6 (5%)	2 (1%)	1 (1%)	2 (2%)
#RENAL LYMPH NODE	(85)	(125)	(250)	(175)	(100)
LYMPHANGIECTASIS			1 (0%)		
#ILIAC LYMPH NODE	(85)	(125)	(250)	(175)	(100)
LYMPHANGIECTASIS	1 (1%)		1 (0%)		1 (1%)
#AXILLARY LYMPH NODE	(85)	(125)	(250)	(175)	(100)
LYMPHANGIECTASIS		1 (1%)			
*SKELETAL MUSCLE	(88)	(125)	(250)	(175)	(100)
THROMBOSIS, NOS			1 (0%)		
#LUNG/BRONCHIOLE	(85)	(125)	(250)	(175)	(99)
PERIARTERITIS					1 (1%)
#LUNG	(85)	(125)	(250)	(175)	(99)
THROMBUS, FIBRIN		2 (2%)	1 (0%)		
#HEART	(85)	(125)	(250)	(175)	(99)
THROMBUS, FIBRIN			1 (0%)		
INFLAMMATION, FIBRINOUS			1 (0%)		
INFLAMMATION, CHRONIC	1 (1%)	1 (1%)	1 (0%)		
FIBROSIS	1 (1%)		1 (0%)		
#HEART/ATRIUM	(85)	(125)	(250)	(175)	(99)
THROMBOSIS, NOS	1 (1%)				
THROMBUS, ORGANIZED			1 (0%)		
THROMBUS, FIBRIN			2 (1%)		

HWBUI0001776

TABLE D1. SUMMARY OF THE INCIDENCE OF NONNEOPLASTIC LESIONS IN MALE RATS IN THE LIFETIME FEED STUDY OF INTERMEDIATE-RANGE (IR) CHRYSOTILE ASBESTOS (Continued)

	CONTROL (UNTR)	DMH	IR	IR + DMH	IR/PW
CIRCULATORY SYSTEM (Continued)					
#MYOCARDIUM	(85)	(125)	(250)	(175)	(99)
MINERALIZATION	2 (2%)	2 (2%)	2 (1%)		2 (2%)
THROMBUS, FIBRIN			1 (0%)		
INFLAMMATION, SUPPURATIVE	1 (1%)	1 (1%)			
INFLAMMATION, CHRONIC		6 (5%)	8 (3%)	15 (9%)	4 (4%)
FIBROSIS	53 (62%)	70 (56%)	170 (68%)	90 (51%)	72 (73%)
FIBROSIS, FOCAL	1 (1%)				
DEGENERATION, NOS	2 (2%)				
#CARDIAC VALVE	(85)	(125)	(250)	(175)	(99)
INFLAMMATION, CHRONIC		1 (1%)			
*AORTA	(88)	(125)	(250)	(175)	(100)
MINERALIZATION	9 (10%)		5 (2%)		2 (2%)
*CORONARY ARTERY	(88)	(125)	(250)	(175)	(100)
MINERALIZATION		1 (1%)			2 (2%)
*PULMONARY ARTERY	(88)	(125)	(250)	(175)	(100)
MINERALIZATION			1 (0%)		
*BRONCHIAL ARTERY	(88)	(125)	(250)	(175)	(100)
INFLAMMATION, CHRONIC		1 (1%)			
*SUP. PANC-DUOD. ARTERY	(88)	(125)	(250)	(175)	(100)
MINERALIZATION			1 (0%)		
THROMBUS, ORGANIZED			1 (0%)		
PERIARTERITIS					1 (1%)
*MESENTERIC ARTERY	(88)	(125)	(250)	(175)	(100)
PERIARTERITIS					1 (1%)
#LIVER	(85)	(125)	(250)	(175)	(100)
THROMBOSIS, NOS	1 (1%)				
THROMBUS, FIBRIN			1 (0%)	1 (1%)	1 (1%)
#PANCREAS	(85)	(124)	(249)	(174)	(99)
THROMBUS, CANALIZED	1 (1%)				
PERIARTERITIS			1 (0%)	5 (3%)	
#COLONIC SEROSA	(85)	(125)	(250)	(175)	(100)
PERIARTERITIS			1 (0%)		
#TESTIS	(84)	(125)	(250)	(175)	(100)
PERIARTERITIS			1 (0%)		1 (1%)
#ADRENAL	(85)	(125)	(250)	(175)	(100)
THROMBOSIS, NOS	1 (1%)				
DIGESTIVE SYSTEM					
*MOUTH	(88)	(125)	(250)	(175)	(100)
ABSCESS, NOS			1 (0%)		
ACANTHOSIS			1 (0%)		
*MOUTH/ORAL CAVITY	(88)	(125)	(250)	(175)	(100)
INFLAMMATION, CHRONIC				1 (1%)	
*TONGUE	(88)	(125)	(250)	(175)	(100)
ECTOPIA					1 (1%)
CYST, NOS				1 (1%)	
EDEMA, NOS					1 (1%)
INFLAMMATION, ACUTE					1 (1%)
ABSCESS, CHRONIC			1 (0%)		
HYPERKERATOSIS			2 (1%)		
ACANTHOSIS			1 (0%)		
#SALIVARY GLAND	(84)	(124)	(247)	(173)	(98)
CYST, NOS				1 (1%)	
INFLAMMATION, ACUTE/ CHRONIC			2 (1%)		
INFLAMMATION, CHRONIC		1 (1%)	3 (1%)	3 (2%)	
HYPERTROPHY, FOCAL			1 (0%)		
#SALIVARY SEROUS GLAND	(84)	(124)	(247)	(173)	(98)
ATROPHY, NOS		1 (1%)			

HWBUI0001777

TABLE D1. SUMMARY OF THE INCIDENCE OF NONNEOPLASTIC LESIONS IN MALE RATS IN THE LIFETIME FEED STUDY OF INTERMEDIATE-RANGE (IR) CHRYSOTILE ASBESTOS (Continued)

	CONTROL (UNTR)	DMH	IR	IR + DMH	IR/PW
DIGESTIVE SYSTEM (Continued)					
#LIVER	(85)	(125)	(250)	(175)	(100)
CYST, NOS		1 (1%)	1 (0%)	1 (1%)	
MULTILOCULAR CYST				3 (2%)	
CONGESTION, NOS	3 (4%)	1 (1%)	2 (1%)		4 (4%)
HEMORRHAGE			1 (0%)		1 (1%)
INFLAMMATION, SUPPURATIVE				1 (1%)	
INFLAMMATION, ACUTE		1 (1%)		2 (1%)	1 (1%)
INFLAMMATION, ACUTE FOCAL			1 (0%)		
INFLAMMATION, CHRONIC	4 (5%)	4 (3%)	5 (2%)	2 (1%)	
INFLAMMATION, CHRONIC FOCAL					1 (1%)
INFLAMMATION GRANULOMATOUS FOCAL			1 (0%)		
FIBROSIS	1 (1%)			1 (1%)	
HEPATITIS, TOXIC	12 (14%)	15 (12%)	33 (13%)	35 (20%)	16 (16%)
DEGENERATION, NOS		1 (1%)			
DEGENERATION, CYSTIC	4 (5%)	36 (29%)	44 (18%)	26 (15%)	21 (21%)
NECROSIS, NOS	4 (5%)	3 (2%)	3 (1%)	2 (1%)	
NECROSIS, FOCAL	1 (1%)		1 (0%)		
NECROSIS, COAGULATIVE			8 (3%)	4 (2%)	2 (2%)
METAMORPHOSIS, FATTY	13 (15%)	14 (11%)	21 (8%)	15 (9%)	11 (11%)
PIGMENTATION, NOS			6 (2%)	1 (1%)	2 (2%)
CYTOPLASMIC VACUOLIZATION			1 (0%)		
FOCAL CELLULAR CHANGE	20 (24%)	35 (28%)	65 (26%)	60 (34%)	25 (25%)
HYPERPLASIA, NOS		3 (2%)	7 (3%)	2 (1%)	2 (2%)
HYPERPLASIA, FOCAL	2 (2%)	6 (5%)	2 (1%)		3 (3%)
ANGIECTASIS	12 (14%)	11 (9%)	12 (5%)	10 (6%)	7 (7%)
#HEPATIC CAPSULE	(85)	(125)	(250)	(175)	(100)
INFLAMMATION, SUPPURATIVE	1 (1%)				
INFLAMMATION, ACUTE FIBRINOUS		1 (1%)			
INFLAMMATION, CHRONIC FOCAL	1 (1%)				
ADHESION, FIBROUS		1 (1%)			
#LIVER/PERIPORTAL	(85)	(125)	(250)	(175)	(100)
FIBROSIS	26 (31%)	13 (10%)	14 (6%)	6 (3%)	27 (27%)
#BILE DUCT	(85)	(125)	(250)	(175)	(100)
CYST, NOS	2 (2%)				
MULTILOCULAR CYST	1 (1%)				
CYSTIC DUCTS	1 (1%)	1 (1%)			
FIBROSIS	1 (1%)				
HYPERPLASIA, NOS	18 (21%)	7 (6%)	58 (23%)	11 (6%)	10 (10%)
HYPERPLASIA, CYSTIC				1 (1%)	
#PANCREAS	(85)	(124)	(249)	(174)	(99)
CYST, NOS		1 (1%)		1 (1%)	
EDEMA, INTERSTITIAL		1 (1%)			
INFLAMMATION, SUPPURATIVE		1 (1%)			
INFLAMMATION, CHRONIC				1 (1%)	
NECROSIS, FIBRINOID					1 (1%)
ATROPHY, NOS	18 (21%)	16 (13%)	50 (20%)	22 (13%)	7 (7%)
ATROPHY, FOCAL	2 (2%)				
#PANCREATIC DUCT	(85)	(124)	(249)	(174)	(99)
HYPERPLASIA, NOS				1 (1%)	
#PANCREATIC ACINUS	(85)	(124)	(249)	(174)	(99)
HYPERPLASIA, NOS			1 (0%)	1 (1%)	
HYPERPLASIA, FOCAL	1 (1%)		1 (0%)		
#ESOPHAGUS	(83)	(125)	(250)	(174)	(98)
INFLAMMATION, CHRONIC					1 (1%)
ABSCESS, CHRONIC					1 (1%)
HYPERKERATOSIS	1 (1%)	1 (1%)			2 (2%)
METAPLASIA, OSSEOUS					1 (1%)

HWBUI0001778

TABLE D1. SUMMARY OF THE INCIDENCE OF NONNEOPLASTIC LESIONS IN MALE RATS IN THE LIFETIME FEED STUDY OF INTERMEDIATE-RANGE (IR) CHRYSOTILE ASBESTOS (Continued)

	CONTROL (UNTR)	DMH	IR	IR + DMH	IR/PW
DIGESTIVE SYSTEM (Continued)					
#STOMACH	(85)	(124)	(250)	(175)	(100)
MINERALIZATION	1 (1%)	1 (1%)	5 (2%)		
CYST, NOS	2 (2%)	1 (1%)	1 (0%)		
EDEMA, NOS	5 (6%)				
HEMORRHAGE	1 (1%)		1 (0%)		
ULCER, NOS	8 (9%)	5 (4%)	2 (1%)	1 (1%)	
INFLAMMATION, SUPPURATIVE			1 (0%)		
INFLAMMATION, ACUTE	6 (7%)	6 (5%)	14 (6%)		4 (4%)
ULCER, ACUTE	5 (6%)	2 (2%)	14 (6%)	2 (1%)	7 (7%)
INFLAMMATION, ACUTE FOCAL	2 (2%)		2 (1%)		1 (1%)
INFLAMMATION, ACUTE/ CHRONIC	8 (9%)	3 (2%)	12 (5%)	7 (4%)	3 (3%)
INFLAMMATION, CHRONIC	2 (2%)	1 (1%)		3 (2%)	1 (1%)
ULCER, CHRONIC			7 (3%)	3 (2%)	
ULCER, PERFORATED		1 (1%)	4 (2%)	2 (1%)	2 (2%)
ADHESION, FIBROUS		1 (1%)			
DEGENERATION, NOS		1 (1%)	2 (1%)		
NECROSIS, NOS		1 (1%)			
NECROSIS, FOCAL			4 (2%)		
HYPERPLASIA, EPITHELIAL					1 (1%)
HYPERPLASIA, BASAL CELL	1 (1%)		1 (0%)		
HYPERKERATOSIS	7 (8%)	3 (2%)		3 (2%)	
ACANTHOSIS	10 (12%)	13 (10%)	18 (7%)	12 (7%)	14 (14%)
METAPLASIA, SQUAMOUS			1 (0%)		
#GASTRIC MUCOSA	(85)	(124)	(250)	(175)	(100)
HYPERPLASIA, NOS			1 (0%)		
#GASTRIC SUBMUCOSA	(85)	(124)	(250)	(175)	(100)
EDEMA, NOS	1 (1%)	3 (2%)	23 (9%)	8 (5%)	10 (10%)
HEMORRHAGE				1 (1%)	
#GASTRIC MUSCULARIS	(85)	(124)	(250)	(175)	(100)
DEGENERATION, NOS			1 (0%)		1 (1%)
#GASTRIC SEROSA	(85)	(124)	(250)	(175)	(100)
ULCER, NOS		1 (1%)			
INFLAMMATION, SUPPURATIVE	1 (1%)				
INFLAMMATION, ACUTE FIBRINOUS		1 (1%)			
ACANTHOSIS		1 (1%)			
#SMALL INTESTINE/MUCOSA	(85)	(125)	(250)	(175)	(100)
HYPERPLASIA, NOS		1 (1%)			
#SMALL INTESTINAL SUB	(85)	(125)	(250)	(175)	(100)
EDEMA, NOS			1 (0%)		
#DUODENUM	(85)	(125)	(250)	(175)	(100)
INFLAMMATION, ACUTE			1 (0%)		
METAPLASIA, OSSEOUS				1 (1%)	
#DUODENAL MUCOSA	(85)	(125)	(250)	(175)	(100)
HYPERPLASIA, NOS				1 (1%)	
#DUODENAL SEROSA	(85)	(125)	(250)	(175)	(100)
INFLAMMATION, ACUTE/ CHRONIC				1 (1%)	
#JEJUNUM	(85)	(125)	(250)	(175)	(100)
DIVERTICULOSIS			1 (0%)		
INFLAMMATION, ACUTE/ CHRONIC				1 (1%)	
#LARGE INTESTINE	(85)	(125)	(250)	(175)	(100)
INFLAMMATION, ACUTE/ CHRONIC	1 (1%)				
INFLAMMATION, CHRONIC	1 (1%)				
FIBROSIS	1 (1%)				
PARASITISM	3 (4%)				

HWBUI0001779

TABLE D1. SUMMARY OF THE INCIDENCE OF NONNEOPLASTIC LESIONS IN MALE RATS IN THE LIFETIME FEED STUDY OF INTERMEDIATE-RANGE (IR) CHRYSOTILE ASBESTOS (Continued)

	CONTROL (UNTR)	DMH	IR	IR + DMH	IR/PW
DIGESTIVE SYSTEM (Continued)					
#COLON	(85)	(125)	(250)	(175)	(100)
ULCER, NOS	1 (1%)				
INFLAMMATION, ACUTE	1 (1%)			1 (1%)	
INFLAMMATION, ACUTE/ CHRONIC					1 (1%)
INFLAMMATION, CHRONIC FOCAL			1 (0%)	1 (1%)	
PARASITISM		6 (5%)	11 (4%)	8 (5%)	
#COLONIC SUBMUCOSA	(85)	(125)	(250)	(175)	(100)
EDEMA, NOS			1 (0%)	1 (1%)	
#COLONIC MUSCULARIS	(85)	(125)	(250)	(175)	(100)
DEGENERATION, NOS			1 (0%)		
#COLONIC SEROSA	(85)	(125)	(250)	(175)	(100)
INFLAMMATION, FIBRINOUS			1 (0%)		
#CECUM	(85)	(125)	(250)	(175)	(100)
EDEMA, NOS		1 (1%)	5 (2%)		
HEMORRHAGE			1 (0%)		
INFLAMMATION, SUPPURATIVE			1 (0%)		
INFLAMMATION, ACUTE	2 (2%)				
ULCER, ACUTE				1 (1%)	
INFLAMMATION, ACUTE/ CHRONIC				1 (1%)	
ABSCESS, CHRONIC				1 (1%)	
PARASITISM	2 (2%)		2 (1%)	1 (1%)	1 (1%)
#ASCENDING COLON	(85)	(125)	(250)	(175)	(100)
INFLAMMATION, ACUTE/ CHRONIC	1 (1%)	1 (1%)		1 (1%)	
INFLAMMATION, CHRONIC		3 (2%)		1 (1%)	
ULCER, CHRONIC				1 (1%)	
INFLAMMATION, CHRONIC FOCAL		1 (1%)			
HYPERPLASIA, EPITHELIAL		2 (2%)		1 (1%)	
#TRANSVERSE COLON	(85)	(125)	(250)	(175)	(100)
PARASITISM		1 (1%)			
#DESCENDING COLON	(85)	(125)	(250)	(175)	(100)
PARASITISM		2 (2%)		3 (2%)	
URINARY SYSTEM					
#KIDNEY	(85)	(125)	(250)	(175)	(100)
MINERALIZATION	1 (1%)	1 (1%)	6 (2%)		1 (1%)
CAST, NOS	78 (92%)	97 (78%)	229 (92%)	125 (71%)	87 (87%)
HYDRONEPHROSIS			1 (0%)	1 (1%)	3 (3%)
CYST, NOS		2 (2%)	26 (10%)	8 (5%)	9 (9%)
CONGESTION, NOS	1 (1%)	1 (1%)	1 (0%)		1 (1%)
PYELONEPHRITIS, ACUTE					1 (1%)
INFLAMMATION, ACUTE	1 (1%)				
INFLAMMATION, ACUTE FOCAL	1 (1%)				
INFLAMMATION, CHRONIC	62 (73%)	77 (62%)	209 (84%)	117 (67%)	84 (84%)
GLOMERULOSCLEROSIS, NOS	1 (1%)				
PIGMENTATION, NOS	9 (11%)	19 (15%)	53 (21%)	7 (4%)	17 (17%)
HYPERPLASIA, TUBULAR CELL	1 (1%)				
HYPERPLASIA, EPITHELIAL	1 (1%)				
#RIGHT KIDNEY	(85)	(125)	(250)	(175)	(100)
CYST, NOS				1 (1%)	
INFLAMMATION, CHRONIC				1 (1%)	
#LEFT KIDNEY	(85)	(125)	(250)	(175)	(100)
CAST, NOS		1 (1%)		1 (1%)	
INFLAMMATION, CHRONIC		1 (1%)		1 (1%)	
#KIDNEY/CORTEX	(85)	(125)	(250)	(175)	(100)
CYST, NOS	3 (4%)				

HWBUI0001780

TABLE D1. SUMMARY OF THE INCIDENCE OF NONNEOPLASTIC LESIONS IN MALE RATS IN THE LIFETIME FEED STUDY OF INTERMEDIATE-RANGE (IR) CHRYSOTILE ASBESTOS (Continued)

	CONTROL (UNTR)	DMH	IR	IR + DMH	IR/PW
URINARY SYSTEM (Continued)					
#KIDNEY/TUBULE	(85)	(125)	(250)	(175)	(100)
PIGMENTATION, NOS	1 (1%)				
HYPERPLASIA, EPITHELIAL	1 (1%)				
#URINARY BLADDER	(84)	(124)	(249)	(174)	(98)
EDEMA, NOS			1 (0%)		
HEMORRHAGE	4 (5%)	1 (1%)	7 (3%)		3 (3%)
INFLAMMATION, SUPPURATIVE	1 (1%)	1 (1%)	2 (1%)		1 (1%)
INFLAMMATION, ACUTE	1 (1%)	1 (1%)			4 (4%)
INFLAMMATION, ACUTE SUPPURATIVE		1 (1%)			
INFLAMMATION, ACUTE/CHRONIC			1 (0%)		1 (1%)
INFLAMMATION, CHRONIC FOCAL			1 (0%)		
INFLAMMATION, GRANULOMATOUS			1 (0%)		
NECROSIS, FOCAL					1 (1%)
HYPERPLASIA, EPITHELIAL	2 (2%)		3 (1%)	1 (1%)	
HYPERPLASIA, PAPILLARY			3 (1%)		
POLYP, INFLAMMATORY			1 (0%)		
#U. BLADDER/SUBMUCOSA	(84)	(124)	(249)	(174)	(98)
HEMORRHAGE	1 (1%)				1 (1%)
*URETHRA	(88)	(125)	(250)	(175)	(100)
OBSTRUCTION, NOS			1 (0%)		
ENDOCRINE SYSTEM					
#PITUITARY	(85)	(124)	(246)	(175)	(100)
CYST, NOS	1 (1%)		3 (1%)	3 (2%)	
MULTILOCULAR CYST				2 (1%)	
HEMORRHAGE			1 (0%)		
FIBROSIS			1 (0%)		
FIBROSIS, FOCAL			1 (0%)		
NECROSIS, FOCAL			1 (0%)		
CHOLESTEROL DEPOSIT			1 (0%)		
PIGMENTATION, NOS			1 (0%)		
HEMOSIDEROSIS			1 (0%)		
HYPERTROPHY, FOCAL			4 (2%)	2 (1%)	
HYPERPLASIA, NOS	1 (1%)				
HYPERPLASIA, FOCAL			3 (1%)	1 (1%)	4 (4%)
ANGIECTASIS	8 (9%)	4 (3%)	6 (2%)	8 (5%)	4 (4%)
#ADRENAL	(85)	(125)	(250)	(175)	(100)
HEMORRHAGE	1 (1%)				
METAMORPHOSIS, FATTY		1 (1%)			
PIGMENTATION, NOS	2 (2%)				
ANGIECTASIS			2 (1%)		
#ADRENAL CORTEX	(85)	(125)	(250)	(175)	(100)
DEGENERATION, CYSTIC			2 (1%)	1 (1%)	
NECROSIS, NOS			1 (0%)		
METAMORPHOSIS, FATTY	22 (26%)	20 (16%)	27 (11%)	17 (10%)	16 (16%)
HYPERTROPHY, FOCAL		1 (1%)	2 (1%)	1 (1%)	1 (1%)
HYPERPLASIA, NOS				1 (1%)	
HYPERPLASIA, FOCAL	1 (1%)	3 (2%)	7 (3%)	1 (1%)	1 (1%)
#ADRENAL MEDULLA	(85)	(125)	(250)	(175)	(100)
MINERALIZATION			1 (0%)		
NECROSIS, NOS		1 (1%)			
HYPERPLASIA, NOS			1 (0%)		
HYPERPLASIA, FOCAL	8 (9%)	7 (6%)	29 (12%)	6 (3%)	8 (8%)

HWBUI0001781

TABLE D1. SUMMARY OF THE INCIDENCE OF NONNEOPLASTIC LESIONS IN MALE RATS IN THE *LIFETIME FEED STUDY OF INTERMEDIATE-RANGE (IR) CHRYSOTILE ASBESTOS* (Continued)

	CONTROL (UNTR)	DMH	IR	IR + DMH	IR/PW
ENDOCRINE SYSTEM (Continued)					
#THYROID	(84)	(124)	(250)	(175)	(99)
CYST, NOS			1 (0%)		
CYSTIC FOLLICLES	10 (12%)	7 (6%)	17 (7%)	6 (3%)	12 (12%)
FOLLICULAR CYST, NOS	1 (1%)		1 (0%)		
INFLAMMATION, ACUTE	1 (1%)				
INFLAMMATION, CHRONIC			1 (0%)		
HYPERPLASIA, NOS				1 (1%)	
HYPERPLASIA, C-CELL	9 (11%)	21 (17%)	51 (20%)	36 (21%)	13 (13%)
HYPERPLASIA, FOLLICULAR-CELL		1 (1%)	1 (0%)		
METAPLASIA, SQUAMOUS			1 (0%)		
#PARATHYROID	(78)	(119)	(243)	(166)	(93)
HYPERPLASIA, NOS	12 (15%)	13 (11%)	30 (12%)	2 (1%)	16 (17%)
#PANCREATIC ISLETS	(85)	(124)	(249)	(174)	(99)
HYPERPLASIA, NOS			1 (0%)	1 (1%)	
HYPERPLASIA, FOCAL	1 (1%)		2 (1%)		
REPRODUCTIVE SYSTEM					
*MAMMARY GLAND	(88)	(125)	(250)	(175)	(100)
DILATATION/DUCTS			2 (1%)		1 (1%)
GALACTOCELE	5 (6%)	5 (4%)	11 (4%)	6 (3%)	3 (3%)
CYSTIC DUCTS	1 (1%)	1 (1%)			
HEMORRHAGE		1 (1%)	1 (0%)		
INFLAMMATION, CHRONIC		1 (1%)	1 (0%)		
INFLAMMATION GRANULOMATOUS FOCAL					1 (1%)
HYPERPLASIA, NOS	13 (15%)	2 (2%)	7 (3%)	1 (1%)	
HYPERPLASIA, EPITHELIAL	1 (1%)				
*PREPUTIAL GLAND	(88)	(125)	(250)	(175)	(100)
DILATATION/DUCTS			3 (1%)		
CYST, NOS					1 (1%)
CYSTIC DUCTS	1 (1%)	3 (2%)			2 (2%)
INFLAMMATION, SUPPURATIVE			1 (0%)		
ABSCESS, NOS			2 (1%)		1 (1%)
INFLAMMATION, ACUTE/CHRONIC			1 (0%)		1 (1%)
ABSCESS, CHRONIC			1 (0%)		
HYPERPLASIA, EPITHELIAL			1 (0%)		
ANGIECTASIS			1 (0%)		
#PROSTATE	(85)	(125)	(249)	(174)	(99)
EDEMA, INTERSTITIAL		1 (1%)			
INFLAMMATION, SUPPURATIVE		1 (1%)	31 (12%)	1 (1%)	2 (2%)
INFLAMMATION, ACUTE	1 (1%)	2 (2%)	1 (0%)		
INFLAMMATION, ACUTE FOCAL			1 (0%)		
ABSCESS, NOS	2 (2%)	1 (1%)	2 (1%)		1 (1%)
INFLAMMATION, ACUTE/CHRONIC	10 (12%)	14 (11%)	52 (21%)	41 (24%)	41 (41%)
INFLAMMATION, CHRONIC	4 (5%)	4 (3%)	1 (0%)		1 (1%)
ABSCESS, CHRONIC					2 (2%)
INFLAMMATION, GRANULOMATOUS		1 (1%)			
INFLAMMATION GRANULOMATOUS FOCAL			1 (0%)		
HYPERPLASIA, NOS			2 (1%)	4 (2%)	
HYPERPLASIA, EPITHELIAL	1 (1%)		21 (8%)		
HYPERPLASIA, FOCAL	1 (1%)		8 (3%)	6 (3%)	3 (3%)

HWBUI0001782

TABLE D1. SUMMARY OF THE INCIDENCE OF NONNEOPLASTIC LESIONS IN MALE RATS IN THE LIFETIME FEED STUDY OF INTERMEDIATE-RANGE (IR) CHRYSOTILE ASBESTOS (Continued)

	CONTROL (UNTR)	DMH	IR	IR + DMH	IR/PW
REPRODUCTIVE SYSTEM (Continued)					
*SEMINAL VESICLE	(88)	(125)	(250)	(175)	(100)
INFLAMMATION, SUPPURATIVE		1 (1%)	3 (1%)		1 (1%)
INFLAMMATION, ACUTE	1 (1%)				1 (1%)
INFLAMMATION, ACUTE/ CHRONIC	2 (2%)				1 (1%)
HYPERPLASIA, NOS		1 (1%)			
HYPERPLASIA, EPITHELIAL	5 (6%)		1 (0%)		1 (1%)
HYPERPLASIA, FOCAL		1 (1%)	2 (1%)		
*COAGULATING GLAND	(88)	(125)	(250)	(175)	(100)
INFLAMMATION, ACUTE/ CHRONIC	1 (1%)		1 (0%)		
INFLAMMATION, CHRONIC	1 (1%)				
HYPERPLASIA, EPITHELIAL	2 (2%)				
#TESTIS	(84)	(125)	(250)	(175)	(100)
MINERALIZATION	4 (5%)		13 (5%)	3 (2%)	
STEATITIS				1 (1%)	
GRANULOMA, SPERMATIC		1 (1%)			1 (1%)
DEGENERATION, NOS	9 (11%)	11 (9%)	15 (6%)	3 (2%)	5 (5%)
HYPERPLASIA, INTERSTITIAL CELL		8 (6%)	6 (2%)	12 (7%)	4 (4%)
#TESTIS/TUBULE	(84)	(125)	(250)	(175)	(100)
DEGENERATION, NOS	2 (2%)		3 (1%)		
*EPIDIDYMIS	(88)	(125)	(250)	(175)	(100)
STEATITIS	4 (5%)	2 (2%)	6 (2%)	5 (3%)	3 (3%)
INFLAMMATION, ACUTE/ CHRONIC					1 (1%)
INFLAMMATION, CHRONIC					1 (1%)
GRANULOMA, SPERMATIC		1 (1%)			
FIBROSIS	1 (1%)				
NECROSIS, FAT	3 (3%)		8 (3%)	3 (2%)	2 (2%)
NERVOUS SYSTEM					
#BRAIN/MENINGES	(85)	(125)	(250)	(175)	(100)
INFLAMMATION, SUPPURATIVE				1 (1%)	
#CEREBRAL VENTRICLE	(85)	(125)	(250)	(175)	(100)
DILATATION, NOS			2 (1%)		1 (1%)
#BRAIN	(85)	(125)	(250)	(175)	(100)
HEMORRHAGE			1 (0%)	1 (1%)	
INFLAMMATION, SUPPURATIVE				1 (1%)	
GLIOSIS			1 (0%)		1 (1%)
#MEDULLA OBLONGATA	(85)	(125)	(250)	(175)	(100)
ABSCESS, NOS				1 (1%)	
SPECIAL SENSE ORGANS					
*EYE	(88)	(125)	(250)	(175)	(100)
HEMORRHAGE	2 (2%)	2 (2%)	4 (2%)	1 (1%)	1 (1%)
INFLAMMATION, SUPPURATIVE			5 (2%)	1 (1%)	
INFLAMMATION, ACUTE					1 (1%)
INFLAMMATION, ACUTE SUPPURATIVE	1 (1%)				
INFLAMMATION, CHRONIC		1 (1%)	2 (1%)		3 (3%)
CATARACT	19 (22%)	27 (22%)	71 (28%)	20 (11%)	24 (24%)
*EYE/CORNEA	(88)	(125)	(250)	(175)	(100)
INFLAMMATION, ACUTE					2 (2%)
INFLAMMATION, ACUTE SUPPURATIVE	1 (1%)				

HWBUI0001783

TABLE D1. SUMMARY OF THE INCIDENCE OF NONNEOPLASTIC LESIONS IN MALE RATS IN THE LIFETIME FEED STUDY OF INTERMEDIATE-RANGE (IR) CHRYSOTILE ASBESTOS (Continued)

	CONTROL (UNTR)	DMH	IR	IR + DMH	IR/PW
SPECIAL SENSE ORGANS (Continued)					
*EYE/RETINA	(88)	(125)	(250)	(175)	(100)
DEGENERATION, NOS	19 (22%)	28 (22%)	68 (27%)	21 (12%)	24 (24%)
*HARDERIAN GLAND	(88)	(125)	(250)	(175)	(100)
INFLAMMATION GRANULOMATOUS FOCAL			1 (0%)		
*EAR	(88)	(125)	(250)	(175)	(100)
INFLAMMATION, ACUTE/CHRONIC					1 (1%)
HYPERPLASIA, EPITHELIAL		1 (1%)	1 (0%)		
*ZYMBAL GLAND	(88)	(125)	(250)	(175)	(100)
DILATATION/DUCTS			1 (0%)	3 (2%)	
CYSTIC DUCTS	2 (2%)			1 (1%)	
INFLAMMATION, ACUTE				1 (1%)	
ABSCESS, NOS		1 (1%)	2 (1%)	1 (1%)	
INFLAMMATION, ACUTE/CHRONIC		1 (1%)			
ABSCESS, CHRONIC		1 (1%)			
INFLAMMATION, GRANULOMATOUS			1 (0%)		
HYPERPLASIA, EPITHELIAL			1 (0%)	1 (1%)	
HYPERKERATOSIS		1 (1%)	1 (0%)		
MUSCULOSKELETAL SYSTEM					
*SKULL	(88)	(125)	(250)	(175)	(100)
HYPEROSTOSIS		1 (1%)	5 (2%)	1 (1%)	2 (2%)
*MANDIBLE	(88)	(125)	(250)	(175)	(100)
ABSCESS, CHRONIC			1 (0%)		
PERIODONTAL CYST				1 (1%)	
*STERNUM	(88)	(125)	(250)	(175)	(100)
HYPEROSTOSIS			1 (0%)		
HYPERPLASIA, NOS					1 (1%)
BODY CAVITIES					
*THORACIC CAVITY	(88)	(125)	(250)	(175)	(100)
ABSCESS, CHRONIC					1 (1%)
*MEDIASTINUM	(88)	(125)	(250)	(175)	(100)
INFLAMMATION, SUPPURATIVE	2 (2%)	1 (1%)			
INFLAMMATION, ACUTE	1 (1%)				
*ABDOMINAL CAVITY	(88)	(125)	(250)	(175)	(100)
STEATITIS			2 (1%)		1 (1%)
NECROSIS, FAT			2 (1%)		1 (1%)
*ABDOMINAL WALL	(88)	(125)	(250)	(175)	(100)
INFLAMMATION, CHRONIC			1 (0%)		
*PLEURA	(88)	(125)	(250)	(175)	(100)
INFLAMMATION, SUPPURATIVE	2 (2%)				
FIBROSIS					1 (1%)
*EPICARDIUM	(88)	(125)	(250)	(175)	(100)
INFLAMMATION, FIBRINOUS		1 (1%)			
INFLAMMATION, ACUTE					2 (2%)
*MESENTERY	(88)	(125)	(250)	(175)	(100)
HEMORRHAGE					1 (1%)
INFLAMMATION, CHRONIC		2 (2%)			1 (1%)
INFLAMMATION, CHRONIC FOCAL					1 (1%)
NECROSIS, FAT				1 (1%)	1 (1%)

HWBUI0001784

TABLE D1. SUMMARY OF THE INCIDENCE OF NONNEOPLASTIC LESIONS IN MALE RATS IN THE LIFETIME FEED STUDY OF INTERMEDIATE-RANGE (IR) CHRYSOTILE ASBESTOS (Continued)

	CONTROL (UNTR)	DMH	IR	IR + DMH	IR/PW
ALL OTHER SYSTEMS					
*MULTIPLE ORGANS	(88)	(125)	(250)	(175)	(100)
MINERALIZATION			2 (1%)	1 (1%)	3 (3%)
CONGESTION, NOS			2 (1%)	1 (1%)	
HEMORRHAGE			1 (0%)		
INFLAMMATION, SUPPURATIVE		1 (1%)	3 (1%)		1 (1%)
INFLAMMATION, ACUTE/ CHRONIC			1 (0%)		
INFLAMMATION, CHRONIC	1 (1%)	4 (3%)	1 (0%)		
FIBROSIS	1 (1%)				
PIGMENTATION, NOS	1 (1%)		1 (0%)		1 (1%)
HYPERPLASIA, NOS	1 (1%)				
DIAPHRAGM					
HERNIA, NOS		2		5	4
INFLAMMATION, CHRONIC	1				1
ADHESION, NOS					1
FOOT					
INFLAMMATION, CHRONIC					1
ADIPOSE TISSUE					
CONGESTION, NOS	1				
HEMORRHAGE		1	1		
INFLAMMATION, CHRONIC	1		1	2	
INFLAMMATION, GRANULO-MATOUS			1		
FIBROSIS	1				
SPECIAL MORPHOLOGY SUMMARY					
NECROPSY PERF/NO HISTO PERFORMED	3				

NUMBER OF ANIMALS WITH TISSUE EXAMINED MICROSCOPICALLY
* NUMBER OF ANIMALS NECROPSIED

HWBUI0001785

TABLE D2. SUMMARY OF THE INCIDENCE OF NONNEOPLASTIC LESIONS IN FEMALE RATS IN THE LIFETIME FEED STUDY OF INTERMEDIATE-RANGE (IR) CHRYSOTILE ASBESTOS

	CONTROL (UNTR)	DMH	IR	IR + DMH	IR/PW
ANIMALS INITIALLY IN STUDY	88	125	250	175	100
ANIMALS NECROPSIED	88	125	250	175	100
ANIMALS EXAMINED HISTOPATHOLOGICALLY	87	125	250	175	100
INTEGUMENTARY SYSTEM					
*SKIN	(88)	(125)	(250)	(175)	(100)
CYST, NOS				1 (1%)	
INFLAMMATION, CHRONIC			1 (0%)		
HYPERKERATOSIS					2 (2%)
*SUBCUT TISSUE	(88)	(125)	(250)	(175)	(100)
ABSCESS, CHRONIC			1 (0%)	1 (1%)	
RESPIRATORY SYSTEM					
#LUNG/BRONCHUS	(87)	(125)	(250)	(175)	(99)
BRONCHIECTASIS					1 (1%)
EDEMA, NOS			1 (0%)		
#LUNG	(87)	(125)	(250)	(175)	(99)
MINERALIZATION					1 (1%)
BRONCHIECTASIS					1 (1%)
CYST, NOS					1 (1%)
CONGESTION, NOS	4 (5%)	6 (5%)	3 (1%)	1 (1%)	
HEMORRHAGE	1 (1%)				1 (1%)
INFLAMMATION, INTERSTITIAL	3 (3%)	3 (2%)	5 (2%)	2 (1%)	1 (1%)
PNEUMONIA, ASPIRATION					3 (3%)
INFLAMMATION, SUPPURATIVE					4 (4%)
INFLAMMATION, ACUTE FOCAL	1 (1%)				
ABSCESS, NOS					1 (1%)
INFLAMMATION, ACUTE/CHRONIC	1 (1%)	5 (4%)			
INFLAMMATION, CHRONIC	16 (18%)	33 (26%)	29 (12%)	17 (10%)	14 (14%)
INFLAMMATION, GRANULOMATOUS				1 (1%)	1 (1%)
FIBROSIS				1 (1%)	
HYPERPLASIA, EPITHELIAL		1 (1%)			
HYPERPLASIA, ALVEOLAR EPITHELIUM	1 (1%)	2 (2%)	6 (2%)	3 (2%)	2 (2%)
#LUNG/ALVEOLI	(87)	(125)	(250)	(175)	(99)
HISTIOCYTOSIS		1 (1%)	3 (1%)	1 (1%)	1 (1%)
HEMATOPOIETIC SYSTEM					
*MULTIPLE ORGANS	(88)	(125)	(250)	(175)	(100)
HYPERPLASIA, PLASMA CELL			1 (0%)		
HYPERPLASIA, LYMPHOID			1 (0%)		
#BONE MARROW	(87)	(125)	(248)	(174)	(98)
ATROPHY, NOS				1 (1%)	
#SPLEEN	(87)	(125)	(249)	(175)	(99)
HEMORRHAGE		1 (1%)			
FIBROSIS	2 (2%)	6 (5%)	4 (2%)	4 (2%)	2 (2%)
FIBROSIS, FOCAL	1 (1%)	2 (2%)		1 (1%)	
INFARCT, NOS		3 (2%)	3 (1%)		2 (2%)
INFARCT, ACUTE			1 (0%)		
PIGMENTATION, NOS			1 (0%)		
HEMOSIDEROSIS	34 (39%)	19 (15%)	121 (49%)	17 (10%)	35 (35%)
HEMATOPOIESIS	4 (5%)	5 (4%)	24 (10%)	20 (11%)	13 (13%)
MYELOPOIESIS		1 (1%)			
#SPLENIC CAPSULE	(87)	(125)	(249)	(175)	(99)
INFLAMMATION, CHRONIC			1 (0%)		
FIBROSIS					2 (2%)

HWBUI0001786

TABLE D2. SUMMARY OF THE INCIDENCE OF NONNEOPLASTIC LESIONS IN FEMALE RATS IN THE LIFETIME FEED STUDY OF INTERMEDIATE-RANGE (IR) CHRYSOTILE ASBESTOS (Continued)

	CONTROL (UNTR)	DMH	IR	IR + DMH	IR/PW
HEMATOPOIETIC SYSTEM (Continued)					
#MANDIBULAR L. NODE	(87)	(125)	(250)	(175)	(99)
CONGESTION, NOS	1 (1%)	1 (1%)	1 (0%)	2 (1%)	1 (1%)
HEMORRHAGE		3 (2%)	2 (1%)	5 (3%)	1 (1%)
INFLAMMATION, SUPPURATIVE			2 (1%)		
INFLAMMATION, CHRONIC					1 (1%)
PIGMENTATION, NOS	3 (3%)	1 (1%)	7 (3%)	2 (1%)	2 (2%)
HYPERPLASIA, PLASMA CELL	16 (18%)	20 (16%)	73 (29%)	14 (8%)	27 (27%)
HYPERPLASIA, RETICULUM CELL			2 (1%)		
HYPERPLASIA, LYMPHOID		1 (1%)	3 (1%)		1 (1%)
#CERVICAL LYMPH NODE	(87)	(125)	(250)	(175)	(99)
CONGESTION, NOS			1 (0%)		
HEMORRHAGE		1 (1%)	1 (0%)		
INFLAMMATION, SUPPURATIVE			1 (0%)		
PIGMENTATION, NOS			1 (0%)	1 (1%)	1 (1%)
HYPERPLASIA, PLASMA CELL	1 (1%)	1 (1%)	5 (2%)	1 (1%)	
#THORACIC LYMPH NODE	(87)	(125)	(250)	(175)	(99)
CONGESTION, NOS			1 (0%)		
#MEDIASTINAL L. NODE	(87)	(125)	(250)	(175)	(99)
MINERALIZATION				1 (1%)	
CONGESTION, NOS		2 (2%)	2 (1%)	4 (2%)	4 (4%)
HEMORRHAGE	10 (11%)	5 (4%)	17 (7%)	14 (8%)	18 (18%)
INFLAMMATION, SUPPURATIVE				1 (1%)	
PIGMENTATION, NOS	22 (25%)	27 (22%)	91 (36%)	47 (27%)	39 (39%)
HYPERPLASIA, PLASMA CELL	2 (2%)	3 (2%)	1 (0%)		4 (4%)
HYPERPLASIA, RETICULUM CELL			1 (0%)	3 (2%)	
HYPERPLASIA, LYMPHOID	1 (1%)		1 (0%)		2 (2%)
#CELIAC LYMPH NODE	(87)	(125)	(250)	(175)	(99)
INFLAMMATION, SUPPURATIVE				1 (1%)	
FIBROSIS			1 (0%)		
PIGMENTATION, NOS			1 (0%)		
#PANCREATIC LYMPH NODE	(87)	(125)	(250)	(175)	(99)
HEMORRHAGE			2 (1%)	1 (1%)	
PIGMENTATION, NOS		1 (1%)	19 (8%)	10 (6%)	5 (5%)
HYPERPLASIA, PLASMA CELL		1 (1%)			1 (1%)
HYPERPLASIA, RETICULUM CELL			4 (2%)		1 (1%)
HYPERPLASIA, LYMPHOID					1 (1%)
#MESENTERIC LYMPH NODE	(87)	(125)	(250)	(175)	(99)
HEMORRHAGE			4 (2%)	1 (1%)	3 (3%)
INFLAMMATION, SUPPURATIVE			1 (0%)		
NECROSIS, NOS					1 (1%)
PIGMENTATION, NOS	10 (11%)	1 (1%)	40 (16%)	5 (3%)	4 (4%)
HYPERPLASIA, PLASMA CELL		1 (1%)	2 (1%)		
HYPERPLASIA, RETICULUM CELL	1 (1%)		6 (2%)	1 (1%)	2 (2%)
HYPERPLASIA, LYMPHOID					1 (1%)
#ILEOCOLIC LYMPH NODE	(87)	(125)	(250)	(175)	(99)
HEMORRHAGE					1 (1%)
INFLAMMATION, SUPPURATIVE		1 (1%)	1 (0%)		
HYPERPLASIA, LYMPHOID			1 (0%)		
#RENAL LYMPH NODE	(87)	(125)	(250)	(175)	(99)
PIGMENTATION, NOS			1 (0%)		1 (1%)
HYPERPLASIA, RETICULUM CELL		1 (1%)	1 (0%)		
#ILIAC LYMPH NODE	(87)	(125)	(250)	(175)	(99)
HYPERPLASIA, PLASMA CELL		1 (1%)			
#AXILLARY LYMPH NODE	(87)	(125)	(250)	(175)	(99)
HYPERPLASIA, PLASMA CELL			1 (0%)		
*STERNUM	(88)	(125)	(250)	(175)	(100)
MYELOFIBROSIS		1 (1%)	4 (2%)	1 (1%)	
HYPERPLASIA, HEMATOPOIETIC		1 (1%)			
#LUNG	(87)	(125)	(250)	(175)	(99)
LEUKOCYTOSIS, NOS		2 (2%)			
LEUKOCYTOSIS, NEUTROPHILIC					1 (1%)

HWBUI0001787

TABLE D2. SUMMARY OF THE INCIDENCE OF NONNEOPLASTIC LESIONS IN FEMALE RATS IN THE LIFETIME FEED STUDY OF INTERMEDIATE-RANGE (IR) CHRYSOTILE ASBESTOS (Continued)

	CONTROL (UNTR)	DMH	IR	IR + DMH	IR/PW
HEMATOPOIETIC SYSTEM (Continued)					
#ALVEOLAR WALL	(87)	(125)	(250)	(175)	(99)
LEUKOCYTOSIS, NOS			2 (1%)		
#LIVER	(87)	(125)	(250)	(175)	(99)
LEUKOCYTOSIS, NOS			1 (0%)		
LEUKOCYTOSIS, NEUTROPHILIC					1 (1%)
HEMATOPOIESIS	1 (1%)		2 (1%)	1 (1%)	1 (1%)
#HEPATIC SINUSOID	(87)	(125)	(250)	(175)	(99)
LEUKOCYTOSIS, NOS			3 (1%)	1 (1%)	1 (1%)
#PEYERS PATCH	(87)	(125)	(249)	(175)	(99)
HYPERPLASIA, LYMPHOID			1 (0%)		1 (1%)
#ADRENAL	(87)	(124)	(249)	(175)	(99)
HEMATOPOIESIS					1 (1%)
#THYMUS	(70)	(106)	(199)	(146)	(95)
CYST, NOS			1 (1%)		
CONGESTION, NOS					1 (1%)
EDEMA, NOS				1 (1%)	
NECROSIS, NOS			1 (1%)		
CIRCULATORY SYSTEM					
#SPLEEN	(87)	(125)	(249)	(175)	(99)
THROMBUS, FIBRIN				1 (1%)	
#MANDIBULAR LYMPH NODE	(87)	(125)	(250)	(175)	(99)
LYMPHANGIECTASIS	2 (2%)	3 (2%)	5 (2%)	5 (3%)	3 (3%)
#CERVICAL LYMPH NODE	(87)	(125)	(250)	(175)	(99)
LYMPHANGIECTASIS		1 (1%)	1 (0%)		
#MEDIASTINAL LYMPH NODE	(87)	(125)	(250)	(175)	(99)
LYMPHANGIECTASIS	1 (1%)	1 (1%)		1 (1%)	
#CELIAC LYMPH NODE	(87)	(125)	(250)	(175)	(99)
LYMPHANGIECTASIS			2 (1%)		
#MESENTERIC LYMPH NODE	(87)	(125)	(250)	(175)	(99)
LYMPHANGIECTASIS	1 (1%)		4 (2%)	1 (1%)	
#ILEOCOLIC LYMPH NODE	(87)	(125)	(250)	(175)	(99)
LYMPHANGIECTASIS	1 (1%)	1 (1%)	4 (2%)	4 (2%)	5 (5%)
#LUNG	(87)	(125)	(250)	(175)	(99)
THROMBUS, FIBRIN			1 (0%)		
#HEART	(87)	(125)	(250)	(175)	(99)
INFLAMMATION, CHRONIC	1 (1%)		1 (0%)		
#HEART/ATRIUM	(87)	(125)	(250)	(175)	(99)
THROMBUS, ORGANIZED					1 (1%)
#HEART/VENTRICLE	(87)	(125)	(250)	(175)	(99)
FIBROSIS					1 (1%)
#MYOCARDIUM	(87)	(125)	(250)	(175)	(99)
INFLAMMATION, CHRONIC	3 (3%)	1 (1%)	10 (4%)	2 (1%)	2 (2%)
FIBROSIS	34 (39%)	15 (12%)	84 (34%)	9 (5%)	32 (32%)
*CORONARY ARTERY	(88)	(125)	(250)	(175)	(100)
MINERALIZATION					2 (2%)
#LIVER	(87)	(125)	(250)	(175)	(99)
THROMBUS, ORGANIZED			1 (0%)		1 (1%)
THROMBUS, FIBRIN					1 (1%)
PERIARTERITIS		1 (1%)			
#KIDNEY	(87)	(125)	(250)	(175)	(99)
THROMBUS, FIBRIN			1 (0%)		
#UTERUS	(87)	(125)	(249)	(175)	(99)
THROMBUS, FIBRIN			1 (0%)		
#ADRENAL	(87)	(124)	(249)	(175)	(99)
THROMBUS, ORGANIZED			1 (0%)		

HWBUI0001788

TABLE D2. SUMMARY OF THE INCIDENCE OF NONNEOPLASTIC LESIONS IN FEMALE RATS IN THE LIFETIME FEED STUDY OF INTERMEDIATE-RANGE (IR) CHRYSOTILE ASBESTOS (Continued)

	CONTROL (UNTR)	DMH	IR	IR + DMH	IR/PW
DIGESTIVE SYSTEM					
*MOUTH	(88)	(125)	(250)	(175)	(100)
ABSCESS, NOS		1 (1%)	1 (0%)		
*MOUTH/ORAL CAVITY	(88)	(125)	(250)	(175)	(100)
INFLAMMATION, SUPPURATIVE			1 (0%)		
#SALIVARY GLAND	(87)	(122)	(248)	(173)	(99)
MINERALIZATION				1 (1%)	
INFLAMMATION, SUPPURATIVE			1 (0%)		
INFLAMMATION, ACUTE				1 (1%)	
INFLAMMATION, CHRONIC			2 (1%)		2 (2%)
ABSCESS, CHRONIC			1 (0%)	1 (1%)	
HYPERPLASIA, EPITHELIAL					1 (1%)
#LIVER	(87)	(125)	(250)	(175)	(99)
HERNIA, NOS					1 (1%)
CYST, NOS	1 (1%)	1 (1%)	1 (0%)	14 (8%)	
HEMORRHAGE	1 (1%)			1 (1%)	
INFLAMMATION, SUPPURATIVE			2 (1%)		
INFLAMMATION, ACUTE	1 (1%)		1 (0%)		2 (2%)
INFLAMMATION, ACUTE/CHRONIC	1 (1%)		1 (0%)		
INFLAMMATION, CHRONIC	3 (3%)	4 (3%)	1 (0%)	10 (6%)	4 (4%)
INFLAMMATION, GRANULOMATOUS	5 (6%)	14 (11%)	31 (12%)	8 (5%)	12 (12%)
FIBROSIS, FOCAL		1 (1%)			
HEPATITIS, TOXIC	15 (17%)	47 (38%)	38 (15%)	58 (33%)	15 (15%)
DEGENERATION, CYSTIC		2 (2%)		5 (3%)	2 (2%)
NECROSIS, NOS			1 (0%)	1 (1%)	
NECROSIS, COAGULATIVE	2 (2%)	8 (6%)	14 (6%)	5 (3%)	5 (5%)
METAMORPHOSIS, FATTY	18 (21%)	13 (10%)	48 (19%)	15 (9%)	22 (22%)
PIGMENTATION, NOS		1 (1%)	12 (5%)	5 (3%)	3 (3%)
FOCAL CELLULAR CHANGE	42 (48%)	57 (46%)	106 (42%)	79 (45%)	59 (60%)
HEPATOCYTOMEGALY				1 (1%)	
HYPERPLASIA, NOS		7 (6%)	6 (2%)	14 (8%)	
HYPERPLASIA, FOCAL		11 (9%)			
ANGIECTASIS	4 (5%)	4 (3%)	6 (2%)	12 (7%)	5 (5%)
#HEPATIC CAPSULE	(87)	(125)	(250)	(175)	(99)
INFLAMMATION, SUPPURATIVE			1 (0%)		
#LIVER/PERIPORTAL	(87)	(125)	(250)	(175)	(99)
FIBROSIS			4 (2%)	1 (1%)	2 (2%)
#BILE DUCT	(87)	(125)	(250)	(175)	(99)
CYST, NOS				1 (1%)	
HYPERPLASIA, NOS			19 (8%)	12 (7%)	4 (4%)
#PANCREAS	(87)	(124)	(249)	(175)	(99)
INFLAMMATION, CHRONIC				2 (1%)	
ATROPHY, NOS	6 (7%)		15 (6%)	3 (2%)	6 (6%)
#ESOPHAGUS	(86)	(121)	(250)	(173)	(99)
HYPERKERATOSIS					2 (2%)
#STOMACH	(87)	(124)	(250)	(174)	(99)
CYST, NOS	1 (1%)	1 (1%)	1 (0%)		1 (1%)
ULCER, NOS			1 (0%)		
INFLAMMATION, SUPPURATIVE			4 (2%)		
INFLAMMATION, ACUTE		1 (1%)	4 (2%)	2 (1%)	1 (1%)
ULCER, ACUTE	4 (5%)	3 (2%)	12 (5%)	7 (4%)	4 (4%)
INFLAMMATION, ACUTE/CHRONIC	5 (6%)	2 (2%)	23 (9%)	6 (3%)	9 (9%)
INFLAMMATION, CHRONIC	4 (5%)		1 (0%)	4 (2%)	
ULCER, CHRONIC		1 (1%)	6 (2%)	3 (2%)	2 (2%)
INFLAMMATION, CHRONIC FOCAL			1 (0%)		
ULCER, PERFORATED	3 (3%)		7 (3%)		1 (1%)
NECROSIS, NOS				1 (1%)	
NECROSIS, FOCAL			2 (1%)	1 (1%)	1 (1%)
HYPERPLASIA, EPITHELIAL			1 (0%)		
HYPERPLASIA, ADENOMATOUS			1 (0%)		
HYPERKERATOSIS	2 (2%)	3 (2%)	4 (2%)	2 (1%)	5 (5%)
ACANTHOSIS	7 (8%)	2 (2%)	20 (8%)	7 (4%)	10 (10%)

HWBUI0001789

TABLE D2. SUMMARY OF THE INCIDENCE OF NONNEOPLASTIC LESIONS IN FEMALE RATS IN THE LIFETIME FEED STUDY OF INTERMEDIATE-RANGE (IR) CHRYSOTILE ASBESTOS (Continued)

	CONTROL (UNTR)	DMH	IR	IR + DMH	IR/PW
DIGESTIVE SYSTEM (Continued)					
#GASTRIC MUCOSA	(87)	(124)	(250)	(174)	(99)
DILATATION, NOS			1 (0%)		
NECROSIS, NOS			1 (0%)		
#GASTRIC SUBMUCOSA	(87)	(124)	(250)	(174)	(99)
EDEMA, NOS	2 (2%)	2 (2%)	13 (5%)	5 (3%)	2 (2%)
EDEMA, INTERSTITIAL			1 (0%)		
#SMALL INTESTINE	(87)	(125)	(249)	(175)	(99)
INFLAMMATION, ACUTE			1 (0%)		
ULCER, ACUTE			1 (0%)		
#SMALL INTESTINAL SUBMUCOSA	(87)	(125)	(249)	(175)	(99)
EDEMA, NOS			1 (0%)		
#PEYER'S PATCH	(87)	(125)	(249)	(175)	(99)
ULCER, ACUTE					1 (1%)
INFLAMMATION, ACUTE/CHRONIC					1 (1%)
HYPERPLASIA, NOS					1 (1%)
HYPERPLASIA, EPITHELIAL					1 (1%)
#COLON	(87)	(125)	(250)	(175)	(99)
INFLAMMATION, ACUTE/CHRONIC				1 (1%)	
INFLAMMATION, CHRONIC		1 (1%)		1 (1%)	
ULCER, CHRONIC				1 (1%)	
PARASITISM		9 (7%)	6 (2%)	5 (3%)	1 (1%)
#COLONIC SUBMUCOSA	(87)	(125)	(250)	(175)	(99)
FIBROSIS, FOCAL			1 (0%)		
#COLONIC SEROSA	(87)	(125)	(250)	(175)	(99)
INFLAMMATION, CHRONIC			1 (0%)		
#CECUM	(87)	(125)	(250)	(175)	(99)
ULCER, NOS		1 (1%)			1 (1%)
INFLAMMATION, SUPPURATIVE			1 (0%)		
INFLAMMATION, ACUTE		1 (1%)			
ULCER, ACUTE			2 (1%)		
INFLAMMATION, ACUTE FOCAL			1 (0%)		
INFLAMMATION, ACUTE/CHRONIC		1 (1%)	1 (0%)		1 (1%)
INFLAMMATION, CHRONIC					2 (2%)
PARASITISM			1 (0%)	1 (1%)	
#ASCENDING COLON	(87)	(125)	(250)	(175)	(99)
PARASITISM				1 (1%)	
#TRANSVERSE COLON	(87)	(125)	(250)	(175)	(99)
DIVERTICULUM				1 (1%)	
INFLAMMATION, CHRONIC				1 (1%)	
PARASITISM		1 (1%)			
ANGIECTASIS			1 (0%)		
#DESCENDING COLON	(87)	(125)	(250)	(175)	(99)
DIVERTICULUM			1 (0%)		
PARASITISM		2 (2%)		1 (1%)	
*ANUS	(88)	(125)	(250)	(175)	(100)
EPIDERMAL INCLUSION CYST	1 (1%)				
URINARY SYSTEM					
#KIDNEY	(87)	(125)	(250)	(175)	(99)
MINERALIZATION	61 (70%)	97 (78%)	194 (78%)	114 (65%)	77 (78%)
CAST, NOS	57 (66%)	51 (41%)	161 (64%)	83 (47%)	65 (66%)
HYDRONEPHROSIS		2 (2%)			2 (2%)
CYST, NOS	1 (1%)	1 (1%)	4 (2%)	1 (1%)	2 (2%)
INFLAMMATION, SUPPURATIVE		1 (1%)			
PYELONEPHRITIS, ACUTE				1 (1%)	
INFLAMMATION, CHRONIC	52 (60%)	25 (20%)	111 (44%)	17 (10%)	36 (36%)
INFLAMMATION, CHRONIC FOCAL				2 (1%)	
NEPHROSIS, NOS				1 (1%)	

HWBUI0001790

TABLE D2. SUMMARY OF THE INCIDENCE OF NONNEOPLASTIC LESIONS IN FEMALE RATS IN THE LIFETIME FEED STUDY OF INTERMEDIATE-RANGE (IR) CHRYSOTILE ASBESTOS (Continued)

	CONTROL (UNTR)	DMH	IR	IR + DMH	IR/PW
URINARY SYSTEM					
#KIDNEY (Continued)	(87)	(125)	(250)	(175)	(99)
INFARCT, NOS			1 (0%)		
INFARCT, ACUTE	1 (1%)				
PIGMENTATION, NOS	30 (34%)	13 (10%)	104 (42%)	18 (10%)	11 (11%)
CYTOMEGALY				1 (1%)	
HYPERPLASIA, TUBULAR CELL				2 (1%)	
ANGIECTASIS			1 (0%)		
#URINARY BLADDER	(85)	(125)	(247)	(175)	(98)
HEMORRHAGE			1 (0%)		1 (1%)
INFLAMMATION, ACUTE/CHRONIC				1 (1%)	
INFLAMMATION, GRANULOMATOUS			4 (2%)	1 (1%)	
CRYSTALS, NOS			1 (0%)		
HYPERPLASIA, EPITHELIAL			5 (2%)	1 (1%)	1 (1%)
ENDOCRINE SYSTEM					
#PITUITARY	(87)	(124)	(249)	(173)	(100)
CYST, NOS		6 (5%)	5 (2%)	6 (3%)	3 (3%)
CONGESTION, NOS				1 (1%)	
EDEMA, NOS		1 (1%)			
INFLAMMATION, ACUTE/CHRONIC			1 (0%)		
INFLAMMATION, CHRONIC			1 (0%)		
PIGMENTATION, NOS		1 (1%)	8 (3%)	3 (2%)	
HYPERTROPHY, NOS					1 (1%)
HYPERTROPHY, FOCAL	3 (3%)	2 (2%)	5 (2%)	1 (1%)	2 (2%)
HYPERPLASIA, FOCAL	1 (1%)	2 (2%)	9 (4%)	3 (2%)	2 (2%)
ANGIECTASIS	7 (8%)	9 (7%)	29 (12%)	22 (13%)	8 (8%)
#ADRENAL	(87)	(124)	(249)	(175)	(99)
CONGESTION, NOS	1 (1%)		2 (1%)	3 (2%)	1 (1%)
HEMORRHAGE					1 (1%)
DEGENERATION, NOS	1 (1%)				
DEGENERATION, CYSTIC			1 (0%)		3 (3%)
DEGENERATION, LIPOID		1 (1%)			
PIGMENTATION, NOS				2 (1%)	
ATROPHY, NOS			1 (0%)	1 (1%)	
HYPERTROPHY, FOCAL				1 (1%)	
ANGIECTASIS			5 (2%)		3 (3%)
#ADRENAL/CAPSULE	(87)	(124)	(249)	(175)	(99)
INFLAMMATION, CHRONIC				1 (1%)	
#ADRENAL CORTEX	(87)	(124)	(249)	(175)	(99)
DEGENERATION, NOS				1 (1%)	
DEGENERATION, CYSTIC			4 (2%)		
NECROSIS, NOS			2 (1%)		
METAMORPHOSIS, FATTY	25 (29%)	18 (15%)	79 (32%)	25 (14%)	25 (25%)
HYPERTROPHY, NOS					1 (1%)
HYPERTROPHY, FOCAL	6 (7%)	4 (3%)	4 (2%)	2 (1%)	
HYPERPLASIA, FOCAL		2 (2%)	7 (3%)	2 (1%)	2 (2%)
ANGIECTASIS	1 (1%)	2 (2%)	4 (2%)		
#ADRENAL MEDULLA	(87)	(124)	(249)	(175)	(99)
METAMORPHOSIS, FATTY		2 (2%)			
HYPERPLASIA, NOS	1 (1%)		1 (0%)		1 (1%)
HYPERPLASIA, FOCAL	3 (3%)	5 (4%)	11 (4%)	3 (2%)	7 (7%)
#THYROID	(87)	(124)	(248)	(174)	(100)
CYST, NOS				1 (1%)	
CYSTIC FOLLICLES	2 (2%)	5 (4%)	13 (5%)	6 (3%)	1 (1%)
INFLAMMATION, CHRONIC FOCAL			1 (0%)		
HYPERPLASIA, NOS		1 (1%)			
HYPERPLASIA, C-CELL	24 (28%)	42 (34%)	53 (21%)	31 (18%)	24 (24%)
HYPERPLASIA, FOLLICULAR-CELL					1 (1%)

HWBUI0001791

TABLE D2. SUMMARY OF THE INCIDENCE OF NONNEOPLASTIC LESIONS IN FEMALE RATS IN THE LIFETIME FEED STUDY OF INTERMEDIATE-RANGE (IR) CHRYSOTILE ASBESTOS (Continued)

	CONTROL (UNTR)	DMH	IR	IR + DMH	IR/PW
ENDOCRINE SYSTEM (Continued)					
#PARATHYROID	(73)	(119)	(235)	(164)	(97)
HYPERPLASIA, NOS	4 (5%)		10 (4%)	1 (1%)	8 (8%)
#PANCREATIC ISLETS	(87)	(124)	(249)	(175)	(99)
HYPERPLASIA, NOS	1 (1%)		1 (0%)	1 (1%)	
REPRODUCTIVE SYSTEM					
*MAMMARY GLAND	(88)	(125)	(250)	(175)	(100)
DILATATION/DUCTS	9 (10%)	1 (1%)			5 (5%)
GALACTOCELE	22 (25%)	19 (15%)	91 (36%)	20 (11%)	36 (36%)
CYST, NOS			1 (0%)		
CYSTIC DUCTS	1 (1%)				
HYPERPLASIA, NOS	1 (1%)	4 (3%)	5 (2%)	7 (4%)	1 (1%)
*PREPUTIAL GLAND	(88)	(125)	(250)	(175)	(100)
DILATATION/DUCTS			1 (0%)		
*CLITORAL GLAND	(88)	(125)	(250)	(175)	(100)
DILATATION/DUCTS	1 (1%)		2 (1%)	1 (1%)	2 (2%)
INFLAMMATION, SUPPURATIVE		1 (1%)	1 (0%)		
ABSCESS, NOS			2 (1%)		1 (1%)
INFLAMMATION, ACUTE/CHRONIC		1 (1%)			
HYPERPLASIA, EPITHELIAL			1 (0%)		
HYPERKERATOSIS					1 (1%)
*VAGINA	(88)	(125)	(250)	(175)	(100)
INFLAMMATION, ACUTE				1 (1%)	
INFLAMMATION, ACUTE/CHRONIC					1 (1%)
HYPERPLASIA, STROMAL				1 (1%)	
#UTERUS	(87)	(125)	(249)	(175)	(99)
HYDROMETRA		2 (2%)	8 (3%)	7 (4%)	4 (4%)
CYST, NOS	1 (1%)				
STEATITIS		1 (1%)			
INFLAMMATION, SUPPURATIVE			1 (0%)	1 (1%)	1 (1%)
PYOMETRA			1 (0%)		
INFLAMMATION, ACUTE	3 (3%)			1 (1%)	
INFLAMMATION, ACUTE/CHRONIC		1 (1%)			1 (1%)
NECROSIS, FAT		1 (1%)			
HEMOSIDEROSIS			1 (0%)		
#CERVIX UTERI	(87)	(125)	(249)	(175)	(99)
CYST, NOS			1 (0%)	1 (1%)	
INFLAMMATION, SUPPURATIVE			1 (0%)		
INFLAMMATION, ACUTE/CHRONIC					1 (1%)
INFLAMMATION, GRANULOMATOUS		1 (1%)			
HYPERPLASIA, EPITHELIAL			1 (0%)		
HYPERPLASIA, STROMAL		3 (2%)	3 (1%)	3 (2%)	
#UTERUS/ENDOMETRIUM	(87)	(125)	(249)	(175)	(99)
CYST, NOS		5 (4%)	5 (2%)	7 (4%)	
HYPERPLASIA, NOS	1 (1%)	2 (2%)	2 (1%)	4 (2%)	
HYPERPLASIA, CYSTIC	4 (5%)	4 (3%)	4 (2%)	2 (1%)	
#OVARY/PAROVARIAN	(87)	(125)	(249)	(174)	(99)
STEATITIS		1 (1%)			
#OVARY	(87)	(125)	(249)	(174)	(99)
MINERALIZATION			1 (0%)		
CYST, NOS		1 (1%)	10 (4%)	2 (1%)	4 (4%)
PAROVARIAN CYST	4 (5%)	2 (2%)	11 (4%)	10 (6%)	4 (4%)
INFLAMMATION, SUPPURATIVE			1 (0%)	1 (1%)	

HWBUI0001792

TABLE D2. SUMMARY OF THE INCIDENCE OF NONNEOPLASTIC LESIONS IN FEMALE RATS IN THE LIFETIME FEED STUDY OF INTERMEDIATE-RANGE (IR) CHRYSOTILE ASBESTOS (Continued)

	CONTROL (UNTR)	DMH	IR	IR + DMH	IR/PW
NERVOUS SYSTEM					
#BRAIN/MENINGES	(87)	(125)	(250)	(175)	(100)
INFLAMMATION, ACUTE/CHRONIC			1 (0%)		
#CEREBRAL VENTRICLE	(87)	(125)	(250)	(175)	(100)
DILATATION, NOS	4 (5%)	1 (1%)	9 (4%)	2 (1%)	10 (10%)
#BRAIN	(87)	(125)	(250)	(175)	(100)
HEMORRHAGE		1 (1%)	1 (0%)		1 (1%)
SPECIAL SENSE ORGANS					
*EYE	(88)	(125)	(250)	(175)	(100)
HEMORRHAGE	1 (1%)	1 (1%)	1 (0%)		
INFLAMMATION, SUPPURATIVE		1 (1%)	1 (0%)		
INFLAMMATION, CHRONIC	1 (1%)		4 (2%)		
CATARACT	30 (34%)	3 (2%)	73 (29%)	28 (16%)	26 (26%)
*EYE/RETINA	(88)	(125)	(250)	(175)	(100)
DEGENERATION, NOS	30 (34%)	4 (3%)	72 (29%)	30 (17%)	27 (27%)
*HARDERIAN GLAND	(88)	(125)	(250)	(175)	(100)
INFLAMMATION, GRANULOMATOUS				1 (1%)	
ATROPHY, NOS			1 (0%)		
*EAR	(88)	(125)	(250)	(175)	(100)
CYST, NOS			1 (0%)		
*ZYMBAL GLAND	(88)	(125)	(250)	(175)	(100)
DILATATION/DUCTS	1 (1%)	2 (2%)		1 (1%)	2 (2%)
INFLAMMATION, ACUTE		1 (1%)			
ABSCESS, CHRONIC				2 (1%)	
HYPERKERATOSIS		5 (4%)		2 (1%)	2 (2%)
MUSCULOSKELETAL SYSTEM					
*SKULL	(88)	(125)	(250)	(175)	(100)
HYPEROSTOSIS	2 (2%)	1 (1%)	5 (2%)	2 (1%)	6 (6%)
*STERNUM	(88)	(125)	(250)	(175)	(100)
CHONDRODYSTROPHY			1 (0%)		
OSTEOCHONDRODYSTROPHY				1 (1%)	
HYPEROSTOSIS	2 (2%)	8 (6%)	20 (8%)	12 (7%)	6 (6%)
*RIB	(88)	(125)	(250)	(175)	(100)
CHONDRODYSTROPHY			1 (0%)		
*SKELETAL MUSCLE	(88)	(125)	(250)	(175)	(100)
INFLAMMATION, CHRONIC FOCAL	1 (1%)				
BODY CAVITIES					
*MEDIASTINUM	(88)	(125)	(250)	(175)	(100)
INFLAMMATION, CHRONIC			1 (0%)		
*ABDOMINAL CAVITY	(88)	(125)	(250)	(175)	(100)
STEATITIS	1 (1%)	1 (1%)	4 (2%)	2 (1%)	
NECROSIS, FAT	1 (1%)		1 (0%)	1 (1%)	
*PLEURA	(88)	(125)	(250)	(175)	(100)
FIBROSIS, FOCAL					1 (1%)
*PERICARDIUM	(88)	(125)	(250)	(175)	(100)
INFLAMMATION, SUPPURATIVE			1 (0%)		
INFLAMMATION, FIBRINOUS			1 (0%)		
*MESENTERY	(88)	(125)	(250)	(175)	(100)
CONGESTION, NOS				1 (1%)	
INFLAMMATION, ACUTE/CHRONIC		1 (1%)			
INFLAMMATION, CHRONIC		1 (1%)			2 (2%)
NECROSIS, FAT		2 (2%)		2 (1%)	1 (1%)

HWBUI0001793

TABLE D2. SUMMARY OF THE INCIDENCE OF NONNEOPLASTIC LESIONS IN FEMALE RATS IN THE LIFETIME FEED STUDY OF INTERMEDIATE-RANGE (IR) CHRYSOTILE ASBESTOS (Continued)

	CONTROL (UNTR)	DMH	IR	IR + DMH	IR/PW
ALL OTHER SYSTEMS					
*MULTIPLE ORGANS	(88)	(125)	(250)	(175)	(100)
CONGESTION, NOS		1 (1%)			
INFLAMMATION, SUPPURATIVE			1 (0%)		
INFLAMMATION, CHRONIC			1 (0%)		
PIGMENTATION, NOS			1 (0%)		
DIAPHRAGM					
HERNIA, NOS	3	3	6	3	
ADIPOSE TISSUE					
INFLAMMATION, CHRONIC			1	3	
NECROSIS, FAT		1		1	
BROAD LIGAMENT					
FIBROSIS	1				
SPECIAL MORPHOLOGY SUMMARY					
NECROPSY PERF/NO HISTO PERFORMED		1			
AUTO/NECROPSY/HISTO PERF			1		1

NUMBER OF ANIMALS WITH TISSUE EXAMINED MICROSCOPICALLY
* NUMBER OF ANIMALS NECROPSIED

HWBUI0001794

HWBUI0001795

APPENDIX E

ANALYSES OF PRIMARY TUMORS IN RATS IN THE LIFETIME FEED STUDIES OF SHORT-RANGE AND INTERMEDIATE-RANGE CHRYSOTILE ASBESTOS AND INTERMEDIATE-RANGE CHRYSOTILE ASBESTOS PLUS 1,2-DIMETHYLHYDRAZINE DIHYDROCHLORIDE

HWBUI0001796

TABLE E1. ANALYSIS OF PRIMARY TUMORS IN MALE RATS IN THE LIFETIME FEED STUDY OF SHORT-RANGE CHRYSOTILE ASBESTOS

	CONTROL (UNTR)	SHORT RANGE (a)
Skin: Keratoacanthoma		
Overall Rates (b)	5/88 (6%)	14/250 (6%)
Adjusted Rates (c)	23.1%	16.8%
Terminal Rates (d)	3/15 (20%)	0/38 (0%)
Life Table Test (e)		P=0.592N
Incidental Tumor Test (e)		P=0.602
Fisher Exact Test (e)		P=0.580N
Subcutaneous Tissue: Fibroma		
Overall Rates (b)	13/88 (15%)	25/250 (10%)
Adjusted Rates (c)	37.9%	26.8%
Terminal Rates (d)	2/15 (13%)	4/38 (11%)
Life Table Test (e)		P=0.185N
Incidental Tumor Test (e)		P=0.133N
Fisher Exact Test (e)		P=0.154N
Subcutaneous Tissue: Fibroma or Fibrosarcoma		
Overall Rates (b)	16/88 (18%)	30/250 (12%)
Adjusted Rates (c)	43.3%	30.0%
Terminal Rates (d)	2/15 (13%)	4/38 (11%)
Life Table Test (e)		P=0.138N
Incidental Tumor Test (e)		P=0.081N
Fisher Exact Test (e)		P=0.104N
Integumentary System: Basal Cell Tumor or Carcinoma		
Overall Rates (b)	3/88 (3%)	16/250 (6%)
Adjusted Rates (c)	7.0%	22.3%
Terminal Rates (d)	0/15 (0%)	4/38 (11%)
Life Table Test (e)		P=0.227
Incidental Tumor Test (e)		P=0.232
Fisher Exact Test (e)		P=0.223
Hematopoietic System: Leukemia		
Overall Rates (b)	37/88 (42%)	109/250 (44%)
Adjusted Rates (c)	71.8%	78.7%
Terminal Rates (d)	6/15 (40%)	19/38 (50%)
Life Table Test (e)		P=0.401
Incidental Tumor Test (e)		P=0.544N
Fisher Exact Test (e)		P=0.450
Liver: Neoplastic Nodule		
Overall Rates (b)	12/88 (14%)	17/248 (7%)
Adjusted Rates (c)	39.7%	21.1%
Terminal Rates (d)	4/15 (27%)	3/38 (8%)
Life Table Test (e)		P=0.056N
Incidental Tumor Test (e)		P=0.031N
Fisher Exact Test (e)		P=0.046N
Liver: Neoplastic Nodule or Hepatocellular Carcinoma		
Overall Rates (b)	15/88 (17%)	19/248 (8%)
Adjusted Rates (c)	47.9%	23.8%
Terminal Rates (d)	4/15 (27%)	4/38 (11%)
Life Table Test (e)		P=0.018N
Incidental Tumor Test (e)		P=0.007N
Fisher Exact Test (e)		P=0.013N
Pancreas: Acinar Cell Adenoma		
Overall Rates (b)	7/86 (8%)	14/247 (6%)
Adjusted Rates (c)	22.7%	19.6%
Terminal Rates (d)	1/15 (7%)	4/38 (11%)
Life Table Test (e)		P=0.362N
Incidental Tumor Test (e)		P=0.258N
Fisher Exact Test (e)		P=0.282N

HWBUI0001797

TABLE E1. ANALYSIS OF PRIMARY TUMORS IN MALE RATS IN THE LIFETIME FEED STUDY OF SHORT-RANGE CHRYSOTILE ASBESTOS (Continued)

	CONTROL (UNTR)	SHORT RANGE (a)
Pituitary: Adenoma		
Overall Rates (b)	20/87 (23%)	42/247 (17%)
Adjusted Rates (c)	54.3%	40.8%
Terminal Rates (d)	4/15 (27%)	5/38 (13%)
Life Table Test (e)		P=0.182N
Incidental Tumor Test (e)		P=0.118N
Fisher Exact Test (e)		P=0.142N
Pituitary: Adenoma or Carcinoma		
Overall Rates (b)	21/87 (24%)	45/247 (18%)
Adjusted Rates (c)	58.4%	42.3%
Terminal Rates (d)	5/15 (33%)	5/38 (13%)
Life Table Test (e)		P=0.196N
Incidental Tumor Test (e)		P=0.124N
Fisher Exact Test (e)		P=0.151N
Adrenal: Pheochromocytoma		
Overall Rates (b)	25/88 (28%)	73/248 (29%)
Adjusted Rates (c)	67.1%	70.0%
Terminal Rates (d)	6/15 (40%)	17/38 (45%)
Life Table Test (e)		P=0.437
Incidental Tumor Test (e)		P=0.500
Fisher Exact Test (e)		P=0.485
Adrenal: Pheochromocytoma or Pheochromocytoma, Malignant		
Overall Rates (b)	26/88 (30%)	78/248 (31%)
Adjusted Rates (c)	67.8%	74.7%
Terminal Rates (d)	6/15 (40%)	20/38 (53%)
Life Table Test (e)		P=0.376
Incidental Tumor Test (e)		P=0.443
Fisher Exact Test (e)		P=0.425
Thyroid: Follicular Cell Adenoma		
Overall Rates (b)	4/86 (5%)	13/246 (5%)
Adjusted Rates (c)	13.5%	14.4%
Terminal Rates (d)	1/15 (7%)	3/38 (8%)
Life Table Test (e)		P=0.505
Incidental Tumor Test (e)		P=0.458
Fisher Exact Test (e)		P=0.538
Thyroid: Follicular Cell Adenoma or Carcinoma		
Overall Rates (b)	6/86 (7%)	25/246 (10%)
Adjusted Rates (c)	16.6%	24.3%
Terminal Rates (d)	1/15 (7%)	4/38 (11%)
Life Table Test (e)		P=0.237
Incidental Tumor Test (e)		P=0.234
Fisher Exact Test (e)		P=0.261
Thyroid: C-Cell Adenoma		
Overall Rates (b)	13/86 (15%)	28/246 (11%)
Adjusted Rates (c)	35.8%	32.1%
Terminal Rates (d)	2/15 (13%)	6/38 (16%)
Life Table Test (e)		P=0.274N
Incidental Tumor Test (e)		P=0.198N
Fisher Exact Test (e)		P=0.234N
Thyroid: C-Cell Carcinoma		
Overall Rates (b)	11/86 (13%)	24/246 (10%)
Adjusted Rates (c)	36.2%	26.2%
Terminal Rates (d)	3/15 (20%)	5/38 (13%)
Life Table Test (e)		P=0.321N
Incidental Tumor Test (e)		P=0.251N
Fisher Exact Test (e)		P=0.274N

HWBUI0001798

TABLE E1. ANALYSIS OF PRIMARY TUMORS IN MALE RATS IN THE LIFETIME FEED STUDY OF SHORT-RANGE CHRYSOTILE ASBESTOS (Continued)

	CONTROL (UNTR)	SHORT RANGE (a)
Thyroid: C-Cell Adenoma or Carcinoma		
Overall Rates (b)	24/86 (28%)	52/246 (21%)
Adjusted Rates (c)	60.8%	51.4%
Terminal Rates (d)	5/15 (33%)	11/38 (29%)
Life Table Test (e)		P=0.182N
Incidental Tumor Test (e)		P=0.094N
Fisher Exact Test (e)		P=0.129N
Parathyroid: Adenoma		
Overall Rates (b)	6/83 (7%)	4/229 (2%)
Adjusted Rates (c)	22.8%	7.8%
Terminal Rates (d)	1/15 (7%)	2/36 (6%)
Life Table Test (e)		P=0.024N
Incidental Tumor Test (e)		P=0.023N
Fisher Exact Test (e)		P=0.025N
Pancreatic Islets: Islet Cell Adenoma		
Overall Rates (b)	6/86 (7%)	18/247 (7%)
Adjusted Rates (c)	19.5%	21.5%
Terminal Rates (d)	1/15 (7%)	3/38 (8%)
Life Table Test (e)		P=0.525
Incidental Tumor Test (e)		P=0.583
Fisher Exact Test (e)		P=0.571
Pancreatic Islets: Islet Cell Carcinoma		
Overall Rates (b)	3/86 (3%)	14/247 (6%)
Adjusted Rates (c)	16.1%	18.7%
Terminal Rates (d)	2/15 (13%)	3/38 (8%)
Life Table Test (e)		P=0.298
Incidental Tumor Test (e)		P=0.277
Fisher Exact Test (e)		P=0.318
Pancreatic Islets: Islet Cell Adenoma or Carcinoma		
Overall Rates (b)	9/86 (10%)	30/247 (12%)
Adjusted Rates (c)	33.3%	35.4%
Terminal Rates (d)	3/15 (20%)	6/38 (16%)
Life Table Test (e)		P=0.376
Incidental Tumor Test (e)		P=0.403
Fisher Exact Test (e)		P=0.421
Mammary Gland: Fibroadenoma		
Overall Rates (b)	11/88 (13%)	27/250 (11%)
Adjusted Rates (c)	46.2%	37.5%
Terminal Rates (d)	5/15 (33%)	7/38 (18%)
Life Table Test (e)		P=0.468N
Incidental Tumor Test (e)		P=0.401N
Fisher Exact Test (e)		P=0.397N
Preputial Gland: Carcinoma		
Overall Rates (b)	6/88 (7%)	13/250 (5%)
Adjusted Rates (c)	20.3%	12.8%
Terminal Rates (d)	2/15 (13%)	2/38 (5%)
Life Table Test (e)		P=0.421N
Incidental Tumor Test (e)		P=0.373N
Fisher Exact Test (e)		P=0.370N
Preputial Gland: Adenoma or Carcinoma		
Overall Rates (b)	6/88 (7%)	14/250 (6%)
Adjusted Rates (c)	20.3%	14.2%
Terminal Rates (d)	2/15 (13%)	2/38 (5%)
Life Table Test (e)		P=0.467N
Incidental Tumor Test (e)		P=0.432N
Fisher Exact Test (e)		P=0.425N

HWBUI0001799

TABLE E1. ANALYSIS OF PRIMARY TUMORS IN MALE RATS IN THE LIFETIME FEED STUDY OF SHORT-RANGE CHRYSOTILE ASBESTOS (Continued)

	CONTROL (UNTR)	SHORT RANGE (a)
Testis: Interstitial Cell Tumor		
Overall Rates (b)	81/87 (93%)	238/246 (97%)
Adjusted Rates (c)	100.0%	100.0%
Terminal Rates (d)	15/15 (100%)	38/38 (100%)
Life Table Test (e)		P=0.336
Incidental Tumor Test (e)		P=0.590
Fisher Exact Test (e)		P=0.128
Testis: Interstitial Cell Tumor or Interstitial Cell Tumor, Malignant		
Overall Rates (b)	81/87 (93%)	239/246 (97%)
Adjusted Rates (c)	100.0%	100.0%
Terminal Rates (d)	15/15 (100%)	38/38 (100%)
Life Table Test (e)		P=0.324
Incidental Tumor Test (e)		P=0.512
Fisher Exact Test (e)		P=0.092
Zymbal Gland: Squamous Cell Papilloma or Carcinoma		
Overall Rates (b)	5/88 (6%)	5/250 (2%)
Adjusted Rates (c)	13.6%	5.8%
Terminal Rates (d)	1/15 (7%)	1/38 (3%)
Life Table Test (e)		P=0.101N
Incidental Tumor Test (e)		P=0.085N
Fisher Exact Test (e)		P=0.088N
Tunica Vaginalis: Mesothelioma, Malignant		
Overall Rates (b)	2/88 (2%)	14/250 (6%)
Adjusted Rates (c)	3.4%	9.6%
Terminal Rates (d)	0/15 (0%)	0/38 (0%)
Life Table Test (e)		P=0.172
Incidental Tumor Test (e)		P=0.191
Fisher Exact Test (e)		P=0.166
All Sites: Mesothelioma, Malignant		
Overall Rates (b)	2/88 (2%)	15/250 (6%)
Adjusted Rates (c)	3.4%	10.1%
Terminal Rates (d)	0/15 (0%)	0/38 (0%)
Life Table Test (e)		P=0.145
Incidental Tumor Test (e)		P=0.161
Fisher Exact Test (e)		P=0.135

(a) Administered 1% short-range chrysotile asbestos in the diet
(b) Number of tumor-bearing animals/number of animals examined at the site
(c) Kaplan-Meier estimated tumor incidence at the end of the study after adjusting for intercurrent mortality
(d) Observed tumor incidence at terminal kill
(e) Beneath the dosed group incidence is the P value corresponding to the pairwise comparison between the dosed group and the controls. The life table analysis regards tumors in animals dying prior to terminal kill as being (directly or indirectly) the cause of death. The incidental tumor test regards these lesions as nonfatal. The Fisher exact test compares directly the overall incidence rates. A lower incidence in the dosed group is indicated by (N).

HWBUI0001800

TABLE E2. ANALYSIS OF PRIMARY TUMORS IN FEMALE RATS IN THE LIFETIME FEED STUDY OF SHORT-RANGE CHRYSOTILE ASBESTOS

	CONTROL (UNTR)	SHORT RANGE (a)
Hematopoietic System: Leukemia		
Overall Rates (b)	28/88 (32%)	101/250 (40%)
Adjusted Rates (c)	68.3%	74.7%
Terminal Rates (d)	3/9 (33%)	10/26 (38%)
Life Table Test (e)		P=0.155
Incidental Tumor Test (e)		P=0.069
Fisher Exact Test (e)		P=0.097
Pituitary: Adenoma		
Overall Rates (b)	39/87 (45%)	101/244 (41%)
Adjusted Rates (c)	89.5%	80.1%
Terminal Rates (d)	6/9 (67%)	13/26 (50%)
Life Table Test (e)		P=0.368N
Incidental Tumor Test (e)		P=0.335N
Fisher Exact Test (e)		P=0.333N
Pituitary: Carcinoma		
Overall Rates (b)	6/87 (7%)	13/244 (5%)
Adjusted Rates (c)	22.6%	10.3%
Terminal Rates (d)	1/9 (11%)	0/26 (0%)
Life Table Test (e)		P=0.362N
Incidental Tumor Test (e)		P=0.439N
Fisher Exact Test (e)		P=0.380N
Pituitary: Adenoma or Carcinoma		
Overall Rates (b)	45/87 (52%)	114/244 (47%)
Adjusted Rates (c)	93.9%	82.2%
Terminal Rates (d)	7/9 (78%)	13/26 (50%)
Life Table Test (e)		P=0.295N
Incidental Tumor Test (e)		P=0.268N
Fisher Exact Test (e)		P=0.249N
Adrenal: Pheochromocytoma		
Overall Rates (b)	9/87 (10%)	38/245 (16%)
Adjusted Rates (c)	38.2%	51.8%
Terminal Rates (d)	2/9 (22%)	7/26 (27%)
Life Table Test (e)		P=0.170
Incidental Tumor Test (e)		P=0.206
Fisher Exact Test (e)		P=0.156
Adrenal: Pheochromocytoma or Pheochromocytoma, Malignant		
Overall Rates (b)	9/87 (10%)	39/245 (16%)
Adjusted Rates (c)	38.2%	52.2%
Terminal Rates (d)	2/9 (22%)	7/26 (27%)
Life Table Test (e)		P=0.153
Incidental Tumor Test (e)		P=0.175
Fisher Exact Test (e)		P=0.136
Thyroid: Follicular Cell Adenoma or Carcinoma		
Overall Rates (b)	5/87 (6%)	12/244 (5%)
Adjusted Rates (c)	38.1%	18.5%
Terminal Rates (d)	3/9 (33%)	2/26 (8%)
Life Table Test (e)		P=0.494N
Incidental Tumor Test (e)		P=0.465N
Fisher Exact Test (e)		P=0.476N
Thyroid: C-Cell Adenoma		
Overall Rates (b)	11/87 (13%)	20/244 (8%)
Adjusted Rates (c)	41.0%	23.9%
Terminal Rates (d)	1/9 (11%)	2/26 (8%)
Life Table Test (e)		P=0.170N
Incidental Tumor Test (e)		P=0.154N
Fisher Exact Test (e)		P=0.157N

HWBUI0001801

TABLE E2. ANALYSIS OF PRIMARY TUMORS IN FEMALE RATS IN THE LIFETIME FEED STUDY OF SHORT-RANGE CHRYSOTILE ASBESTOS (Continued)

	CONTROL (UNTR)	SHORT RANGE (a)
Thyroid: C-Cell Carcinoma		
Overall Rates (b)	7/87 (8%)	21/244 (9%)
Adjusted Rates (c)	33.3%	30.1%
Terminal Rates (d)	1/9 (11%)	4/26 (15%)
Life Table Test (e)		P=0.522
Incidental Tumor Test (e)		P=0.555
Fisher Exact Test (e)		P=0.537
Thyroid: C-Cell Adenoma or Carcinoma		
Overall Rates (b)	17/87 (20%)	40/244 (16%)
Adjusted Rates (c)	57.7%	47.4%
Terminal Rates (d)	2/9 (22%)	6/26 (23%)
Life Table Test (e)		P=0.319N
Incidental Tumor Test (e)		P=0.289N
Fisher Exact Test (e)		P=0.304N
Mammary Gland: Adenoma		
Overall Rates (b)	2/88 (2%)	14/250 (6%)
Adjusted Rates (c)	10.0%	21.9%
Terminal Rates (d)	0/9 (0%)	2/26 (8%)
Life Table Test (e)		P=0.175
Incidental Tumor Test (e)		P=0.161
Fisher Exact Test (e)		P=0.166
Mammary Gland: Fibroadenoma		
Overall Rates (b)	49/88 (56%)	146/250 (58%)
Adjusted Rates (c)	97.1%	96.4%
Terminal Rates (d)	8/9 (89%)	22/26 (85%)
Life Table Test (e)		P=0.399
Incidental Tumor Test (e)		P=0.353
Fisher Exact Test (e)		P=0.374
Mammary Gland: Adenocarcinoma		
Overall Rates (b)	6/88 (7%)	19/250 (8%)
Adjusted Rates (c)	40.8%	27.4%
Terminal Rates (d)	2/9 (22%)	3/26 (12%)
Life Table Test (e)		P=0.488
Incidental Tumor Test (e)		P=0.562
Fisher Exact Test (e)		P=0.511
Clitoral Gland: Carcinoma		
Overall Rates (b)	2/88 (2%)	17/250 (7%)
Adjusted Rates (c)	8.2%	22.2%
Terminal Rates (d)	0/9 (0%)	3/26 (12%)
Life Table Test (e)		P=0.101
Incidental Tumor Test (e)		P=0.085
Fisher Exact Test (e)		P=0.087
Clitoral Gland: Papilloma, Adenoma or Carcinoma		
Overall Rates (b)	3/88 (3%)	19/250 (8%)
Adjusted Rates (c)	10.5%	23.2%
Terminal Rates (d)	0/9 (0%)	3/26 (12%)
Life Table Test (e)		P=0.144
Incidental Tumor Test (e)		P=0.102
Fisher Exact Test (e)		P=0.129
Uterus: Endometrial Stromal Polyp		
Overall Rates (b)	15/87 (17%)	34/245 (14%)
Adjusted Rates (c)	49.1%	43.8%
Terminal Rates (d)	2/9 (22%)	4/26 (15%)
Life Table Test (e)		P=0.321N
Incidental Tumor Test (e)		P=0.256N
Fisher Exact Test (e)		P=0.276N

HWBUI0001802

TABLE E2. ANALYSIS OF PRIMARY TUMORS IN FEMALE RATS IN THE LIFETIME FEED STUDY OF SHORT-RANGE CHRYSOTILE ASBESTOS (Continued)

(a) Administered 1% short-range chrysotile asbestos in the diet
(b) Number of tumor-bearing animals/number of animals examined at the site
(c) Kaplan-Meier estimated tumor incidence at the end of the study after adjusting for intercurrent mortality
(d) Observed tumor incidence at terminal kill
(e) Beneath the dosed group incidence is the P value corresponding to the pairwise comparison between the dosed group and the controls. The life table analysis regards tumors in animals dying prior to terminal kill as being (directly or indirectly) the cause of death. The incidental tumor test regards these lesions as nonfatal. The Fisher exact test compares directly the overall incidence rates. A lower incidence in the dosed group is indicated by (N).

HWBUI0001803

TABLE E3. ANALYSIS OF PRIMARY TUMORS IN MALE RATS IN THE LIFETIME FEED STUDY OF INTERMEDIATE-RANGE CHRYSOTILE ASBESTOS

	CONTROL (UNTR)	IR (a)	IR/PW	IR vs IR/PW
Skin: Papilloma or Squamous Cell Papilloma				
Overall Rates (b)	5/88 (6%)	8/250 (3%)	3/100 (3%)	
Adjusted Rates (c)	46.1%	12.2%	14.0%	
Terminal Rates (d)	3/7 (43%)	0/29 (0%)	1/11 (9%)	
Life Table Test (e)		P=0.159N	P=0.224N	P=0.617
Incidental Tumor Test (e)		P=0.225N	P=0.326N	P=0.622N
Fisher Exact Test (e)		P=0.230N	P=0.292N	P=0.612N
Integumentary System: Keratoacanthoma				
Overall Rates (b)	1/88 (1%)	19/250 (8%)	8/100 (8%)	
Adjusted Rates (c)	3.2%	23.9%	32.7%	
Terminal Rates (d)	0/7 (0%)	3/29 (10%)	3/11 (27%)	
Life Table Test (e)		P=0.039	P=0.048	P=0.506
Incidental Tumor Test (e)		P=0.027	P=0.026	P=0.512
Fisher Exact Test (e)		P=0.017	P=0.027	P=0.527
Integumentary System: Fibroma				
Overall Rates (b)	17/88 (19%)	51/250 (20%)	12/100 (12%)	
Adjusted Rates (c)	45.2%	61.4%	49.2%	
Terminal Rates (d)	1/7 (14%)	10/29 (34%)	3/11 (27%)	
Life Table Test (e)		P=0.485N	P=0.103N	P=0.083N
Incidental Tumor Test (e)		P=0.465	P=0.156N	P=0.057N
Fisher Exact Test (e)		P=0.480	P=0.119N	P=0.042N
Integumentary System: Fibrosarcoma				
Overall Rates (b)	7/88 (8%)	6/250 (2%)	1/100 (1%)	
Adjusted Rates (c)	21.5%	5.2%	3.8%	
Terminal Rates (d)	0/7 (0%)	0/29 (0%)	0/11 (0%)	
Life Table Test (e)		P=0.021N	P=0.024N	P=0.373N
Incidental Tumor Test (e)		P=0.024N	P=0.017N	P=0.411N
Fisher Exact Test (e)		P=0.028N	P=0.021N	P=0.358N
Subcutaneous Tissue: Sarcoma				
Overall Rates (b)	1/88 (1%)	3/250 (1%)	5/100 (5%)	
Adjusted Rates (c)	1.3%	5.4%	21.3%	
Terminal Rates (d)	0/7 (0%)	1/29 (3%)	1/11 (9%)	
Life Table Test (e)		P=0.706N	P=0.164	P=0.034
Incidental Tumor Test (e)		P=0.688	P=0.117	P=0.032
Fisher Exact Test (e)		P=0.721	P=0.138	P=0.046
Integumentary System: Fibroma, Fibrosarcoma, or Sarcoma				
Overall Rates (b)	24/88 (27%)	59/250 (24%)	17/100 (17%)	
Adjusted Rates (c)	56.6%	65.9%	61.7%	
Terminal Rates (d)	1/7 (14%)	11/29 (38%)	4/11 (36%)	
Life Table Test (e)		P=0.186N	P=0.058N	P=0.191N
Incidental Tumor Test (e)		P=0.302N	P=0.086N	P=0.157N
Fisher Exact Test (e)		P=0.291N	P=0.064N	P=0.113N
Hematopoietic System: Leukemia				
Overall Rates (b)	31/88 (35%)	96/250 (38%)	37/100 (37%)	
Adjusted Rates (c)	67.8%	72.9%	72.9%	
Terminal Rates (d)	1/7 (14%)	11/29 (38%)	4/11 (36%)	
Life Table Test (e)		P=0.506	P=0.520	P=0.529N
Incidental Tumor Test (e)		P=0.309	P=0.356	P=0.508N
Fisher Exact Test (e)		P=0.346	P=0.460	P=0.453N
Liver: Neoplastic Nodule				
Overall Rates (b)	6/85 (7%)	13/250 (5%)	5/100 (5%)	
Adjusted Rates (c)	23.1%	17.9%	10.4%	
Terminal Rates (d)	0/7 (0%)	2/29 (7%)	0/11 (0%)	
Life Table Test (e)		P=0.321N	P=0.407N	P=0.592N
Incidental Tumor Test (e)		P=0.362N	P=0.377N	P=0.571N
Fisher Exact Test (e)		P=0.344N	P=0.389N	P=0.589N

HWBUI0001804

TABLE E3. ANALYSIS OF PRIMARY TUMORS IN MALE RATS IN THE LIFETIME FEED STUDY OF INTERMEDIATE-RANGE CHRYSOTILE ASBESTOS (Continued)

	CONTROL (UNTR)	IR (a)	IR/PW	IR vs IR/PW
Liver: Neoplastic Nodule or Hepatocellular Carcinoma				
Overall Rates (b)	8/85 (9%)	19/250 (8%)	6/100 (6%)	
Adjusted Rates (c)	27.9%	28.9%	11.5%	
Terminal Rates (d)	0/7 (0%)	5/29 (17%)	0/11 (0%)	
Life Table Test (e)		P=0.321N	P=0.300N	P=0.408N
Incidental Tumor Test (e)		P=0.391N	P=0.277N	P=0.387N
Fisher Exact Test (e)		P=0.372N	P=0.275N	P=0.395N
Pancreas: Acinar Cell Adenoma				
Overall Rates (b)	3/85 (4%)	23/249 (9%)	9/99 (9%)	
Adjusted Rates (c)	19.5%	38.5%	26.8%	
Terminal Rates (d)	0/7 (0%)	7/29 (24%)	1/11 (9%)	
Life Table Test (e)		P=0.113	P=0.108	P=0.564
Incidental Tumor Test (e)		P=0.066	P=0.102	P=0.578
Fisher Exact Test (e)		P=0.065	P=0.109	P=0.574N
Large Intestine: Adenomatous Polyp				
Overall Rates (b)	0/85 (0%)	9/250 (4%)	2/100 (2%)	
Adjusted Rates (c)	0.0%	10.2%	7.4%	
Terminal Rates (d)	0/7 (0%)	1/29 (3%)	0/11 (0%)	
Life Table Test (e)		P=0.088	P=0.315	P=0.343N
Incidental Tumor Test (e)		P=0.084	P=0.235	P=0.385N
Fisher Exact Test (e)		P=0.069	P=0.291	P=0.348N
Pituitary: Adenoma				
Overall Rates (b)	14/85 (16%)	49/246 (20%)	18/100 (18%)	
Adjusted Rates (c)	39.1%	50.3%	47.8%	
Terminal Rates (d)	0/7 (0%)	5/29 (17%)	3/11 (27%)	
Life Table Test (e)		P=0.398	P=0.435	P=0.531N
Incidental Tumor Test (e)		P=0.284	P=0.415	P=0.458N
Fisher Exact Test (e)		P=0.299	P=0.470	P=0.403N
Pituitary: Adenoma or Carcinoma				
Overall Rates (b)	18/85 (21%)	52/246 (21%)	19/100 (19%)	
Adjusted Rates (c)	43.7%	52.0%	48.8%	
Terminal Rates (d)	0/7 (0%)	5/29 (17%)	3/11 (27%)	
Life Table Test (e)		P=0.461N	P=0.470N	P=0.523N
Incidental Tumor Test (e)		P=0.552	P=0.479N	P=0.438N
Fisher Exact Test (e)		P=0.553N	P=0.426N	P=0.387N
Adrenal: Pheochromocytoma				
Overall Rates (b)	16/85 (19%)	59/250 (24%)	32/100 (32%)	
Adjusted Rates (c)	61.5%	60.6%	87.2%	
Terminal Rates (d)	2/7 (29%)	8/29 (28%)	8/11 (73%)	
Life Table Test (e)		P=0.322	P=0.058	P=0.051
Incidental Tumor Test (e)		P=0.189	P=0.014	P=0.045
Fisher Exact Test (e)		P=0.225	P=0.030	P=0.070
Adrenal: Pheochromocytoma or Pheochromocytoma, Malignant				
Overall Rates (b)	17/85 (20%)	63/250 (25%)	32/100 (32%)	
Adjusted Rates (c)	62.7%	64.7%	87.2%	
Terminal Rates (d)	2/7 (29%)	10/29 (28%)	8/11 (73%)	
Life Table Test (e)		P=0.310	P=0.082	P=0.089
Incidental Tumor Test (e)		P=0.170	P=0.023	P=0.083
Fisher Exact Test (e)		P=0.206	P=0.046	P=0.124
Thyroid: Follicular Cell Carcinoma				
Overall Rates (b)	5/84 (6%)	13/250 (5%)	2/99 (2%)	
Adjusted Rates (c)	19.8%	17.8%	12.6%	
Terminal Rates (d)	0/7 (0%)	2/29 (7%)	1/11 (9%)	
Life Table Test (e)		P=0.468N	P=0.161N	P=0.201N
Incidental Tumor Test (e)		P=0.532N	P=0.191N	P=0.155N
Fisher Exact Test (e)		P=0.489N	P=0.160N	P=0.151N

HWBUI0001805

TABLE E3. ANALYSIS OF PRIMARY TUMORS IN MALE RATS IN THE LIFETIME FEED STUDY OF INTERMEDIATE-RANGE CHRYSOTILE ASBESTOS (Continued)

	CONTROL (UNTR)	IR (a)	IR/PW	IR vs IR/PW
Thyroid: Follicular Cell Adenoma or Carcinoma				
Overall Rates (b)	6/84 (7%)	25/250 (10%)	5/99 (5%)	
Adjusted Rates (c)	21.5%	31.6%	21.8%	
Terminal Rates (d)	0/7 (0%)	3/29 (10%)	1/11 (9%)	
Life Table Test (e)		P=0.329	P=0.365N	P=0.150N
Incidental Tumor Test (e)		P=0.270	P=0.429N	P=0.108N
Fisher Exact Test (e)		P=0.294	P=0.387N	P=0.098N
Thyroid: C-Cell Adenoma				
Overall Rates (b)	13/84 (15%)	29/250 (12%)	9/99 (9%)	
Adjusted Rates (c)	44.6%	38.6%	34.5%	
Terminal Rates (d)	1/7 (14%)	6/29 (21%)	3/11 (27%)	
Life Table Test (e)		P=0.196N	P=0.144N	P=0.364N
Incidental Tumor Test (e)		P=0.260N	P=0.153N	P=0.300N
Fisher Exact Test (e)		P=0.228N	P=0.137N	P=0.320N
Thyroid: C-Cell Carcinoma				
Overall Rates (b)	19/84 (23%)	38/250 (15%)	23/99 (23%)	
Adjusted Rates (c)	59.9%	47.2%	57.6%	
Terminal Rates (d)	2/7 (29%)	5/29 (17%)	3/11 (27%)	
Life Table Test (e)		P=0.068N	P=0.526	P=0.046
Incidental Tumor Test (e)		P=0.095N	P=0.436	P=0.040
Fisher Exact Test (e)		P=0.084N	P=0.532	P=0.054
Thyroid: C-Cell Adenoma or Carcinoma				
Overall Rates (b)	30/84 (36%)	65/250 (26%)	32/99 (32%)	
Adjusted Rates (c)	76.9%	69.1%	76.1%	
Terminal Rates (d)	3/7 (43%)	11/29 (38%)	6/11 (55%)	
Life Table Test (e)		P=0.051N	P=0.381N	P=0.121
Incidental Tumor Test (e)		P=0.071N	P=0.470N	P=0.124
Fisher Exact Test (e)		P=0.061N	P=0.372N	P=0.146
Pancreatic Islet: Islet Cell Adenoma				
Overall Rates (b)	5/85 (6%)	6/249 (2%)	5/99 (5%)	
Adjusted Rates (c)	29.1%	9.6%	18.4%	
Terminal Rates (d)	1/7 (14%)	1/29 (3%)	0/11 (0%)	
Life Table Test (e)		P=0.088N	P=0.483N	P=0.141
Incidental Tumor Test (e)		P=0.114N	P=0.542N	P=0.176
Fisher Exact Test (e)		P=0.119N	P=0.528N	P=0.174
Pancreatic Islets: Islet Cell Carcinoma				
Overall Rates (b)	3/85 (4%)	17/249 (7%)	6/99 (6%)	
Adjusted Rates (c)	6.9%	36.3%	19.6%	
Terminal Rates (d)	0/7 (0%)	8/29 (28%)	1/11 (9%)	
Life Table Test (e)		P=0.278	P=0.337	P=0.526N
Incidental Tumor Test (e)		P=0.188	P=0.304	P=0.519N
Fisher Exact Test (e)		P=0.204	P=0.330	P=0.504N
Pancreatic Islets: Islet Cell Adenoma or Carcinoma				
Overall Rates (b)	8/85 (9%)	23/249 (9%)	11/99 (11%)	
Adjusted Rates (c)	34.0%	43.2%	34.4%	
Terminal Rates (d)	1/7 (14%)	9/29 (31%)	1/11 (9%)	
Life Table Test (e)		P=0.440N	P=0.489	P=0.315
Incidental Tumor Test (e)		P=0.577N	P=0.420	P=0.345
Fisher Exact Test (e)		P=0.556N	P=0.449	P=0.363
Mammary Gland: Fibroadenoma				
Overall Rates (b)	3/88 (3%)	16/250 (6%)	7/100 (7%)	
Adjusted Rates (c)	10.5%	28.5%	27.9%	
Terminal Rates (d)	0/7 (0%)	5/29 (17%)	1/11 (9%)	
Life Table Test (e)		P=0.301	P=0.238	P=0.459
Incidental Tumor Test (e)		P=0.219	P=0.223	P=0.488
Fisher Exact Test (e)		P=0.223	P=0.223	P=0.501

HWBUI0001806

TABLE E3. ANALYSIS OF PRIMARY TUMORS IN MALE RATS IN THE LIFETIME FEED STUDY OF INTERMEDIATE-RANGE CHRYSOTILE ASBESTOS (Continued)

	CONTROL (UNTR)	IR (a)	IR/PW	IR vs IR/PW
Preputial Gland: Carcinoma				
Overall Rates (b)	3/88 (3%)	11/250 (4%)	3/100 (3%)	
Adjusted Rates (c)	7.1%	9.5%	9.5%	
Terminal Rates (d)	0/7 (0%)	0/29 (0%)	0/11 (0%)	
Life Table Test (e)		P=0.489	P=0.611N	P=0.403N
Incidental Tumor Test (e)		P=0.446	P=0.579N	P=0.390N
Fisher Exact Test (e)		P=0.483	P=0.597N	P=0.397N
Preputial Gland: Adenoma or Carcinoma				
Overall Rates (b)	4/88 (5%)	11/250 (4%)	3/100 (3%)	
Adjusted Rates (c)	11.1%	9.5%	9.5%	
Terminal Rates (d)	0/7 (0%)	0/29 (0%)	0/11 (0%)	
Life Table Test (e)		P=0.567N	P=0.453N	P=0.403N
Incidental Tumor Test (e)		P=0.612N	P=0.414N	P=0.390N
Fisher Exact Test (e)		P=0.579N	P=0.429N	P=0.397N
Testis: Interstitial Cell Tumor				
Overall Rates (b)	79/84 (94%)	237/250 (95%)	89/100 (89%)	
Adjusted Rates (c)	100.0%	100.0%	100.0%	
Terminal Rates (d)	7/7 (100%)	29/29 (100%)	11/11 (100%)	
Life Table Test (e)		P=0.471N	P=0.404N	P=0.439N
Incidental Tumor Test (e)		P=0.306	P=0.572	P=0.330N
Fisher Exact Test (e)		P=0.489	P=0.172N	P=0.048N
Testis: Interstitial Cell Tumor or Interstitial Cell Tumor, Malignant				
Overall Rates (b)	79/84 (94%)	238/250 (95%)	89/100 (89%)	
Adjusted Rates (c)	100.0%	100.0%	100.0%	
Terminal Rates (d)	7/7 (100%)	29/29 (100%)	11/11 (100%)	
Life Table Test (e)		P=0.484N	P=0.404N	P=0.428N
Incidental Tumor Test (e)		P=0.242	P=0.572	P=0.257N
Fisher Exact Test (e)		P=0.432	P=0.172N	P=0.035N
Tunica Vaginalis: Mesothelioma, Malignant				
Overall Rates (b)	2/88 (2%)	13/250 (5%)	5/100 (5%)	
Adjusted Rates (c)	2.4%	9.8%	18.0%	
Terminal Rates (d)	0/7 (0%)	0/29 (0%)	1/11 (9%)	
Life Table Test (e)		P=0.208	P=0.315	P=0.570N
Incidental Tumor Test (e)		P=0.189	P=0.199	P=0.583N
Fisher Exact Test (e)		P=0.203	P=0.278	P=0.589N
All Sites: Mesothelioma, Malignant				
Overall Rates (b)	2/88 (2%)	14/250 (6%)	5/100 (5%)	
Adjusted Rates (c)	2.4%	10.2%	18.0%	
Terminal Rates (d)	0/7 (0%)	0/29 (0%)	1/11 (9%)	
Life Table Test (e)		P=0.173	P=0.315	P=0.512N
Incidental Tumor Test (e)		P=0.153	P=0.199	P=0.531N
Fisher Exact Test (e)		P=0.166	P=0.278	P=0.529N
All Sites: Mesothelioma				
Overall Rates (b)	5/88 (6%)	16/250 (6%)	6/100 (6%)	
Adjusted Rates (c)	13.4%	15.0%	19.3%	
Terminal Rates (d)	0/7 (0%)	0/29 (0%)	1/11 (9%)	
Life Table Test (e)		P=0.521	P=0.610	P=0.538N
Incidental Tumor Test (e)		P=0.490	P=0.519	P=0.557N
Fisher Exact Test (e)		P=0.521	P=0.588	P=0.554N

HWBUI0001807

TABLE E3. ANALYSIS OF PRIMARY TUMORS IN MALE RATS IN THE LIFETIME FEED STUDY OF INTERMEDIATE-RANGE CHRYSOTILE ASBESTOS (Continued)

(a) Administered 1% intermediate-range (IR) chrysotile asbestos in the diet
(b) Number of tumor-bearing animals/number of animals examined at the site
(c) Kaplan-Meier estimated tumor incidence at the end of the study after adjusting for intercurrent mortality
(d) Observed tumor incidence at terminal kill
(e) Beneath the dosed group incidence are the P values corresponding to pairwise comparisons between that dosed group and the controls. The pairwise comparison between the dosed groups is in the final column. The life table analysis regards tumors in animals dying prior to terminal kill as being (directly or indirectly) the cause of death. The incidental tumor test regards these lesions as nonfatal. The Fisher exact test compares directly the overall incidence rates. A lower incidence in a dosed group than in the controls or in the IR plus preweaning gavage than the IR group is indicated by (N).

HWBUI0001808

TABLE E4. ANALYSIS OF PRIMARY TUMORS IN FEMALE RATS IN THE LIFETIME FEED STUDY OF INTERMEDIATE-RANGE CHRYSOTILE ASBESTOS (a)

	CONTROL (UNTR)	IR (a)	IR/PW	IR vs IR/PW
Subcutaneous Tissue: Fibroma				
Overall Rates (b)	5/88 (6%)	9/250 (4%)	3/100 (3%)	
Adjusted Rates (c)	27.2%	10.5%	10.1%	
Terminal Rates (d)	1/10 (10%)	1/29 (3%)	0/11 (0%)	
Life Table Test (e)		P=0.262N	P=0.289N	P=0.569N
Incidental Tumor Test (e)		P=0.308N	P=0.302N	P=0.496N
Fisher Exact Test (e)		P=0.287N	P=0.292N	P=0.537N
Subcutaneous Tissue: Fibroma or Fibrosarcoma				
Overall Rates (b)	6/88 (7%)	13/250 (5%)	3/100 (3%)	
Adjusted Rates (c)	31.8%	13.9%	10.1%	
Terminal Rates (d)	1/10 (10%)	1/29 (3%)	0/11 (0%)	
Life Table Test (e)		P=0.322N	P=0.185N	P=0.323N
Incidental Tumor Test (e)		P=0.403N	P=0.195N	P=0.252N
Fisher Exact Test (e)		P=0.370N	P=0.190N	P=0.281N
Hematopoietic System: Leukemia				
Overall Rates (b)	34/88 (39%)	82/250 (33%)	29/100 (29%)	
Adjusted Rates (c)	75.1%	59.5%	58.2%	
Terminal Rates (d)	3/10 (30%)	6/29 (21%)	3/11 (27%)	
Life Table Test (e)		P=0.184N	P=0.155N	P=0.389N
Incidental Tumor Test (e)		P=0.227N	P=0.150N	P=0.294N
Fisher Exact Test (e)		P=0.195N	P=0.108N	P=0.289N
Liver: Neoplastic Nodule or Hepatocellular Carcinoma				
Overall Rates (b)	4/87 (5%)	6/250 (2%)	1/99 (1%)	
Adjusted Rates (c)	16.0%	6.5%	1.8%	
Terminal Rates (d)	0/10 (0%)	0/29 (0%)	0/11 (0%)	
Life Table Test (e)		P=0.215N	P=0.152N	P=0.359N
Incidental Tumor Test (e)		P=0.256N	P=0.156N	P=0.346N
Fisher Exact Test (e)		P=0.241N	P=0.147N	P=0.363N
Pituitary: Adenoma				
Overall Rates (b)	49/87 (56%)	103/249 (41%)	50/100 (50%)	
Adjusted Rates (c)	93.4%	88.2%	90.2%	
Terminal Rates (d)	8/10 (80%)	20/29 (69%)	7/11 (64%)	
Life Table Test (e)		P=0.017N	P=0.332N	P=0.064
Incidental Tumor Test (e)		P=0.014N	P=0.314N	P=0.056
Fisher Exact Test (e)		P=0.012N	P=0.237N	P=0.089
Pituitary: Carcinoma				
Overall Rates (b)	4/87 (5%)	14/249 (6%)	1/100 (1%)	
Adjusted Rates (c)	13.1%	11.1%	3.2%	
Terminal Rates (d)	0/10 (0%)	0/29 (0%)	0/11 (0%)	
Life Table Test (e)		P=0.475	P=0.150N	P=0.056N
Incidental Tumor Test (e)		P=0.382	P=0.156N	P=0.044N
Fisher Exact Test (e)		P=0.481	P=0.144N	P=0.041N
Pituitary: Adenoma or Carcinoma				
Overall Rates (b)	53/87 (61%)	117/249 (47%)	51/100 (51%)	
Adjusted Rates (c)	94.2%	89.5%	90.5%	
Terminal Rates (d)	8/10 (80%)	20/29 (69%)	7/11 (64%)	
Life Table Test (e)		P=0.031N	P=0.220N	P=0.202
Incidental Tumor Test (e)		P=0.027N	P=0.160N	P=0.236
Fisher Exact Test (e)		P=0.018N	P=0.112N	P=0.288
Adrenal: Cortical Adenoma				
Overall Rates (b)	4/87 (5%)	10/249 (4%)	5/99 (5%)	
Adjusted Rates (c)	15.5%	11.1%	17.8%	
Terminal Rates (d)	1/10 (10%)	0/29 (0%)	0/11 (0%)	
Life Table Test (e)		P=0.477N	P=0.592	P=0.409
Incidental Tumor Test (e)		P=0.563N	P=0.548	P=0.439
Fisher Exact Test (e)		P=0.512N	P=0.581	P=0.431

HWBUI0001809

TABLE E4. ANALYSIS OF PRIMARY TUMORS IN FEMALE RATS IN THE LIFETIME FEED STUDY OF OF INTERMEDIATE-RANGE CHRYSOTILE ASBESTOS (Continued)

	CONTROL (UNTR)	IR (a)	IR/PW	IR vs IR/PW
Adrenal: Pheochromocytoma				
Overall Rates (b)	8/87 (9%)	25/249 (10%)	11/99 (11%)	
Adjusted Rates (c)	45.3%	39.6%	44.6%	
Terminal Rates (d)	3/10 (30%)	6/29 (17%)	3/11 (27%)	
Life Table Test (e)		P=0.573N	P=0.440	P=0.370
Incidental Tumor Test (e)		P=0.495	P=0.404	P=0.412
Fisher Exact Test (e)		P=0.503	P=0.427	P=0.451
Adrenal: Pheochromocytoma or Pheochromocytoma, Malignant				
Overall Rates (b)	10/87 (11%)	25/249 (10%)	13/99 (13%)	
Adjusted Rates (c)	47.9%	39.6%	50.1%	
Terminal Rates (d)	3/10 (30%)	6/29 (17%)	3/11 (27%)	
Life Table Test (e)		P=0.336N	P=0.472	P=0.189
Incidental Tumor Test (e)		P=0.430N	P=0.430	P=0.213
Fisher Exact Test (e)		P=0.420N	P=0.456	P=0.256
Thyroid: Follicular Cell Adenoma				
Overall Rates (b)	6/87 (7%)	13/248 (5%)	6/100 (6%)	
Adjusted Rates (c)	37.5%	19.1%	9.7%	
Terminal Rates (d)	3/10 (30%)	2/29 (7%)	0/11 (0%)	
Life Table Test (e)		P=0.341N	P=0.530N	P=0.449
Incidental Tumor Test (e)		P=0.364N	P=0.563N	P=0.512
Fisher Exact Test (e)		P=0.367N	P=0.517N	P=0.478
Thyroid: Follicular Cell Carcinoma				
Overall Rates (b)	1/87 (1%)	14/248 (6%)	7/100 (7%)	
Adjusted Rates (c)	6.2%	23.3%	26.1%	
Terminal Rates (d)	0/10 (0%)	4/29 (14%)	0/11 (0%)	
Life Table Test (e)		P=0.097	P=0.069	P=0.345
Incidental Tumor Test (e)		P=0.079	P=0.048	P=0.354
Fisher Exact Test (e)		P=0.065	P=0.050	P=0.397
Thyroid: Follicular Cell Adenoma or Carcinoma				
Overall Rates (b)	7/87 (8%)	27/248 (11%)	13/100 (13%)	
Adjusted Rates (c)	41.4%	38.7%	33.3%	
Terminal Rates (d)	3/10 (30%)	6/29 (21%)	0/11 (0%)	
Life Table Test (e)		P=0.362	P=0.219	P=0.288
Incidental Tumor Test (e)		P=0.311	P=0.167	P=0.330
Fisher Exact Test (e)		P=0.299	P=0.197	P=0.348
Thyroid: C-Cell Adenoma				
Overall Rates (b)	11/87 (13%)	26/248 (10%)	20/100 (20%)	
Adjusted Rates (c)	58.3%	40.1%	52.0%	
Terminal Rates (d)	5/10 (50%)	8/29 (28%)	2/11 (18%)	
Life Table Test (e)		P=0.281N	P=0.130	P=0.009
Incidental Tumor Test (e)		P=0.341N	P=0.093	P=0.012
Fisher Exact Test (e)		P=0.354N	P=0.124	P=0.016
Thyroid: C-Cell Carcinoma				
Overall Rates (b)	11/87 (13%)	41/248 (17%)	12/100 (12%)	
Adjusted Rates (c)	34.6%	47.4%	52.7%	
Terminal Rates (d)	2/10 (20%)	6/29 (21%)	4/11 (36%)	
Life Table Test (e)		P=0.320	P=0.547N	P=0.272N
Incidental Tumor Test (e)		P=0.219	P=0.554N	P=0.191N
Fisher Exact Test (e)		P=0.249	P=0.534N	P=0.185N
Thyroid: C-Cell Adenoma or Carcinoma				
Overall Rates (b)	21/87 (24%)	65/248 (26%)	30/100 (30%)	
Adjusted Rates (c)	72.7%	71.0%	79.5%	
Terminal Rates (d)	6/10 (60%)	14/29 (48%)	6/11 (55%)	
Life Table Test (e)		P=0.518	P=0.236	P=0.186
Incidental Tumor Test (e)		P=0.386	P=0.184	P=0.246
Fisher Exact Test (e)		P=0.410	P=0.232	P=0.277

HWBUI0001810

TABLE E4. ANALYSIS OF PRIMARY TUMORS IN FEMALE RATS IN THE LIFETIME FEED STUDY OF INTERMEDIATE-RANGE CHRYSOTILE ASBESTOS (Continued)

	CONTROL (UNTR)	IR (a)	IR/PW	IR vs IR/PW
Pancreatic Islets: Islet Cell Adenoma or Carcinoma				
Overall Rates (b)	6/87 (7%)	13/249 (5%)	7/99 (7%)	
Adjusted Rates (c)	13.9%	22.7%	23.6%	
Terminal Rates (d)	0/10 (0%)	3/29 (10%)	0/11 (0%)	
Life Table Test (e)		P=0.315N	P=0.604	P=0.279
Incidental Tumor Test (e)		P=0.382N	P=0.565	P=0.304
Fisher Exact Test (e)		P=0.365N	P=0.597	P=0.330
Mammary Gland: Adenoma				
Overall Rates (b)	6/88 (7%)	21/250 (8%)	11/100 (11%)	
Adjusted Rates (c)	22.4%	31.3%	32.0%	
Terminal Rates (d)	0/10 (0%)	6/29 (21%)	1/11 (9%)	
Life Table Test (e)		P=0.465	P=0.248	P=0.244
Incidental Tumor Test (e)		P=0.377	P=0.203	P=0.279
Fisher Exact Test (e)		P=0.416	P=0.230	P=0.283
Mammary Gland: Fibroadenoma				
Overall Rates (b)	49/88 (56%)	128/250 (51%)	58/100 (58%)	
Adjusted Rates (c)	100.0%	92.0%	93.9%	
Terminal Rates (d)	10/10 (100%)	21/29 (72%)	8/11 (73%)	
Life Table Test (e)		P=0.209N	P=0.445	P=0.123
Incidental Tumor Test (e)		P=0.318N	P=0.322	P=0.110
Fisher Exact Test (e)		P=0.275N	P=0.431	P=0.151
Mammary Gland: Adenocarcinoma				
Overall Rates (b)	5/88 (6%)	9/250 (4%)	4/100 (4%)	
Adjusted Rates (c)	15.7%	21.2%	12.7%	
Terminal Rates (d)	0/10 (0%)	4/29 (14%)	1/11 (9%)	
Life Table Test (e)		P=0.248N	P=0.435N	P=0.504
Incidental Tumor Test (e)		P=0.286N	P=0.421N	P=0.532
Fisher Exact Test (e)		P=0.287N	P=0.420N	P=0.536
Clitoral Gland: Carcinoma or Squamous Cell Carcinoma				
Overall Rates (b)	1/88 (1%)	18/250 (7%)	4/100 (4%)	
Adjusted Rates (c)	3.2%	26.1%	12.6%	
Terminal Rates (d)	0/10 (0%)	5/29 (17%)	0/11 (0%)	
Life Table Test (e)		P=0.037	P=0.214	P=0.218N
Incidental Tumor Test (e)		P=0.031	P=0.247	P=0.186N
Fisher Exact Test (e)		P=0.022	P=0.227	P=0.195N
Uterus: Endometrial Stromal Polyp				
Overall Rates (b)	13/87 (15%)	22/249 (9%)	10/99 (10%)	
Adjusted Rates (c)	37.4%	31.4%	30.2%	
Terminal Rates (d)	1/10 (10%)	6/29 (21%)	0/11 (0%)	
Life Table Test (e)		P=0.070N	P=0.231N	P=0.375
Incidental Tumor Test (e)		P=0.078N	P=0.227N	P=0.385
Fisher Exact Test (e)		P=0.084N	P=0.219N	P=0.426

(a) Administered 1% intermediate-range (IR) chrysotile asbestos in the diet
(b) Number of tumor-bearing animals/number of animals examined at the site
(c) Kaplan-Meier estimated tumor incidence at the end of the study after adjusting for intercurrent mortality
(d) Observed tumor incidence at terminal kill
(e) Beneath the dosed group incidence are the P values corresponding to pairwise comparisons between that dosed group and the controls. The pairwise comparison between the dosed groups is in the final column. The life table analysis regards tumors in animals dying prior to terminal kill as being (directly or indirectly) the cause of death. The incidental tumor test regards these lesions as nonfatal. The Fisher exact test compares directly the overall incidence rates. A lower incidence in a dosed group than in the controls or in the IR plus preweaning gavage than the IR group is indicated by (N).

HWBUI0001811

TABLE E5. ANALYSIS OF PRIMARY TUMORS IN MALE RATS IN THE LIFETIME FEED STUDY OF INTERMEDIATE-RANGE CHRYSOTILE ASBESTOS PLUS 1,2-DIMETHYLHYDRAZINE DIHYDROCHLORIDE

	CONTROL (UNTR)	DMH (a)	IR + DMH (b)	DMH vs IR + DMH
Skin: Papilloma or Squamous Cell Papilloma				
Overall Rates (c)	5/88 (6%)	2/125 (2%)	4/175 (2%)	
Adjusted Rates (d)	16.8%	11.1%	13.9%	
Terminal Rates (e)	4/26 (15%)	2/18 (11%)	2/18 (11%)	
Life Table Test (f)		P=0.373N	P=0.621N	P=0.378
Incidental Tumor Test (f)		P=0.358N	P=0.499N	P=0.396
Fisher Exact Test (f)		P=0.106N	P=0.143N	P=0.509
Skin: Keratoacanthoma				
Overall Rates (c)	1/88 (1%)	6/125 (5%)	11/175 (6%)	
Adjusted Rates (d)	3.2%	24.2%	30.0%	
Terminal Rates (e)	0/26 (0%)	4/18 (22%)	1/18 (6%)	
Life Table Test (f)		P=0.028	P=0.002	P=0.240
Incidental Tumor Test (f)		P=0.070	P=0.018	P=0.356
Fisher Exact Test (f)		P=0.138	P=0.049	P=0.389
Subcutaneous Tissue: Fibroma				
Overall Rates (c)	17/88 (19%)	13/125 (10%)	15/175 (9%)	
Adjusted Rates (d)	33.8%	38.7%	43.7%	
Terminal Rates (e)	3/26 (12%)	5/18 (28%)	5/18 (28%)	
Life Table Test (f)		P=0.502N	P=0.508N	P=0.573
Incidental Tumor Test (f)		P=0.134N	P=0.094N	P=0.455N
Fisher Exact Test (f)		P=0.052N	P=0.012N	P=0.366N
Subcutaneous Tissue: Fibrosarcoma				
Overall Rates (c)	7/88 (8%)	3/125 (2%)	2/175 (1%)	
Adjusted Rates (d)	17.0%	5.2%	6.3%	
Terminal Rates (e)	1/26 (4%)	0/18 (0%)	1/18 (6%)	
Life Table Test (f)		P=0.258N	P=0.113N	P=0.416N
Incidental Tumor Test (f)		P=0.096N	P=0.023N	P=0.379N
Fisher Exact Test (f)		P=0.061N	P=0.008N	P=0.346N
Subcutaneous Tissue: Fibroma or Fibrosarcoma				
Overall Rates (c)	23/88 (26%)	16/125 (13%)	17/175 (10%)	
Adjusted Rates (d)	44.1%	41.9%	48.4%	
Terminal Rates (e)	4/26 (15%)	5/18 (28%)	6/18 (33%)	
Life Table Test (f)		P=0.363N	P=0.286N	P=0.471N
Incidental Tumor Test (f)		P=0.042N	P=0.014N	P=0.335N
Fisher Exact Test (f)		P=0.012N	P=0.001N	P=0.255N
Hematopoietic System: Leukemia				
Overall Rates (c)	31/88 (35%)	42/125 (34%)	71/175 (41%)	
Adjusted Rates (d)	60.4%	68.9%	76.6%	
Terminal Rates (e)	10/26 (38%)	6/18 (33%)	5/18 (28%)	
Life Table Test (f)		P=0.016	P<0.001	P=0.076
Incidental Tumor Test (f)		P=0.181	P=0.065	P=0.172
Fisher Exact Test (f)		P=0.460N	P=0.241	P=0.134
Liver: Neoplastic Nodule				
Overall Rates (c)	6/85 (7%)	12/125 (10%)	10/175 (6%)	
Adjusted Rates (d)	17.5%	33.4%	20.3%	
Terminal Rates (e)	3/26 (12%)	3/18 (17%)	2/18 (11%)	
Life Table Test (f)		P=0.039	P=0.211	P=0.249N
Incidental Tumor Test (f)		P=0.105	P=0.500	P=0.155N
Fisher Exact Test (f)		P=0.351	P=0.431N	P=0.148N
Liver: Hepatocellular Carcinoma				
Overall Rates (c)	2/85 (2%)	17/125 (14%)	20/175 (11%)	
Adjusted Rates (d)	5.8%	38.3%	41.1%	
Terminal Rates (e)	1/26 (4%)	3/18 (17%)	3/18 (17%)	
Life Table Test (f)		P<0.001	P<0.001	P=0.528N
Incidental Tumor Test (f)		P<0.001	P<0.003	P=0.336N
Fisher Exact Test (f)		P=0.003	P=0.009	P=0.348N

HWBUI0001812

TABLE E5. ANALYSIS OF PRIMARY TUMORS IN MALE RATS IN THE LIFETIME FEED STUDY OF INTERMEDIATE-RANGE CHRYSOTILE ASBESTOS PLUS 1,2-DIMETHYLHYDRAZINE DIHYDROCHLORIDE (Continued)

	CONTROL (UNTR)	DMH (a)	IR + DMH (b)	DMH vs IR + DMH
Liver: Neoplastic Nodule or Hepatocellular Carcinoma				
Overall Rates (c)	8/85 (9%)	27/125 (22%)	29/175 (17%)	
Adjusted Rates (d)	22.8%	59.5%	50.7%	
Terminal Rates (e)	4/26 (15%)	6/18 (33%)	4/18 (22%)	
Life Table Test (f)		P<0.001	P<0.001	P=0.372N
Incidental Tumor Test (f)		P<0.001	P<0.016	P=0.159N
Fisher Exact Test (f)		P=0.014	P=0.084	P=0.171N
Pancreas: Acinar Cell Adenoma				
Overall Rates (c)	3/85 (4%)	7/124 (6%)	14/174 (8%)	
Adjusted Rates (d)	11.5%	28.9%	35.1%	
Terminal Rates (e)	3/26 (12%)	4/18 (22%)	3/18 (17%)	
Life Table Test (f)		P=0.059	P=0.003	P=0.148
Incidental Tumor Test (f)		P=0.073	P=0.026	P=0.237
Fisher Exact Test (f)		P=0.362	P=0.131	P=0.288
Large Intestine: Adenomatous Polyp				
Overall Rates (c)	0/85 (0%)	31/125 (25%)	45/175 (26%)	
Adjusted Rates (d)	0.0%	45.0%	45.7%	
Terminal Rates (e)	0/26 (0%)	2/18 (11%)	1/18 (6%)	
Life Table Test (f)		P<0.001	P<0.001	P=0.376
Incidental Tumor Test (f)		P<0.001	P<0.001	P=0.479
Fisher Exact Test (f)		P<0.001	P<0.001	P=0.483
Large Intestine: Mucinous Cystadenocarcinoma				
Overall Rates (c)	0/85 (0%)	7/125 (6%)	19/175 (11%)	
Adjusted Rates (d)	0.0%	9.5%	19.9%	
Terminal Rates (e)	0/26 (0%)	0/18 (0%)	0/18 (0%)	
Life Table Test (f)		P=0.016	P<0.001	P=0.077
Incidental Tumor Test (f)		P=0.125	P=0.019	P=0.085
Fisher Exact Test (f)		P=0.025	P<0.001	P=0.081
Large Intestine: Adenocarcinoma or Mucinous Cystadenocarcinoma				
Overall Rates (c)	0/85 (0%)	9/125 (7%)	20/175 (11%)	
Adjusted Rates (d)	0.0%	11.7%	20.5%	
Terminal Rates (e)	0/26 (0%)	0/18 (0%)	0/18 (0%)	
Life Table Test (f)		P=0.006	P<0.001	P=0.142
Incidental Tumor Test (f)		P=0.090	P=0.017	P=0.156
Fisher Exact Test (f)		P=0.008	P<0.001	P=0.153
Large Intestine: Adenomatous Polyp, Adenocarcinoma, or Mucinous Cystadenocarcinoma				
Overall Rates (c)	0/85 (0%)	40/125 (32%)	62/175 (35%)	
Adjusted Rates (d)	0.0%	51.5%	54.4%	
Terminal Rates (e)	0/26 (0%)	2/18 (11%)	1/18 (6%)	
Life Table Test (f)		P<0.001	P<0.001	P=0.248
Incidental Tumor Test (f)		P<0.001	P<0.001	P=0.326
Fisher Exact Test (f)		P<0.001	P<0.001	P=0.311
Pituitary: Adenoma				
Overall Rates (c)	14/85 (16%)	12/124 (10%)	16/175 (9%)	
Adjusted Rates (d)	35.3%	39.8%	48.0%	
Terminal Rates (e)	6/26 (23%)	5/18 (28%)	6/18 (33%)	
Life Table Test (f)		P=0.463	P=0.266	P=0.402
Incidental Tumor Test (f)		P=0.487N	P=0.564N	P=0.566
Fisher Exact Test (f)		P=0.107N	P=0.066N	P=0.514N
Pituitary: Adenoma or Carcinoma				
Overall Rates (c)	18/85 (21%)	15/124 (12%)	17/175 (10%)	
Adjusted Rates (d)	40.2%	44.5%	50.1%	
Terminal Rates (e)	6/26 (23%)	5/18 (28%)	6/18 (33%)	
Life Table Test (f)		P=0.492	P=0.477	P=0.564N
Incidental Tumor Test (f)		P=0.365N	P=0.260N	P=0.374N
Fisher Exact Test (f)		P=0.059N	P=0.012N	P=0.318N

HWBUI0001813

TABLE E5. ANALYSIS OF PRIMARY TUMORS IN MALE RATS IN THE LIFETIME FEED STUDY OF INTERMEDIATE-RANGE CHRYSOTILE ASBESTOS PLUS 1,2-DIMETHYLHYDRAZINE DIHYDROCHLORIDE (Continued)

	CONTROL (UNTR)	DMH (a)	IR + DMH (b)	DMH vs IR + DMH
Adrenal: Pheochromocytoma				
Overall Rates (c)	16/85 (19%)	20/125 (16%)	34/175 (19%)	
Adjusted Rates (d)	41.6%	59.9%	68.5%	
Terminal Rates (e)	8/26 (31%)	9/18 (50%)	8/18 (44%)	
Life Table Test (f)		P=0.085	P=0.002	P=0.102
Incidental Tumor Test (f)		P=0.239	P=0.050	P=0.204
Fisher Exact Test (f)		P=0.362N	P=0.525	P=0.272
Adrenal: Pheochromocytoma or Pheochromocytoma, Malignant				
Overall Rates (c)	17/85 (20%)	20/125 (16%)	34/175 (19%)	
Adjusted Rates (d)	43.4%	59.9%	68.5%	
Terminal Rates (e)	8/26 (31%)	9/18 (50%)	8/18 (44%)	
Life Table Test (f)		P=0.115	P=0.003	P=0.102
Incidental Tumor Test (f)		P=0.306	P=0.078	P=0.204
Fisher Exact Test (f)		P=0.286N	P=0.519N	P=0.272
Thyroid: Follicular Cell Adenoma				
Overall Rates (c)	1/84 (1%)	1/124 (1%)	14/175 (8%)	
Adjusted Rates (d)	2.1%	2.8%	28.5%	
Terminal Rates (e)	0/26 (0%)	0/18 (0%)	2/18 (11%)	
Life Table Test (f)		P=0.720	P=0.001	P=0.003
Incidental Tumor Test (f)		P=0.752	P=0.011	P=0.006
Fisher Exact Test (f)		P=0.646N	P=0.020	P=0.003
Thyroid: Follicular Cell Carcinoma				
Overall Rates (c)	5/84 (6%)	8/124 (6%)	14/175 (8%)	
Adjusted Rates (d)	13.1%	29.9%	19.7%	
Terminal Rates (e)	2/26 (8%)	4/18 (22%)	0/18 (0%)	
Life Table Test (f)		P=0.130	P=0.045	P=0.299
Incidental Tumor Test (f)		P=0.171	P=0.246	P=0.403
Fisher Exact Test (f)		P=0.564	P=0.377	P=0.394
Thyroid: Follicular Cell Adenoma or Carcinoma				
Overall Rates (c)	6/84 (7%)	9/124 (7%)	28/175 (16%)	
Adjusted Rates (d)	14.9%	31.8%	42.7%	
Terminal Rates (e)	2/26 (8%)	4/18 (22%)	2/18 (11%)	
Life Table Test (f)		P=0.138	P<0.001	P=0.010
Incidental Tumor Test (f)		P=0.184	P=0.009	P=0.020
Fisher Exact Test (f)		P=0.600	P=0.034	P=0.017
Thyroid: C-Cell Adenoma				
Overall Rates (c)	13/84 (15%)	11/124 (9%)	18/175 (10%)	
Adjusted Rates (d)	33.6%	22.4%	31.9%	
Terminal Rates (e)	6/26 (23%)	2/18 (11%)	1/18 (6%)	
Life Table Test (f)		P=0.576	P=0.225	P=0.291
Incidental Tumor Test (f)		P=0.184N	P=0.461N	P=0.431
Fisher Exact Test (f)		P=0.108N	P=0.159N	P=0.421
Thyroid: C-Cell Carcinoma				
Overall Rates (c)	19/84 (23%)	15/124 (12%)	21/175 (12%)	
Adjusted Rates (d)	42.4%	38.3%	44.6%	
Terminal Rates (e)	6/26 (23%)	3/18 (17%)	3/18 (17%)	
Life Table Test (f)		P=0.559N	P=0.361	P=0.385
Incidental Tumor Test (f)		P=0.184N	P=0.124N	P=0.538N
Fisher Exact Test (f)		P=0.035N	P=0.024N	P=0.559N
Thyroid: C-Cell Adenoma or Carcinoma				
Overall Rates (c)	30/84 (36%)	25/124 (20%)	37/175 (21%)	
Adjusted Rates (d)	60.3%	52.4%	61.5%	
Terminal Rates (e)	10/26 (38%)	5/18 (28%)	4/18 (22%)	
Life Table Test (f)		P=0.529	P=0.183	P=0.258
Incidental Tumor Test (f)		P=0.069N	P=0.134N	P=0.499
Fisher Exact Test (f)		P=0.011N	P=0.011N	P=0.477

HWBUI0001814

TABLE E5. ANALYSIS OF PRIMARY TUMORS IN MALE RATS IN THE LIFETIME FEED STUDY OF INTERMEDIATE-RANGE CHRYSOTILE ASBESTOS PLUS 1,2-DIMETHYLHYDRAZINE DIHYDROCHLORIDE (Continued)

	CONTROL (UNTR)	DMH (a)	IR + DMH (b)	DMH vs IR + DMH
Pancreatic Islets: Islet Cell Adenoma				
Overall Rates (c)	5/85 (6%)	1/124 (1%)	5/174 (3%)	
Adjusted Rates (d)	12.7%	5.6%	18.2%	
Terminal Rates (e)	2/26 (8%)	1/18 (6%)	2/18 (11%)	
Life Table Test (f)		P=0.166N	P=0.532	P=0.123
Incidental Tumor Test (f)		P=0.091N	P=0.489N	P=0.164
Fisher Exact Test (f)		P=0.042N	P=0.199N	P=0.206
Pancreatic Islets: Islet Cell Adenoma or Carcinoma				
Overall Rates (c)	8/85 (9%)	7/124 (6%)	9/174 (5%)	
Adjusted Rates (d)	18.9%	28.7%	30.8%	
Terminal Rates (e)	3/26 (12%)	4/18 (22%)	3/18 (17%)	
Life Table Test (f)		P=0.509	P=0.381	P=0.468
Incidental Tumor Test (f)		P=0.577N	P=0.521N	P=0.602N
Fisher Exact Test (f)		P=0.221N	P=0.153N	P=0.527N
Preputial Gland: Carcinoma				
Overall Rates (c)	3/88 (3%)	7/125 (6%)	10/175 (6%)	
Adjusted Rates (d)	7.1%	13.6%	15.6%	
Terminal Rates (e)	0/26 (0%)	0/18 (0%)	0/18 (0%)	
Life Table Test (f)		P=0.114	P=0.066	P=0.506
Incidental Tumor Test (f)		P=0.320	P=0.330	P=0.569N
Fisher Exact Test (f)		P=0.346	P=0.313	P=0.588
Preputial Gland: Adenoma or Carcinoma				
Overall Rates (c)	4/88 (5%)	7/125 (6%)	10/175 (6%)	
Adjusted Rates (d)	10.6%	13.6%	15.6%	
Terminal Rates (e)	1/26 (4%)	0/18 (0%)	0/18 (0%)	
Life Table Test (f)		P=0.183	P=0.110	P=0.506
Incidental Tumor Test (f)		P=0.429	P=0.431	P=0.569N
Fisher Exact Test (f)		P=0.496	P=0.469	P=0.588
Testis: Interstitial Cell Tumor				
Overall Rates (c)	79/84 (94%)	112/125 (90%)	160/175 (91%)	
Adjusted Rates (d)	100.0%	100.0%	100.0%	
Terminal Rates (e)	26/26 (100%)	18/18 (100%)	18/18 (100%)	
Life Table Test (f)		P<0.001	P<0.001	P=0.149
Incidental Tumor Test (f)		P=0.284	P=0.055	P=0.344
Fisher Exact Test (f)		P=0.193N	P=0.320N	P=0.366
Testis: Interstitial Cell Tumor or Interstitial Cell Tumor, Malignant				
Overall Rates (c)	79/84 (94%)	113/125 (90%)	160/175 (91%)	
Adjusted Rates (d)	100.0%	100.0%	100.0%	
Terminal Rates (e)	26/26 (100%)	18/18 (100%)	18/18 (100%)	
Life Table Test (f)		P<0.001	P<0.001	P=0.168
Incidental Tumor Test (f)		P=0.236	P=0.055	P=0.463
Fisher Exact Test (f)		P=0.249N	P=0.320N	P=0.455
Zymbal Gland: Squamous Cell Carcinoma				
Overall Rates (c)	1/88 (1%)	15/125 (12%)	22/175 (13%)	
Adjusted Rates (d)	2.5%	25.3%	28.6%	
Terminal Rates (e)	0/26 (0%)	1/18 (6%)	1/18 (6%)	
Life Table Test (f)		P<0.001	P<0.001	P=0.433
Incidental Tumor Test (f)		P=0.011	P=0.007	P=0.555
Fisher Exact Test (f)		P=0.002	P<0.001	P=0.515
Zymbal Gland: Squamous Cell Papilloma or Carcinoma				
Overall Rates (c)	1/88 (1%)	16/125 (13%)	25/175 (14%)	
Adjusted Rates (d)	2.5%	25.9%	33.9%	
Terminal Rates (e)	0/26 (0%)	1/18 (6%)	2/18 (11%)	
Life Table Test (f)		P<0.001	P<0.001	P=0.344
Incidental Tumor Test (f)		P=0.010	P=0.003	P=0.458
Fisher Exact Test (f)		P=0.001	P<0.001	P=0.424

HWBUI0001815

TABLE E5. ANALYSIS OF PRIMARY TUMORS IN MALE RATS IN THE LIFETIME FEED STUDY OF INTERMEDIATE-RANGE CHRYSOTILE ASBESTOS PLUS 1,2-DIMETHYLHYDRAZINE DIHYDROCHLORIDE (Continued)

	CONTROL (UNTR)	DMH (a)	IR + DMH (b)	DMH vs IR + DMH
Zymbal Gland: Carcinoma				
Overall Rates (c)	2/88 (2%)	18/125 (14%)	24/175 (14%)	
Adjusted Rates (d)	4.5%	27.9%	30.0%	
Terminal Rates (e)	0/26 (0%)	1/18 (6%)	1/18 (6%)	
Life Table Test (f)		P<0.001	P<0.001	P=0.547
Incidental Tumor Test (f)		P=0.016	P=0.013	P=0.454N
Fisher Exact Test (f)		P=0.002	P=0.002	P=0.497N
Zymbal Gland: Papilloma or Carcinoma				
Overall Rates (c)	2/88 (2%)	19/125 (15%)	27/175 (15%)	
Adjusted Rates (d)	4.5%	28.5%	35.1%	
Terminal Rates (e)	0/26 (0%)	1/18 (6%)	2/18 (11%)	
Life Table Test (f)		P<0.001	P<0.001	P=0.454
Incidental Tumor Test (f)		P=0.014	P=0.005	P=0.547N
Fisher Exact Test (f)		P=0.001	P<0.001	P=0.545
All Sites: Mesothelioma				
Overall Rates (c)	4/88 (5%)	6/125 (5%)	7/175 (4%)	
Adjusted Rates (d)	7.6%	17.1%	8.2%	
Terminal Rates (e)	0/26 (0%)	1/18 (6%)	0/18 (0%)	
Life Table Test (f)		P=0.274	P=0.408	P=0.552N
Incidental Tumor Test (f)		P=0.562	P=0.289N	P=0.470N
Fisher Exact Test (f)		P=0.601	P=0.533N	P=0.475N

(a) Administered 1,2-dimethylhydrazine dihydrochloride (DMH) by gavage
(b) Administered 1% intermediate-range (IR) chrysotile asbestos in the diet and DMH by gavage
(c) Number of tumor-bearing animals/number of animals examined at the site
(d) Kaplan-Meier estimated tumor incidence at the end of the study after adjusting for intercurrent mortality
(e) Observed tumor incidence at terminal kill
(f) Beneath the dosed group incidence are the P values corresponding to pairwise comparisons between that dosed group and the controls. The pairwise comparison between the dosed groups is in the final column. The life table analysis regards tumors in animals dying prior to terminal kill as being (directly or indirectly) the cause of death. The incidental tumor test regards these lesions as nonfatal. The Fisher exact test compares directly the overall incidence rates. A lower incidence in a dosed group than in the controls or in the IR plus DMH group than in the DMH group is indicated by (N).

HWBUI0001816

TABLE E6. ANALYSIS OF PRIMARY TUMORS IN FEMALE RATS IN THE LIFETIME FEED STUDY OF INTERMEDIATE-RANGE CHRYSOTILE ASBESTOS PLUS 1,2-DIMETHYLHYDRAZINE DIHYDROCHLORIDE

	CONTROL (UNTR)	DMH (a)	IR + DMH (b)	DMH vs IR + DMH
Subcutaneous Tissue: Fibroma				
Overall Rates (c)	5/88 (6%)	2/125 (2%)	1/175 (1%)	
Adjusted Rates (d)	9.1%	8.3%	0.8%	
Terminal Rates (e)	5/55 (9%)	0/16 (0%)	0/27 (0%)	
Life Table Test (f)		P=0.567	P=0.258N	P=0.347N
Incidental Tumor Test (f)		P=0.619N	P=0.182N	P=0.340N
Fisher Exact Test (f)		P=0.106N	P=0.018N	P=0.376N
Subcutaneous Tissue: Fibroma or Fibrosarcoma				
Overall Rates (c)	6/88 (7%)	3/125 (2%)	2/175 (1%)	
Adjusted Rates (d)	10.9%	10.6%	1.8%	
Terminal Rates (e)	6/55 (11%)	0/16 (0%)	0/27 (0%)	
Life Table Test (f)		P=0.428	P=0.315N	P=0.308N
Incidental Tumor Test (f)		P=0.593N	P=0.172N	P=0.353N
Fisher Exact Test (f)		P=0.110N	P=0.019N	P=0.346N
Hematopoietic System: Leukemia				
Overall Rates (c)	34/88 (39%)	70/125 (56%)	93/175 (53%)	
Adjusted Rates (d)	51.5%	86.1%	85.8%	
Terminal Rates (e)	24/55 (44%)	8/16 (50%)	15/27 (56%)	
Life Table Test (f)		P<0.001	P<0.001	P=0.175N
Incidental Tumor Test (f)		P=0.002	P<0.001	P=0.347N
Fisher Exact Test (f)		P=0.009	P=0.018	P=0.355N
Liver: Neoplastic Nodule				
Overall Rates (c)	3/87 (3%)	12/125 (10%)	21/175 (12%)	
Adjusted Rates (d)	5.2%	33.5%	32.4%	
Terminal Rates (e)	2/55 (4%)	3/16 (19%)	3/27 (11%)	
Life Table Test (f)		P<0.001	P<0.001	P=0.446
Incidental Tumor Test (f)		P=0.027	P=0.017	P=0.319
Fisher Exact Test (f)		P=0.071	P=0.016	P=0.322
Liver: Hepatocellular Carcinoma				
Overall Rates (c)	1/87 (1%)	12/125 (10%)	19/175 (11%)	
Adjusted Rates (d)	1.8%	36.2%	38.3%	
Terminal Rates (e)	1/55 (2%)	3/16 (19%)	7/27 (26%)	
Life Table Test (f)		P<0.001	P<0.001	P=0.572
Incidental Tumor Test (f)		P=0.002	P<0.001	P=0.505
Fisher Exact Test (f)		P=0.009	P=0.003	P=0.439
Liver: Neoplastic Nodule or Hepatocellular Carcinoma				
Overall Rates (c)	4/87 (5%)	22/125 (18%)	38/175 (22%)	
Adjusted Rates (d)	7.0%	54.2%	57.4%	
Terminal Rates (e)	3/55 (5%)	5/16 (31%)	9/27 (33%)	
Life Table Test (f)		P<0.001	P<0.001	P=0.406
Incidental Tumor Test (f)		P<0.001	P<0.001	P=0.258
Fisher Exact Test (f)		P=0.003	P<0.001	P=0.233
Large Intestine: Adenomatous Polyp				
Overall Rates (c)	0/87 (0%)	33/125 (26%)	46/175 (26%)	
Adjusted Rates (d)	0.0%	71.0%	53.3%	
Terminal Rates (e)	0/55 (0%)	8/16 (50%)	6/27 (22%)	
Life Table Test (f)		P<0.001	P<0.001	P=0.390N
Incidental Tumor Test (f)		P<0.001	P<0.001	P=0.531
Fisher Exact Test (f)		P<0.001	P<0.001	P=0.543N
Large Intestine: Mucinous Cystadenocarcinoma				
Overall Rates (c)	0/87 (0%)	14/125 (11%)	16/175 (9%)	
Adjusted Rates (d)	0.0%	20.9%	19.3%	
Terminal Rates (e)	0/55 (0%)	1/16 (6%)	2/27 (7%)	
Life Table Test (f)		P<0.001	P<0.001	P=0.327N
Incidental Tumor Test (f)		P=0.055	P=0.036	P=0.305N
Fisher Exact Test (f)		P<0.001	P=0.001	P=0.346N

HWBUI0001817

TABLE E6. ANALYSIS OF PRIMARY TUMORS IN FEMALE RATS IN THE LIFETIME FEED STUDY OF INTERMEDIATE-RANGE CHRYSOTILE ASBESTOS PLUS 1,2-DIMETHYLHYDRAZINE DIHYDROCHLORIDE (Continued)

	CONTROL (UNTR)	DMH (a)	IR + DMH (b)	DMH vs IR + DMH
Large Intestine: Adenocarcinoma or Mucinous Cystadenocarcinoma				
Overall Rates (c)	0/87 (0%)	15/125 (12%)	19/175 (11%)	
Adjusted Rates (d)	0.0%	21.6%	24.5%	
Terminal Rates (e)	0/55 (0%)	1/16 (6%)	3/27 (11%)	
Life Table Test (f)		P<0.001	P<0.001	P=0.410N
Incidental Tumor Test (f)		P=0.055	P=0.009	P=0.396N
Fisher Exact Test (f)		P<0.001	P<0.001	P=0.448N
Large Intestine: Adenomatous Polyp, Adenocarcinoma, or Mucinous Cystadenocarcinoma				
Overall Rates (c)	0/87 (0%)	46/125 (37%)	61/175 (35%)	
Adjusted Rates (d)	0.0%	74.8%	62.7%	
Terminal Rates (e)	0/55 (0%)	8/16 (50%)	8/27 (30%)	
Life Table Test (f)		P<0.001	P<0.001	P=0.291N
Incidental Tumor Test (f)		P<0.001	P<0.001	P=0.435N
Fisher Exact Test (f)		P<0.001	P<0.001	P=0.411N
Kidney: Mixed Tumor, Malignant				
Overall Rates (c)	0/87 (0%)	13/125 (10%)	34/175 (19%)	
Adjusted Rates (d)	0.0%	21.8%	30.0%	
Terminal Rates (e)	0/55 (0%)	1/16 (6%)	0/27 (0%)	
Life Table Test (f)		P<0.001	P<0.001	P=0.043
Incidental Tumor Test (f)		P=0.073	P=0.022	P=0.021
Fisher Exact Test (f)		P<0.001	P<0.001	P=0.023
Pituitary: Adenoma				
Overall Rates (c)	49/87 (56%)	31/124 (25%)	51/173 (29%)	
Adjusted Rates (d)	68.5%	60.6%	80.5%	
Terminal Rates (e)	33/55 (60%)	4/16 (25%)	18/27 (67%)	
Life Table Test (f)		P=0.054	P=0.005	P=0.472
Incidental Tumor Test (f)		P=0.009N	P=0.225N	P=0.337
Fisher Exact Test (f)		P<0.001N	P<0.001N	P=0.236
Pituitary: Carcinoma				
Overall Rates (c)	4/87 (5%)	1/124 (1%)	1/173 (1%)	
Adjusted Rates (d)	6.7%	6.2%	1.3%	
Terminal Rates (e)	3/55 (5%)	1/16 (6%)	0/27 (0%)	
Life Table Test (f)		P=0.601N	P=0.336N	P=0.642N
Incidental Tumor Test (f)		P=0.398N	P=0.104N	P=0.685N
Fisher Exact Test (f)		P=0.094N	P=0.045N	P=0.662N
Pituitary: Adenoma or Carcinoma				
Overall Rates (c)	53/87 (61%)	32/124 (26%)	52/173 (30%)	
Adjusted Rates (d)	73.2%	63.9%	80.8%	
Terminal Rates (e)	36/55 (65%)	5/16 (31%)	18/27 (67%)	
Life Table Test (f)		P=0.064	P=0.011	P=0.497
Incidental Tumor Test (f)		P=0.004N	P=0.095N	P=0.355
Fisher Exact Test (f)		P<0.001N	P<0.001N	P=0.251
Adrenal: Pheochromocytoma				
Overall Rates (c)	8/87 (9%)	6/124 (5%)	8/175 (5%)	
Adjusted Rates (d)	14.2%	19.2%	18.0%	
Terminal Rates (e)	7/55 (13%)	1/16 (6%)	2/27 (7%)	
Life Table Test (f)		P=0.149	P=0.215	P=0.449N
Incidental Tumor Test (f)		P=0.588	P=0.612	P=0.505N
Fisher Exact Test (f)		P=0.166N	P=0.117N	P=0.562N
Adrenal: Pheochromocytoma or Pheochromocytoma, Malignant				
Overall Rates (c)	10/87 (11%)	7/124 (6%)	9/175 (5%)	
Adjusted Rates (d)	17.8%	20.5%	21.2%	
Terminal Rates (e)	9/55 (16%)	1/16 (6%)	3/27 (11%)	
Life Table Test (f)		P=0.156	P=0.228	P=0.407N
Incidental Tumor Test (f)		P=0.589N	P=0.602	P=0.471N
Fisher Exact Test (f)		P=0.101N	P=0.057N	P=0.523N

HWBUI0001818

TABLE E6. ANALYSIS OF PRIMARY TUMORS IN FEMALE RATS IN THE LIFETIME FEED STUDY OF INTERMEDIATE-RANGE CHRYSOTILE ASBESTOS PLUS 1,2-DIMETHYLHYDRAZINE DIHYDROCHLORIDE (Continued)

	CONTROL (UNTR)	DMH (a)	IR + DMH (b)	DMH vs IR + DMH
Thyroid: Follicular Cell Adenoma				
Overall Rates (c)	6/87 (7%)	7/124 (6%)	9/174 (5%)	
Adjusted Rates (d)	10.9%	24.4%	18.6%	
Terminal Rates (e)	6/55 (11%)	3/16 (19%)	3/27 (11%)	
Life Table Test (f)		P=0.036	P=0.086	P=0.424N
Incidental Tumor Test (f)		P=0.206	P=0.314	P=0.533N
Fisher Exact Test (f)		P=0.462N	P=0.379N	P=0.527N
Thyroid: Follicular Cell Carcinoma				
Overall Rates (c)	1/87 (1%)	5/124 (4%)	7/174 (4%)	
Adjusted Rates (d)	1.8%	14.4%	14.0%	
Terminal Rates (e)	1/55 (2%)	1/16 (6%)	2/27 (7%)	
Life Table Test (f)		P=0.015	P=0.014	P=0.541N
Incidental Tumor Test (f)		P=0.150	P=0.081	P=0.558N
Fisher Exact Test (f)		P=0.211	P=0.191	P=0.610N
Thyroid: Follicular Cell Adenoma or Carcinoma				
Overall Rates (c)	7/87 (8%)	12/124 (10%)	16/174 (9%)	
Adjusted Rates (d)	12.7%	36.3%	30.7%	
Terminal Rates (e)	7/55 (13%)	4/16 (25%)	5/27 (19%)	
Life Table Test (f)		P=0.001	P=0.004	P=0.391N
Incidental Tumor Test (f)		P=0.055	P=0.068	P=0.483N
Fisher Exact Test (f)		P=0.440	P=0.478	P=0.521N
Thyroid: C-Cell Adenoma				
Overall Rates (c)	11/87 (13%)	9/124 (7%)	18/174 (10%)	
Adjusted Rates (d)	18.5%	28.7%	32.1%	
Terminal Rates (e)	9/55 (16%)	2/16 (13%)	4/27 (15%)	
Life Table Test (f)		P=0.072	P=0.019	P=0.348
Incidental Tumor Test (f)		P=0.474	P=0.398	P=0.287
Fisher Exact Test (f)		P=0.141N	P=0.358N	P=0.241
Thyroid: C-Cell Carcinoma				
Overall Rates (c)	11/87 (13%)	9/124 (7%)	12/174 (7%)	
Adjusted Rates (d)	17.0%	35.5%	21.5%	
Terminal Rates (e)	6/55 (11%)	4/16 (25%)	1/27 (4%)	
Life Table Test (f)		P=0.093	P=0.225	P=0.410N
Incidental Tumor Test (f)		P=0.537	P=0.188N	P=0.450N
Fisher Exact Test (f)		P=0.141N	P=0.097N	P=0.539N
Thyroid: C-Cell Adenoma or Carcinoma				
Overall Rates (c)	21/87 (24%)	17/124 (14%)	29/174 (17%)	
Adjusted Rates (d)	32.3%	55.1%	45.2%	
Terminal Rates (e)	14/55 (25%)	6/16 (38%)	5/27 (19%)	
Life Table Test (f)		P=0.017	P=0.015	P=0.472
Incidental Tumor Test (f)		P=0.467	P=0.397N	P=0.381
Fisher Exact Test (f)		P=0.040N	P=0.102N	P=0.298
Mammary Gland: Adenoma				
Overall Rates (c)	6/88 (7%)	2/125 (2%)	5/175 (3%)	
Adjusted Rates (d)	10.9%	5.3%	9.2%	
Terminal Rates (e)	6/55 (11%)	0/16 (0%)	1/27 (4%)	
Life Table Test (f)		P=0.627N	P=0.441	P=0.443
Incidental Tumor Test (f)		P=0.436N	P=0.548N	P=0.404
Fisher Exact Test (f)		P=0.055N	P=0.120N	P=0.382
Mammary Gland: Fibroadenoma				
Overall Rates (c)	49/88 (56%)	36/125 (29%)	41/175 (23%)	
Adjusted Rates (d)	76.1%	82.1%	70.7%	
Terminal Rates (e)	40/55 (73%)	10/16 (63%)	13/27 (48%)	
Life Table Test (f)		P<0.001	P=0.036	P=0.059N
Incidental Tumor Test (f)		P=0.269	P=0.206N	P=0.030N
Fisher Exact Test (f)		P<0.001N	P<0.001N	P=0.180N

HWBUI0001819

TABLE E6. ANALYSIS OF PRIMARY TUMORS IN FEMALE RATS IN THE LIFETIME FEED STUDY OF INTERMEDIATE-RANGE CHRYSOTILE ASBESTOS PLUS 1,2-DIMETHYLHYDRAZINE DIHYDROCHLORIDE (Continued)

	CONTROL (UNTR)	DMH (a)	IR + DMH (b)	DMH vs IR + DMH
Mammary Gland: Adenocarcinoma				
Overall Rates (c)	5/88 (6%)	0/125 (0%)	1/175 (1%)	
Adjusted Rates (d)	8.4%	0.0%	1.3%	
Terminal Rates (e)	4/55 (7%)	0/16 (0%)	0/27 (0%)	
Life Table Test (f)		P=0.170N	P=0.216N	(g)
Incidental Tumor Test (f)		P=0.087N	P=0.077N	(g)
Fisher Exact Test (f)		P=0.012N	P=0.018N	(g)
Uterus: Endometrial Stromal Polyp				
Overall Rates (c)	13/87 (15%)	7/125 (6%)	15/175 (9%)	
Adjusted Rates (d)	21.2%	19.6%	25.1%	
Terminal Rates (e)	9/55 (16%)	2/16 (13%)	3/27 (11%)	
Life Table Test (f)		P=0.433	P=0.158	P=0.310
Incidental Tumor Test (f)		P=0.195N	P=0.306N	P=0.230
Fisher Exact Test (f)		P=0.021N	P=0.089N	P=0.229
Zymbal Gland: Squamous Cell Carcinoma				
Overall Rates (c)	1/88 (1%)	14/125 (11%)	26/175 (15%)	
Adjusted Rates (d)	1.4%	27.9%	40.2%	
Terminal Rates (e)	0/55 (0%)	0/16 (0%)	5/27 (19%)	
Life Table Test (f)		P<0.001	P<0.001	P=0.338
Incidental Tumor Test (f)		P=0.041	P<0.001	P=0.235
Fisher Exact Test (f)		P=0.003	P<0.001	P=0.229
Zymbal Gland: Squamous Cell Papilloma or Carcinoma				
Overall Rates (c)	1/88 (1%)	15/125 (12%)	28/175 (16%)	
Adjusted Rates (d)	1.4%	30.1%	41.9%	
Terminal Rates (e)	0/55 (0%)	0/16 (0%)	5/27 (19%)	
Life Table Test (f)		P<0.001	P<0.001	P=0.328
Incidental Tumor Test (f)		P=0.024	P<0.001	P=0.224
Fisher Exact Test (f)		P=0.002	P<0.001	P=0.210

(a) Administered 1,2-dimethylhydrazine dihydrochloride (DMH) by gavage
(b) Administered 1% intermediate-range (IR) chrysotile asbestos in the diet and DMH by gavage
(c) Number of tumor-bearing animals/number of animals examined at the site
(d) Kaplan-Meier estimated tumor incidence at the end of the study after adjusting for intercurrent mortality
(e) Observed tumor incidence at terminal kill
(f) Beneath the dosed group incidence are the P values corresponding to pairwise comparisons between that dosed group and the controls. The pairwise comparison between the dosed groups is in the final column. The life table analysis regards tumors in animals dying prior to terminal kill as being (directly or indirectly) the cause of death. The incidental tumor test regards these lesions as nonfatal. The Fisher exact test compares directly the overall incidence rates. A lower incidence in a dosed group than in the controls or in the IR plus DMH group than in the DMH group is indicated by (N).
(g) P value not calculated because of low incidence in both dose groups

HWBUI0001820

HWBUI0001821

APPENDIX F

INCIDENCES OF TUMORS IN F344/N RATS RECEIVING NO TREATMENT IN CONTEMPORARY LIFETIME ASBESTOS STUDIES

HWBUI0001822

TABLE F1. INCIDENCE OF EPITHELIAL TUMORS OF THE LARGE INTESTINE IN MALE F344/N RATS RECEIVING NO TREATMENT IN LIFETIME STUDIES

Asbestos Studies	Incidence	Diagnosis
SR Chrysotile	0/87 (0.0%)	
IR Chrysotile	0/85 (0.0%)	
Tremolite	1/118 (0.8%)	Adenomatous polyp, NOS
Crocidolite	1/117 (0.8%)	Adenomatous polyp, NOS
	1/117 (0.8%)	Carcinoma, NOS
Amosite	0/117 (0.0%)	
TOTAL	3/524 (0.6%)	
SD (a)	0.8%	

(a) Standard deviation

TABLE F2. INCIDENCE OF INTEGUMENTARY SYSTEM KERATOACANTHOMAS IN MALE F344/N RATS RECEIVING NO TREATMENT IN LIFETIME STUDIES

Asbestos Studies	Incidence
SR Chrysotile	5/88 (6%)
IR Chrysotile	1/88 (1%)
Tremolite	6/118 (5%)
Crocidolite	4/118 (3%)
Amosite	4/117 (3%)
TOTAL	20/529 (3.8%)
SD (a)	1.8%

(a) Standard deviation

HWBUI0001823

TABLE F3. INCIDENCE OF CLITORAL GLAND TUMORS IN FEMALE F344/N RATS RECEIVING NO TREATMENT IN LIFETIME STUDIES

Asbestos Studies	All Adenoma	All Carcinoma	Adenoma or Carcinoma
SR Chrysotile	1/88 (1%)	2/88 (2%)	3/88 (3%)
IR Chrysotile	0/88 (0%)	1/88 (1%)	1/88 (1%)
Tremolite	0/118 (0%)	6/118 (5%)	6/118 (5%)
Crocidolite	1/118 (1%)	5/118 (4%)	6/118 (5%)
Amosite	0/117 (0%)	6/117 (5%)	6/117 (5%)
TOTAL	2/529 (0.4%)	20/529 (3.8%)	22/529 (4.2%)
SD (a)	0.6%	1.8%	1.7%

(a) Standard deviation

TABLE F4. INCIDENCE OF ADRENAL GLAND TUMORS IN MALE F344/N RATS RECEIVING NO TREATMENT IN LIFETIME STUDIES

Asbestos Studies	Pheochromocytoma	Malignant Pheochromocytoma	All Pheochromocytoma
SR Chrysotile	25/88 (28%)	2/88 (1%)	26/88 (30%)
IR Chrysotile	16/85 (19%)	1/85 (1%)	17/85 (20%)
Tremolite	38/118 (32%)	3/118 (3%)	41/118 (35%)
Crocidolite	33/117 (28%)	2/117 (2%)	35/117 (30%)
Amosite	39/117 (33%)	3/117 (3%)	39/117 (33%)
TOTAL	151/525 (28.8%)	10/525 (1.9%)	158/525 (30.1%)
SD (a)	5.7%	0.7%	5.8%

(a) Standard deviation

TABLE F5. INCIDENCE OF MESOTHELIOMAS IN MALE F344/N RATS RECEIVING NO TREATMENT IN LIFETIME STUDIES

Asbestos Studies	NOS	Malignant	Malignant or NOS
SR Chrysotile	0/88 (0%)	2/88 (2%)	2/88 (2%)
IR Chrysotile	3/88 (3%)	2/88 (2%)	5/88 (6%)
Tremolite	0/118 (0%)	10/118 (8%)	10/118 (8%)
Crocidolite	1/118 (1%)	4/118 (3%)	5/118 (4%)
Amosite	0/117 (0%)	2/117 (2%)	2/117 (2%)
TOTAL	4/529 (1%)	20/529 (4%)	24/529 (5%)
SD (a)	1.5%	2.8%	2.7%

(a) Standard deviation

HWBUI0001824

HWBUI0001825

APPENDIX G

ANALYSIS OF FORMULATED DIETS AND DOSE MIXTURES

HWBUI0001826

APPENDIX G. ANALYSIS OF DIETS AND DOSE MIXTURES

I. Analysis of Formulated Diets (Illinois Institute of Technology Research Institute)

A. Ashing Procedure

Five pellets were taken from each formulated diet and seven pellets from the untreated control diet. Each pellet was individually crushed and transferred to a tared crucible. The sample size was 350-500 mg of asbestos-containing diet and 1,000-1,500 mg of control diet in each crucible. The sample size was selected on the basis of the linear range of atomic absorption and the average background concentration of magnesium in the diet.

The crucibles containing the diet were placed in a muffle furnace. The temperature was raised slowly to 550° C to prevent loss of material by flashing and maintained overnight. The ashed samples were cooled to room temperature before being chemically digested.

B. Chemical Digestion

The chemical resistance of chrysotile asbestos to acids is poor; therefore, magnesium, a major constituent of chrysotile, can be extracted by hydrochloric acid.

The ashed samples were quantitatively transferred to 100-ml beakers through the use of distilled water. Twenty milliliters of a 1:1:2 solution of nitric and hydrochloric acid in distilled water were added to each beaker. The samples were placed on a hot plate and gently boiled for 8 hours; hydrochloric acid and distilled water were added to maintain the 20-ml volume. Any sample evaporated to dryness was discarded. The samples were cooled and diluted.

C. Dilution of Samples for Atomic Absorption

The sample dilution procedure included the addition of potassium (K^+), lanthanum (La^{3+}), and hydrochloric acid from a stock solution to the volumetric flask. The potassium ion conditions the flame; the lanthanum complexes with potentially interfering phosphates; and the hydrochloric acid assures a pH less than 3 in each sample. The final dilution contained 100 mg/liter of K^+ and 30 mg/liter of La^{3+}. The sample was quantitatively transferred to the volumetric flask and dilution was completed. If digestion or silica removal was incomplete, the dilution would be cloudy and the sample discarded.

D. Atomic Absorption Analysis

Atomic absorption spectroscopy provides sensitive, precise analysis for magnesium at low concentrations. Standards, treated as the samples, were used to determine calibration curves. A linear calibration curve from 0 to 2 mg/liter for magnesium is typical. Calibration data were taken immediately before the sample data and at the conclusion of the sample run; spot checks were made throughout each sample set. The instrument response was converted to concentration by a calibration curve. Samples greater than 110% of the highest standard were diluted and reanalyzed.

E. Results

Results are presented in Tables G1 and G2.

HWBUI0001827

TABLE G1. ANALYSIS OF FORMULATED DIETS IN THE LIFETIME FEED STUDIES OF SHORT-RANGE CHRYSOTILE ASBESTOS

Date Mixed	Determined Concentration in Feed for Target Concentration of 10,000 ppm (1%)
11/21/77	8,500 ± 400
12/07/77	11,100 ± 600
12/07/77	10,000 ± 600
02/01/78	9,100 ± 900
03/22/78	10,900 ± 4,500
05/22/78	9,300 ± 600
07/11/78	8,600 ± 500
09/14/78	8,900 ± 1,200
10/30/78	8,000 ± 400
12/11/78	9,300 ± 1,700
02/15/79	10,600 ± 400
04/06/79	10,700 ± 600
05/19/79	10,600 ± 500
06/26/79	8,700 ± 100
08/28/79	9,700 ± 600
10/16/79	9,100 ± 400
12/03/79	9,300 ± 900
01/10/80	8,600 ± 200
02/27/80	11,700 ± 1,600
04/18/80	9,000 ± 1,200
05/29/80	11,900 ± 900
07/18/80	10,000 ± 1,100
	Mean = 9,700 ± 2,100

HWBUI0001828

TABLE G2. ANALYSIS OF FORMULATED DIETS IN THE LIFETIME FEED STUDIES OF INTERMEDIATE-RANGE CHRYSOTILE ASBESTOS

Date Mixed	Determined Concentration in Feed for Target Concentration of 10,000 ppm (1%)
11/21/77	8,900 ± 1,000
12/07/77	10,200 ± 500
12/07/77	10,800 ± 800
12/07/77	10,400 ± 1,000
02/10/78	10,200 ± 1,100
02/01/78	10,400 ± 1,400
03/22/78	10,900 ± 700
03/22/78	11,000 ± 1,000
05/22/78	10,200 ± 700
05/22/78	9,900 ± 2,300
07/11/78	9,300 ± 300
07/11/78	9,100 ± 700
09/14/78	9,000 ± 400
09/14/78	9,100 ± 1,200
10/30/78	9,100 ± 200
10/30/78	8,500 ± 900
12/15/78	10,400 ± 1,200
12/15/78	10,900 ± 800
02/15/79	10,200 ± 2,600
02/15/79	11,100 ± 500
04/06/79	11,000 ± 500
04/60/79	11,600 ± 2,400
05/09/79	10,000 ± 1,000
05/09/79	10,700 ± 700
06/26/79	9,500 ± 500
08/28/79	10,000 ± 500
08/28/79	9,900 ± 500
10/16/79	11,500 ± 200
10/16/79	10,200 ± 100
12/03/79	9,900 ± 500
12/03/79	10,700 ± 400
01/10/80	9,400 ± 400
01/10/80	10,100 ± 600
02/27/80	12,900 ± 800
02/27/80	12,900 ± 900
04/18/80	9,100 ± 300
05/29/80	11,400 ± 1,000
05/29/80	10,200 ± 900
07/18/80	10,000 ± 2,000
	Mean = 10,272 ± 983

HWBUI0001829

II. 1,2-Dimethylhydrazine Dihydrochloride (DMH) Solution Analysis (Hazleton Laboratories, America)

- Solutions were analyzed approximately 1 hour before dosing and the evening after dosing. A colorimetric method was followed which used pentacyanoamino ferrate as the color reagent and DMH as the standard.

- A fresh aqueous $Na_3[Fe(CN)_5NH_4]$ (sodium pentacyanoamino ferrate) solution (20 mg/ml) was prepared daily.

- A fresh stock solution of DMH in 0.2 M acetate buffer pH 5.0 (200 µg/ml) also was prepared daily and kept on ice after preparation.

- A borate buffer (0.05 M) was adjusted to pH 8.5 with 0.1 M sodium hydroxide.

- The required amounts of dosing solution were prepared in glass containers with acetate buffer as the solvent.

- Aliquots of each dosing solution were taken before dosing for a qualitative determination by a UV scan from 350 nm to 220 nm, which was run on a Beckman DK-2A Spectrophotometer with acetate buffer as the reference.

- Colorimetric quantitative analysis of samples collected before and after dosing was performed by the addition of 2.5 ml of the pentacyanoamino solution (0.2 ml stock diluted with 7.8 ml borate buffer) to 0.5 ml of sample or 0.5 ml of reference (acetate buffer); 0.05 ml of 50% aqueous hydrochloric acid was added to both solutions, and they were mixed thoroughly. The color was read immediately at 536 nm on a spectrophotometer.

- The results were compared with a standard curve for DMH.

HWBUI0001830

TABLE G3. ANALYSIS OF DOSE MIXTURES OF 1,2-DIMETHYLHYDRAZINE DIHYDROCHLORIDE IN THE LIFETIME FEED STUDIES OF INTERMEDIATE-RANGE CHRYSOTILE ASBESTOS (a)

Dosing Date		Sex	Gravimetric Concentration (mg/ml)	Analytical Concentration (mg/ml)
02/22/78	Predose	Male	3.84	2.70
				2.70
		Female	7.79	4.56
				5.06
	Postdose	Male	--	2.27
				2.53
		Female	--	4.05
				4.19
03/08/78	Predose	Male	3.87	3.85
				3.92
		Female	7.73	7.40
				7.54
	Postdose	Male	--	1.62
				2.02
		Female	--	3.75
				2.80
03/22/78	Predose	Male	3.87	2.70
				2.92
		Female	7.76	7.40
				7.40
	Postdose	Male	--	2.20
				2.40
		Female	--	4.20
				3.80
04/05/78	Predose	Male	3.88	1.27
				1.20
		Female	7.66	5.20
				5.30
	Postdose	Male	--	2.65
				2.65
		Female	--	5.30
				5.30
04/19/78	Predose	Male	3.88	2.36
				2.92
		Female	7.75	6.83
				5.35
	Postdose	Male	--	2.53
				1.91
		Female	--	2.36
				2.92

(a) Values represent milligrams of 1,2-dimethylhydrazine dihydrochloride per milliliter of acetate buffer.

HWBUI0001831

APPENDIX H

FEED AND COMPOUND CONSUMPTION BY RATS IN THE LIFETIME FEED STUDIES OF CHRYSOTILE ASBESTOS

HWBUI0001832

TABLE H1. FEED AND COMPOUND CONSUMPTION BY MALE RATS IN THE LIFETIME FEED STUDY OF SHORT-RANGE CHRYSOTILE ASBESTOS

Week	Control		Dosed Group			
	Grams Feed/ Day (a)	Body Weight (grams)	Grams Feed/ Day (a)	Body Weight (grams)	Dosed/ Control (b) (grams)	Dose/ Day (c)
7	16	152	16	156	1.0	1,053
8	17	175	18	182	1.0	965
9	16	200	17	205	1.1	843
10	16	222	18	224	1.1	823
12	17	250	17	254	1.0	681
13	17	262	17	267	1.0	642
14	16	271	17	275	1.1	629
15	16	280	17	285	1.0	586
16	16	283	17	290	1.0	581
17	18	295	15	291	0.8	515
18	14	301	17	299	1.2	554
19	17	310	17	308	1.0	552
20	17	314	18	316	1.0	556
30	18	366	18	356	1.0	502
40	16	394	17	396	1.1	437
50	18	423	18	424	1.0	431
60	17	430	17	429	1.0	386
70	17	452	18	451	1.0	393
80	18	467	16	462	0.9	343
90	17	470	17	470	1.0	368
100	16	461	16	456	1.0	351
110	16	444	15	430	0.9	339
120	17	430	15	411	0.9	361
130	15	376	16	383	1.1	410
Mean	17	334	17	334	1.0	554
SD (d)	1.0		1.0		0.1	199.7
CV (e)	5.7		6.1		8.1	36.0

(a) Grams of feed removed from feed hopper per animal per day. Not corrected for scatter.
(b) Grams of feed per day for the dosed group divided by that for the controls
(c) Milligrams of short-range chrysotile asbestos consumed per day per kilogram of body weight
(d) Standard deviation
(e) Coefficient of variation = (standard deviation/mean) × 100

HWBUI0001833

TABLE H2. FEED AND COMPOUND CONSUMPTION BY FEMALE RATS IN THE LIFETIME FEED STUDY OF SHORT-RANGE CHRYSOTILE ASBESTOS

Week	Control		Dosed Group			
	Grams Feed/ Day (a)	Body Weight (grams)	Grams Feed/ Day (a)	Body Weight (grams)	Dosed/ Control (b) (grams)	Dose/ Day (c)
7	13	124	12	129	1.0	941
8	13	135	12	139	0.9	874
9	12	143	13	149	1.0	844
10	13	153	13	156	1.0	824
12	13	163	12	168	0.9	714
13	12	167	13	172	1.0	731
14	13	170	13	175	1.0	751
15	12	175	13	180	1.0	706
16	13	174	12	180	1.0	675
17	12	181	11	180	0.9	611
18	10	182	12	181	1.2	655
19	12	187	12	185	1.0	664
20	12	188	13	189	1.1	673
30	12	206	12	204	1.0	595
40	12	220	12	223	1.0	545
50	13	247	14	244	1.0	556
60	15	262	13	269	0.9	478
70	14	290	14	291	1.0	491
80	14	311	14	316	1.0	429
90	14	326	14	331	1.0	423
100	16	332	13	328	0.8	405
110	14	324	13	308	0.9	408
120	14	326	14	312	1.0	453
130	14	303	12	291	0.9	417
140	14	293	13	279	1.0	471
Mean	13	223	13	223	1.0	613
SD (d)	1.3		0.8		0.1	160.4
CV (e)	9.6		6.2		7.9	26.1

(a) Grams of feed removed from feed hopper per animal per day. Not corrected for scatter.
(b) Grams of feed per day for the dosed group divided by that for the controls
(c) Milligrams of short-range chrysotile asbestos consumed per day per kilogram of body weight
(d) Standard deviation
(e) Coefficient of variation = (standard deviation/mean) × 100

HWBUI0001834

TABLE H3. FEED AND COMPOUND CONSUMPTION BY MALE RATS IN THE LIFETIME FEED STUDY OF INTERMEDIATE-RANGE CHRYSOTILE ASBESTOS

	Control		IR				IR/PW			
Week	Grams Feed/ Day (a)	Body Weight (grams)	Grams Feed/ Day (a)	Body Weight (grams)	IR/ Control (b) (grams)	Dose/ Day (c)	Grams Feed/ Day (a)	Body Weight (grams)	IR/PW/ Control (b) (grams)	Dose/ Day (c)
8	15	134	15	136	1.0	1,103	16	148	1.1	1,110
9	16	159	16	160	1	991	17	166	1.1	1,024
10	16	183	16	180	1	889	16	195	1	828
11	16	203	16	197	1	805	16	221	1	737
12	17	218	16	216	1	761	17	234	1	733
13	16	231	17	227	1	736	18	245	1.1	746
14	17	246	14	234	0.9	611	16	254	0.9	613
15	17	256	15	245	0.9	612	16	266	0.9	591
16	16	258	16	257	1	623	17	276	1.1	606
17	16	267	17	267	1	626	16	286	1	574
18	15	278	16	276	1.1	580	17	295	1.1	567
19	17	285	17	281	1	600	17	303	1	556
20	17	294	16	290	1	567	17	312	1	559
21	15	293	17	292	1.1	572	18	319	1.1	555
31	16	344	17	333	1.1	519	18	355	1.1	495
41	17	393	16	371	1	443	16	400	1	404
51	16	402	18	396	1.1	451	19	419	1.1	447
61	17	417	16	401	0.9	388	15	417	0.9	360
71	17	443	17	424	1	408	17	441	1	376
81	17	460	18	433	1	412	18	458	1.1	402
91	16	463	17	432	1.1	384	16	462	1.1	356
101	15	452	16	423	1.1	385	16	447	1.1	355
111	16	446	16	415	1	382	17	426	1	389
121	17	423	15	393	0.9	393	17	405	1	430
131	16	394	17	359	1.1	481	15	373	0.9	406
141	16	352	18	327	1.1	546	16	354	1	440
Mean	16	319	16	306	1.0	587	17	326	1.0	564
SD (d)	0.7		0.9		0.1	194.5	1.0		0.1	200.0
CV (e)	4.6		5.6		7.0	33.1	5.8		6.8	35.5

(a) Grams of feed removed from feed hopper per animal per day. Not corrected for scatter.
(b) Grams of feed per day for the dosed group divided by that for the controls
(c) Milligrams of intermediate-range chrysotile asbestos consumed per day per kilogram of body weight
(d) Standard deviation
(e) Coefficient of variation = (standard deviation/mean) × 100

HWBUI0001835

TABLE H4. FEED AND COMPOUND CONSUMPTION BY FEMALE RATS IN THE LIFETIME FEED STUDY OF INTERMEDIATE-RANGE CHRYSOTILE ASBESTOS

Week	Control		IR				IR/PW			
	Grams Feed/ Day (a)	Body Weight (grams)	Grams Feed/ Day (a)	Body Weight (grams)	IR/ Control (b) (grams)	Dose/ Day (c)	Grams Feed/ Day (a)	Body Weight (grams)	IR/PW/ Control (b) (grams)	Dose/ Day (c)
8	12	119	11	114	0.9	990	12	116	1	1,071
9	12	131	12	126	1	952	13	130	1	967
10	12	141	11	134	0.9	842	12	140	1	847
11	11	144	12	143	1	819	12	151	1	766
12	13	154	11	149	0.9	767	12	155	0.9	765
13	12	158	12	151	1	795	13	159	1.1	791
14	12	165	11	154	0.9	696	11	164	0.9	697
15	12	166	10	157	0.8	646	11	168	0.9	663
16	11	167	12	162	1	723	12	173	1	669
17	11	169	12	166	1.1	723	12	175	1.1	694
18	12	173	11	169	1	668	11	180	1	635
19	12	175	12	171	1	693	12	182	1	636
20	12	180	12	175	1	661	11	184	1	621
21	11	178	12	175	1.1	669	12	189	1.1	627
31	11	196	12	190	1	609	12	201	1.1	597
41	11	219	11	207	0.9	511	11	223	1	512
51	13	235	13	224	1.1	599	13	241	1.1	557
61	12	259	12	251	1	472	11	257	0.9	434
71	13	280	13	272	1	467	14	277	1	490
81	13	303	13	291	1	457	14	303	1.1	453
91	12	323	13	302	1.1	435	12	313	1	397
101	12	330	13	303	1.1	438	14	320	1.2	451
111	14	329	13	303	0.9	420	15	315	1.1	467
121	13	324	12	300	0.9	410	15	315	1.1	463
131	13	308	13	268	1	490	14	301	1.1	465
141	13	286	13	255	1	515	14	287	1	473
Mean (d)	12	216	12	204	1.0	633	12	216	1.0	623
SD (d)	0.8		0.9		0.1	165.8	1.1		0.1	171.0
CV (e)	6.5		7.5		7.4	26.2	9.1		6.8	27.4

(a) Grams of feed removed from feed hopper per animal per day. Not corrected for scatter.
(b) Grams of feed per day for the dosed group divided by that for the controls
(c) Milligrams of intermediate-range chrysotile asbestos consumed per day per kilogram of body weight
(d) Standard deviation
(e) Coefficient of variation = (standard deviation/mean) × 100

HWBUI0001836

TABLE H5. FEED AND COMPOUND CONSUMPTION BY MALE RATS RECEIVING DMH WITH AND WITHOUT INTERMEDIATE-RANGE CHRYSOTILE ASBESTOS IN THE LIFETIME FEED STUDY OF INTERMEDIATE-RANGE CHRYSOTILE ASBESTOS

	Control		DMH			DMH plus IR			
Week	Grams Feed/ Day (a)	Body Weight (grams)	Grams Feed/ Day (a)	Body Weight (grams)	DMH/ Control (b) (grams)	Grams Feed/ Day (a)	Body Weight (grams)	DMH + IR/ Control (b) (grams)	Dose/ Day (c)
8	15	134	15	131	1.0	15	134	1.0	1,087
9	16	159	15	150	0.9	16	154	1.0	1,030
10	16	183	16	177	1.0	16	181	1.0	876
11	16	203	16	199	1.0	16	197	1.0	798
12	17	218	17	216	1.0	16	214	1.0	741
13	16	231	16	226	1.0	16	221	1.0	718
14	17	246	17	245	1.0	15	233	0.9	638
15	17	256	17	252	1.0	15	242	0.9	620
16	16	258	16	259	1.0	16	253	1.0	638
17	16	267	14	262	0.9	15	261	1.0	591
18	15	278	16	274	1.1	17	270	1.1	619
19	17	285	17	282	1.0	17	277	1.0	619
20	17	294	17	294	1.0	17	281	1.0	605
21	15	293	15	290	1.0	17	288	1.1	595
31	16	344	17	340	1.0	17	332	1.1	521
41	17	393	16	390	0.9	16	370	1.0	429
51	16	402	19	416	1.1	18	390	1.1	465
61	17	417	16	421	0.9	15	402	0.9	370
71	17	443	18	446	1.0	17	423	1.0	395
81	17	460	16	452	0.9	17	426	1.0	402
91	16	463	16	462	1.0	16	437	1.0	373
101	15	452	15	461	1.0	16	421	1.1	390
111	16	446	17	447	1.0	17	407	1.0	421
121	17	423	18	410	1.1	17	387	1.0	443
131	16	394	17	374	1.1	16	362	1.0	430
Mean	16	318	16	315	1.0	16	303	1.0	593
SD (d)	0.7		1.0		0.1	0.9		0.1	198.2
CV (e)	4.6		6.3		5.7	5.6		6.7	33.5

(a) Grams of feed removed from feed hopper per animal per day. Not corrected for scatter.
(b) Grams of feed per day for the dosed group divided by that for the controls
(c) Milligrams of intermediate-range chrysotile asbestos consumed per day per kilogram of body weight
(d) Standard deviation
(e) Coefficient of variation = (standard deviation/mean) × 100

HWBUI0001837

TABLE H6. FEED AND COMPOUND CONSUMPTION BY FEMALE RATS RECEIVING DMH WITH AND WITHOUT INTERMEDIATE-RANGE CHRYSOTILE ASBESTOS IN THE LIFETIME FEED STUDY OF INTERMEDIATE-RANGE CHRYSOTILE ASBESTOS

	Control		DMH			DMH plus IR			
Week	Grams Feed/ Day (a)	Body Weight (grams)	Grams Feed/ Day (a)	Body Weight (grams)	DMH/ Control (b) (grams)	Grams Feed/ Day (a)	Body Weight (grams)	DMH + IR/ Control (b) (grams)	Dose/ Day (c)
8	12	119	12	115	1.0	11	110	0.9	1,013
9	12	131	12	126	0.9	12	120	0.9	964
10	12	141	12	137	1.0	11	133	1.0	859
11	11	144	11	145	1.0	11	137	1.0	803
12	13	154	11	152	0.9	11	144	0.9	784
13	12	158	12	152	1.0	11	144	0.9	754
14	12	165	12	161	1.0	10	151	0.8	691
15	12	166	12	160	1.0	10	153	0.9	682
16	11	167	12	162	1.0	12	160	1.0	741
17	11	169	10	164	0.9	11	162	1.0	661
18	12	173	12	168	1.0	12	166	1.0	723
19	12	175	13	173	1.1	12	170	1.0	714
20	12	180	12	179	1.0	12	170	1.0	714
21	11	178	11	174	1.0	12	173	1.1	685
31	11	196	11	196	1.0	12	190	1.1	617
41	11	219	11	217	0.9	11	204	1.0	546
51	13	235	14	239	1.1	13	224	1.0	593
61	12	259	13	261	1.0	11	247	0.9	451
71	13	280	13	285	1.0	13	267	1.0	492
81	13	303	13	303	1.0	14	280	1.1	495
91	12	323	13	316	1.0	13	293	1.0	444
101	12	330	13	325	1.1	14	294	1.1	462
111	14	329	16	314	1.1	15	284	1.1	513
Mean	12	204	12	201	1.0	11	190	1.0	670
SD (d)	0.8		1.2		0.1	1.1		0.1	157.2
CV (e)	6.2		10.2		6.5	9.6		8.2	23.5

(a) Grams of feed removed from feed hopper per animal per day. Not corrected for scatter.
(b) Grams of feed per day for the dosed group divided by that for the controls
(c) Milligrams of intermediate-range chrysotile asbestos consumed per day per kilogram of body weight
(d) Standard deviation
(e) Coefficient of variation = (standard deviation/mean) × 100

HWBUI0001838

HWBUI0001839

APPENDIX I

PATHOGEN BURDEN IN RATS IN THE LIFETIME FEED STUDIES OF SHORT-RANGE CHRYSOTILE ASBESTOS

HWBUI0001840

APPENDIX I. PATHOGEN BURDEN

A. Pathogen Burden Summary: F_0

Sections of brain, heart, lung, spleen, liver, kidney, small intestine, large intestine, salivary gland, urinary bladder, harderian gland, skin, anus, and trachea from eight male and eight female rats were examined microscopically (Tables I1-I3).

Evidence of mild respiratory disease was present in all sections of lung examined. In some rats, small foci of mononuclear cells were present adjacent to the bronchial tissue, and in other rats, small cuffs of lymphoid cells were evident, particularly at the bifurcation of the bronchi. These lesions were very mild.

A section of kidney from one female rat revealed an area of early nephritis with a focal area of regenerative tubule epithelium. This wedge-shaped lesion, producing an area of depression on the capsule, may have resulted from an infarction.

The remaining tissues were not remarkable.

HWBUI0001841

TABLE I1. INDIVIDUAL HISTOPATHOLOGIC FINDINGS IN F_0 RATS IN THE LIFETIME FEED STUDIES OF SHORT-RANGE CHRYSOTILE ASBESTOS

Organ and Description	Animal Number	Male								Female							
		1 1 7	1 1 8	1 1 9	1 2 0	1 2 1	1 2 2	1 2 3	1 2 4	1 2 5	1 2 6	1 2 7	1 2 8	1 2 9	1 3 0	1 3 1	1 3 2
Brain		X	X	X	X	X	X	X	X	X	X	X	X	X	X	X	X
Heart		X	X	X	X	X	X	X	X	X	X	X	X	X	X	X	X
Lung																	
Minimal peribronchial lymphoid hyperplasia		1	1	1	1	1	1	1	1	1	1	1	1	1	1	1	1
Artificial collapse										P	P						
Spleen		X	X	X	X	X	X	X	X	X	X	X	X	X	X	X	X
Liver		X	X	X	X	X	X	X	X	X	X	X	X	X	X	X	X
Kidney		X	X	X	X	X	X	X	X	X	X		X	X	X	X	X
Regenerative tubule epithelium												P					
Early interstitial nephritis												P					
Small intestine		X	X	X	X	X	X	X	X	X	X	X	X	X	X	X	X
Large intestine		X	X	X	X	X	X	X	X	X	X	X	X	X	X	X	X
Salivary gland		X	X	X	X	X	X	X	X	X	X	X	X	X	X	X	X
Urinary bladder		X	X	X	X	X	X	X	X	X	X	X	X	X	X	X	X
Harderian gland		X	X	X	X	X	X	X	X	X	X	X	X	X	X	X	X
Skin		X	X	X	X	X	X	X	X	X	X	X	X	X	X	X	X
Anus		X	X	O	X	X	X	X	X	X	O	X	X	X	X	X	X
Trachea		X	X	X	O	X	X	X	X	X	X	X	X	X	X	X	X

Type of Finding:

O = Tissue Absent
X = Tissue Examined and Not Remarkable
A = Autolysis
P = Finding Present

Degree of Finding:

1 = Minimal
2 = Slight
3 = Moderate
4 = Moderately Severe
5 = Severe

HWBUI0001842

TABLE I2. MICROSCOPIC EXAMINATION FOR ENDOPARASITES AND BACTERIA IN F_0 RATS IN THE LIFETIME FEED STUDIES OF SHORT-RANGE CHRYSOTILE ASBESTOS

Animal/Specimen Number (a)	Microorganisms Identified (b)
117/3701	3+ Coliform; 1+ *Proteus morganii*
118/3702	1+ Coliform; 1+ *Proteus vulgaris*
119/3703	3+ Coliform (3 types)
120/3704	2+ Coliform (2 types)
121/3705	3+ Coliform (2 types)
122/3706	4+ Coliform (2 types); 4+ *Proteus vulgaris*
123/3707	4+ Coliform; 4+ *Proteus vulgaris*
124/3708	No growth
125/3709	1+ Coliform
126/3710	1+ Coliform; 1+ *Proteus vulgaris*
127/3711	2+ Coliform; 1+ *Proteus vulgaris*
128/3712	2+ Coliform (2 types)
129/3713	1+ Coliform
130/3714	3+ Coliform (2 types); 1+ *Proteus vulgaris*
131/3715	2+ Coliform (2 types)
132/3716	2+ Coliform (2 types)

(a) Date of specimen: 9/28/77
(b) Lung, spleen, feces, and tracheal wash were examined for each specimen; no growth observed in the spleen or lungs; no mycoplasma isolated from tracheal washings.

HWBUI0001843

TABLE I3. MURINE VIRUS ANTIBODY DETERMINATION IN F_0 RATS IN THE LIFETIME FEED STUDIES OF SHORT-RANGE CHRYSOTILE ASBESTOS

Sample Number	Complement Fixation	
	Sendai	LCM
701	–	–
702	–	–
703	–	–
704	–	–
705	–	–
706	–	–
707	–	–
708	–	–
709	–	–
710	–	–
711	–	–
712	–	–
713	–	–
714	–	–
715	–	–
716	–	–
Significant titer	10	10

HWBUI0001844

B. Pathogen Burden Summary: F_1

Sections of brain, heart, lung, spleen, liver, kidney, small intestine, large intestine, salivary gland, urinary bladder, harderian gland, skin, anus, and trachea were examined from four males and four females in the untreated control group and four males and four females in the 1% SR chrysotile group that were killed for pathology burden (Tables I4 and I5).

Evidence of early spontaneous respiratory disease was present in the lungs of all rats examined. In one control male and two SR chrysotile males, only small foci of mononuclear cells were present adjacent to the bronchioles. In the remaining rats, minimal-to-slight peribronchial lymphoid hyperplasia was present. Agonal hemorrhage occurred in one control female.

In sections of kidney, foci of regenerative tubule epithelium and foci of mononuclear cells were noted in one control male. Foci of mineralization were noted at the corticomedullary junction of two females in the control and SR chrysotile groups.

Focal nonsuppurative tracheitis occurred in one control male.

The remaining tissues examined were not remarkable.

HWBUI0001845

TABLE I4. INDIVIDUAL HISTOPATHOLOGIC FINDINGS IN F_1 RATS IN THE LIFETIME FEED STUDIES OF SHORT-RANGE CHRYSOTILE ASBESTOS

	Untreated Control								Short-Range							
	Male				Female				Male				Female			
Animal Number / Organ and Description	19707	19808	19909	20000	20001	20002	20903	20004	20005	20006	20007	20008	20009	20110	20111	20112
Brain	X	X	X	X	X	X	X	X	X	X	X	X	X	X	X	X
Heart	X	X	X	X	X	X	X	X	X	X	X	X	X	X	X	X
Lung																
Foci of mononuclear cells	P					P										
Peribronchial lymphoid hyperplasia		1	2	2	2		1	2	1	1	1	1	2	1	2	2
Agonal hemorrhage									P							
Spleen	X	X	X	X	X	X	X	X	X	X	X	X	X	X	X	X
Liver	X	X	X	X	X	X	X	X			X	X	X	X	X	X
Nonsuppurative pericholangitis									1	1						
Kidney	X	X	X		X	X	X	X			X	X		O		X
Foci of regenerative tubule epithelium				P												
Foci of mononuclear cells				P												
Foci of mineralization									P	P			P		P	
Small intestine	X	X	X	X	X	X	X	X	X	X	X	X	X	X	X	X
Large *intestine*	X	X	X	X	X	X	X	X	X	X	X	X	X	X	X	X
Salivary gland	X	X	X	X	X	X	X	X	X	X	X	X	X	X	X	X
Urinary bladder	X	X	O	X	X	X	X	X	X	X	X	X	X	X	X	X
Harderian gland	X	X	X	X	X	X	X	X	X	X	X	X	X	X	X	X
Skin	X	X	X	X	X	X	X	X	X	X	X	X	X	X	X	X
Anus	X	X	X	X	X	X	X	X	X	X	X	X	X	X	X	X
Trachea	X	X	X		X	X	X	X	X	X	X	X	X	X	X	X
Focal nonsuppurative tracheitis				P												

Type of Finding:

O = Tissue Absent
X = Tissue Examined and Not Remarkable
A = Autolysis
P = Finding Present

Degree of Finding:

1 = Minimal
2 = Slight
3 = Moderate
4 = Moderately Severe
5 = Severe

HWBUI0001846

TABLE I5. MICROSCOPIC EXAMINATION FOR ENDOPARASITES AND BACTERIA IN F_1 RATS IN THE LIFETIME FEED STUDIES OF SHORT-RANGE CHRYSOTILE ASBESTOS

Animal/Specimen Number (a)	Microorganisms Identified (b)
197/3880	3 + Group D Streptococcus; 1 + Micrococcus; 1 + Coliform; 1 + *Proteus vulgaris*
198/3881	1 + Coliform; 4 + Group D Streptococcus; 3 + Micrococcus
199/3882	1 + Coliform; 3 + Group D Streptococcus; 3 + Micrococcus
200/3883	1 + Coliform; 3 + Group D Streptococcus; 3 + Micrococcus
201/3884	1 + Coliform; 3 + Group D Streptococcus; 3 + Micrococcus
202/3885	1 + Coliform; 1 + *Proteus vulgaris*; 3 + Group D Streptococcus; 3 + Micrococcus
203/3886	1 + Coliform; 4 + Group D Streptococcus
204/3887	1 + Coliform; 1 + *Proteus vulgaris*; 4 + Group D Streptococcus; 1 + Micrococcus
205/3888	1 + *Proteus vulgaris*; 4 + Group D Streptococcus; 4 + *Staphylococcus epidermidis*; 3 + Micrococcus
206/3889	1 + Coliform; 4 + Group D Streptococcus; 4 + *Staphylococcus epidermidis*; 1 + *Proteus vulgaris*
207/3890	4 + Group D Streptococcus; 3 + Micrococcus
208/3891	1 + Coliform; 3 + Group D Streptococcus; 3 + *Staphylococcus epidermidis*
209/3892	1 + Coliform; 3 + Micrococcus; 1 + *Proteus vulgaris*; 3 + *Staphylococcus epidermidis*; 3 + Group D Streptococcus
210/3893	1 + Coliform; 3 + *Staphylococcus epidermidis*
211/3894	No growth
212/3895	1 + Coliform; 1 + *Proteus vulgaris*; 3 + *Staphylococcus epidermidis*

(a) Date of specimen: 1/26/78
(b) Lung, spleen, feces, and tracheal wash were examined for each specimen; no growth observed in the spleen or lungs; no mycoplasma isolated from tracheal washings.

HWBUI0001847

APPENDIX J

PATHOGEN BURDEN IN RATS IN THE LIFETIME FEED STUDIES OF INTERMEDIATE-RANGE CHRYSOTILE ASBESTOS

HWBUI0001848

APPENDIX J. PATHOGEN BURDEN

I. Pathogen Burden Procedures

A. Types of Specimens Obtained:

1. Feces: flotation Bac-T and stereomicroscopic dissection
2. Blood: smear and staining (intracellular parasites)
3. Tracheal wash: mycoplasma
4. Body tissue: gross necropsy, histopathologic examination, and Bac-T
5. Blood serum: viral antibody profile
6. Scotch Tape impression slides: microscopic for ectoparasites

B. Methods

1. Fecal Flotation: modified zinc sulfate concentration method

   a. Zinc sulfate (USP) solution ($ZnSO_4$) at a specific gravity of 1.118 and a small aliquot of fecal material (15:1) are mixed in a standard centrifuge tube until well suspended.

   b. $ZnSO_4$ is added to the suspension until the tube is in a near overflow position.

   c. A slide coverslip is placed over the top of the centrifuge tube and allowed to stand for a minimum of 5 minutes.

   d. The slide coverslip is then removed and placed on an appropriately sized microscope slide for examination. (One drop of Iodine Stain for wet-mount fecal examination was employed infrequently in some cases.)

   e. Composite fecal samples for flotation were obtained from three sites: lower colon, cecum, and jejunum.

   f. Fecal samples from these sites were also dissected and examined under a stereomicroscope for the presence of endoparasites.

   g. Fecal samples from the colon were transported to the diagnostic microlaboratory in buffer glyceriated saline and cultured in the appropriate media for isolation and identification of enteric pathogens.

2. Blood

   a. Whole blood films (two each) were made of each animal by the blood smear technique. These films were in turn stained (Wright's) and microscopically examined for the presence of blood parasites.

   b. Approximately 1 ml of whole blood for serum harvest was obtained for viral antibody profile using aseptic technique. Whole blood samples were centrifuged. The serum was harvested, diluted 1:5 in 1N saline, and heat inactivated before shipment to an outside commercial laboratory for analysis.

HWBUI0001849

3. Tracheal Wash (Lung)

Aseptic tracheal washes with physiologic saline (one per animal) were obtained and placed in appropriate media for mycoplasm culture and identification.

4. Body Tissue

a. Aseptically obtained sections of spleen and lung were placed in appropriate media and cultured for the presence of pathogenic organisms.

b. Body tissues as outlined for each 840 series study (16 tissues) were examined grossly at necropsy and placed in 10% neutral buffered formalin for histopathologic examination.

5. Scotch Tape Impression Slides

Ordinary scotch tape was pressed firmly against both the anus (perianal fold) and the hair covering at the anterior dorsum aspect of the neck. The tape was then applied to an ordinary microscopic slide for low-power microscopic examination for ectoparasites and/or migratory intestinal parasites (pinworms).

II. Pathogen Burden Summary: F_0

Sections of brain, heart, lung, spleen, liver, kidney, small intestine, large intestine, salivary gland, urinary bladder, harderian gland, skin, anus, and trachea from eight male and eight female rats were examined microscopically (Tables J1 and J2).

Evidence of early chronic respiratory disease was present in all animals: minimal-to-moderate peribronchial lymphoid hyperplasia (six males, seven females); focal accumulations of mononuclear cells (two males); focal accumulations of alveolar macrophages (one female); and minimal lymphoid hyperlasia (one female).

Lymphoid hyperplasia was present in the spleen and cervical lymph nodes of a single female.

In sections of liver, minimal nonsuppurative pericholangitis was present in two males. In sections of kidney, minimal focal interstitial nephritis, characterized by focal accumulations of mononuclear inflammatory cells, was present in two males and one female.

The remaining tissues were not remarkable.

HWBUI0001850

TABLE J1. INDIVIDUAL HISTOPATHOLOGIC FINDINGS IN F_0 RATS IN THE LIFETIME FEED STUDIES OF INTERMEDIATE-RANGE CHRYSOTILE ASBESTOS

Organ and Description	Animal Number	Male								Female							
		1 3 3	1 3 4	1 3 5	1 3 6	1 3 7	1 3 8	1 3 9	1 4 0	1 4 1	1 4 2	1 4 3	1 4 4	1 4 5	1 4 6	1 4 7	1 4 8
Brain		X	X	X	X	X	X	X	X	X	X	X	X	X	X	X	X
Heart		X	X	X	X	X	X	X	X	X	X	X	X	X	X	X	X
Lung														X			
Peribronchial lymphoid hyperplasia			1		2	2	1	2	3	1	1	1	1		2	1	2
Artifactual collapse			P				P						P				
Foci of mononuclear cells		P		P													
Perivascular lymphoid hyperplasia																	1
Accumulations of alveolar macrophages																P	
Spleen		X	X	X	X	X	X	X	X	X	X		X	X	X	X	X
Lymphoid hyperplasia												P					
Liver		X	X			X	X	X	X	X	X	X	X	X	X	X	X
Nonsuppurative pericholangitis				1	1												
Kidney		X	X	X	X		X		X	X	X	X	X		X	X	X
Focal interstitial nephritis						1		1						1			
Small intestine		X	X	X	X	X	X	X	X	X	X	X	X	X	X	X	X
Large intestine		X	X	X	X	X	X	X	X	X	X	X	X	X	X	X	X
Salivary gland		X	O	X	X	X	X	X	X	X	X	X	X	X	O	X	X
Urinary bladder		X	X	X	X	X	X	X	X	X	X	X	X	X	X	X	X
Harderian gland		X	X	X	X	X	X	X	X	X	X	X	X	X	X	X	O
Skin		X	X	X	X	X	X	X	X	X	X	X	X	X	X	X	X
Anus		X	X	X	X	X	X	X	X	X	X	X	X	X	X	X	X
Trachea		X	X	X	X	X	X	X	X	X	X	X	X	X	X	X	X
Cervical lymph nodes																	
Lymphoid hyperplasia												P					

Type of Finding:

O = Tissue Absent
X = Tissue Examined and Not Remarkable
A = Autolysis
P = Finding Present

Degree of Finding:

1 = Minimal
2 = Slight
3 = Moderate
4 = Moderately Severe
5 = Severe

HWBUI0001851

TABLE J2. MICROSCOPIC EXAMINATION FOR ENDOPARASITES AND BACTERIA IN F_0 RATS IN THE LIFETIME FEED STUDIES OF INTERMEDIATE-RANGE CHRYSOTILE ASBESTOS

Animal/Specimen Number (a)	Microorganisms Identified (b)
133/3726	1+ Coliform
134/3727	1+ Coliform
135/3728	1+ Coliform; 1+ *Proteus vulgaris*
136/3729	1+ Coliform
137/3730	1+ Coliform; 1+ *Proteus vulgaris*
138/3731	1+ Coliform
139/3732	1+ Coliform
140/3733	1+ Coliform
141/3734	No growth
142/3735	2+ Coliform
143/3736	1+ Coliform; 1+ *Proteus vulgaris*
144/3737	1+ Coliform
145/3738	1+ Coliform
146/3739	1+ Coliform
147/3740	2+ Coliform; 1+ *Proteus vulgaris*
148/3741	1+ Coliform

(a) Date of specimen: 10/13/77
(b) Lung, spleen, feces, and tracheal wash were examined for each specimen; no growth observed in the spleen or lungs; no mycoplasma isolated from tracheal washings.

HWBUI0001852

III. Pathogen Burden Summary: F_1

Sections of brain, heart, lung, spleen, liver, kidney, small intestine, large intestine, salivary gland, urinary bladder, harderian gland, skin, and anus were examined from four males and four females in the control and dosed groups of the F_1 generation which were killed for pathology burden (Tables J3-J5).

Evidence of early chronic respiratory disease, consisting of minimal-to-slight peribronchial lymphoid hyperplasia, was present in nearly all animals.

In sections of kidney, small foci of regenerative tubule epithelium were noted in the cortex of one dosed male. Small foci of mineralization were noted in the medullary of one dosed and two control females.

The remaining tissues examined were not remarkable.

HWBUI0001853

TABLE J3. MURINE VIRUS ANTIBODY DETERMINATION IN F_1 RATS IN THE LIFETIME FEED STUDIES OF INTERMEDIATE-RANGE CHRYSOTILE ASBESTOS

Sample Number	Complement Fixation	
	Sendai	LCM
197	–	–
198	–	–
199	–	–
200	–	–
201	–	–
202	–	–
203	–	–
204	–	–
205	–	–
206	–	–
207	–	–
208	–	–
209	–	–
210	–	–
211	–	–
212	–	–
Significant titer	10	10

HWBUI0001854

TABLE J4. INDIVIDUAL HISTOPATHOLOGIC FINDINGS IN F_1 RATS IN THE LIFETIME FEED STUDIES OF INTERMEDIATE-RANGE CHRYSOTILE ASBESTOS

	Untreated Control								Intermediate-Range							
	Male				Female				Male				Female			
Animal Number	2 1 3	2 1 4	2 1 5	2 1 6	2 2 1	2 2 2	2 2 3	2 2 4	2 1 7	2 1 8	2 1 9	2 2 0	2 2 5	2 2 6	2 2 7	2 2 8
Organ and Description																
Brain	X	X	X	X	X	X	X	X	X	X	X	X	X	X	X	X
Heart	X	X	X	X	X	X	X	X	X	X	X	X	X	X	X	X
Lung										X						
Peribronchial lymphoid hyperplasia	1	1	1	2	1	1	1	1	1		2	1	1	1	1	2
Spleen	X	X	X	X	X	X	X	X	X	X	X	X	X	X	X	X
Liver	X	X	X	X	X	X	X	X	X	X	X	X	X	X	X	X
Kidney	X	X	X	X		X	X	X	X	X	X			X	X	X
Foci of regenerative tubule epithelium												P				
Foci of mineralization					P								P			
Small intestine	X	X	X	X	X	X	X	X	X	X	X	X	X	X	X	X
Large intestine	X	X	X	X	X	X	X	X	X	X	X	X	X	X	X	X
Salivary gland	X	X	X	X	X	X	X	X	X	X	X	X	X	X	X	X
Urinary bladder	X	X	X	X	O	O	O	X	X	X	X	X	X	X	O	X
Lacrimal gland	X	X	X	X	X	X	X	X	X	X	X	X	X	X	X	X
Skin	X	X	X	X	X	O	X	X	X	O	X	X	X	X	X	X
Anus	X	X	X	X	X	X	X	X	X	X	X	X	X	X	X	X

Type of Finding:

O = Tissue Absent
X = Tissue Examined and Not Remarkable
A = Autolysis
P = Finding Present

Degree of Finding:

1 = Minimal
2 = Slight
3 = Moderate
4 = Moderately Severe
5 = Severe

HWBUI0001855

TABLE J5. MICROSCOPIC EXAMINATION FOR ENDOPARASITES AND BACTERIA IN F_1 RATS IN THE LIFETIME FEED STUDIES OF INTERMEDIATE-RANGE CHRYSOTILE ASBESTOS

Animal/Specimen Number (a)	Microorganisms Identified (b)
213/3897	4+ Group D Streptococcus; 1+ Micrococcus; 3+ Coliform; 1+ *Pseudomonas aeruginosa*
214/3898	1+ Coliform; 4+ Group D Streptococcus; 3+ Bacillus; 1+ *Proteus vulgaris*
215/3899	1+ Coliform; 4+ Group D Streptococcus; 1+ Micrococcus; 4+ Diphtheroids
216/3900	1+ Coliform; 4+ Group D Streptococcus; 1+ Micrococcus; 4+ Diphtheroids; 1+ *Staphylococcus epidermidis*
217/3901	1+ Coliform; 4+ Group D Streptococcus; 4+ Diphtheroids
218/3902	2+ Bacillus; 3+ Group D Streptococcus; 1+ *Pseudomonas aeruginosa*
219/3903	1+ Coliform; 4+ Group D Streptococcus; 3+ Micrococcus; 4+ Diphtheroids; 1+ *Proteus vulgaris*; 1+ *Pseudomonas aeruginosa*
220/3904	3+ Bacillus; 4+ Group D Streptococcus; 3+ Micrococcus; 1+ *Pseudomonas aeruginosa*
221/3905	3+ Coliform; 4+ Group D Streptococcus; 1+ Micrococcus; 4+ Diphtheroids; 1+ *Proteus morganii*
222/3906	1+ Coliform; 1+ *Proteus morganii*; 4+ Group D Streptococcus; 3+ Micrococcus; 3+ Diphtheroids
223/3907	1+ Bacillus; 4+ Group D Streptococcus; 1+ Micrococcus
224/3908	1+ Coliform; 4+ Diphtheroids; 4+ Group D Streptococcus; 2+ Micrococcus
225/3909	1+ *Proteus vulgaris*; 4+ Group D Streptococcus; 1+ Coliform; 1+ Micrococcus
226/3910	1+ Micrococcus; 4+ Group D Streptococcus; 1+ *Pseudomonas aeruginosa*
227/3911	1+ Coliform; 4+ Group D Streptococcus; 3+ *Proteus vulgaris*; 1+ Micrococcus
228/3912	1+ Coliform; 1+ Micrococcus; 1+ *Proteus vulgaris*; 4+ Group D Streptococcus

(a) Date of specimen: 2/9/78
(b) Lung, spleen, feces, and tracheal wash were examined for each specimen; no growth observed in the spleen or lungs; no mycoplasma isolated from tracheal washings.

HWBUI0001856

HWBUI0001857

APPENDIX K

CLINICAL SIGNS IN RATS IN THE LIFETIME FEED STUDIES OF SHORT-RANGE CHRYSOTILE ASBESTOS

HWBUI0001858

TABLE K1. SUMMARY OF CLINICAL SIGNS OBSERVED IN RATS BEFORE MORIBUND KILL IN THE LIFETIME FEED STUDIES OF SHORT-RANGE CHRYSOTILE ASBESTOS: UNTREATED CONTROL (a)

	Weeks 75-79		Weeks 80-84		Weeks 85-89		Weeks 90-94	
	Male	Female	Male	Female	Male	Female	Male	Female
Number of animals killed in moribund condition	2	3	1	2	5	5	3	2
Pale				1	2		1	
Thin				1	1		1	
Hunched		1		1				
Head tilt							1	
Eyes pale						1	1	
Eyes lacrimating		1						
Dark crust or red stains surrounding eyes		1				1		
Depressed					2			
Labored respiration			1					
Wheezing				1				
Abdomen dark							1	
Abdomen distended and/or firm							1	
Palpable mass in abdomen				1	4	2	2	1
Tissue mass (abscessed)-- inguinal, pelvis, ear, neck, nose, face, axilla, back, flank, or abdomen						4		
Alopecia			1					
Inactive					1			
Urine stains		1		1		1	1	
Red discharge around nose and anal area	1							
Bloody crust around nose and front paws or head				1			1	
Circling							1	
Loss of equilibrium							1	
Paralysis in hindlegs						1		
Muscle tone flaccid							1	
Testes dark							1	

	Weeks 95-99		Weeks 100-104	
	Male	Female	Male	Female
Number of animals killed in moribund condition	4	1	3	9
Pale	1		2	5
Thin	3	1	1	3
Hunched	1			
Head tilt		1		1
Eyes pale	1		1	
Malocclusion	1			
Depressed	2	1	2	4
Aggressive-like behavior	1			
Rapid respiration	1			
Wheezing	3			
Palpable mass in abdomen	2		1	3
Tissue mass (abscessed)-- inguinal, pelvis, ear, neck, nose, face, axilla, back, flank, or abdomen	2		1	4
Extremities appeared yellow			1	
Unkempt				2
Urine stains			1	1
Loss of equilibrium				2
Weakness in hindlegs	1			
Sores and alopecia on back				1
Muscle tone flaccid				1

(a) The intervals were arbitrarily selected based on weeks when a large percentage of moribund kills occurred. Clinical signs observed after the last interval selected were believed not to be readily discernible from signs of aging.

HWBUI0001859

TABLE K2. SUMMARY OF CLINICAL SIGNS OBSERVED IN RATS BEFORE MORIBUND KILL IN THE LIFETIME FEED STUDIES OF SHORT-RANGE CHRYSOTILE ASBESTOS: SHORT RANGE (a)

	Weeks 75-79		Weeks 80-84		Weeks 85-89		Weeks 90-94	
	Male	Female	Male	Female	Male	Female	Male	Female
Number of animals killed in moribund condition	4	3	5	4	7	6	10	10
Pale					2		1	3
Thin	1	1			3	4	3	3
Hunched					1	3	1	3
Head tilt								2
Eye(s)								
Pale		1	1	1	1	2	2	2
Dark						1		
Squinted		1			1			1
Bloody crust or red stains	1				2	2		3
Opaque							1	1
Depressed			2		3	2	3	3
Labored respiration			1				1	
Rapid respiration			2				1	
Cyanotic							1	
Wheezing					1	1	3	
Abdomen distended and/or firm	1		1		1			2
Abdomen dark			1		1			
Palpable mass in abdomen						1	3	5
Nodule(s)					1	1		1
Tissue mass (abscessed)-- head, back, ear, abdomen, axilla, neck, inguinal, side, lower midline, or flank	2	1	1		2	2	3	2
Cold to touch					1			
Rough haircoat					2	2	1	3
Bloody crust on lower midline or front paws and nose					1	1		
Alopecia								1
Urine stains					1	1		5
Soft feces					1			
Animal circling								1
Loss of equilibrium					1			
Ataxia						2		
Muscle tone flaccid					1		1	3
Vagina red and nodule protruding								1
Testes dark			1					
Paralysis or partial paralysis in hindlegs			1				1	1
Inactive						1		

	Weeks 95-99		Weeks 100-104	
	Male	Female	Male	Female
Number of animals killed in moribund condition	14	9	16	15
Pale	4	7	5	8
Thin	4	4	11	9
Hunched		1		
Head tilt			3	2
Eye(s)				
Pale	3	1	1	
Squinted		1		
Bloody crust or red stains	1	1		
Red discharge	1			

HWBUI0001860

TABLE K2. SUMMARY OF CLINICAL SIGNS OBSERVED IN RATS BEFORE MORIBUND KILL IN THE LIFETIME FEED STUDIES OF SHORT-RANGE CHRYSOTILE ASBESTOS: SHORT-RANGE (a) (Continued)

	Weeks 95-99		Weeks 100-104	
	Male	Female	Male	Female
Depressed	3	6	7	11
Labored respiration				1
Wheezing	1		1	
Abdomen distended and/or firm			1	
Palpable mass in abdomen	5	5	9	4
Nodule(s)			1	1
Tissue mass (abscessed)--head, back, ear, abdomen, axilla, neck, inguinal, side, lower midline, or flank	3	5		6
Unkempt			2	
Cold to touch		2	1	1
Rough haircoat	1			
Prostrate in cage	1		1	2
Alopecia		1		
Urine stains		1		1
Malocclusion				1
Loss of righting reflex	1		1	2
Loss of equilibrium			2	3
Muscle tone flaccid	2	1	1	1
Paralysis or partial paralysis in hindlegs	2		3	
Inactive	1		1	
Extremities appeared yellow			1	
Discharge from anus	1			
Right hindleg was stiff, swollen, immobile; sores on surface	1			

(a) The intervals were arbitrarily selected based on weeks when a large percentage of moribund kills occurred. Clinical signs observed after the last interval selected were believed not to be readily discernible from signs of aging.

HWBUI0001861

APPENDIX L

CLINICAL SIGNS IN RATS IN THE LIFETIME FEED STUDIES OF INTERMEDIATE-RANGE CHRYSOTILE ASBESTOS

HWBUI0001862

TABLE L1. SUMMARY OF CLINICAL SIGNS OBSERVED IN RATS BEFORE MORIBUND KILL IN THE LIFETIME FEED STUDIES OF INTERMEDIATE-RANGE CHRYSOTILE ASBESTOS: UNTREATED CONTROL (a)

	Weeks 63-67		Weeks 68-73		Weeks 74-78		Weeks 79-83	
	Male	Female	Male	Female	Male	Female	Male	Female
Number of animals killed in moribund condition					2	1		1
Number of animals with no clinical signs reported					1			
Thin						1		1
Wheezing								1
Tissue mass--chest								1
Loss of equilibrium or righting reflex					1			
Small size						1		
Lying in cage					1			
Spinning					1			

	Weeks 84-88		Weeks 89-93	
	Male	Female	Male	Female
Number of animals killed in moribund condition	4	4	1	1
Number of animals with no clinical signs reported	1			
Pale	1	1		
Thin	1	2		
Hunched	1			
Eyes				
Pale	1	2		1
Dark red stains around		1		
Squinted		1		
Head tilt		2	1	
Head swollen			1	
Wheezing			1	
Labored respiration		1		
Palpable mass in abdomen	1			1
Tissue mass--inguinal, side of body, or leg	2	1		
Loss of equilibrium or righting reflex		1		
Ataxia		1		
Depressed		1		
Loss of pain perception		1		
Circling		1		
Low feed consumption			1	
Urine stains		1		

(a) The intervals were arbitrarily selected based on weeks when a large percentage of moribund kills occurred. Clinical signs observed after the last interval selected were believed not to be readily discernible from signs of aging.

HWBUI0001863

TABLE L2. SUMMARY OF CLINICAL SIGNS OBSERVED IN RATS BEFORE MORIBUND KILL IN THE LIFETIME FEED STUDIES OF INTERMEDIATE-RANGE CHRYSOTILE ASBESTOS: DMH (a)

	Weeks 63-67		Weeks 68-73		Weeks 74-78		Weeks 79-83	
	Male	Female	Male	Female	Male	Female	Male	Female
Number of animals killed in moribund condition	1	1	1	2	15	12	1	10
Number of animals with no clinical signs reported				1	5	8		
Pale								5
Thin					1		1	2
Hunched					3		1	2
Eyes								
Pale					1	1	1	1
Bloody crust, dark discharge		1			1	1		1
Discharge from nose and mouth	1							
Red discharge from ear					1			
Wheezing	1							
Labored respiration					1			2
Rapid respiration								1
Inactivity and/or depression	1							2
Abdomen distended (bloated) and/or firm		1			1			
Palpable mass in abdomen					1			6
Tissue mass--head, inguinal, neck, ear, throat, back, perineal, or abdomen					1		1	3
Rough haircoat							1	
Discolored discharge around vagina						1		
Stains on fur	1		1		1			
Fecal stains				1				
Discolored (red) discharge or stains around anus					4	2		
Nodule protruding from anus					2	1		
Body (extremities) had yellow appearance					1	1		2
Animal appeared paralyzed								1
Cold to touch	1							

	Weeks 84-88		Weeks 89-93	
	Male	Female	Male	Female
Number of animals killed in moribund condition	13	22	6	5
Number of animals with no clinical signs reported	1	4		
Pale	4	8	1	2
Thin	4	4	3	
Hunched	4	4		
Eyes				
Pale		2	2	2
Opaque or cloudy	1		1	
Lacrimating			1	1
Bloody crust, dark discharge	1		1	
Bloody crust around mouth	1			
Red discharge from ear		1		
Head tilt	2	1		
Malocclusion	2			
Wheezing	2	1	1	
Labored respiration		1	1	
Circling	1			

HWBUI0001864

TABLE L2. SUMMARY OF CLINICAL SIGNS OBSERVED IN RATS BEFORE MORIBUND KILL IN THE LIFETIME FEED STUDIES OF INTERMEDIATE-RANGE CHRYSOTILE ASBESTOS: DMH (a)
(Continued)

	Weeks 84-88		Weeks 89-93	
	Male	Female	Male	Female
Inactivity and/or depression	3	4	1	
Abdomen distended (bloated) and/or firm			1	
Palpable mass in abdomen	1	12	3	4
Tissue mass--head, inguinal, neck, ear, throat, back, perineal, or abdomen	6	4	2	1
Nodule		1	2	1
Rough haircoat	2		2	
Swelling around vagina		1		
Discolored discharge around vagina				1
Urine stains	1	1		
Discolored (red) discharge or stains around anus	2		1	1
Nodule protruding from anus	2	1	1	1
Body (extremities) had yellow appearance	1	1		
Muscle tone flaccid				1
Soft feces	3		1	

(a) The intervals were arbitrarily selected based on weeks when a large percentage of moribund kills occurred. Clinical signs observed after the last interval selected were believed not to be readily discernible from signs of aging.

HWBUI0001865

TABLE L3. SUMMARY OF CLINICAL SIGNS OBSERVED IN RATS BEFORE MORIBUND KILL IN THE LIFETIME FEED STUDIES OF INTERMEDIATE-RANGE CHRYSOTILE ASBESTOS: INTERMEDIATE RANGE (a)

	Weeks 63-67		Weeks 68-73		Weeks 74-78		Weeks 79-83	
	Male	Female	Male	Female	Male	Female	Male	Female
Number of animals killed in moribund condition		1	1	11	11	7	2	2
Number of animals with no clinical signs reported			1	1	8	6		1
Pale				1				
Thin							1	
Hunched							1	
Eyes								
Pale		1					1	
Bloody crust surrounding both eyes				1		1		
Lacrimating						1		
Labored respiration					1		1	
Wheezing					1			
Depression							1	
Ataxia					1			
Loss of equilibrium							1	
Discharge (red) from anus					1			
Stains on fur--paws, nose, or eye		1						
Rough haircoat							1	
Abdomen distended and/or firm		1		1				
Tissue mass--axilla								1

	Weeks 84-88		Weeks 89-93		Weeks 94-98		Weeks 99-103	
	Male	Female	Male	Female	Male	Female	Male	Female
Number of animals killed in moribund condition	7	6	8	9	6	11	11	13
Number of animals with no clinical signs reported				1				
Pale	2		2			4	6	8
Thin	4	2	2	3	4	2	8	4
Hunched	1	2	2					
Eyes								
Pale	1	4	4	1		5		
Bloody crust surrounding both eyes	1							
Squinted	1				1			
Opaque	1							
Head tilt	1		1	1		3	1	1
Malocclusion				1		1		
Labored respiration	1	1		1	1	1	1	
Wheezing	1	1		1	1			
Chest firm				1				
Salivating					2			
Alopecia				2				
Inactive						3	1	2
Depression	3	1	2	1	2	5	4	3
Loss of equilibrium						2	1	2
Loss of righting reflex					1	1		
Discharge (red) from anus			1					
Discharge (red) from vagina								1
Nodule		2	2					1
Unkempt					1		2	1
Bloody crust on paws								1
Stains on fur--paws, nose, or eye	1				1		1	
Rough haircoat	2		1					

HWBUI0001866

TABLE L3. SUMMARY OF CLINICAL SIGNS OBSERVED IN RATS BEFORE MORIBUND KILL IN THE LIFETIME FEED STUDIES OF INTERMEDIATE-RANGE CHRYSOTILE ASBESTOS: INTERMEDIATE RANGE (a) (Continued)

	Weeks 84-88		Weeks 89-93		Weeks 94-98		Weeks 99-103	
	Male	Female	Male	Female	Male	Female	Male	Female
Abdomen distended and/or firm	1		2					
Abdomen dark			2					
Palpable mass in abdomen	3	2	3	1		6	3	7
Tissue mass--head, neck, axilla, chest, mouth, neck, shoulder, hip, or lower midline	2	3		3	2	2	4	2
Cold to touch	1							
Animal prostrate in cage								2
Extremities yellow	1							
Scrotum dark			2					
Muscle tone flaccid	1		3			1		
Spastic movement					1			
Paralysis--flaccid							1	
Protruding mass from vagina								1

(a) The intervals were arbitrarily selected based on weeks when a large percentage of moribund kills occurred. Clinical signs observed after the last interval selected were believed not to be readily discernible from signs of aging.

HWBUI0001867

TABLE L4. SUMMARY OF CLINICAL SIGNS OBSERVED IN RATS BEFORE MORIBUND KILL IN THE LIFETIME FEED STUDIES OF INTERMEDIATE-RANGE CHRYSOTILE ASBESTOS: IR + DMH (a)

	Weeks 63-67		Weeks 68-73		Weeks 74-78		Weeks 79-83	
	Male	Female	Male	Female	Male	Female	Male	Female
Number of animals killed in moribund condition	1	2	3	3	17	10	13	15
Number of animals with no clinical signs reported			2		14	8	7	7
Pale				1			1	1
Thin	1	1	1					1
Hunched	1	1	1					
Eyes								
Pale				2			1	4
Lacrimating						1		1
Red discharge and/or bloody (dark) crust surrounding eye(s)	1	1	1	1				2
Bloody crust around nose			1					1
Ears appeared yellow		1						
Dark red crust in ear or red discharge from ear					1			
Swelling around neck								1
Wheezing		1	1				1	
Labored respiration							1	
Depression or inactivity				2				
Tissue mass--inguinal, axilla, chest, perineal, ear, head, neck, or side of body	1	1	1				2	2
Abdomen distended (bloated)		1		3		1	1	1
Abdomen firm				2		1		1
Palpable mass in abdomen							1	4
Nodule protruding from anus							2	
Discharge (red) from anus					1			3
Discolored discharge from vagina								1
Urine stains		2		2				
Fecal stains or soft feces				1		1	1	
Rough haircoat	1						1	
Cold to touch				1				
Alopecia								1
Yellowish appearance or extremities appeared yellow							1	
Movement absent in hindlegs					1			
Discolored urine							1	
Scrotum dark							1	

	Weeks 84-88		Weeks 89-93	
	Male	Female	Male	Female
Number of animals killed in moribund condition	13	18	8	5
Number of animals with no clinical signs reported	1	7		2
Pale	1	7	2	
Thin	3	7	3	1
Hunched	2	1		1
Eyes				
Pale	3		2	3
Dark				1
Opaque				1
Red discharge and/or bloody (dark) crust surrounding eye(s)	1		1	1
Red discharge from mouth	1			

HWBUI0001868

TABLE L4. SUMMARY OF CLINICAL SIGNS OBSERVED IN RATS BEFORE MORIBOUND KILL IN THE LIFETIME FEED STUDIES OF INTERMEDIATE-RANGE CHRYSOTILE ASBESTOS: IR + DMH (a) (Continued)

	Weeks 84-88		Weeks 89-93	
	Male	Female	Male	Female
Head tilt	1			1
Dark red crust in ear or red discharge from ear			1	
Wheezing	1		2	
Labored respiration	1			
Rapid respiration	1			
Depression or inactivity	1		2	1
Circling	1			
Tissue mass--inguinal, axilla, chest, pesineal, ear, head, neck, or side of body		3	4	1
Abdomen distended (bloated)	2		1	
Palpable mass in abdomen	4	9	4	3
Nodule			1	
Nodule protruding from anus	4	1		
Discharge (red) from anus	1	1	1	
Discolored discharge from vagina				1
Fecal stains or soft feces	1		1	
Rough haircoat	3	1	2	1
Cold to touch		1		
Left leg had bloody crust and discharge			1	
Yellowish appearance or extremities yellow	1	2		
Muscle tone flaccid		1		1
Disclored urine				2

(a) The intervals were arbitrarily selected based on weeks when a large percentage of moribund kills occurred. Clinical signs observed after the last interval selected were believed not to be readily discernible from signs of aging.

HWBUI0001869

TABLE L5. SUMMARY OF CLINICAL SIGNS OBSERVED IN RATS BEFORE MORIBUND KILL IN THE LIFETIME FEED STUDIES OF INTERMEDIATE-RANGE CHRYSOTILE ASBESTOS: IR/PW (a)

	Weeks 63-67		Weeks 68-73		Weeks 74-78		Weeks 79-83	
	Male	Female	Male	Female	Male	Female	Male	Female
Number of animals killed in moribund condition	0	1	2	0	1	3	3	2
Number of animals with no clinical signs reported			1		1	2	2	1
Thin								1
Hunched								1
Bloody crust surrounding eye(s)						1		1
Eye lacrimating								1
Labored respiration		1					1	
Wheezing						1		1
Tissue mass--ear, back, side of body, or chest			1			1		
Depression		1						
Animal appeared paralyzed							1	
Prostrate in cage		1						
Rough haircoat								1

	Weeks 84-88		Weeks 89-93		Weeks 94-98		Weeks 99-103	
	Male	Female	Male	Female	Male	Female	Male	Female
Number of animals killed in moribund condition	1	3	0	3	3	3	2	3
Number of animals with no clinical signs reported				1				
Pale						1	1	2
Thin		3			1	2	1	2
Hunched		2						
Eye(s) pale				2	3			1
Bloody crust surrounding eye(s)				1				
Red discharge from nose	1							
Bloody crust around nose		1						
Head tilt						1		
Wheezing	1	1						1
Abdomen distended (bloated) and dark					1			
Palpable mass or masses in abdomen				2	1		1	1
Tissue mass--ear, back, side of body, or chest		1		1	1	2	1	3
Lack of coordination or equilibrium		1				1		
Depression or inactivity		1		2	2	1		
Muscle tone flaccid						1		
Prostrate in cage								1
Urine stains		1				2		
Discolored urine				1				
Discharge (red) from vagina								1

(a) The intervals were arbitrarily selected based on weeks when a large percentage of moribund kills occurred. Clinical signs observed after the last interval selected were believed not to be readily discernible from signs of aging.

HWBUI0001870

HWBUI0001871

APPENDIX M

DATA AUDIT SUMMARY

HWBUI0001872

APPENDIX M. DATA AUDIT SUMMARY

The experimental data from the lifetime feed studies of chrysotile asbestos (short-range and intermediate-range fibers) in F344/N rats conducted at Hazleton Laboratories, Inc., were audited for completeness, consistency, and accuracy of the experimental data and for consistency of scientific procedures with Good Laboratory Practices. The in-life phase of the study was completed before NTP's requirement for full compliance with Good Laboratory Practices regulations in October 1981. The experimental data audit was performed by Dynamac Corporation in March 1984. The audit team consisted of the following: Ms. Shirley Corson, Pathology; Mr. Chris Dippel, Toxicology and Chemistry; Mr. James Konz, Pathology; Mr. Curt Lunchick, Toxicology; Mr. James Plautz, Toxicology and Chemistry; Dr. Ronald Schueler, Pathology; and Dr. Karen Whitkin, Toxicology.

The full report of the audit of the chrysotile asbestos studies is on file at the National Toxicology Program, NIEHS. The audit consisted of (a) review of records for the in-life portion of the study, including clinical observations and body weight data for 10% of the animals, mortality records for 20% of the animals, and all environmental records; (b) review of chemistry data including fiber characterization, fiber distribution (homogeneity) and concentration in diet preparation method development, and diet analysis for 10% of the samples; and (c) review of pathology data consisting of (i) a 20% random sample of individual animal pathology records (IADR's), (ii) slide/block match for a 20% random sample of animals in all groups, and (iii) wet tissues for a 10% random sample of animals in groups 82M, 82F, 93M, 93F, 95M, and 95F.

The audit identified no major problems with the conduct of the study or with collection or reporting of the experimental data. The analytical chemistry data for chrysotile asbestos were adequate and supported the stated conclusions of the Technical Report. Although dosing records were present for the two groups receiving DMH, records for preparation and analysis of DMH dose solutions were not available for audit. Animals were identified by ear tags. Although ear tags were missing from wet tissues in approximately 10% of the bags opened, in all the remaining wet tissue bags the tag number corresponded with the bag number. Apparent discrepancies between gross observations during necropsy and microscopic diagnoses were infrequent and consisted predominantly of minor tissue alterations with no impact on study interpretation. For seven rats (081M-one, 082M-four, 082F-one, 092F-one), cecal or colon "nodules" were noted, apparently by the pathology technician ("trimmer"). Pathologic changes, however, were not observed on microscopic examination, although lymphoid nodules (normal structure) were sometimes present. For one rat (091M), two colon "polyps" were described but microscopic examination revealed two lymphoid nodules. The remaining wet tissue (colon) did not show evidence of any polyps. Thus, the apparent discrepancies in gross microscopic correlation for the intestine can be explained by prominent lymphoid structures, which are a normal component of the intestine. The slide/block match was generally good. One or two slides for each of three rats were labeled with the wrong slide number but were appropriately identified by animal and histology number. For each of two other rats, one slide was identified by the incorrect histology number but matched the appropriately labeled block.

In conclusion, no discrepancies were found that would influence the final interpretation of this experiment.

☆U.S. GOVERNMENT PRINTING OFFICE: 1985 491 292 21291

HWBUI0001873