found in only one animal and the fibrotic changes in this group could therefore not be attributed to infection. Although the progression of the lesions in this group was exceptionally slow up to 100 days, a marked increase in collagen was found thereafter, till the termination of the experiment at 220 days. An advanced grade-3 fibrosis was produced in this period (Fig. 4), compared to a grade-1, in animals without infection, in the asbestos group.

No malignant tumours or any neoplasms of the pleura were observed, although pleural thickening was found in a few cases with infection and in most animals injected with the quartz-asbestos mixture (Fig. 5).



Fig. 2. Rat lung with infection, 200 days after the injection of 50 mg. of asbestos dust, showing grade-2 fibrosis. (Silver impregnation × 150.)

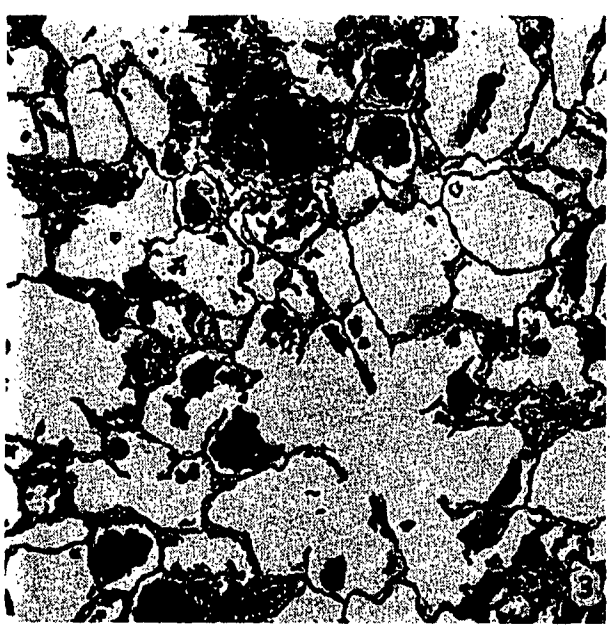

Fig. 3. Rat lung without infection, 220 days after the injection of 50 mg. of asbestos dust, showing grade-1 fibrosis, dust aggregates, and alveolar wall thickening. (Silver impregnation × 150.)

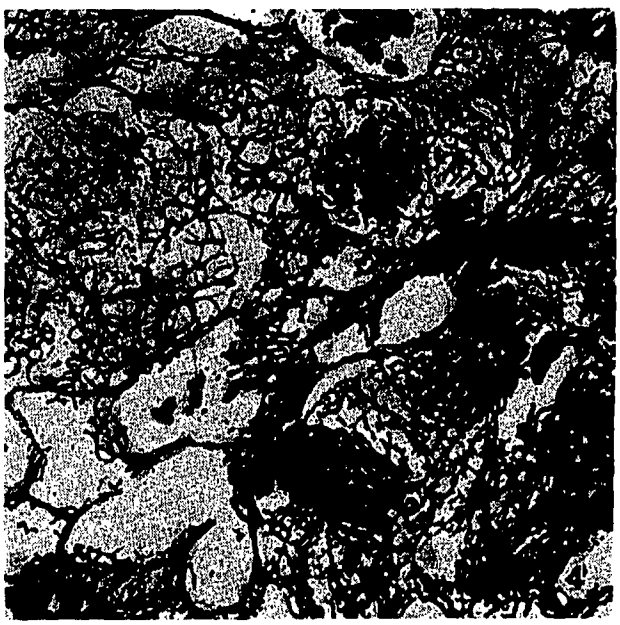

Fig. 4. Rat lung section, 200 days after the injection of dust consisting of 12·5 mg. quartz + 37·5 mg. asbestos, showing massive grade-3 fibrosis. (Silver impregnation × 150.)

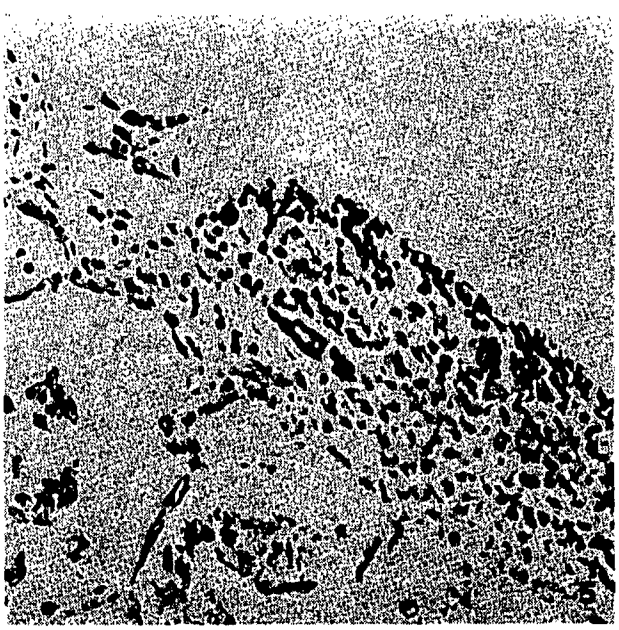

Fig. 5. Part of lung section, 180 days after injection of a quartz-asbestos mixture, showing pleural thickening with mononuclear-cell infiltration. (H. & E. × 150.)