Name _____

No. 35376

Interpretation of Single roentgenogram of chest

taken on 2/3/72

Plant: Millington, N. J.

Reading Date 2/15/72

No abnormality of the lungs is seen. Bilateral cancified pleura plaques on the diaphragm are noted.

GEORGE W. WRIGHT, M. D.
Saint Luke's Hospital
11311 Shaker Boulevard
Cleveland, Ohio 44104



KK 12952

H Conf dist

Name [redacted] Plant: Millington, N.J.

No. 55376 Reading Date 11-9-70

Interpretation of single roentgenogram of chest

taken on 10-30-70

No abnormality seen within the lungs. There are bilateral calcified pleura plaques on the diaphragms.

GEORGE W. WRIGHT, M. D.
Saint Luke's Hospital
11311 Shaker Boulevard
Cleveland, Ohio 44104

KK 2983

Name

Plant: Millington, New Jersey

No. 35376

Reading Date 9-11-68

Interpretation of single roentgenogram of chest

taken on 8-30-68

No significant abnormality seen.

See previous reports regarding the pleura plaque calcifications.

GEORGE W. WRIGHT, M. D.
Saint Luke's Hospital
11311 Shaker Boulevard
Cleveland, Ohio 44104

KK129854

Name _____ Plant: Millington, N.J.

No. 35376 Reading Date 4-20-66

Interpretation of single roentgenogram of chest

taken on 4-6-66

No significant abnormality seen in the lungs and a comparison of this film to others of 1953, 1955, 1957, 1960, and 1962 shows no appreciable change in the lung markings.

In the current film there are small calcific deposits on the diaphragmatic surface of each lung field. In retrospect, these can be seen as early as 1955 but have increased in size. These are rather commonly seen in persons who have been exposed to "talc" or other forms of asbestos but may originate from other causes.

GEORGE W. WRIGHT, M. D.
Saint Luke's Hospital
11311 Shaker Boulevard
Cleveland, Ohio 44104

KK 12955

Name

Plant: Millington, N. J.

No. 92-62

Reading Date: 6/27/62

Interpretation of single roentgenogram of chest

taken on 6/21/62

No significant abnormality seen.

GEORGE W. WRIGHT, M. D.
Saint Luke's Hospital
11311 Shaker Boulevard
Cleveland 4, Ohio

KK12296

NGC

Name

Plant : Millington, New Jersey

No. 11-60

Reading Date : 3/30/60

Interpretation of single roentgenogram of chest

taken on 3/22/60 compared with taken on

No significant abnormality seen.

GEORGE W. WRIGHT, M. D.
Saint Luke's Hospital
11311 Shaker Boulevard
Cleveland 4, Ohio

KK 2957

GEORGE W. WRIGHT, M. D.

DEPARTMENT OF
EXPERIMENTAL MEDICINE

ST. LUKE'S HOSPITAL
11311 SHAKER BLVD.
CLEVELAND 4, OHIO

January 3, 1956

No. 55-23-B
Name

National Gypsum Co.
Millington, N. J.

Interpretation of single roentgenogram
of chest taken on 12-1-55
compared with taken on 9-15-53

No change.

KK-2958

GEORGE W. WRIGHT, M.D.

DEPARTMENT OF
EXPERIMENTAL MEDICINE

SAINT LUKE'S HOSPITAL
11311 SHAKER BLVD.
CLEVELAND 4, OHIO

No. R 3790
Name.

Natl. Gypsum Co.
Millington, N.J.

Interpretation of stereo roentgenogram
of chest taken on 4-9-54
compared with taken on

Stereo films as of this date show no nodulation. There is a moderate degree of increase of border vascular marking.

The descending aorta is either very tortuous or the site of an aneurysm.

KK 12959

GEORGE W. WRIGHT, M. D.

DEPARTMENT OF
EXPERIMENTAL MEDICINE

ST. LUKE'S HOSPITAL
11311 SHAKER BLVD.
CLEVELAND 4, OHIO

January 3, 1956

No. 55-33-B
Name

National Gypsum Co.
Millington, N. J.

Interpretation of single roentgenogram
of chest taken on 11-30-55
compared with taken on 9-15-53 & 4-9-54

There has been no change.

The abnormal degree of bronchovascular exaggeration persists. My records fail to show that I received an occupational history for this man. Same is still desired!

A small calcific plaque in the left diaphragmatic pleura and a small circular cyst with slight bone density around it are seen in the 4th left and 3rd and 6th right ribs. These were present in 1953.

KK 12990

GEORGE W. WRIGHT, M.D.

DEPARTMENT OF
EXPERIMENTAL MEDICINE

SAINT LUKE'S HOSPITAL
11311 SHAKER BLVD.
CLEVELAND 4, OHIO

No.36
Name

51. Gypsum Co.
llington, N.J.

Interpretation of sinde roentgenogram
of chest taken on 9-15-53
compared with taken on

The bronchovascular markings are markedly exaggerated throughout both lungs. In some areas, notably the middle thirds on both sides, there are indistinct shadows suggestive of true nodulation.

A stereo roentgenogram and careful industrial history- especially as to silico and asbestos exposure- is needed in order to adequately assay this X-ray film.

KK12991

GEORGE W.

DEPARTMENT OF
EXPERIMENTAL MEDICINE

No. 41
Name

Natl. Gypsum Co.
Millington, N.J.

Interpretation of single roentgenogra
of chest taken on 9-15-53
compared with taken on

No abnormality seen

KK12992

Name [redacted] Plant: Millington, N. J.

No. 35376 Reading Date 2/15/72

Interpretation of Single roentgenogram of chest

taken on 2/3/72

No abnormality of the lungs is seen. Bilateral cancified pleura plaques on the diaphragm are noted.

GEORGE W. WRIGHT, M. D.
Saint Luke's Hospital
11311 Shaker Boulevard
Cleveland, Ohio 44104

KK 2995

Name

Plant: Millington, N.J.

No. 55376

Reading Date 11-9-70

Interpretation of single roentgenogram of chest

taken on 10-30-70

No abnormality seen within the lungs. There are bilateral calcified pleura plaques on the diaphragms.

GEORGE W. WRIGHT, M. D.
Saint Luke's Hospital
11311 Shaker Boulevard
Cleveland, Ohio 44104

KK 129939

Name (redacted)

Plant: Millington, New Jersey

No. 35376

Reading Date 9-11-68

Interpretation of single roentgenogram of chest

taken on 8-30-68

No significant abnormality seen.

See previous reports regarding the pleura plaque calcifications.

GEORGE W. WRIGHT, M. D.
Saint Luke's Hospital
11311 Shaker Boulevard
Cleveland, Ohio 44104

KK13000

Name

Plant: Millington, N.J.

No. 25376

Reading Date 4-20-66

Interpretation of single roentgenogram of chest

taken on 4-6-66

No significant abnormality seen in the lungs and a comparison of this film to others of 1953, 1955, 1957, 1960, and 1962 shows no appreciable change in the lung markings.

In the current film there are small calcific deposits on the diaphragmatic surface of each lung field. In retrospect, these can be seen as early as 1955 but have increased in size. These are rather commonly seen in persons who have been exposed to "talc" or other forms of asbestos but may originate from other causes.

GEORGE W. WRIGHT, M. D.
Saint Luke's Hospital
11311 Shaker Boulevard
Cleveland, Ohio 44104

KK 13001

Plant: Millington, N. J.

Name

Reading Date: 6/27/62

No. 92-62

Interpretation of single roentgenogram of chest

taken on 6/21/62

No significant abnormality seen.

GEORGE W. WRIGHT, M. D.
Saint Luke's Hospital
11311 Shaker Boulevard
Cleveland 4, Ohio

AK 13002

NGC

Name

Plant : Millington, New Jersey

No. 11-60

Reading Date : 3/30/60

Interpretation of single roentgenogram of chest

taken on 3/22/60 compared with taken on

No significant abnormality seen.

GEORGE W. WRIGHT, M. D.
Saint Luke's Hospital
11311 Shaker Boulevard
Cleveland 4, Ohio

AA 13003

Name:

Plant: Millington, N.J. (NOC)

No. 3/57/B

Reading Date: 9/17/57

Interpretation of Single roentgenogram of chest

taken on 9/11/57 compared with taken on

No significant abnormality seen.

GEORGE W. WRIGHT, M. D.
Saint Luke's Hospital
11311 Shaker Boulevard
Cleveland 4, Ohio

13014

This blank to be filled out and sent to the Company on the day the injured employe receives last treatment.

H. O. APP'D BY

DATE PAID

CHECK NO.

Statement of Dr. Richard A. Raffman, M.D., F.A.C.S

Name of Employer? National Gypsum Company

e of Injured? Age? 32 Date of Injury? 6/3 19 69

First aid rendered by? John Chrobak, M. D. Subsequent aid? Richard A. Raffman, M.D., F.A.C.S.

CODE: O—office. V—house visit. H—hospital visit. N—night visit. X—X-ray. S—operation.

19 69	1	2	3	4	5	6	7	8	9	10	11	12	13	14	15	16	17	18	19	20	21	22	23	24	25	26	27	28	29	30	31
Jan.																															
Feb.																															
Mar.																															
Apr.																															
May																															
June						CX			S	OD				O				O													
July																															
Aug.																															
Sept.																															
Oct.																															
Nov.																															
Dec.																															

First Aid	Consultation	one each	$10.00	$10 00
Office Visits	three		$7.00	21 00
se Visits			"	
pital Visits			"	
Night Visits			"	
Operations	one		$100.00	100 00
~~XXXX~~ X-ray	one		$10.00	10 00
Other Charges must be itemized and explained fully				
Drugs $1.00				1 00
Total Expense for Medical Aid				$142 00

Diagnosis Metallic foreign body embedded in muscles of left forearm.

Explain in detail any special treatment, if any, giving reasons for same and of what they consisted

Describe treatment Consultation & examination, x-ray, drugs, excision of steel foreign body from left forearm, dressings changed, removal of sutures.

Result Good

Patient refused treatment on = 19

Is patient capable of doing same work as before injury? Yes If not, why?

Patient pronounced able to resume work as of 19

Patient discharged as cured on Referred To John CHrobak, M.D. for further treatment.

Any permanent injury? Describe fully Yes, scar on left forearm.

Dated at Madison, New Jersey (City) (State) this 20th day of June 1969

Dr. Richard A. Raffman, M.D., F.A.C.S.

Street and Number 28 Walnut Street

City and State Madison, New Jersey

3095

STANDARD FORM FOR

SURGEON'S REPORT

Approved by I. A. I. A. B. C.

State's Number For:	File: Carrier: Employer:
Carrier's File No.	
(The spaces above not to be filled in by Employer)	

National Gypsum Company
Millington,
New Jersey

Attention: Mr. Tolin

The Patient

1. Name of Injured Person _____ Age: 52 Sex: M
2. Addres: No. and St. _____ City or Town? _____ State?
3. Name and Address of Employer: National Gypsum Company, Millington, New Jersey

The Accident

4. Date of Accident: 6/3/69 Hour 2:15 P.M. Date disability began _____
5. State in patient's own words where and how accident occurred: "I was driving a chisle, [illegible] of metal, when a piece of steel flew off and landed in my left forearm."

The Injury

6. Give accurate description of nature and extent of injury and state your objective findings: 2 pieces of [illegible] body embedded in the muscles of the left forearm.
7. Will the injury result in (a) Permanent defect? Yes If so, what? Scar in left forearm.
   (b) Facial or head disfigurement? No
   (Permanent disability such as loss of whole or parts of fingers, facial or head disfigurement, etc., must be accurately marked on chart on reverse side of this report.)
8. Is accident above referred to the only cause of patient's condition? Yes If not, state contributing causes: _____
9. Is patient suffering from any disease of the heart, lungs, brain, kidneys, blood, vascular system or any other disabling condition not due to this accident No Give particulars _____
10. Has patient any physical impairment due to previous accident or disease? No Give particulars: _____
11. Has normal recovery been delayed for any reason? No Give particulars: _____

Treatment

12. Date of your first treatment: 6/7/69 Who engaged your services? [redacted]
13. Describe treatment given by you: Consultation & examination, x-ray, drugs, exp[illegible] foreign bodies from left forearm, dressings changed.
14. Were X-Rays taken? Yes By whom? R. A. Raffman, M.D., F.A.C.S. (Name and Address) When? _____
15. X-Ray diagnosis: 2 metallic foreign bodies in forearm.
16. Was patient treated by anyone else? Yes By whom? Dr. Chrobak National Gyp[illegible] (Name and Address) When? _____
17. Was patient hospitalized? No Name and address of hospital: _____
18. Date of admission to hospital: _____ Date of discharge: _____
19. Is further treatment needed? Yes For how long? 2 weeks

Disability

20. Patient ~~was~~ will be able to resume regular work on: 6/11/69
21. Patient ~~was~~ will be able to resume light work on: 6/11/69
22. If death ensued give date: _____

REMARKS: (Give any information of value not included above) _____

I am a duly licensed physician in the State of New Jersey
I was graduated from New York Medical School in New York City Year _____
Date of this report: 6/16/69 (Signed) Richard A. Raffman, M.D.
This report must be signed personally by physician. Address: 28 Walnut St., Madison Telephone _____

13006

FREDERICK S. BARNES, M. D.
FELLOW, AMERICAN COLLEGE OF LEGAL MEDICINE

61 PASSAIC AVENUE
PASSAIC, N. J. 07055

PHONE: 777-3841

File: 712 69 021
Injd:
SS# :
Assd: National Gypsum Co.

Laverack & Haines, Inc.
238 Main St.
Buffalo, N.Y.

Gentlemen:

Herewith, report of orthopedic examination made at this office on 3/10/70:

NAME: [redacted] BORN: USA AGE: 53 MM
SPOUSE: Anna Marie CHILDREN: 2 WT: 168 HT: 5'8" HAIR: Grey EYES: Brown
OCC: Millwright.

OTHER INJURIES: 1960 Herpes Zaster; 1933 fractured l/ankle; 1960 cervical spine injury; 1958 r/thumb, $1,100.

PRESENT HISTORY: On 6/3/69 hitting metal and a piece flew into l/lower arm.

MEDICAL: F/A on D/A - went to Dispensary, exam; next day went to Overlook Hospital, Summit, x-rays; 2 days later saw Dr. Raffman, Madison, x-rays; 6/7/69 adm. to All Souls Hospital, Morristown, surgery by Dr. Raffman, hospitalized 1 day.
Lost 1 day from work.
COMPLAINTS: Pains off and on, mainly in winter.

PHYSICAL FINDINGS:
The petitioner is a well developed, well nourished, adult male.
LEFT FOREARM:
On the radial aspect to the radial side of the dorsum at about the junction of the middle and distal thirds, there is a transverse, difficult to discern, operative scar (about 3 cm. by less than 1). There is no tenderness. He indicates that at times he has some discomfort distal to the scar. There are three, small, healing, superficial, lacerations or abrasions of the radial aspect of the wrist.
At the wrist, dorsiflexion and deviation slightly incomplete, palmar flexion complete. He complains of some discomfort at the extreme of ulnar deviation.
Motion at the elbow complete without discomfort. He is noted to have small, subcutaneous nodules scattered over the upper extremity.
X-rays of the forearm by Dr. Scovern on 3/10/70 with a lead marker over the scar revealed no radio-opaque foreign body in the soft tissue in that region. There was a tiny metallic foreign body in the soft tissues on the medial aspect of the forearm.
A report from Dr. Raffman dated 6/16/69 indicates first treatment 6/7/69 for injury of 6/3. Under history "a piece of steel flew off and landed in my left forearm". Under diagnosis "two pieces of steel foreign bo

COPY

FREDERICK S. BARNES, M. D.
FELLOW, AMERICAN COLLEGE OF LEGAL MEDICINE
61 PASSAIC AVENUE
PASSAIC, N. J. 07055
PHONE: 777-5641

embedded in the muscles of the left forearm". He indicates x-rays by him on 6/7 reveal the foreign bodies.

A report from a doctor whose name I cannot decipher, dated ?/6/69 indicates first treatment 6/5/69 for injury of 6/3. Diagnosis "small laceration on dorsum of left arm". He indicates x-rays at Overlook Hospital reveal "deeply embedded foreign bodies".

An x-ray report from the Overlook Hospital dated 6/4/69 with respect to the left forearm indicates "at least two small, metallic-like densities in the soft tissues of the distal 3rd of the forearm, one adjacent to the radius and the other adjacent to the ulna. On the frontal view, there is an open safety pin on the film presumably a marker with the point of the pin almost in line with the metallic fragment on the radial aspect of the forearm.

Incidentally, in the report from Dr. Raffaah, under treatment, he indicates in part "excision of steel foreign bodies from left forearm".

DIAGNOSIS & CONCLUSION:

Based upon the history and taking into consideration the above noted medical information, the petitioner sustained a penetrating injury of the l/forearm with a small, retaining, metallic foreign body as a result of the June 1969 incident. Thereafter, removal of the metallic, foreign body was accomplished.

Taking into consideration the results of examination together with the above noted medical information, I would suggest that you consider payment to the petitioner permanent disability of about 3-1/2% of the left hand.

Yours truly,

FREDERICK S. BARNES, M. D.

BF
4/13/70

COPY

3.5% = 8 wks @ $40.00

40
8
$320.

MARKET 3-5080

AUDIOMETRIC EVALUATION

1961

ate _____ Center No. _____

ame _____ Age 45 Sex _____ Test No. _____

ested by MAINTENANCE Audiometer _____ Estimated Accuracy: Good ___ Fair ___ Poor ___

PURE TONE AUDIOGRAM

Frequency in Cycles per Second

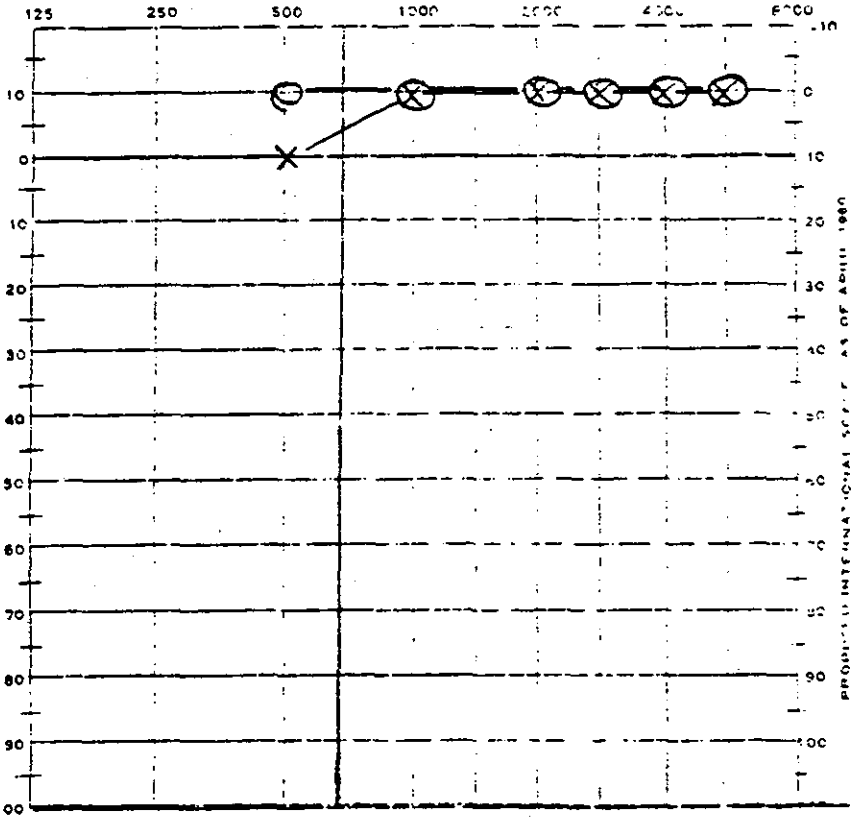

Audiogram Code

	AIR		BONE			
	Unmasked	Masked	Unmasked	Masked	S/L	Color
R	O-O	Δ-Δ	[illegible]	> - >	[illegible]	Red
L	X-X	□-□	[illegible]	< - <	[illegible]	Blue

Average Loss A/C

Freq.	R	L
500		
1000		
2000		
[illegible]		
Avg.		

Additional Tests

SISI

FREQ	250	500	1000	2000	3000	4000	6000
R							
L							

SPEECH HEARING TESTS

Test		R	L	S/N
Sp. Reception Threshold (SRT)		db	db	db
Discrim. Scores PB	Quiet	%	%	%
	Noise	%	%	%

DISTORTED SPEECH TESTS

	Low - Pass	Faint	Comb.
R			
L			

3009

NATIONAL GYPSUM COMPANY

PHYSICAL EXAMINATION RECORD

☐ SALARIED PLANT, OFFICE, SALES DISTRICT Millington
☑ HOURLY

DATE 7/13/71

☐ PRE-EMPLOYMENT ☐ REINSTATEMENT ☑ PERIODIC HEALTH

NAME [redacted] ADDRESS

DATE OF BIRTH 11/12/16 (AGE 54) ☐ SINGLE ☑ MARRIED OTHER

LAST EMPLOYMENT

PREVIOUS MEDICAL

HEIGHT 5'8"

WEIGHT 167

DISFIGUREMENT (INDICATE)

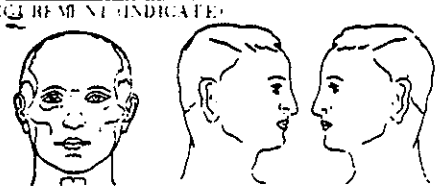

VISION-DISTANT with, w/out glasses: R.E. 20/ L.E. 20/

VISION-NEAR with, w/out glasses: R.E. 20/ L.E. 20/

COLOR VISION:

WASSERMAN Hb: To lab.

URINALYSIS Neg.

SUGAR ALBUMIN

HERNIA Neg

CHEST Neg. CONFIGURATION Well developed EXPANSION

INGUINAL RINGS R N. L N NORMAL ENLARGED RELAXED

HEART N.S.R BLOOD PRESSURE 138/80

OPERATIVE SCARS Neg.

LUNGS Clear

FEMALE APPLICANTS DATE OF LAST MENSTRAL PERIOD MENSES

BACK AND EXTREMITIES – EDEMA, AMPUTATIONS, FUNCTIONAL DEFECTS, DEFORMITIES

Neg.

SPECIFIC FINDINGS – ADDITIONAL

NEUROLOGICAL

Neg.

SKIN ERUPTION Neg

GENERAL CONDITION: ☒ GOOD ☐ FAIR ☐ POOR: EXAMINEE HAS BEEN ADVISED OF SIGNIFICANT FINDINGS ☒ YES ☐ NO

SUMMARY OF PERMANENT DEFECTS, IMPAIRMENTS:

Advised to see Eye Dr. re. spots before eye.

APPLICANT'S SIGNATURE (HERE AND ON REVERSE SIDE) EMOTIONAL STABILITY INTELLIGENCE

JOB ASSIGNMENT ACCEPT ✓ DEFER REJECT PHYSICIAN'S SIGNATURE [signature]

COMPANY APPROVALS

PERSONNEL MANAGER BUFFALO

DISTRICT SALES MANAGER

PLANT MANAGER

SAFETY SUPER.

DATE PART EXAMINED FILM NO.

X-RAY REPORT – RADIOGRAPHIC FINDINGS

3011

M.D.

NATIONAL GYPSUM COMPANY

PLANT, OFFICE, SALES DISTRICT Millington-Hourl

PHYSICAL EXAMINATION RECORD

DATE 9-29-65

☐ PRE-EMPLOYMENT ☐ REINSTATEMENT ☒ PERIODIC HEALTH

[redacted] ADDRESS

DATE OF BIRTH 11/12/16 (AGE 49) ☐ SINGLE ☒ MARRIED OTHER

LAST EMPLOYMENT

HEIGHT	DISFIGUREMENT – FACE, HEAD OR NECK	VISION-DISTANT	VISION-NEAR	WASSERMAN	Hb:
5'8"	1" scar across tip of nose			To lab.	
WEIGHT	1" scar from lat canthus to	C.R.E. 20/30	20/	URINALYSIS	
160	rt eye laterally - 1/2" scar (l) eyelid	U.L.E. 20/40	20/	SUGAR Neg	ALBUMIN Neg

HEART	CHEST	HERNIA	ABDOMEN	L.M.P.
Good Quality No Murmurs	Well developed	Neg	Neg	

CONFIGURATION CHEST EXPANSION	BLOOD PRESSURE	INGUINAL RINGS	NORMAL ENLARGED RELAXED
Equal bilaterally	124/76	R slight weakness slight weakness	

LUNGS	OPERATIVE SCARS
Clear.	None

BACK AND EXTREMITIES – EDEMA, AMPUTATIONS, FUNCTIONAL DEFECTS, DEFORMITIES

grossly normal

CIFIC FINDINGS – NEUROLOGICAL

Neg.

SKIN ERUPTION

Neg

SUMMARY OF PERMANENT DEFECTS, IMPAIRMENTS; EXAMINEE HAS BEEN ADVISED OF SIGNIFICANT FINDINGS ☒ YES ☐ NO

Recommend eye exam. for this man.

EMOTIONAL STABILITY	INTELLIGENCE
Good	Good

APPLICANT'S SIGNATURE	Accept	Condit. Accept	Reject	PHYSICIAN'S SIGNATURE
				G. M. Shkarn

JOB ASSIGNMENT	PREVIOUS MEDICAL

COMPANY APPROVALS	DATE	PART EXAMINED	FILM NO.
PERSONNEL MANAGER BUFFALO	X-RAY REPORT – RADIOGRAPHIC FINDINGS		
DISTRICT SALES MANAGER			
PLANT MANAGER			
SAFETY SUPER.			M.D.

13012

NG 909 Rev. 5-

NATIONAL GYPSUM COMPANY

Sales District

Office

Name | Address [redacted] | Plant Millington, N.J.

ate | Dept. | Check No. 79

Age 46 | Color | S M W D* | Children

PHYSICAL RECORD
(TO BE COMPLETED BY PLANT OR OFFICE)

Arthritis | Epilepsy | Hernia

Operations | List on reverse side any hospital admissions in past 5 years.

Venereal Diseases | Tuberculosis

Liquor | Tobacco | Drugs

Other Illnesses

Injuries – description, location, % disability

Compensation Received | Do you have a workmen's compensation case pending for either injury or illness?

Have you a history of silicosis or any other dust disease? | Have you ever been in military service?

Have any of your parents or brothers or sisters had Tuberculosis, Cancer, Diabetes, Epilepsy or Insanity?

Last previous employment

I certify that the above answers are true, correctly recorded, and that I am in good health, and that I have never suffered from Silicosis, except (history)

Signature of Applicant | Witness

* If divorced, give date and place

PHYSICAL EXAMINATION
(TO BE COMPLETED BY DOCTOR)

Over Weight / Normal Weight / Under Weight —

Height 5'8 | Weight 166

Eyes: Right 20/25 | Left 20/30 | Corrected: Right | Left | Binocular Vision 20/25

Pupils ✓ | Cornea ✓

Lungs ✓ | Shortness of Breath none | Chest X-Ray —

Heart ✓ | Blood Pressure 120/64 | Pulse 64

Ears ✓ | Nose ✓ | Teeth ✓

Throat and Tonsils ✓ | Hearing: Right 20/20 | Left 20/20

Abdomen ✓ | Hernia ✓

Spine ✓ | Hemorrhoids ✓

Extremities ✓

Scars ✓ (Note % of defects if any exist) | Musculature ✓

Skin ✓ | Glands ✓ (Head and neck only – give location) | Genitals ✓

Reflexes ✓ | Mentality ✓

Blood Test ✓ | Urinalysis ✓

General Condition: Good — Fair Poor | Nutrition: Good — Fair Poor

Do you recommend applicant for work? A | Type of Work?

Remarks

APPROVED

FOREMAN | Date 6/12/63

SAFETY SUPERVISOR | Examined by [signature] M.

PLANT

THIS EMPLOYEE'S CONDITION IS KNOWN BY HIS SUPERVISOR YES X NO —

NATIONAL GYPSUM COMPANY

Sales District 14

Office

Name _____ Address [redacted] Plant Mill

Date April 17, 1959 Dept. _____ Check No. _____

Age 42 Color W S M W D* Children _____

PHYSICAL RECORD

(TO BE COMPLETED BY PERSONNEL DEPARTMENT)

Arthritis _ Epilepsy _ Hernia _

Operations — List on reverse side any hospital admissions in past 5 years.

Venereal Diseases _____ Tuberculosis _____

Liquor _____ Tobacco _____ Drugs _____

Other Illnesses _____

Injuries – description, location, % disability _____

Compensation Received _____ Do you have a workmen's compensation case pending for either injury or illness?

Have you a history of silicosis or any other dust disease? _____ Have you ever been in military service?

Have any of your parents or brothers or sisters had Tuberculosis, Cancer, Diabetes, Epilepsy or Insanity?

Last previous employment _____

I certify that the above answers are true, correctly recorded, and that I am in good health, and that I have never suffered from Silicosis, except (history)

Signature of Applicant _____ Witness _____

* If divorced, give date and place

PHYSICAL EXAMINATION

(TO BE COMPLETED BY DOCTOR)

Height _____ Weight 156 Over Weight / Normal Weight ✓ / Under Weight

Eyes: Right 20/ Left 20/ Corrected: Right _____ Left _____ Binocular Vision _____

Pupils ✓ Cornea ✓

Lungs ✓ Shortness of Breath ✓ Chest X-Ray —

Heart ✓ Blood Pressure 140/80 Pulse 76

Ears ✓ Nose ✓ Teeth ✓

Throat and Tonsils ✓ Hearing: Right 20/20 Left 20/20

Abdomen ✓ Hernia ✓

Spine ✓ Hemorrhoids ✓

Extremities ✓

Scars ✓ (Note % of defects if any exist) Musculature ✓

Skin ✓ Glands ✓ (Head and neck only – give location) Genitals ✓

Reflexes ✓ Mentality ✓

Blood Test ✓ Urinalysis ✓

General Condition: Good ✓ Fair _____ Poor _____ Nutrition: Good ✓ Fair _____ Poor _____

Do you recommend applicant for work? A Type of Work? _____

Remarks _____

APPROVED	
FOREMAN	Date 4-17-59
SAFETY SUPERVISOR	Examined by [signature] M.D.
PLANT MANAGER	THIS EMPLOYEE'S CONDITION IS KNOWN BY HIS SUPERVISOR. YES ☐ NO ☐

PHYSICAL EXAMINATION

CLOCK NUMBER 85 DATE 11-21-72

NAME [redacted]

ADDRESS [redacted] CITY & STATE [redacted]

BLOOD TEST

EYES ✓ L 20-20 R 20-20

EARS ✓

NOSE ✓

THROAT ✓

HEART ✓

PANS ✓

BLOOD PRESSURE 112/72

[illegible]

[illegible]

X-RAY [illegible]

PREVIOUS [illegible]

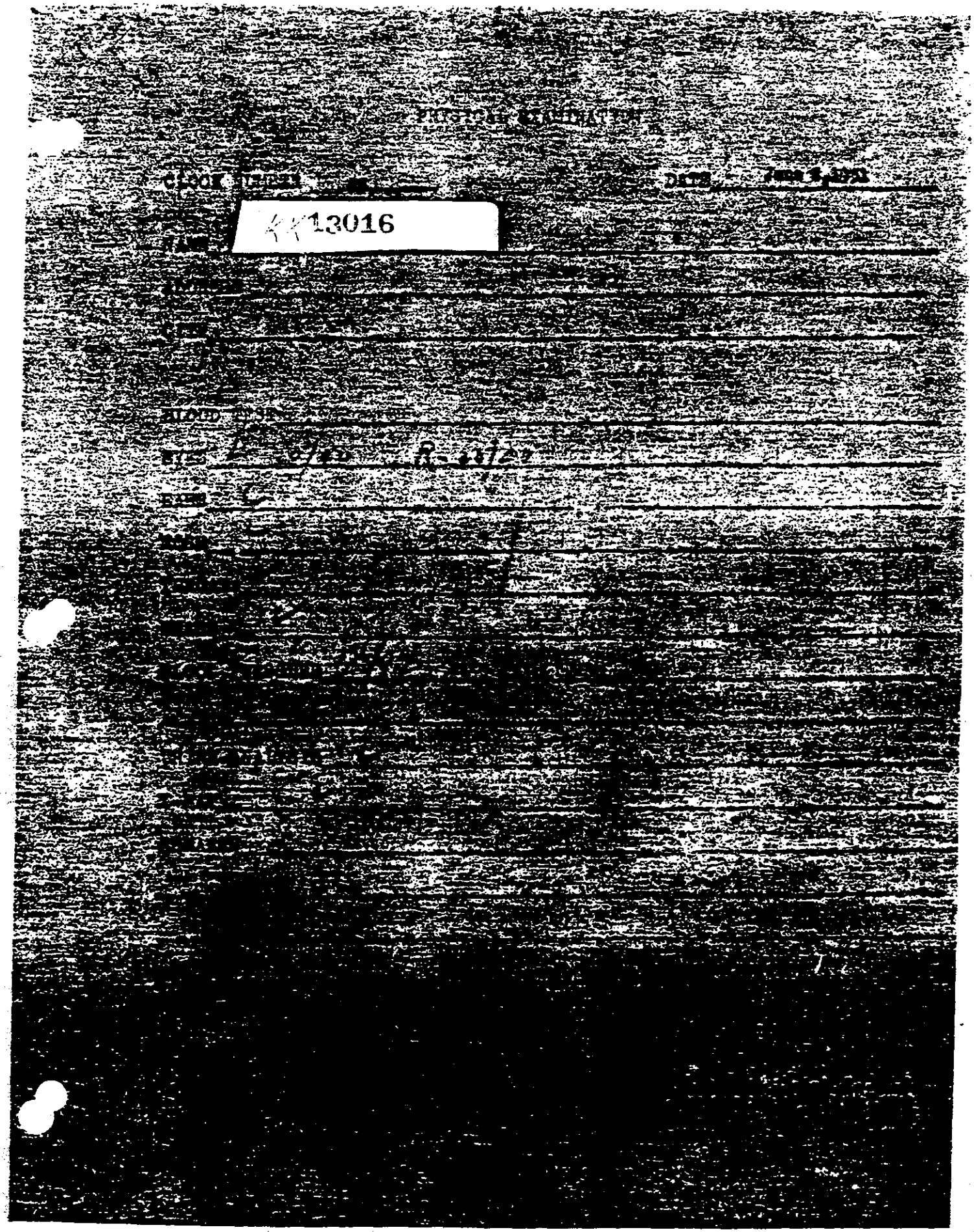
13016

PHYSICAL EXAMINATION MAY 5 1950

BLOCK NUMBER [illegible] DATE January 14, 1949

KK 13017

NAME

ADDRESS

CITY

BLOOD TEST

EYES Left 4 Right 6 Both 6

EARS

NOSE

THROAT

HEART

BLOOD

URINE ANALYSIS

PHYSICAL EXAMINATION

CLOCK NUMBER 85 OCTOBER 1947

NAME

ADDRESS

CITY

BLOOD TEST: NEGATIVE ✓ POSITIVE

EYES: ✓ 20-40

EARS: ✓

NOSE: ✓

THROAT: ✓

HEART: ✓

BLOOD PRESSURE: 128/80

URINE ANALYSIS: ✓

X-RAY: ✓

REMARKS:

A H Bauman

Physician's Signature

KK 3-18

Enrico C. Funaro, M. D. Edward G. Allen, M. D.

25 Franklin Street
Morristown, New Jersey
Jefferson 8-8181

March 23, 1960

G. W. Wright, M. D.
11311 Shaker Boulevard
Cleveland 4, Ohio

Re:
National Gypsum, Millington, N.J.
Chest Xray No: 11-60-B.

Dear Dr. Wright:

Examination of the thorax fails to demonstrate any evidence of an active pleural or parenchymal disease process. The cardiovascular silhouette is of normal size and contour for the patient's age and habitus. The visualized bony structures are unremarkable.

Thank you for referring to us,

Sincerely yours,

Edward G. Allen, M.D.

EGA/ers

13019