Exhibit 6 Neperol 11/79

Dietary Effects of Polychlorinated Biphenyls on Mink

(6) Q-984-7

(1) (4)
N. S. Plotonow and L. H. Karstad*

ABSTRACT

Poisoning occurred in 32 mink fed diets containing meat from cows which had been fed a polychlorinated biphenyl (PCB), Aroclor 1254. No live kits were produced and all adult mink died during a 105 day period of feeding a ration containing 3.57 ppm of PCB. At a level of 0.64 ppm of PCB in ration one of 12 mink produced three kits, all of which died during the first day after birth. Clinical signs were limited to weight loss and passage of black tarry feces. The gross lesions seen were yellowish discoloration of the liver and hemorrhage into the abdominal cavity or gastrointestinal tract. Microscopic lesions were nephrosis, fatty degeneration and necrosis of the liver, brain edema, disseminated intravascular coagulation, and fibrosis of coronary arteries. It is concluded that mink are highly sensitive to small quantities of PCB fed for an extended period of time.

RÉSUMÉ

On a empoisonné 32 visons en leur servant une ration qui contenait de la viande de vaches auxquelles on avait donné un diphényle polychloré (PCB), l'Aroclor 1254. On n'obtint aucun petit et tous les visons adultes moururent au cours d'une période de 105 jours durant laquelle on leur servit une ration contenant 3.57 ppm de PCB. A la concentration de 0.64 ppm de PCB dans la ration, une femelle, sur un total de 12, mit bas trois petits qui moururent en moins de 24 heures après leur naissance. Les signes cliniques se traduisirent par une perte de poids et le passage de fèces d'apparence goudronnée. Les lésions macroscopiques consistaient en une décoloration jaunâtre du foie et en des hémorragies intra-abdominales ou gastro-intestinales. Les lésions microscopiques étaient les suivants: néphrose, dégénérescence graisseuse et nécrose hépatiques, oedème cérébral, coagulation intra-vasculaire disséminée et fibrose des artères coronaires.

Les auteurs en viennent à la conclusion que le vison est très vulnérable à l'ingestion prolongée de petites quantités de PCB.

INTRODUCTION

Polychlorinated biphenyl (PCB) compounds are now recognized as widespread environmental contaminants of aquatic or terrestrial ecosystems. Since fish and various biproducts made from domestic animals are generally included in the diet of ranch-raised mink, it seemed to be important to know the effects of PCB compounds on mink, when included in the diet for an extended period of time.

MATERIALS AND METHODS

Thirty-two ranch mink approximately one year old were divided into two groups with four standard dark males, four pastel females, and eight standard dark females in each group. Each group of 16 mink was fed a separate ration. Rations were prepared from two Jersey cows which had been given orally ten consecutive daily doses of 1 and 10 mgm per kgm, respectively of a PCB,

(1) Departments of Biomedical Sciences and Pathology, University of Guelph, Guelph, Ontario, CANADA

This paper was presented in part at the Fifteenth Annual Meeting of the Canadian Federation of Biological Societies, Québec, Québec, June 1972.

This research was financially supported by the Canada Mink Breeders' Association and the Ontario Ministry of Agriculture and Food.

Submitted August 8, 1972.

(1) Univ Guelph, 2 Dept Pathol / 3 Guelph / 4 Ontario / 5 Canada

DSW 028745

STLCOPCB4012707

namely Aroclor 1254[1], dissolved in a small amount of olive oil and mixed with dairy concentrate. Twenty-four hours after the last doses were given, the cows were killed; fat, musculature, liver and kidneys were removed, thoroughly ground and mixed with commercial mink food cereal at a level of 24% cereal. The resulting rations contained 0.64 ppm and 3.57 ppm of total PCB, respectively.

The cows did not have any clinical, gross or histopathological signs of intoxication. If these animals had been slaughtered at an inspected meat plant, they would without doubt have passed as fit for human consumption.

Feeding *ad libitum* was begun two months before the breeding season, i.e. on January 7 and continued until June 17, 1971 (160 days).

Beginning in early March the 12 females in each test diet group were presented daily for breeding to one of the four males in the group, until the female was found to be receptive and mating took place. The semen of each male, collected by vaginal aspiration from a just-bred female, was examined microscopically for motile sperm.

The remaining 101 breeding female mink plus males and mink designated for other experiments in the institutional herd from which the test mink were taken were maintained on a commercial mixed ration, purchased locally. They were managed during the breeding and whelping seasons just as were the experimental PCB-fed animals. For practical purposes, they were regarded as no-treatment controls. During the course of the PCB experiments 50 to 60 mink from this herd were removed for aleutian disease research, either killed at once for tissue cultures or maintained on other premises for infection experiments.

All of these mink were examined for gross and histopathological lesions.

Necropsies were performed on experimental mink which died and those which were killed after PCB feeding was discontinued. Blood from the heart and samples of tissues from the major body organs and psoas muscle were taken for PCB analysis. Portions of brain, lungs, heart, spleen, liver, kidney, intestine, adrenal and reproductive organs were fixed in 10% formalin, processed for histology by paraffin embedding and sectioned at approximately 6 microns. Hematoxylin-eosin stain was used routinely. Where necessary for study of lesions of blood vessels, selected tissue sections were stained by the allochrome procedure (5).

TABLE I. Lesions Seen in Mink Fed PCB

PCB (ppm)	3.57	3.57	0.64	0.64
No of mink	12	4	12	4
Sex	F	M	F	M
No of deaths	12/12	4/4	2/12	0/4
Mean survival (days)	74	96	154	160*
Gross Lesions				
Weight loss	8/12	2/4	0/12	0/4
Hemorrhages	9/12	3/4	0/12	0/4
Yellow liver	6/12	2/4	1/12	0/4
Microscopic Lesions				
Nephrosis	5/12	1/4	1/12	0/4
Liver necrosis	2/12	2/4	0/12	0/4
Disseminated intravascular coagulation	2/12	0/4	1/12	0/4
Brain edema	3/12	0/4	0/12	0/4
Coronary arteriosclerosis	0/12	1/4	1/12	1/4

*All mink in this group survived to the end of the feeding period, 160 days

The PCB were extracted from various tissues as well as from samples of rations by the method of Grant *et al* (3) and subsequently analyzed by the method of Sissenbrecker and Ecobichon (12) using a Micro-Tech, Model MT-220[2], gas chromatograph, equipped with a ^{63}Ni high temperature electron capture detector. The quantitation of the PCB was performed by measuring total peak area as the detector response, using an Infotronics, Model 208[3], automatic digital integrator equipped with a baseline tracking and drift corrector. The PCB were separated from DDT and its analogs by the method described by Armour and Burke (1).

RESULTS

Reproduction

Fifteen of the 24 females were bred normally. Of the remaining nine, five on the higher PCB diet which were not bred, died

[1]Aroclor 1254 (mixture of chlorinated biphenyls containing 54% chlorine) was generously supplied by Monsanto Canada Ltd., Toronto, Ontario.

[2]Tracer Inc., Augustin, Texas, U.S.A.

[3]Infotronics Ltd., Shannon, Ireland.

DSW 028746

STLCOPCB4012708

either before or during the breeding period. Two of the four on the low PCB diet died during May. In all other cases, failure to breed was caused either by the female rejecting the male or because the female was too weak to participate.

All males produced motile sperm, yet no litters were produced by the females fed the ration containing 3.57 ppm of PCB and only one of the females fed 0.64 ppm PCB produced a litter. Three kits were born to this female but they died during their first day of life.

Clinical Signs and Mortality

The first mink to die was an adult female fed the ration with the higher level PCB which was dead on day 43 of the experiment. Deaths occurred sporadically thereafter. All of the mink fed the 3.57 ppm PCB ration were dead by day 105. Two of the mink fed 0.64 ppm PCB died on days 122 and 129, respectively. The feeding of this ration was terminated on the 160th day, at which time four of the surviving mink, three males and one female, were killed with an overdose of ether so that specimens could be taken for PCB analysis and histopathology. From day 161 to day 277 the surviving mink which had been fed the 0.64 ppm PCB ration were fed the regular commercial ration which was fed to the no-treatment controls. Three female and one male mink were killed for examination on each of days 40 and 82 after the cessation of PCB feeding. The remaining two female mink were killed on day 277.



Fig. 1. Lung of a female standard dark mink which died suddenly with disseminated thrombosis on day 129 of 0.64 ppm PCB feeding. Note the vein occluded by a large platelet thrombus. H & E. X65.



Fig. 2. Coronary artery of the mink described in Fig. 1. Most of the smooth muscle of the media has been replaced by fibrous connective tissue. Allochrome. X165.



Fig. 3. Lesions similar to those of Fig. 2 in the coronary artery of a standard dark male mink killed by ether inhalation after 160 days of 0.64 ppm PCB feeding. Allochrome. X530.

At both treatment levels, males survived longer than females. There was a marked difference in survival between treatment levels (Table I).

Clinical signs were either absent or nonspecific. A few mink died suddenly while they were still in good flesh, but many of the mink became emaciated on the PCB diets; they had poor appetites and in some cases became lethargic and very weak before they died. Some passed tarry feces, indicating gastrointestinal hemorrhage.

Gross Lesions

The gross lesions seen at necropsy were emaciation, blood in the gastrointestinal tract or intra-abdominal hemorrhage, and yellowish discoloration of the livers. These changes were not consistent in all cases. Their frequencies are given in Table I. Hemorrhages seemed to be more often chronic rather than massive and acute. It was not possible to relate the blood present in the abdominal cavity to lesions in the blood vessels or visceral organs. Bleeding

DSW 028747

STLCOPCB4012709

TABLE II. Mean Concentrations (± stand. dev.) in ppm of Polychlorinated Biphenyls (PCB) in Various Tissues of Mink Fed Rations Containing Ingredient(s) Contaminated with PCB

PCB level in ration (ppm)	Number of Animals	Period[a]	Blood	Brain	Kidney	Liver	Muscle	Heart
3.57	15	—	1.80 ± 1.42	4.72 ± 3.31	7.12 ± 4.59	11.99 ± 11.0	3.31 ± 0.93	8.31 ± 7.21
0.64	2[b]	0	0.71 ± 0.01	0.52 ± 0.01	1.20 ± 0.28	1.10 ± 0.03	0.52 ± 0.12	1.10 ± 0.23
0.64	4	0	0.12 ± 0.02	1.35 ± 0.45	1.74 ± 0.65	1.23 ± 0.10	0.37 ± 0.51	1.12 ± 0.45
0.64	4	1	0.10 ± 0.05	0.60 ± 0.26	1.12 ± 0.87	0.37 ± 0.15	0.43 ± 0.43	1.60 ± 0.71
0.64	4	2	0.24 ± 0.03	0.90 ± 0.13	1.85 ± 0.43	1.21 ± 0.05	0.77 ± 0.19	1.25 ± 0.26
0.64	2	3	0.05 ± 0.07	0.33 ± 0.01	1.09 ± 0.01	1.33 ± 0.16	0.61 ± 0.09	1.11 ± 0.03
Control (0.30 ± 0.03)	8	—	0.12 ± 0.03	0.32 ± 0.09	0.29 ± 0.07	0.39 ± 0.14	0.23 ± 0.15	0.35 ± 0.14

[a]Period (in months) after withdrawal of PCB ration
[b]Died during feeding the ration containing 0.64 ppm of PCB

seemed to have occurred by diapedesis. Similarly, the blood which was present in the gastrointestinal tracts of eight of the 18 mink which died was not traceable to ulcers or other gross lesions. Usually the blood was partially digested.

Slight splenic enlargement was found in about half the dead mink. Hydropericardium and hydroperitoneum, seen in birds poisoned with PCB, were never found.

Microscopic Lesions

The most frequently observed microscopic lesions are listed in Table I, with their frequencies of occurrence. Some degree of nephrosis was noted in about half of the mink which died. This consisted of vacuolar degenerative changes in tubular epithelial cells, flattening of the epithelium in some of the convoluted tubules, and dilatation of lumens containing fibrin casts. Foamy or flocculent eosinophilic exudates were sometimes present in Bowman's capsules.

Minimal to moderate focal liver necrosis was seen in four mink on the high PCB diet. The yellow color seen on gross inspection was due to the presence of large fat vacuoles in many hepatic cells. Brain edema, characterized by mild or moderate spongiosis and diffusely distributed, was seen in three of the dead mink.

Disseminated intravascular coagulation was a prominent lesion in three mink. These animals appeared to have died of extensive disseminated thrombosis followed by multiple hemorrhages in organs such as the lung (Fig. 1), and brain and either hemorrhage or irregular pooling of blood in sinusoids of the spleen and liver. Some of the spleens had populations of megakaryocytes which seemed to be greater than normal.

Fibrosis of the media of coronary arteries (Figs. 2 and 3) was a lesion which apparently developed late in the course of the experiment. It was found in two standard dark mink which died on days 105 and 129 of PCB feeding and in another which was killed for examination on day 160. The mink which died on day 105 was on the high level PCB diet; the other two were on the lower level diet. Healing and recent infarcts were present in the left ventricular myocardium of the mink which died on day 105.

No lesions were noted in the male and female reproductive organs. Many of the females had uterine hypertrophy, evidence of recent pregnancy, and the female mink which died during late March and April all

DSW 028748

STLCOPCB4012710

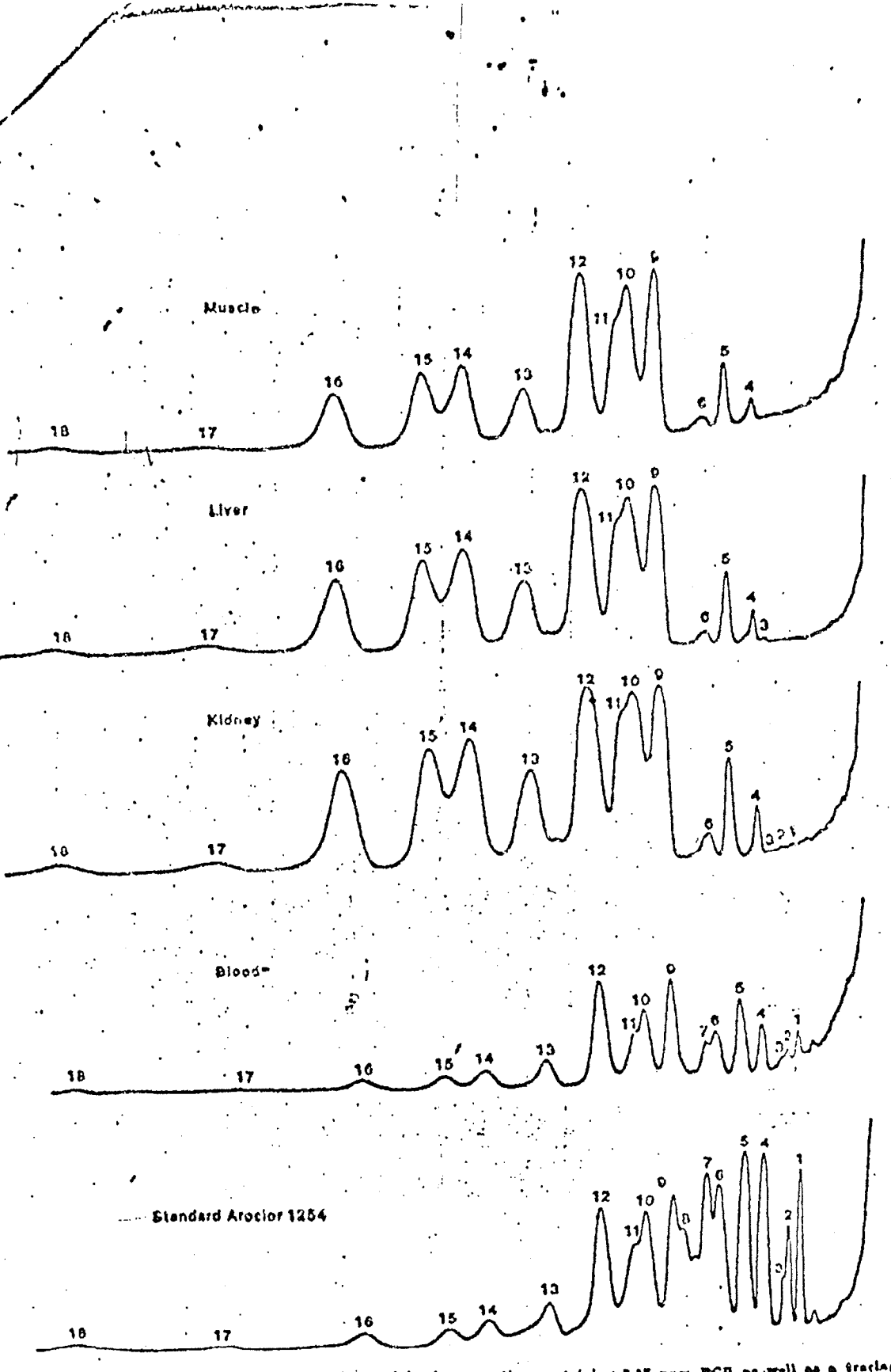

Fig. 4. Chromatograms of tissue extracts from mink given a ration containing 3.87 ppm PCB as well as a fraction of a standard Aroclor 1254.

DSW 028749

STLCOPCB4012711

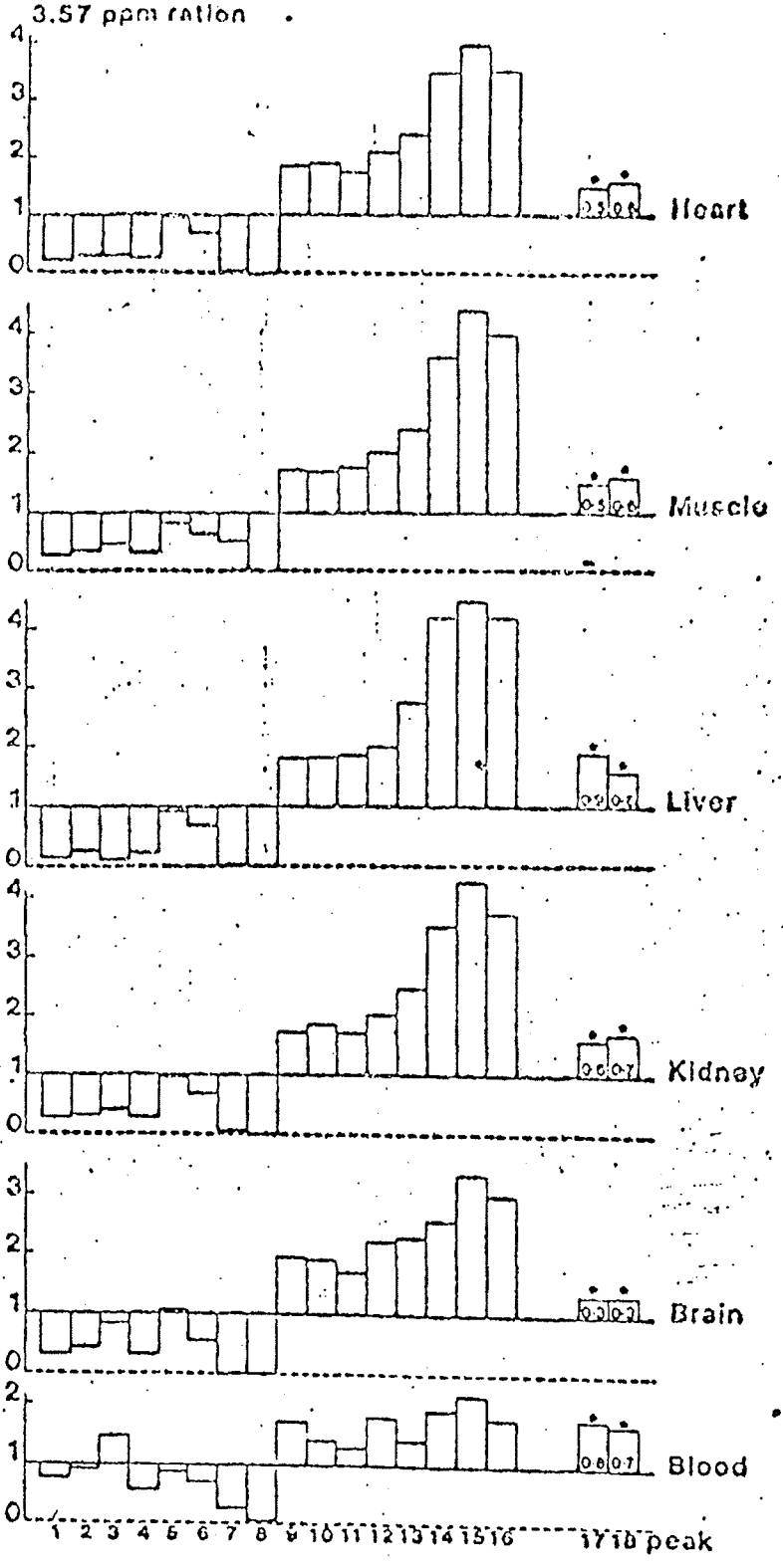

Fig. 5. Ratios between the mean percentages of chromatographic peaks of various tissue extracts of the group given the ration containing 3.57 ppm PCB, to the percentage of the same peak in the Aroclor 1254 standard.

DSW 028750

STLCOPCB4012712

had corpora lutea present, in various degrees of regression. Ovarian follicles seemed to be present in adequate numbers during the breeding period, although many of the follicles were undergoing regressive changes in mink which died. Females which died before or at the beginning of the breeding period had quiescent uteri which were juvenile in appearance. Male mink which died during March and April had histological evidence of spermatogenesis. Those which died or were killed later had testicular changes typical of post-breeding regression.

No lesions were observed in the adrenal glands.

Tissue Distribution of PCB

The concentrations of PCB in various tissues of principal and control mink are given in Table II.

In the group of mink fed the higher level of PCB, the concentrations of these compounds were lowest in the blood and highest in the liver. In the same group, the PCB concentrations in the brain were relatively high, especially when one considers that they were higher than in the skeletal muscle. The concentrations of PCB in kidneys were higher than in the brain, but lower than in the hearts and livers.

In mink fed the ration containing 0.64 ppm of PCB, the PCB concentrations in tissues were similar in all organs analyzed, except in blood, where the lowest levels were detected. Similarly, in mink fed the commercial control ration, the PCB concentrations were nearly identical in the analyzed tissues, except in blood.

The resolution by gas-chromatography of Aroclor 1254 standard as well as extracts of various feed or tissue samples (under the operating conditions used in the present study) resulted in up to 18 distinct peaks. Figure 4 depicts the chromatographic tracing of tissue extracts from mink fed the ration containing 3.57 ppm PCB as well as the tracing of a standard Aroclor 1254. Note the decrease of early emerging peaks of tissue extracts, disappearance of peak 8 and increase of late emerging peaks.

The data depicted in Fig. 5 and Fig. 6 show the ratios between the mean percentages of peaks from each tissue extract of groups given 3.57 ppm and 0.64 ppm PCB to the percentages of the corresponding peak of the standard Aroclor 1254. The base line in each case is unity. The zero value indicates the disappearance of the peak; the values between unity and zero indicate the percentage decrease of the peak; the values higher than unity indicate the increases in percentage above the value of the standard.

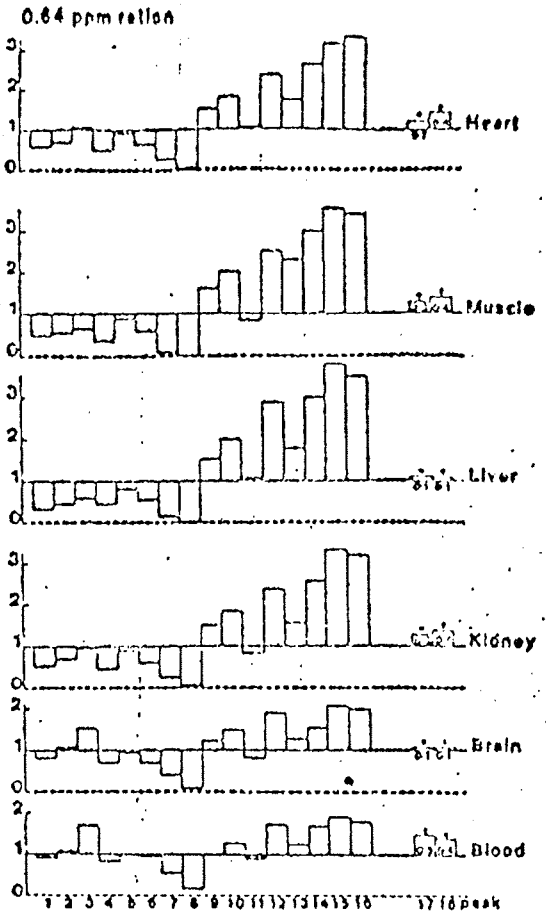

Fig. 6. Ratios between the mean percentages of chromatographic peaks of various tissue extracts of the group given ration containing 0.64 ppm PCB, to the percentage of the same peak in the Aroclor 1254 standard.

The percentage reductions of the first eight peaks and the percentage increases in the subsequent peaks in these two figures are evident. The first eight emerging peaks were significantly reduced in all tissues, except in blood, where the reduction was not always significant. The second eight peaks were always significantly increased proportionally to the Aroclor 1254 standard. These changes were most pronounced in the liver and least so in the blood. Peak 8 was reduced to zero in all tissues, except in blood; peak 7 was the next most strongly reduced. In peaks emerging after peak 8, the proportional percentage increase was nearly directly related to the retention time, i.e. peak 16 increased more than peak 9.

DSW 028751

STLCOPCB4012713

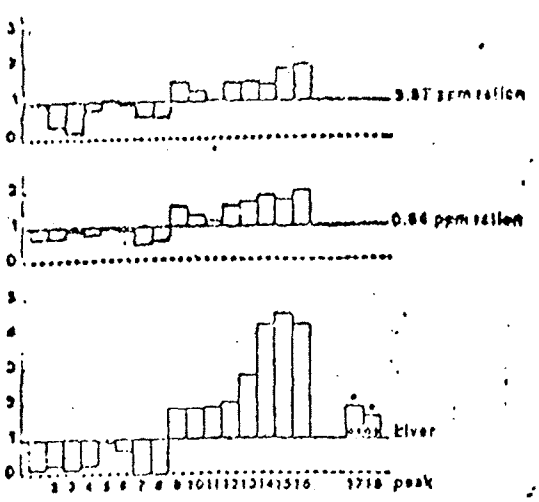

Fig. 7. Ratios between the percentages of chromatographic peaks of ration containing 3.57 ppm (upper figure) and ration containing 0.64 ppm PCB (middle figure). The lower figure, given for comparison, are the ratios of the liver of the group of mink fed 3.57 ppm PCB.

This tendency was not observed in blood. On all chromatograms a substantial percentage increase was noted in peaks 17 and 18. These two peaks are below 0.1% in the Aroclor 1254 mixture.

Figure 7 shows the ratios expressed similarly to Fig. 5 and Fig. 6 but give the ratios for both PCB rations fed, and for comparison the values of livers of the group fed 3.57 ppm.

Reproduction and Health of Control Mink

The 101 mink which received the commercial ration and which were regarded as no-treatment controls, produced only an average of 1.81 kits per female bred (satisfactory production is considered to be four kits per female).

When the commercial ration was analyzed the following results were obtained. The data represent means of six samples taken at intervals during the experiment.

Percent fat	— 8.2
p,p′ — DDE	— 0.012 ppm
p,p′ — DDD	— 0.010 ppm
o,p′ — DDT	— 0.004 ppm
p,p′ — DDT	— 0.008 ppm
Total DDT	— 0.033 ppm
Dieldrin	— 0.006 ppm
PCB	— 0.30 ppm

No outbreak of infectious disease was diagnosed in the herd during these experiments. Lesions similar to those of the principal PCB-fed groups were found in several dozen control mink killed for tissue culture purposes and used in Aleutian disease research.

DISCUSSION

From the impaired reproduction and mortality observed, and the tissue concentrations of PCB found, it can be concluded that the mink were very susceptible to the effects of PCB compounds as dietary contaminants. The clinical and gross and microscopic tissue abnormalities were rather nonspecific, so that diagnosis in cases of naturally occurring PCB poisoning would be very difficult. Reproductive failure, weight loss and tarry droppings could suggest either starvation or aleutian disease, a common disease of mink. The PCB-fed mink may have been on an inadequate nutritional plane, but if so, it was not because the diet lacked essential nutrients but rather that the mink lost appetite and did not eat enough of the feed that was put before them. Aleutian disease would be ruled out on histopathology, however, since the severe hepatitis and nephritis of aleutian disease, marked by proliferation of plasma cells, was not seen in the PCB-poisoned mink.

The occurrence of liver damage in mink which also developed hemorrhagic tendencies suggests a breakdown in hemostasis in which prothrombin deficiency may be a causative factor. Blood coagulation studies should be made in future research on PCB poisoning in mink. Splenic enlargement and increased numbers of megakaryocytes in the spleen may represent compensatory responses in attempts to maintain hemostasis. The cause of the disseminated intravascular coagulation seen in the three mink is unknown. Hormonal effects of PCB may have been responsible for the reproductive failure. The presence of corpora lutea in the ovaries of the mink which died during or immediately after the normal gestation period indicates that ovulation did occur but that gestation did not continue to term.

Fatty degeneration of the liver and liver necrosis has been described in other species treated with PCB compounds. Degenerative kidney lesions also have been

DSW 028752

STLCOPCB4012714

scribed in other species by some workers. Platonow *et al* (9) have described perivascular hemorrhages around coronary arteries in the hearts of chickens fed Aroclor. The coronary arterial lesions seen in three of the mink in these experiments are unexplained but thought to be related to the PCB feeding, since lesions of this type have not been seen by the authors previously. Their appearance in two of three mink which died between days 105 and 129 of PCB feeding and in one of four mink killed on day 160 may mean that lesions in these vital arteries develop as a late response to low-level PCB ingestion. This should be investigated further in mink and also in other species.

The poor reproduction in the no-treatment controls may be referable to the low (0.3 ppm) but significant amounts of PCB found in the control commercial ration. The controls, therefore, actually were an unplanned lower PCB treatment group of mink. Lesions referable to the PCB content of the control ration were not seen in the mink from this herd which were used for research on aleutian disease during the course of these PCB experiments. The low concentrations of dieldrin as well as DDT and its analogs and metabolites in the control ration are for all practical purposes of no toxicological significance.

It has been suggested that PCB affect enzyme systems that metabolize several sex hormones, which ultimately leads to reproductive failure. Thus, Risebrough *et al* (11) reported that the PCB induce the activity of hydroxylating enzyme which metabolizes estradiol. The estrogenic activity of various PCB mixtures upon the rat uterus was described by Bitman and Cecil (2). Platonow and Funnel (7, 8) reported that chronic feeding of PCB in cockerels resulted in anti-androgenic effects, as assessed by decreased development of testicles and comb. These signs appeared as early as one week after the start of continuous feeding of a PCB-contaminated diet.

It was recently demonstrated by Nowicki and Norman (6) that the post-mitochondrial hepatic fraction (microsomes + cytosol) from PCB-treated cockerels and pullets metabolized testosterone, estradion-17β and 4-androstene-3, 17-dione at increased rates. The metabolic rates of these three natural steroid hormones were increased approximately three-fold over untreated birds. Platonow, Liptrap and Geissinger (8) reported on the effect of oral administration of PCB (Aroclor 1254) in the adult boar. The doses of PCB were such that no gross or histological lesions could be seen. However, the presence of significant biochemical alterations were recorded. These changes consisted in drastic reduction of urinary levels of two gonadal hormones: dehydroepiandrosterone and estrogen, indicating that PCB have a deleterious effect upon reproductive activity. The primary site of o,p'-DDD inhibition of ACTH-induced steroidogenesis in the adrenal cortex appears to be on the ACTH-regulated intramitochondrial conversion of cholesterol to pregnenolone (4). Since the chemical formulae of PCB's are similar to that of DDT, it is possible that the hormonal disturbances due to PCB are located at the same site. At least this is a probable site of PCB effect in the boar, because pregnenolone is a precursor of dehydroepiandrosterone in steroidogenesis.

In comparison to domestic animals (8, 9, 10, 13) mink seem to extensively metabolize the PCB, Aroclor 1254 used in this experiment. The changes occurring on the chromatograms of various tissue extracts indicated significant reduction of the first eight peaks, with simultaneous increases of the peaks emerging thereafter. The order of appearance of peaks on the PCB chromatogram is related to the extent of chlorination of biphenyls. Thus, monochlorbiphenyls appear before dichlorobiphenyls, trichlorobiphenyls before tetrachlorobiophenyls, etc., and decachlorobiphenyl (the completely chlorinated biphenyl) emerges as the last peak. The reduction of peaks of lower retention indicates that mink can metabolize PCB of lower chlorination numbers. Since this reduction in faster emerging peaks is much less pronounced in the cow (13), pig (10), or chicken (8), one might suggest that the extent of PCB metabolism is related to the extent of susceptibility to the toxic effect of PCB. Mink appear to be more susceptible to PCB than the domestic animals studied. However, further studies are required to confirm or reject the above hypothesis.

ACKNOWLEDGMENTS

The authors are grateful to Drs. Joan Budd and Peter Lusis for assistance in necropsies, to Mrs. N. Y. Chen for performing

DSW 028753

STLCOPCB4012715

...analyses of PCB, and to Mr. Hugh Bel... for care of the experimental mink. The histopathology was done while the junior author was a visiting professor at Utah State University.

REFERENCES

1. ARMOUR, J. A. and J. A. BURKE. Method for separating polychlorinated biphenyls from DDT and its analogs. J. Ass. off. analyt. Chem. 53: 761-768, 1970.
2. BITMAN, J. and H. C. CECIL. Estrogenic activity of DDT analogues and polychlorinated biphenyls. J. agric. Fd Chem. 18: 1108-1112, 1970.
3. GRANT, D. L., W. E. J. PHILLIPS and D. C. VILLENEUVE. Metabolism of a polychlorinated biphenyl (Aroclor 1254) mixture in the rat. Bull. envir. Contam. Toxic. 6: 162-172, 1971.
4. HART, M. M. and J. A. STRAW. Studies on the site of action of o,p'-DDD in the dog adrenal cortex. I. Inhibition of ACTH-mediated pregnenolone synthesis. Steroids 17: 559-573, 1971.
5. LILIE, R. D. Allochrome stain. Am. J. clin. Path. 31: 484, 1951.
6. NOWICKI, H. G. and A. W. NORMAN. Enhanced hepatic metabolism of testosterone, (-)nitrosterone, Fedione, and extradiol-17-f in chicken pre-treated with DDT or PCB. Steroids 19: 85-100, 1972.
7. PLATONOW, N. S. and H. S. FUNNELL. Anti-androgenic-like effect of polychlorinated biphenyls in cockerels. Vet. Rec. 88: 109-110, 1971.
8. PLATONOW, N. S. and H. S. FUNNELL. The distribution and some effects of polychlorinated biphenyls (Aroclor 1254) in cockerels during prolonged feeding trial. Can. J. comp. Med. 36: 8691, 1972.
9. PLATONOW, N. S., L. H. KARSTAD and P. W. SASCHENBRECKER. Tissue distribution of polychlorinated biphenyls (Aroclor 1254) in cockerels: Relation to the duration of exposure and observation on pathology. Can. J. comp. Med. 37: 99-95, 1973.
10. PLATONOW, N. S., R. M. LIPTRAP and H. D. GEISSINGER. The distribution and excretion of polychlorinated biphenyls (Aroclor 1254) and their effect on urinary gonadal steroid levels in the boar. Bull. envir. Contam. Toxic. 7: 358-365, 1972.
11. RISEBROUGH, R. W., P. REICHE, D. B. PEAKALL, S. G. HERMAN and M. N. KIRVEN. Polychlorinated biphenyls in the global ecosystem. Nature, Lond. 226: 1098-1102, 1968.
12. SASCHENBRECKER, P. W. and D. J. ECOBICHON. Extraction and gas chromatographic analysis of chlorinated insecticides from animal tissue. J. agric. Fd Chem. 15: 168-170, 1957.
13. SASCHENBRECKER, P. W., N. S. PLATONOW and H. S. FUNNELL. Metabolic study of polychlorinated biphenyls in lactating ocws. Proc. Can. Fed. Biol. Soc. 14: 65, 1971.

DSW 028754

1 Univ Guelph, 2 Dept Pathol / 3 Guelph / 4 Ontario / 5 Canada

398-400

STLCOPCB4012716