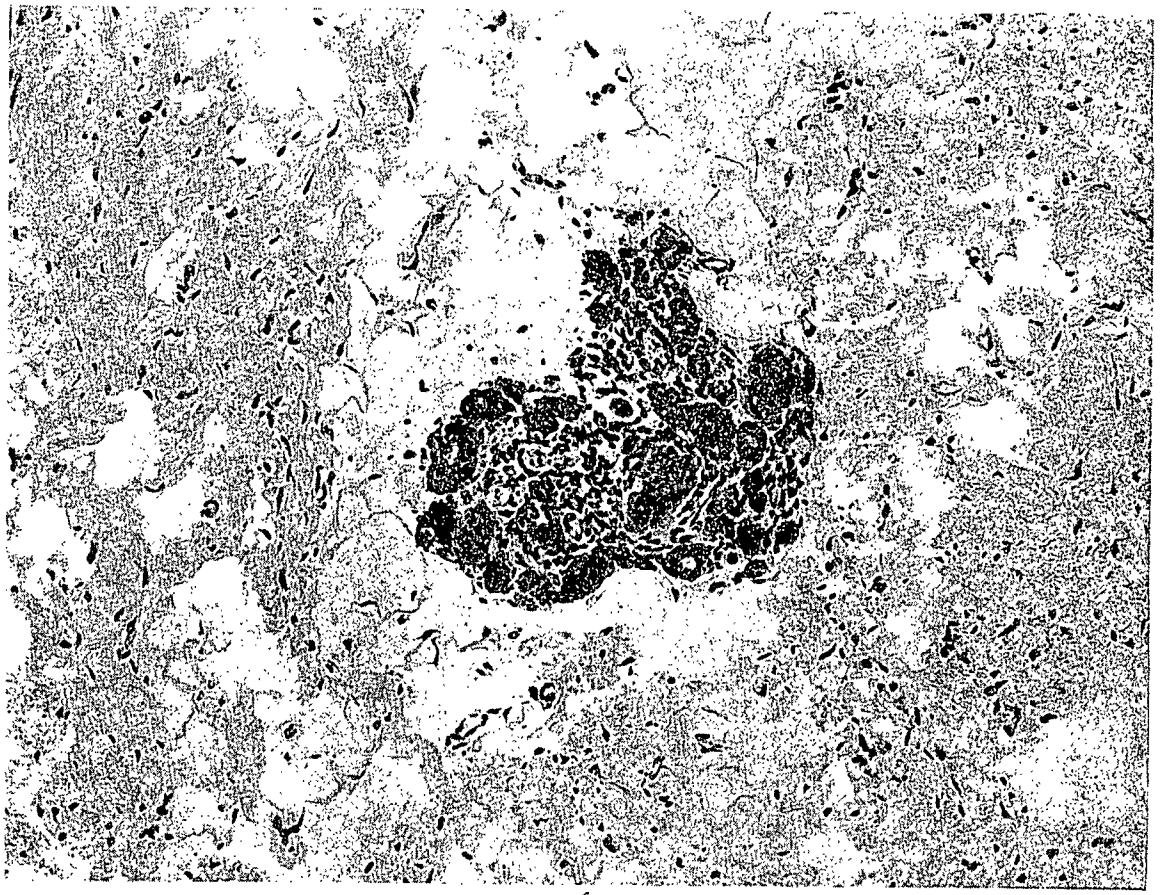

Fig. 3.—Skin of pig two months after implantation of sample B. The particles of dust are collected into phagocytic cells; there are a few lymphocytes and minimal fibrosis. One multinucleated foreign body giant cell is clearly visible. (Hematoxylin and eosin; × 160.)

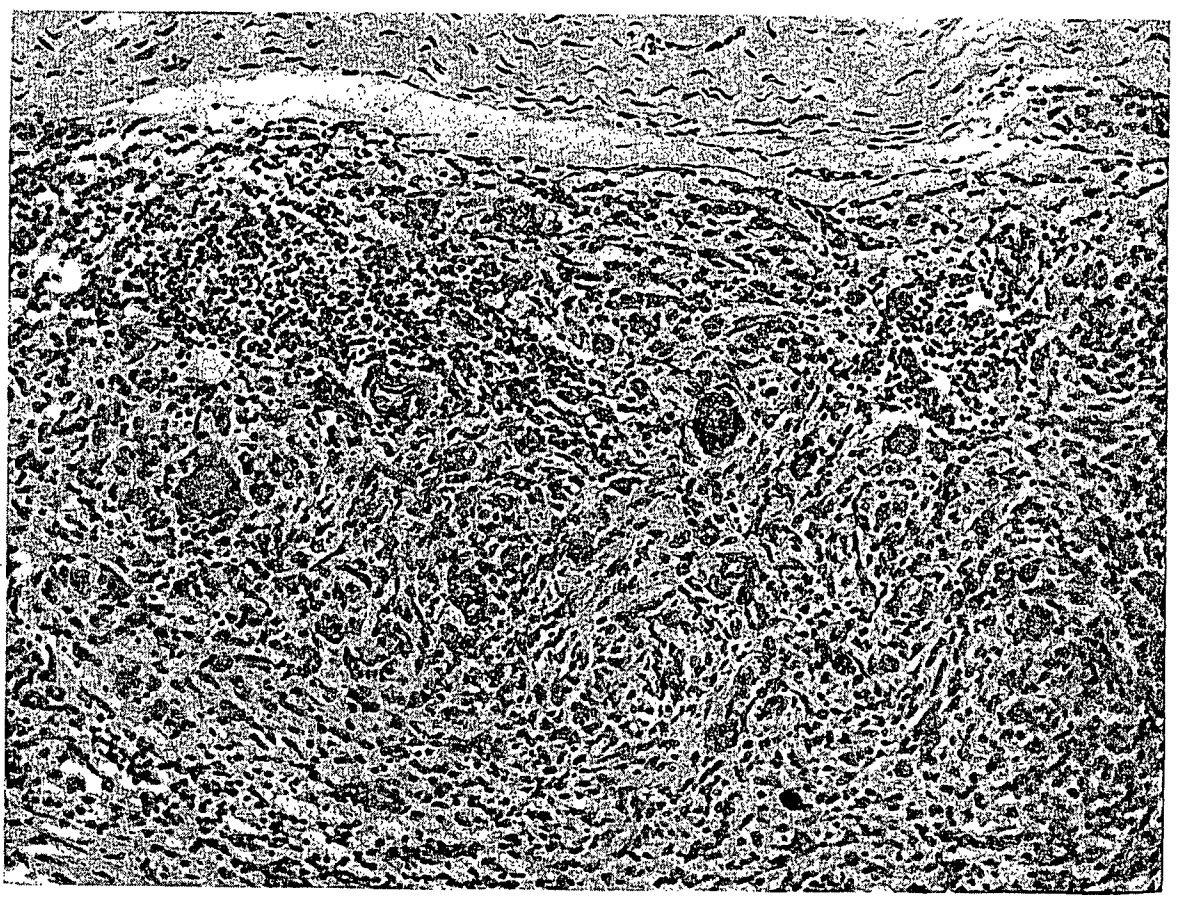

Fig. 4.—Section through skin of pig two months after implantation of sample C. Granuloma comprised of connective tissue, lymphocytes, phagocytes and occasional giant cells of Langhans' type. A structure which resembles a conchoidal body is present in one giant cell. (Hema-