in Europe. It was proposed to the International Conference on Pneumoconiosis in Sydney, Australia, in 1950 and accepted with minor changes. It has not been widely adopted in this country so far, but the author has noted its increasing use.

The classification has two major divisions, the simple pneumoconiosis and the complicated (see Figure 13). In the simple group, three categories are recog-

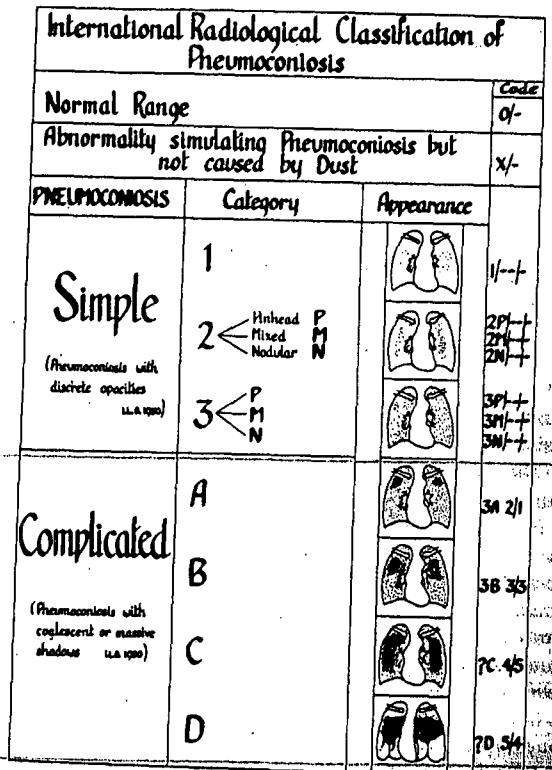

Figure 13. Diagram of new international roentgenological classification of pneumoconiosis.

nized, based on extent of distribution of small round opacities. The previously used term "reticulation" was dropped because it was realized that the lacelike appearance actually was due to collections of pinhead shadows.

Categories of Simple Pneumoconiosis

Category 1. A few characteristic opacities 0.5 to 3 mm. in diameter are seen usually in the second, third, and fourth anterior rib spaces, midway between the

mediastinum and periphery, more commonly on the right than on the left. Occasionally they appear more peripherally. The vascular markings are clearly visible. To make a diagnosis of Category 1 simple pneumoconiosis, the characteristic abnormality must be found in at least two rib spaces, and in each must extend over 1.5 cm. or more.

Category 2. Opacities 0.5 to 3 mm. in diameter are more numerous and are distributed throughout the lung fields, but they are usually less profuse and are commonly absent in the peripheral third. The vascular markings are still visible although not so clearly as in Category 1.

Category 3. The opacities are now profusely distributed throughout the whole of both lung fields, including the periphery, but at the apices they may be relatively sparse.

The distinction among the categories is made chiefly on the profusion of the opacities, but their diffusion throughout the lung field, especially at the peripheral parts, and the degree of obscuration of the lung markings also are taken into account. In cases where the distribution of the opacities is uneven, the category is determined by the half lung field that shows the greatest abnormality.

Categories 1, 2, and 3 may be further subdivided into the following:

P, Pinhead type. This occurs in about 10 per cent of cases. Opacities up to 1 mm. in diameter are uniformly distributed throughout both lung fields, giving rise to a profuse and uniform granularity.

M, Mixed type. In these films, opacities of various sizes ranging up to 3 mm. in diameter are distributed throughout the lung fields.

N, Nodular type. In these films, discrete, more or less circular opacities, seldom more than 5 mm. in diameter, of homogeneous density are distributed throughout the lung fields. This is the usual appearance of classical silicosis.

Complicated pneumoconiosis. The earliest roentgenographic evidence of progressive massive fibrosis is the presence, on a background of Category 2 or Category 3 simple pneumoconiosis, of larger (1 cm. or more in diameter), less well-defined opacities than those characteristic of simple pneumoconiosis itself. These opacities often resemble reinfection-type tuberculosis, both in their position and in their appearance. They most commonly develop in the posterolateral segment of the upper lobes and the apical segments of the lower lobes, more commonly on the right than on the left; but the shadows are not strictly segmental, and in a posteroanterior film the commonest distribution is over a longitudinal section of the upper and mid-zones midway between the hilus and the periphery.

In the course of time, these shadows tend to grow and coalesce to form larger shadows of various shapes and sizes. New areas of opacity may develop in other parts of the lung, and ultimately a large portion of both lung fields may be occupied by massive shadows. Later, the shadows tend to contract with an increase in their density, with subsequent severe distortion of the lung architecture and with the development of gross emphysema.

The classification of these shadows is based upon the observation of the