Inhibitory Effect of Polychlorinated Biphenyls on Liver Tumorigenesis in Rats Treated With 3'-Methyl-4-dimethylaminoazobenzene, *N*-2-Fluorenylacetamide, and Diethylnitrosamine [1,2]

Sachio Makiura, Haruko Aoe, Seiichi Sugihara, Kazuya Hirao, Masayuki Arai, *and* Nobuyuki Ito [3]

SUMMARY—Studied were the effects of polychlorinated biphenyls (PCB) on liver carcinogenesis in rats treated with the hepatic carcinogens 3'-methyl-4-dimethylaminoazobenzene (3'-Me-DAB), *N*-2-fluorenylacetamide (2-FAA), and or diethylnitrosamine (DEN). Animals were examined histopathologically after they had received the experimental diet for 20 weeks and then the stock diet for 4 weeks. Liver tumors developed in 65.2, 53.8, and 92.3% of rats in groups treated with 0.03% 3'-Me-DAB, 0.015% 2-FAA, and 0.0025% DEN, respectively. Rats that received 0.05% PCB only did not develop liver tumors, and those treated with PCB and the carcinogens developed only a few tumors. Multiple liver tumors developed after treatment with 0.03% 3'-Me-DAB plus 0.0025% DEN (92.3% incidence) and 0.015% 2-FAA plus 0.0025% DEN (61.5%); after treatment with these combinations plus PCB, the incidence of liver tumors was very low or zero. Histologic examination showed that PCB also inhibited development of nodular hyperplasias, oval cell infiltration, and bile duct proliferation induced in the liver by the chemical carcinogens.—J Natl Cancer Inst 53: 1253–1257, 1974.

POLYCHLORINATED BIPHENYLS (PCB) are used, among other ways, as a solvent in ink and heat-transfer media; they also cause environmental pollution (*1–4*). Investigators have reported chronic toxic effects in various animals (*5, 6*). Fuhremann and Lichtenstein (*7*) reported the synergistic effects of PCB and DDT in insects. Recently, we reported that PCB alone induce hepatic tumors in mice and also promote the induction of tumors in mice by benzene hexachloride (*8, 9*). Furthermore, Kimura and Baba (*10*) reported that PCB induce neoplastic changes in the livers of female rats.

This paper describes the effects of PCB on liver carcinogenesis in rats treated with the 3 hepatocarcinogens 3'-methyl-4-dimethylaminoazobenzene (3'-Me-DAB), *N*-2-fluorenylacetamide (2-FAA), and diethylnitrosamine (DEN).

MATERIALS AND METHODS

Male Sprague-Dawley rats (Fuji Animal Farm, Tokyo, Japan), initially weighing about 185 g, were divided into 12 groups. They were given the basal diet described previously (*11*) supplemented with 0.03% 3'-Me-DAB, 0.015% 2-FAA (both from Yoneyama Chemical Industries Ltd., Osaka, Japan) and/or 0.05% PCB [Kanechlor 500 contains an average of 55.0% pentachlorobiphenyl, 26.5% tetrachlorobiphenyl, 12.8% hexachlorobiphenyl, and 5.0% trichlorobiphenyl (lot 360, Kanegafuchi Chemical Co., Osaka, Japan)] and/or drinking water supplemented with 0.0025% DEN (Nakarai Chemical Ltd., Kyoto, Japan). All animals were given food and water ad libitum and were housed 6 per wire cage under a natural light-dark cycle in a room air-conditioned at 24° C. They were weighed weekly.

The carcinogens were given to 11 groups of rats as follows: group 1: 3'-Me-DAB in diet; group 2: 2-FAA in diet; group 3: DEN in water; group 4: PCB in diet; group 5: PCB plus 3'-Me-DAB in diet; group 6: PCB plus 2-FAA in diet; group 7: PCB in diet plus DEN in water; group 8: 3'-Me-DAB in diet plus DEN in water; group 9: 2-FAA in diet plus DEN in water; group 10: PCB plus 3'-Me-DAB in diet and DEN in water; group 11: PCB plus 2-FAA in diet and DEN in water. Rats in control group 12 were given the basal diet without carcinogens.

Animals were given experimental diets for 20 weeks and then stock diet (Oriental MF, Oriental Yeast Co., Tokyo, Japan) for 4 weeks. Animals that died within 16 weeks from the start of the experiment were excluded.

At the end of the experiment, animals were denied food for 18 hours, anesthetized with ether, and killed. The liver, kidneys, and spleen of animals that died naturally or were killed were weighed and examined grossly.

For histologic examination, tissues were fixed in 10% buffered formalin, embedded in paraffin, and stained with hematoxylin and eosin. If necessary, tissues were also given Mallory's stain and periodic acid-Schiff.

RESULTS

Changes in Body and Liver Weight (Table 1)

The body weight of all rats increased during the experiment, but animals treated with carcinogens and/or PCB gained much less weight than controls. In particular, animals in group 11 (PCB+2-FAA+DEN) gained only about half as much weight as controls.

The liver weight, as a percentage of the body weight, was generally at least twice as great in experimental groups as in the control. This increase was due to development of tumors and/or in animals treated with PCB, to swelling of the liver. In groups

[1] Received March 25, 1974; accepted July 18, 1974.

[2] Supported in part by grants for scientific research from the Ministry of Health of Japan (1973), the Ministry of Education of Japan (880157, 1973), and the Experimental Pathological Research Association (1973–74).

[3] Department of Oncological Pathology, Cancer Center Institute, Nara Medical University, Kashihara, Nara 634, Japan.

MONS 082669

TABLE 1.—Changes in the body and liver weights of male rats treated with PCB and chemical carcinogens for 24 weeks

Group [a]	Experimental period (wk) [b]	Initial No. of rats	Effective No. of rats [c]	Body weight (g)		Liver weight (final)	
				Initial	Final	g	Percent body weight
1. 3'-Me-DAB	24. 0	24	23	189. 7	475. 5	18. 6	3. 9
2. 2-FAA	24. 0	16	13	195. 8	423. 8	19. 1	4. 5
3. DEN	23. 6	16	13	182. 0	431. 5	28. 7	6. 7
4. PCB	24. 0	24	19	188. 0	400. 5	21. 6	5. 4
5. PCB+3'-Me-DAB	24. 0	24	23	191. 9	397. 4	25. 6	6. 4
6. PCB+2-FAA	24. 0	24	17	190. 7	389. 2	23. 1	6. 0
7. PCB+DEN	23. 3	16	9	183. 3	317. 6	20. 9	6. 6
8. 3'-Me-DAB+DEN	23. 8	16	13	182. 9	387. 3	64. 5	16. 7
9. 2-FAA+DEN	20. 5	16	11	184. 9	310. 5	38. 0	12. 2
10. PCB+3'-Me-DAB+DEN	24. 0	16	13	187. 7	309. 2	20. 5	6. 8
11. PCB+2-FAA+DEN	23. 7	16	12	180. 7	276. 0	20. 8	7. 6
12. Control	24. 0	12	10	184. 6	518. 9	12. 1	2. 3

[a] PCB, 0.03% Kanechlor 500; 3'-Me-DAB, 0.06%; 2-FAA, 0.016%; DEN, 0.0025%.
[b] Animals fed experimental diet for 20 wk and then stock diet for 4 wk. Numbers <24 indicate that rats died before 24 wk.
[c] Rats that died within 16 wk from start of expt. were excluded from initial No.

8 and 9, treated with 2 carcinogens, liver weights increased greatly due to development of large liver tumors.

Gross Findings in the Liver

The livers of rats treated with PCB alone had no tumors. The surfaces were smooth and most were speckled yellowish-white (fig. 1). In contrast, the livers of rats treated with 3'-Me-DAB, 2-FAA, and/or DEN had irregular surfaces with multiple large, yellowish tumors up to 2.5 cm in diameter. Some cancerous nodules showed central umbilications and hemorrhagic change. In many animals, malignant neoplasms of the liver and metastases from liver tumors were noticed in the omentum, mesenteric lymph nodes, and diaphragm. Malignant neoplasms and metastases were most frequent in rats treated with 2 hepatocarcinogens, such as those in group 9 (fig. 2). Non-neoplastic areas of the liver showed cirrhotic changes, and the surface of the liver of some rats treated with 2-FAA had many small cysts. Administration of PCB clearly reduced neoplastic and cirrhotic changes of the liver, even in animals treated with 2 hepatocarcinogens (fig. 3). However, small white nodules were seen in the livers of animals treated with PCB plus 2 carcinogens.

Histologic Findings in the Liver (Table 2)

Hepatocellular carcinomas.—Treatment with 1 carcinogen induced hepatocellular carcinomas. These were found in 15 of 23 rats (65.2%) treated with 3'-Me-DAB, 7 of 13 (53.8%) treated with 2-FAA, and 12 of 13 (92.3%) treated with DEN. No rats treated with PCB alone developed hepatocellular carcinomas. Treatment with 2 carcinogens resulted in a higher incidence of hepatocellular carcinomas than treatment with carcinogen plus PCB, i.e., in 12 of 13 rats (92.3%) treated with 3'-Me-DAB plus DEN and 9 of 11 (81.8%) treated with 2-FAA plus DEN. However, the incidence was very low in animals treated with 2 carcinogens plus PCB [1 of 13 rats (7.7%) treated with 3'-Me-DAB and DEN plus PCB, and none of 12 animals treated with 2-FAA and DEN plus PCB].

Nodular hyperplasia.—Almost all rats in groups treated with 1 carcinogen developed nodular hyperplasia in the liver: 22 of 23 rats (95.7%) fed 3'-Me-DAB and 13 of 13 rats (100.0%) fed 2-FAA or DEN. No nodular hyperplasia was found in the livers of rats treated with PCB only. Moreover, nodular hyperplasia did not develop in the livers of animals treated with 3'-Me-DAB or DEN plus PCB and developed in only 1 of the 17 rats (5.9%) treated with 2-FAA plus PCB. All rats treated with 2 carcinogens developed nodular hyperplasias in the liver. However, these were found only in 4 of 13 rats (30.8%) treated with 3'-Me-DAB and DEN plus PCB and in 3 of 12 rats (25.0%) treated with 2-FAA and DEN plus PCB.

Non-neoplastic areas.—The livers of rats treated with PCB showed parenchymal cell hypertrophy and centrolobular areas with foamy or vacuolated cytoplasm. Nuclear irregularities of parenchymal cells were occasional (fig. 4). In rats treated with 1 or 2 chemical carcinogens, oval cell infiltration and bile duct proliferation were usually noticed. Cholangiofibrosis developed more often in rats treated with 2 carcinogens than in those treated with only one. In rats treated with 2 carcinogens plus PCB, oval cell infiltration and bile duct proliferation in the liver were slight.

DISCUSSION

Results of the present study show that PCB inhibit the hepatocarcinogenic actions of 3'-Me-DAB, 2-FAA, and DEN in rats. Previously, several authors reported the tumorigenic action of PCB on rat and mouse liver (*8–10*); in the present work, we observed no hepatocarcinogenesis in rats treated with PCB only. This difference may depend on the dose and period of administration of PCB, because we found that many hyperplastic nodules developed in the livers of male rats treated with 1000 ppm PCB (Kanechlor 500) for 72 weeks (Ito N, Nagasaki H, Makiura S: Unpub-

MUNS 082670

TABLE 2.—*Histopathologic changes of the liver in male rats treated with PCB and chemical carcinogens for 24 weeks*

Group [a]	Effective No. of rats [b]	Histopathology of liver: Fatty changes	Cell hypertrophy	Oval cell infiltration	Bile duct proliferation	Cholangiofibrosis [c]	Nodular hyperplasia [c]	Cancer [c]
1. 3'-Me-DAB	23	+	±	+	+	1 (4.3)	22 (95.7)	15 (65.2)
2. 2-FAA	13	±	±	+ +	+ +	0	13 (100.0)	7 (53.8)
3. DEN	13	+	±	+	+	0	13 (100.0)	12 (92.3)
4. PCB	19	+ +	+ +	±	+	0	0	0
5. PCB + 3'-Me-DAB	23	+	+	±	±	0	0	0
6. PCB + 2-FAA	17	+	+	±	±	1 (5.9)	1 (5.9)	0
7. PCB + DEN	9	+ +	+	±	+	1 (11.1)	0	0
8. 3'-Me-DAB + DEN	13	+	±	+ +	+ +	4 (30.8)	13 (100.0)	12 (92.3)
9. 2-FAA + DEN	11	+	±	+ +	+ +	0	11 (100.0)	9 (81.8)
10. PCB + 3'-Me-DAB + DEN	13	+	±	+	+	3 (23.1)	4 (30.8)	1 (7.7)
11. PCB + 2-FAA + DEN	12	+	±	+	+	2 (14.3)	3 (25.0)	0
12. Control	10	−	−	−	−	0	0	0

[a] See footnote a, table 1.
[b] See footnote r, table 1.
[c] Number (and percent) of rats with cholangiofibrosis, nodular hyperplasia, or cancer of liver.

lished results). In the present work, the livers of rats treated with PCB alone showed fatty changes and cell hypertrophy, as reported by other investigators (*6, 12*). Also, administration of 2 carcinogens caused marked oval cell infiltration and bile duct proliferation, whereas administration of PCB with 2 carcinogens greatly reduced these histologic changes.

Treatment for 24 weeks with 0.05% benzene hexachloride (BHC) had a hepatocarcinogenic action in mice (*13–15*), and supplementation of BHC with 0.025% PCB for 24 weeks promoted this effect (*9*). This suggested that a mixture of hepatocarcinogens and PCB might have a synergistic action in promoting hepatocarcinogenesis in experimental animals. However, in the present work, PCB clearly inhibited the production in rats of liver neoplasms induced by potent hepatocarcinogens other than BHC.

Incidence of cytoplasmic lesions of liver parenchymal cells in the smooth endoplastic reticulum is increased, and microsomal enzymes are induced, in animals given PCB and in man poisoned with PCB (*9, 16*). These effects of PCB have been investigated, not only histologically and by electron microscopy but also by biochemical analysis (*17–19*). Phenobarbital or methylcholanthrene are reported to have protective effects against the hepatocarcinogenic actions of azo dyes or 2-FAA (*11, 20–24*). Their effects in the test animals are apparently due to stimulation of liver enzymes which convert the carcinogens to noncarcinogenic metabolites (*25*). However, Hoch-Ligeti et al. (*26*) and Makiura et al. (*27*) reported that methylcholanthrene did not inhibit the induction by DEN of liver cancer in rats. These results and the inhibitory effect of PCB on the hepatocarcinogenic actions of compounds such as 3'-Me-DAB and 2-FAA suggest that a microsomal enzyme system metabolizing drugs may be involved somehow in the inhibitory effect of PCB. However, they suggest that not only a microsomal enzyme system but also some other factors may have an important function in the inhibitory effect of PCB on the carcinogenicity of DEN. The synergistic actions of mixtures of certain hepatic carcinogens have been observed in rats (*28, 29*). The synergistic actions of DEN and 3'-Me-DAB or 2-FAA were also observed in this work. Combinations of 2 carcinogens caused marked invasive growth of hepatic carcinomas and death from tumors early during the observation period. However, PCB inhibited the development of hepatic carcinomas even in animals treated with 2 carcinogens. This suggests that PCB must be very strong inducers of the enzymes that metabolize carcinogens.

The difference between the present results and reports on the effect of PCB in promoting liver tumorigenesis induced by BHC in mice suggests that the mechanism of carcinogenesis by BHC, which contains many chloride groups, differs from that by other hepatocarcinogens such as 3'-Me-DAB, 2-FAA, and DEN.

REFERENCES

(*1*) KORMAN JH, TEN NOEVER DE BRAUW MC, DE VOS RH: Chlorinated biphenyls in fish, mussels and birds from the river Rhine and the Netherlands coastal area. Nature (Lond) 221:1126–1128, 1969

(*2*) REYNOLDS LM: Polychlorobiphenyls (PCBs) and their interference with pesticide residue analysis. Bull Environ Contam Toxicol 4:128–143, 1969

(*3*) PRAKALL DB, LAGER JL: Polychlorinated biphenyls, another long life widespread chemical in the environment. Bioscience 20:958–964, 1970

(*4*) TSAO CH, SULLIVAN WN, NORMYSTEIN I: A comparison of evaporation rates and toxicity to house flies of lindane and lindane-chlorinated polyphenyl deposits. J Econ Entomol 46:882–884, 1953

(*5*) VOS JG, BEEMS RB: Dermal toxicity studies of technical polychlorinated biphenyls and fractions thereof in rabbits. Toxicol Appl Pharmacol 19:617–633, 1971

(*6*) KOLLER LD, ZINKL JG: Pathology of polychlorinated biphenyls in rabbits. Am J Pathol 70:363–378, 1973

(*7*) FURNEMANN TW, LICHTENSTEIN EP: Increase in the toxicity of organophosphorus insecticides to house flies due to polychlorinated biphenyl compounds. Toxicol Appl Pharmacol 22:628–640, 1972

(*8*) NAGASAKI H, TOMII S, MEGA T, et al: Hepatocarcinogenicity of polychlorinated biphenyls in mice. Gann 63:803, 1972

MONS 082671

(9) ITO N, NAGASAKI H, ARAI M, et al: Histopathologic studies on liver tumorigenesis induced in mice by technical polychlorinated biphenyls and its promoting effect on liver tumors induced by benzene hexachloride. J Natl Cancer Inst 51:1637–1646, 1973

(10) KIMURA N, BABA T: Neoplastic changes in the rat liver induced by polychlorinated biphenyl. Gann 64:105–108, 1973

(11) MARUYAMA M, ITO N, KOSHIBA Y, et al: Influence of 3-methylcholanthrene on liver carcinogenesis in rats ingesting DL-ethionine, 3'-methyl-4-dimethylaminoazobenzene, and N-2-fluorenylacetamide. Cancer Res 27:2011–2019, 1967

(12) ITO N, NAGASAKI H, ARAI M: Interactions of liver tumorigenesis in mice treated with technical polychlorinated biphenyls (PCBs) and benzene hexachloride (BHC). Int Symp on Ecolog Chem, Susono, Japan, 1973, pp 141–147

(13) NAGASAKI H, TOMII S, MEGA T, et al: Carcinogenicity of benzene hexachloride (BHC). *In* Topics in Chemical Carcinogenesis, Proc 2d Int Symp of The Princess Takamatsu Cancer Research Fund. Tokyo, Univ Tokyo Press, 1972, pp 343–353

(14) ———: Hepatocarcinogenic effect of α-, β-, γ- and δ-isomers of benzene hexachloride in mice. Gann 63:393, 1972

(15) ITO N, NAGASAKI H, ARAI M, et al: Histologic and ultrastructural studies on hepatocarcinogenicity of benzene hexachloride in mice. J Natl Cancer Inst 51:817–826, 1973

(16) HIRAYAMA C, IRIBA T, YAMAMOTO T: Fine structural changes of the liver in a patient with chlorobiphenyl intoxication. Fukuoka Acta Medica 60:455–461, 1969

(17) TANAKA K, KOMATSU F: Shortening of hexobarbital sleeping time after small doses of PCB in rats. Fukuoka Acta Medica 63:360–366, 1972

(18) LATTERST CL, FARBER TM, BAKKA AM, et al: Effect of polychlorinated biphenyls on hepatic microsomal enzymes in the rats. Toxicol Appl Pharmacol 23: 112–122, 1972

(19) CHEN TS, DUFFUS KP: Studies on the enzyme inducing effect of polychlorinated biphenyls. Toxicol Appl Pharmacol 26:504–512, 1973

(20) PERAINO C, FRY MR, STAFFELDT E: Reduction and enhancement by phenobarbital of hepatocarcinogenesis induced in the rat by 2-acetylaminofluorene. Cancer Res 31:1506–1512, 1971

(21) IMMATE M, WATANABE M, OBARISHIA S: Effect of barbital on carcinogenic actions and metabolism of 4-dimethylaminoazobenzene. Gann 58:267–881, 1967

(22) KUNZ W, SCHAUDE G, THOMAS C: The effect of phenobarbital and halogenised hydrocarbons on nitrosamine carcinogenesis. Z Krebsforsch 72:291–304, 1969

(23) MILLER EC, MILLER JA, BROWN RR, et al: On the protective action of certain polycyclic aromatic hydrocarbons against carcinogenesis by aminoazo dyes and 2-acetylaminofluorene. Cancer Res 18:469–477, 1958

(24) GRAM TE, ROGERS LA, FOUTS JR: Effect of pretreatment of rabbits with phenobarbital or 3-methylcholanthrene on the distribution of drug-metabolizing enzyme activity in subfractions of hepatic microsomes. J Pharmacol Exp Ther 157:485–445, 1967

(25) GELBOIN HV: Carcinogens, enzyme induction, and gene action. Adv Cancer Res 10:1–81, 1967

(26) HOCH-LIBERT C, ARGUS MF, ARCOS JC: Combined carcinogenic effects of dimethylnitrosamine and 3-methylcholanthrene in the rat. J Natl Cancer Inst 40:535–549, 1968

(27) MAKIURA S, KAMAMOTO Y, SUGIHARA S, et al: Effect of 1-naphthyl isothiocyanate and 3-methylcholanthrene on hepatocarcinogenesis in rats treated with diethyl-p-nitrosamine. Gann 64:101–104, 1973

(28) MACDONALD JC, MILLER EC, MILLER JA, et al: The synergistic action of mixtures of certain hepatic carcinogens. Cancer Res 12:50–54, 1952

(29) ITO N, HIASA Y, KONISHI Y, et al: The development of carcinoma in liver of rats treated with *o*-toluylenediamine and the synergistic and antagonistic effects with other chemicals. Cancer Res 29:1137–1148, 1969

MONS 082672



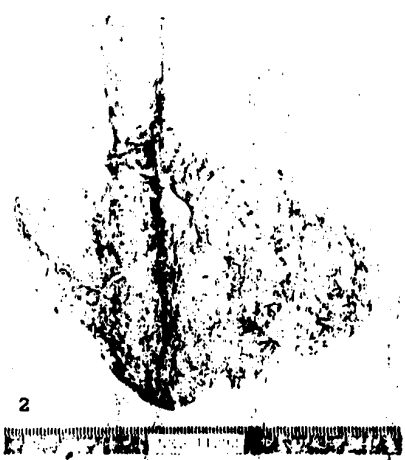





FIGURE 1.—Liver of rat given PCB. *Note* speckled, yellowish-white, smooth surface.

FIGURE 2.—Liver of rat treated with 3'-Me-DAB and DEN. Many neoplastic changes and small cysts are seen.

FIGURE 3.—Liver of rat treated with 3'-Me-DAB, DEN, and PCB. The smooth surface has a few white spots.

FIGURE 4.—Fatty changes and nuclear irregularities in liver of rat treated with PCB only. Some oval cell infiltration is seen. Hematoxylin and eosin. × 100

MONS 082673