Induction of Adenofibrosis and Hepatomas of the Liver in BALB/cJ Mice by Polychlorinated Biphenyls (Aroclor 1254) [1]

Renate D. Kimbrough, M.D., [2, 3] *and Ralph E. Linder* [2, 4, 5]

SUMMARY—Two groups of 50 BALB/cJ inbred male mice were fed 300 ppm of a polychlorinated biphenyl, Aroclor 1254, in the diet for 11 and 6 months, respectively. The 6 months' feeding was followed by 5 months' recovery. Two additional groups of 50 mice each were fed plain chow. All 22 surviving mice fed Aroclor 1254 for 11 months had greatly enlarged livers representing 25% of their body weight, whereas those fed the experimental diet for 6 months only had slightly, but significantly, enlarged livers. Adenolibrosis was observed in all 22 livers of mice fed Aroclor 1254 for 11 months but not in the other groups. Of the 22 mice fed 300 ppm Aroclor 1254 for 11 months, 9 had 10 hepatomas measuring 0.1–1.5 cm in diameter. One of 24 surviving mice fed Aroclor 1254 for only 6 months, followed by a control diet for 5 months, had a hepatoma 0.3 cm in diameter. No controls had hepatomas.—J Natl Cancer Inst 53: 547–552, 1974.

IN PREVIOUS STUDIES with Sherman rats, prolonged feeding of polychlorinated biphenyls (PCB's) Aroclor 1254 particularly, but also Aroclor 1260, induced a lesion, classified as adenofibrosis, in the liver (*1, 2*). Edwards and White (*3*) and Stewart and Snell (*4*) described this lesion in detail.

On gross inspection adenofibrosis, also called cholangiofibrosis, is firm and grayish white and has a pitted or granular surface. Microscopically, it consists of fibrosis and proliferated, atypical-appearing glandular epithelium that forms cysts and ducts. To ascertain whether this lesion could also be produced in mice, we conducted the present study.

MATERIALS AND METHODS

Two hundred 5- to 6-week-old BALB/cJ inbred male mice were purchased from The Jackson Laboratory, Bar Harbor, Maine. According to information from the Jackson Laboratory (*5–7*), this strain has a very low incidence of spontaneous tumors, particularly hepatomas.

The mice were distributed randomly into 4 groups of 50. They were tagged individually and caged in groups of 5. The mice were weighed every 2 weeks for the first 6 weeks and thereafter every 4 weeks. Two groups of 50 mice each were fed 300 ppm Aroclor 1254 in ground Purina Laboratory Chow. After 6 months of exposure, 1 group was given plain ground chow, while the other group consumed the experimental diet for 11 months. The 2 additional groups were controls and were fed plain ground laboratory chow throughout the 11-month study. Food consumption was measured during the 2d and 6th week of exposure and thereafter every 8 weeks in the group exposed to the experimental diet for 11 months and in 1 control group.

The Aroclor 1254 (Lot AK-38, from Monsanto Chemical Co., St. Louis, Mo.) was first dissolved in ether and then mixed with cornstarch. The ether was allowed to evaporate, and the Aroclor 1254–cornstarch mixture was added to increasing amounts of ground chow.

Early in the experiment, some mice were lost because of fighting. All mice, including controls, were caged in pairs 2 months after onset of the experiment. Since most mice that died did so early in the study and often showed a great deal of autolysis, they were not included in the final evaluation of the liver pathology. Organs of all mice that were killed were inspected grossly for lesions; the livers were removed, weighed, fixed, and then carefully inspected grossly for hepatomas. Any abnormal-appearing tissue was also examined microscopically. The tissues were fixed in 4% buffered formaldehyde, stained with hematoxylin and eosin, and examined with the light microscope.

RESULTS

In the control group, the food consumption ranged from 167 to 198 g/kg body weight/day. In the group fed Aroclor 1254 for 11 months, it ranged from 159 to 171 g/kg body weight/day, which resulted in a mean dosage level of Aroclor 1254 of 49.8 mg/kg day. During the first 4 months, 23 mice died in the 2 control groups and 20 in the 2 experimental groups. Table 1 gives the total survivors in the different groups, body and liver weights, and incidence of hepatomas. A slight, but statistically significant, increase in body weight was observed in mice receiving the experimental diet for 11 months. Compared to controls, these mice had large livers, representing 25% of their body weight. The surface of the liver of 9 of these mice contained nodules of varying sizes up to 1.5 cm in diameter. All livers of the mice that were killed in this group showed orange fluorescence under ultraviolet light, indicative of elevated porphyrin levels. The body weights of the mice fed Aroclor 1254 for only 6 months were comparable to those of the control groups at the time they were killed; but, when the treated diet was discontinued, they weighed an average of 3 g more than the controls.

Upon microscopic examination of the livers of the 34 and 24 surviving controls in the 2 groups, 45 livers were normal. A few times a liver cell showed a large, hyperchromatic nucleus or binucleation. The re-

[1] Received March 1, 1974; accepted April 18, 1974.

[2] Formerly Environmental Protection Agency, Chamblee Toxicology Laboratory, 4770 Buford Highway, Chamblee, Ga. 30341.

[3] *Present address:* Center for Disease Control, Toxicology Section, 1600 Clifton Road, N.E., Atlanta, Ga. 30333.

[4] *Present address:* Environmental Protection Agency, Research Triangle Park, N.C. 27711.

[5] Dr. H. L. Stewart kindly reviewed the slides and Dr. M. Deringer supplied the information on the spontaneous incidence of hepatomas.

MONS 085757

TABLE 1.—*Body weights, liver weights, and hepatoma incidence in surviving mice fed Aroclor 1254 in the diet and in controls fed plain chow*

Dietary level (ppm)	Dosage level (mg/kg/day)	Time exposed to experimental diet	Total mice	Total survivors	Final body weight of survivors: arithmetic mean (g)	Liver weight: arithmetic mean (g)	Liver weight expressed as percentage of body weight	Hepatoma incidence* in survivors
0	0	0	50	34	30.7	1.77	5.8	0
0	0	0	50	24	30.3	1.78	5.8	0
300	49.8	11 months	50	22	33.8†	8.62†	25.5†	3(0.1–0.4 cm Ø) 3(0.5 cm Ø) 4(1–1.5 cm Ø)
300	Not checked	6 months and 5 months' recovery	50	24	31.5	2.37†	7.5†	1(0.3 cm Ø)

*Determined when mice were 12 months old. Ø = diameter.
†P<0.001. A t-test was used for the statistical evaluation.

maining 13 livers had focal, round-cell infiltrates and occasionally small areas of necrosis and fibrosis. All mice with round-cell infiltrates in the liver had small skin abscesses, usually near the groin, which appeared to be abscesses of the preputial gland.

Microscopic examination of the livers of the 22 survivors in the group receiving the experimental diet for 11 months (fig. 1) showed markedly enlarged liver cells. The nuclei of the hepatocytes were enlarged, hyperchromatic, and atypical. The cytoplasm was either smooth or vacuolated. Macrophages and Kupffer's cells contained a brown pigment. Slight, diffuse interstitial fibrosis and numerous, large extracellular hyaline bodies were also seen. Some livers had extensive areas of coagulation necrosis and fibrosis (fig. 2). A general pleomorphism was noted in a number of livers. Degeneration, necrosis, and atrophy of individual liver cells were also observed.

A few nuclei showed karyorrhexis. Some smaller cells and proliferation of the focal nodular type were also noted. The irregular outer surface of the liver with areas of retraction indicated that proliferation, atrophy, and regression had occurred. Occasional calcareous deposits ≈5–8μ in diameter were present. In each of the livers, several areas were seen where the parenchyma was replaced by glandular formations of proliferated epithelial cells which formed ducts and often produced mucus. These epithelial cells were surrounded by either sparse (fig. 3) or abundant connective tissue.

In addition to the above findings for all 22 livers of mice treated for 11 months (table 1), 10 hepatomas were found (fig. 4); of these, 3 measured 0.1–0.4 cm in diameter, 3 measured 0.5 cm, and 4 measured 1–1.5 cm. The tumors developed in a total of 9 mice. On gross inspection, they appeared as tan nodules. On microscopic examination, they consisted of well-differentiated hepatocytes that were relatively uniform and usually smaller than the surrounding liver cells. The tumors were well circumscribed and surrounded by compressed hepatic parenchyma or strands of fibrous tissue. The larger tumors contained areas where the sinusoids were dilated and filled with a pink-staining amorphous material. On gross inspection of the organs at autopsy, metastases were not seen. However, detailed screening for metastases including serial sectioning of lungs was not undertaken.

Most livers of the 24 mice surviving 6 months of dietary exposure to PCB's followed by a 5-month recovery had enlarged cells; often these liver cells had enlarged, atypical, hyperchromatic nuclei, although the livers at autopsy weighed only slightly more than those of the controls. Necrosis of individual liver cells was observed and some nuclei showed karyorrhexis.

The macrophages and Kupffer's cells usually contained a brown pigment. Many liver cells, particularly those in the periphery of the lobules, had vacuolated cytoplasm. The livers of about two-thirds of these mice showed slight-to-moderate diffuse, interstitial fibrosis. The outer surface of the livers still showed small indentations but not as pronounced as those in the group receiving PCB's for 11 months. Numerous extracellular hyaline bodies were observed in some

MONS 085758

livers. In addition, many calcareous deposits, light in the center and darker in the periphery, were also seen (fig. 5). They were more frequent in this group than in the one fed PCB's for 11 months. A few livers showed bile duct proliferation. Only 1 liver contained a small hepatoma measuring 0.3 cm in diameter. The liver cells comprising the hepatoma were well-differentiated hepatocytes.

Except for the subcutaneous abscess formations in some mice and 1 sweat gland adenoma, no other findings of note were made in the mice of any groups.

DISCUSSION

Two significant findings were made in the present study: adenofibrosis of the liver and hepatomas. Thus adenofibrosis can also be induced in mice and does not occur solely in rats where it has been described previously (*1, 3*). A similar lesion may occur in hamsters (*8*). In the mouse lesion, the epithelial component was much better differentiated and less pleomorphic than in the rat lesion (*1*). The pattern of the lesions and the interrelationship with fibrosis were the same. Ducts and cysts formed in areas of adenofibrosis in both the mouse and rat livers. Whether adenofibrosis is a precursor of a malignant lesion or occurs concomitantly with malignant lesions of the liver is still debated. In an excellent review, Stewart and Snell (*4*) concluded that the lesion showed no convincing evidence of a precancerous lesion. Reuber (*8*) postulated that cholangiocarcinomas would develop from adenofibrosis in rats as well as hamsters.

The mouse strain used in this study only rarely develops hepatomas spontaneously. Peters et al. (*5*) observed 6 hepatomas in a group of 2000 BALB/cCr mice, a subline from the Andervont subline at the National Cancer Institute; one would expect incidences similar to those observed in the BALB/cJ subline. Madison et al. (*6*) found 13 (0.62%) hepatomas in 2088 BALB/cCr mice 18 months of age. In the present study none of the controls, 1 of 24 mice fed PCB's for 6 months, and 9 of 22 mice fed PCB's for 11 months developed hepatomas.

Although the hepatomas were well differentiated, according to Andervont and Dunn (*9*), they represent potentially malignant lesions, a certain percentage of which can metastasize and be transplanted. From the appearance of the lesion, it is impossible to predict which tumor will be malignant. The size of the liver tumors cannot be used as a criterion. Quite possibly the tumors would have been larger and would have occurred more often had the mice been allowed to complete their lifespans.

A Japanese PCB, Kanechlor 400, was recently reported to have induced hepatomas in female Donryu rats (*10*), and Kanechlor 500, when fed at a dietary level of 500 ppm for 32 weeks, produced hepatomas in male dd mice (*11*). The dietary levels of PCB's in our study, as well as those of the Japanese studies, were high compared to levels that could be found in the normal human diet. Presently, temporary tolerance levels, ranging from 0.2 ppm in infant food to 5 ppm in fish and poultry, have been set by the U.S. Food and Drug Administration (FDA) under the authority of Section 406 of the Federal Food, Drug, and Cosmetic Act. The temporary tolerance level in poultry was set on a fat basis. The FDA concluded that the total daily food intake of PCB's should not exceed 1.4 mg/adult (*12*). The mice in the present study consumed daily ≈50 mg PCB's/kg body weight, which is 2500 times as much as the theoretical daily human consumption of 0.02 mg/kg body weight calculated by the FDA. The present study does not indicate whether lower levels would also induce hepatomas or whether a "no-effect level" for hepatomas could be established in rodents.

We have not previously observed calcareous deposits in livers of experimental rodents. The deposits we presently observed could represent calcification of small foci of tissue necrosis, particularly in areas where extracellular hyaline bodies were present.

REFERENCES

(*1*) Kimbrough RD, Linder RE, Gaines TB: Morphological changes in livers of rats fed polychlorinated biphenyls. Arch Environ Health 25:354–364, 1972

(*2*) Kimbrough RD: Pancreatic type tissue in livers of rats fed polychlorinated biphenyls. J Natl Cancer Inst 51:679–681, 1973

(*3*) Edwards JE, White J: Pathologic changes with special reference to pigmentation and classification of hepatic tumors in rats fed p-dimethylaminoazobenzene (butter yellow). J Natl Cancer Inst 2:157–183, 1941

(*4*) Stewart HL, Snell KC: The histopathology of experimental tumors of the liver of the rat. A critical review of the histopathogenesis. Acta Un Int Contr Cancer 13:770–803, 1957

(*5*) Peters RL, Rabstein LS, Spahn GJ, et al: Incidence of spontaneous neoplasms in breeding and retired breeder BALB/cCr mice throughout the natural life span. Int J Cancer 10:273–282, 1972

(*6*) Madison RM, Rabstein LS, Bryan WR: Mortality rate and spontaneous lesions found in 2928 untreated BALB/cCr mice. J Natl Cancer Inst 40:683–685, 1968

(*7*) Deringer MK: Occurrence of mammary tumors, reticular neoplasms, and pulmonary tumors in strain BALB/cAnDe breeding female mice. J Natl Cancer Inst 35:1047–1052, 1965

(*8*) Reuber MD: Histogenesis of cholangiofibrosis and well differentiated cholangiocarcinoma in Syrian hamsters given 2-acetoamidofluorene or 2-diacetoamidofluorene. Cann 59–239–246, 1968

(*9*) Andervont HB, Dunn TB: Transplantation of spontaneous and induced hepatomas in inbred mice. J Natl Cancer Inst 13:455–503, 1952

(*10*) Kimura NT, Baba T: Neoplastic changes in the rat liver induced by polychlorinated biphenyl. Gann 64:105–108, 1973

(*11*) Ito N, Nagasaki H, Arai M, et al: Histopathologic studies on liver tumorigenesis induced in mice by technical polychlorinated biphenyls and its promoting effect on liver tumors induced by benzene hexachloride. J Natl Cancer Inst 51:1637–1646, 1973

(*12*) Food and Drug Administration: Final environmental impact statement rule making on polychlorinated biphenyls. Dec. 18 1972

MONS 085759

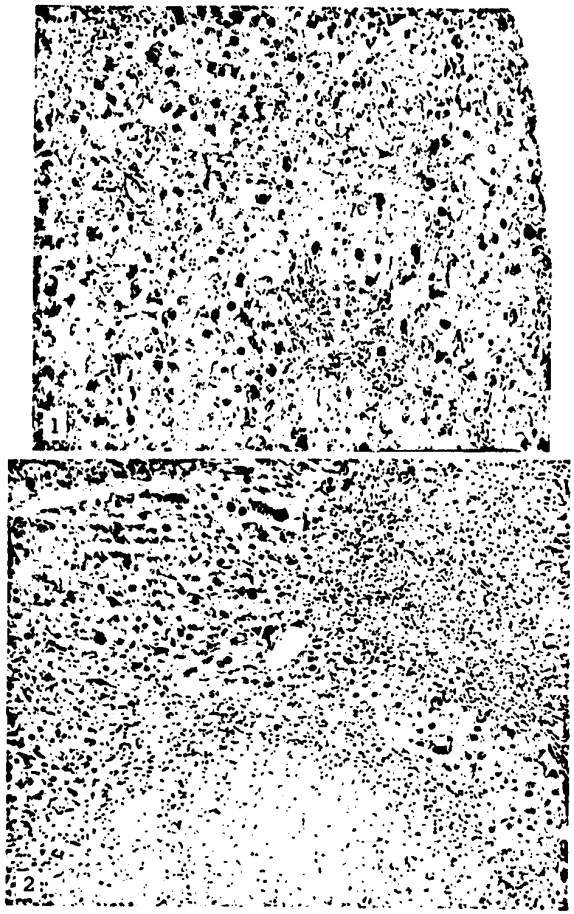

FIGURE 1.—Liver of mouse fed 300 ppm Aroclor 1254 for 11 months. *Note* enlarged pleomorphic hepatocytes and interstitial fibrosis in some areas. Hematoxylin and eosin (H & E). × 100

FIGURE 2.—Liver of mouse fed 300 ppm Aroclor 1254 for 11 months. *Note* extensive coagulation necrosis and fibrosis. H & E. × 100

MONS 085760



FIGURE 3.—Liver of mouse fed 300 ppm Aroclor 1254 for 11 months. *Note* epithelial cells forming ducts and surrounded by connective tissue. H & E. × 125

fibrosis

× 100

NDER

MONS 085761





FIGURE 4.—Well-circumscribed hepatoma showing compressed hepatic parenchyma proper in the *upper right-hand corner*. H & E. × 20
FIGURE 5.—Liver of mouse fed Aroclor 1254 for 6 months, followed by recovery for 5 months. *Note* line of calcareous deposits traversing through *center* of section. H & E. × 125

MONS 085762