CRC Critical Rev. Volume 14 pp 33-86, 1985 ST0005903

LUNG RESPONSE TO PARTICULATES WITH EMPHASIS ON ASBESTOS AND OTHER FIBROUS DUSTS

Author: Ki Poong Lee
Department of Pathology
Haskell Laboratory
Du Pont Company
Department of Animal Science and Agricultural Biochemistry
University of Delaware
Newark, Delaware

NOTIC
This material is pro
U. S. Code 17 copyright

Referee: Jerrold L. Abraham
Department of Pathology
Upstate Medical Center
State University of New York
Syracuse, New York

I. INTRODUCTION

Pneumoconiosis might have already existed when man began to use tools to dig in the ground and to shape flints for arrow and spearheads. Occupational lung disease, especially related to mining, has been known by Greek, Egyptian, and Chinese physicians dating back to B.C. A variety of general definitions has been given to the term "pneumoconiosis". A recent definition is the presence of inhaled dust in the lungs and the tissue response to its presence. Dust consists of solid particles of mineral or organic origin dispersed in air either following mechanical disintegration of rocks, minerals, and other materials or to the decomposition of organic materials such as cotton fibers, pollens, and fungal spore. Dust is distinct from vapors, fumes (0.1 to 1.0 μm), and smokes although all these categories are commonly embraced by the general term "aerosol". Pneumoconiosis includes lung disorders due to inhaled dusts and dusts mixed with fume.

Today, we recognize many different types of pneumoconiosis as a result of the industrial revolution in the early 19th century. In the future, we are going to face new forms of occupational pneumoconiosis with many new products or processes which create both industrial and environmental particulates. Some dusts are so inert that they provoke only a mild macrophage response (dust particles engulfed by macrophages) with the general lung architecture totally intact while others cause widespread pulmonary damage such as fibrosis, granuloma, lung cancer, and/or pleural mesothelioma. The pulmonary response is determined by factors such as (1) nature of dust particles, (2) the site of dust deposition in the respiratory tract, (3) the amount of dust deposited in the lung (4) the exposure period, and (5) individual idiosyncrasy and immunological status. Certain dust may be antigenic and provoke immune reaction while others may predispose to tuberculosis or lung cancer.

The lung clearance mechanism presents a most remarkable defense to inhaled particles. Dust found in the lung is a small fraction of dust which is inhaled during a lifetime. A coal miner working under poor conditions may receive a total alveolar dust load of 1000 g during a lifetime. However, it is unusual to find more than about 40 g of dust in the lungs of miners at post-mortem examination.[1] This illustrates the importance of the lung clearance mechanism and suggests that removal of inhaled dust particles from the lungs is quite effective.

A difficult problem in occupational lung disease is to ascertain a causal relationship between a particular structural or functional derangement and an inhaled agent since many

ST0005904

pulmonary changes are not pathognomonic and similar tissue responses may be found in unexposed individuals. The clinical and pathological changes of chronic beryllium disease are very similar to sarcoidosis. It is also difficult to separate workers with asbestos-related pulmonary fibrosis from nonoccupational cryptogenic fibrosing alveolitis. Asbestos fibers or asbestos bodies in the lungs proves nothing more than the worker has been exposed to asbestos in the past, and does not provide absolute diagnostic value. In contrast to experimental animals in controlled conditions, workers are exposed to a variety of dust particles and infectious agents in addition to occupation-related dust exposure. Therefore, interpretation of human data is further complicated by the compounding effects of lifestyle factors such as cigarette smoking (which in many cases is quantitatively far greater than the subtle changes induced by inhalation of dust particles in the working environment). The types of tissue response induced by inorganic (mineral) dusts may be classified into five categories: (1) macrophage reaction (nuisance dust-soot, iron, TiO_2), (2) foreign body granuloma (beryllium, talc), (3) sarcoid-type granuloma (beryllium), (4) collagenized fibrosis: diffuse interstial (hard metals asbestos), nodular (quartz, silica), and (5) neoplasia (asbestos, nickel, ionizing radiation in mining).

Since various forms of dust induce a variety of pulmonary responses, it is beyond the scope of this brief review to discuss pneumoconiosis. This presentation is limited to the pulmonary response to nuisance dust, asbestos, manmade inorganic, and organic fibers. In addition, the respirability of dust and its clearance is discussed since knowledge about this mechanism is essential for understanding lung response to particulates.

II. DUST DEPOSITION

A. Aerodynamic Size

There are many ways to express particle size and most medical literature concerning pneumoconiosis has used the expression of actual or equivalent diameters. Recent scientific literature regarding dust deposition uses particle radius to express size. Nonspherical particles are frequently expressed in terms of equivalent spheres, for example, on the basis of equal volumes, equal masses, or equal aerodynamic drag. A parameter of common use is the aerodynamic diameter. This term incorporates both particle density and drag and can be described as the diameter of a unit density sphere having the same terminal settling velocity as the particle in question. The upper limits of aerodynamic diameter in respirable compact particles is approximately 10 μm.[2-4] Relationships between aerodynamic size and dimensional parameters of fibers are investigated with a gravitational aerosol spectrometer.[5] The length of a fiber has only limited influence on its aerodynamic size while there is a close relationship between the diameter of a fiber and its aerodynamic size.[6] The upper limit of respirability for long fibrous particles is approximately 10 μm aerodynamic diameter which corresponds to 3.5 μm fiber diameter.

B. Mechanism of Dust Deposition

Most environmental or industrial dusts contain particles in a wide range of sizes and shapes. The fraction in each size range needs to be measured to properly assess the potential health hazard. The inhalation toxicity of dust particles is highly dependent upon the respirability of dust particles, the nature of the particles, and the site of their deposition in the respiratory tract. Deposition efficiency depends upon the size, shape, density, aerodynamic properties of the particles, along with the anatomy of the airways. Five mechanisms involved in dust deposition within the airways are interception, impaction, sedimentation, diffusion, and electrostatic precipitation.

Interception — This process is usually insignificant in the case of nonfibrous particles but is important for fibrous dust particles[7] such as asbestos, fiberglass, or inorganic fibers.

DOW 07405

IST0005905

Fiber length is the most important deposition factor for interception. Fibers as long as 200 μm have been observed in human lungs.[5]

Impaction — Inhaled air follows a tortuous path through the nose or mouth to the branching airways in the lung. When air changes direction, the inertial momentum of particles tends to keep them moving in their prior directions, which can carry them onto the airway surfaces. For particles larger than 3 μm in aerodynamic diameter, this process is most important in deposition in the nasopharyngeal and tracheobronchial regions.[8,9]

Sedimentation — Gravitational sedimentation can occur in all airways except for a few vertical airways. It is an important mechanism for deposition in the smaller bronchi, bronchioles, and alveolar ducts (where the airways are small and the air velocity low). Sedimentation becomes less effective when the terminal setting velocity of the particle falls below 0.001 cm/sec, which corresponds to a unit density sphere of 0.5 μm diameter. This speed (terminal velocity) is proportional to the density of the particles and the square of its diameter. Large particles fall considerably faster than small ones and a particle of silica or iron falls faster than a pollen grain of the same size. Special consideration must be made for particles greater than about 20 μm and for those with diameters smaller than 1 μm.

Diffusion — Inhaled submicron particles are continuously subjected to bombardment by surrounding gas molecules. This induces a random movement of the particles (Brownian motion) which result in diffusion from one region of a gas volume to another. The diffusivity of a particle is inversely proportional to its diameter but is independent of its density. Both diffusivity and sedimentation have very low values for particles with diameters above about 0.5 μm.[1] For particle diameters smaller than 0.5 μm[2] diffusional deposition is important in small airways and alveoli and at airway bifurcations.

Electrostatic precipitation — Most ambient particles have reached charge equilibrium and have low charges. Thus, deposition due to charge is usually small in comparison to that by other mechanisms.[1,3]

C. Dust Deposition in the Nose

A very large fraction of inhaled particle deposition occurs in the anterior unciliated nares of the nasal passages where the particles are retained until they are removed mechanically, i.e., by nose blowing or sneezing. People who normally breathe through the mouth may expect greater dust deposition in their lungs than those who breathe only through the nose. Few particles larger than 20 μm in diameter and only about 50% of particles of 5 μm in diameter are able to penetrate the nose during breathing.[10] Many particles, even as small as 1 μm in diameter, are deposited in the nose during normal breathing — much of this is on the unciliated anterior portion. The nose is probably as an efficient filter as the ciliated airways.[11]

Nasal hairs provide an aerodynamic barrier to the penetration of particles of compact shape and also to fibrous particles. Experiments using a hollow cast containing artificial nasal hairs indicate that deposition of fibrous dust particles increases with increasing fiber length, with virtually no penetration of particles greater than 200 μm in length of fibrous particles.[8] Long fibers tend to have large diameters and consequently, substantial falling speed. The falling speed of most long fibers allows little time in the breathing zone, hence it is difficult for them to be taken into the respiratory system by either nose or mouth breathing.

D. Dust Deposition in Respiratory Region

To assess health hazard, it is important to know both the total deposition of inhaled particles and the proportion which is deposited beyond the terminal bronchioles. The initial pathological changes of pneumoconiosis are mainly in the bronchioles and adjoining alveoli. Most dust particles are irregular in shape and size and are aggregated into loosely formed

DOW 07406

EST0005906

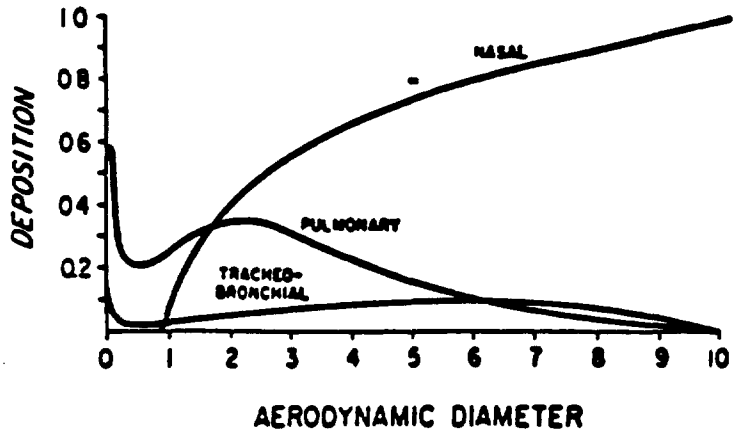

FIGURE 1. Regional deposition of inhaled aerosols as a function of particle size (μ). Nose breathing at 15 respirations per minute and 750 cm³ tidal volume. The pulmonary compartment refers to deposition beyond the terminal bronchiole. (From *Health Phys.*, 12, 179, 1966. With permission of the Health Physics Society.)

clumps. The deposition of this dust depends upon the mobility or settling velocity of the particles or aggregates and not on their apparent microscopic sizes.[1] A clump of coal dust may appear 15 μm in diameter, but if its structure is fairly loose, it may settle as a 7 μm diameter sphere. In the lung it will therefore be deposited in the same manner as if it were a 7 μm diameter sphere.

An illustration of fractional dust deposition in the nose, tracheobronchial airways, and alveoli is shown in Figure 1. The upper limits of dust deposition in the alveolar region is approximately 10 μm in aerodynamic diameter. There is disagreement as to the size of particles from which alveolar deposition is maximal, however, it is generally accepted that this particle size lies between 1 to 4 μm.[10-15]

E. Deposition of Fibrous Particles

Short fibers with an aspect ratio (length/diameter) less than five show little tendency for preferred orientation in the airways and would be too short to be greatly influenced by interception. Longer fibers (aspect ratio >5) show a marked tendency to align parallel to the stream of air flow and to deposit in the bifurcations of the respiratory bronchioles.[9] Deposition by interception begins to be effective with fibers approximately 6 μm in length and this increases with increasing fiber length.[16] An increase in fiber length also increases deposition by sedimentation and impaction. Fiber shape plays a very important role in deposition; for example, needle-shaped amphibole deposits five times more effectively than curled chrysotile. The curled shape of chrysotile behaves as a three-dimensional object with random alignment in airways and allows efficient deposition at airway bifurcations.[9,17] In contrast, straight amphibole fibers are essentially one-dimensional and tend to align with the airstream and allow deeper penetration than curled fibers.[3,9]

Size analysis of particles found in human lungs exposed to asbestos fibers indicates that upper limits of respirable fiber are either 3.5 μm in diameter or 200 μm in length.[18-22] Similar upper limits are seen in lungs of glass fiber workers.[23] In rodents exposed to either asbestos, fiberglass, or mineral fibers, the same upper limits are obtained, thus supporting the data obtained from humans.[24-26] Fibers with an aspect ratio of between 10 and 100 have an aerodynamic diameter which is between 3 and 4 times the fiber diameter. Thus, it would appear that fibers with diameters exceeding 2 μm and with aspect ratios greater than 10 will

DOW 07407

be virtually nonrespirable to rats.[27,28] In fibers with constant diameter, alveolar deposition decreases with increasing fiber length. Alveolar deposition falls steeply as aerodynamic diameter increases from 2 to 3 μm.[6] Total deposition in the human lungs increases steeply with the same range of aerodynamic diameters, but a relatively high deposition in alveolar region is obtained as compared with data from rats.[25] The lower deposition in the alveoli of the rats is attributed to efficient dust deposition in the nasal cavity since rats are obligatory nasal breathers and have larger, more convoluted nasal turbinates than man does. Dust particles of 2 and 3 μm aerodynamic diameter allow maximum dust deposition in alveoli of man. Rats exposed to fiberglass also show maximum deposition when particles are of that size.[25]

III. DUST CLEARANCE

In the airways, the dust clearing mechanism is aided by a mucous blanket covering the mucociliary escalator. The surface of each tracheal epithelial cell is covered with approximately 200 cilia and numerous microvilli.[29,30] The ciliary movement of large bronchi beats 1000 to 1500/min resulting in transport of 1 to 3.5 cm/min. Ciliary movement in the small bronchi is only 1/10 of this rate.[31] The mucous blanket derives its mucin from the goblet cells of the tracheobronchial mucosa and submucosal glands. The surface fluid is about 5 μm in thickness and consists of two phases: a watery sol layer on the cell surface covered by a thick viscoid-elastic gel layer of mucin.[31] The numerous microvilli in the ciliated cell may regulate the density of sol layer by absorbing fluid so that only tips of cilia contact the viscoid-elastic transporting layer during their flick motion.[31]

The speed of particle clearance depends on the particle size, shape, nature (inert, toxic), and deposition sites in the lung. Lung clearing mechanisms begin within 24 hr after inhalation of aerosols with particles being ingested by alveolar macrophages.[32-36] Following intratracheal instillation, particles are observed within alveolar macrophages, vesicles of membranous pneumocytes, and lymphatics within 30 min.[37] However, when inhaled particles are deposited in the alveolar walls and lung interstitum, particle elimination rate is delayed. Lung clearance of industrial dust such as diatoms[38] and asbestos[39,40] is slow as these materials have been found in the sputum of workers 20 years after cessation of heavy occupational exposure.

Short asbestos fibers (<5 μm) are cleared from the lung via conducting airways more efficiently than longer fibers (>50 μm). Fibers exceeding 50 μm in length are difficult for alveolar macrophages to transport to the ciliated epithelium of airways. Using data on fiber length distribution recovered by lavage, and knowing the dimensions of the rat alveolus (less than 150 μm in diameter when inflated) and alveolar macrophages (12 μm), it is suggested that long fibers are more likely to penetrate the alveolar wall since they tend to bridge the alveolar ducts or alveoli resulting in alveolar epithelial cell damage.[41] In general, most fibers recovered from human lungs are 5 to 10 μm indicating that these fiber sizes are cleared less efficiently than are short fibers.[18,20] The half-time for alveolar clearance of various asbestos types ranges from 60 to 90 days following a single inhalation exposure in rats.[26] Approximately 40% of titanium dioxide particles initially deposited clear during the first 25 days postexposure.[42] At 130 days postexposure, about 80% is cleared.[43] The TiO_2 content of the tracheal lymph nodes increases only slightly and is negligible during the first 25 days postexposure.[44]

The dust clearing mechanism for small particles in the alveoli is complex. The onset of alveolar clearance is within minutes after exposure and overlaps the rapid mucociliary clearance from the tracheobronchial airways.[45,46] The number of alveolar macrophages in both the alveoli and airways increases rapidly within hours,[32] but little is known how the dust-laden macrophages (dust cells) reach the mucociliary escalator in the airways. It has been postulated that a layer of fluid lining the alveolar surface moves directly to mucous

ST0005908



FIGURE 2. Fiberglass particles (arrows) in the cytoplasm of the membranous pneumocyte. Empty spaces (E) are artifacts due to removal of dust particles. Few effects are noted on the cell. Alveolar air space (A), capillary lumen (CL). (Magnification × 25,200.) (From Lee, K. P., Barras, C. E., Griffith, F. D., and Waritz, R. S., *Lab. Invest.*, 40, 123, 1979. With permission.)

blanket of the bronchioles[47-49] thus providing a moving surface for transport. Inhaled particles show a tendency to aggregate densely in the respiratory bronchioles, alveolar ducts, and adjoining alveoli within 1 week after inhalation exposure. Several possible dust cell or particle migration routes to the airway mucociliary escalator can be postulated: (1) penetration of alveolar walls, (2) entering lymphatic pathways to peribronchial lymphoid tissue, (3) entering alveolar vascular channel and reaching to the peribronchial walls or peribronchial lymphoid tissue, and (4) direct dust cell penetration of the bronchiolar walls from adjacent alveoli.

For many years it was believed that macrophages migrated from the lung interstitium to the alveolar air spaces, engulfed dust particles, and then migrated back into the interstitium. This concept is opposed by those who feel that dust particles penetrate the alveolar walls as naked particles and are subsequently ingested by interstitial macrophages.[50-53] However, it should be emphasized that dust deposition in the alveolar epithelial cells (Figure 2) does not occur on a massive scale since the phagocytic activity of alveolar lining cells is very limited as compared to that of alveolar macrophages (Figure 3). Based on observations that small numbers of particles are ingested by membranous pneumocytes following exposure to various types of dusts,[32,53-56] massive particle transportation to lung interstitum is more likely carried out by reentry of dust cells rather than direct entry of naked particles to the interstitium.

Tracheobronchial epithelial cells can ingest and retain particles.[57,58] Some particles transverse the epithelium and are found about 1 week later in peribronchial region.[32,59] Experiments using radioactive particles indicate that macrophages ingest the particles on the surface of

DOW 07409

ST0005909



FIGURE 3. Alveolar macrophage loaded with numerous inhaled asbestos (arrows) in the phagosomes. A migrating macrophage protruded pseudopodia (p) through alveolar wall (AW). Alveolar air space (A), collagen fibers (C), membranous pneumocyte (M).

the airways before dust cells penetrate the epithelium. This occurs predominantly in areas where the epithelium is cuboidal (containing relatively few ciliated cells).[60] Inhaled radioactive particles are deposited beneath the basement membrane of intrapulmonary airways between 7 and 17 days after inhalation, but much sooner (24 hr) after intratracheal instillation.[61]

The mediastinal and tracheobronchial lymph nodes which directly drain from the lung show massive accumulation of dust particles (Figure 4). Some dust cells enter the lymphatics and blood vessels at the trabecular, hilar, and pericapsular regions. The dust cells migrate directly to adjacent adipose tissue from the mediastinal lymph nodes.[62] Peribronchial lymphoid tissue is markedly hyperplastic and protrudes into the lumen causing dust cells to be directly exposed to the luminal surface of the airways. Microscopic observation suggests that dust cells found in the peribronchial lymphoid tissue can directly enter the mucociliary escalator. Morphological observations of direct entry of dust cells into the peribronchial lymphatic vessels (Figures 5-7) have been made.[62] Some investigators[37,63,64] believe that dust particles are transported to lymph nodes via lymphatics as naked particles, not by dust cells. However, recent studies on ultrastructure of dust cells in the lymph nodes indicate that dust particles are transported by dust cells since the ultrastructural characteristics of these cells are similar to those of alveolar macrophages and are different from those of lymph nodes.[65] Animal experiments demonstrate that cytotoxic particles such as quartz are transported to lymph nodes in greater amounts than are "nuisance" dust particles.[32,39,63,66,66] These ultrastructural studies indicate that the alveolar epithelium, rather than the endothelium, acts as the chief barrier to diffusion of macromolecules. This is largely due to the unique structure of the alveolar lining cells which are held by continuous tight junction. In contast, endothelial cells are joined discontinuously. When quartz-containing macrophages are killed (cytotoxic effects), they release intracellular particles into the alveolar air spaces and extensive damage to the alveolar epithelial cells occurs. The dust cells can penetrate the underlying connective tissue compartment through discontinuous epithelial lining cells.

DOW 07410

EST0005910



FIGURE 4. Fiberglass-laden macrophage in the hilar lymph node. Note numerous dust particles within phagosomes (P) containing granular and membranous materials. Note long curved cytoplasmic process of macrophage (thin arrows). (Magnification × 12,000.)

Morphological observations reveal direct entry of dust cells into either the alveolar walls,[67] blood vessels (Figure 8)[62,68] or bronchial wall.[69] It is assumed that dust cells are able to reach the bronchioles by passing through either alveolar or bronchiolar walls.[69,70] Some dust cells in the lung can migrate to the pericardium or parietal pleura through adhesioned fibrotic pulmonary pleura. Transmigrated dust cells are seen more often in the liver or spleen than in other organs of rats exposed to either TiO_2 or fibrous manmade inorganic fibers (Figure 9).[62] Coal dust deposition has been seen in 10.4% of liver and 19.5% of spleen sections from coal workers but this deposition has not been associated with any pathologic tissue response.[71] Asbestos bodies or fibers in humans have been found in the gastric wall,[72,77] gastric carcinoma,[74] abdominal tumors,[75,76] parietal pleura,[72,77] pleural mesothelioma,[72,78] spleen,[72,73] and liver.[72] The transmigration of materials such as coal dust, asbestos bodies, or fibers does indicate that particles are capable of entering systemic blood or lymphatic circulation and can reach various organs and tissues.

IV. LUNG RESPONSE TO NUISANCE DUST

A. Criteria for Biologically "Nuisance Dust"

In a strict sense, there are no biologically "inert" dusts; that is dusts which do not provoke any pulmonary response when inhaled in some finite amount. In practice, the pulmonary response to "nuisance" dust is characterized by little adverse effects over long periods of time when exposure concentrations are not excessive. The biological criteria for "nuisance" dust are (1) reversibility of pulmonary lesions, (2) insignificant amount of collagen fiber formation, and (3) perservation of intact general architecture of alveoli. Some "nuisance"

DOW 07411

FST0095911



FIGURE 5. Titanate fibers are deposited in the peribronchial lymphoid tissue, and a lymphatic vessel contains several dust cells (arrows). (H. E. stain; magnification × 100.) (From Lee, K. P., Barras, C. E., Griffith, F. D., and Waritz, R. S., *Am. J. Pathol.*, 102, 314, 1981. With permission.)



FIGURE 6. A higher magnification of the titanate fibers (arrows) indicated by twisted arrows in Figure 5. The inset shows birefringent dust fibers in a macrophage. (H. E. stain; magnification × 500.) (From Lee, K. P., Barras, C. E., Griffith, F. D., and Waritz, R. S., *Am. J. Pathol.*, 102, 314, 1981. With permission.)

DOW 07412

ST0005912

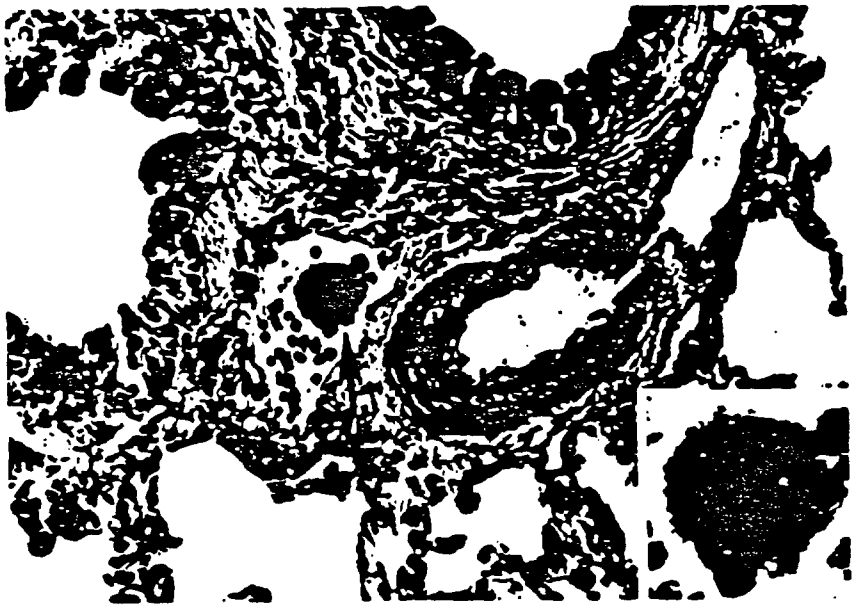

FIGURE 7 Note a dust-laden giant cell (arrow) in the peribronchial lymphatic vessel. (Trichrome stain; magnification × 250.) The inset shows a higher magnification of the dust-laden giant cell. (Magnification × 500.) (From Lee, K. P., Barras, C. E., Griffith, F. D., and Waritz, R. S., *Am. J. Pathol.*, 102, 314, 1981. With permission.)

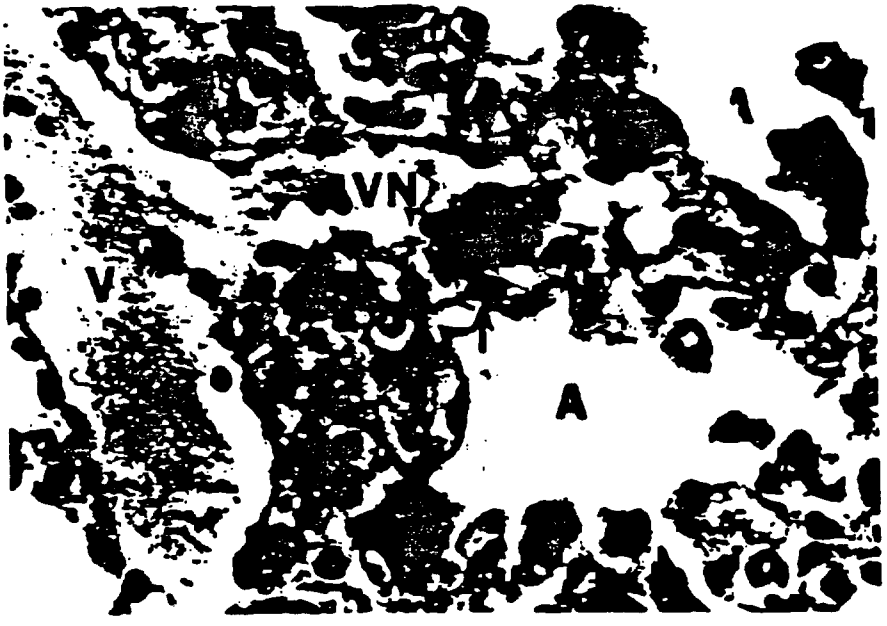

FIGURE 8 A pulmonary venule (VN) branched off the pulmonary vein (V) shows a dust-laden giant cell and endothelial cells (arrows). The alveoli (A) show numerous dust cells and hyperplastic alveolar lining cells. (H. E. stain; magnification × 500.) (From Lee, K. P., Barras, C. E., Griffith, F. D., and Waritz, R. S., *Am. J. Pathol.*, 102, 314, 1981. With permission.)

DOW 07413

ST0005913



FIGURE 9 The dust-laden giant cells (G) in the hepatic sinusoids are surrounded by compressed hepatic cells and minimal inflammation. (H. E. stain; magnification × 150.) (From Lee, K. P., Barras, C. E., Griffith, F. D., and Waritz, R. S., *Am. J. Pathol.*, 102, 314, 1981. With permission.)

dust particles listed in documentation of threshold limit values (TLV®) are TiO_2, calcium carbonate, calcium silicate, graphite (synthetic), gypsum, Kaolin, silicon, limestone, silicon carbide, starch, and mineral wool fiber.[76] With "nuisance" dusts, dust-laden macrophages do accumulate in bronchiolar region, adjoining alveoli, and perivascular tissue. Little collagen fiber is deposited following exposure to nuisance dusts such as iron and iron oxide, tin, barium, antimony, zirconium, rare-earth elements, chromite, vanadium, limestone, and cement.[80]

The TLV® refers to airborne concentrations of substances and represent conditions under which it is believed that nearly all workers may be repeatedly exposed day after day without adverse effects. The TLV® is derived from the best available information from industrial experience, human and experimental animal studies. The TLV® values of all substances are reviewed and published annually by the Committee on Threshold Standards of the American Conference of Governmental Industrial Hygienists. It should be understood that TLV® does not indicate a definite dust concentration which is safe, and above which is not. The TLV® assumes that if hazardous materials can be prevented from exceeding a certain empirically determined level at any time, below this level it is unlikely that disease will result during the working lifetime. TLV®s are expressed as particles per cm^3 or as millions of particles per cubic foot (mppcf). The TLV® of "nuisance" dust is 10 mg/m^3 or 30 mppcf.

B. Lung Response to Glass Fibers

Animals exposed to glass fibers by inhalation show only the nuisance dust response[54,81-86] with fine particles (<2.0 μm)[54] or thick fibrous particles (1 to 3 μm in diameter, 10 μm in length).[81] Pulmonary fibrosis, lung cancers, or pleural fibrosis are induced in the same species following either intratracheal instillation or intrapleural implantation with fine

DOW 07414

ST0005914

fibrous fibers (<1.5 μm in diameter, > 8 μm in length).[87-90] The latter results cannot be directly extrapolated to man because of the high exposure concentrations and unnatural exposure route. However, these animal experiments do raise a question about the potential health hazard of fine glass fibers. In a post-mortem study of the lungs of 20 workers exposed to glass fibers for 16 to 32 years (compared to the lungs of 26 urban dwellers), no significant detrimental effects were found.[91] The fiber size distribution was less that 3 μm in diameter and 5 to 25 μm in length. Several epidemiological studies on glass fiber workers have been conducted, all of which indicate to date that exposure to glass fibers is not a health hazard and does not produce carcinogenic effects.[91-95]

Intratracheal instillation or intrapleural implantation studies demonstrate that the fibrogenicity or carcinogenicity of glass fibers is related to the fiber dimensions. Fibers less than, or equal to, 1.5 μm in diameter and greater than 8 μm in length have fibrogenic or carcinogenic potential.[87-90] Most fibers in commercial use have a nominal diameter of 6 μm or greater but do contain some fibers with diameter equal to or less than 1.5 μm. Fine diameter glass fibers with a nominal diameter less than 1 μm have been manufactured for certain highly specialized applications such as aerospace insulation and sophisticated filtration. Since the ultrafine glass fibers have only been commercially produced in the last 10 years, results from the preceding negative epidemiologic studies cannot be applied. An ongoing inhalation study in hamsters has yielded to this point no evidence of carcinogenicity or fibrogenicity.[96] However, baboons exposed by inhalation to a fine fiberglass dust (0.5 to 1.0 μm in diameter, 3.1 to 6.3 μm in length) similar to those of crocidolite asbestos, develop focal peribronchial fibrosis with scant ferruginous body formation.[97]

C. Lung Response to Fine Fiberglass Particulates

In rats, guinea pigs, and hamsters, fine airborne fiberglass particles (most less than < 2 μm), are generally phagocytized by intraalveolar free macrophages (Figure 10). It is difficult to identify the tiny dust particles in the macrophages because they have a refractive index similar to the microscopic slide glass and are neither strongly refractive nor polarized.[54] Dust cells accumulate mainly in respiratory bronchioles, alveolar ducts, and adjoining alveoli. The alveolar wall enclosing dust cells shows marked hyperplasia of cuboidal lining cells (Figure 10). The dust cells reveal various stages of disintegration releasing dust particles and granular cellular debris. The granular material is faintly eosinophilic, weak PAS positive, and light green with trichrome stain in the early stage of alveolar proteinosis. After 90 days exposure, this condenses to form compact granular material which is relatively cell free, strongly PAS positive, and diastase resistant (Figures 11, 12). The pulmonary response seen is compatible with alveolar proteinosis.[54] The granular material is markedly decreased by 6 months postexposure and disappears by 1 year. Dust cells are decreased in number, densely aggregated, and are sharply defined by cuboidal alveolar lining cells from 6 months to 2 years postexposure. The remaining alveoli retain normal appearance. Neither significant collagenization nor stromal alteration is observed in the dust laden areas (Figure 11).[83-85] Occasionally, minute collagenized fibrosis and fine reticulin fiber networks are formed in the alveolar septal walls where the large aggregates of dust cells are present 2 years postexposure.[54] The hilar and mediastinal lymph nodes reveal an accumulation of dust-laden macrophages without any significant fibrosis or tissue response. Aggregated dust cells are generally localized in the medullary sinusoids with some in the subcortical sinusoids of the lymph nodules after 90-day exposure. Thereafter, dust cell accumulation increases gradually. The medullary and subcortical sinusoids become almost completely replaced by dust cells, leaving only a thin rim of cortical lymphoid tissue 2 years postexposure. Ferruginous bodies develop from fibrous dust particles but not from tiny dust particles. These are first seen 6 months postexposure in hamsters and guinea pigs but are not seen in rats.

DOW 07415

EST0005915



FIGURE 10. Dust-laden macrophages are sharply confined and surrounded by cuboidal alveolar linging cells (C). Alveolar duct (Ad). (H. E. stain; magnification × 400.) (From Lee, K. P., Barras, C. E., Griffith, F. D., and Wantz, R. S., *Lab. Invest.*, 40, 2, 123, 1981. With permission.)

Under electron microscopy, most dust particles appear to be phagocytized by intraalveolar free macrophages or neutrophils. Some particles are free in the alveolar air spaces and associated with cellular debris, myelin figures, and lamellar structures. Some particles are retained in the Type I pneumocytes, and show very little effect on their structure (Figure 3). A few particles reach the interstitium of the alveolar septum. The dust particles in the macrophages are either lodged in the cytoplasm or within the phagosomes (Figure 13). The particles retain their original morphologic characteristics in respect to configuration, size, and electron density.

In areas of heavy dust accumulation the alveoli containing dust particles are lined mainly with Type II pneumocytes. These reveal various stages of regenerative changes. Generally, they are flattened, possess short microvilli, and contain few myelin figures (Figure 14). The granular material seen under light microscopy is composed of numerous myelin figures (Figure 15), lamellar structures (Figure 16), dust particles, cellular debris, degenerating macrophages (Figure 13) and polymorphonuclear leukocytes. The myelin figures consist of concentric wavy membranes interspaced irregularly; their configurations are identical with those of the Type II pneumocytes. The lamellar structures are arranged in either parallel, or irregular arrangements (Figure 16). The lamellae consist of three layers in which an electron-dense layer is sandwiched between electron-opaque layers. Normal architecture of the alveoli is restored following removal of dust cells from the alveolar air spaces. However, alveoli containing dust cells are still lined mainly by the Type II pneumocytes at 2 years postexposure.[54]

DOW 07416

ST0005916

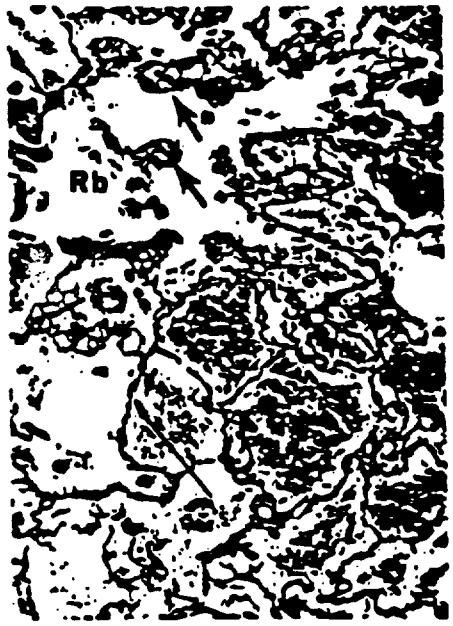

FIGURE 11. Note lack of collagen fiber deposition in the alveolar walls surrounding fiberglass particulates and granular proteinous material in the air spaces. The alveolar walls consist of fine reticulin fiber networks (thin arrows). The respiratory bronchiolar lumen (Rb) contains dust-laden macrophages (arrows). (Silver impregnation; magnification × 400.) (From Lee, K. P., Barras, C. E., Griffith, and Waritz, R. S., *Lab. Invest.*, 40, 123, 1979. With permission.)

D. Reparative Response of Type II Pneumocytes

The pulmonary reaction to nuisance dust particles is characterized by dust cell accumulation in the alveoli with proliferation of Type II pneumocytes as a reparative response to damaged Type I pneumocytes (Figures 10 and 12). However, there is no significant collagenized fibrosis in the dust-deposited areas (Figure 11). Proliferation of Type II pneumocytes is known as a nonspecific reparative tissue reaction to damaged Type I pneumocytes following exposure to many forms of toxic lung injuries. Damaged Type I pneumocytes are followed almost immediately by a proliferation of Type II pneumocytes, which replace the necrotic Type I pneumocytes. After replacement, the Type II pneumocytes gradually transform into Type I pneumocytes through intermediate stages. The pneumocytes in the intermediate stage show either none or markedly decreased lamellar inclusions and short microvilli.[54] In oxygen-induced lung damage, the epithelial injury is confined to Type I pneumocytes and repaired by Type II pneumocytes within 3 days.[96-99] Similar reparative findings are found within 2 to 3 days after exposure to NO_2,[100,101] $FeCl_3$,[102] $CdCl_2$,[103,104] ozone,[105,106] and oxygen.[107]

E. Alveolar Macrophage Response to Dust Particles

After exposure to nuisance dust, the lungs show a most striking finding: that of dense aggregates of foamy alveolar macrophages (Figure 10) and dust cells in the alveoli without any alteration of stromal lung structure (Figure 11). The alveolar macrophages are the resident

DOW 07417



FIGURE 12. The alveolar air spaces are filled with PAS-positive granular material. Fiberglass (0.7 × 10⁶/l., 90-days exposure. (PAS method; magnification × 300.) (From Lee, K. P., Barras, C. E., Griffith, F. D., Wartz, R. S., and Lapin, C. A., *Environ. Res.*, 24, 167, 1981. With permission.)

mononuclear phagocytes of the lung and function as the primary defense against inhaled particulates. It has been shown that macrophage output increases proportional to dose following exposure to dust particles.[108] Dust clearance from the alveoli is a function of the macrophages. Very rapid increases in macrophages are found as early as 4 hr after intratracheal instillation of particles suggesting the release of preexisting cells such as monocytes or interstitial macrophages.[109] After intratracheal instillation of carbon particles, a tenfold increase in macrophages is seen within 24 hr; a level which is maintained for several days.[109] It may be in the interstitum that the alveolar macrophages develop the functional and metabolic features that distinguish it from the blood monocytes.[110,111]

There are two complimentary mechanisms which enable the lung to handle a large particulate load. The early response produces new alveolar macrophages, probably by migration of blood monocytes through the interstitium to the alveoli, with perhaps some migration of preexisting interstitial macrophages.[108] The second phase involves increased mitotic activity in the interstitial compartment of the lung where preexisting, or newly arrived, mononuclear cells divide and cross the epithelial barrier into the alveoli. Factors such as total load, size, and chemical composition of the particles are known to influence the output of macrophages.[108] The origin of alveolar macrophages has been the subject of a continuing debate. There are several possible sources of the extra cells that appear in response to a load demand. They may arise by (1) division of free alveolar macrophages, (2) migration of blood monocytes, (3) release of interstitial macrophages, or (4) proliferation of interstitial macrophagic precursors with subsequent migration of daughter cells.

DOW 07418

FST0005918



FIGURE 13 Degenerating dust-laden macrophage in the alveolar air space (A). Some dust particles are confined in the phagosomes. Note extrusion of lysosomal granular material into extracellular space and disintegrating cytoplasm. Note edematous membranous pneumocytes (P) showing reduced cytoplasmic matrix density (Magnification × 12,000.) (From Lee, K. P., Barras, C. E., Griffith, F. D., and Waritz, R. S., *Lab Invest.* 40, 123, 1979. With permission.)

F. Particulate-Induced Alveolar Proteinosis

Pulmonary alveolar proteinosis is an uncommon human disease characterized by the intraalveolar accumulation of an acellular, fine granular material which stains well with eosin and the periodic acid-Schiff reaction[112] without diastase digestion (Figure 13). The material present within the alveoli, characterized as a phospholipid, may lead to an alveolocapillary block. The main component is dipalmitoyl lecithin (the major component of surfactant) associated with cholesterol, denatured proteins, and gamma globulins.[113-116] Although chemically similar to surfactant, it lacks surface-tension lowering activity.[116] An increased number of Type II pneumocytes lining the alveolar walls are seen in association with degenerating pneumocytes and pulmonary macrophages. Myeloid bodies, which are present in the amorphous material seen by electron microscopy, are considered to be phospholipid in nature.[117-119]

Many hypotheses have been proposed to explain alveolar proteinosis, but no convincing etiology for the condition exists. Based on a review of case studies, the pathogenesis can be postulated as follows: (1) over production of normal or abnormal phospholipids by Type II pneumocytes.[119-122] (2) desquamation of Type II pneumocytes.[112] (3) primary failure of lung clearance.[123-125] and (4) possible passage of blood proteins into alveolar debris due to damage of the alveolar basement membrane.[126,127] The disease is neither species- nor agent-specific. The alveolar proteinosis is associated with various forms of materials such as dust particles.[122,128,129,131] drugs.[132,133,134] and infectious agents.[135-138]

DOW 07419

EST0005919



FIGURE 14 Alveolar walls lined with regenerated granular pneumocytes showing scanty myelin figures (M) and short microvilli (arrows). The air space (A) contains membranous and granular materials. (Magnification × 12,000.) (From Lee, K. P., Barras, C. E., Griffith, F. D., and Waritz, R. S., *Lab. Invest.*, 40, 123, 1979. With permission.)

In dust particle-induced alveolar proteinosis, the disease process appears to be initiated when inhaled particles in the alveoli activate the output of alveolar macrophages which elicits a marked proliferation of Type II pneumocytes (Figures 10 and 13). The resulting over-production of surfactant, as a result of the reparative tissue response to damaged Type I pneumocytes, leads to excess phospholipid which overwhelms the macrophages already overloaded with dust particles. Lysosomes of the macrophages are compromised and the excess surfactant accumulates. Apparently, these foamy macrophages are incapable of effective alveolar clearance and release the cytoplasmic content upon disintegration. This leads to the release of hydrolytic enzymes into the alveoli which transform the surfactant into amorphous granular material.

Although the pathogenesis is still disputed, both the alveolar macrophages and Type II pneumocytes play essential roles.[112,113,136,140] In man, the alveoli adjacent to the alveolar proteinosis often contain many foamy macrophages. The pathogenesis of human alveolar proteinosis is probably similar to that in the experimental animal model.[117,141] In animals, alveolar proteinosis has been produced by exposure to a variety of silica,[122] quartz,[130,131] fiberglass,[54] cristobalite, and pyro-aluminum powder.[129] According to case reviews, persons showing this lesion worked in dusty settings[140] and occasionally had heavy exposure to silica dust.[142,143] Almost half of the patients are exposed to dust particles including silica, asbestos, aluminum, broken fluorescent tubes, chlorinated resin, tin, and molybdenum[140] along with various solvents. The size analyses of particles from the lung tissue of 25 cases of alveolar proteinosis indicate that 53% of the particles are less than 1 μm in diameter, 47% are 1 to 10 μm, and 0.4% are greater than 10 μm. The concentration of alveolar particles is twice the mean of control cases.[144]

DOW 07420

ST0005920



FIGURE 15. Cytoplasm of a foamy alveolar macrophage is packed densely with numerous myelin figures (M). Alveolar air space (A) is filled with cholesterol clefts (C). Membranous debris, and similar myelin figures (M) seen in a macrophage. Alveolar wall (AW), alveolar capillary lumen (CL). (Magnification × 8,170.)

V. LUNG RESPONSE TO PARTICULATES BY INTRATRACHEAL INSTILLATION

Intratracheal instillation techniques have been used extensively in research laboratories to measure the lung response to dust particles since the technique is simple, inexpensive, easy to quantitate, and presents minimal hazard to laboratory personnel. However, disadvantages of this technique are (1) introduction of unrespirable large-sized particles by an unnatural route, (2) overloading the lung clearance mechanism with large doses in a short time, (3) uneven particle distribution pattern with preferential deposition in the dependent portion of the lung, and (4) avoiding upper respiratory defense mechanism(s).

Since most laboratory animals are obligatory nosebreathers, considerable amounts of inhaled particles are removed in the nose or upper respiratory passages. Animals receiving intratracheal instillation show different patterns of particle deposition than do animals following inhalation of an aerosol. In the former situation, the apical portion of lung receives less and the more dependent portion receives more particles. In the latter situation, there is a more uniform distribution with preferential deposition in the apical lobe.[165]

Intratracheal instillation of fibrous particles such as asbestos or manmade inorganic fibers to rats results in retention of long fibers, mostly in the terminal bronchioles. Short fibers can reach the respiratory bronchioles, alveolar ducts, and alveoli. At 2 days postinstillation (PI), acute obliterative bronchiolitis develops and the epithelium of terminal bronchioles is extensively denuded and accompanied by acute inflammatory exudate (Figure 17). Adjacent alveoli contain particles showing marked hyperplasia of cuboidal alveolar lining cells (Type

DOW 07421

ST0005921



FIGURE 16. Air space is filled with lamellar structures showing parallel (P), quadric (Q), configuration, and free dust particles (arrows). (Magnification × 25,200.) (From Lee, C. E., Barras, Griffith, F. D., and Wantz, R. S., *Lab. Invest.*, 40, 123, 1979. With permission.)

II pneumonocytes). By 7 days PI, the acute inflammatory exudate subsides and is replaced by chronic inflammatory cells and dust-laden giant cells in the dust deposition areas. The terminal bronchioles develop a polypoid granulomatous mass following organization of the acute inflammatory exudate. The polypoid granulomas attach to the bronchiolar wall and are partially covered by regenerating epithelium from adjacent intact epithelium. Some are subdivided by slit-like spaces lined with regenerated bronchiolar epithelium (Figure 18). The polypoid granulomas reveal dust-laden macrophages, giant cells, chronic inflammatory cells, and dense reticulum fiber networks with scanty collagen fiber deposition. The respiratory bronchiolar regions show granulomatous lesions and thickened alveolar walls with proliferating fibroblasts, alveolar lining cells, dust cells, and chronic inflammatory cells.

After 14 days PI, the polypoid granulomas are completely covered with regenerated respiratory epithelium and show numerous dust-laden giant cells, proliferating fibroblasts, and extensive reticulum fiber networks with minimal collagen fiber deposition. After 28 and 56 days PI, the polypoid granulomas in the terminal bronchioles are reduced markedly in size, their cellularity leaving wide spaces of air passage, and showing significant amount of collagen fiber deposition. The granulomatous lesions in the respiratory bronchiolar region are sharply marked from adjacent alveoli and reveal slight collagen fiber deposition in the respiratory bronchiolar walls and adjoining alveolar walls (Figure 19). By 3 months PI, the polypoid granulomas in the terminal bronchioles are reduced markedly in size as well as cellularity, while collagen fiber deposition becomes more obvious with expansion of amorphous eosinophilic stroma. The granulomatous lesions in the respiratory bronchioles and alveoli convert to fibrotic lesions with increasing collagen fiber deposition. At 1 and 2 years

DOW 07422

ST0005922



FIGURE 17 The respiratory bronchiole (Rb) is obliterated with accumulation of fibrous particles (arrow) and acute inflammatory exudate. Adjacent alveolus (A) is occluded with inflammatory cells and hyperplastic alveolar lining cells. Terminal bronchiole (Tb), potassium titanate fiber (0.25 ml of a 1% suspension), 2nd days postinstillation (PI). (H. E. stain; magnification × 100.)

PI, the polypoid granulomas in the terminal bronchioles decrease gradually in size and cellularity along with the increase in collagen fiber deposition (Figure 20). At the end of 2 years PI, the polypoid granulomas are extensively collagenized with amorphous eosinophilic stroma, but dust-laden giant cells are still present. Similarly, the granulomatous lesions in the respiratory bronchioles show marked decrease in cellularity and are converted to collagenized fibrosis.

The polypoid granulomas in the terminal bronchioles are not developed by inhalation exposure, even though the animals were exposed to very high concentrations. This is an artifactual tissue response to unrespirable large particles or to aggregated particles. In the intratracheal instillation studies with three different sizes of manmade inorganic fibers, the longer fibers were retained mainly in the terminal bronchioles and induced larger polypoid granulomas. The size of polypoid granuloma is proportional to the fiber length of instilled fibers. Polypoid granulomas in the terminal bronchioles were induced in rats by intratracheal instillation with fiberglass, but they disappeared at the end of 2 years PI.[81,84] However, the fibrogenic pulmonary response is not observed in rats exposed to fiberglass.[81] Thus, false-positive results, pulmonary fibrosis induced by intratracheal instillation, have been attained.[146] When metallic aluminum powder is injected intratracheally into the lungs of rats, large collagenous scars develop.[147,148] However, the same material when inhaled does not produce pulmonary fibrosis.[148]

It is difficult to assess the fibrogenic potential of particles using intratracheal instillation and to convert this directly to potential fibrogenic activity following inhalation. For the proper assessment of fibrogenic potential, it is recommended that one group of animals be

DOW 07423



FIGURE 18 The lumen of terminal bronchiole is subdivided into two compartments (L) by fibrous tissue loaded with dust particles (arrow) and regenerated terminal bronchiolar epithelium. Alveolus (A). potassium titanate fiber (0.25 ml of a 1% suspension). 7 days PI (H. E. stain; magnification × 100.)

treated by intratracheal instillation using both a negative control and a positive control with particles having similar physical shape and size distribution to the particle in question. Long fibrous particles such as asbestos, fiberglass, or manmade inorganic fibers have remarkable fibrogenic activity in rats and induce large collagenized polypoid granulomas in the terminal bronchioles and collagenized fibrosis in the respiratory bronchioles and adjacent alveoli following intratracheal instillation. Typical silicotic nodules develop in rats following intratracheal instillation of from either 10 or 50 mg quartz, but only dust cell reactions with no fibrogenic response are seen in rats given 2.5 mg. When a material is instilled intratracheally without negative or positive control groups, the pulmonary response can be mistakenly interpreted as negative or positive depending on a number of variables including the size of the dose instilled. Intratracheal instillation can be used as a screening technique to detect fibrogenic potential of particles. When collagenous fibrosis is developed in the dust-deposited areas after intratracheal instillation, it is desirable to initiate a short-term inhalation experiment (2 to 4 weeks) with appropriate exposure concentrations and a longer recovery period (3 to 6 months) to confirm fibrogenicity of test material. The use of intratracheal instillation as a screening tool to detect the fibrogenic potential of particles needs careful interpretation.

VI. PLEURAL AND PULMONARY RESPONSE TO ASBESTOS

A. Morphology of Asbestos and Manmade Fibers

Asbestos is a generic term referring to naturally occurring hydrated mineral silicates of serpentine and amphibole groups which, although having different physical and chemical properties, share fibrous shape. Chrysotile, crocidolite, and amosite are economically im-

DOW 07424

ST0005924



FIGURE 19. The respiratory bronchiole (Rb) is obliterated with granuloma showing dust-laden, foreign body giant cells (G) and adjacent alveolar wall (A) is thickened. Terminal bronchiole (Tb), potassium titanate fiber (0.25 ml of a 1% suspension), 28 days PI. (H. E. stain, magnification × 100.)

portant asbestos whereas anthophyllite, actinolite, and tremolite have little economic value because of their limited availability and low tensile strength. Large quantities of asbestos have been used in the manufacture of asbestos-cement products (tile, roofing, pipes, sheet) and the chrysotile form is widely used in floor tile and paper products. Asbestos is also widely used for manufacturing textiles and friction materials (brake lining and clutch facing). Crocidolite is used for filter products and anthophyllite as a filling material in rubber and plastics. Over 90% of the asbestos consumed in the U.S. is the fibrous variety of serpentine, also known as chrysotile.

The crystal structures of the two main asbestos-forming minerals, the amphiboles and serpentines, are very different. The amphiboles are "chain silicates" in which SiO_4-tetrahedra are linked to form very long bands four tetrahedra wide. These bands run parallel to the fiber axis and are linked by cations (mainly Ca and Mg in tremolite, Na, Mg, and Fe in crocidolite and Mg and Fe in amosite and anthophyllite). The serpentine minerals are "layered silicates" in which SiO_4-tetrahedra are linked to form very wide thin sheets. The tetrahedra all point in the same direction and their apical oxygens are part of an (O, OH)–Mg–(OH) sheet which is itself formed by Mg–(O,OH) octahedra. The fundamental serpentine layer is polar and has both tetrahedral and octahedral components. The mismatch in dimensions of these two components generally leads to curvature of the layers and, in chrysotile asbestos, the layers form either scrolls or concentric cylinders with very high length/width ratio and length parallel to the fiber axis.[146]

Chrysotile fibers are characterized by white, soft, flexible, and curly configurations (Figure 21). Crocidolite and amosite fibers (Figure 22) are blue and brown, respectively, and are shorter, stiffer, and straighter than those of chrysotile. Amosite is more brittle and has less

DOW 07425

STOOO5925



FIGURE 20. The lumen of terminal bronchiole is occluded with dust-laden, collagenized polypoid fibrotic mass. The luminal space (L) is a slit-like appearance and bounded with regenerated terminal bronchiolar epithelium. Potassium titanate fiber (0.25 mℓ of a 1% suspension), 1 year PI. (H. E. stain; magnification × 100.)

tensile strength. Tremolite is fibrous but brittle and breaks down into small fragments. Serpentine and amphibole consist of polyfilamentous structures with multiple subunit layers. When asbestos fractures, fibers split longitudinally and they release fibril subunits (Figures 21 and 22).

The manmade vitreous fibers (glass, mineral wool, aluminum silicate), have no regularity in their structure (Figure 23). Therefore, fracture will occur in a random manner and fibers tend to fracture transversely into shorter fragments with the same diameter (Figure 23). The synthetic polycrystalline fibers (aluminum oxide, silicon carbide, sodium aluminum carbonate, potassium titanate, graphite) have been used as reinforcing fibers for high performance plastics (Figure 24). Since the fibers lack cleavage planes and because of their isotropic nature, they fracture in the same gross manner as manmade vitreous fibers. The natural mineral fibers (wollastonite, attapulgite, sepiolite, amphiboles, zeolite) offer an almost infinite variety of structural possibilities. The basic feature of these fibers is a series of covalently bonded silicon-oxygen chains which have charge-balancing cations placed in alternate layers. The properties of the crystal are very much dependent upon the nature of the cations. This in turn has a great influence on the manner in which the crystal fractures when subjected to grinding or other mechanical action. The cleavage pattern of these fibers will present bladed or needle-shaped fragments.[130] Certain aramid synthetic fibers consist of interwoven fibrils showing various sizes and shapes, and are mainly flattened in appearance. When these fibers are abraded, isolated airborne fibrils show irregularly branched or flattened shapes.

DOW 07426

ST0005926



FIGURE 21. Distal end of fractured chrysotile shows various sized, numerous fibrils (arrows) by longitudinal splitting. (Magnification × 10,000.)



FIGURE 22. Amosite fibers illustrate longitudinal splitting (arrows) and formation of thin fibers (wavy arrows). (Magnification × 3000.) (From Lee, K. P., Barras, C. E., Griffith, Wantz, R. S., and Lapin, C. A., *Environ Res.*, 24, 167, 1981. With permission.)

DOW 07427

ST0005927



FIGURE 23. Fiberglass fibers show large diameter and marked variation in both the diameter and length. (Magnification × 1000.) (From Lee, K. P., Barras, C. E., Griffith, F. D., Waritz, R. S., and Lapin, C. A., *Environ. Res.*, 24, 167, 1981. With permission.)



FIGURE 24. Potassium titanate fibers present needle shape with relatively uniform diameter. (Magnification × 1000.) (From Lee, K. P., Barras, C. E., Griffith, F. D., Waritz, R. S., and Lapin, C. A., *Environ. Res.*, 24, 167, 1981. With permission.)

DOW 07428

TST0005928



FIGURE 25. A longitudinal section of segmented asbestos body in the alveolar macrophage. Central core (thin arrow) of asbestos is surrounded with densely packed iron micelles (arrows). Cytoplasmic processes of macrophage (P). (Magnification × 21,000.)

B. Asbestos Bodies (Ferruginous Bodies) in Asbestos-Related Disease

Some inhaled asbestos fibers can be transformed to asbestos bodies within alveolar macrophages after the phagocytized fibers are incorporated into the phagosomes along with endogenous iron (ferritin) (Figure 26)[151,152] and acid mucopolysaccharides.[153] Strikingly, only a small proportion of phagocytized fibers are converted to asbestos bodies.[154-156] The ratio of asbestos bodies to uncoated fibers in the lung is approximately 1:10,000 in the general population[157] and 1:50 to 1:400 in individuals with moderate to heavy asbestos exposure.[156] Asbestos bodies are generally 20 to 150 μm long and 3 to 5 μm in diameter, golden yellow or brown in color, and "drumstick", "beaded-string", or "sausage"-like in appearance (Figure 25). Asbestos bodies are formed on fibers longer than 40 μm with very few forming on those less than 10 μm.[20,88,158,159] The iron-containing protein coat of asbestos bodies is positive for Prussian blue and stains blue with Perl's reagent. The core of the fiber is 0.1 to 1.0 μm diameter and is transparent, colorless, and usually straight. Asbestos bodies show various fragmentation stages including beaded fragments in the macrophages and extracellular granular fragments (Figure 26). The number of asbestos bodies and fragmentation increases with time following deposition in experimental animals.[88] Asbestos bodies are found in the membranous pneumocytes (Figure 27) and endothelial cells (Figure 28) of alveolar capillaries in addition to macrophages or giant cells in hamsters exposed to asbestos.

Asbestos bodies are a hallmark of asbestos exposure, but not of asbestosis (pulmonary fibrosis). They can be identified in the sputum and their presence indicates only past exposure, proving neither asbestosis nor asbestos-related disease. Conversely, the absence of asbestos bodies in sputum does not rule out the possibility of asbestosis.[160] The number of asbestos

DOW 07429



FIGURE 26 Asbestos bodies (arrows) in giant cells or macrophages show various sizes and shapes, drum stick, beaded string (bent arrow), multiple segments, and amorphous fragmented debris. A thin arrow indicates uncoated asbestos fiber. Perl's method. (Magnification × 400.)



FIGURE 27 Asbestos body formation (arrow) in the membranous pneumocytes (p). Central core of asbestos is obscured by densely packed iron micelles. Alveolar air space (A), granular pneumocytes (G). (Magnification × 21,000.)

DOW 07430

EST0005930



FIGURE 28. A transverse section of an asbestos body (arrow) in the alveolar capillary endothelium (E). Red blood cell (R), basement membrane (B), membranous pneumocyte (P), alveolar air space (A). (Magnification × 21,000.)

bodies present can be used as a crude indicator of exposure, but only large numbers indicate heavy expoure. When asbestos bodies are visible in tissue sections, exposure is certainly substantial; but even in this instance asbestosis is not necessarily indicated.[161] There is no relation between the number of asbestos bodies and the presence, or absence, of lung or gastrointestinal cancer.[162-164] Asbestos bodies are not found in mesothelioma, but short or fragmented bodies have been identified in parietal pleural plaques.[165]

It is well known that asbestos-like body formation of filamentous dust particles from various origins are found in man;[165,167,168] these are called pseudoasbestos bodies. Filamentous ceramic aluminum silicate fibers, sheet silicate, glass fibers, and inorganic manmade fibers can produce pseudoasbestos bodies in experimental animals.[169] Some ferruginous bodies can be differentiated from asbestos bodies by their opaque and irregular contour, but others are indistinguishable. Therefore, the generic term "ferruginous bodies" has been suggested for fibers surrounded with an iron-protein coat.[169] With this definition, asbestos bodies represent one form of ferruginous body. However, since most ferruginous bodies found in human lungs consist exclusively of an asbestos core, the specific term asbestos bodies is preferred, and the generic term ferruginous body should be reserved for those which do not contain an asbestos core.[161] Ferruginous bodies in coal or graphite pneumoconiosis have a black core and are usually shorter and thicker than asbestos bodies.[169] The core of ferruginous bodies induced by exposure to silicates such as talc and mica has a yellow core.[162] However, some ferruginous bodies in the lungs of talc workers are indistinguishable from the asbestos bodies, probably due to fibers of tremolite or possibly anthophyllite which may be present in talc.[169] Ultrastructural examination of individual fibers (using either scanning or transmission electron microscopy) is not a useful technique for the identification since most fibers have very few, if any, specific features. Energy-dispersive X-ray spectrometry and electron

DOW 07431

diffraction transmission microscopy permit the chemical and crystallographic analysis of a fiber in tissue. However, these methods are of limited diagnostic application since it is time consuming and requires specialized equipment and highly trained personnel.

Asbestos or ferruginous bodies can be found in the lung fluid of 20 to 48% of adults living in urban areas without known exposure to asbestos.[165,169,170] Upon careful examination, almost all urban residents are found to have a few of these bodies.[171] Sections of lung tissue have revealed these bodies in 53 to 60%[172] and 40.9 to 91%[173] of the urban population. Numbers of asbestos bodies have been found to correlate in a general way with occupation.[158] An important question here is do these asbestos bodies have asbestos fiber cores? Some investigators[171] suggest that most asbestos bodies found in the general population are really ferruginous bodies with cores of some nonasbestos minerals. Others claim that most of those found in the general population are asbestos when examined by electron microprobe.[161] Asbestos bodies contain mainly commercial amphibole fibers (amosite and crocidolite) in males, while about half of the bodies found in female lungs are anthophyllite and tremolite. The asbestos bodies in females are suspected to be the result of exposure to cosmetic talc containing anthophyllite and tremolite since most asbestos (90%) in industrial use is serpentine (chrysotile).

C. Pleural Plaques

Hyaline plaques of the parietal pleura are often associated with asbestosis. These appear as a yellow-white patchy or nodular thickening with a smooth or nodular surface. They are usually multiple, are located almost exclusively on the parietal pleura, and tend to be present along the lower riblines. They exist as various shapes and sizes from small nodules to covering large areas of the pleura. Pleural plaques rarely adhere to either pulmonary pleura or parietal pericardium. The majority are bilateral and symmetrically arranged.[174] Plaques are also often found on the diaphragm where they are characteristically confined to the central tendons.

Microscopically, the plaques consist of almost entirely avascular, acellular collagen fibers arranged parallel to the surface with hyaline changes and give a characteristic "basket-weave" appearance. Dystrophic calcification (87%) is present in the central area where collagen has degenerated.[174] In a developing plaque, growth appears from the deepest aspect where vascularity remains, and sometimes, fibroblast-like cells, infiltrates of lymphocytes and plasma cells are found. The findings indicate that plaques are developed from an extrapleural rather than a pleural site.[175]

Little is known about pathogenesis of the pleural plaques. Why are the lesions virtually confined to the parietal pleura and why does asbestosis so often occur independently? Pleural plaques are thought to develop from the inflammatory response to mechanical irritation by fibers projecting through the visceral pleura of the lung.[175,176] Contrary to this theory, pleural plaques show an absence of surface inflammatory reaction and no adhesions. Another hypothesis is the intracellular transmigration of asbestos particles to the parietal pleural via the lymphatics.[177,178] The sites of plaque formation coincide with the pathways of lymphatic drainage and the selected sites are possibly zones of relative stasis.[179]

Asbestos bodies, their fragments, and uncoated amphibole or short fibers are demonstrated within plaques.[175,178] and chrysotile shows a tendency to concentrate in calcified areas.[180] The mean length of fibers detected in the lungs and pulmonary pleura is greater than those in the parietal pleura.[181] Pleural plaques show a very modest increase (10- to 50-fold) in the numbers of commercial amphiboles present although the total number of fibers in the lungs is not different from that in the control.[181,182] Generally, short asbestos or manmade fibers (<5 μm) are not fibrogenic in the lungs,[87,183] why are they fibrogenic in the parietal pleura? Are genetic or immunological factors involved in the pathogenesis of pleural plaque or in the parietal pleura more sensitive to short fibers? In an attempt to clarify possible involvement

DOW 07432

SLT 005932

of immunological mechanism, some markers of the immune reaction have been investigated. There are increases in the incidence of antinuclear factor and rheumatoid factor in patients with asbestos exposure,[183,184] and levels of serum gamma globulins are higher in asbestos-exposed persons with plaques.[185] However, the information concerning this relationship is so meager that further studies are required. Pleural plaques are found in people in agricultural communities with no known exposure to asbestos[186,187] and also are found in cattle in the same region of Czechoslovakia.[188] In a tobacco growing region of Bulgaria where pleural plaques are endemic, farmers till soil containing anthophyllite, tremolite, and sepiolite.[189] In a Canadian (Quebec) chrysotile mining complex, calcified plaques are found to be very common in workers in some mines, and rare in others which are not very distant from each other.[190] These observations suggest the possibility that causative agents other than asbestos fibers are involved in the induction of pleural plaques.

The prevalence of plaques is not related to total dust exposure but, given a minimal initial exposure, the prevalence depends on age. A high incidence of pleural calcification has been observed in older members of farming families[191,192] and is rare in those under 30.[193] It is postulated that an interval of 20 years from the onset of occupational exposure is necessary to develop calcified plaques.[194] The evidence of diffuse intrapulmonary fibrosis is absent in more than half the cases of pleural plaques.[190] Pleural plaques do not indicate the existence of asbestosis any more than do asbestos bodies in the sputum. There is no evidence to implicate that the plaques are precursors of malignant mesothelioma. The plaques have no effect on life expectancy and are not the cause of any complications.[190]

D. Mesothelioma and Lung Cancer in Asbestosis

Malignant mesotheliomas of the pleura or peritoneum are exceptionally rare in persons not exposed to asbestos. In some occupationally exposed groups the incidence is approximately 10% of all deaths.[195] In a recent study of insulation workers[196] the prevalence of the mesothelioma was 8% and mortality from lung cancer was 21%. Mesotheliomas develop many years after the initial exposure: in most cases after 25 to 30 years. Cases with a latency of more than 40 years have been described.[197] The tumors occur in both sexes and generally the pleural origin is much more common than peritoneal,[198,199] although tumors in the latter site are more frequent in women.[200] The occurrence appears to be closely related to exposure to either crocidolite alone or to a mixture of fiber types including crocidolite. In some cases, exposure appears to have been solely nonoccupational due to residing in close proximity to either a dockyard or an asbestos processing plant,[201-203] or to household contact with asbestos brought home by factory workers on their clothes.[204]

The importance of different types of asbestos in the pathogenesis of mesothelioma in man has been explored in numerous epidemiologic studies. Anthophyllite fails to produce the tumor, although pleural plaques occur commonly in populations exposed to this material.[205] The very weak carcinogenic response to anthophyllite is believed to reflect the relatively broad diameter of the fiber. Mesotheliomas are strongly associated with crocidolite, which are different in physical characteristics from one mine to another and these varying forms differ in carcinogenic potential.[206] The importance of chrysotile in mesothelioma is not well known and remains a subject of controversy.

The mesothelioma is gray, yellow, or ivory-white and covers focal areas of the lungs with some tendency to spread into interlobular fissures and totally enclose the lung including the mediastinum. In advanced cases, the gross appearance of the lung is not diagnostic. In the early stages, it may be difficult to distinguish the tumor from pleural plaques. The peritoneal tumor shows a similar gross appearance and encasts most of the abdominal organs. Spread of both pleural and peritoneal tumors to local lymph nodes is fairly common. Tumor metastasis occurs in about half the cases of mesotheliomas in either site[207-210] and is not related to certain tumor types. The mesotheliomas reveal markedly diversified microscopic

DOW 07433

patterns: at one extreme the appearance closely resembles adenocarcinoma and at the other, fibrosarcoma. Epithelial and connective tissue elements are usually present. Malignant mesothelial cells can differentiate into the number of different cell lines.[54] Four distinct histological patterns are recognized:[210] (1) tubulo-papillary type (predominantly epithelial), (2) sarcomatous type (predominantly mesenchymal), (3) undifferentiated cell type (predominantly epithelial), and (4) mixed type. A characteristic feature of mesothelioma is the tendency to grow along needle tracts and through surgical incisions.[196] The most important step to establish diagnosis of malignant mesothelioma is to distinguish the tumors from primary bronchogenic adenocarcinoma and from metastatic carcinoma and sarcoma.

Morphologically, the diagnosis of mesotheliomas presents difficulty in differentiation from adenocarcinomas because of a wide diversity of tissue patterns in malignant mesotheliomas. Staining for mucin is often helpful since malignant mesotheliomas produce a mucinous substance, hyaluronic acid, located chiefly extracellularly which stains blue with Alcian® Blue and colloidal iron but not with periodic-acid-Schiff (PAS) or mucicarmine. The glycogen in the epithelial cells of mesotheliomas can be removed by pretreatment with diastase. By contrast, adenocarcinomas often produce an intracellular, diastase-resistant mucin which is usually PAS-positive but occasionally gives the Alcian® Blue reaction. In many cases the PAS test is negative in mesothelioma sections which are predigested by the enzyme diastase, whereas a strongly positive reaction within cell cytoplasm and mucin in the lumina of neoplastic glands is found in adenocarcinomas or pseudomesothelial carcinoma of the lung.[211] The histochemical methods have proven helpful, but in many cases they lack the sensitivity needed for definitive diagnosis.[207,212,213] The demonstration of hyaluronic acid by electrophoresis of tumor tissue[214] or quantitative analysis of hyaluronic acid by specific glycosaminoglycan-degrading enzymes[215] may be valuable. The distribution of keratin proteins and carcinoembryonic antigen (CEA) may be determined in the mesotheliomas and adenocarcinomas by an indirect immunoperoxidase method. Adenocarcinomas of the lung usually stain weakly or negatively for keratin proteins.[4]The profile of strong keratin stain and weak or absent CEA staining appears characteristic of mesotheliomas and may be useful in defining the epithelial element of these neoplasm and in distinguishing them from adenocarcinomas.[216] Utilization of electron microscopy is limited to differential diagnosis of malignant mesotheliomas because the ultrastructural features of mesotheliomas are similar to those of many carcinomas and sarcomas.

A causal relationship between lung cancer and asbestos exposure has been established by epidemiological surveys conducted in various countries. Asbestos-associated lung cancers have a longer latency (in excess of 20 years) but occur at an earlier age than lung cancers in nonexposed persons.[217] There is a dose-related increase in incidence of lung cancers among asbestos workers.[218-222] The frequency of lung cancer is increased in the smokers[223] with effects of smoking and asbestos being synergistic and multiplicative.[224] In insulation workers, smokers have a fivefold increase in the risk of lung cancer compared with a nonsmoking population.[225] The risk of lung cancer is 50-fold greater in asbestos workers who smoke in comparison to nonsmokers who are not exposed to asbestos.[223,226] Since the lung cancers occur in the area of the fibrosis, they usually locate in the lower lobes.[223,227,228] Various histological types of lung cancer are observed in the asbestos workers but the most common histological type appears to be adenocarcinoma.[223,227,229]

E. Asbestosis

Asbestosis (asbestos pneumoconiosis) is a bilateral diffuse interstitial pulmonary fibrosis caused by deposition of asbestos. The term does not refer to the lesions in the pleura. The disease has been most common among workers in milling, insulation, and shipyards. Asbestosis occurs in 0.5% of Rhodesia chrysotile industry workers surveyed from 1963 to 1967,[230] 1.4% in British naval dockyard workers from 1960 to 1971,[231] and 1.1% shipyard pipe insulators in the U.S. from 1965 to 1973.[232] There is no epidemiological evidence

DOW 07434

EST0005934

indicating that a particular type of asbestos is responsible for asbestosis since these workers have been exposed to many different types of fibers in a variety of processes over the years.

Macroscopic appearances — Gross findings of the lungs varies markedly depending upon the severity and extent of the lesions. In the early stages, there are no obvious gross abnormalities and the lungs are normal size. With progression, the lungs become small and rubbery in consistency, and the pulmonary pleura is thickened with a focal diffuse pattern which tends to occur in the lower half of the lungs. The cut-surface of the lungs reveals distinct intralobular septa of the lower lobes and pronounced pleural margins. As a rule, the extent of fibrosis is similar in both lungs. In advanced cases, the cavities (1 to 15 mm) of the honeycomb lung are developed from dilated air spaces with fibrosis and retraction of the residual structure. The cut-surface shows honeycombing that is most prominent in the lower lobes. There is no evidence that exposure to asbestos contributes to the development of emphysema.[195] The tracheobronchial lymph nodes are often enlarged but no fibrotic changes are observed.

Microscopic appearances — Little is known about the early stages of asbestosis in man except from the information obtained from experimental animals. Initially, first-order respiratory bronchioles are affected by the fibrotic process; this spreads peripherally into the alveolar ducts, atria, and alveoli. Asbestos bodies and asbestos-laden macrophages may be present in the alveoli and fibrotic respiratory bronchioles. Collagenous fibrosis replaces the reticulin fibers and alveoli are more or less obliterated. The fibrogenic process involves varying numbers of respiratory bronchioles with obliteration of many alveoli, especially in subpleural regions.[229] With advance of the fibrotic process, the tissue adjacent to the respiratory bronchioles is affected extensively but the general architecture is preserved. In later stages, the lung parenchyma is diffusely replaced by fibrotic tissue and fibrous-walled cysts are formed, particularly in the subpleural and paraseptal regions of the lower lobes. At this stage, peribronchial and perivascular fibrosis are also observed.

Interstitial infiltration of lymphocytes and plasma cells are found in some patients but usually are not prominent in asbestosis. Also, multinucleated giant cells are variable in the fibrotic lesions. The identification of asbestos bodies in the lung tissue with typical fibrotic lesions is required to establish the diagnosis. Asbestos bodies are usually observed in the advanced stages of the disease. However, sometimes they are difficult to identify because asbestos bodies or fragmented, uncoated fibers are cleared from the lung. Therefore, multiple tissue sections should be examined to demonstrate asbestos bodies or uncoated fibers. Since most of the uncoated asbestos fibers in the lung sections are usually short (<5 μm), they are difficult to identify by light microscopy.

A committee of North American pathologists has proposed standards for grading the severity of asbestosis to develop a common basis for communication among pathologists and between pathologists, radiologists, and clinicians.[195,233]

Grade 0: No fibrosis is associated with bronchioles.

Grade 1: Fibrosis involves wall of at least one respiratory bronchiole with or without extension into the septa of the immediately adjacent layer of alveoli; no fibrosis is present in more distant alveoli.

Grade 2: Fibrosis appears as in Grade 1, plus involvement of alveolar ducts or two or more layers of adjacent alveoli; there still must be a zone of nonfibrotic alveolar septa between adjacent bronchioles.

Grade 3: Fibrosis appears as in Grade 2, but with coalescence of fibrotic change such that all alveoli between at least two adjacent bronchioles have thickened, fibrotic septa; some alveoli may be obliterated completely.

Grade 4: Fibrosis appears as in Grade 3, but with formation of new spaces of a size larger than alveoli, ranging up to as much as 1 cm; this lesion has been termed honeycombing. Spaces may or may not be lined by epithelium.

DOW 07435

The proportion of the respiratory bronchioles involved by the disease process needs to be assessed. The grades pertain to the relative numbers of bronchioles in the slide involved in fibrosis — not just the numbers involved to the maximum degree as recorded under severity — as follows:

Grade A (1): Only occasional bronchioles are involved — most show no lesion.
Grade B (2): More than occasional involvement is seen, but less than half of all bronchioles are involved.
Grade C (3): More than half of all bronchioles are involved.

F. Fiber Dimension-Related Fibrogenicity and Carcinogenicity

Little is known about the pathogenesis of pulmonary fibrosis or carcinogenesis although animal experiments with asbestos have been available for over 40 years. Asbestos carcinogenesis is thought to be related to trace metals, polycyclic aromatic hydrocarbons, or absorbed carcinogenic agents.[231,232] However, suspected carcinogens associated with asbestos have not shown any significant effects on tumor induction.[236,237] The polyfilamentous structure of asbestos is thought to be responsible for pulmonary fibrosis and carcinogenesis, whereas manmade fibers are neither fibrogenic nor carcinogenic because they are of monofilamentous structure.[238] However, the theory of the structure-related fibrogenesis or carcinogenesis has not been widely accepted. Rats, guinea pigs, and hamsters exposed to manmade fibers (potassium titanate) by inhalation develop dose-related pulmonary fibrosis in all three species but mesotheliomas only in hamsters.[88]

Recently, attention has been drawn to the importance of fiber-dimensional configurations in the experimental induction of pleural or peritoneal mesotheliomas and pulmonary fibrosis. Short fibers (<5 μm) provoke only macrophage response, but longer fibers (>10 μm) produce a giant cell granuloma with collagenized fibrosis.[88] Also, the carcinogenicity of fibrous particles seems to be related to fiber diameter and length rather than other physicochemical properties of fibers. Pleural mesotheliomas and sarcomas are induced in rats by intrapleural implantation with natural mineral or manmade fibers such as asbestos, fiberglass, attapulgite, wallastonite, silicon carbide, mineral wool, and potassium titanate.[89-97] Carcinogenicity decreases as more fibers exceed 2.5 μm in diameter and as their length decreases below 10 μm. An optimal dimension of fiber particles for mesothelioma induction is less than 1.5 μm in diameter and greater than 8 μm in length.[89,97] The size-related carcinogenesis of fibrous particles has been substantiated by either intrapleural[239] or intraperitoneal injection[240] with fiberglass, and carcinogenic response appears to depend on length, diameter, and the aspect ratio (length/diameter).[240] Crocidolite is most potent followed by amosite, anthophyllite, and chrysotile.[241] However, the incidence of human mesothelioma after exposure to different forms of asbestos does not correlate with the relative potency determined in animal studies. Fiberglass below 0.5 μm in diameter produced mesotheliomas whereas fibers of more than 3 μm diameter are much less carcinogenic or fibrogenic in rats following intrapleural injection.[239] These results emphasize the importance of fiber dimension for tumor induction because fibers of different internal structure and chemical composition than asbestos but of similar size induce pleural mesotheliomas. The occurrence of mesotheliomas in Turkey after exposure to a naturally occurring zeolite fiber with dimensions similar to asbestos, supports the theory of fiber-dimension-related carcinogenicity.[242] Recently, several different kinds of asbestos minerals in addition to zeolite fibers were found in environmental samples, and also lung tissue of mesothelioma patients revealed both fibrous zeolites and asbestos minerals. Whether asbestos fibers are solely responsible for mesotheliomas is not known because zeolite alone is capable of producing tumors in experimental animals.[243] It should be noted that intrapleural or intraperitoneal injection of asbestos or manmade fibers has little relevance to human exposure because of the unnatural exposure route, the large quantity of material used and avoidance of the lung defense mechanism. It has been postulated that

DOW 07436

ST0005936

tumor induction following intrapleural implantation with particulates may be due to a mechanical, solid-state, or Oppenheim effect[244] and there is no definite evidence of carcinogenic effects in man. Mesothelioma induction by either intrapleural or intraperitoneal injection of asbestos or manmade fibers raises the concern for potential health hazard by exposure to manmade fibers. This concern stimulated a review of epidemiological studies including not only fiberglass-producing plant workers but also those handling mineral wools. A recent review indicates that manmade vitreous fibers do not cause an increased risk of lung cancer or nonmalignant lung disease.[245]

The durability of fibrous particles is another important consideration in the production of biological effects such as pulmonary fibrosis and carcinogenicity because particles can be denatured by either body fluid or macrophages. Fiberglass shows distinct solubility, reduction in fiber length and diameter, and disappearance of finer fibers in synthetic "plasma" solution.[246] When mineral fiber insulation wools are treated with simulated body fluid, focal corrosion occurs. The relative inertness of fiberglass may be explained by shortening or disintegration of fibers by focal corrosion.[247]

G. Theory of Asbestos-Induced Pulmonary Fibrosis

Macrophages appear to play an important role in asbestos-induced fibrosis via a two-stage mechanism. First is the fiber-macrophage interaction followed by a macrophage-fibroblast interaction. Tissue cultures have been used to determine cellular effects of asbestos. Short asbestos fibers (<5 μm) are completely ingested, intermediate fibers (5 to 20 μm) are occasionally phagocytized by one macrophage, but large fibers (>30 μm) are surrounded by several macrophages and each end of fiber may remain in an extracellular position.[248] The short fibers are retained in phagocytic vesicles of the macrophage and secondary lysosomes for several hours. A few days later, some fibers are seen free within the cytoplasm, presumably a result of lysosomal membrane lysis. It is postulated that the first phase prolonged stimulation by asbestos fibers is a trigger for chronic lysosomal enzyme release. These enzymes might have a direct effect on the fibroblast, or fibroblast stimulation, might result from products of tissue destruction or mediators released from the inflammatory response. Asbestos differs from silica in that it induces selective release of lysosomal hydrolases without cell death.[249] Chrysotile produces a noticeable hemolysis but crocidolite and amosite are relatively inactive. This difference may be attributable to the amount of protein adsorbed on the surface of fibers.[250] For fibrogenicity, there is weak correlation between hemolytic potency and early and late macrophage toxicity. As to a relationship between these properties and carcinogenesis, there is only speculation.

The mechanism of interaction of asbestos with cytoplasmic and lysosomal membranes[248,251] is thought to be the result of fiber surface magnesium groups interacting electrostatically with sialic acid groups on membrane glycoproteins. These glycoproteins, which are usually able to migrate with the membrane, are immobilized in the area of contact with fiber. This aggregation of proteins forms ion-conduction channels permitting the efflux of potassium and influx of sodium ions and water; this results in osmotic lysis of the cell. However, there is some doubt about whether surface magnesium ions are the correct explanation for toxic effects of asbestos fibers. This theory does not explain the fibrogenic effects of crocidolite which is magnesium-free.[252] Immunological mechanisms are suspected for induction of the granulomatous tissue reaction in berylliosis and silicosis, but evidence in asbestos-induced fibrosis is weak and no more than pure speculation.

VII. ANIMAL EXPERIMENTS WITH ASBESTOS AND MANMADE FIBERS

A. Pulmonary Response to Asbestos and Thin Inorganic Fibers

All types of asbestos can produce pulmonary fibrosis, however, there are no discernible differences in the morphological features of lesions induced. Also, morphological charac-

DOW 07437

teristics of the pulmonary response induced by asbestos is similar to that of thin manmade potassium titatanate (PT) fibers which have similar fiber length, diameter, and shape.[36] The magnitude of granulomatous and fibrogenic reaction is related to the fiber length for both asbestos or PT fibers. The longer fibers produce marked giant cell granulomas with collagenized fibrosis in the respiratory bronchiolar region, while short fibers produce only macrophage response. Significant species differences in terms of fibrogenicity, granulomatous tissue reaction, and asbestos or ferruginous body formation exist. In hamsters exposed to either asbestos or PT fibers, active cellular granulomas with minimal collagenized fibrosis persist throughout the life span after 3 months exposure, whereas rats show minimal granulatous tissue reaction but extensive collagenized fibrosis. Asbestos or ferruginous bodies induced by amosite and titanate fibers, respectively, develop in hamsters and guinea pigs but not in rats.

The early tissue response to inhaled asbestos in man is very poorly understood since most lung tissue obtained from biopsy or autopsy are in advanced stages of asbestosis and the tissues of interest are obscured by extensive collagenized fibrosis. Therefore, the early tissue reactions need to be inferred from information obtained by animal experiments. On day 20 of inhalation exposure to either amosite or two types PT fibers in rats, hamsters, and guinea pigs, dust particles are retained in the respiratory bronchioles, alveolar ducts, and adjoining alveoli. Most particles are phagocytized by intraalveolar macrophages and some in foreign body giant cells.[36] Most dust cells are free within alveoli which themselves are lined with hyperplastic cuboidal cells (Type II pneumocytes). On day 50 of the exposure, dust-laden macrophages (dust cells), giant cells, and hyperplastic alveolar lining cells are increased. Some alveolar air spaces adjacent to the alveolar ducts are occluded with dust cells, giant cells, inflammatory cells, proliferating fibroblasts, and hyperplastic alveolar cells. The respiratory bronchiolar walls are thickened by dust-laden giant cells and proliferating fibroblasts where reticulin fiber networks, containing scanty collagen fibers, are formed. Obliterative bronchiolitis is observed in rats and hamsters exposed to PT fibers as a very high concentration but not in guinea pigs. On day 90, the respiratory bronchiolar region shows patchy thickening caused by foreign body granuloma with marked proliferation of fibroblasts (Figures 29, 30) and reticulin fiber networks with loosely interwoven collagen fibers. The pathological lesions are sharply confined to respiratory bronchiolar region. The bronchiolarization of alveoli adjacent to the terminal bronchioles is increased (Figure 31). Some dust-laden giant cells in the alveoli are partially or completely integrated into either bronchiolar or adjoining alveolar walls with proliferating fibroblasts and hyperplastic alveolar cells. In hamsters, but not rats or guinea pigs, marked acute inflammatory cells are seen.

After 90 days exposure and 6 months of recovery, the dust-laden granulomatous lesions in rats are reduced in cellularity and show increased collagen fiber deposition. Free intraalveolar dust cells are markedly fewer, and most hyperplastic cuboidal alveolar lining cells have been replaced by flattened alveolar lining cells. In contrast, hamsters and guinea pigs still show active cellular granulomas with markedly proliferating fibroblasts, inflammatory cells, and hyperplastic alveolar lining cells. The collagen deposition in the granulomatous lesions is somewhat more prominent in hamsters than guinea pigs but is less prominent in rats. At 1 year postexposure, the cellularity of the granulomatous lesions and the number of dust cells are decreased while collagen fiber deposition becomes slightly more prominent. By 2nd year postexposure, the respiratory bronchioles, alveolar ducts, and adjoining alveoli in rats show patchy thickenings with collagenized fibrosis (Figures 32 and 33), while the dust-laden giant cells, inflammatory cells, and fibroblasts are markedly reduced in number (Figures 34 and 35). In guinea pigs and hamsters, most dust-laden giant cells and dust cells are free in the alveoli. Collagenized fibrosis in the respiratory bronchiolar region is slightly greater in hamsters than in guinea pigs, but is less than seen in rats. Accumulation of dust particles is apparent in the tracheobronchial lymph nodes after 50 exposures and increased

DOW 07438

EST0005933



FIGURE 29. Asbestos-laden giant cells (G) are surrounded by markedly proliferating fibroblasts and inflammatory cells, mainly lymphocytes in the respiratory bronchiolar region (Rb). Terminal bronchiole (Tb), rat, asbestos (3.1×10^{6}/l, 90 days exposure (H. E. stain; magnification × 300.) (From Lee, K. P., Barras, C. E., Griffith, F. D., Waritz, R. S., and Lapin, C. A., *Environ. Res.*, 24, 167, 1981. With permission.)

gradually thereafter in all species. Most particles are less than 2 μm. Slight fibrosis is found in dust accumulated areas. Asbestos bodies and ferruginous bodies (formed from potassium titanate fibers) develop after 50 days exposure in hamsters and guinea pigs but not in rats. The number of asbestos and ferruginous bodies increase gradually thereafter and the asbestos bodies appear to segment and fragment as time passes.

It is difficult to induce pleural mesotheliomas by inhalation exposure to various types of asbestos in laboratory animals and only a small number of pleural mesotheliomas have been induced in rats.[252] In contrast, a very high incidence of mesotheliomas can be produced by intraperitoneal[253-257] or intrapleural[258-259] injection of asbestos in rats. A low incidence of pulmonary adenomas, adenocarcinomas, and epidermoid carcinomas can be induced in mice[260,261] and rats.[252,253,262] by inhalation exposure to asbestos. Tumors of the respiratory tract and lung are produced by intratracheal instillation of asbestos.[263-267] Pleural mesotheliomas developed in hamsters exposed to potassium titanate fibers after 18 months postexposure (Figures 36-39), but not in guinea pigs or rats.[96] Hamsters show more fibrotic pleuritis with dust cells and variable mesothelial hyperplasia than do rats or guinea pigs.

B. Comparative Pulmonary Response in Human and Animal Asbestosis

In general, the latent period of asbestosis, pleural plaque, mesothelioma, or lung cancer in humans is long, requiring about 20 years from first exposure.[104-109] In experimental asbestosis in animals, this latent period for fibrosis is very short with slightly collagenized fibrosis seen after 90 days.[96] However, the latency of either asbestos-induced mesothelioma

DOW 07439

ST0005939



FIGURE 30 Dust-laden giant cells (G) are enclosed by proliferating alveolar lining cells and inflammatory cells. Note fibroblast proliferation is not as remarkable as that shown in Figure 29. Dust cell aggregates (arrows) in the alveolar air space are surrounded by hyperplastic alveolar lining cells and obliterate the air spaces. Terminal bronchiole (Tb). rat. PT fiber (41.8×10^9 f). 90 days exposure. (H. E. stain: magnification × 300.) (From Lee, K. P., Barras, C. E., Griffith, F. D., Waritz, R. S., and Lapin, C. A., *Environ. Res.*, 24, 167, 1981. With permission.)

or lung cancer is longer, ranging from one half to 2 years in laboratory rodents.[252,253,262] After cessation of asbestos exposure, pulmonary fibrosis in humans is progressive, with coalescing fibrotic lesions involving a large portion of the lung. At the end stages, the lung reveals extensive reconstruction and coalescence of the alveoli with formation of microscopic and ultimately macroscopic cysts; the condition known as "honeycomb lung".[195] In contrast, in laboratory animals, after cessation of asbestos exposure, pulmonary fibrosis is not progressive. The fibrotic lesions follow the initial damage in severity and are confined to the respiratory bronchioles, alveolar ducts, and adjoining alveoli after discontinuation of asbestos exposure. Neither extensive pulmonary fibrosis nor "honeycomb lung" is developed. The anatomic location (respiratory bronchiolar region) of initial lung damage in human asbestosis is similar to that in experimental animals, but the distribution of severely damaged lung tissue in human asbestosis is different. The lesions in advanced human asbestosis is usually most prominent in the lower lobes and subpleural tissue,[80,195] while animal asbestosis does not show any preferential lobular location. Multinucleated giant cells in human asbestosis are a variable feature of the lesions; in some cases they are prominent, whereas in others they are rarely seen.[195] Numerous giant cells invariably appear to form giant cell granulomatous lesions in the respiratory bronchiolar region throughout the lifetime of laboratory animals (more in hamsters and guinea pigs than rats). Pleural plaques are often observed in man following asbestos exposure. In contrast, there are no reports of pleural plaque formation in laboratory animals even though pleural mesothelioma are induced in laboratory rodents

DOW 07440

FST0005940



FIGURE 31. The alveolar walls (A) adjacent to the terminal bronchiole are lined with ciliated columnar epithelium (bronchiolarization). Rat, PT fiber (41.8 × 10⁹/ℓ), 90 days exposure. (H. E. stain; magnification × 300.)



FIGURE 32. The respiratory bronchioles (Rb) and adjoining alveoli (A) are thickened with deposition of collagen fibers (arrows). Rat, PT fiber (41.8 × 10⁹/ℓ), 2 years post-exposure. (Silver impregnation technique; magnification × 100.)

DOW 07441

ST0005941



FIGURE 33 Alveolar wall is markedly thickened with abundant collagen fiber (C) deposition and alveolar macrophages showing uncoated asbestos (thin arrows) and asbestos body (thick arrow). Alveolar capillary lumen (CL), alveolar wall (AW), alveolar air space (A), red blood cell (R). Hamster, asbestos (3.1 × 10⁹/f), 18 months postexposure (Magnification × 8,170.)

by various types of asbestos. In advanced human asbestosis, cor pulmonale may develop as a complication of diffuse pulmonary fibrosis, while experimental animals do not have such cardiac complications because (1) the pulmonary fibrosis is not progressive and (2) fibrotic lesions are confined to the respiratory bronchiolar region with remaining lung parenchyma maintaining normal architecture.

C. Pulmonary Response to Organic Manmade Fibers

Commercial development of organic manmade (OMM) fibers started in the 1930s and was followed by full-scale production of many OMM fibers in the 1940s through 1960s. No conclusive evidence links the manufacturing or processing or synthetic fibers with serious health hazards. There are several epidemiological studies on workers employed in manmade fiber productions.[268-271] Only three reports concern worker exposure which are known to be limited to synthetic fibers.[272-274] Of three reports, one study suggests mild reduction in pulmonary function among workers in a polyacrylonitrile plant.[271] Little is known about pulmonary response to inhaled OMM fibers and their pathogenicity is a controversial topic. OMM fibers are generally considered nuisance dusts. Until recently, we have had only one report of 7 patients showing various bronchopulmonary disease in workers exposed to synthetic fibers.[275] The patients in this study had asthma, hypoxia, dyspnea, hypocapnia, spontaneous pneumothorax, extrinsic allergic alveolitis, chronic bronchitis with bronchiectasis, and chronic pneumonia. The pulmonary disease may be triggered by an immunologic response. The lungs reveal various degrees of cellular infiltration in airways or parenchymal tissue with fibrosis and emphysema in some cases. The lesions show nylon, polyester, or acrylic fibers. However, many questions can be raised concerning the validity of this study.[276] The patients' groups appear to be so diverse that a common etiological factor to all the cases

DOW 07442

EST0005942



FIGURE 34. The respiratory bronchiole (Rb) and adjacent alveoli (A), show prominent collagenization (C). Dust-laden giant cells (G) and macrophages are embedded in the collagen with scanty fibrocytes. Note markedly decreased cellularity in the collagenized area in comparison to that of the 90-day exposure (Figure 29). Alveolar air space (A). Rat, asbestos (3.1 × 10⁸/f), 2 years postexposure (H. E. stain; magnification × 300.) (From Lee, K. P., Barras, C. E., Griffith, F. D., Waritz, R. S., and Lapin, C. A., *Environ. Res.*, 24, 167, 1981. With permission.)

is hard to accept. None of these patients had an occupational history limited only to a synthetic fiber; in most cases they had also been exposed to wool and cotton. The study does not have control lung biopsy (from persons not employed in the synthetic fiber industry) to compare with those of the exposed patients. Similar lesions might be found in control population since inhalation of various types of synthetic fibers occurs in homes and other nonworking environments. The findings of textile fibers per se would only indicate past exposure, not necessarily disease as a result of it. Since the study does not present accurate exposure information, a dose-related pathogenicity of OMM fibers cannot be postulated. There is no conclusive evidence regarding the suspected immunologic mechanisms involved in the formation of the lung lesions here. It is suggested that synthetic fibers may act as haptens to induce allergic reactions.[269] However, again the patients are exposed to synthetic fibers in addition to wool or cotton fibers. Health hazard to cotton fiber is suspected to be a result of a hypersensitive immune reaction due to inhalation of the dust of raw cotton, flax, and hemp in the workplace.[276,277] Further, synthetic organic fibers used in textiles are generally large in diameter[278] and do not penetrate the lung. The respirability of dust particles are influenced by the fiber diameter and upper limits of respirable fiber diameter is about 3 μm. Because of the above, the potential health hazard of OMM fibers appears to be considerably reduced when compared to either asbestos or thin manmade fibers.

DOW 07443

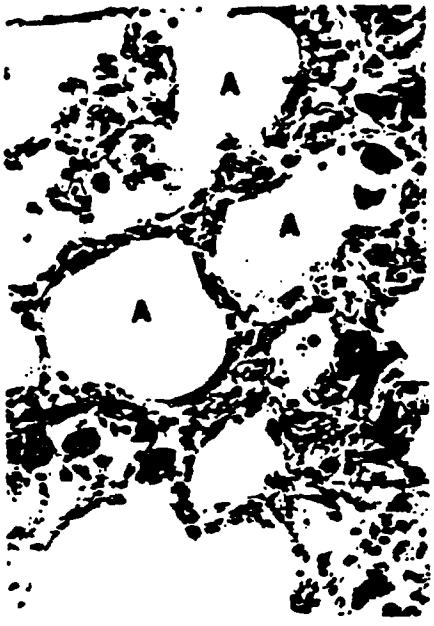

FIGURE 35. The collagenization of alveolar walls is not as prominent as that shown in Figure 34. Note markedly reduced cellularity of collagenized area in comparison to that of the 90-day exposure shown in Figure 30. Rat, PT fiber (41.8 × 10⁹/ml), 2 years postexposure. Alveolar air space (A). (H. E. stain; magnification × 300.)



FIGURE 36. White glistening tumor nodules (arrows) are scattered throughout the visceral pleura of the lung. Hamster, PT fiber (41.8 × 10⁹/ml, 18 months postexposure. (From Lee, K. P., Barras, C. E., Griffith, F. D., Waritz, R. S., and Lapin, C. A., *Environ. Res.*, 24, 167, 1981. With permission.)

DOW 07444

EST0005944



FIGURE 37 Same hamster shown in Figure 25. Well-circumscribed white glistening tumor nodules (arrows) are distributed throughout the parietal pleura of the thoracic wall (T) and diaphragm (D). (From Lee, K. P., Barras, C. E., Griffith, F. D., Waritz, R. S., and Lapin, C. A., *Environ. Res.*, 24, 167, 1981. With permission.)

In a study designed to test the role of synthetic fibers in producing pulmonary lesions, guinea pigs were exposed to nylon and acrylic dust at a high concentration for 11 months.[279] Lesions are developed in the interalveolar septa consisting of granulomatous cellular proliferation with histocytes and fibroblasts. Inhaled particles are seen within the granulomatous lesions. This experiment does not provide information concerning detailed exposure concentration or information on airborne fiber numbers and gravimetric concentrations (gravimeter milligrams per liter). Hence, it is impossible to determine dose-related pathogenicity of the fibers and to extrapolate the animal data to man.

Few animal experiments looking at the pulmonary tissue response to other synthetic fibers, either by inhalation or intratracheal instillation, are available. Polyester fiber "skins" are irregularly constricted and sausage-like when examined under light microscopy and are brilliantly birefringent under polarized microscopy. Particle sizes ranged from 1 to 1000 μm in length and 1 to 4 μm in width. Rats were treated intratracheally with 0.25 mℓ of a 1% suspension of these particles and were killed at various times throughout a 2-year postexposure (PE) period. Long unrespirable fibers are retained in either the small bronchi or terminal bronchioles, whereas, shorter fibers are trapped in the respiratory bronchioles and adjacent alveoli. On the second day PE, acute inflammatory reactions were found in the areas where unrespirable large particulates are retained. At 1 week PE, the acute inflammatory exudate is replaced with chronic inflammatory cells and the large particulates are retained in the foreign body giant cell granulomas which are developed in the terminal or respiratory bronchioles. Respirable sized particulates are phagocytized by alveolar macrophages. The foreign body granulomas gradually decrease in number and size, and dust cells decrease in number progressively throughout the first year PE. By 2 years PE, large unrespirable particulates are still seen in the granulomas at the terminal bronchioles, while small particulates have mostly been removed by the lung clearing mechanisms. There is no evidence of collagen fiber formation, fibrosis, or significant alteration of the lung stromal architecture.

DOW 07445

ST0005945



FIGURE 38. Same hamster shown in Figure 36. The pleural surface (P) is covered with tumor nodules showing collagenized connective tissue (C) adjacent to the pleura and neoplastic mesothelial cells (M). Note collapsed lung parenchyma (L) is free of tumor invasion. Hamster, PT fiber (41.8 × 10⁹/ℓ), 18 months postexposure. (Trichrome stain; magnification × 30.) (From Lee, K. P., Barras, C. E., Griffith, F. D., Waritz, R. S., and Lapin, C. A., *Environ. Res.*, 24, 167, 1981. With permission.)

VIII. SUMMARY

Many theories have been proposed to explain asbestosis and asbestos-related pulmonary disease. However, none of the theories give a completely plausible explanation for the pathogenesis. Recently, attention has been drawn to a theory that the fibrogenicity or carcinogenicity of fibrous dust particles is related to fiber diameter and length rather than to chemical properties. This theory may help partially elucidate the disease process but is still far from solving the enigma of pulmonary fibrosis or carcinogenesis. The theory cannot explain the absence of these pathological effects among fiberglass workers or experimental animals exposed by inhalation (even though mesotheliomas are induced by intrapleural implantation and fiber dimension-related fibrogenicity is demonstrated by intratracheal injection). Little information regarding the pulmonary response to manmade fibrous particles is available in animals following inhalation exposure. Attempts should be made to confirm the absence of adverse effects using animal inhalation experiments even though to this point there is no conclusive evidence that either lung cancer or pulmonary diseases can be produced among employees in manmade fiber industries.

A new research trend seems concentrated on testing the durability of asbestos or manmade fibers. This is based on the concept that biological effects of fibrous particles are the result of relative durability and that particles which can be fragmented or shortened may be less

DOW 07446

TST0005946



FIGURE 39. Nose migrated PT fibers (arrows) in the collagenized pleura (P) with hyperplastic mesothelial cells. Lung parenchyma (L), mesothelioma (M), hamster. PT fiber (41.8 × 10⁹/ℓ), 18 months postexposure. (H. E. Stain; magnification × 500.) (From Lee, K. P., Barras, C. E., Griffith, F. D., Waritz, R. S., and Lapin, C. A., *Environ. Res.*, 24, 167, 1981. With permission.)

pathogenic. In the last two decades, considerable understanding about pulmonary fibrosis and carcinogenesis of asbestos has been achieved by clinical and animal experiments. In vitro tests including cytotoxicity, hemolysis, immunology, and enzyme biochemistry have provided important information on the interrelationships among these various biological effects of asbestos.

ACKNOWLEDGMENT

The author wishes to thank Mr. Gerald L. Kennedy, Jr., for critical reading of the manuscript and Mrs. Janice R. Gibbons for typing the manuscript. The author also wishes to thank Laboratory Investigation for permission to use micrographs (Figures 2, 10-11, 13, 14, 16), The American Journal of Pathology for micrographs (Figures 5-9), and Environmental Research for micrographs (Figures 12, 22, 23, 24, 29-30, 34, 36-39).

DOW 07447

REFERENCES

1. Muir, D. C. F., *Clinical Aspect of Inhaled Particles*. International Ideas, Philadelphia, 1972, chap. 1.
2. Lippmann, M. and Altshuler, B., Regional deposition of aerosols, in *Air Pollution and the Lung*, Aharonson, E. F., Ben-David, A., Klingberg, M. A., and Kaye, M., Eds., John Wiley & Sons, New York, 1975, 25.
3. Raabe, O. G., Pulmonary Toxicology of Respirable Particles, Technical Information Center, U. S. Department of Energy, Washington, D.C., 1980.
4. Raabe, O. G., *Deposition and Clearance of Inhaled Aerosols*, Department of Energy Rep. UCD-472-503, Laboratory for Energy-Related Health, National Technical Information Service, 1979.
5. Timbrell, V., An aerosol spectrometer and its applications, in *Assessment of Airborne Particles*, Mercer, T. T., Morrow, P. E., and Stober, W., Eds., Charles C Thomas, Springfield, Ill., 1972, 290.
6. Timbrell, V., Aerodynamic considerations and other aspects of glass fiber, in Occupational Exposure to Fibrous Glass HEW Publ. No. (NIOSH) 76-151, U.S. Department of Health, Education and Welfare, Washington, D.C., 1976, 43.
7. Harris, R. L. and Fraser, D. A., A model for deposition of fibers in the human respiratory system, *Am. Ind. Hyg. Assoc. J.*, 37, 73, 1976.
8. Pattle, R. E., The retention of gases and particles in the human nose, in *Inhaled Particles and Vapours*, Davies, C. N., Ed., Pergamon Press, Elmsford, N.Y., 1961, 302.
9. Bohning, D. E., Albert, R. E., Lippmann, M., and Foster, W. M., Tracheobronchial particle deposition and clearance, *Arch. Environ. Health*, 30, 457, 1975.
10. Landahl, H. D., On the removal of airborne droplets by the human respiratory tract. I The lung, *Bull. Math. Biophys.*, 12, 43, 1950.
11. Proctor, D. F., Swift, D. L., Quinlan, M., Salmon, S., Takagi, Y., and Evering, S., The nose and man's atmospheric environment, *A.M.A. Arch. Environ. Health*, 18, 671, 1950.
12. Brown, J. H., Cook, K. M., Ney, F. G., and Hatch, T., Influence of particle size upon the retention of particulate matter in the human lung, *Am. J. Public Health*, 40, 450, 1950.
13. Davies, C. N., A comparison between inhaled dust and the dust recovered from human lungs, *Health Physics*, 10, 1029, 1964.
14. Beeckmans, J. M., The deposition of aerosols in the respiratory tract, *Can. J. Physiol. Pharmacol.*, 43, 157, 1965.
15. Altshuler, B., Palmes, E. D., and Nelson, N., Regional aerosol deposition in the human respiratory tract in *Inhaled Particles and Vapours II*, Davies, C. N., Ed., Pergamon Press, Oxford, 1967, 323.
16. Broady, A. R., Hill, L. H., Adkins, B., Jr., and O'Connor, R. W., Chrysotile asbestos inhalation in rats: deposition pattern and reaction of alveolar epithelium and pulmonary macrophages, *Am. Resp. Dis.*, 123, 670, 1982.
17. Lee, K. P., Kelly, D. P., and Kennedy, G. L., Jr., Pulmonary response to inhaled Kevlar® aramid synthetic fibers in rats, *Toxicol. Appl. Pharmacol.*, 71, 242, 1983.
18. Timbrell, V., Deposition and retention of fibers in the human lung, *Ann. Occup. Hyg.*, 26, 347, 1982.
19. Timbrell, V., Measurement of fibers in human lung tissue, in *Biological Effects of Mineral Fibers*, Wagner, J. C., Ed., IARC Scientific Publ. No. 30, IARC, Lyon, 1980, 113.
20. Morgan, A. and Holmes, A., Concentrations and dimensions of coated and uncoated asbestos fibres in the human lung, *Br. J. Ind. Med.*, 37, 25, 1980.
21. Whitwell, F., Scott, J., and Grimshaw, M., Relationship between occupation and asbestos fibre content of the lungs and patients with pleural mesothelioma, lung cancer and other diseases, *Thorax*, 32, 377, 1977.
22. Morgan, A., Black, A., Evans, N., Holmes, A., and Pritchard, J. N., Deposition of sized glass fibers in the respiratory tract of the rat, *Ann. Occup. Hyg.*, 23, 353, 1980.
23. Gross, P., Tuma, J., and DeTreville, R. T. P., Lungs of workers exposed to fiberglass, *Arch. Environ. Health*, 23, 67, 1971.
24. Hammad, Y., Dinsa, J., Craighead, J., and Weill, H., Deposition of inhaled manmade mineral fibers in the lungs of rats, *Am. Occup. Hyg.*, 26, 179, 1982.
25. Morgan, A., Fiber dimensions: their significance in the deposition and clearance of inhaled fibrous dusts in *Dusts and Disease*, Lemen, R. and Dement, J. M. Y., Eds., Pathotox Publishers, Park Forest South, Ill., 1979, 87.
26. Morgan, A., Evans, J. D., and Holmes, A., Deposition and clearance of inhaled fibrous minerals in the rat. Studies using radioactive tracer techniques, in *Inhaled Particles IV*, Walton, W. H., Ed., Pergamon Press, Oxford, 1977, 1, 259.
27. Stober, W., Dynamic shape factors of nonspherical aerosol particles in *Assessment of Airborne Particles*, Mercer, T. T., Morton, P. E., and Stober, W., Eds., Charles C Thomas, Springfield, Ill., 1972, 249.
28. Timbrell, V., The inhalation of fibrous dusts, *Ann. N.Y. Acad. Sci.*, 132, 255, 1965.
29. Rhodin, J., Ultrastructure and function of the human tracheal mucosa, *Am. Rev. Respir. Dis.*, 93, 1, 1966.

DOW 07448

ST0005948

30. **Rhodin, J. and Dalhamn, T.**, Electron microscopy of the tracheal ciliated mucosa in rat. *Z. Zellforsch. Mikrosk. Anat. Mikrosk. Anat.*, 44, 345, 1956.
31. **Kilburn, K. H.**, A hypothesis for pulmonary clearance and its implications. *Am. Rev. Respir. Dis.*, 98, 449, 1968.
32. **Sorokin, S. P. and Brain, J. D.**, Pathways of clearance in mouse lungs exposed to iron oxide aerosols. *Anat. Rec.*, 181, 581, 1975.
33. **Booker, D. V., Chamberlain, A. C., Runde, J., Muir, D. C. F., and Thompson, M. L.**, Elimination of 5 μ particles from the human lung. *Nature (London)*, 215, 30, 1967.
34. **Lippman, M. and Albert, R. E.**, The effect of particle size on the regional deposition of inhaled aerosols in the human respiratory tract. *Am. Ind. Hyg. Assoc. J.*, 30, 257, 1969.
35. **Lourenco, R. V., Klimek, K. F., and Borowski, C. J.**, Deposition and clearance of 2 μm particles in the tracheobronchial tree of normal subjects. *J. Clin. Invest.*, 50, 1411, 1971.
36. **Sanchis, J., Dolovich, M., Chalmers, R., and Newhouse, M.**, Quantitation of regional aerosol clearance in the normal human lung. *J. Appl. Physiol.*, 33, 757, 1972.
37. **Lauweryns, J. M. and Baert, J. H.**, The role of the pulmonary lymphatics in the defense of the diseased lung: morphological and experimental studies of the transport mechanisms of intratracheally instilled particles. *Ann. N.Y. Acad. Sci.*, 221, 244, 1974.
38. **Wende, E.**, Gewerbehygiene und Klinik der Kieselgursilikose zugleich ein Beitrag zu Gewerbehygiene lungenaggressiver Staube. *Zentralbl. Arbeitsmed. Arbeitsschutz. Suppl.*, No. 6.
39. **Luton, P., Champeix, J., and Faure, P.**, The significance of the presence of the asbestos body in the expectoration of asbestos workers. *Arch. Mal. Prof. Med. Trav.*, 8, 56, 1947.
40. **Livingstone, R. and Street, F. W.**, A case of pulmonary asbestosis. *Br. Med. J.*, 939, 1950.
41. **Morgan, A., Talbot, R. J., and Holmes, A.**, Significance of fibre length in the clearance of asbestos fibres from the lung. *Br. J. Ind. Med.*, 35, 146, 1978.
42. **Ferin, J.**, Lung clearance of particles, in *Air Pollution and Lung*, Aharonson, E. F., Ben-David, A., and Klingberg, M. A., Eds., John Wiley & Sons, New York, 1976, 64.
43. **Ferin, J. and Leach, L. J.**, The effects of selected air pollutants on clearance on titanic oxide particles from the lungs of rats, in *Inhaled Particles IV*, Walton, W. H., Ed., Pergamon Press, Oxford, 1977, 1, 333.
44. **Klosterkotter, W. and Gone, F.**, Long-term storage, migration and elimination of dust in the lungs of animals, with special respect to the influence of polyvinyl-pyridine-N-oxide in *Inhaled Particles III*, Walton, W. H., Ed., Unwin Bros., Surrey, England, 1971, 1, 273.
45. **Ferin, J.**, Observations concerning alveolar dust clearance, *Ann. N.Y. Acad. Sci.*, 200, 66, 1972.
46. **Schoenberg, M. D., Gilman, P. A., Mumaw, V., and Moore, B. D.**, Proliferation of the reticuloendothelial system and phagocytosis, *Exp. Mol. Pathol.*, 2, 126, 1963.
47. **Kilburn, K. H.**, A hypothesis for pulmonary clearance and its implications, *Am. Rev. Respir. Dis.*, 98, 449, 1968.
48. **Staube, N. C.**, The "liquid veins" of the lung, *Physiologist*, 9, 294, 1966.
49. **Macklin, C. C.**, Pulmonary sumps, dust accumulations, alveolar fluid and lymph vessels, *Acta. Anat.*, 23, 1, 1955.
50. **Morrow, P. E.**, Lymphatic drainage of the lung in dust clearance, *Ann. N. Y. Acad. Sci.*, 200, 46, 1972.
51. **Lauweryns, J. M. and Baert, J. H.**, Alveolar clearance and the role of the pulmonary lymphatics, *Am. Rev. Respir. Dis.*, 115, 625, 1977.
52. **Green, G. M., Jakab, G. S., Low, R. B., and Davis, G. S.**, Defense mechanisms of the respiratory membrane, *Am. Rev. Respir. Dis.*, 115, 479, 1977.
53. **Brain, J. D., Sorokin, S. P., and Godleski, J. J.**, Quantification, origin and fate of pulmonary macrophage, in *Respiratory Defense Mechanisms* (Lung Biology in Health and Disease, Vol. 5, Part II), Brain, J., Proctor, P., and Reid, L., Eds., Marcel Dekker, New York, 1977, 849.
54. **Lee, K. P., Barras, C. E., Frank, F. D., and Warita, R. S.**, Pulmonary response to glass fiber by inhalation exposure, *Lab. Invest.*, 40, 123, 1979.
55. **Suzuki, Y. and Churg, J.**, Structure and development of the asbestos body, *Am. J. Pathol.*, 55, 79, 1969.
56. **Corrin, B.**, Phagocytic potential of pulmonary alveolar epithelium with particular reference to surfactant metabolism, *Thorax*, 24, 110, 1969.
57. **Masse, R., Fritsch, P., Ducousso, R., Lafuma, J., and Chretien, J.**, Retention de particules dans les cellules bronchiques, relations possible avec les carcinogenes inhales, *C. R. Hebd. Seances. Acad. Sci., Ser. D*, 276, 2923, 1973.
58. **Watson, A. Y. and Brain, J. D.**, Uptake of iron oxide aerosols by mouse airway epithelium, *Lab. Invest.*, 40, 450, 1979.
59. **Masse, R., Ducousso, R., Nolibe, D., Lafuma, J., and Chretien, J.**, Passage transbronchique des particules metalliques, *Rev. Fr. Mal. Resp.*, 1, 123, 1974.
60. **Stirling, C. and Patrick, G.**, The localization of particles retained in the trachea of the rat, *J. Pathol.*, 131, 309, 1980.

DOW 07449

61. Gore, D. H. and Patrick, G., A quantitative study of the penetration of insoluble particles into the tissue of the conducting airways. *Ann. Occup. Hyg.*, 36, 149, 1982.
62. Lee, K. P., Barras, C. E., Griffith, F. D., and Waritz, R. S., Pulmonary response and transmigration of inorganic fibers by inhalation exposure. *Am. J. Pathol.*, 102, 314, 1981.
63. Gross, P. and Hatch, T., Pneumoconiosis: the requirements for lymphatic dust transport. *Int. Arch. Gewerbepathol., Gewerbehyg.*, 19, 660, 1962.
64. Klosterkotter, W. and Bunemann, G., Untersuchungen uber die Ausscheidung inhalierter Staube im tierexperiment. *Beitr. Silikoseforsch.*, 3, 145, 1959.
65. Johansson, A. and Camner, P., Are alveolar macrophages translocated to the lymph nodes?, *Thorax*, 35, 157, 1980.
66. Strecker, F. J., Tissue reaction in rat lungs after dust inhalation with special regard to bronchial dust elimination and to the penetration of dust into the lung interstices and lymphatic nodes, in *Inhaled Particles and Vapours II*, Davis, C. N., Ed., Pergamon Press, Oxford, 1967, 141.
67. Holt, P. F., Short communication. Dust elimination from pulmonary alveoli. *Environ. Res.*, 23, 224, 1980.
68. Holt, P. F., Transport of inhaled dust to extrapulmonary sites. *J. Pathol.*, 133, 123, 1981.
69. Holt, P. F., Translocation of asbestos dust through the bronchial wall. *Environ. Res.*, 27, 255, 1982.
70. Tucker, A. D., Wyatt, J. H., and Undery, D., Clearance of inhaled particles from alveoli by normal interstitial drainage pathways. *J. Appl. Physiol.*, 35, 719, 1973.
71. LeFevre, M. E., Green, F. H. Y., Joel, D. D., and Laqueur, W., Frequency of black pigment in livers and spleens of coal workers. Correlation with pulmonary pathology and occupational information. *Human Pathol.*, 13, 1121, 1982.
72. Borow, M., Conston, A., Livornese, L., and Schalet, N., Mesothelioma following exposure to asbestos: a review of 72 cases. *Chest*, 64, 641, 1973.
73. Pooley, F., Locating fibers in the bowel wall. *Environ. Health Perspect.*, 9, 235, 1974.
74. Teliochi, M. and Rubenstone, A. I., Pulmonary asbestos associated with primary carcinoma of the lung, bronchial adenomas and adenocarcinoma of the stomach. *Arch. Pathol.*, 72, 234, 1961.
75. Godwin, M. C. and Jagatic, J. J., Asbestos and mesotheliomas. *Environ. Res.*, 3, 391, 1970.
76. Kent, E. E., Asbestosis and abdominal neoplasms. *Lancet*, 2, 1211, 1960.
77. Hourihane, D. O'. B., A biopsy series of mesotheliomata, and attempts to identify asbestos within some of the tumors. *Ann. N.Y. Acad. Sci.*, 132, 647, 1965.
78. von Hayek, H., Die menschliche Lunge. 2 erganzte und erweiterte Auflage. Springer-Verlag, Berlin, 1970.
79. ACGIH, *Threshold Limit Values for Chemical Substances and Physical Agents in the Work Environment*, Cincinnati, 1982, 50.
80. Parkes, W. R., *Occupational Lung Disorders*, 2nd ed., Butterworths, London, 1974, chaps. 1, 6, 9.
81. Schepers, G. W. H., Durkan, T. M., Delahant, A. B., Redlin, A. J., Schmidt, J. G., The biological action of fiberglass-plastic dust. *Arch. Ind. Health*, 18, 34, 1958.
82. Schepers, G. W. H., Pulmonary histologic reactions to inhaled fiberglass-plastic dust. *Am. J. Pathol.*, 35, 1169, 1959.
83. Gross, P., Kaschak, M., Tolker, E. E., Babyak, M. A., and DeTreville, R. T. P., The pulmonary reaction to high concentrations and fibrous glass dust. *Arch. Environ. Health*, 20, 696, 1970.
84. Gross, P., Westrick, M. L., and McNerney, J. M., Glass dust: a study of its biologic effects. *Arch. Ind. Health*, 21, 10, 1960.
85. Gross, P., The biologic categorization of inhaled fiberglass dust. *Arch. Environ. Health*, 31, 101, 1976.
86. Lee, K. P., Barras, C. E., Griffith, F. D., Waritz, R. S., and Lapin, C. A., Comparative pulmonary response to inhaled inorganic fibers with asbestos and fiberglass. *Environ. Res.*, 24, 167, 1981.
87. Davis, J. M. G., Pathological Aspects of the Injection of Glass Fiber into the Pleural and Peritoneal Cavities of Rats and Mice, in *Occupational Exposure to Fibrous Glass*, HEW Publ. No. (NIOSH) 76-151, U. S. Department of Health, Education and Welfare, Washington, D.C., 1974, 141.
88. Kuschner, M. and Wright, G. W., The Effects of Intratracheal Instillation of Glass Fiber of Varying Size in Guinea Pigs, in *Occupational Exposure to Fibrous Glass*, HEW Publ. No. (NIOSH) 76-151, U. S. Department of Health, Education and Welfare, Washington, D.C., 1974, 151.
89. Stanton, M. F. and Wrench, C., Mechanisms of mesothelioma induction with asbestos and fibrous glass. *J. Natl. Cancer Inst.*, 48, 797, 1972.
90. Stanton, M. F., Layard, M., Tegeris, A., Miller, M., May, M., and Kent, E., Carcinogenicity of fibrous glass: pleural response in the rat in relation to fiber dimension. *J. Natl. Cancer Inst.*, 58, 587, 1977.
91. Enterline, P. E. and Henderson, V., A study of the health of retired fibrous glass workers. *Arch. Environ. Health*, 30, 113, 1975.
92. Hill, J. W., Whitehead, W. S., Cameron, J. D., and Hedgecock, G. A., Glass fibers: absence of pulmonary hazard in production workers. *Br. J. Ind. Med.*, 30, 174, 1973.
93. Nasr, A. N. M., Dilchek, T., and Scholtens, P. A., The prevalence of radiographic abnormalities in the chests of fiberglass workers. *J. Occup. Med.*, 13, 371, 1971.

DOW 07450

EST0035950

94. Utidjian, H. M. D. and de Treville, R. T. P., Fibrous Glass Manufacturing and Health. Report of an Epidemiological Study: Part I. Trans. 35th Annu. Meet. of Industrial Health Foundation, Pittsburgh, Pa., October 13 to 14, 1970, 98.
95. Wright, G. W., Airborne fibrous glass particles, *APh. Environ. Health*, 16, 175, 1968.
96. Smith, D. M., Ortiz, L. W., and Archuleta, R. F., Chronic Exposure of Laboratory Animals to Inhaled Small Diameter Glass Fibers, Occupational Health Conference, Copenhagen, April 20 to 22, 1981, Programme and Abstracts, Regional Office for Europe World Health Organization, Copenhagen, 1982.
97. Goldstein, B., Rendall, R. E. G., and Webster, I., A comparison of the effects of exposure of baboons to crocidolite and fibrous-glass dusts, *Environ. Res.*, 32, 344, 1983.
98. Bowden, D. H. and Adamson, I. Y. R., Reparative changes following pulmonary cell injury. Ultrastructural, cytodynamic and surfactant studies in mice after oxygen exposure, *Arch. Pathol.*, 92, 279, 1971.
99. Adamson, I. Y. R. and Bowden, D. H., The type 2 cell as progenitor of alveolar epithelial regeneration. A cytodynamic study in mice after exposure to oxygen, *Lab. Invest.*, 30, 35, 1974.
100. Evans, M. J., Cabral, L. C., Stephens, R. J., and Freeman, G., Acute kinetic response and renewal of the alveolar epithelium following injury by nitrogen dioxide, *Chest*, 65, 62S, 1974.
101. Evans, M. J., Cabral, L. J., Stephens, R. J., and Freeman, G., Transformation of alveolar type 2 cells to type 1 cells following exposure to NO_2, *Exp. Mol. Pathol.*, 22, 142, 1975.
102. Penha, P. D. and Werthamer, S., The role of pneumocyte II in alveolar injury and repair, *Am. Rev. Respir. Dis.*, 107, 1109, 1973.
103. Stelzner, M. F., Baron, D. A., and Esterly, J. R., Cadmium-induced lung injury, *Lab. Invest.*, 32, 457, 1975.
104. Strauss, R. H., Palmer, K. C., and Hayes, J. A., Acute lung injury induced by cadmium aerosol, *Am. J. Pathol.*, 84, 561, 1978.
105. Stephens, R. J., Sloane, M. F., Evans, M. J., and Freeman, G., Early response of lung to low levels of ozone, *Am. J. Pathol.*, 74, 31, 1974.
106. Plopper, C. G., Dungworth, D. L., and Tyler, W. S., Pulmonary lesions in rats exposed to ozone: a correlated light and electron microscopic study, *Am. J. Pathol.*, 71, 375, 1973.
107. Kapanci, Y., Weibel, E. R., Kaplan, H. P., and Robinson, F. R., Pathogenesis and reversibility of the pulmonary lesions of oxygen toxicity in monkeys. II. Ultrastructural and morphometric studies, *Lab. Invest.*, 20, 101, 1969.
108. Adamson, I. Y. R. and Bowden, D. H., Adaptive response of the pulmonary macrophagic system to carbon. II. Morphologic studies, *Lab. Invest.*, 38, 430, 1978.
109. Klotz, O., Pulmonary anthracosis a community disease, *Am. J. Public Health*, 4, 887, 1944.
110. Van Furth, R., Origin and kinetics of monocytes and macrophages, *Semin. Hematol.*, 7, 125, 1970.
111. Volkman, A. and Gowans, J. L., The origin of macrophages from bone marrow in the rat, *Br. J. Exp. Pathol.*, 46, 62, 1965.
112. Rosen, S. H., Castleman, B., and Liebow, A. A., Pulmonary alveolar proteinosis, *N. Engl. J. Med.*, 258, 1123, 1958.
113. Hook, G. E. R., Bell, D. Y., Gilmore, L. B., Nadeau, D., Reasor, M. J., and Talley, F. A., Composition of bronchoalveolar lavage effluents from patients with pulmonary alveolar proteinosis, *Lab. Invest.*, 39, 342, 1978.
114. Kuhn, C., Györkey, F., Levine, B. E., and Ramirez-Rivera, J., Pulmonary alveolar proteinosis, *Lab. Invest.*, 15, 492, 1966.
115. McClenahan, J. B. and Musseenden, R., Pulmonary alveolar proteinosis, *Arch. Intern. Med.*, 133, 284, 1974.
116. Ramirez-R, J. and Harlan, W. R., Pulmonary alveolar proteinosis, *Am. J. Med.*, 45, 502, 1968.
117. Costello, J. F., Moriarty, D. C., Braithwaite, M. A., Turner-Warwick, M., and Corrin, B., Diagnosis and management of alveolar proteinosis: the role of electron microscopy, *Thorax*, 30, 121, 1975.
118. Divertie, M. B., Brown, A. L., and Harrison, E. G., Pulmonary alveolar proteinosis, *Am. J. Med.*, 40, 351, 1966.
119. Larson, R. K. and Gordinier, R., Pulmonary alveolar proteinosis: report of six cases, review of the literature, and formulation of a new theory, *Ann. Intern. Med.*, 62, 292, 1965.
120. Nicholas, J. J., Auchincloss, J. H., and Rudolph, L., Pulmonary alveolar proteinosis: a case with improvement after a short course of endobronchial instillations of heparin, *Ann. Intern. Med.*, 62, 358, 1965.
121. Golde, D. W., Territo, M., Finley, T. N., and Cline, M. J., Defective lung macrophages in pulmonary alveolar proteinosis, *Ann. Intern. Med.*, 85, 304, 1976.
122. Heppleston, A. G. and Young, A. E., Alveolar lipo-proteinosis: an ultrastructural comparison of the experimental and human forms, *J. Pathol.*, 107, 107, 1971.
123. Gross, P. and Hatch, T., Pulmonary alveolar clearance: its mechanism and its relation to pulmonary disease, *J. Occup. Med.*, 5, 191, 1963.

DOW 07451

124. Ramirez-R., J., Nyka, W., and McLaughlin, J., Pulmonary alveolar proteinosis: diagnostic techniques and observations. *N. Engl. J. Med.*, 268, 165, 1963.
125. Ramirez-R. J., Schultz, R. B., and Dutton, R. E., Pulmonary alveolar proteinosis: a new technique and rationale for treatment. *Arch. Intern. Med.*, 112, 419, 1963.
126. Henkin, R. I. and Bishop, H. A., Pulmonary clearance of radioactive iodinated serum albumin in man. *J. Lab. Clin. Med.*, 60, 709, 1962.
127. Ramirez-R. J., Pulmonary alveolar proteinosis, in *Biochemical Clinics. Vol. 4. The Lung*. Kugelmass, I. N., Ed., Reuben H. Donnelly Corp., New York, 1964, 165.
128. Corrin, B. and King, E., Pathogenesis of experimental pulmonary alveolar proteinosis. *Thorax*, 25, 230, 1970.
129. Heppleston, A. G., Wright, N. A., and Stewart, J. A., Experimental alveolar lipoproteinosis following the inhalation of silica. *J. Pathol.*, 101, 293, 1970.
130. Gross, P. and de Treville, R. T. P., Alveolar proteinosis. *Arch. Pathol.*, 86, 255, 1968.
131. Heppleston, A. G., Fletcher, K., and Wyatt, I., Changes in the composition of lung lipids and the "turnover" of dipalmitoyl lecithin in experimental alveolar lipoproteinosis induced by inhaled quartz. *Br. J. Exp. Pathol.*, 55, 384, 1974.
132. Schober, R., Bensch, K. G., Kosek, J. C., and Northway, W., On the origin of the membranous intraalveolar material in pulmonary alveolar proteinosis. *Exp. Mol. Pathol.*, 21, 246, 1974.
133. Lullmann-Rauch, R., Reil, G. H., Rossen, E., and Seiler, K. U., The ultrastructure of rat lung changes induced by an anoretic drug (Chlurophentermine). *Virchows Arch. B. Zellpathol.*, 11, 167, 1972.
134. Vijeyaratnam, G. S. and Corrin, B., Pulmonary alveolar proteinosis developing from desquamative interstitial pneumonia in long-term toxicity studies of iprindole in the rat. *Virchows Arch. A. Pathol. Anat.*, 358, 1, 1973.
135. Reyes, J. M. and Putong, P. B., Association of pulmonary alveolar lipoproteinosis with mycobacterial infection. *Am. J. Clin. Pathol.*, 478, 1980.
136. Andriole, V. T., Bailas, M., and Wilson, G. L., The association of nocardiosis and myocardiosis pulmonary alveolar proteinosis. *Ann. Intern. Med.*, 60, 266, 1964.
137. Hartung, M. and Salfelder, K., Pulmonary alveolar proteinosis and histoplasmosis. *Virchows Arch. A. Pathol. Anat.*, 368, 281, 1975.
138. Raschod, M. and Bisaeti, M., Pulmonary alveolar proteinosis and cytomegalovirus infection. *Arch. Pathol. Lab. Med.*, 103, 139, 1979.
139. Payseur, C. R., Konwaiser, B. E., and Hyde, L., Pulmonary alveolar proteinosis. *Am. Rev. Tuberc.*, 79, 906, 1958.
140. Davidson, J. M. and Macleod, W. M., Pulmonary alveolar proteinosis. *Br. J. Dis. Chest*, 63, 13, 1969.
141. Schober, R., Kosek, J. C., and Bensch, K. G., Origin of the membraneous intra-alveolar material in pulmonary alveolar proteinosis. *Lab. Invest.*, 30, 388, 1974.
142. Hoffmann, E. O., Lamberty, J., Pizzolato, P., and Coover, J., The ultrastructure of acute silicosis. *Arch. Pathol.*, 96, 104, 1973.
143. Xipell, J. M., Ham, K. N., Price, C. G., and Thomas, D. P., Acute silico-lipoproteinosis. *Thorax*, 32, 104, 1977.
144. McEuen, D. D. and Abraham, J. L., Particulate concentration in pulmonary alveolar proteinosis. *Am. J. Pathol.*, 86, 63a, 1977.
145. Brain, J. D., Knudson, D. E., Sorokin, S. P., and Davis, M. A., Pulmonary distribution of particles given by intratracheal instillation or by aerosol inhalation. *Environ. Res.*, 11, 13, 1976.
146. Gross, P., de Treville, R. T. P., Cralley, L. J., Granoquist, W. T., and Pandeck, F. L., The pulmonary response to fibrous dusts of diverse compositions. *Am. Ind. Hyg. Assoc. J.*, 31, 125, 1970.
147. Corrin, B., Aluminum pneumoconiosis. II. Effect on the rat lung of intratracheal injections of stamped aluminum powders containing different lubricating agents and of a granular aluminum powder. *Br. J. Ind. Med.*, 20, 268, 1963.
148. Gross, P., Harley, R. A., and de Treville, R. T. P., Pulmonary reaction to metallic aluminum powders: an experimental study. *Arch. Environ. Health*, 26, 227, 1973.
149. Zussman, J., The Crystal Structure of Amphibole and Serpentine Minerals, in Workshop on Asbestos: Definition and Measurement Methods. NBS Spec. Publ. 506, Gravatt, C. C., Ed., U. S. Government Printing Office, Washington, D.C., 1978, 35.
150. Leineweber, J. P., Dust chemistry and physics: mineral and vitreous fibers, in *Biological Effects of Mineral Fibers*, Wagner, J. C. and Davis, W., Eds., International Agency for Research on Cancer, Lyon, 1980, 881.
151. Davis, J. M. G., Electron microscope studies of asbestosis in man and animals. *Ann. N.Y. Acad. Sci.*, 132, 98, 1965.
152. Suzuki, Y. and Churg, J., Formation of the asbestos body. A comparative study with three types of asbestos. *Environ. Res.*, 3, 107, 1969.

DOW 07452

EST0005952

153. Governa, M. and Rasseda, C., A histochemical study of the asbestos body coating, *Br. J. Ind. Med.*, 29, 154, 1972.
154. Langer, A. M., Baden, V., Hammond, E. C., and Selikoff, I. J., Inorganic fibres, including chrysotile in lungs at autopsy: preliminary report, in Inhaled Particles III, Walton, W. H., Ed., Unwin Bros., Surrey, England, 1971, 683.
155. Pooley, F. D., Oldham, P. D., Chang-Hyun Um, and Wagner, J. C., The detection of asbestos in tissues, in *Pneumoconiosis. Proc. Int. Conf., Johannesburg, 1969*, Shapiro, H. A., Ed., Oxford University Press, Cape Town, 1970, 108.
156. Ashcroft, T. and Heppleston, A. G., The optical and electron microscopic determination of pulmonary asbestos fibre concentration and its relation to the human pathological reaction, *J. Clin. Pathol.*, 26, 224, 1973.
157. Churg, A. and Warnock, M. L., Asbestos fibers in the general population, *Am. Rev. Respir. Dis.*, 122, 669, 1980.
158. Pooley, F. D., Asbestos bodies, their formation, composition and character, *Environ. Res.*, 5, 363, 1972.
159. Davis, J. M. G. and Gross, P., Are ferruginous bodies an indication of atmospheric pollution by asbestos?, in *Biological Effects of Asbestos*, International Agency for Research on Cancer, Lyon, 1973, 238.
160. Parkes, W. R., *Occupational Lung Disorders*, Butterworths, London, 1982.
161. Churg, A., Fiber counting and analysis in the diagnosis of asbestos-related disease, *Human Pathol.*, 13, 381, 1982.
162. Churg, A. and Warnock, M. L., Asbestos and other ferruginous bodies: their formation and clinical significance, *Am. J. Pathol.*, 102, 442, 1981.
163. Churg, A. M. and Warnock, M. L., Numbers of asbestos bodies in urban patients with lung cancer and gastrointestinal cancer and in matched controls, *Chest*, 76, 143, 1979.
164. Nizze, H., Exposure to asbestos and the genesis of pleural plaques and neoplasia, *Arch. Pathol.*, 95, 213, 1973.
165. Anjilvel, L. and Thurbeck, W. M., The incidence of asbestos bodies in the lungs at random necropsies in Montreal, *Can. Med. Assoc. J.*, 95, 1179, 1966.
166. Sebastien, P., Fondimare, A., Bignon, J., Mouchaux, G., Desbordes, J. and Bonnaud, G., Topographic distribution of asbestos fibres in human lung in relation to occupational and non-occupational exposure, in *Inhaled Particles IV*, Walton, W. H. and McGovern, B., Eds., Pergamon Press, Oxford, 1977, 435.
167. Thomson, J. G. and Graves, W. M., Asbestos as an urban air contaminant, *Arch. Pathol.*, 81, 458–464, 1966.
168. Cauna, D., Totten, R. S., and Gross, P., Asbestos bodies in human lungs at autopsy, *JAMA*, 192, 371, 1965.
169. Gross, P., Cralley, L. J., and de Treville, R. T. P., Asbestos bodies: their non-specificity, *Am. Ind. Hyg. Assoc. J.*, 28, 541, 1967.
170. Thomson, J. G., Kaschula, R. O. C., and Macdonald, R. R., Asbestos as a modern urban hazard, *S. Afr. Med. J.*, 37, 77, 1963.
171. Gross, P., de Treville, R. T. P., and Haller, M. N., Pulmonary ferruginous bodies in city dwellers, *Arch. Environ. Health*, 19, 186, 1969.
172. Selikoff, I. J. and Hammond, E. C., Asbestos bodies in the New York City population in two periods of time, in *Pneumoconiosis. Proc. Int. Conf., Johannesburg, 1969*, Shapiro, H. A., Ed., Oxford University Press, Cape Town, 1970.
173. Bhagavan, B. S. and Kass, L. G., Secular trends in prevalence and concentration of pulmonary asbestos bodies — 1940 to 1972, *Arch. Pathol. Lab. Med.*, 100, 539, 1976.
174. Meurman, L., Asbestos bodies and pleural plaques in a Finnish series of autopsy cases, *Acta Pathol. Microbiol. Scand., Suppl.*, 181, 1966.
175. Thomson, J. G., The pathogenesis of pleural plaques, in *Pneumoconiosis. Proc. Int. Conf., Johannesburg, 1969*, Shapiro, H. A., Ed., Oxford University Press, Cape Town, 1970, 138.
176. Heard, B. E. and Williams, R., The pathology of asbestosis with reference to lung function, *Thorax*, 16, 264, 1961.
177. Entickmap, J. B. and Smither, W. J., Peritoneal tumours in asbestosis, *Br. J. Ind. Med.*, 21, 20, 1964.
178. Hourihane, D. O'B., Lessof, L., and Richardson, P. C., Hyaline and calcified pleural plaques as an index of exposure to asbestos, *Br. Med. J.*, 1, 1069, 1966.
179. Lemon, W. S. and Higgins, G. M., Absorption from the pleural cavity of dogs, *Am. J. Med. Sci.*, 184, 846, 1932.
180. Le Bouffant, L., Martin, J. C., Daniel, H., and Daniel, H., Structure and composition of pleural plaques, in *Biological Effects of Asbestos*, International Agency for Research on Cancer, Lyon, 1973, 249.
181. Lemeunanger, J., Rousselot, P., Mandard, J. C., Le Bouffant, L., and Borel, B., Les pleurésies hénignes de l'asbeste, *Rev. Fr. Mal. Respir.*, 4 (Suppl. 2), 75, 1976.

DOW 07453

ST0005953

182. Churg, A., Asbestos fibers and pleural plaques in an autopsy population. *Am. Rev. Respir. Dis.*, 123, 135, 1981.
183. Perrin, B., Viglioni, E. C. and Selikoff, I. J., Rheumatoid factor in serum of individuals exposed to asbestos. *Ann. N.Y. Acad. of Sci.*, 132, 112, 1965.
184 Turner Warwick, M. and Parkes, W. R., Circulating rheumatoid and antinuclear factors in asbestos workers. *Br. Med. J.*, 3, 492, 1970.
185. Navratil, M., Pleural calcifications due to asbestos exposure compared with relevant findings in the non-exposed population, in *Inhaled Particles III*, Walton, W. H., Ed., Unwin Bros., Surrey, England, 1970, 695.
186. Zolov, C., Burilkov, T., and Babadjov, L., Pleural asbestosis in agricultural workers. *Environ. Res.*, 1, 287, 1967.
187. Navratil, M., Meravkova, K., and Trippe, F., Follow-up study of pleural hyalinosis in individuals not exposed to asbestos dust. *Environ. Res.*, 15, 108, 1978.
188 Rous, V. and Studeny, J., Aetiology of pleural plaques. *Thorax*, 25, 270, 1970.
189 Burilkov, T. and Michailova, L., Asbestos content of soil and endemic pleural asbestosis. *Environ. Res.*, 3, 443, 1970.
190. Cartier, P., Discussion on pleural plaques. *Ann. N.Y. Acad. Sci.*, 132, 387, 1965.
191. Hromek, J., Large scale incidence of characteristic pleural changes in the inhabitants of the western section of the former Jihlava region. *Rozhl. Tuberk.*, 22, 405, 1962.
192. Marsova, D., Beitrag zur Atiologie der Pleuraverkalkungen. *Z. Tuberk.*, 121, 329, 1964.
193 Kiviluoto, R., Pleural calcification as a roentgenologic sign of nonoccupational endemic anthophyllite asbestosis. *Acta Radiol.*, Supplementum 194, 1960.
194 Selikoff, I. J., The occurrence of pleural calcification among asbestos insulation workers. *Ann. N.Y. Acad. Sci.*, 132, 351, 1965.
195. Craighead, J. E., Abraham, J. L., Churg, A., Green, F. H. Y., Kleinerman, J., Pratt, P. C., Seemayer, T. A., Vallyathan, V., and Weill, H., The pathology of asbestos-associated disease of the lungs and pleural cavities: diagnostic criteria and proposed grading schema. *Arch. Pathol. Lab. Med.*, 106, 544, 1982.
196. Selikoff, I. J., Hammond, E. C., and Seidman, H., Mortality experience of insulation workers in the United States and Canada 1943 to 1976. *Ann. N.Y. Acad. Sci.*, 330, 91, 1979.
197 Kannerstein, M., Churg, J., and McCaughey, W. T. E., Asbestos and mesothelioma: a review. *Pathol. Annu.*, 13, 81, 1978.
198 Elmes, P. C. and Simpson, M. J. C., The clinical aspects of mesothelioma. *Q. J. Med.*, 45, 427, 1976.
199 Milne, J. E. H., Thirty-two cases of mesothelioma in Victoria, Australia: a retrospective survey related to occupational asbestos exposure. *Br. J. Ind. Med.*, 33, 115, 1976.
200. Newhouse, M. L., Berry, G., Wagner, J. C., and Turok, M. E., A study of the mortality of female asbestos workers. *Br. J. Ind. Med.*, 29, 134, 1972.
201. Wagner, J. C., Munday, E. E., and Harington, J. S., Histochemical demonstration of hyaluronic acid in pleural mesotheliomas. *J. Pathol. Bact.*, 84, 73, 1962.
202. Bohlig, H., Dabbert, A. F., Dalquen, P., Hain, E., and Hinz, I., Epidemiology of malignant mesothelioma in Hamburg. *Environ. Res.*, 3, 365, 1970.
203. Newhouse, M. L. and Thompson, H., Mesothelioma of pleura and peritoneum following exposure to asbestos in the London area. *Br. J. Ind. Med.*, 22, 261, 1965.
204. Anderson, H. A., Lilis, R., Daum, S. M., Fischbein, A. S. and Selikoff, I. J., Household-contact asbestos neoplastic risk. *Ann. N.Y. Acad. Sci.*, 271, 311, 1976.
205. Meurman, L. O., Kiviluoto, R., and Hakama, M., Mortality and morbidity among the working population of anthophyllite asbestos miners in Finland. *Br. J. Ind. Med.*, 31, 105, 1974.
206. Wagner, J. C., Sleggs, C. A., and Marchand, P., Diffuse pleural mesothelioma and asbestos exposure in Northwestern Cape Province. *Br. J. Ind. Med.*, 17, 260, 1960.
207. Kannerstein, M. and Churg, J., Peritoneal mesothelioma. *Human Pathol.*, 8, 83, 1977.
208. Edge, J. R. and Choudhary, S. L., Malignant mesothelioma of the pleural in Barrow-in-Furness. *Thorax*, 33, 26, 1978.
209 Roberts, G. A., Distant visceral metastasis in pleural mesothelioma. *Br. J. Dis. Chest*, 70, 246, 1976.
210. Whitwell, F. and Rawcliffe, R. M., Diffuse malignant pleural mesothelioma and asbestos exposure. *Thorax*, 26, 6, 1971.
211. Harwood, T. R., Gracey, D. R. and Yobas, H., Pseudomesotheliomatous carcinoma of the lung. *Am. J. Clin. Pathol.*, 65, 159, 1976.
212. Kannerstein, M., Churg, J., and Magner, D., Histochemistry in the diagnosis of malignant mesothelioma. *Ann. Clin. Lab. Sci.*, 3, 207, 1973.
213. Kannerstein, M., McCaughey, W. T. E., Churg, J., and Selikoff, I. J., A critique of the criteria for the diagnosis of diffuse malignant mesothelioma. *Mt. Sinai J. Med.*, 44, 485, 1979.

DOW 07454

EST0005956

214. Waxler, B., Eisenstein, R., and Battifora, H., Electrophoresis of tissue glycosaminoglycans as an aid in the diagnosis of mesotheliomas, *Cancer*, 44, 221, 1979.
215. Arai, H., Kang, K-Y., Sato, H., Satoh, K., Nagai, H., Motomiya, M., and Kono, K., Significance of the quantification and demonstration of hyaluronic acid in tissue specimens for the diagnosis of pleural mesothelioma, *Am. Rev. Respir. Dis.*, 120, 529, 1979.
216. Corson, J. M. and Pinkus, G. S., Mesothelioma: profile of keratin proteins and carcinoembryonic antigen-immunoperoxidase study of 20 cases and comparison with pulmonary adenocarcinoma, *Am. J. Pathol.*, 108, 80, 1982.
217. Martinchaig, K. M., Newell, D. J., Barnsley, W. C., Cowan, W. K., Feinmann, E. L., and Oliver, E., Unsuspected exposure to asbestos and bronchogenic carcinoma, *Br. Med. J.*, 1, 746, 1977.
218. Weill, M., Hughes, J., and Waggenspack, G., Influence of dose and fiber type on respiratory malignancy risk in asbestos cement manufacturing, *Am. Rev. Respir. Dis.*, 120, 345, 1979.
219. McDonald, J. C., Liddell, F. D. K., Gibbs, G. W., Eyssen, G. E., and McDonald, A. D., Dust exposure and mortality in chrysotile mining, *Br. J. Ind. Med.*, 37, 11, 1980.
220. Buchanan, W. D., Asbestosis and primary intrathoracic neoplasms, *Ann. N.Y. Acad. Sci.*, 132, 507, 1965.
221. Newhouse, M. L., Asbestos in the work place and the community, *Ann. Occup. Hyg.*, 16, 97, 1973.
222. McDonald, J. C., Asbestos and lung cancer: has the case been proven?, *Chest*, 78, 374, 1980.
223. Whitwell, F., Newhouse, M. L., and Bennett, D. R., A study of the histological cell types of lung cancer in workers suffering from asbestosis in the United Kingdom, *Br. J. Ind. Med.*, 31, 298, 1974.
224. Saracci, R., Asbestos and lung cancer: an analysis of the epidemiological evidence on the asbestos-smoking interaction, *Int. J. Cancer*, 20, 323, 1977.
225. Hammond, E. C., Selikoff, I. J., and Seidman, H., Asbestos exposure, cigarette smoking and death rates, *Ann. N.Y. Acad. Sci.*, 330, 473, 1979.
226. Selikoff, I. J., Hammond, E. C., and Churg, J., Asbestos exposure, smoking and neoplasia, *JAMA*, 204, 100, 1968.
227. Hueper, W. C., Occupational and environmental cancer of respiratory tract, *Recent Results Cancer Res.*, 3, 43, 1966.
228. Jacob, G. and Anspach, M., Pulmonary neoplasia among Dresden asbestos workers, *Ann. N.Y. Acad. Sci.*, 132, 536, 1965.
229. Heurihane, D. O'B. and McCaughey, W. T. E., Pathological aspects of asbestosis, *Postgrad. Med. J.*, 42, 613, 1966.
230. Gelfand, M. and Morton, S. A., Asbestosis in Rhodesia, in *Pneumoconiosis. Proc. Int. Conf., Johannesburg, 1969*, Shapiro, H. A., Ed., Oxford University Press, Cape Town, 1970, 204.
231. McMillan, G. H. G., Sheers, G., and Pethybridge, R., A radiological follow-up study of the effect of asbestos in dockyard workers in Devonport, *J. R. Naval Med. Serv.*, 64, 88, 1978.
232. Murphy, R. L. H., Gaensler, E. A., Ferris, B. G., Fitzgerald, M., Selliday, N., and Morrisey, W., Diagnosis of asbestosis. Observations from a longitudinal survey of shipyard pipe coverers, *Am. J. Med.*, 65, 488, 1978.
233. Green, F. H. Y. and Attfield, M., Pathology standards for asbestosis, *Scand. J. Work. Environ. Health*, 9, 162, 1983.
234. Commins, B. T. and Gibbs, G. N., Contaminating organic material in asbestos, *Br. J. Cancer*, 23, 358, 1969.
235. Roe, F. J. C., Walters, M. A., and Harington, J. S., Tumour initiation by natural and contaminating asbestos oils, *Int. J. Cancer*, 1, 491, 1966.
236. Wagner, J. C. and Berry, G., Mesotheliomas in rats following inoculation with asbestos, *Br. J. Cancer*, 23, 567, 1969.
237. Harington, J. S., Chemical factors (including trace elements) in etiological mechanisms, in *Biological Effects of Asbestos*, International Agency for Research on Cancer, Lyon, 1973, 304.
238. Gross, P., The locus of pathogenicity of asbestos dust, *Arch. Environ. Health*, 27, 240, 1973.
239. Wagner, J. C., Berry G., and Skidmore, J. W., Studies of the Carcinogenic Effects of Fiber Glass of Different Diameters Following Intrapleural Inoculation in Experimental Animals, in Occupational Exposure to Fibrous Glass, HEW Publ. No. (NIOSH) 76-151, U. S. Department of Health Education and Welfare, Washington, D.C., 1976, 193.
240. Pott, F., Huth, F., and Friedrichs, K. H., Results of Animal Carcinogenesis Studies after Application of Fibrous Glass and their Implications Regarding Human Exposure, in Occupational Exposure to Fibrous Glass, HEW Publ. No. (NIOSH) 76-151, U. S. Department of Health Education and Welfare, Washington, D.C., 1976, 183.
241. Wagner, J. C., The significance of asbestos in tissue, *Recent Results Cancer Res.*, 39, 37, 1972.
242. Baris, Y. I., Sahin, A. A., Ozesmi, M., Kerse, I., Ozen, E., Kolac, An. B., Altinors, M., and Gelenpel, A., Outbreak of pleural mesothelioma and chronic fibrosing pleurisy in village of Karain-Urgup in Anatolia, *Thorax*, 33, 181, 1978.

DOW 07455

243. Rohl, A. N., Langer, A. M., Moncure, G., Selikoff, I. J., and Fischbein, A., Endemic pleural disease associated with exposure to mixed fibrous dust in Turkey. *Science*, 216, 518, 1982.
244. Bryson, G. and Bischoff, F., Silicate-induced neoplasms. *Prog. Exp. Tumour Resp.*, 9, 77, 1967.
245. Gross, P., Manmade vitreous fibers: present status of research on health effects. *Int. Arch. Occup. Environ. Health.*, 50, 103, 1982.
246. Leineweber, J. P., Solubility of Fibers in Vitro and In Vivo. Occupational Health Conf., Copenhagen, April 20 to 22, 1982. Programme and Abstracts. Regional Office for Europe. World Health Organization, Copenhagen, 1982.
247. Klingholz, R. and Steinkopf, B., The Reactions of MMMF in a Physiological Model Fluid and in Water, Occupational Health Conf., Copenhagen, April 20 to 22, 1982. Programme and Abstracts. Regional Office for Europe. World Health Organization, Copenhagen, 1982.
248. Allison, A. C., Mechanisms of macrophage damage in relation to the pathogenesis of some lung diseases, in *Lung Biology in Health and Disease*, Vol. 5, *Respiratory Defense Mechanisms* (Part II), Brain, J. D., Proctor, D. F. and Reid, L. M., Eds., Marcel Dekker, New York, 1977, 1075.
249. Harington, J. S., Allison, A. C., and Badami, D. V., Mineral fibers: chemical, physicochemical and biological properties, *Adv. Pharmacol. Chemother.*, 12, 291, 1975.
250. Davies, P., Allison, A. C., Ackerman, J., Butterfield, A., and Williams, S., Asbestos induces selective release of lysosomal enzymes from mononuclear phagocytes, *Nature (London)*, 251, 423, 1974.
251. Richards, R. J. and Wasteman, F. S., The effects of silica dust and alveolar macrophages on lung fibroblast grown in vitro, *Life Sci.*, 14, 355, 1974.
252. Wagner, J. C., Berry, G., Skidmore, J. W., and Timbrell, V., The effect of the inhalation of asbestos in rats, *Br. J. Cancer*, 29, 252, 1974.
253. Reeves, A. L., Pure, H. E., Smith, R. G., and Verwald, A. J., Experimental asbestos carcinogenesis, *Environ. Res.*, 4, 496, 1971.
254. Maltoni, C., and Annoscia, C., Mesotheliomas in Rats Following the Intraperitoneal Injection of Crocidolite. Characterization of Human Tumors, Int. Symp. Biological Characterization of Human Tumors, Bologna, April 4 to 6, 1973.
255. Pott, F. and Friedricha, K. H., Tumoren der Ratten Nach I. P. Injektion faser formiger Staube, *Naturwissenschaften*, 59, 318, 1972.
256. Pott, F., Huth, F., and Friedricha, K. H., Tumorigenic effect of fibrous dusts in experimental animals, *Environ. Health Perspect.*, 9, 1974.
257. Pott, E. F., Huth, F., and Friedricha, K. H., Rat tumors after intraperitoneal injection of ground chrysotile asbestos and benzo(a)pyrene, *Zentralbl. Bakteriol., Parasitenk., Infektionskr. Hyg. Abt I Orig. Reihe B*, 155, 463, 1972.
258. Wagner, J. C., Berry, G., and Timbrell, V., Mesotheliomas in rats after inoculation with asbestos and other materials, *Br. J. Cancer*, 28, 173, 1973.
259. Stanton, M. F., Some aetiological considerations of fibre carcinogenesis, in *Biological Effects of Asbestos*, International Agency for Research on Cancer, Lyon, 1973, 284.
260. Lynch, K. M., McIver, F. A., and Cain, J. R., Pulmonary tumours in mice exposed to asbestos dust, *Arch. Ind. Health*, 15, 207, 1957.
261. Reeves, A. L., Pure, H. E., and Smith, R. G., Inhalation carcinogenesis from various forms of asbestos, *Environ. Res.*, 8, 178, 1974.
262. Gross, P., deTreville, R. T. P., Tolker, B., Kaschak, M., and Babyak, M. A., Experimental asbestosis. The development of lung cancer in rats with pulmonary deposits of chrysotile asbestos dust, *Arch. Environ. Health*, 15, 345, 1967.
263. Miller, L., Smith, W. E., and Berlinger, S. W., Tests for effect of asbestos on benzo(a)pyrene carcinogenesis in the respiratory tract, *Ann. N.Y. Acad. Sci.*, 132, 489, 1965.
264. Vosame, A., in *International Agency for Research on Cancer, Annu. Rep. 1971*, Lyon, 1972, 46.
265. Pylev, L. N., Morphological lesions in rat lungs induced by intratracheal injection of chrysotile asbestos alone and with benzo(a)pyrene, *Vopr. Onkol.*, 18, 40, 1972.
266. Pylev, L. N. and Shabad, L. M., Some results of experimental studies in asbestos carcinogenesis, in *Biological Effects of Asbestos*, International Agency for Research on Cancer, Lyon, 1973, 99.
267. Shabad, L. M., Pylev, L. N., Krivanoseva, L. V., Kulagina, T. F., and Nemenko, B. A., Experimental studies on asbestos carcinogenicity, *J. Natl. Cancer Inst.*, 52, 1175, 1974.
268. Mason, T. J., Cancer mortality in U. S. counties with plastics and related industries, *Environ. Health Perspect.*, 11, 79, 1975.
269. Multineri, A. and Venerandi, T., Natural and synthetic fibers as causes of asthma and rhinitis, *Ann. Allerg.*, 41, 48, 1978.
270. Vobecky, J., Devroede, G., Lacaille, J., and Weber, A., An occupational group with a high risk of large bowel cancer, *Gastroenterology*, 75, 221, 1978.
271. Valic, F. and Zuskin, E., Respiratory-function changes in textile workers exposed to synthetic fibers, *Arch. Environ. Health*, 32, 283, 1977.

DOW 07456

EST0005956

272. Tiller, J. R., An investigation of byssinosis in a rayon mill, *Trans. Assoc. Ind. Med. Off.*, 7, 157, 1958.
273. Tiller, J. R. and Schilling, R. S. F., Respiratory function during the day in rayon workers: a study in byssinosis, *Trans. Assoc. Ind. Med. Off.*, 7, 161, 1958.
274. Boubays, A., Fibers and fibrosis, *Ann. Intern. Med.*, 83, 898, 1975.
275. Pimentel, J. C., Avila, R., and Lourenco, A. G., Respiratory disease caused by synthetic fibers: a new occupational disease, *Thorax*, 30, 204, 1975.
276. Massoud, A. A. E. and Taylor, G., Byssinosis: antibody to cotton antigens in normal subjects and in cotton cardroom workers, *Lancet*, 2, 607, 1964.
277. Taylor, G., Massoud, A. A. E., and Lucas, F., Studies on the aetiology of byssinosis, *Br. J. Ind. Med.*, 28, 143, 1971.
278. Textile Research Institute, Methods of measuring the particle sizes of respirable dusts: a review of the literature with special emphasis on fibrous dust, Rep. No. 5, Princeton, N.J., 1980.

DOW 07457