Review Article

Medical Progress

RENAL-CELL CARCINOMA

ROBERT J. MOTZER, M.D., NEIL H. BANDER, M.D., AND DAVID M. NANUS, M.D.

RENAL-CELL carcinoma is characterized by a lack of early-warning signs (which results in a high proportion of patients with metastases), diverse clinical manifestations, and resistance to radiotherapy and chemotherapy, and there is a potential role for immunomodulation in the inhibition of tumor growth. In this review we discuss recent developments in epidemiology, histologic classification, tumor biology, methods of diagnosis and staging, surgical techniques, and immunotherapy for patients with metastatic disease.

EPIDEMIOLOGY

Renal-cell carcinoma accounts for **2** percent of **all** cancers.' Its incidence varies among countries by a factor of **20** among men and by a factor of 10 among women, with the highest rates in North Americans and Scandinavians.2 It is estimated that there will be **30,600** new diagnoses of kidney cancer and **12,000** deaths fiom the disease in the United States during 1996.3Worldwide mortality from kidney cancer is expected to exceed **100,000** in the year ***2000.4***

Renal-cell carcinoma originates in the renal cortex and accounts for 80 to **85** percent of malignant kidney tumors.' Other histologic types include transitional-cell carcinoma of the renal pelvis, making up **15** to **20** percent of kidney cancers in adults, and Wilms' tumor (nephroblastoma) in children.'

Renal-cell carcinoma occurs nearly twice as often in men as in women, and in the United States its incidence is equivalent among whites and blacks.' Patients are generally more than 40 years old at diagnosis, and the disease occurs predominantly in the seventh and eighth decades of life.[1] A 40-year-old man's lifetime risk of renal-cell carcinoma is **1.27** percent, and the risk of death is **0.51** percent.'

The incidence of renal-cell carcinoma has been rising steadily, increasing 38 percent from **1974** through **1990** (Fig. 1).[1] The increase has been accompanied by a small but significant improvement in five-year survival, from **52** percent among patients with disease diagnosed between **1974** and **1976** to 58 percent among patients with disease diagnosed between **1983** and 1989.[1] Both these trends appear to be due to improved capability of diagnosis. Kidney tumors are detected more frequently by the newer radiologic techniques, and at lower stages, when they can be resected for cure.

A recent international case–control study has provided new insight into the causative role of environmental factors.[5-9] Cigarette smoking doubles the likelihood of renal-cell carcinoma and contributes to as many as one third of all cases.[10,11] Obesity is **also** a risk factor, particularly in women, in whom there is a linear relation between increasing body weight and the increased risk of renal-cell carcinoma.[7,12] Additional factors associated with the development of the disease include hypertension, treatment for hypertension, or both[11]; unopposed estrogen therapy[6]; and occupational exposure to petroleum products, heavy metals, or asbestos.[8] The risk of renal-cell carcinoma has **also** been reported to be increased in patients with acquired cystic kidney disease associated with chronic renal insufficiency13and tuberous sclerosis.[14]

In most cases, renal-cell carcinoma occurs without a recognizable hereditary pattern. Having a first-degree family member with a diagnosis of renal-cell carcinoma increases the risk fourfold, but only a small fraction of patients have an affected family member.[15] Several rare familial forms are characterized by autosomal dominant inheritance, young age at diagnosis (the third to **fifth** decades), and bilateral and multifocal tumors.[16,17]

Von Hippel–Lindau disease is a familial multiple-cancer syndrome in which there is a predisposition to a variety of neoplasms, including renal-cell carcinomas (with clear-cell histology) and renal cysts, retinal hemangiomas, hemangioblastomas of the cerebellum and spinal cord, pheochromocytomas, and pancreatic carcinomas and cysts.[16] The disease is clinically heterogeneous, and in particular, differences in patients' susceptibility to pheochromocytoma have been noted.[16] Renal cysts are frequently multiple and bilateral, often containing malignant

From the Genitourinary Oncology Service, Division of Solid Tumor Oncology, Department of Medicine, Memorial Sloan-Kettering Cancer Center (R.J.M., D.M.N.); the Department of Urology, New York Hospital (N.H.B.) and the Departments of Medicine (R.J.M., D.M.N.) and Urology (N.H.B.), Cornell University Medical College — all in New York. Address reprint requests to Dr. Motzer at Memorial Hospital, 1275 York Ave., New York, NY 10021.

©1996, Massachusetts Medical Society.

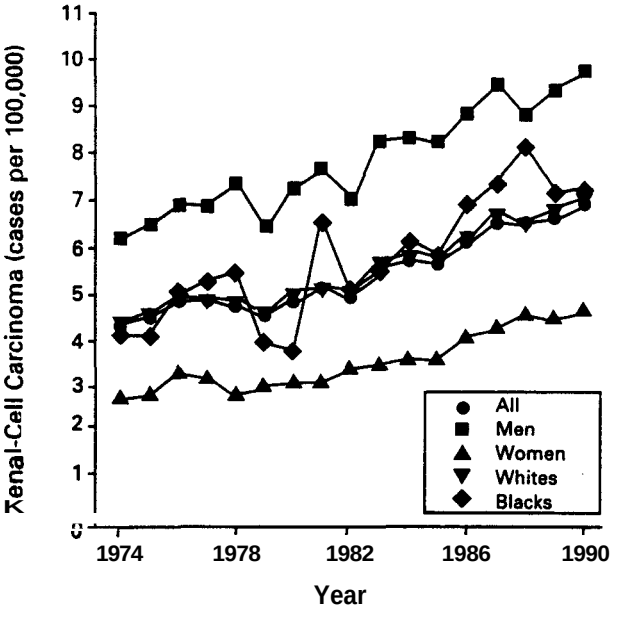

Figure 1. Trends in the Incidence of Renal-Cell Carcinoma in the United States.

Data are from the cancer statistics of the Surveillance, Epidemiology, and End Results Program.[1]

tumors. Renal-cell carcinoma develops in nearly 40 percent of patients with von Hippel–Lindau disease and is a major cause of death among these patients.[16]

Several kindreds with familial clear-cell carcinoma have a constitutional balanced translocation between the short arm of chromosome 3 (3p) and either chromosome 6 or chromosome 8.[17-19] Another hereditary form is characterized by multiple tumors of papillary histology that are not associated with chromosomal abnormalities of 3p.[20] Cytogenetic and molecular genetic analyses of such tumors have contributed substantially to our understanding of tumor pathogenesis.

TUMOR BIOLOGY AND HISTOGENESIS

Pathological Classification and Cytogenetics

Renal-cell carcinomas have historically been classified according to cell type (clear, granular, spindle, or oncocytic) and growth pattern (acinar, papillary, or sarcomatoid). This classification gave little insight into the clinical behavior of the carcinoma. A new histopathological classification of renal tumors was proposed in 1986, based on morphologic, histochemical, and electron-microscopical data21 and subsequently validated by cytogenetic and molecular studies (Table 1).[22-26] Five types of carcinomas are distinguished: clear-cell, chromophilic (papillary), chromophobic, oncocytic, and collecting-duct (Bellini's duct) tumors (the histologic features of these are reviewed by Weiss et al.[23] and Storkel and van den Berg[27]). Clear-cell carcinomas make up 75 to 85 percent of tumors and are characterized by a deletion of one or both copies of chromosome 3p.[28] A higher nuclear grade[23,29] or the presence of a sarcomatoid pattern[23,30] correlates with a poorer prognosis.

Chromophilic carcinomas comprise approximately 14 percent of renal cancers, are often multifocal and bilateral, and commonly present as small tumors (less than 3 cm in diameter).[31] These tumors do not contain 3p deletions32 but have monosomy Y, trisomy 7, and msomy 17.[33] Chromophilic tumors usually have a low stage at presentation, and the prognosis is more favorable than with clear-cell carcinomas.[31,34] Both clear-cell and chromophilic carcinomas originate from cells in the proximal tubule of the nephron[22,35] and express cell-surfice proteins normally found on such cells. The pattern of expression can further link the histogenesis of individual tumors to the proximal convoluted tubule, the pars recta, or a proximal-tubule progenitor cell.[35]

Approximately 4 percent of renal-cell cancers involve chromophobic carcinomas, which have a hypodiploid number of chromosomes[25,36] and multiple chromosomal losses, but no 3p loss.[26] Patients with these tumors generally have an excellent prognosis.[25,37] Renal oncocytomas are uncommon tumors that are only rarely associated with metastases.[38] Collecting-duct carcinomas are extremely rare23and clinically aggressive.[39] No reproducible genetic alterations have been identified that are characteristic of oncocytomas or collecting-duct tumors.

Molecular Genetic Abnormalities

Classic cytogenetic analyses of kindreds with familial clear-cell carcinoma have shown a translocation breakpoint on the short arm of chromosome 3.[18,19] Molecular genetic studies of this region in both familial and sporadic renal-cell carcinoma have often revealed chromosomal losses from 3p14 to 3p26.[28,40,41] The discovery that von Hippel–Lindau disease, which is characterized by a high incidence of bilateral renal-cell carcinoma, was also linked to chromosome 3p[42] allowed researchers to use DNA fiom affected families to identify the gene for von Hippel–Lindau disease at chromosome 3p25.[43] Analysis of this gene in sporadic renal-cell carcinomas of the clear-cell type revealed the loss of one allele in as many as 97 percent of tumors,[44,45] with frequent point mutations or transcriptional inactivation through hypermethylation of the remaining allele (Fig. 2).[44-46] These data suggest that the von Hippel–Lindau gene is a classic tumor-suppressor gene whose inactivation contributes to tumor development.

The von Hippel–Lindau gene is involved in controlling gene transcription. The protein it encodes inhibits the elongation of transcription by binding to elongin B and C, two regulatory subunits of a transcriptional elongation factor complex.[47,48] Rein-

TABLE 1. PATHOLOGICAL CLASSIFICATION OF **RENAL-CELL** CARCINOMA.

CARCINOMA TYPE	GROWTH PATTERN	CELL OF ORIGIN	CYTOGENETIC CHARACTERISTICS		INCIDENCE (%)
			MAJOR	MINOR	
Clear-cell	Acinar or sarcomatoid	Proximal tubule	3p−	+5, +7, +12, −6q, −8p, −9, −14q, −Y	75–85
Chromophilic*	Papillary or sarcomatoid	Proximal tubule	+7, +17, −Y	+12, +16, +20, −14	12–14
Chromophobic	Solid, tubular, or sarcomatoid	Intercalated cell Of cortical collecting duct†	Hypodiploid‡	—	4–6
Oncocytic	Typified by tumor nests	Intcrcaiated cell of cortical collecting duct	Undetermined§	—	2–4
Collecting-duct	Papillary or sarcomatoid	Medullary collecting duct	Undetermined§	—	1

*These tumors were previously classified as papillary tumors.

†This classification is based on the work of Storkel et al.[24]

‡Few chromophobic tumors have been characterized by cytogenetic analysis. Flow-cytometric analysis meals a hypodiploid chromosome number,[25] and molecular genetic studies have found multiple chromosomal losses.[26]

§Not enough tumors have been studied by cytogenetic analysis for the most frequent abnormalities to be determined accurately.

troducing the von Hippel–Lindau gene into cells affected by renal-cell carcinoma inhibits their growth[49] and the formation of tumor.[50]

Other regions of genetic loss have been identified in clear-cell carcinomas,[51,52] including a site on chromosome 3p that is distinct from the von Hippel–Lindau gene.[53,54] The presence of multiple genetic losses in clear-cell tumors is associated with a poor prognosis.[52,54]

Regulation of the Cell Cycle

The development of renal-cell carcinoma from normal renal epithelium may also involve alterations in genes whose products control cell division. These include genes that participate directly in controlling the cell cycle, such as the retinoblastoma (*Rb*) gene, the p53 tumor-suppressor gene, and the *ras* gene family, whose proteins are involved in communicating signals from outside the cell to the nucleus (signal transduction). Mutations of the p53 gene in primary renal-cell carcinomas are infrequent,[55-57] although p53 protein is expressed in approximately one third of such tumors[58,59] and may be associated with the development of metastatic disease.[59] Alterations in other cell-cycle genes, such as *Rb*[60,61] and the cyclin-dependent kinase inhibitors p21 and p16,[62,63] are infrequent. Mutations that activate the *ras* genes are rare,[64] but a downstream mediator of this signaling pathway may be activated.[65]

Increased expression of growth factors or their receptors may also enhance cellular replication in renal-cell carcinoma. In such carcinomas, overexpression of the epidermal growth factor receptor,[66,67] its ligand (transforming growth factor α),[66,68] and insulin-like growth factor receptors69 has been reported. Angiogenic growth factors, such as basic fibroblast growth factor and vascular endothelial growth factor, may contribute to the hypervascularity characteristically found in clear-cell carcinomas[70,71] and to the development of metastases,[72] and they may have prognostic importance.70 Elevated levels of the *myc* oncogene are found in a large proportion of sporadic renal cancers,[73] but they do not appear to be prognostic.[60] Abnormalities in known tumor-suppressor genes are infrequent[74-78] and do not appear to play a major part in the development of renal-cell carcinoma.

DIAGNOSIS

Clinical Presentation

Because of its multiple presenting signs and symptoms, renal-cell carcinoma has been called the "internist's tumor." Small, localized tumors rarely produce symptoms, however, and for this reason the diagnosis is often delayed until after the disease is advanced. The most common presentations are hematuria (in 50 to 60 percent of patients), abdominal pain (in 40 percent), and a palpable mass in the flank or abdomen (in 30 to 40 percent).[79] These three symptoms occur as a combination ("classic triad") in less than 10 percent of patients. Other signs and symptoms are relatively nonspecific — fever, night sweats, malaise, and weight loss. Two percent of male patients present with a varicocele, usually left-sided, due to obstruction of the testicular vein.[79]

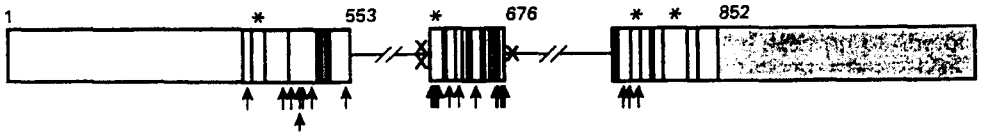

Figure 2. Mutations in the von Hippel–Lindau Gene in Sporadic Renal-Cell Carcinomas.

Sequence analysis of the von Hippel–Lindau gene in kindreds with von Hippel–Lindau disease revealed an array of mutations in the germ-line DNA. DNA analyses of tumor tissue from patients with sporadic clear-cell carcinomas showed that one copy of the von Hippel–Lindau gene was lost and that the remaining copy was mutated. The three cloned exons of the gene are indicated by boxes. The numbers refer to the length of the open reading frame and the locations of the intron breaks. Arrows denote nucleotide substitutions, and vertical lines within exons denote nucleotide deletions or insertions. Each asterisk is a nonsense mutation. and each X is a splice-site mutation. Modified from Gnarra et al.[44] with the permission of the publisher.

In recent years, the widespread application of computed tomography and ultrasonography for other indications has led to increased detection of renal-cell carcinoma as an incidental finding.[80] This is not surprising, given that two thirds of renal-cell carcinomas found in a series of patients studied at autopsy from 1958 to 1969 were not recognized clinically.81 At present, 25 to 40 percent of diagnoses are made after the detection of an incidental renal mass,[80,82,83] as compared with 10 percent or less before these imaging techniques came into common use.[79,82] Most important, tumors found incidentally are typically smaller than those that produce symptoms and are more likely to be resected for cure.[82-84]

One to 3 percent of tumors are bilateral. Twenty-five to 30 percent of patients have overt metastases at initial presentation. Frequent sites include the lung parenchyma (in 50 to 60 percent of patients with metastases), bone (in 30 to 40 percent), liver (in 30 to 40 percent), and brain (in 5 percent).[79] Unusual sites of metastases are characteristic of renal cancer, however, and virtually any organ site can be involved, including the thyroid, pancreas, skeletal muscle, and skin or underlying soft tissue. A broad range of paraneoplastic syndromes that are found in less than 5 percent of patients has been reported, including erythrocytosis, hypercalcemia, hepatic dysfunction (Stauffer's syndrome), and amyloidosis; these are reviewed by Ritchie and Chisholm.[79] Their causes include tumor-produced hormone-like substances (erythropoietin85 and parathyroid hormone–related protein[86]) and the formation of immune complexes (as in amyloidosis and nephropathy).[87] The presence of paraneoplastic syndromes does not necessarily imply that there is metastatic disease or contraindicate the resection of a localized tumor.

Evaluation of Renal Masses

Diagnostic imaging of renal masses has evolved beyond intravenous urography and angiography. Although the former remains useful in initial screening for hematuria, ultrasonography and dynamic intravenous contrast-enhanced computed tomography are more accurate in detecting and characterizing renal masses.[88,89] For tumors 3 cm in diameter or less, the sensitivities of urography, ultrasonography, and computed tomography have been quantified as 67 percent, 79 percent, and 94 percent, respectively." Arteriography is rarely used in diagnosis; it is performed mainly in selected cases for preoperative mapping of vasculature, primarily when nephron-sparing surgery is planned.

The accuracy of computed tomography in defining the extent of a tumor preoperatively (i.e., in determining the stage, as described below) is approximately 90 percent.[90] This technique has recognized limitations in the evaluation of minimally enlarged regional lymph nodes and of the degree of cephalad tumor extension into the vena cava. Although regional lymph nodes more than 2 cm in diameter are nearly always involved with metastases, lymph nodes 1 to 2 cm in diameter may be caused by either metastasis or reactive hyperplasia.[90,91] Therefore, the presence of lymph-node enlargement of this degree does not preclude surgical management.

Magnetic resonance imaging with intravenous gadolinium is superior to computed tomography in evaluating the inferior vena cava when tumor involvement is suspected.[92] Magnetic resonance imaging is also useful in detecting renal masses and in staging when contrast material cannot be administered intravenously, because of either allergy to such material or renal insufficiency.[93]

Simple, uncomplicated cysts, pseudotumors, and angiomyolipomas (renal hamartomas) have characteristic appearances when studied by ultrasonography and computed tomography; they can be diagnosed radiologically, and the patients generally do not require a biopsy.[94] Complicated cystic lesions can be categorized on the basis of their appearance on computed tomography, and confidence levels for the probability that they contain malignant elements can be assigned.[95] The computed tomographic detection of a central stellate scar within a homogeneous, well-circumscribed solid mass suggests the presence of an oncocytoma, but this finding is nonspecific and does not exclude the possibility of a clear-cell carcinoma.[38]

It must be emphasized that for their diagnosis, all

potentially malignant lesions require the procurement of tissue, which is obtained at surgery in patients with localized tumors. Although the majority of malignant tumors involving the kidney are renal-ccll carcinomas, the differential diagnosis includes squamous-cell and transitional-cell carcinomas (of the renal pelvis), Wilms' tumor, sarcoma, lymphoma, and metastatic carcinoma. Renal tumors smaller than 3 cm in diameter are often referred to as adenomas, but the distinction is controversial, and they should be treated in the same way as carcinomas.

SURGERY

Radical Nephrectomy

Surgical resection remains the cornerstone of treatment for renal-cell carcinoma. The radical nephrectomy, which includes a resection of kidney, perirenal fat, and ipsilateral adrenal gland, was widely adopted in the early 1960s.[96] The rationale for using this approach as compared with simple nephrectomy was based on the recognition that in some patients perinephric fat was involved; moreover, the philosophy prevailing at the time mandated the widest possible surgical margins. With better understanding of tumor biology and changing patterns of presentation, the value of adrenalectomy and lymphadenectomy is being reassessed.

Involvement of the ipsilateral adrenal gland has an overall incidence of approximately 4 percent and in most instances is associated with the direct extension of an upper-pole lesion or with advanced locoregional or metastatic disease.[97-99] It has been estimated that adjunctive adrenalectomy contributes to cure in less than 0.5 percent of patients.97 Since adrenal involvement can be identified preoperatively by computed tomography,[99] adrenalectomy may be reserved for patients with large upper-pole lesions, abnormal-appearing adrenal glands on computed tomography, or both.

The extent and benefit of lymphadenectomy remain controversial. In 10 to 20 percent of patients, nodal involvement is found at surgery without clinically evident distant metastases.[100-102] Virtually all such patients later relapse with distant metastases despite lymphadenectomy.[101] Although an occasional patient may be cured by resection of a lymph-node metastasis, in most patients the benefit of lymphadenectomy is limited to the prognostic information it provides.

Nephron-Sparing Surgery

Nephron-sparing surgery (partial nephrectomy) should be attempted in patients with bilateral tumors or cancer of an anatomically or functionally solitary kidney (an "absolute" indication) and in selected patients in whom the contralateral kidney is threatened by an associated disease, such as hypertension or diabetes mellitus (a "relative" indication). The rate of local recurrence in the partially resected kidney ranges from 4 to 10 percent[103-108] and reflects the fact that most patients treated in this manner had large tumors, multifocal tumors, or both. Nevertheless, these patients' overall survival is similar to that of patients with disease of similar stage who undergo radical nephrectomy.[109-111]

Because of these favorable results and the increased number of diagnoses of smaller tumors, nephron-sparing surgery has been used to treat patients who have small localized tumors and a normal contralateral kidney (an "elective" indication). The primary concern associated with this approach is that a multicentric renal-cell Carcinoma would go unrecognized, resulting in a recurrence of disease in the salvaged kidney or at the site of the resected lesion.[112] However, among selected patients with small, single tumors the proportion who have local recurrences is generally 2 percent or less (Table 2),[103-106,111,113] a percentage similar to the proportion of patients in whom a tumor in the contralateral kidney develops after radical nephrectomy.[114] These data support the use of nephron-sparing surgery in selected patients with small (≤4 cm) polar lesions and a normal contralateral kidney.

Vena Caval Involvement

Renal-cell carcinoma tends to invade the renal vein and the inferior vena cava, occasionally reaching

TABLE 2. RATES OF TUMOR RECURRENCE IN KIDNEYS TREATED BY NEPHRON-SPARING SURGERY, AS REPORTED IN VARIOUS STUDIES.

STUDY	MEDIAN FOLLOW-UP	INDICATION*	
		ABSOLUTE OR RELATIVE	ELECTIVE
	mo	no. of recurrences/total no. of patients (%)	
Morgan and Zincke[103]	59	6/98 (6)	0/20
Moll et al.[104]	42	2/47 (4)	0/105
Steinbach et al.[105]	54	3/49 (6)	2/72 (3)
Licht et al.[106]	38	9/199 (5)	1/17 (6)
Provet et al.[111]	36	4/25 (16)	0/19
Thrasher et al.[107]	40	2/42 (5)	0/6
Herr[113]	36	0/0	1/41 (2)
Novick et al.[108]	50	9/100 (9)	0/0
All	—	35/560 (6)	4/280 (1)

*An absolute indication for nephron-sparing surgery was defined as the presence of bilateral tumors or renal-cell carcinoma of a solitary kidney, a relative indication as the presence of an associated disease that threatened the function of the contralateral kidney, and an elective indication as the presence of a normal contralateral kidney.

the right atrium. In the absence of detectable metastases, about half of patients whose tumors extend into the vena cava can have prolonged survival after surgical resection.[115,116] Cardiopulmonary bypass with deep hypothermic cardiac arrest should be considered in the case of thrombi that extend cephalad in the vena cava beyond the hepatic veins. This approach allows the tumor and associated thrombus to be excised, with close visual examination of the atrium and caval lumen, decreasing the risk of sudden, life-threatening hemorrhage. The surgical excision of tumors with vena caval involvement is complex and should be undertaken in a specialized center; even then, the operative mortality ranges from 5 to 10 percent.[117,118]

Surgery in Patients with Metastatic Disease

Nephrectomy may be justified in selected patients with metastatic disease when the intention is to improve the quality of life, as by alleviating local symptoms. *Also,* when there is a solitary metastasis, its surgical resection is indicated in selected patients, given the five-year survival rate of approximately 30 percent.[119] However, patients who have solitary metastases at the time of their initial diagnosis generally do poorly, even when the primary and metastatic sites are both resected aggressively.[119]

Nephrectomy is not justifiable when the intention is to induce spontaneous tumor regression, because of the low incidence of such regression (<1 percent), the uncertainty about whether there is a causal link between the removal of the primary tumor and the spontaneous regression of metastases, and the morbidity and mortality associated with nephrectomy.[120] *Also,* the debulking of tumors before the start of systemic therapy is not general practice, because it has not been shown to improve the outcome of treatment and may preclude the administration of the systemic therapy.[121,122] Since obtaining complete resolution of the tumor at the primary site with systemic therapy is difficult, it may be preferable to consider nephrectomy after immunotherapy in highly selected patients who have had a major response, to assess the response fully and remove any residual viable tumor.

ASSIGNMENT OF STAGE AND PROGNOSIS

The most important determinant of survival is the anatomical extent of the tumor — that is, the pathologic stage. Patients with organ-confined disease that is resected completely generally have better outcomes than those with nodal involvement or distant metastases. Other prognostic indicators include histologic pattern, nuclear grade, and DNA content, but these are less established and influential than the tumor stage (as reviewed by Thrasher and Paulson[123]).

Two staging systems, that of the American Joint Committee on Cancer[124] and the modified Robson staging system,[96] are commonly used to define the extent of disease (Table 3). According to cancer-registry data, among 3307 patients with renal-cell carcinoma diagnosed in Illinois from 1975 through 1985, approximately 40 percent had stage I tumors at initial presentation, 10 percent had stage II tumors, 20 percent had stage III tumors, and 30 percent had stage IV tumors.[125]

Five-year survival ranges from 65 to 85 percent for patients with Robson stage I disease, from 45 to 80 percent for those with stage II disease, 15 to 35 percent for those with stage III disease, and 0 to 10 percent for those with stage IV disease.[119] The outcome of stage III cancers varies considerably, depending on whether there is vascular invasion or nodal involvement. In patients without regional nodal or distant metastatic disease, five-year survival approaches 50 percent after the complete resection of tumors associated with an extension into the renal vein. In contrast, less than one third of patients with regional nodal metastases survive five years.[125]

Twenty to 30 percent of patients with localized tumors relapse after radical nephrectomy.[126,127] Less than 5 percent have local recurrences, whereas lung metastases are the most common sites of distant relapse, occurring in 50 to 60 percent of patients.[126,127] The median time before a relapse after nephrectomy is 15 to 18 months, and 85 percent of relapses occur within 3 years.[126,127] In general, the longer the disease-free interval from diagnosis to the recognition of metastatic disease, the longer the survival. No recognized systemic therapy reduces the likelihood of relapse. Furthermore, radiation therapy is not beneficial after nephrectomy, even in patients with nodal involvement or incompletely resected tumors.[128]

SYSTEMIC THERAPY FOR ADVANCED DISEASE

Many types of systemic therapy have been studied to assess their effects against metastatic renal-cell carcinoma. The clinical method of evaluating the antitumor effect of a drug involves determining the proportion of patients who have an "objective" response, defined as either the complete disappearance of tumor (a complete response) or a reduction in the tumor burden by more than 50 percent (a partial response).

Hormonal and chemotherapeutic agents have little or no effect against renal-cell carcinoma.[129] The most extensively studied are vinblastine and floxuridine. Recent trials failed to demonstrate any antitumor effect for vinblastine.[129] Floxuridine may have minimal antitumor activity, but the responses are generally partial and relatively brief.[129] No chemotherapeutic agent has produced responses in proportions that justify its use as single-agent therapy. Therefore, the study of new agents is indicated in patients who have never had chemotherapy. Moreover, agents that reverse the multidrug resistance associated with P-gly-

TABLE 3. COMPARISON OF THE MODIFIED ROBSON STAGING SYSTEM FOR RENAL-CELL CARCINOMA WITH THE STAGING SYSTEM OF THE AMERICAN JOINT COMMITTEE ON CANCER:

EXTENT OF DISEASE	ROBSON	AMERICAN JOINT COMMITTEE ON CANCER			
		TUMOR	NODE	METASTASIS	STAGE
		score			
Confined to renal capsule					
Size, ≤2.5 cm	I	1	0	0	I
Size, >2.5 cm	I	2	0	0	II
Extending through renal capsule but confined to Gerota's fascia	II	3a	0	0	III
With renal-vein or caval involvement	III	3b, 3c	0	0	III
With regional nodal involvement					
Single node ≤2 cm	III	1–3a	1	0	III
More extensive	III	1–3a	2, 3	0	IV
With direct organ invasion	IV	4	Any	0	IV
With distant metastasis	IV	Any	Any	1	IV

*These systems are described more fully in Robson et al.[96] and the handbook of the American Joint Committee on Cancer.[124]

TABLE 4. RESULTS OF TREATMENT FOR ADVANCED RENAL-CELL CARCINOMA WITH INTERFERON AND INTERLEUKIN-2.

AGENT AND TYPE OF REGIMEN	NO. OF STUDIES	NO. OF PATIENTS	PERCENTAGE WITH RESPONSE*	REFERENCE
Interferon alfa	29	1042	12	Wirth[133]
Interferon beta	3	56	14	Wirth[133]
Interferon gamma	10	234	12	Wirth[133]
Interleukin-2				
High-dose, bolus	10	537	19	Law et al.[135]
Other inpatient	22	650	15	Law et al.[135]
Low-dose, outpatient	6	104	20	Law et al.[135]
Interferon plus interleukin-2	23	607	19	Vogelzang et al.[136]

*Dam include both complete and partial responses.

coprotein, including verapamil and cyclosporine, have not enhanced the antitumor effect of vinblastine in patients with metastatic renal-cell carcinoma.[129,130]

Modifiers of Biologic Response

Late relapses after nephrectomy, prolonged stabilization of disease in the absence of systemic treatment,[131] and rare spontaneous regressions[132] suggest that host immune mechanisms are important in regulating tumor growth and have fostered the study of immunotherapy[133-136] (Table 4).

The interferons have a direct antiproliferative effect on renal-tumor cells in vitro,[137] stimulate host mononuclear cells, and enhance the expression of major-histocompatibility-complex molecules. The overall proportion of responses to interferon alfa in 1042 patients was 12 percent.[133] Patients with prior nephrectomy and metastases predominantly located in the lung are more likely to have a response and to survive longer.[138,139] The proportion of objective responses has been reported to be as high as 30 percent among patients with these characteristics.[140] The average period from the start of treatment to the occurrence of an objective response is three to four months, and the response rarely lasts more than two years.[133] A dose range of 5 million to 20 million units of recombinant interferon alfa per day appears to have maximal efficacy and averts the greater toxic effects associated with higher doses.[141] Adding vinblastine to interferon alfa is no better than interferon alfa alone, and the toxicity is increased.[138,140,142] Interferon gamma has been studied less extensively and also shows low antitumor activity.[133]

Interleukin-2 affects tumor growth by activating lymphoid cells in vivo without affecting tumor proliferation directly. In the initial study by the National Cancer Institute, short intravenous infusions of high-dose interleukin-2 combined with autologous lymphocytes (lymphokine-activated killer cells) produced objective responses in over 30 percent of patient~.'~Subsequent studies showed that lymphokine-activated killer cells add no therapeutic benefit and can be eliminated from the treatment.[135] In a multicenter series of more than 250 patients treated with high-dose interleukin-2 alone, there were complete responses in 4 percent and partial responses in 8 percent.[143] Some responses were durable, however, and the median duration of response was 23 months.[143] Toxic effects associated with large bolus doses of interleukin-2 are related to increased vascular permeability and require inpatient monitoring, often in an intensive care unit. High-dose interleukin-2 has been associated with a 4 percent incidence of treatment-related death[143] and should be offered only to patients with normal cardiac, renal, and pulmonary function. More recently, similar proportions of responses were obtained with lower doses of subcutaneously administered interleukin-2 (Table 4).[135] The toxicity is considerably less, but whether the responses last as long as those obtained with the high-dose bolus schedule remains to be determined. The proportions of responses appear to be no better with combinations of interleukin-2 and interferon alfa than with interleukin-2 alone.[136]

Small numbers of patients have complete or partial responses to interferon, interleukin-2, or both, but their responses can be dramatic, with reduction of bulky tumors, and occasionally the responses are durable. Because most patients do not respond and have no clear evidence of improved survival, these

agents by themselves should not be considered effective treatments for renal-cell carcinoma, but should rather be viewed as indicating a direction for continued research. New combination regimens of interleukin-2, interferon alfa, and fluorouracil[144]; interferon alfa plus 13-*cis*-retinoic acid[145]; and interleukin-2 plus tumor-infiltrating lymphocytes[146] have promise but need to be assessed further in randomized trials, and the study of new biologic-response modifiers remains a priority.

Two aspects of patient care should be emphasized in view of the resistance of renal-cell carcinoma to systemic therapy. First, one option in asymptomatic patients is close surveillance, with systemic treatment delayed (and toxicity thus avoided) until symptoms appear or there is evidence of progression. Renal-cell carcinoma can have a protracted course; one prospective study of surveillance alone showed that over 10 percent of patients were free of progressive disease for more than one year after the detection of metastases.[131] Second, systemic therapy cannot be relied on to palliate symptoms (such as pain due to bone metastases) or treat complications (such as spinal cord compression); these must be managed with aggressive supportive care (i.e., with analgesia, irradiation, or surgery, as indicated).

FUTURE DIRECTIONS

The need for continued research in renal-cell carcinoma is highlighted by the fact that nearly half of patients — and more specifically, all but 5 to 10 percent of those with metastatic disease — die within five years of diagnosis.[1] Clearly, the causal factors must be defined further, with a focus on the prevention and early detection of tumors. In the past 10 years, studies of renal-cell carcinoma have improved our understanding of the molecular basis of renal cancers. Many questions remain unanswered, however, and translating the advances into improved therapies will require elucidating the cellular events that determine the clinical course.

A major obstacle to cure is the lack of effective treatment for patients at high risk for relapse or metastatic disease. Systemic therapy for renal-cell carcinoma should be administered, whenever possible, in the context of a clinical trial. Gene therapy[147,148] and treatment with new cytokines[149] and retinoids[145,150] have shown promise in preclinical models and warrant further investigation. The continued study of novel treatment strategies and the identification of new agents with better antitumor activity remain the highest priorities for clinical trials in patients with this refractory tumor.

We are indebted to Victor Reuter, M.D., Susan Hilton, M.D., Zuo-feng Zhang, M.D., Ph.D., and W. Marston Linehan, M.D., for their review of the manuscript.

REFERENCES

1. Kosary CL, McLaughlin JK. Kidney and renal pelvis. In: Miller BA, Ries LAG, Hankey BF, et al., eds. SEER cancer statistics review, 1973-1990. Bethesda, Md.: National Cancer Institute, 1993. (NIH publication no. 93-2789, XI.1-XI.22.)
2. Parkin DM, Pisani P, Ferlay J. Estimates of the worldwide incidence of eighteen major cancers in 1985. Int J Cancer 1993;54:594-606.
3. Cancer facts & figures — 1996. Atlanta: American Cancer Society, 1996.
4. Pisani P, Parkin DM, Ferlay J. Estimates of the worldwide mortality from eighteen major cancers in 1985: implications for prevention and projections of future burden. Int J Cancer 1993;55:891-903.
5. McCredie M, Pommer W, McLaughlin JK, et al. International renal-cell cancer study. II. Analgesics. Int J Cancer 1995;60:345-9.
6. Lindblad P, Mellemgaard A, Schlichofer B, et al. International renal-cell cancer study. V. Reproductive factors, gynecologic operations and exogenous hormones. Int J Cancer 1995;61:192-8.
7. Mellemgaard A, Lindblad P, Schlichohr B, et al. International renal-cell cancer study. III. Role of weight, height, physical activity and use of amphetamines. Int J Cancer 1995;60:350-4.
8. Mandel JS, McLaughlin JK, Schlichofer B, et al. International renal-cell cancer study. IV. Occupation. Int J Cancer 1995;61:601-5.
9. Wolk A, Gridley G, Niwa S, et al. International renal cell cancer study. VII. Role of diet. Int J Cancer 1996;65:67-73.
10. McLaughlin JK, Mandel JS, Blot WJ, Schuman LM, Mehl ES, Fraumeni JF Jr. A population-based case-control study of renal cell carcinoma. J Natl Cancer Inst 1984;72:275-84.
11. Yu MC, Mack TM, Hanisch R, Cicioni C, Henderson BE. Cigarette smoking, obesity, diuretic use, and coffee consumption as risk factors for renal cell carcinoma. J Natl Cancer Inst 1986;77:351-6.
12. Wolk A, Lindblad P, Adami H-O. Nutrition and renal cell cancer. Cancer Causes Control 1996;7:5-18.
13. Ishikawa I, Kovacs G. High incidence of papillary renal cell tumours in patients on chronic haemodialysis. Histopathology 1993;22:135-9.
14. Washecka R, Hanna M. Malignant renal tumors in tuberous sclerosis. Urology 1991;37:340-3.
15. Mellemgaard A, Engholm G, McLaughlin JK, Olsen JH. Risk factors for renal cell carcinoma in Denmark. I. Role of socioeconomic status, tobacco use, beverages, and family history. Cancer Causes Control 1994;5:105-13.
16. Lamiell JM, Salazar FG, Hsia YE. von Hippel-Lindau disease affecting 43 members of a single kindred. Medicine (Baltimore) 1989;68:1-29.
17. Cohen AJ, Li FP. Berg S, et al. Hereditary renal-cell carcinoma associated with a chromosomal translocation. N Engl J Med 1979;301:592-5.
18. Pathak S, Strong LC, Ferrell RE, Trindade A. Familial renal cell carcinoma with a 3;11 chromosome translocation limited to tumor cells. Science 1982;217:939-41.
19. Kovacs G, Brusa P, De Riese W. Tissue-specific expression of a constitutional 3;6 translocation: development of multiple bilateral renal-cell carcinomas. Int J Cancer 1989;43:422-7.
20. Zbar B, Tory K, Merino M, et al. Hereditary papillary renal cell carcinoma. J Urol 1994;151:561-6.
21. Thoenes W, Storkel S, Rumpelt HJ. Histopathology and classification of renal cell tumors (adenomas, oncocytomas and carcinomas): the basic cytological and histopathological elements and their use for diagnostics. Pathol Res Pract 1986;181:125-43.
22. van den Berg E, van der Hout AH, Oosterhuis JW, et al. Cytogenetic analysis of epithelial renal-cell tumors: relationship with a new histopathological classification. Int J Cancer 1993;55:223-7.
23. Weiss LM, Gelb AB, Medeiros LJ. Adult renal epithelial neoplasms. Am J Clin Pathol 1995;103:624-35.
24. Storkel S, Steart PV, Drenckhahn D, Thoenes W. The human chromophobe cell renal carcinoma: its probable relation to intercalated cells of the collecting duct. Virchows Arch B Cell Pathol Incl Mol Pathol 1989;56:237-45.
25. Akhtar M, Kardar H, Linjawi T, McClintock J, Ali MA. Chromophobe cell carcinoma of the kidney: a clinicopathologic study of 21 cases. Am J Surg Pathol 1995;19:1245-56.
26. Speicher MR, Schoell B, du Manoir S, et al. Specific loss of chromosomes 1, 2, 6, 10, 13, 17, and 21 in chromophobe renal cell carcinomas revealed by comparative genomic hybridization. Am J Pathol 1994;145:356-64.
27. Storkel S, van den Berg E. Morphological classification of renal cancer. World J Urol 1995;13:153-8.
28. Presti JC Jr, Rao PH, Chen Q, et al. Histopathological, cytogenetic, and molecular characterization of renal cortical tumors. Cancer Res 1991;51:1544-52.
29. Fuhrman SA, Lasky LC, Limas C. Prognostic significance of morphologic parameters in renal cell carcinoma. Am J Surg Pathol 1982;6:655-63.

30. Ro JY, Ayala AG, Sella A, Samuels ML, Swanson DA. Sarcomatoid renal cell carcinoma: clinicopathologic: a study of 42 cases. Cancer 1987;59: 516-26.
31. Mancilla-Jimenez R, Stanley RJ, Blath RA. Papillary renal cell carcinoma: a clinical, radiologic, and pathologic study of 34 cases. Cancer 1976; 38:2469-80.
32. Kovacs G, Wilkens L, Papp T, de Riese W. Differentiation between papillary and nonpapillary renal cell carcinomas by DNA analysis. J Nad Cancer Inst 1989;81:527-30.
33. Kovacs G, Fuzesi L, Emanual A, Kung HF. Cytogenetics of papillary renal cell tumors. Genes Chromosom Cancer 1991;3:249-55.
34. Sene AP, Hunt L, McMahon RF, Carroll RN. Renal carcinoma in patients undergoing nephrectomy: analysis of survival and prognostic factors. Br J Urol 1992;70:125-34.
35. Bander NH, Finstad CL, Cordon-Cardo C, et al. Analysis of a mouse monoclonal antibody that reacts with a specific region of the human proximal tubule and subsets of renal cell carcinomas. Cancer Res 1989;49: 6774-80.
36. Kovacs A, Kovacs G. Low chromosome number in chromophobe renal cell carcinomas. Genes Chromosom Cancer 1992;4:267-8.
37. Crotty TB, Farrow GM, Lieber MM. Chromophobe cell renal carcinoma: clinicopathological features of 50 cases. J Urol 1995;154:964-7.
38. Morra MN, Das S. Renal oncocytoma: a review of histogenesis, histopathology, diagnosis and treatment. J Urol 1993;150:295-302.
39. Kennedy SM, Merino MJ, Linchan WM, Roberts JR, Robertson CN, Neumann RD. Collecting duct carcinoma of the kidney. Hum Pathol 1990;21:449-56.
40. Zbar B, Brauch H, Talmadge C, Linchan M. Loss of alleles of loci on the short arm of chromosome 3 in renal cell carcinoma. Nature 1987;327: 721-4.
41. Maher ER, Yates JRW. Familial renal cell carcinoma: clinical and molecular genetic aspects. Br J Cancer 1991;63:176-9.
42. Seizinger BR, Rouleau GA, Ozelius LJ, et al. Von Hippel-Lindau disease maps to the region of chromosome 3 associated with renal cell carcinoma. Nature 1988;332:268-9.
43. Latif F, Tory K, Gnarra J, et al. Identification of the von Hippel-Lindau disease tumor suppressor gene. Science 1993;260:1317-20.
44. Gnarra JR, Tory K, Weng Y, et al. Mutations of the VHL tumour suppressor gene in renal carcinoma. Nat Genet 1994;7:85-90.
45. Foster K, Prowse A, van den Bug A, et al. Somatic mutations of the von Hippel-Lindau disease tumour suppressor gene in non-familial clear cell renal carcinoma. Hum Mol Genet 1994;3:2169-73.
46. Herman JG, Latif F, Weng Y, et al. Silencing of the VHL tumor-suppressor gene by DNA methylation in renal carcinoma. Proc Nad Acad Sci U S A 1994;91:9700-4.
47. Duan DR, Pause A, Burgess WH, et al. Inhibition of transcription elongation by the VHL tumor suppressor protein. Science 1995;269:1402-6.
48. Kibel A, Iliopoulos O, DeCaprio JA, Kaelin WG Jr. Binding of the von Hippel-Lindau tumor suppressor protein to Elongin B and C. Science 1995;269:1444-6.
49. Chen F, Kishida T, Duh FM, et al. Suppression of growth of renal carcinoma cells by the von Hippel-Lindau tumor suppressor gene. Cancer Res 1995;55:4804-7.
50. Iliopoulos O, Kibel A, Gray S, Kaelin WG Jr. Tumor suppression by the human von Hippel-Lindau gene product. Nat Med 1995;1:822-6.
51. Thrash-Bingham CA, Salazar H, Freed JJ, Greenberg RE, Tartof KD. Genomic alterations and instabilities in renal cell carcinomas and their relationship to tumor pathology. Cancer Res 1995;55:6189-95.
52. Moch H, Presti JC Jr, Sauter G, et al. Genetic aberrations detected by comparative genomic hybridization are associated with clinical outcome in renal cell carcinoma. Cancer Res 1996;56:27-30.
53. Brauch H, Pomer S, Hieronymus T, Schadt T, Lohrke H, Komitowski D. Genetic alterations in sporadic renal-cell carcinoma: molecular analyses of tumor suppressor gene harboring chromosomal regions 3p, 5q, and 17p. World J Urol 1994;12:162-8.
54. van den Berg A, Hulsbeek MMF, de Jong D, et al. Major role for a 3p21 region and lack of involvement of the t(3;8) breakpoint region in the development of renal cell carcinoma suggested by loss of heterozygosity analysis. Genes Chromosom Cancer 1996;15:64-72.
55. Uchida T, Wada C, Shitara T, Egawa S, Mashimo S, Koshiba K. Infrequent involvement of p53 mutations and loss of heterozygosity of 17p in the tumorigenesis of renal cell carcinoma. J Urol 1993;150:1298-301.
56. Imai Y, Strohmeyer TG, Fleischhacker M, Slamon DJ, Koeffler HI? p53 Mutations and MDM-2 amplification in renal cell cancers. Mod Pathol 1994;7:766-70.
57. Kikuchi Y, Kishi T, Suzuki M, Furusato M, Aizawa S. Polymerase chain reaction-single strand conformation polymorphism analysis of the p53 gene in paraffin-embedded surgical material from human renal cell carcinomas. Virchows Arch A Pathol Anat Histopathol 1994;424:229-33.
58. Bot FJ, Godschalk JC, Krishnadath KK, van der Kwast TH, Bosman FT. Prognostic factors in renal-cell carcinoma: immunohistochemical detection of p53 protein versus clinico-pathological parameters. Int J Cancer 1994;57:634-7.
59. Uhlman DL, Nguyen PL, Manivel JC, et al. Association of immunohistochemical staining for p53 with metastatic progression and poor survival in patients with renal cell carcinoma. J Natl Cancer Inst 1994;86: 1470-5.
60. Lipponen P, Eskelinen M, Syrjanen K Expression of tumour-suppressor gene Rb, apoptosis-suppressing protein Bcl-2 and c-Myc have no independent prognostic value in renal adenocarcinoma. Br J Cancer 1995;71: 863-7.
61. Walther MM, Gnarra JR, Elwood L, et al. Loss of heterozygosity occurs centromeric to RB without associated abnormalities in the retinoblastoma gene in tumors from patients with metastatic renal cell carcinoma. J Urol 1995;153:2050-4.
62. Shiohara M, el-Deiry WS, Wada M, et al. Absence of WAF1 mutations in a variety of human malignancies. Blood 1994;84:3781-4.
63. Cairns P, Tokino K, Eby Y, Sidransky D. Localization of tumor suppressor loci on chromosome 9 in primary human renal cell carcinomas. Cancer Res 1995;55:224-7.
64. Nanus DM, Mentle IR, Motzer RJ, Bander NH, Albino AP. Infrequent ras oncogene point mutations in renal cell carcinoma. J Urol 1990; 143:175-8.
65. Oka H, Chatani Y, Hoshino R, et al. Constitutive activation of mitogen-activated protein (MAP) kinases in human renal cell carcinoma. Cancer Res 1995;55:4182-7.
66. Mydlo JH, Michaeli J, Cordon-Cardo C, Goldenberg AS, Heston WD, Fair WR. Expression of transforming growth factor alpha and epidermal growth factor receptor messenger RNA in neoplastic and nonneoplastic human kidney tissue. Cancer Res 1989;49:3407-11.
67. Uhlman DL, Nguyen P, Manivel JC, et al. Epidermal growth factor receptor and transforming growth factor a expression in papillary and nonpapillary renal cell carcinoma: correlation with metastatic behavior and prognosis. Clin Cancer Res 1995;1:913-20.
68. Atlas I, Mendelsohn J, Baselga J, Fair WR, Masui H, Kumar R. Growth regulation of human renal carcinoma cells. role of transforming growth factor alpha. Cancer Res 1992;52:3335-9.
69. Kellerer M, von Eye Corleta H, Muhlhofer A, et al. Insulin- and insulin-like growth-factor-I receptor tyrosine-kinase activities in human renal carcinoma. Int J Cancer 1995;62:501-7.
70. Nanus DM, Schmitz-Drager BJ, Motzer RJ, et al. Expression of basic fibroblast growth factor in primary human renal tumors: correlation with poor survival. J Natl Cancer Inst 1993;85:1597-9.
71. Berger DP, Herbstritt L, Dengler WA, Marme D, Mertelsmann R, Fiebig HH. Vascular endothelial growth factor (VEGF) mRNA expression in human tumor models of different histologies. Ann Oncol 1995;6:817-25.
72. Fidler IJ. The biology of renal cancer metastasis. Semin Urol 1992;10: 3-11.
73. Yao M, Shuin T, Misaki H, Kubota Y. Enhanced expression of c-myc and epidermal growth factor receptor (C-erbB-1) genes in primary human renal cancer. Cancer Res 1988;48:6753-7.
74. Anglard P, Tory K, Brauch H, et al. Molecular analysis of genetic changes in the origin and development of renal cell carcinoma. Cancer Res 1991;51:1071-7.
75. Brooks JD, Bova GS, Marshall FF, Isaacs WB. Tumor suppressor gene allelic loss in human renal cancers. J Urol 1993;150:1278-83.
76. Kanayama H, Takigawa H, Kagawa S. Analysis of nm23 gene expressions in human bladder and renal cancers. Int J Urol 1994;1:324-31.
77. Walther MM, Anglard P, Gnarra J, et al. Expression of nm23 in cell lines derived from patients with metastatic renal cell carcinoma. J Urol 1995;154:278-82.
78. Suzuki Y, Tamura G, Maesawa C, Fujioka T, Kubo T, Satodate R. Analysis of genetic alterations in renal cell carcinoma using the polymerase chain reaction. Virchows Arch A Pathol Anat Histopathol 1994;424:453-7. [Erratum, Virchows Arch A Pathol Anat Histopathol 1994;425:335.]
79. Ritchie AWS, Chisholm GD. The natural history of renal carcinoma. Semin Oncol 1983;10:390-400.
80. Porena M, Vespasiani G, Rosi P, et al. Incidentally detected renal cell carcinoma: role of ultrasonography. J Clin Ultrasound 1992;20:395-400.
81. Hellsten S, Berge T, Whelin L. Unrecognized renal cell carcinoma: clinical and diagnostic aspects. Scand J Urol Nephrol 1981;15:269-72.
82. Konnack JW, Grossman HB. Renal cell carcinoma as an incidental finding. J Urol 1985;134:1094-6.
83. Thompson IM, Peek M. Improvement in survival of patients with renal cell carcinoma — the role of the serendipitously detected tumor. J Urol 1988;140:487-90.
84. Smith SJ, Rosniak MA, Megibow AJ, Hulnick DH, Horii SC, Raghavendra BN. Renal cell carcinoma: earlier discovery and increased detection. Radiology 1989;170:699-703.

85. Nseyo UO, Williams PD, Murphy GP. Clinical significance of erythropoietin levels in renal carcinoma. Urology 1986;28:301-6.
86. Gotoh A, Kitazawa S, Mizuno Y, et al. Common expression of parathyroid hormone-related protein and no correlation of calcium level in renal cell carcinomas. Cancer 1993;71:2803-6.
87. Cronin RE, Kaehny WD, Miller PD, et al. Renal cell carcinoma: unusual systemic manifestations. Medicine (Baltimore) 1976;55:291-311.
88. Warshauer DM, McCarthy SM, Street L, et al. Detection of renal masses: sensitivities and specificities of excretory urography/linear tomography, US, and CT. Radiology 1988;169:363-5.
89. Amendola MA, Brec RL, Pollack HM, et al. Small renal cell carcinomas: resolving a diagnostic dilemma. Radiology 1988;166:637-41.
90. Johnson CD, Dunnick NR, Cohan RH, Illescas FF. Renal adenocarcinoma: CT staging of 100 tumors. AJR Am J Roentgenol 1987;148:59-63.
91. Studer UE, Scherz S, Scheidegger J, et al. Enlargement of regional lymph nodes in renal cell carcinoma is often not due to metastases. J Urol 1990;144:243-5.
92. Semelka RC, Shoenut JP, Magro CM, Kroeker MA, MacMahon R, Greenberg HM. Renal cancer staging: comparison of contrast-enhanced CT and gadolinium-enhancing fat-suppressed spin-echo and gradient-echo MR imaging. J Magn Reson Imaging 1993;3:597-602.
93. Rofsky NM, Weinreb JC, Bosniak MA, Libes RB, Birnbaum BA. Renal lesion characterization with gadolinium-enhanced MR imaging: efficacy and safety in patients with renal insufficiency. Radiology 1991;180:85-9.
94. Bosniak MA. The small (C3.0 cm) renal parenchymal tumor: detection, diagnosis, and controversies. Radiology 1991;179:307-17. [Erratum, Radiology 1991;181:289.]
95. *Idem.* The current radiological approach to renal cysts. Radiology 1986;158:1-10.
96. Robson CJ, Churchill BM, Anderson W. The results of radical nephrectomy for renal cell carcinoma. J Urol 1969;101:297-301.
97. Sagalowsky AI, Kadesky KT, Ewalt DM, Kennedy TJ. Factors influencing adrenal metastasis in renal cell carcinoma. J Urol 1994;151:1181-4.
98. Shalev M, Cipolla B, Guille F, Staerman F, Lobel B. Is ipsilateral adrenalectomy a necessary component of radical nephrectomy? J Urol 1995;153:1415-7.
99. Gill IS, McClennan BL, Kerbl K, Carbone JM, Wick M, Clayman RV. Adrenal involvement from renal cell carcinoma: predictive value of computerized tomography. J Urol 1994;152:1082-5.
100. Giuliani L, Giberti C, Martorana G, Rovida S. Radical extensive surgery for renal cell carcinoma: long-term results and prognostic factors. J Urol 1990;143:468-74.
101. Phillips PE, Messing EM. Role of lymphadenectomy in the treatment of renal cell carcinoma. Urology 1993;41:9-15.
102. Herrlinger A, Schrott KM, Schott G, Sigel A. What are the benefits of extended dissection of the regional renal lymph nodes in the therapy of renal cell carcinoma. J Urol 1991;146:1224-7.
103. Morgan WR, Zincke H. Progression and survival after renal-conserving surgery for renal cell carcinoma: experience in 104 patients and extended followup. J Urol 1990;144:852-8.
104. Moll V, Becht E, Ziegler M. Kidney preserving surgery in renal cell tumors: indications, techniques and results in 152 patients. J Urol 1993;150:319-23.
105. Steinbach F, Stockle M, Muller SC, et al. Conservative surgery of renal cell tumors in 140 patients: 21 years of experience. J Urol 1992;148:24-9.
106. Licht MR, Novick AC, Goormastic M. Nephron sparing surgery in incidental versus suspected renal cell carcinoma. J Urol 1994;152:39-42.
107. Thrasher JB, Robertson JE, Paulson DF. Expanding indications for conservative renal surgery in renal cell carcinoma. Urology 1994;43:160-8.
108. Novick AC, Streem SB. Montie JE, et al. Conservative surgery for renal cell carcinoma: a single-center experience with 100 patients. J Urol 1989;141:835-9.
109. Marberger M, Pugh RCB, Auvert J, et al. Conservation surgery of renal carcinoma: the EIRSS experience. Br J Urol 1981;53:528-32.
110. Steinbach F, Stockle M. Hohenfellner R. Current controversies in nephron-sparing surgery for renal-cell carcinoma. World J Urol 1995;13:163-5.
111. Provet J, Tessler A, Brow J, Golimbu M. Bosniak M, Morales P. Partial nephrectomy for renal cell carcinoma: indications, results and implications. J Urol 1991;145:472-6.
112. Whang M, O'Toole K, Bixon R, et al. The incidence of multifocal renal cell carcinoma in patients who are candidates for partial nephrectomy. J Urol 1995;154:968-71.
113. Herr HW. Partial nephrectomy for renal cell carcinoma with a normal opposite kidney. Cancer 1994;73:160-2.
114. Saitoh H, Nakavama M, Nakamura K, Satoh T. Distant metastasis of renal adenocarcinoma in nephrectomized cases J Urol 1982;127:1092-5.
115. Skinner DG. Colvin RB, Vermillion CD, Pfister RC, Leadbetter WF. Diagnosis and management of renal cell carcinoma: a clinical and pathologic study of 309 cases. Cancer 1971;28:1165-77.
116. Cherrie RJ, Goldman DG, Lindner A, deKernion JB. Prognostic implications of vena caval extension of renal cell carcinoma. J Urol 1982;128:910-2.
117. Marshall FF, Dietrick DD, Baumgartner WA, Reitz BA. Surgical management of renal cell carcinoma with intracaval neoplastic extension above the hepatic veins. J Urol 1988;139:1166-72.
118. Novick AC. Current surgical approaches, nephron-sparing surgery, and the role of surgery in the integrated immunologic approach to renal-cell carcinoma. Semin Oncol 1995;22:29-33.
119. Couillard DR, deVere White RW. Surgery of renal cell carcinoma. Urol Clin North Am 1993;20:263-75.
120. McCaffrey JA, Motzer RJ. What is the role of nephrectomy in patients with metastatic renal cell carcinoma? Semin Oncol 1996;23:xix-xx.
121. Robertson CN, Linehan WM, Pass HI, et al. Preparative cytoreductive surgery in patients with metastatic renal cell carcinoma treated with adoptive immunotherapy with interleukin-2 or interleukin-2 plus lymphokine activated killer cells. J Urol 1990;144:614-8.
122. Rackley RR, Klein EA, Novick AD. Morbidity and mortality of primary adjuvant nephrectomy in immunotherapy for renal cell carcinoma. J Urol 1991;145:Suppl:422A. abstract.
123. Thrasher JB, Paulson DF. Prognostic factors in renal cancer. Urol Clin North Am 1993;20:247-62.
124. Beahrs OH, Henson DE, Hutter RVP, Kennedy BJ. Handbook for staging of cancer: from the manual for staging of cancer. 4th ed. Philadelphia: J.B. Lippincott, 1993.
125. Kidney cancer: a report by 97 Illinois hospitals on cases diagnosed in 1975-85. Report no. 12 of Results in treating cancer. Chicago: American Cancer Society, 1989.
126. Sandock DS, Seftel AD, Resnick MI. A new protocol for the followup of renal cell carcinoma based on pathological stage. J Urol 1995;154:28-31.
127. Rabinovitch RA, Zelefsky MJ, Gaynor JJ, Fuks Z. Patterns of failure following surgical resection of renal cell carcinoma: implications for adjuvant local and systemic therapy. J Clin Oncol 1994;12:206-12.
128. Kjaer M, Frederiksen PL, Engelholm SA. Postoperative radiotherapy in stage II and III renal adenocarcinoma: a randomized trial by the Copenhagen Renal Cancer Study Group. Int J Radiat Oncol Biol Phys 198753:665-72.
129. Yagoda A, Abi-Rached B, Petrylak D. Chemotherapy for advanced renal-cell carcinoma: 1983-1993. Semin Oncol 1995;22:42-60.
130. Motzer RJ, Lyn P, Fischer P, et al. Phase 1/11 trial of dexverapamil plus vinblastine for patients with advanced renal cell carcinoma. J Clin Oncol 1995;13:1958-65.
131. Oliver RT, Nethersell AB, Bottomley JM. Unexplained spontaneous regression and alpha-interferon as treatment for metastatic renal carcinoma. Br J Urol 1989;63:128-31.
132. Vogelzang NJ, Priest ER, Borden L. Spontaneous regression of histologically proved pulmonary metastases from renal cell carcinoma: a case with 5-year followup. J Urol 1992;148:1247-8.
133. Wirth MP. Immunotherapy for metastatic renal cell carcinoma. Urol Clin North Am 1993;20:283-95.
134. Rosenberg SA, Lotze MT, Muul LM, et al. A progress report on the treatment of 157 patients with advanced cancer using lymphokine-activated killer cells and interleukin-2 or high-dose interleukin-2 alone. N Engl J Med 1987;316:889-97.
135. Law TM. Motzer RJ. Mazumdar M, et al. Phase III randomized trial of interleukin-2 with or without lymphokine-activated killer cells in the treatment of patients with advanced renal cell carcinoma. Cancer 1995;76:824-32.
136. Vogelzang NJ, Lipton A, Figlin RA. Subcutaneous interleukin-2 plus interferon alfa-2a in metastatic renal cancer: an outpatient multicenter trial. J Clin Oncol 1993;11:1809-16.
137. Nanus DM, Pfeffer LM, Bander NH, Bahri S, Albino AI. Antiproliferative and antitumor effects of alpha-interferon in renal cell carcinomas: correlation with the expression of a kidney-associated differentiation glycoprotein. Cancer Res 1990;50:4190-4.
138. Minasian LM. Motzer RJ, Gluck L, Mazumdar M, Vlamis V, Krown SE. Interferon alfa-2a in advanced renal cell carcinoma: treatment results and survival in 159 patients with long-term follow-up. J Clin Oncol 1993;11:1368-75.
139. Fossa SD, Martinelli G, Otto U, et al. Recombinant interferon alfa-2a with or without vinblastine in metastatic renal cell carcinoma: results of a European multi-center phase III study. Ann Oncol 1992;3:301-5.
140. Neidhart JA, Anderson SA. Harris JE, et al. Vinblastine fails to im-

prove response of renal cancer to interferon alfa n1: high response rate in patients with pulmonary metastases. J Clin Oncol 1991;9:832-6.
141. Krown SE. Interferon treatment of renal cell carcinoma: current status and future prospects. Cancer 1987;59:647-51.
142. Fossa SD, Raabe N, Moe B. *Recombinant interferon-alpha with or* without vinblastine in metastatic renal carcinoma: results of a randomised phase II study. Br J Urol 1989;64:468-71.
143. Fyfe G, Fisher RI, Rosenberg SA, Sznol M, Parkinson DR, Louie A. Results of treatment of 255 patients with metastatic renal cell carcinoma who received high-dose recombinant interleukin-2 therapy. *J Clin Oncol* 1995;13:688-96.
144. Hänninen EL, Kirchner H, Atzpodien J. Interleukin-2 based home therapy of metastatic renal cell carcinoma: risks and benefits in 215 consecutive single institution patients. J Urol 1996;155:19-25.
145. Motzer RJ, Schwartz L, Law TM, et al. Interferon alfa-2a and 13-cis-retinoic acid in renal cell carcinoma: antitumor activity in a phase II trial and interactions in vitro. J Clin Oncol 1995;13:1950-7.
146. Pierce WC, Belldegrun A, Figlin RA. Cellular therapy: scientific rationale and clinical results in the treatment of metastatic renal cell carcinoma. Semin Oncol 1995;22:74-80.
147. Gastl G, Finstad CL, Guarini A, et al. Retroviral vector mediated *lymphokine gene transfer into human renal cancer cells.* Cancer Res 1992; 52:6229-36.
148. Belldegrun A, Tso CL, Sakata T, et al. Human renal carcinoma line transfected with interleukin-2 and/or interferon alpha genes: implications for live cancer vaccines. J Natl Cancer Inst 1993;85:207-16.
149. *Wiggimton JM, Komschlies KL, Back TC, Franco JL, Brunda MJ,* Wiltrout RH. Administration of interleukin 12 with pulse interleukin 2 and the rapid and complete eradication of murine renal carcinoma. J Natl Cancer Inst 1996;88:38-43.
150. Hoffman AD, Engelstein D, Bogenrieder T, et al. Expression of *retinoic acid receptor β in human renal cell carcinomas correlates with sensi*tivity to the antiproliferative effects of 13-*cis*-retinoic acid. Clin Cancer Res 1996;2:1077-82.



Stove, China

ALBERT R. FREDERICK, JR., M.D.