PLAINTIFF'S EXHIBIT

ASA-675

TESTS FOR CARCINOGENICITY OF ASBESTOS

Wm. E. Smith, Llonas Miller, R. E. Elsasser, D. D. Hubert

Reprinted from Annals of The New York Academy of Sciences
Volume 132, Article 1, Pages 456-488
December 31, 1965

ASARCO ELP 0002916

TESTS FOR CARCINOGENICITY OF ASBESTOS*

Wm. E. Smith, Llonas Miller, R. E. Elsasser, D.D. Hubert
Health Research Institute, Fairleigh Dickinson University
Madison, N. J.

Reports in this Annal and elsewhere associate exposure to asbestos with numerous cases of pulmonary carcinomas and mesotheliomas in man. Early observations on this association were reviewed by one of us.[1] Recently, Selikoff, Churg and Hammond[2] reported studies on a group of 632 insulaton workers exposed to asbestos for 20 or more years. In these men, pulmonary carcinomas were found at six times the expected incidence and carcinomas of the gastrointestinal tract at three times the expected incidence. Pleural mesothelioma, a rare tumor, was found in three men and peritoneal mesothelioma in another.

In contrast to statistical association between exposure to asbestos and development of cancer in man, a large literature on experimental studies has failed to furnish any definite evidence for induction of malignant tumors in animals exposed to various varieties and preparations of asbestos by inhalation or intratracheal injection. Recently, Wagner[3] reported mesotheliomas in rats after intrapleural injection of chrysotile and crocidolite varieties of asbestos, and our group reported fibrosis and development of mesothelioma in hamsters after intrapleural injection of the amosite variety of asbestos.[4] Detailed accounts of mesotheliomas in animals and associated tissue reactions have not as yet been presented. These are offered in the present paper together with reports of intratracheal and feeding tests with asbestos.

In extensive experimentation at the Saranac Laboratory, reviewed by Vorwald *et al.*,[5] and by others reviewed by Behrens,[6] no cancers were found in guinea pigs, rats, rabbits or cats examined after long-continued inhalation exposures or after long maintenance following one or two intratracheal injections. Nordman and Sorge[7] reported lung tumors in two mice after inhalation of chrysotile asbestos over a period of nine months. Their claim for induction of cancer with this material must be evaluated, however, with the consideration that one of the tumors reported by them was an adenomatous type not uncommon as a spontaneous tumor in mouse lungs, and their photograph of the other lesion leaves a question as to whether it may have been an area of squamous metaplasia rather than neoplasia. Lynch *et al.*[8] exposed mice to a commercial preparation of chrysotile asbestos by inhalation for 8 to 12 hours daily for five days per week

*This work was supported by U. S. Public Health Service Research Grant CA 07681 from the National Cancer Institute and by a grant from the Deering Milliken Foundation.

ASARCO ELP 0002917

beginning at two months of age and sacrificing for examination at 19 or 24 months of age. In 127 exposed mice compared to 222 controls, they found that the percentage of individuals bearing single pulmonary adenomas was the same (28 per cent) in both groups, but the percentage of individuals bearing multiple pulmonary adenomas was greater in exposed mice (18 per cent) than in the controls (8 per cent). They did not regard any of the tumors in their animals as carcinomas.

With known carcinogens, it has often been found that the latent period between first exposure and development of tumor can occupy a considerable proportion of the life span of a test species, and that this period increases with decrease in potency or dose of carcinogen. Tests for carcinogenicity of materials of weak or unknown potency must therefore extend over periods approximating the natural life span of the species selected for the test. The experiments by Lynch and his associates on mice were designed to meet this requirement. In the inhalation experiments by Vorwald and his associates, considerable numbers of guinea pigs and rats were observed over periods approximating their natural life spans. Long-term studies of this nature have not yet been reported for other species given experimental exposures to asbestos and sacrificed at relatively early periods for study of asbestosis.[9] A considerable period of years might be required for adequate tests in long-lived species such as cats, dogs or monkeys. In experiments reported by one of us and associates,[10] 1,373 days were required to induce cancer in the rhesus monkey with a highly carcinogenic petroleum derivative that elicited cancer within 411 days in rabbits and 70 days in mice. This same material did not elicit cancer in tests with rats or guinea pigs, an illustration of another aspect of tests for carcinogenicity i.e., variation in susceptibility of different species.

In designing tests to explore the question of carcinogenicity of asbestiform minerals, we therefore determined to utilize a species that had not been previously employed for the purpose, and that had a relatively short life span. The golden Syrian hamster met these requirements. Also, intratracheal injection proved to be conveniently accomplished in hamsters.

Characteristics of samples selected for the tests presented a further consideration. In contrast to increasing fibrogenicity of silica with decrease in particle size, it had been reported that intratracheal injections of chrysotile with average fiber length of 20 to 50 microns induced fibrosis in the lungs of guinea pigs but that the fibrogenic action of this material was lost when milled to average lengths of 3 microns or less.[3] It was therefore of interest to note that a principal sample used for inhalation exposures in the Saranac experiments was said to contain only 6.7 per cent of fibers longer than 10 microns and 20 per cent of particles described as "grains." The "grains" may not have been asbestos but dust from rock that had surrounded veins of asbestos in the deposits from which it had

ASARCO ELP 0002918

been mined. Other samples used in inhalation exposures by the Saranac group were said to have an even smaller content of fibrous asbestos. The sample used for the inhalation experiments by Lynch's group was said to be composed to the extent of 95.5 per cent of material that "appears to be mostly irregular pieces of granular serpentine rock." Intratracheal injections of long-fiber preparations of a variety of asbestiform minerals were done in the Saranac experiments with guinea pigs and rats, but these experiments were not designed to test for carcinogenicity and animals were sacrificed at relatively early times to study development of asbestosis.

A further requirement for tests for carcinogenicity of asbestos was therefore to prepare samples consisting principally of asbestos fibers freed insofar as possible of rock dust and other impurities. A method for this purpose was developed in this laboratory by Badollet and Gantt.[11] Since any effects of fiber lengths upon possible carcinogenicity may differ from effects upon fibrogenicity, preparations with a broad range of fiber lengths were employed for our animal tests.

A review of experimental studies of lung cancer has been published.[12] In the present work, pleural mesotheliomas were found in hamsters after intrapleural injection of amosite and of harsh chrysotile but not after intrapleural injection of soft chrysotile. Diagnosis of these tumors and comparison of them with mesotheliomas in man has been discussed elsewhere.[13] Tumors were also found in the gastrointestinal tract and liver of hamsters fed asbestos but these may have been spontaneous growths unrelated to asbestos. No tumors have as yet resulted from intratracheal injections of asbestos, but many animals injected by this route are still living. From necropsy findings in these experiments, some theoretical considerations arose in regard to genesis of tumors after exposure to asbestos. These will be discussed.

Methods

For intrapleural and intratracheal injections, soft chrysotile Sample 2, harsh chrysotile Sample 1 and amosite Sample 7 prepared by Badollet and Gantt[11] were used. Distribution of fibers in various size ranges in these samples are detailed in their paper. The per cent of fibers between 5 and 100 microns in these samples was 90, 92.5 and 87 per cent, respectively. Average fiber lengths were 67, 36 and 17.6 microns, respectively.

For feeding, new batches of soft chrysotile and of amosite were from time to time prepared with characteristics roughly approximating those of Sample 2 and Sample 7, respectively.

For intrapleural injection, the hair over the right chest was clipped away and the skin was swabbed with tincture of iodine and then with 70

ASARCO ELP 0002919

per cent alcohol. The right chest was stabbed six times with a sharp-pointed 25 gauge needle with object of inducing pneumothorax.[14] Two days later, injections were made with an 18 gauge needle. The bevel of this needle was ground short and rounded to favor deposition of inoculum in the pleural space rather than into the lung. As described in the text, the inoculum occasionally failed to be deposited in the pleural space and was found instead in the tissue of the chest wall, but in only one instance was there evidence that the inoculum had been inflated into the lung.

For intratracheal injection, the technique used by Herrold and Dunham[15] for hamsters was followed, using Nembutal anesthesia.

The hamsters were maintained on a commercial pelleted feed "GLF Diet for Hamsters," W. F. Fisher, Bound Brook N. J., supplemented with apples, carrots or spinach three times a week. Water was available ad libitum. When asbestos was added to the diet, the commercial feed was purchased as an unpelleted powder and one per cent of the asbestos sample was mixed into it, adding three per cent dextrin as a binder. The mix was moistened with water and molded into blocks which were dried overnight in an oven at 64°C. These blocks then replaced the commercial pellets in the daily regimen of hamsters designated to receive asbestos in their feed. Weight records of hamsters fed these blocks, supplemented with apples, carrots or spinach as above, showed gain and maintenance of body weight comparable to that of hamsters on the diet without asbestos.

For all experiments, male hamsters obtained from a commercial breeder (Lakeview Hamster Colony, Newfield, N. J.) who were about two months of age at the start of the tests were used. They were housed in open mesh cages. They were weighed biweekly. Animals exhibiting persisting loss of 20 per cent or more of body weight or who appeared moribund were sacrificed for examination. Otherwise, they were allowed to live out their natural life spans. At sacrifice or natural death, necropsies were performed that were complete except that the brain and nasal sinuses were not examined. The oropharynx and cheek pouches were inspected. The larynx, trachea and bronchi were opened by dorsal incision, and examined with the lungs under a dissecting microscope at 7 × magnification. Observations were recorded and tissues taken for histological examination. The right and left lungs were taken separately and routinely saved. They were cut vertically through the hilum except where tumors or other gross findings required additional blocks. Blocks of other tissues were taken where indicated by gross findings. In animals that had received asbestos in their diets, and in untreated controls, the esophagus was tied off and the stomach distended with 2 ml. formalin by a needle run in from the duodenum. As this needle was withdrawn, a ligature laid around the duodenum was pulled tight. The distended stomach was placed in formalin and subsequently bisected for examination by a cut along the lesser and greater

ASARCO ELP 0002920

curvatures. The small and large intestines, the cecum and rectum were opened, examined, coiled on cardboard for their full lengths and fixed.

All tissues were fixed in 10 per cent formalin containing 2 per cent sodium acetate. Hematoxylin and eosin were used for routine staining. Mallory's connective tissue stain was used for special studies. Amosite and harsh chrysotile fibers could often be seen in tissue sections by reduced illumination through closing the diaphragm of the microscope condenser. This procedure seldom revealed fibers in tissues treated with soft chrysotile. In the course of this work, a method for visualizing asbestos fibers in tissue sections without destroying tissue relationships was developed.[16]

Findings

Experiment A

This experiment comprised 60 hamsters divided into four treatment groups of 15 animals each. Each animal in three of these groups was given a single intrapleural injection of 25 mg. of a sample of asbestos suspended in 0.5 ml. of a 0.9 per cent sodium chloride solution. Those in *Group 1* received harsh chrysotile Sample 1; those in *Group 2* received soft chrysotile Sample 2; those in *Group 4* received amosite Sample 7. *Groups 1* and *2* received one per cent soft chrysotile in the diet. *Group 4* received



Figure 1. Pleural adhesion 97 days after injection of harsh chrysotile. Alveolar lung tissue is seen at upper left of photograph, muscle bundles of the chest wall at bottom. Cross section of a rib shows in lower right corner. The space between the lung and the chest wall is filled by the thick adhesion. The large round or elongated dark structures in the adhesion are blood vessels. 100 ×.

ASARCO ELP 0002921

one per cent amosite in the diet. *Group 3* was maintained as a control, untreated with asbestos. Results were as follows.

Group 1. Three hamsters were examined between 97 and 102 days after injection. In two, the injected asbestos was found to have been deposited in the chest wall instead of the pleural cavity. There was little reaction around it. In the third, all lobes of the right lung were bound by adhesions to the parietal pleura. The thickest area of adhesions was a 7 × 3 × 2 mm. firm gray zone on the medial surface of the right lower lobe. The base of this lobe was adherent to the diaphragm. Histologically, the adhesions formed a densely cellular and highly vascular granulomatous inflammation with prominent pleural thickening (FIGURES 1 and 2). Asbestos fibers were seen in the adhesions, but asbestos bodies were not found.



FIGURE 2. Higher power view of an area of the adhesion shown in FIGURE 1. Most of the cells are macrophages, some of which are coalescing to form multinucleated giant cells. 400 ×.

On the 157th day, a hamster was sacrificed because of the loss of 40 gm. in weight, and deformity of the chest. All lobes of the right lung were densely adherent to each other and to the parietal pleura. The right pleural cavity was obliterated by these adhesions, which compressed the right lung and contracted the right chest wall inward. A firm gray-white 10 × 7 × 2 mm. discoid lesion bound the base of the right lung to the diaphragm. The inferior surface of the heart was bound by dense adhesions to the parietal pericardium and diaphragm. There were adhesions between the pericardium and the left lung. The adhesions in this animal differed from

ASARCO ELP 0002922

those in the preceding animal in that they contained many well-developed multinucleated giant cells often with a dozen small nuclei arranged in a circle around the periphery. The discoid lesion was a thick adhesion with a necrotic center that contained granules of calcium.

Five hamsters died or were sacrificed between 281 and 398 days. In two of these, nothing remarkable was found aside from a nodule around a subcutaneous deposit of asbestos. The other three had dense pleural adhesions involving the right lung, delicate adhesions involving some areas of the left lung, and, in two, obliteration of the pericardial cavity by adhesions. As in the preceding animals, the lobes of the lungs stood out as pink and air-containing though compressed to varying degrees by the adhesions on their surfaces. In the 398-day animal, the adhesions were sparsely cellular fibrillar connective tissue with only occasional giant cells. There were calcium deposits in necrotic foci (FIGURE 3). A mass measuring 15 × 9 × 5 mm. lay in the mesentery of the small intestine. Microscopically, it proved to be a malignant lymphoma.

On the 415th day, a hamster (H 12) was sacrificed because of paralysis of both hind legs. The lobes of the right lung were pink and air-containing but compressed by a solid tumor that measured 30 × 20 × 15 mm. and lay between the chest wall and right lung from which it could not be separated (FIGURE 4). The cut surface of the tumor was gray-white, firm, and



FIGURE 3. Pleural adhesion 398 days after injection of harsh chrysotile. Fibrous tissue surrounds an area of necrosis in which there is a large deposit of calcium (black). 100 ×.

ASARCO ELP 0002923



FIGURE 4. Coronal section of thoracic organs from a hamster that developed a pleural mesothelioma 419 days after injection of harsh chrysotile. The tumor is the dark mass on the right. The ventricles of the heart are seen on the left. The right lower lobe of the lung is compressed between the tumor and the heart. Note that the tumor has extended along the pleural surface without invading the lung. The base of the lung is bound by an adhesion to the diaphragm. The diaphragm is the inverted U-shaped structure beneath the lung. Pleural adhesions show as light gray zones between the lung and the diaphragm, and between the lung and the tumor. 8 ×.



FIGURE 5. Higher magnification of an area from FIGURE 4. The tumor is on the right. The compressed lung is on the left. The light gray zone between them is fibrous thickening of the pleura. 100 ×.

ASARCO ELP 0002924



FIGURE 6. Anaplastic, elongated cells of the tumor shown in FIGURES 4 and 5. There are several mitoses. 400 ×.



FIGURE 7. Section of the thorax of a hamster that developed a pleural mesothelioma 527 days after injection of harsh chrysotile. The tumor is the dark mass. Intercostal muscles and ribs are seen in cross section on the right. The tumor has invaded and destroyed three intercostal muscles and two ribs. Alveolar lung tissue is in the center of the photograph. The heart is on the left. The gray zone between the lung and the heart is a thick pleural adhesion. 3 ×.

ASARCO ELP 0002925

appeared living throughout except for a small central area of friable, granular material some of which was examined in a drop of water and seen to contain asbestos fibers. This granular center was reminiscent of the areas of necrosis with calcification surrounded by granulomatous inflammation and fibrosis seen in preceding animals. The tumor may have arisen in the wall of such a lesion. It was composed of densely packed, basophilic, elongated cells whose nuclei varied greatly in size but nearly filled the cells (FIGURES 5 and 6). There were occasional mitoses. It compressed but did not invade the lung. It had invaded and replaced several thoracic vertebrae. Adhesions between the tumor and the lung, and between the lung and heart, were sparsely cellular, fibrillar connective tissue

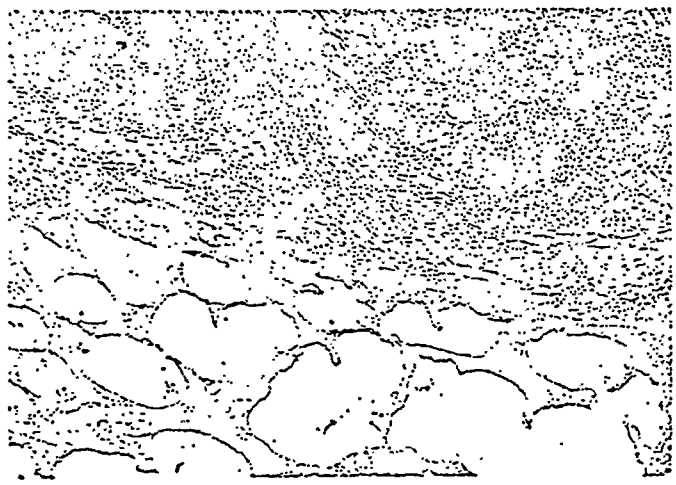

FIGURE 8. Junction of the tumor of FIGURE 7 and the lung. Note that the tumor does not invade the lung but is seperated from it by thickened pleura. 100 ×.

in which asbestos fibers, but no asbestos bodies, were seen. Giant cells were rare.

Pieces of this tumor were transplanted aseptically with a trocar into the right posterior thigh muscles of three adult male hamsters, three adult female hamsters and three new-born BALB/C mice. No growth occurred in the mice. Progressively growing tumors developed at the transplant sites in each of the six hamsters, and all of these animals died with large tumors 50 to 70 mm. in diameter within 10 to 15 weeks.

Among the surviving animals of the original *Group 1*, one was sacrificed because of labored breathing on the 527th day. It had a solid, fine-textured, hard, white tumor measuring 20 × 15 × 10 mm. which lay behind

ASARCO ELP 0002926

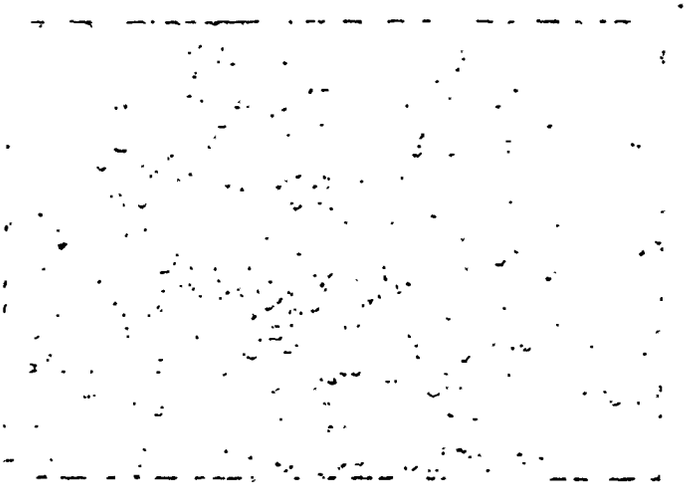

FIGURE 9. Spindle cells of the tumor of FIGURES 7 and 8. Two mitoses are near the center of the photograph. 400 ×.

the heart. The lungs were bound to the chest wall, mediastinum and diaphragm by adhesions or by the tumor (FIGURES 7 and 8). The pericardial sac was obliterated by adhesions. The liver contained a 6 × 4 × 3 mm. grape-like cluster of cysts with paper-thin walls, filled with clear fluid. The tumor was composed of spindle cells (FIGURE 9).

Another animal of the original group was sacrificed on the 539th day. In it, there were adhesions in the right pleural cavity and pericardial sac.

Three hamsters of Group 1 survive at the present writing.

Group 2. Two hamsters were examined 200 days after injection. In one, there was no evidence of asbestos or reaction to it in the pleural cavities or lungs. In the other, all lobes of the right lung were broadly bound to each other and to the chest wall by thick adhesions. The base of the right lower lobe was bound to the diaphragm by a firm, gray 6 × 6 × 4 mm. mass with an ill-defined edge. This proved to be an area of necrosis surrounded by fibrous tissue containing macrophages and multinucleated giant cells. The adhesions elsewhere also showed foci of necrosis, but were for the most part composed of sparsely cellular fibrillar connective tissue.

On the 255th day, a hamster dying of "wet tail" was found to have the right pleural cavity entirely obliterated by firm adhesions which surrounded and encased the lobes of the right lung. The thickest adhesions were between the base of the right lower lobe and the diaphragm, where

ASARCO ELP 0002927



FIGURE 10. Pleural adhesion 255 days after injection of soft chrysotile. The lung is on the left. The rest of the field is filled with the thick adhesion, which contains many discrete, dark-gray islands of cells lying amid fibrillar connective tissue. Some of these islands are shown at higher magnification in FIGURES 11–13. 100 ×.



FIGURE 11. Junction of the lung and pleural adhesion of the specimen shown in FIGURE 10. The lung is on the left. In the area between the lung and the center of the adhesion, there is hypertrophy and hyperplasia of mesothelial cells of the pleura which are seen as plump, rounded or cuboidal cells. 400 ×.

ASARCO ELP 0002928

two nodular lesions, 7 × 7 × 3 mm. and 6 × 6 × 5 mm., were located. On the right side of the pericardial sac, there was an adhesion 4 mm. wide and ½ mm. thick between parietal and visceral pericardium. Sections of the lesions at the base of the right lower lobe and of the adhesions elsewhere resembled those described in the preceding animal, but the nodular masses contained much finely granular material that stained blue with hematoxylin and was considered to be calcium. Also, the adhesions contained many islands of cuboidal cells which lay in clusters or lined cleft-like spaces. They resembled cells of the thickened pleura (FIGURES 10–13).

In a hamster sacrificed on the 852nd day because of weight loss, the lateral surfaces of the right upper and middle lobes were bound by adhesions to the chest wall and their medial surfaces to the mediastinum.



FIGURE 12. Mesothelial cells lining a cleft deep within the adhesion of FIGURE 10. 400 ×.

The dorsal surface of the heart was adherent to the parietal pericardium in an area continuous with the adhesion of the right lung to the mediastinum. At the base of the right lower lobe, there was a 13 × 4 × 4 mm. yellow mass containing necrotic tissue and granular material surrounded by a capsule 1 mm. thick. Microscopically, the granular material was found to be calcium, and the capsule was fibrillar connective tissue lightly infiltrated by round cells. In it, a few asbestos fibers were seen. There were occasional multinucleated giant cells, but these were degenerating. Occasional islands of cuboidal cells lay in the adhesions near the pleural surface.

ASARCO ELP 0002929

A hamster that died on the 381st day had thick pleural adhesions surrounding all lobes of the right lung except the infracardiac lobe.

In a hamster killed on the 427th day, a boggy, yellow mass measuring 16 × 12 × 12 mm. replaced the right upper and middle lobes. The cut surface showed it to be soft, caseous material surrounded by a thin capsule. Asbestos fibers were seen in some of this material suspended in a drop of water. It was concluded that the injected asbestos in this animal had been deposited into the lung instead of into the pleural space. The tissue response to this injection contrasted markedly with the previously described granulomatous and fibrotic responses to intrapleural injections.

On the 434th day, a hamster sacrificed because of weight loss had a 10 × 8 × 8 mm. yellow mass in the right costophrenic angle. It lay in the

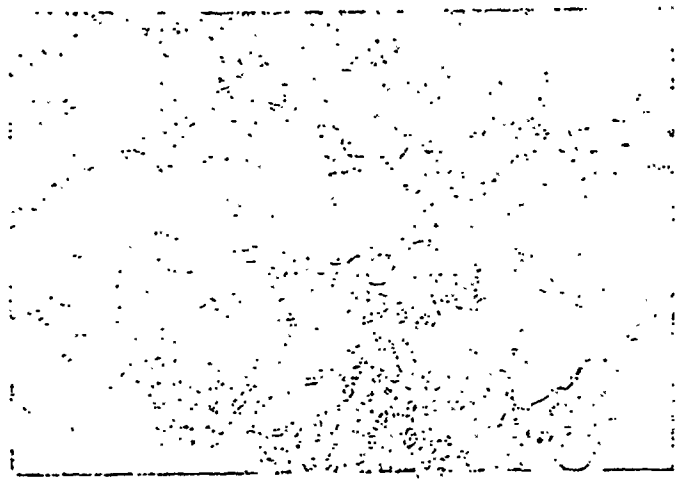

FIGURE 13. Mesothelial cells arranged in discrete islands deep within the adhesion of FIGURE 10. This adhesion was attached to the chest wall and the block was decalcified. The appearance of the nuclei in FIGURES 12 and 13 is an artifact of decalcification. 400 ×.

pleural space, compressing the right lower and middle lobes and binding them to the chest wall and diaphragm. The cut surface revealed granular yellowish-white material lying in a fibrous mesh-work surrounded by a tough gray wall 1 to 3 mm. thick. An ulcer was present in the forestomach. It was a thickening 5 mm. in diameter with a central crater.

A large, well-developed hamster that had seemed in good condition was found dead on the 440th day. In the right axilla, there was a 20 × 10 × 6 mm. encapsulated mass containing thin, greenish-yellow pus. The pleural

ASARCO ELP 0002930

cavities each contained about 2 ml. of clear, thin fluid. There were no pleural adhesions. The lungs were small, dull and boggy. The fluid in the pleural cavities was attributed to congestive failure. The liver contained numerous thin-walled cysts filled with clear fluid. The median lobe was largely replaced by a solid tumor which proved histologically to be a cholangiocarcinoma.

On the 455th day, a hamster was sacrificed because of a 10 mm. mass in the right axilla. It communicated by a wide extension beneath the clavicle with a 20 mm. mass in the subcutaneous tissue on the right side of the neck. The mass in the axilla was composed of tough fibrous tissue with white, granular deposits of calcium. The mass in the neck was a thin-walled sac filled with moist, white caseous material. The pleural cavities, lungs and other organs were not remarkable.

A hamster sacrificed because of labored breathing on the 476th day had extensive pleural adhesions (FIGURE 14) on the right with a 10 mm. mass extending from the right pleural cavity through an intercostal space into the subcutaneous tissue of the right chest where it communicated with a thin-walled cyst filled with colorless fluid. Four blocks from different areas of this specimen revealed no tumor. The parietal and visceral layers of pericardium were bound together by adhesions continuous with adhesions binding the right lung to the mediastinum. The left lung was

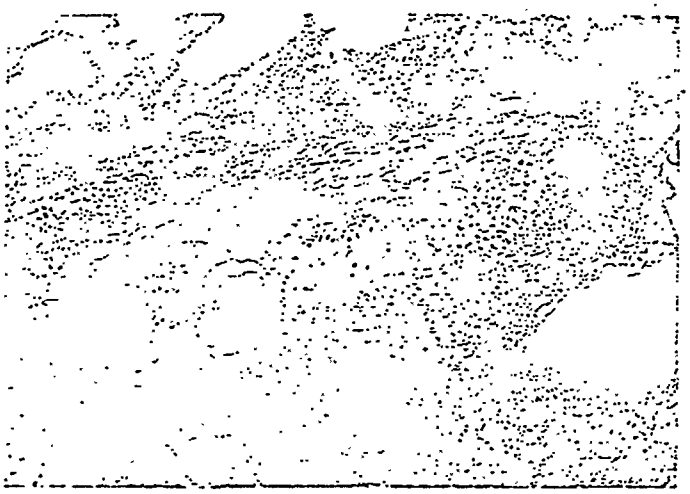

FIGURE 14. Pleural adhesion 476 days after injection of soft chrysotile. The lung is seen at the top. The center of the adhesion is necrotic and contains deposits of calcium which show as black areas. The deposit on the right is surrounded by fibrosis. 100 ×.

ASARCO ELP 0002931

not remarkable, but the left pleural cavity contained watery fluid as did the peritoneum, suggesting congestive failure. Seven cysts, 2 to 12 mm. in diameter, were found in the liver.

An animal sacrificed on the 557th day had, in the right axilla, a 10 × 7 × 4 mm. yellow nodule with a contiguous 11 mm. spherical mass. The cut surface of the latter showed a 2 mm. thick, tough rind surrounding dry, granular, white material that grated under the knife. Microscopic examination of this material in a drop of water with reduced illumination showed occasional asbestos fibers. The rind of this mass had undergone neoplastic change and proved to be a sarcoma.

In an animal found dying on the 588rd day, all lobes of the right lung were bound to each other by adhesions that were delicate except for four areas where there were spherical or ovoid yellow, opaque masses about 5 mm. in diameter. Two of these masses bound the right lower lobe to the diaphragm. The liver contained three fluid-filled cysts that were 2, 9 and 11 mm. in diameter, respectively. In the mesentery adjacent to the descending colon, there was an 8 × 3 mm. discoid lesion which proved microscopically to be an anaplastic malignant neoplasm. This lesion is being studied by electronic ashing[15] to learn whether asbestos fibers were associated with it.

One animal of Group 2 escaped on the 157th day. Two survive at present.

Group 3. In this untreated control group there were nine deaths between 131 and 548 days after the start of the test. These deaths were attributed to an endemic disease of hamsters known as "wet tail." The tissues of these animals were not remarkable aside from injection of blood vessels or hemorrhage in gut, liver and lungs attributed to infection. There were no tumors. The pleural cavities were not remarkable. No cysts were found in the livers. Nor were any anatomical lesions found in three hamsters of Group 3 that died on the 375th, 480th and 555th days of causes we were unable to determine. The three remaining animals of this group survive at the present writing.

Eight untreated control hamsters from another experiment were sacrificed at ages of 480 days, ± 30 days. The tissues of these animals were not remarkable. There were no cysts in their livers. No tumors were found at any sites.

In hamsters obtained from the same colony but used for experiments not involving asbestos, we found cysts in the livers of four individuals, a tumor of the adrenal cortex in one, a malignant tumor in the lower genitourinary tract of another, and gastric ulcers in six.

Group 4. A large tumor was found in a hamster sacrificed because of labored respiration 244 days after injection. On opening the abdomen, a

ASARCO ELP 0002932



FIGURE 15. Mesothelioma in a pleural adhesion 244 days after injection of amosite. The fibrillar connective tissue (light gray) of the adhesion contrasts with the darker islands and sheets of tumor cells. 100 ×.

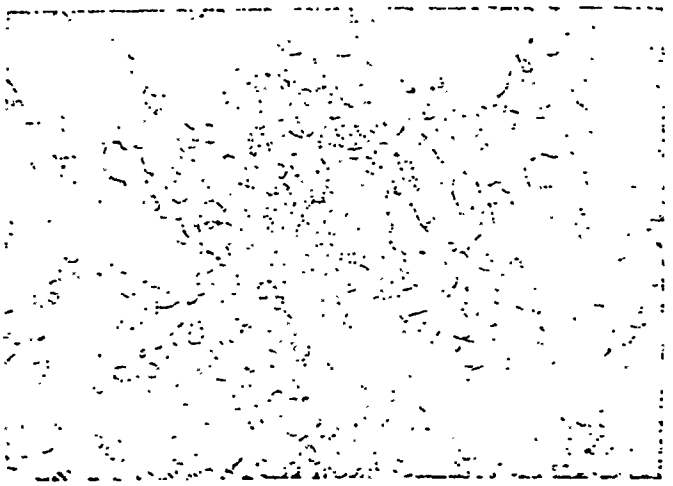

FIGURE 16. Another area of the tumor of FIGURE 15. Here, it is invading the diaphragm. The pleomorphic polygonal cells of the tumor are growing between muscle bundles of the diaphragm. There are several mitoses. 400 ×.

ASARCO ELP 0002933



FIGURE 17. Pleural adhesion between lung and chest wall in another hamster 244 days after injection of amosite. Air spaces of the lung are seen on the right. This adhesion was very vascular. The dark round or elongated structures are blood vessels. This adhesion contained great numbers of multinucleated giant cells packed with amosite fibers. 100 ×.



FIGURE 18. Higher magnification of multinucleated giant cells from the lesion shown in FIGURE 17. Innumerable amosite fibers lie within these cells and in the surrounding tissue. The fibers are best seen by examining the photograph with a hand lens. The large, dark structures are blood vessels. 400 ×.

ASARCO ELP 0002934

pinkish-white mass was seen extending from the chest through the diaphragm. It was surrounded by a delicate capsule which had perforated at the lower pole, revealing the contents of the mass as soft, lumpy tissue. On opening the chest, this mass was seen to be part of a tumor that measured 40 × 20 × 15 mm. and was composed of soft, somewhat translucent, light-gray tissue that largely filled both the right and left pleural cavities, displacing the lungs posteriorly, and covering the diaphragm with a sheet of gray tissue 3 mm. thick which had the soft texture of the tumor in contrast to the tough, yellowish pleural adhesions described in preceding animals. The tumor was composed of plump pleomorphic polygonal cells and some areas of spindle cells (FIGURES 15 and 16). They had abundant, moderately acidophilic cytoplasm and large, oval, vesicular nuclei. In a



FIGURE 19. Asbestos granuloma in an interlobular fissure of the right lung 272 days after injection of amosite. Alveolar lung tissue is seen at opposite corners of the photograph. This granuloma is densely speckled with giant cells. 100 ×.

fibrous adhesion between the right lung and the tumor, many multinucleated giant cells were packed with asbestos fibers. Large numbers of asbestos fibers lay in the tumor in the area adjacent to this adhesion. Metastatic deposits of tumor cells were found in the liver and lymph nodes. Additional photographs of this tumor and a metastasis of it are contained in a preliminary publication.[13]

Three other hamsters of this group died, presumably of "wet tail," between the 244th and 252nd day. In one of these, the lungs were not remarkable, and a yellowish nodule on the outer side of the thorax showed

ASARCO ELP 0002935

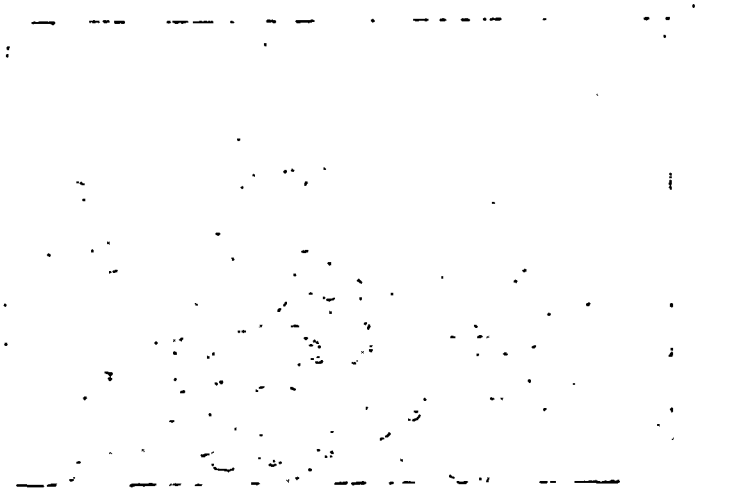

FIGURE 20. Higher magnification of multinucleated giant cells in the lesion of FIGURE 19. Innumerable amosite fibers can be seen by examining the photograph with a hand lens. Many are packed into the giant cells. 400 ×.

that the injected asbestos had been deposited there rather than into the pleural space. In the second, pleural adhesions bound the right middle and lower lobes to each other, and to the chest wall and diaphragm. In the third, thick adhesions encased the lobes of the right lung and bound the inferior surface of the heart to the diaphragm (FIGURE 17). There were a few delicate adhesions between the left lung and the diaphragm, and between the apex of the left lung and parietal pleura. The thick adhesions around the right lung were highly vascular and densely cellular with great numbers of multinucleated giant cells loaded with asbestos fibers (FIGURE 18). In an adhesion between the right lung and heart, there were many islands of cuboidal cells that appeared to be sequestrated mesothelial cells of the pleura.

A hamster sacrificed on the 272nd day because of gradual loss of 60 gm. in weight over the preceding three months had extensive yellow adhesions up to 1 mm. thick in the right pleural cavity and delicate adhesions in the left. Both right and left lungs were adherent to the mediastinum. The pericardial cavity was obliterated by adhesions up to 3 mm. thick. There was a 3 mm. rounded firm yellow nodule at the apex of the right lung and another similar nodule adjoining the right ventricle. Microscopically, these nodules were fibrous tissue studded with large numbers of multinucleated giant cells (FIGURE 19). Many asbestos fibers lay both

ASARCO ELP 0002936

within and outside the giant cells (FIGURE 20). In the thickened pleura, there were numerous clefts lined by cuboidal or rounded cells with small vesicular nuclei.

Firm and extensive yellowish adhesions up to 2 mm. thick encased both the right and left lungs and the heart of a hamster dying on the 275th day. To search for possible early stages of neoplastic change, serial sections were cut on a block from an area where the right lower lobe was densely adherent to the diaphragm. These showed granulomatous inflammation. The area between lung and diaphragm, and between lung and chest wall was filled with dense fibrous tissue that stained a brilliant blue with Mallory's connective tissue stain (FIGURE 21). This tissue contained many multinucleated giant cells, macrophages, lymphocytes, fibroblasts, and some plasma cells. Innumerable asbestos fibers were present, many within the giant cells. A lymph node contained many macrophages and many asbestos fibers. The lung itself was partly collapsed and markedly congested, but otherwise not remarkable. Many places in the scar near the lung showed islands of cuboidal cells in acinar arrangements. From the scar tongues of fibrous tissue extended between muscle bundles of the diaphragm and chest wall. These tongues of tissue stained blue with Mallory's connective tissue stain. No cells were found that could be recognized as neoplastic.

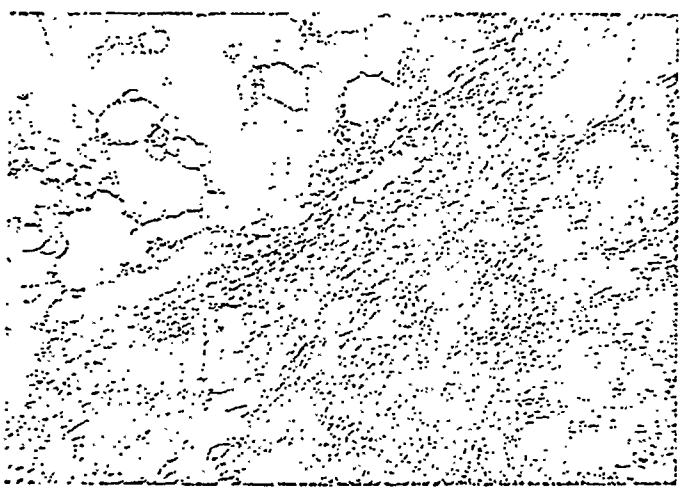

FIGURE 21. Fibrotic pleural adhesion between the right lower lobe and the diaphragm 275 days after injection of amosite. Air spaces of the lung are in the upper left corner. This section was stained with Mallory's connective tissue stain. The thick pleural adhesion stained a brilliant blue. 100 ×.

ASARCO ELP 0002937

On the 355th day, a hamster was noted to have a distended abdomen which felt boggy and gave a dull sound on percussion. This animal had shown a sudden gain of 80 gm. in weight. Smear of fluid from the abdomen showed large round tumor cells with large vesicular nuclei. At necropsy, dense yellow adhesions were found on the diaphragmatic surface of the left lung and delicate colorless adhesions on the diaphragmatic surface of the heart. The right lung was completely encased by dense yellow adhesions. On the posterior and diaphragmatic aspect of the right lower lobe there was a mass extending through the diaphragm into the abdominal cavity. This mass, 15 mm. in diameter, was composed of soft, grayish white tumor tissue. In the mesentery of the bowel, there were at least 50 nodules of such tissue 1 to 11 mm. in diameter. Lacteals in the mesentery were greatly distended. There was a 6 mm. mass adjacent to the aorta at the level of the kidneys. The liver had several small, superficial, gray nodules. There also was a gastric ulcer.



FIGURE 22. Mesothelioma cells (dark gray) lying between the right lung (*top*) and a thick adhesion (light gray) that bound this lung to the heart (*bottom of photograph*) at 355 days after injection of amosite. This tumor spread widely over the pleural surface of the lung. 100 ×.

Jacob Churg, who describes cases of human mesotheliomas in this Annal,[17] furnished the enclosed note on his study of blocks from this hamster (FIGURES 22–27).

Right lung and tumor. The lung is partly collapsed and is partly surrounded by a layer of granulation tissue containing asbestos fibers,

ASARCO ELP 0002938



FIGURE 23. Higher magnification of an area in FIGURE 22. Polyhedral or irregularly-shaped tumor cells occupy the upper half of the photograph. The lower half shows the fibrous pleural adhesion with two multinucleated giant cells. 400 ×.



FIGURE 24. Lung with two metastases of the tumor shown in FIGURES 22 and 23. 100 ×.

ASARCO ELP 0002939

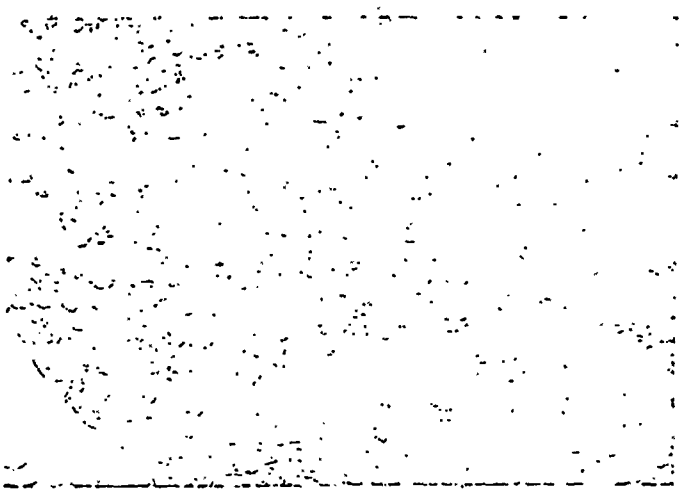

FIGURE 23. Higher magnification of the edge of one of the metastases shown in FIGURE 24. The compact mass of large tumor cells (*right*) abuts open alveolar lung tissue (*left*). 400 ×.

macrophages, lymphocytes, plasma cells, numerous fibroblasts and dense collagen. The tumor is located mainly on the diaphragmatic and posterior surfaces of the lung. It consists of polyhedral or irregularly shaped, sometimes elongated cells with variable, generally light nuclei and often prominent nucleoli. The cytoplasm is distinctly eosinophilic. Many mitoses are seen. Asbestos fibers and even occasional asbestos bodies are found between the tumor cells. The tumor infiltrates the base of the lung. A small independent plaque of tumor is found on the lung surface between lung tissue and asbestos granulation tissue. An independent nodule of tumor is found near the trachea. This apparently represents a lymph node metastasis. In addition to the tumor and the remnants of lymphoid tissue, this nodule contains a considerable amount of iron pigment and a smaller amount of asbestos fibers. Occasional foreign body giant cell is seen.

Lung and heart. Asbestos granulation tissue with numerous asbestos fibers is found adherent to the lung and also extending into the interlobular fissure. Granulation tissue is also adherent to the heart, apparently having invaded the pericardium. It also extends into the diaphragm. Small nodules of metastatic tumors are found in the lung and in the diaphragm.

Metastasis. Metastases are found both in the chest and abdomen. They

ASARCO ELP 0002940

replace the thymus, are seen in the retroperitoneal space, in the liver, kidney, mesentery and omentum, around the pancreas and adrenal, attached to the serosa of the large and small intestine and the stomach. No tumor metastasis was found in the vertebral column.

Stomach. An ulcer of considerable size is found in the stomach. It is quite acute with necrosis of the mucosa and dense infiltration of the submucosa by polymorphonuclear leucocytes. Asbestos bodies are found in one area at the base of the mucosa distant from the ulcerated area.

A hamster sacrificed on the 423rd day after gradual loss of 55 gm. in weight over a period of six months had all lobes of the right lung bound to each other and to the parietal pleura by gray adhesions 1 to 2 mm. thick. The right lower lobe and the heart were bound to the diaphragm by a broad, continuous, yellow adhesion 2 mm. thick. These were fibrous adhesions with great numbers of giant cells containing asbestos fibers. There were many asbestos bodies. Search was made for areas of beginning neoplasia but none were identified. Some small spaces in the adhesions were lined by cuboidal cells.

In a hamster dying on the 458rd day of an unknown cause, the injected asbestos evidently had failed to reach the pleural space but had been deposited partly in the subcutaneous tissue of the chest wall and partly in intercostal muscle. In the subcutaneous area, there was an 11 mm.



FIGURE 26. Intestine with metastasis of the tumor of FIGURE 22. Intestinal glands are on the right. Muscle coats of the intestine are seen as a narrow band separating the glands from the mass of the metastasis. 100 ×.

ASARCO ELP 0002941

spherical nodule of fibrous tissue which was attached to a 3 mm. nodule in the muscle.

On the 432nd day, a hamster was sacrificed because of edema with a gain of 32 gm. in weight in two weeks. The pericardial cavity was obliterated by adhesions. Anasarca, ascites and enlargement of the liver indicated congestive heart failure. The left lung was delicately adherent to the mediastinum. All lobes of the right lung were delicately adherent to each other and to the parietal pleura with a prominent thickening between the right lower lobe and the diaphragm. This was an ovoid-shaped, 10 × 8 × 5 mm., lesion with a tough, thick rind surrounding granular material which proved to be necrotic tissue containing asbestos fibers and granules of calcium. Adjoining the wall of this lesion, a small tumor composed of

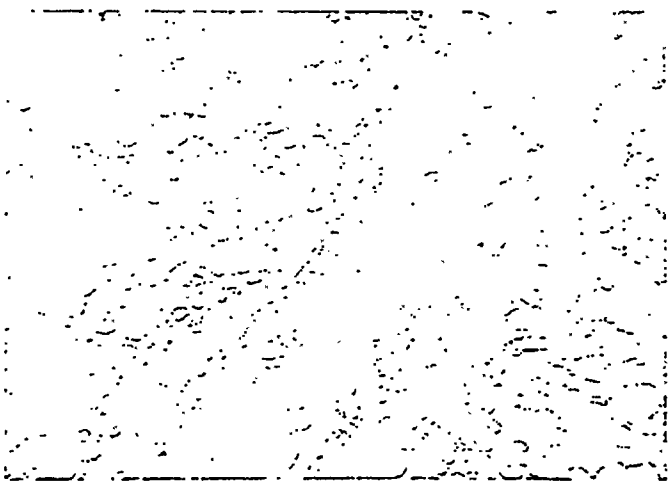

FIGURE 27. Higher magnification of an area in FIGURE 26. From right to left are seen intestinal glands, intestinal wall, then the cells of the metastasis. 400 ×.

neoplastic spindle cells was found in the microscopic sections (for photographs, see Reference 18, FIGURES 7 and 8).

On the 514th day, a hamster sacrificed because of weakness and weight loss showed equally extensive obliterative pericarditis but congestive failure had not set in. Gross findings in the right and left pleural cavities were almost identical with those described for the preceding animal, the most prominent lesion being a 6 × 4 × 4 mm. nodule in the right costophrenic angle. Another hamster, that died on the same day, had very similar adhesions in the right and left pleural cavities with a 4 mm. firm granular

ASARCO ELP 0002942

nodule in the right costophrenic angle. There was a 6 mm. grape-like cluster of thin-walled, fluid-filled cysts in the median lobe of the liver.

An 8 mm. thin-walled cyst was in the median lobe of the liver of a hamster sacrificed on the 552nd day because of congestive failure associated with obliterative pericarditis. Both lungs were densely adherent to the mediastinum. The base of the left lung was bound to the diaphragm by a wide mat of yellow adhesions 2 mm. thick. All lobes of the right lung were bound to each other and to the parietal pleura by dense adhesions. There was a 7 × 5 × 5 mm. mass of yellow adhesions in the right costophrenic angle.

One animal of Group 4 was lost. The last of the 15 hamsters in this group was sacrificed 559 days after injection. He was a big animal in excellent condition. There was delicate adhesive pericarditis. Both lungs were adherent to the mediastinum. Delicate adhesions bound the left lung in some places to the chest wall and the diaphragm. All the lobes of the right lung were adherent to each other and to the parietal pleura, the thickest adhesion being a 1 mm. yellow mat, between the right middle and right lower lobes, and a 7 × 3 × 3 mm. yellow mat between the right lower lobe and the diaphragm. The liver contained ten thin-walled cysts 1 to 11 mm. in diameter filled with clear fluid.

It will be apparent that in the last four hamsters described, the asbestos had evidently been injected into the most suitable position for induction of pleural mesothelioma, and these four animals had lived 270 to 315 days longer than the time of detection of the first mesothelioma in Group 4, yet no tumor resulted in them.

Intratracheal Injections

To gain experience with the technique for intratracheal injections of hamsters[14] trials were made with suspensions of India ink in saline. The animals used in these trials were sacrificed immediately after injection, and examined for site of deposition of the ink. In the first groups, the ink was sometimes found in the lungs and sometimes in the stomach, the latter event showing that the pipette had been introduced into the esophagus rather than the trachea. As experience was gained, it was found that ink could be reliably deposited into the lungs by delivering the injection only when pressure on the chest wall caused a rise in fluid level in the pipette, showing that the pipette was positioned in the trachea rather than in the esophagus. These tests also showed that a volume of 0.1 ml. of saline could be safely injected, but that a volume of 0.2 ml. caused deaths immediately after injection, evidently from asphyxiation.

In undertaking tests for carcinogenicity of samples of asbestos by the intratracheal route, a first requirement was to learn the amounts of these materials that could be injected into hamsters without unacceptable losses

ASARCO ELP 0002943

of animals. For this work, we used the same three samples of asbestos that had been used in the preceding tests by the intrapleural route. The amosite and harsh chrysotile fibers settled and resuspended readily in saline, but the soft chrysotile fibers tended to form a gel which choked animals and led to deaths immediately after intratracheal injections. Doses of these three samples which caused only occasional losses after single injection were then utilized for *Experiment B* to explore amounts that could be administered by repeated weekly injections. Survivors of *Experiment B* have been maintained throughout their lives to observe for development of tumors.

Experiment B

Forty-two hamsters divided into three treatment groups were started on weekly intratracheal injections of harsh chrysotile Sample 1, soft chrysotile Sample 2, or amosite Sample 7. The volume of each injection was 0.1 ml. The amount of asbestos and the suspending medium is stated under the descriptions of these groups. Several suspending media were utilized in an effort to reduce losses from injections. Because of high initial losses in groups treated with both chrysotile samples, additional cohorts of 15 hamsters each were started on these samples. Results were as follows.

Group 5. Twelve hamsters were given an intratracheal injection of 2.5 mg. harsh chrysotile Sample 1 suspended in 0.1 ml. saline. One died immediately after injection. This dose was repeated one week later, and two animals died. For subsequent weekly injections, the dose was reduced to 1.25 mg. Three animals died immediately after the first of these reduced doses which were administered in casein suspension instead of saline. Only four survived a total of eight injections, each thereby receiving a total of 12.5 mg. of harsh chrysotile. These lived until 181, 216, 256 and 357 days, respectively, after the first injection. No tumors were found in them.

A second cohort of 15 hamsters was given weekly intratracheal injections of 1.25 mg. of this sample, but human plasma was used as the suspending medium. After 12 weekly injections, there had been only one death in this cohort. The injections were continued. Nine animals survived a series of 24 injections, each thus receiving a total of 30 mg. harsh chrysotile. Of these, five died at 178, 175, 314, 321 and 404 days, respectively, after the first injection, and four are still living. No tumors were found in the animals that have thus far died in this cohort aside from a hemangioma of the liver. Roentgenological examination of the chest does not show tumor in any of the four survivors.

Group 6. Of 15 hamsters given an intratracheal injection of 2.5 mg. of soft chrysotile Sample 2 in 0.1 ml. saline, four died immediately after injection and all of the others died within the following week.

A second cohort of 15 hamsters was then given an intratracheal injec-

ASARCO ELP 0002944

tion of 1.25 mg. of this sample in 0.1 ml. saline. There were no losses of animals within the first week, and this dose was repeated to a total of ten injections at weekly intervals during which seven animals died immediately after the injections. In the 16th week, two died of "wet tail." Six survive at present, 15 months after their first injection, having received a total of 12.5 mg. of soft chrysotile. Roentgenological examination of the chest does not show a tumor in any of these six survivors.

Group 7. Fifteen hamsters were given intratracheal injections of 2.5 mg. of amosite Sample 7 in 0.1 ml. saline. One died immediately after the first injection and another immediately after the third. Thirteen survived a course of ten injections, thereby receiving a total of 25 mg. each. Of these survivors, three died between 147 and 168 days after the first injection. Seven died of "wet tail" between 209 and 216 days, one at 442 days, one at 488 days, and one is still alive. No tumors were found in those that died.

Experiment C

Three groups of 60 hamsters each were started on weekly intratracheal injections of, respectively, amosite, soft chrysotile, or saline. A fourth group was set aside as an untreated control. The preparation of amosite used in this test was from the same batch used in all preceding tests. The chrysotile was prepared from the same ore as that used in the preceding work, but was processed to an average fiber length of 30 microns.

Twenty-one hamsters survive 11 months after the first injection of the amosite sample, of which they each received a total of 25 mg., delivered in ten weekly doses of 2.5 mg. apiece. Twenty-five hamsters survive six months after the first injection of the chrysotile sample, of which they each received a total of 6.25 mg., delivered in ten weekly doses that were reduced, because of losses, from 1.25 to 0.5 mg. apiece. No tumors have been found in the respiratory tract of any animals that have thus far died in this experiment.

In sum, no tumors have been found in the respiratory tracts of hamsters that have thus far died in any of the groups treated with asbestos by the intratracheal route. Each of the samples of asbestos induced pulmonary lesions resembling asbestosis, as will be described in another place. Large numbers of asbestos fibers were widely distributed through lungs, as was readily seen in the case of amosite or harsh chrysotile by closing the diaphragm of the microscope condenser in examining the sections. This procedure seldom visualized fibers of soft chrysotile in tissues, but asbestos bodies were found with ordinary illumination in lungs treated with soft chrysotile, in addition to those treated with the other varieties of asbestos. There were numerous islands of adenomatoid tissue and occasional small,

ASARCO ELP 0002945

calcified pleural plaques. Fibrosis was a prominent feature, but it tended to be delicate and interstitial. In no instance did these lungs show thick fibrotic lesions comparable to those described in the hamsters given single massive intrapleural injections.

Discussion

The three preparations of asbestos studied each induced granulomatous inflammation, necrosis, calcification, and fibrosis after intrapleural injection into hamsters. These reactions were most extensive on the side in which the injection had been made, but transport of injected fibers was attested by the frequent finding of similar reactions in the pericardial cavity and occasionally in the contralateral pleural cavity. In early specimens the cellular response consisted principally of macrophages. Later, multinucleated giant cells, often filled with asbestos fibers, were numerous. Still later, fibrosis was the outstanding feature. Tissue reactions of this nature formed extensive adhesions which encased lobes of the lungs and sometimes the heart. Granules of calcium developed in these adhesions. The thicker adhesions tended to have necrotic centers. By closing the diaphragm of the microscope condenser, asbestos fibers were often readily visible in large numbers in histological sections of pleural adhesions in hamsters that had been injected with amosite or harsh chrysotile, but were rarely visible in hamsters injected with the preparation of soft chrysotile. Multinucleated giant cells were much more numerous in pleural adhesions of hamsters treated with amosite than in those treated with chrysotile.

Pleural mesotheliomas were found at 244, 358 and 482 days after intrapleural injection of amosite, at 419 and 527 days after injection of harsh chrysotile, but not after injection of soft chrysotile in groups of 15 hamsters given single injections of 25 mg. of preparations of these materials. Amosite and harsh chrysotile fibers have less water associated with the molecule[11] and can be felt to be stiffer and more spiky to the touch when handled. Histologically, two of the tumors resembled epithelial types of mesotheliomas seen in man, and three resembled fibrous types.[12] Injection of asbestos into the pleural cavity, as done in this experimental work, does not, of course, reproduce conditions of exposure in man. The experiments do show, however, that intrapleural injection in hamsters affords a means for estimating the potential tumor-inducing action of asbestiform minerals.

Intratracheal injections, which more closely simulate the route of exposure in man, have thus far failed to elicit tumors in hamsters treated with the three preparations of asbestos studied in the present work. After intratracheal injections, fibers of asbestos were widely distributed throughout the lungs but no lesions resulted that were comparable in thickness to the fibrotic areas found after intrapleural injection of a massive dose of

ASARCO ELP 0002946

asbestos. In the four large tumors found in the pleural space, the precise point of origin could not be determined. The fifth tumor, however, was small and it could be seen to have arisen in the thick fibrous wall of a pleural adhesion. Similarly, a sarcoma was found in a thick fibrous wall that surrounded a deposit of soft chrysotile in the subcutaneous tissue of the axilla in another hamster in this work. These observations suggest that asbestos may posses no primary carcinogenicity, but that tumors may arise from the reactive tissue engendered by it.

Warburg has detailed evidence supporting a theory that carcinogens act by interfering with cellular respiration.[48] The pleural adhesions seen in early specimens in the present work were highly vascular, but in the later specimens vascular channels were choked off by the development of dense fibrous tissue. Respiration of many cells in densely fibrotic pleural adhesions was manifestly impaired as evidenced by the many central foci of necrosis described in these lesions. It may thus be that tumors associated with asbestos arise from cells whose respiration is impaired by entrapment in dense fibrous tissue. In our early case of a fibrous type of mesothelioma, the tumor was, as mentioned above, seen to arise from such dense fibrous tissue. As mentioned in descriptions of other specimens from these experiments, somewhat cuboidal cells were often seen lying in islands or lining clefts in fibrous pleural adhesions. These cells resembled mesothelial cells of the pleura. Entrapment of cells preserving these characteristics in fibrous tissue affords a possible theoretical explanation for the development of epithelial types of mesotheliomas.

In the literature cited earlier in this paper on animals exposed to asbestos by inhalation or intratracheal injection, no cases have been described that show the extensive fibrosis that can result from asbestos in human lungs. The concept just discussed suggests that this may be a reason for the failure of tumors to develop in the lungs of animals thus far studied. Against this concept stands the finding that carcinoma is not unusually frequent in the lungs of men with the fibrosis induced by silica.[1] Wagner,[3] however, has reported a mesothelioma in a rat after intrapleural injection of silica.

Experimental induction of mesotheliomas by any means provides an approach toward study of the genesis of these tumors. From observations described in the present paper on tissue reactions preceding appearance of such tumors in hamsters it can be seen that they followed extensive fibrotic reactions. In the present work, the fibrotic reactions were induced by asbestos. It is possible that mesotheliomas may arise in hamsters from other materials that induce equivalent pleural fibrosis. The findings thus leave unanswered the question of whether asbestos fibers posses primary carcinogenicity.

Because of a recent report[2] of an increased frequency of carcinomas in

ASARCO ELP 0002947

the gastrointestinal tract of an occupational group of men exposed to asbestos, we added asbestos to the diet of hamsters in one of the experiments reported here, and maintained them on such feed throughout life. In these animals there were occasional gastric ulcers, one lymphoma that invaded the pancreas, and a cholangiocarcinoma of the liver. Gastric ulcers, lymphomas and cholangiocarcinoma have been described as spontaneous lesions in hamsters by Fortner *et al.*[35,36] in valuable papers on spontaneous tumors of hamsters. In one of our hamsters that was fed asbestos, there was an anaplastic neoplasm in the mesentery near the colon. This lesion is being studied further by a recently developed method for detection of asbestos fibers in tissues.[36]

The question of whether asbestos fibers may potentiate the action of a carcinogen present in cigarette smoke was explored in experiments reported in an accompanying paper.[21]

Conclusion

Gross and histological changes following single massive intrapleural injections of asbestos into hamsters have been described. Thick fibrotic adhesions ensued. Later, pleural mesotheliomas were found in occasional hamsters that had received brittle varieties of asbestos but not in those that had received a soft variety.

No tumors have as yet appeared in the respiratory tracts of hamsters given repeated intratracheal injections of these varieties of asbestos. Pulmonary fibrosis occurred following intratracheal injections, but this was not comparable in thickness to the fibrotic lesions induced by intrapleural injections.

The experiments show that asbestos can induce mesotheliomas in hamsters. They raise a question as to whether these tumors signify a primary carcinogenic action of asbestos fibers or are secondary and nonspecific epiphenomena of fibrosis.

Acknowledgment

Roentgenological examination of the chests of selected hamsters in these experiments was made by Franklin Reed, M.D. and Bruce Burtan, M.D., Department of Radiology, Morristown Memorial Hospital, Morristown, N. J. Their collaboration is appreciated.

References

1. Smith, Wm. E. 1952. Survey of some current British and European studies of occupational tumor problems. A. M. A. Arch. Indust. Hyg. Occup. Med. 5: 242–263 (Refer to pp. 249–254, 262–262).
2. Selikoff, I. J., J. Churg & E. C. Hammond. 1964. Asbestos exposure and neoplasia. J. Am. Med. Assn. 188: 22–26.
3. Wagner, J. C. 1962. Experimental production of mesothelial tumours of the pleura by implantation of dusts in laboratory animals. Nature 196: 180–181.

ASARCO ELP 0002948

4. SMITH, WM. E., L. MILLER, J. CHURG & I. J. SELIKOFF. 1964. Pleural reaction and mesothelioma in hamsters injected with asbestos. Proc. Am. Assn. Canc. Res. 5: 59.
5. VORWALD, A. J., T. M. DUNCAN & P. C. PRATT. 1951. Experimental st... of asbestosis. A. M. A. Arch. Indust. Hyg. Occup. Med. 3: 1–48.
6. BEHNENS, W. 1931. Über experimentelle Asbestosis. Schweiz. Z. Path. 14: 273–297.
7. NORDMANN, H. & A. SORGE. 1941. Lungenkrebs durch Asbeststaub im Tierversuch. Z. Krebsforsch. 51: 168–182.
8. LYNCH, K. M., F. A. MCIVER & J. R. CAIN. 1957. Pulmonary tumors in mice exposed to asbestos dust. A. M. A. Arch. Indust. Health 15: 207–214.
9. WAGNER, J. C. 1963. Asbestosis in experimental animals. Brit. J. Indust. Med. 20: 1–12.
10. SUGIURA, K., WM. E. SMITH & D. A. SUNDERLAND. 1956. Experimental production of carcinoma in rhesus monkeys. Cancer Res. 16: 951–955.
11. BADOLLET, M. S. & W. A. GANTT. 1965. Preparation of asbestos fibers for experimental use. This Annal.
12. SMITH, WM. E. 1956. Experimental Studies. *In* Pulmonary Carcinoma: Pathogenesis, Diagnosis and Treatment. Edgar Mayer & H. C. Maier, Eds.: 340. New York University Press. New York, N. Y.
13. SMITH, WM. E., L. MILLER, J. CHURG & I. J. SELIKOFF. 1965. Mesotheliomas in hamsters following intrapleural injection of asbestos. J. Mt. Sinai Hosp. 32: 1–8.
14. SELIKOFF, I. J., L. G. TOMERTHOFF & E. H. ROBITZEK. 1948. Initial pneumothorax. A new safe induction technique. Quart. Bull. Sea View Hosp. 10: 98–100.
15. HEROLD, K. M. & L. J. DUNHAM. 1962. Induction of carcinoma and papilloma of the tracheobronchial mucosa of the Syrian hamster by intratracheal instillation of benzo(a)pyrene. J. Nat. Canc. Inst. 28: 467–492.
16. BERNELEY, C., J. CHURG, WM. E. SMITH & I. J. SELIKOFF. 1965. The detection and localization of mineral fibers in tissue. This Annal.
17. CHURG, J., S. MOOLTEN & S. ROSEN. 1965. Histological characteristics of mesothelioma associated with asbestos. This Annal.
18. WARBURG, O. 1956. On the origin of cancer cells. Science 123: 309–314.
19. FORTNER, J. G., A. G. MAHY & G. R. SCHRODT. 1961. Transplantable tumors of the Syrian (golden) hamster. Part I: Tumors of the alimentary tract, endocrine glands and melanomas. Canc. Res. 21(2): 161–198.
20. FORTNER, J. G., A. G. MAHY & R. S. COTRAN. 1961. Transplantable tumors of the Syrian (golden) hamster. Part II: Tumors of the hematopoietic tissues, genitourinary organs, mammary glands and sarcomas. Canc. Res. 21(2): 199–284.
21. MILLER, L., WM. E. SMITH & S. W. BERLINER. 1965. Tests for effect of asbestos on benzo(a)pyrene carcinogenesis in the respiratory tract. This Annal.

ASARCO ELP 0002949