) bronchial reactivity t: etha-
), 1321–1326.
Benson, F. B. (1970). Th. Chat-
nitrogen dioxide. II. Incidence
–588.
1980). Respiratory disease rates
e. *Amer. Rev. Respir. Dis.* 121,

que assay and primary isolation
ells (MDCK) in the presence of

., G., Jr., Gibb, F. R., Morrow,
ity to nitrates in subjects with

, Exposure chamber for studies
siderations. *J. Aerosol Sci.* 15,

R., and Morrow, P. E. (1979).
. *J. Appl. Physiol.* 46, 1 -196.
Crystal, R. G. (1984). ormal
ge have a limited capacity to

nitrogen dioxide on the uptake
lothel. Soc. 11, 627–636.

ENVIRONMENTAL RESEARCH 48, 193–210 (1989)

PLAINTIFF'S EXHIBIT

SA-460

Rat Lung Reactivity to Natural and Man-Made Fibrous Silicates following Short-Term Exposure[1]

IRMA LEMAIRE,* PAUL G. DIONNE,† DENIS NADEAU,‡ AND JACQUES DUNNIGAN§

Department of Pharmacology, Faculty of Health Sciences, University of Ottawa and †The Ottawa General Hospital, 451 Smyth Road, Ottawa, Ontario, Canada K1H 8M5; and ‡Laboratoire de Caracterisation de l'Amiante, Département de biologie, Faculté des Sciences and §l'Institut de l'Amiante, Pavillon Marie-Victorin, Université de Sherbrooke, Sherbrooke, Québec, Canada J1K 2R1

Received June 30, 1988

The inflammatory and fibrogenic potential of three naturally occurring and two man-made industrial minerals were compared. Groups of five rats each received respectively a single intratracheal instillation of saline (control), UICC chrysotile B asbestos, short chrysotile 4T30, attapulgite, xonotlite (a calcium silicate), and Fiberfrax (an aluminum silicate) at doses of 1, 5, and 10 mg. One month after the treatment, assessment of lung morphology and bronchoalveolar lavage were performed on each animal. Under these conditions, UICC chrysotile B at all doses tested (1, 5, and 10 mg) induced fibrotic lesions in bronchiolar tissues while short chrysotile 4T30 (1, 5, and 10 mg) caused focal accumulation of inflammatory cells in the alveolar structures but no apparent fibrosis. Compared to these positive reactions with different fibrogenicity, xonotlite caused minimal inflammatory reactions detectable only at high dose (10 mg) and by bronchoalveolar analysis. By contrast, the rat lung reacted more significantly to attapulgite and Fiberfrax although the tissue reaction differed considerably for these two materials. While attapulgite, at doses up to 10 mg caused minimal reactions characterized by mononuclear cell infiltration mainly in the alveolar structures, Fiberfrax at 1 mg and higher caused significant granulomatous reactions and the appearance of early fibrosis. Overall the order of lung biological reactivity observed for the various silicates was xonotlite ≪ attapulgite < short chrysotile 4T30 < Fiberfrax < UICC chrysotile B. These observations indicate that Fiberfrax, attapulgite, and, to a lesser extent, xonotlite are biologically active within the time span studied and potentially deleterious for lung tissue.

© 1989 Academic Press, Inc.

INTRODUCTION

Because of the well-documented deleterious effects of chrysotile asbestos on the lung (Becklake, 1976; Selikoff and Lee, 1978; Selikoff and Cuyler Hammond, 1979), new naturally occurring fibrous materials have been proposed for asbestos substitution in various applications. Among these, attapulgite, a naturally occurring magnesium aluminum silicate (Haden, 1963) was proposed as a component of an asbestos-free friction material (Washabaugh, 1983) and has found wide use in many other applications including adhesives, sealants, mastics, paints, and pharmaceuticals (Haden and Schwint, 1967; Hénin and Caillère, 1975). Similarly, numerous man-made materials such as xonotlite (Funk, 1965) and Fiberfrax (Nadeau

[1] Supported by grants from the "Institut de l'Amiante" and the Medical Research Council of Canada (MRC). I. Lemaire is a scholar from the MRC.

0013-9351/89 $3.00

Copyright © 1989 by Academic Press, Inc
All rights of reproduction in any form reserved

et al., 1987) have also been selected as suitable alternatives to asbestos. Fi frax, an aluminum silicate material has been used as a substitute for chrysotile a estos in applications where thyxotropic properties are desired and as an add. ve to epoxies, caulking compounds, fine paper production, and injection molding compounds. Xonotlite, a calcium silicate fibrous material has been introduced for substitution of asbestos in temperature insulation products. Despite the extensive use of these newly introduced materials, relatively few studies have been carried out to determine their biological activity and hence, their safety from a health standpoint. In this regard, commercially available attapulgite and xonotlite fibers are in the respirable range, the lung being a preferential target site for their effects. In addition, recent *in vitro* studies have reported significant cytotoxic effects for attapulgite (Jaurand *et al.*, 1979; Nadeau *et al.*, 1983; Harvey *et al.*, 1984) and Fiberfrax (Nadeau *et al.*, 1987) and to a lesser extent, for xonotlite (Skaug *et al.*, 1984; Nadeau *et al.*, 1987). These observations prompted us to investigate the *in vivo* effects of these materials on the lung. Previously, we have shown that intratracheal instillations in rats may be used to evaluate the relative lung react y of various dusts (Lemaire *et al.*, 1985). In this study, we used this animal m l to assess the effects of xonotlite, attapulgite, and Fiberfrax in comparison wit two preparations of chrysotile asbestos that differ in their fibrogenic potential.

MATERIALS AND METHODS

Animals

Male Wistar rats weighing 250 to 300 g were purchased from Charles River Canada, Inc. (St. Constant, Québec). These animals were derived from a pathogen-free colony, shipped behind filter barriers, and housed in a horizontal laminar flow isolator (Johns Scientific, Inc., Toronto). They were given Purina Chow and water *ad libitum* and were used 1 week later.

Fibers

UICC standard sample of chrysotile B was obtained from the Nation Research Institute for Occupational Diseases, Johannesburg, South Africa. ery short 4T30 chrysotile fibers were isolated as described (Nadeau *et al.*, 1987) rom Johns–Manville grade 4T30 chrysotile fibers according to the sedimentation procedure of Jolicoeur *et al.* (1981). Fiberfrax (HSA, high specific area) was obtained from the Carborundum Co. (Niagara Falls, NY) and a short fraction of this material was extracted as described previously (Nadeau *et al.*, 1987). The calcium silicate xonotlite was a commercially available product (trademark, Promatek) and the clay mineral-attapulgite was obtained from the Quincy deposits (Florida). These two materials are already in the respirable range and were tested as supplied. Each sample was autoclaved for 45 min and suspended in sterile phosphate-buffered saline (PBS, pH 7.4) with a Dounce glass homogenizer prior to instillation into the animals. Preparation and physicochemical properties of the silicate fibers used in this study have been described in detail earlier (Nadeau *et al.*, 1987). Characteristics of the fibers used in this study are summarized in Table 1 and differences in fiber length are illustrated in Fig. 1.

Materials

UICC chrysotile B[a]
Short chrysotile 4T30[b]
Attapulgite[b]
Xonotlite[b]
Fiberfrax[b]

[a] As described by Timbr
[b] As reported by Nadeau

Experimental Protoc

Animals received a
maire *et al.*, 1986) o
attapulgite, xonotlite
doses (1, 5, or 10 mg
1 month after treatm

Bronchoalveolar La

Bronchoalveolar l
1985). A total volum
The bronchoalveolar
min, washed in PBS.
Biological Co., Gran
ber and viability wa
lavage cells were m
and stained with Wr

Lung Morphology

Histopathology w
Begin *et al.*, 1987).
median longitudinal
immersion in phosp
choalveolar lavage
in paraffin and rep
hematoxylin and ec

Statistical Analysis

Results are expr
differences betwee
Student *t* test (*P*

TABLE I
CHARACTERISTICS OF INJECTED MATERIALS

Materials	Length (μm)	Average length (μm)	Diameter (μm)	Aspect ratio	Specific surface area (m^2/g)	Surface charge (mV)
UICC chrysotile B[a]	58% < 5	—	—	—	26.8	+36
Short chrysotile 4T30[b]	100% < 5	0.9	0.1	12.3	36	+45
Attapulgite[b]	100% < 1	0.8	0.1	15.3	133	−29
Xonotlite[b]	100% < 3	1.2	0.2	5.8	42	−24
Fiberfrax[b]	50% < 5	8.3	0.2	38.5	15	−43

[a] As described by Timbrell (1970).
[b] As reported by Nadeau *et al.* (1987).

Experimental Protocol

Animals received a single intratracheal instillation as described previously (Lemaire *et al.*, 1986) of either saline, UICC chrysotile B, short chrysotile 4T30, attapulgite, xonotlite, or Fiberfrax. Groups of 7 animals each received various doses (1, 5, or 10 mg) of these materials and a total of 110 animals were examined 1 month after treatment.

Bronchoalveolar Lavage (BAL)

Bronchoalveolar lavage was performed as described previously (Lemaire, 1985). A total volume of 50 ml PBS in 5-ml aliquots was infused in each animal. The bronchoalveolar cells were obtained by centrifugation at 200*g* at 4°C for 10 min, washed in PBS, and finally resuspended in RPMI 1640 medium (Grand Island Biological Co., Grand Island, NY). Cells were counted in a hemocytometer chamber and viability was determined by trypan blue exclusion. Differential counts of lavage cells were made from cytocentrifuge smears prepared with 2.5×10^4 cells and stained with Wright–Giemsa stain.

Lung Morphology

Histopathology was performed as described previously (Lemaire *et al.*, 1985; Begin *et al.*, 1987). After bronchoalveolar lavage, the lungs were removed and a median longitudinal section of the upper left lobe (1 mm thick) was fixed by immersion in phosphate-buffered 4% formaldehyde. For the 1-mg group, bronchoalveolar lavage was not performed. After fixation, lung tissue was embedded in paraffin and representative sections 5-μm thick were cut and stained with hematoxylin and eosin.

Statistical Analysis

Results are expressed as mean values ± SEM. The statistical significance of differences between treated and control groups was determined with the use of the Student *t* test ($P < 0.05$).

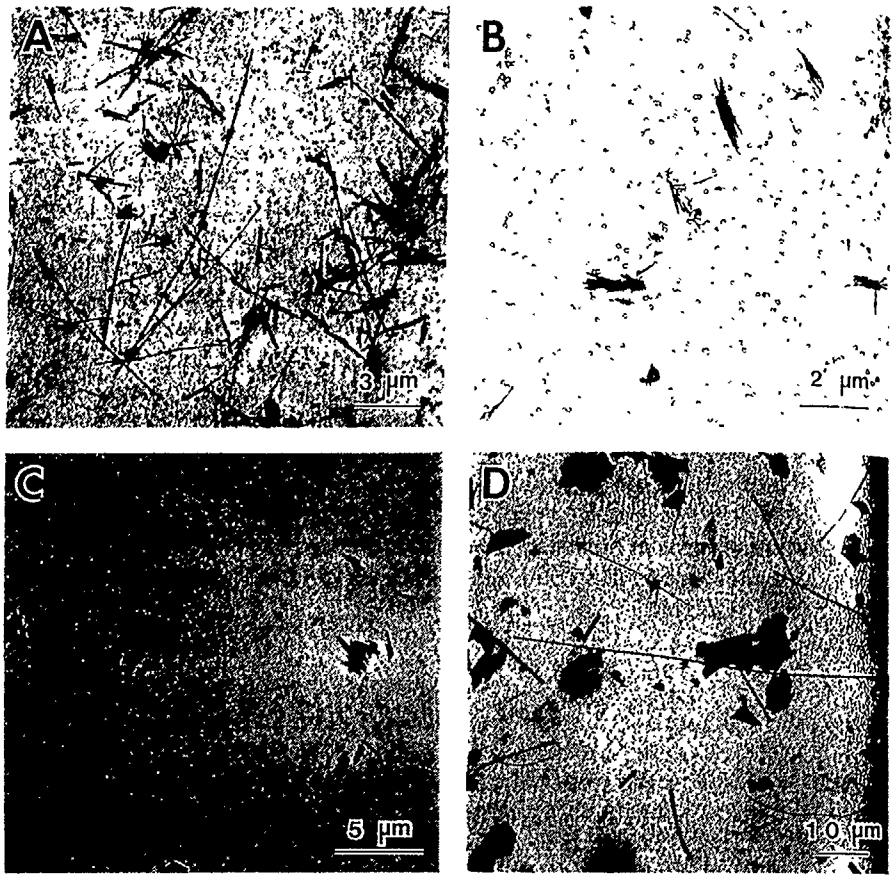

FIG. 1. Transmission electron micrographs of very short 4T30 chrysotile (A, ×3100), An rican attapulgite (B, ×5270), xonotlite (C, ×2400), and Fiberfrax short fiber fraction isolated by water sedimentation (D, ×740).

RESULTS

Survival and Incidence of Histological Lesions

All animals survived the exposure period and comparison of the average body weights revealed no significant difference between groups at all doses tested. However as summarized in Table 2, significant histological differences in relation to treatment were seen and lesions were arbitrarily categorized as A, B, C, and D for clarity. Descriptions of the typical lesions within each group are given below and almost all the animals in a particular group were affected.

Histopathology

Controls. Rats injected with saline showed normal lung morphology i all groups studied. Figures 2A and 2B shows the histological features of these l ngs

SUMMARY OF NUMBERS

Treatment	Dose (mg)
line	—
notlite	1
	5
	10
CC chrysotile B	1
	5
rt 4T30 chrysotile	1
	5
	10
apulgite	1
	5
	10
erfrax	1
	5
	10

One animal had a higher degr

with normal bronchioles, al specific lesions were obser *UICC chrysotile B.* As f cheal instillation of UICC terized by focal fibroblasti tissues which distorted an features of bronchiolitis obl the lesions, predominantly ferred to as type D here.

Short chrysotile 4T30. A fibrosis, animals were trea 1985). Intratracheal instilla associated with multifocal caused by interstitial mon thelioid cells (Fig. 4B). T categorized as type B (Ta postexposure at any dose

Xonotlite. This preparati made mineral, caused no s after treatment with doses was seen in lung sections of saline-treated animals

Attapulgite. The lung re at 1 month by the presen (Fig. 6A) and readily rec





·l chrysotile (A, ×3100), An ·ican
·rt fiber fraction isolated by ·ater

·parison of the average body
: groups at all doses tested.
logical differences in relation
·tegorized as A, B, C, and D
each group are given below
: affected.

·nal lung morphology i· all
·gical features of these l· ·gs

TABLE 2
SUMMARY OF NUMBERS OF ANIMALS WITH LESIONS 1 MONTH AFTER EXPOSURE

Treatment	Dose (mg)	Number of animals examined	Body weight (g)	Number of animals with lesions			
				A	B	C	D
Saline	—	25	435 ± 6	0	0	0	0
Xonotlite	1	5	451 ± 5	0	0	0	0
	5	5	429 ± 9	0	0	0	0
	10	5	442 ± 9	0	0	0	0
UICC chrysotile B	1	5	427 ± 11	—	—	—	5
	5	5	427 ± 10	—	—	—	5
Short 4T30 chrysotile	1	5	450 ± 8	—	2	—	—
	5	10	434 ± 7	—	7	—	—
	10	5	442 ± 9	—	5	—	—
Attapulgite	1	5	438 ± 7	5	—	—	—
	5	10	438 ± 8	10	—	—	—
	10	5	454 ± 11	5[a]	—	—	—
Fiberfrax	1	5	421 ± 6	—	—	5	—
	5	10	430 ± 5	—	—	10	—
	10	5	422 ± 10	—	—	5	—

[a] One animal had a higher degree of Type A lesion.

with normal bronchioles, alveolar ducts and sacs, and alveoli. No abnormality or specific lesions were observed in this group.

UICC chrysotile B. As previously described (Lemaire *et al.*, 1985), intratracheal instillation of UICC chrysotile B fibers caused significant lesions characterized by focal fibroblastic proliferation and collagen deposition in bronchiolar tissues which distorted and obstructed small airways (Figs. 3A and 3B). These features of bronchiolitis obliterans were seen at both doses tested (1 and 5 mg) and the lesions, predominantly located in and around terminal bronchioles, are referred to as type D here.

Short chrysotile 4T30. As a positive control for inflammatory reaction without fibrosis, animals were treated with very short 4T30 chrysotile (Lemaire *et al.*, 1985). Intratracheal instillations of 1, 5, and 10 mg of 4T30 chrysotile fibers were associated with multifocal septal thickening and alveolar distortion (Fig. 4A) caused by interstitial mononuclear cell infiltration, mainly macrophages and epithelioid cells (Fig. 4B). The small airways were not affected by these lesions categorized as type B (Table 2) and no evidence of fibrosis was seen 1 month postexposure at any dose tested.

Xonotlite. This preparation of fine calcium silicate fibers, a relatively new man-made mineral, caused no significant histological alterations of rat lung. One month after treatment with doses as high as 10 mg, no evidence of inflammatory reaction was seen in lung sections examined, and the lung morphology was similar to that of saline-treated animals (Figs. 5A and 5B).

Attapulgite. The lung reaction to treatment with attapulgite was characterized at 1 month by the presence of numerous fibers entrapped in the alveolar spaces (Fig. 6A) and readily recognized as birefringent material under polarized micro-

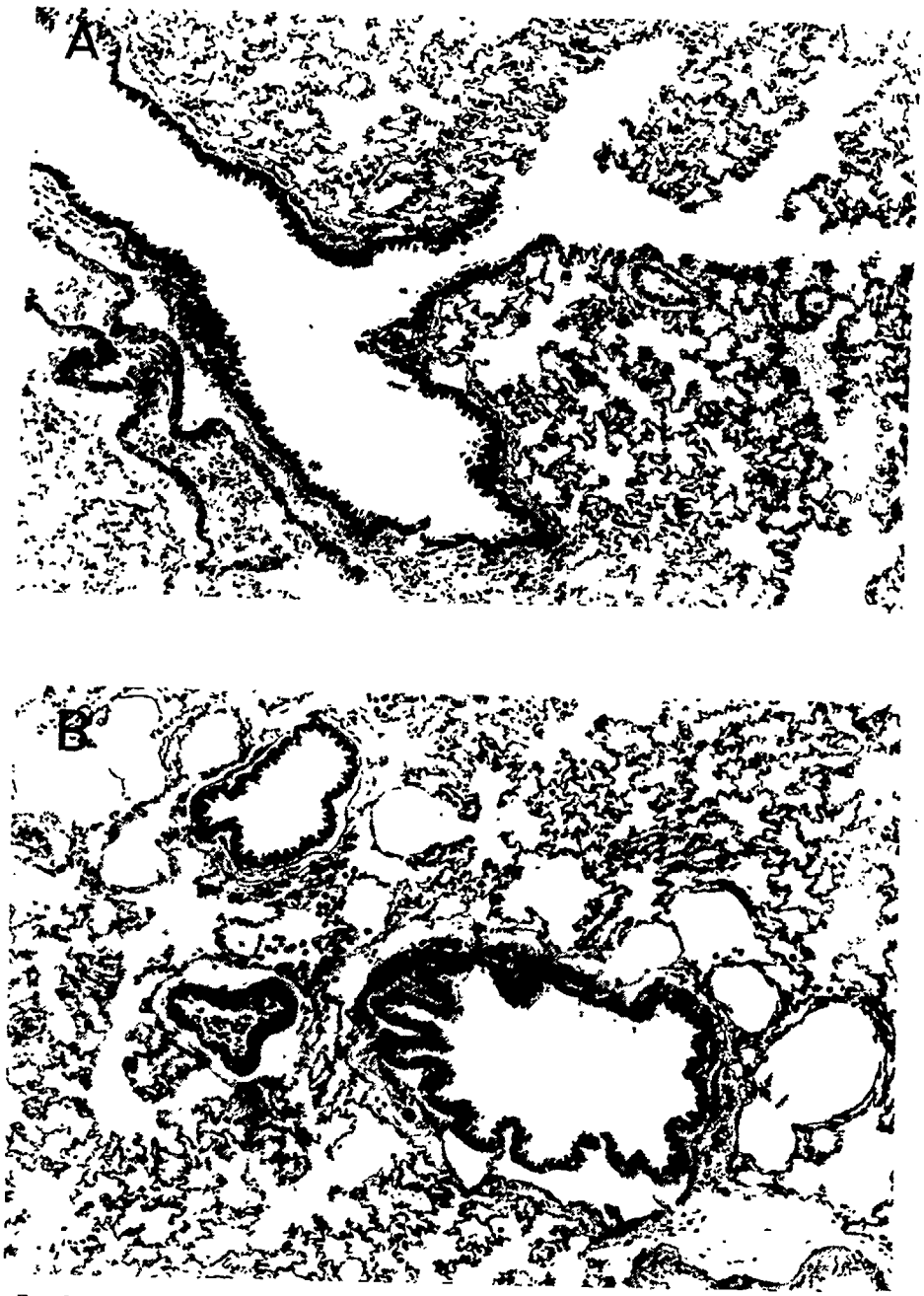

FIG. 2. Lung histopathology of saline-treated rats. Longitudinal (A, ×122) and cross sectio· ·B, ×122) representing normal bronchioles and alveolar ducts and sacs, and alveoli.



Fi· . 3. Fibrotic lesion
(B, · 122). Alveolar stru





:l (A, ×122) and cross sectic B,
.s, and alveoli.

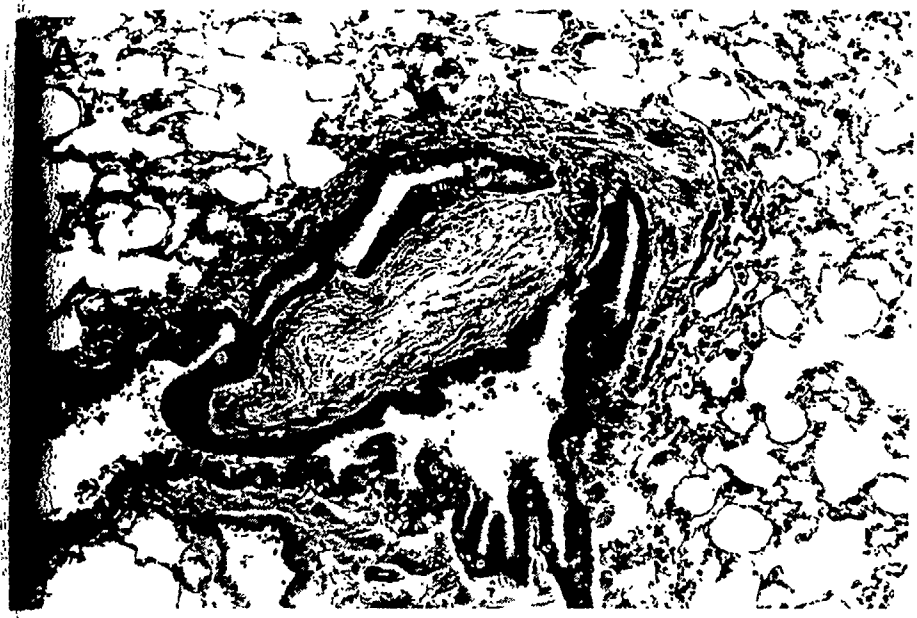

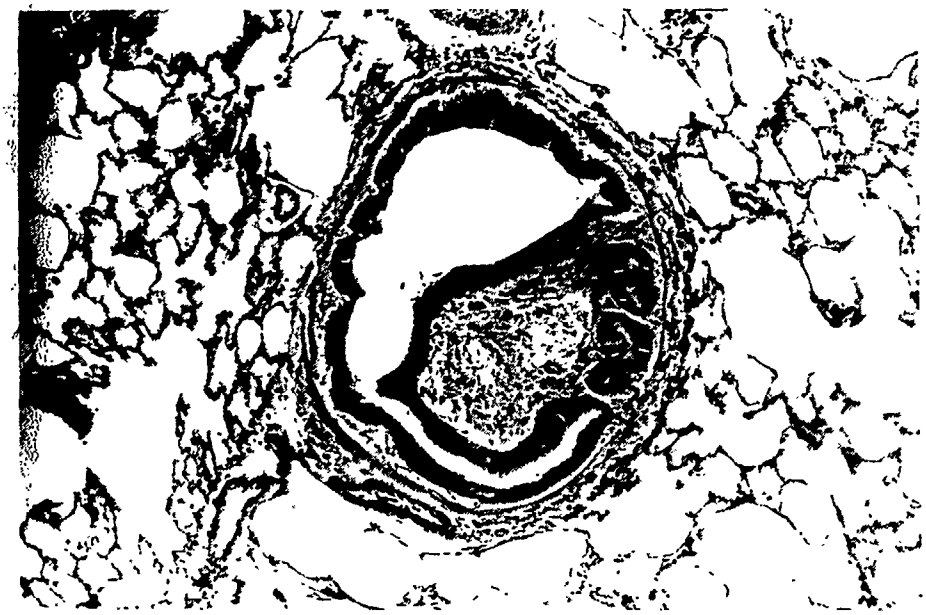

FIG. 3. Fibrotic lesions caused by UICC chrysotile B fibers (A, ×122) located in bronchiolar tissue (B, ×122). Alveolar structures are not affected.

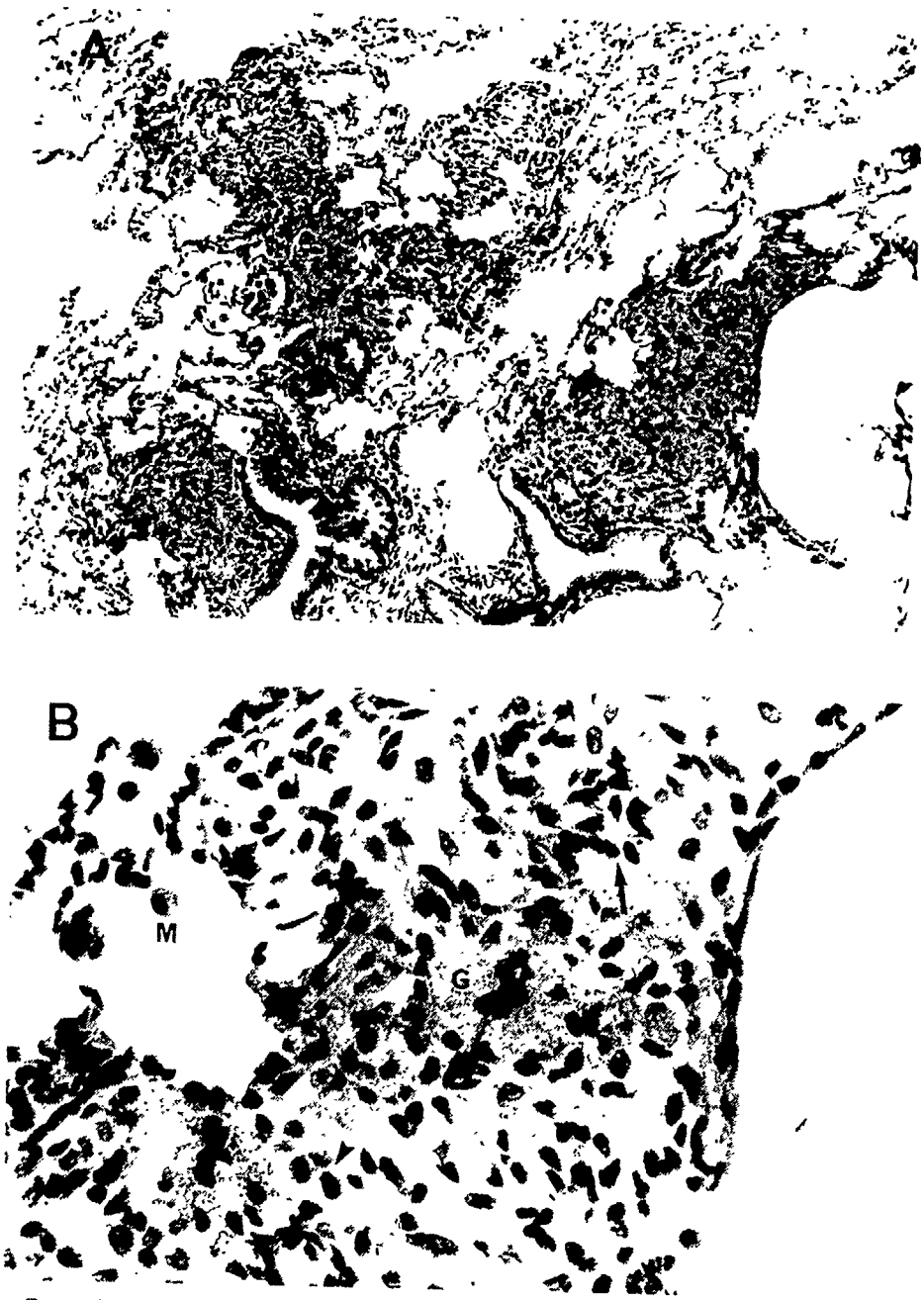

FIG. 4. Interstitial inflammatory reaction 1 month after instillation of short 4T30 chrysotile fibers. Small sheets of packed mononuclear cells obliterate the lung parenchyma (A, ×122). Accumu[illegible]on of macrophages (M), epithelioid cells (arrowhead), lymphocytes (arrow), and giant cell (G) (B [illegible]86).



FIG. 5. Lung histopathol[illegible] ×122) and alveoli (B, ×122





ıtion of short 4T30 chrysotil ners. nchyma (A, ×122). Accumu. on of row), and giant cell (G) (B, ×486).





FIG. 5. Lung histopathology of rats treated with 5 mg of xonotlite. Normal terminal bronchioles (A, ×122) and alveoli (B, ×122).

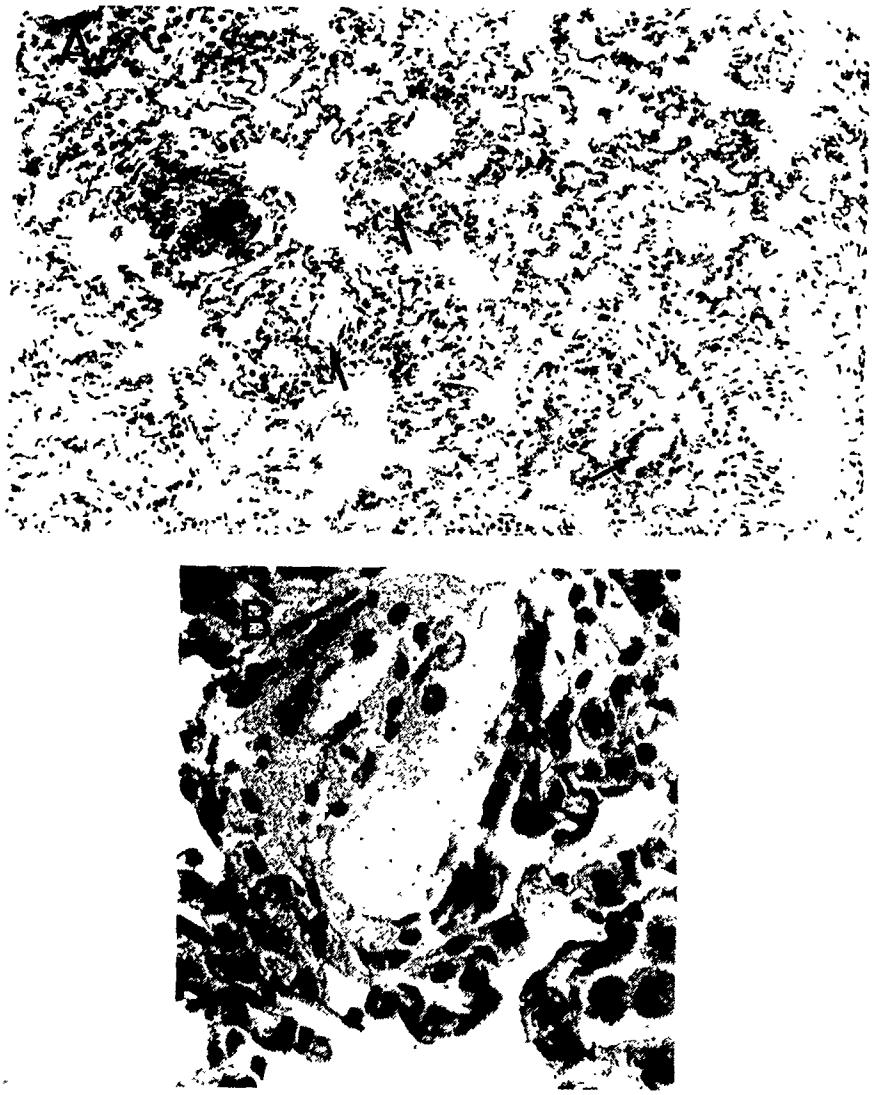

FIG. 6. Lung reaction to attapulgite. Presence of the fibers in the alveolar spaces (arrows), (A, ×122); they are easily recognized under polarized microscopic examination (B, ×486). Accumulation of large, foamy macrophages around the attapulgite fibers (C, ×486).

scopic examination (Fig. 6B). Accumulation of inflammatory cells mostly macrophages and epithelioid cells was seen around these fiber deposits and formed a compact cellular infiltrate at their periphery focally dispersed throughout the alveolar region (Fig. 6C). This lesion is referred to as type A and was observed in animals treated with 1, 5, and 10 mg of attapulgite. In this latter group, however, one animal out of five had a type A lesion of greater intensity.

Fiberfrax. Anima
changes different fr
reaction observed
phocytes (Fig. 7A)
predominantly arou
seen in these lesion
ing for collagen. Th
animals of this grou
group, however, fo
dose-related pulmo

Bronchoalveolar C

Lavage fluid rec
comparison, value
corrected for lavag
per 45 ml lavage fl
animals contained a
with no eosinophil
cytes (PMN) (Table





: the alveolar spaces (arrows). (A.
:mination (B, ×486). Accumulation
×6).

mmatory cells mostly mac-
fiber deposits and form·d a
lispersed throughout t al-
ype A and was obser\ l in
this latter group, how· ·er,
intensity.



FIG. 6—*Continued.*

Fiberfrax. Animals treated with Fiberfrax had a pattern of lung histological changes different from those previously described. The significant inflammatory reaction observed was characterized mainly by the presence of numerous lymphocytes (Fig. 7A) and epithelioid giant cells (Fig. 7B). The lesions were located predominantly around terminal bronchioles (Fig. 7C). Areas of early fibrosis were seen in these lesions although more definitive proof would require specific staining for collagen. These lesions defined as type C in Table 2 were present in all animals of this group and at all the doses tested (1, 5, and 10 mg). In the 10-mg group, however, four animals out of five had more extensive lesions suggesting a dose-related pulmonary response.

Bronchoalveolar Cell Analysis

Lavage fluid recovery was 45 ml (90%) for control animals (Table 3). For comparison, values of total cell counts in lavage fluid of treated groups were corrected for lavage fluid recovery, and all values were expressed as cell counts per 45 ml lavage fluid recovered. The BAL fluid obtained from saline-injected animals contained an average of 9.2×10^6 cells and consisted of 99% macrophages with no eosinophils, no lymphocytes, and very few polymorphonuclear leukocytes (PMN) (Table 3). Animals treated with short chrysotile fibers 4T30 exhibited

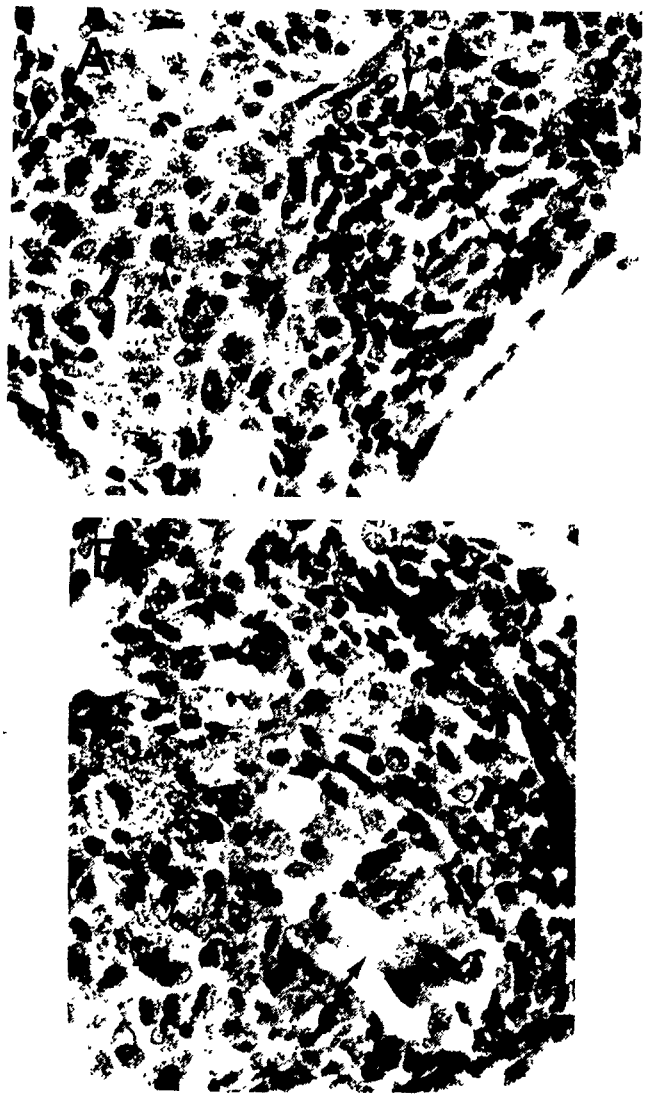

FIG. 7. Lesions caused by Fiberfrax instillation. Accumulation of epithelioid cells (arrowhead) (A, ×486), numerous lymphocytes, (arrows) (A, ×486), and giant cells (arrow) (B, ×486) around terminal bronchioles (C, ×122).

no significant change in BAL cell numbers and populations except for a small but significant increase in macrophages in the 10-mg group. By contrast, intratracheal injection of UICC chrysotile B asbestos caused a significant increase in total BAL cells recovered (14.9×10^6 cells compared to 9.2 for controls). Differential analysis further demonstrated that the total cell population contained 97% macrophages indicating that exposure to chrysotile B was associated at that stage with



FIG. 7—*Continued.*

a significant accumulation of macrophages and small increases of neutrophils and lymphocytes. Compared to saline and asbestos-treated rats, no significant change was seen in the number of BAL cells obtained from animals exposed to the calcium silicate, xonotlite. The BAL fluids of rats injected with 5 and 10 mg respectively contained an average of 10.1×10^6 and 11×10^6 cells. However, small but significant increases in neutrophils and lymphocytes were observed in the 10-mg group. On the other hand, there was a significant increase in the total number of cells recovered from the lavage fluid of animals exposed to 5 and 10 mg attapulgite (14.8×10^6 and 15×10^6 respectively compared to 9.2×10^6 for saline-treated rats). Differential analysis revealed that such increases were due mainly to macrophages and neutrophils in both groups. A significant increase in lymphocytes which represented 3.6% of total cells was also found in the 5-mg group (Table 3). Finally, 1 month after exposure to Fiberfrax, significantly higher numbers of cells were recovered after bronchoalveolar lavage. An average of 12.1×10^6 and 11.7×10^6 cells were found respectively for animals treated with 5 and 10 mg. However, in these groups the inflammatory response was characterized mainly by neutrophil (14 and 27% of total cells) and lymphocyte (5 and 4% of total cells) accumulations (Table 3).

DISCUSSION

Much of our knowledge of the interaction of fibers with tissues and their potential harmful effect to human health relates to asbestos. However, humans can be exposed to some natural and man-made mineral fibers other than asbestos, and there is now enough evidence of potential harm from a number of these materials to indicate that new fiber types should be subjected to careful testing by animal experiments. In this study, we used a rat model (Lemaire *et al.*, 1985) to evaluate the short-term biological effects of xonotlite, attapulgite, and Fiberfrax fibers on

TABLE 3
ANALYSIS OF BRONCHOALVEOLAR LAVAGE (BAL) OBTAINED FROM CONTROL AND TREATED RATS

	Saline	Xonotlite		Attapulgite		4T30		Chrysotile B		Fiberfrax	
		5	10	5	10	5	10	5	10	5	10
Total cell ($\times 10^6$)	9.2 ± 0.6	10.1 ± 0.7	11 ± 1	14.8 ± 1.2*	15 ± 0.3	10.2 ± 0.3	11.4 ± 0.5*	14.9 ± 0.5*	—	12.1 ± 0.7*	11.7 ± 0.6*
Viability (%)	95.9 ± 0.7	97 ± 1	95 ± 1	95.6 ± 0.9	94.5 ± 1	96.6 ± 0.5	95.7 ± 0.7	91.9 ± 2	—	95.7 ± 0.7	95.3 ± 0.8
BAL cell recovery %	90 ± 2	94 ± 1	91 ± 2	93 ± 1	91 ± 3	92 ± 1	86 ± 4	83.1 ± 3*	—	88 ± 2	90 ± 1
Macrophages[a]	99.9 ± 0.1	99.9 ± 0.1	95.6 ± 1*	91 ± 2*	92 ± 2*	100	100	97.2 ± 1	—	81.6 ± 1.7*	70.3 ± 3*
Neutrophils[a]	0.1 ± 0.1	0	3 ± 0.7*	6 ± 1*	8 ± 2*	0	0	1.6 ± 0.6	—	14 ± 0.7*	27.2 ± 3**
Lymphocytes[a]	0	0	1.8 ± 0.6*	3.6 ± 0.6*	0	0	0	1.2 ± 0.7	—	5 ± 0.8*	4 ± 2*
Eosinophils[a]	0	0	0	0	0	0	0	0	—	0	0

[a] Differential counts (% of total cells).
* Significantly different from control at $P < 0.05$.

the lung in comparis
chrysotile 4T30. Thr
and chrysotile 4T30
dimensional range, tr
tilite had small activi
whereas attapulgite
sections and bronch
gestion that reactivi
strictly confirmed in
μm compared to 0.8
had much less activi
tologic examination
xonotlite is two time
al., 1987). These cha
ministered may in fa
Localization of fib
diameter and second
diameter will achieve
intercepted at bifurc
tion, attapulgite and
alveolar structures v
B affected mainly th
significant percentag
chioles. However, r
asbestos, Fiberfrax
UICC chrysotile B c
associated with the
chosen in this study
various fibrous silic
lung reactivity was
chrysotile 4T30 > a
ous assumption that
Engelbrecht, 1970;
However, our data
gite, chrysotile 4T3(
observed with attap
or resolve will requi

Previous studies h
lavage may be an ir
(Reynolds *et al.*, 19
vestigators have de
in experimental silic
tosis (Dodson *et al.*
emphasized the pre
multinucleated gian
1981; Dauber *et al.*,

the lung in comparison with two "control" dusts, UICC chrysotile B asbestos and chrysotile 4T30. Three of the five materials tested, namely, xonotlite, attapulgite, and chrysotile 4T30, were short fibers in the respirable range. Despite their close dimensional range, these preparations differed in their biological activity. Xonotlite had small activity detectable only at high dose (10 mg) by BAL cell analysis whereas attapulgite and chrysotile caused mononuclear cell infiltration in lung sections and bronchoalveolar compartments at both doses tested. Thus the suggestion that reactivity decreases with fiber length (Davis *et al.*, 1985) was not strictly confirmed in our study since xonotlite which had an average length of 1.2 μm compared to 0.8 and 0.9 μm respectively for attapulgite and chrysotile 4T30 had much less activity as evidenced by bronchoalveolar lavage analysis and histologic examination. One should not forget, however, that the aspect ratio of xonotlite is two times less than that of attapulgite and chrysotile 4T30 (Nadeau *et al.*, 1987). These characteristics imply that the total fiber number by weight administered may in fact be less than that with the other two short silicate fibers.

Localization of fiber within the respiratory system depends primarily on fiber diameter and secondarily on fiber length. Fibers smaller than 5 μm and of 0.2 μm diameter will achieve greater alveolar penetration than longer fibers which may be intercepted at bifurcations of smaller bronchioles. Consistent with this assumption, attapulgite and chrysotile 4T30 caused lesions localized primarily in the alveolar structures whereas longer fibers such as Fiberfrax and UICC chrysotile B affected mainly the bronchioles. These last two preparations which contained significant percentages of longer fibers caused fibrotic lesions of terminal bronchioles. However, it should be pointed out that, contrary to UICC chrysotile asbestos, Fiberfrax sample contains only 40% fibers (Nadeau *et al.*, 1987). While UICC chrysotile B caused severe, well-advanced fibrosis, Fiberfrax exposure was associated with the appearance of early fibrosis. Therefore, at the time interval chosen in this study, one can differentiate the degree of lung reactivity to the various fibrous silicates. Based on our histological observations, the degree of lung reactivity was in the decreasing order: UICC chrysotile B > Fiberfrax > chrysotile 4T30 > attapulgite ≫ xonotlite. Overall, our study supports the previous assumption that short fibers are less fibrogenic than long fibers (Burger and Engelbrecht, 1970; Davis *et al.*, 1978) at least within the time scale studied. However, our data also indicate that three preparations of short fibers, attapulgite, chrysotile 4T30, and xonotlite, are biologically active. Whether the lesions observed with attapulgite and chrysotile 4T30 will evolve further toward fibrosis or resolve will require investigation over a longer time span.

Previous studies have indicated that the composition of cells recovered by lung lavage may be an indication of the type and severity of interstitial lung disease (Reynolds *et al.*, 1977; Weinberger *et al.*, 1978; Haslam *et al.*, 1980). Many investigators have described an accumulation of both neutrophils and macrophages in experimental silicosis (Miller and Kagan, 1977; Dauber *et al.*, 1982) and asbestosis (Dodson *et al.*, 1980; Schoenberger *et al.*, 1982; Lemaire *et al.*, 1986) and emphasized the predominance of the latter. Additionally, increased numbers of multinucleated giant cells were reported in these pathogeneses (Richards *et al.*, 1981; Dauber *et al.*, 1982; Lemaire *et al.*, 1985). In our study, the recovery of cells

Differential counts (% of total cells)
* Significantly different from control at $P < 0.05$.

from lavaged lungs was similar with the various silicates tested except ch, sotile B, indicating that retention of free cells within the lung spaces due to blockage of certain areas of the lung did not occur and that lungs were effectively sampled by lavage. However, major differences in the quality and intensity of the inflammatory response were observed in relation to treatment. Exposure to xonotlite (5 mg) was not associated with a significant inflammatory reaction in the bronchoalveolar compartment. This correlated well with the absence of pathological changes in the lung tissue. However, on the basis of our observation of a small increase in the number of neutrophils 1 month after exposure at the highest dose tested (10 mg), one cannot exclude the possibility that a chronic inflammatory response and subsequent lung lesion may develop with time. In this regard, recent *in vitro* studies have reported a cytotoxic effect of xonotlite for rat alveolar macrophages (Nadeau *et al.*, 1987). Since many dusts cytotoxic to macrophages *in vitro* have been usually found to cause fibrosis *in vivo* (Styles and Wilson, 1973; Da ..s *et al.*, 1980) further follow-up studies are currently in progress to clarify tl . By contrast, attapulgite and Fiberfrax exposure gave rise to chronic inflammatory reactions in the bronchoalveolar compartment. The increase in the number of cells recovered was not dose dependent in both cases indicating that the response was already maximal at a dose level of 5 mg. While attapulgite caused accumulation of macrophages, neutrophils, and lymphocytes, Fiberfrax exposure was associated mostly with neutrophil and lymphocyte infiltration. Thus these materials with different physicochemical properties induced selective changes in the cell populations. Whether this represents a different mechanism of interaction which could eventually result in two types of lung injury (absence or presence of fibrosis) or different stages of a common cellular pathway involved in fibrogenesis is unknown. Neutrophils have been implicated in the pathogenesis of pulmonary fibrosis and the pneumoconiosis (Hunninghake *et al.*, 1979; Crystal *et al.*, 1981). Similarly macrophage has been shown to be one of the major cell types involved in the response to various fibrogenic dusts including asbestos (Holt *et al.*, 1966; Becklake, 1976; Tetley *et al.*, 1976; Warheit *et al.*, 1984; Lemaire *et al.*, 198. and silica (Miller and Kagan, 1977; Dauber *et al.*, 1982). The exact relationship between the nature of the inflammatory response and the induction of fibrosis is not clear. However, neutrophils are able to produce a number of proteases and in particular collagenase (Gadek *et al.*, 1979) which may initiate changes in lung metabolism. In addition, macrophages also produce a variety of enzymes and cytokines (Fels and Cohn, 1986; Nathan, 1987) including growth factors and interleukin-1, all of which can stimulate fibroblast activity directly. Interestingly, the silicates tested in our study, namely, attapulgite and Fiberfrax, and to a lesser extent xonotlite, increased significantly the number of neutrophils. Moreover attapulgite and Fiberfrax also induced alterations of macrophage morphology and appearance of multinucleated giant macrophages in the lavage fluids and lung sections. Furthermore, the observation of birefringent materials in the case of attapulgite may be indicative of the persistence of the material within the alveolar structures. Therefore, the reaction to injected attapulgite and Fiberfrax i: ats included some of the histologic and cellular features of asbestos-induced fib sis. In conclusion, our study demonstrates that attapulgite, Fiberfrax, and xon. lite

cannot be conside
extrapolated to co
health effect from
ations.

The authors thank D
and B. Mason for exce

Becklake, M. R. (1976
and implications fo
Begin, R., Massé, S., P
tien, P. (1987). The
Burger, B. F., and Em
reference asbestos
Crystal, R. G., Gadek
(1981). Interstitial l
Med 70, 542–568
Dauber, J. H., Rossma
types and impaired
226–236.
Davies, R., Chamberlai
eral dusts using ma
181–184.
Davis, J. M. G., Becke
number of fibres in
673–688.
Davis, J. M. G., Bolton
A. (1985). Compari
assay systems. *In*
pp. 405–411. NATO
Dodson, R. F., Willian
"amosite": A corr
Lung 157, 143–154
Funk, H. (1965). Chem
treatment. *In* "Sy
University of Lond
Gadek, J. E., Kalman,
S. D., and Crystal
idiopathic pulmona
Haden, W. L., Jr. (196
Haden, W. L., Jr., and
Chem. 59, 58–69.
Harvey, G., Pagé, M.
mineral fibers. *Br*
Haslam, P. L., Turto
Turner-Warwick, M
obtained with lung
Hénin, S., and Caller
Vol. 2, pp. 335–3
Holt, P. F., Mills, J., a
J. Pathol. Bacteri

cannot be considered as biologically inert. Although, these results cannot be extrapolated to conditions of human exposure, the possibility of a deleterious health effect from these widely used silicate fibers warrants special considerations.

ACKNOWLEDGMENTS

The authors thank Dr. M. Keaney, J. Craigie, and M. St. Jean for competent technical assistance and B. Mason for excellent secretarial help.

REFERENCES

Becklake, M. R. (1976). Asbestos-related diseases of the lung and other organs: Their epidemiology and implications for clinical practice. *Amer. Rev. Respir. Dis.* 114, 187–227.

Begin, R., Massé, S., Rola-Pleszezynski, M., Geoffrey, M., Martel, M., Desmarais, Y., and Sebastien, P. (1987). The lung biological activity of American attapulgite. *Environ. Res.* 42, 328–339.

Burger, B. F., and Engelbrecht, F. M. (1970). The biological effects of the international standard reference asbestos samples (UICC) on the lungs of rats. *S. Afr. Med. J.* 44, 1271–1274.

Crystal, R. G., Gadek, J. E., Ferrans, V. J., Fulmer, J. D., Line, B. R., and Hunninghake, G. W. (1981). Interstitial lung disease: Current concepts of pathogenesis, staging and therapy. *Amer. J. Med.* 70, 542–568.

Dauber, J. H., Rossman, M. D., and Daniele, R. P. (1982). Pulmonary fibrosis: Bronchoalveolar cell types and impaired function of alveolar macrophages in experimental silicosis. *Environ. Res.* 29, 226–236.

Davies, R., Chamberlain, M., Brown, R. C., and Griffiths, D. M. (1980). Identification of toxic mineral dusts using mammalian cells. Transactions of the Royal Society of Edinburg. *Earth Sci.* 71, 181–184.

Davis, J. M. G., Beckett, T., Bolton, R. E., Collings, P., and Middleton, A. P. (1978). Mass and number of fibres in the pathogenesis of asbestos-related lung disease in rats. *Brit. J. Cancer* 37, 673–688.

Davis, J. M. G., Bolton, R. E., Cowie, H., Donaldson, K., Gormley, I. P., Jones, A. D., and Wright A. (1985). Comparisons of the biological effects of mineral fibre samples using in vitro and in vivo assay systems. *In* "In Vitro Effectes of Mineral Dusts" (E. G. Beck and J. Bignon, Eds.), Vol 3, pp. 405–411. NATO ASI Series G: Ecological Sciences, Springer-Verlag, Heidelberg.

Dodson, R. F., Williams, M. G., and Hurst, G. A. (1980). Early response of free airway cells to "amosite": A correlated study using electron microscopy and energy dispersive X-ray analysis. *Lung* 157, 143–154.

Funk, H. (1965). Chemical alteration of poorly crystallized calcium silicate hydrates by hydrothermal treatment. *In* "Symposium on Autoclaved Calcium Silicate Building Products," pp. 122–123. University of London, School of Pharmacy, London.

Gadek, J. E., Kalman, J. A., Fells, G., Weinberger, S. E., Horwitz, A. L., Reynolds, H. Y., Fulmer, S. D., and Crystal, R. G. (1979). Collagenase in the lower respiratory tract of patients with idiopathic pulmonary fibrosis. *N. Engl. J. Med.* 301, 737–742.

Haden, W. L., Jr. (1963). Attapulgite: Properties and uses. *Clays Clay Miner.* 10, 284–290.

Haden, W. L., Jr., and Schwint, I. A. (1967). Attapulgite: Its properties and applications. *Ind. Eng. Chem.* 59, 58–69.

Harvey, G., Pagé, M., and Dumas, L. (1984). Binding of environmental carcinogens to asbestos and mineral fibers. *Brit. J. Ind. Med.* 41, 396–400.

Haslam, P. L., Turton, C. W. G., Heard, B., Lukosek, A., Collins, J. V., Salsbury, A. J., and Turner-Warwick, M. (1980). Bronchoalveolar lavage in pulmonary fibrosis: Comparison of cells obtained with lung biopsy and clinical features. *Thorax* 35, 9–18.

Hénin, S., and Caillère, S. (1975). Fibrous minerals. *In* "Soil Components" (J. E. Gieseking, Ed.), Vol. 2, pp. 335–349. Springer-Verlag, New York.

Holt, P. F., Mills, J., and Young, D. K. (1966). The early effects of chrysotile asbestos on the rat lung. *J. Pathol. Bacteriol.* 87, 15–23.

Hunninghake, G. W., Gadek, J. E., Kawanami, O., Ferrans, U. J., and Crystal, R. G. (1979 nflammatory and immune processes in the human lung in health and disease: Evaluation by bronchoalveolar lavage. *Amer. J. Pathol.* 97, 149–206.

Jaurand, M. C., Bignon, J., Magne, L., Renier, A., and Lafuma, J. (1979). Interaction des fibres avec les globules rouges et les macrophages alvéolaires in vitro. *Rev. Fr. Mal. Respir.* 7, 717–722.

Jolicoeur, C., Roberge, P., and Fortier, J. L. (1981). Separation of short fibers from bulk chrysotile asbestos fiber materials: Analysis and physico-chemical characterization. *Canad. J. Chem.* 59, 1140–1148.

Lemaire, I. (1985). Characterization of the bronchoalveolar cellular response in experimental asbestosis. Different reactions depending on the fibrogenic potential. *Amer. Rev. Respir. Dis.* 131, 144–149.

Lemaire, I., Nadeau, D., Dunnigan, J., and Massé, S. (1985). An assessment of the fibrogenic potential of very short 4T30 chrysotile by intratracheal instillation in rats. *Environ. Res.* 36, 314–326.

Lemaire, I., Beaudoin, H., Massé, S., and Grondin, C. (1986). Alveolar macrophage stimulation of lung fibroblast growth in asbestos-induced pulmonary fibrosis. *Amer. J. Pathol.* 122, 205–211.

Miller, K., and Kagan, E. (1977). The in vivo effects of quartz on alveolar macrophage membrane topography and on the characteristics of the intrapulmonary cell poulation. *J. Reticuloendothel. Soc.* 21, 307–316.

Nadeau, D., Fouquette-Couture, L., Paradis, D., Khorami, J., Lane, D., and Dunnigan, J 1987). Cytotoxicity of respirable dusts from industrial minerals: Comparison of two naturally occurring and two man-made silicates. *Drug Chem. Toxicol.* 10, 49–86.

Nadeau, D., Paradis, D., Gaudreau, A., Pelé, J. P., and Calvert, R. (1983). Biological evaluation of various natural and man-made mineral fibers: Cytotoxicity, hemolytic activity and chemiluminescence study. *Environ. Health Perspect.* 51, 374.

Reynolds, H. Y., Fulmer, J. D., Kazmierowski, J. A., Roberts, W. C., Frank, M. M., and Crystal, R. G. (1977). Analysis of cellular and protein content of bronchoalveolar lavage fluid from patients with idiopathic pulmonary fibrosis and chronic hypersensitivity pneumonitis. *J. Clin. Invest.* 59, 165–175.

Richards, R. J., Tetley, T. D., and Hunt, J. (1981). The biological reactivity of calcium silicate composites: *In vivo* studies. *Environ. Res.* 26, 243–257.

Schoenberger, C. I., Hunninghake, G. W., Kawanami, O., Ferrans, V. J., and Crystal, R. G. (1982). Role of alveolar macrophages in asbestosis: Modulation of neutrophil migration to the lung after acute asbestos exposure. *Thorax* 37, 803–809.

Selikoff, I. S., and Cuyler Hammond, E. (1979). Health hazards of asbestos exposure. *Ann. N.Y. Acad. Sci.* 330, 1–814.

Selikoff, I. J., and Lee, D. J. K. (1978). "Asbestos and Disease." New York, Academic Pre

Skaug, V., Davies, R. and Gylseth, B. (1984). In vitro macrophage cytotoxicity of five calcium silicates. *Brit. J. Ind. Med.* 141, 116–121.

Styles, J. A., and Wilson, J. (1973). Comparison between in vitro toxicity of polymer and mineral dusts and their fibrogenicity. *Ann. Occup. Hyg.* 16, 241–250.

Tetley, T. D., Hert, P. M., Richards, R. J., and McDermott, M. (1976). Chrysotile-induced asbestosis: Changes in the free cell poulation, pulmonary surfactant and whole lung tissue of rats. *Brit. J. Exp. Pathol.* 57, 505–514.

Timbrell, V. (1970). Characteristics of the international union against cancer standard reference samples of asbestos. *In* "Pneumoconiosis" (Proceedings of an International Conference, Johannesburg), pp. 28–36.

Warheit, D. B., Chang, I. Y., Hill, L. H., Hook, G. E. R., Crapo, J. D., and Brody, A. R. (1984). Pulmonary macrophage accumulation and asbestos-induced lesions at sites of fiber deposition. *Amer. Rev. Respir. Dis.* 129, 301–310.

Washabaugh, F. J. (1983). (to Engelhard Corp., Edison, NJ). U.S. Patent 4, 373, 037.

Weinberger, S. E., Kelman, J. A., Elson, N. A., Young, R. C., Jr., Reynolds, H. Y., Fulmer, J. D., and Crystal, R. G. (1978). Bronchoalveolar lavage in interstitial lung disease. *Ann. Intern Med.* 89, 459–466.

Impairment of
to N

Basic Medical Sci

The relationship
mains unknown b
To investigate wh
exposure on immu
gen dioxide (NO_2
days. Organ weigh
cells (SRBC), and
weights in mice e
periods. The weig
mixture were dec
weights of both o
to O_3 or the mixtu
not show the sup
antibody response
to O_3 or the mixtu
modify the effects
Press, Inc.

Immune respon
fection, inflammat
mechanisms in the
oxide (NO_2) and
mentally, the local
ozone on immune
roth, 1976; Joel
Driscoll *et al.* 198
O_3 exposure on an
and showed the in
al. 1982; Ozawa
the effect of air
especially import
known about the
et al. (1977) show
resistance to strep
whether the effec
T-cell-dependent
not.

EISSGAR-
AND URI
SSOR CELL
. . . 1

URITANI,
AMAYA.
ERAL EN-
I INTAKE
. . . 7

IPS, AND
FAIR IN A
. . . 17

ANCER IN
STE DIS-
W YORK 29

EVALUA-
THE RE-
. . . 42

ID DIS-
TYRHYN-
. . . 49

ONSE OF
-EPOXY
. . . 57

DOMI-
CHID-
ATMENT
CE AND
. . 70

IDE BACK COVER

Environmental Research

A Journal of Environmental Medicine
and the Env[illegible]

UT SOUTHWESTERN
MEDICAL CENTER
AT DALLAS
APR 26 1989
NOT TO BE TAKEN
FROM LIBRARY

EDI[illegible]
Phili[illegible]

SENIOR C[illegible]
Irvi[illegible]

MANAGING EDITOR
José A. Valciukas

ASSOCIATE EDITORS

E. Baker	R. Lauwerys	G. S. Omenn
D. V. Bates	R. Lilis	D. P. Rall
T. W. Clarkson	C. Maltoni	E. K. Silbergeld
D. Hoel	M. A. Mehlman	Y. Suzuki
B. Holmberg	H. Needleman	K. Tsuchiya

ISSN 0013-9351

This Number Completes Volume 48
Volume 48, Number 2, April 1989