DEPOSITION EXHIBIT OMC
Repageorge
11-1D 8.28.81

N.Y. STATE JOURNAL OF MEDICINE, 43, (1943).

OCCUPATIONAL ACNE

Louis Schwartz, M.D., and Samuel M. Peck, M.D., Bethesda, Maryland

OCCUPATIONAL acne is one of the most frequent forms of occupational dermatitis. It occurs among workers exposed to certain chemicals which, when lodged in the pores of the skin, may not only plug the openings and cause the retention of the secretions of the glands but also act as stimulants for the formation of keratin and thus lead to comedo formation and occupational acne.

Occupational acnes occur among the workers exposed to the following chemicals:

Chemical	Occupation
Insoluble cutting oils and to some extent soluble cutting oils	Machinists
Crude petroleum	Oil-field workers, paraffin pressmen, oil refiners
Coal tar	Makers and distillers of coal tar
Heavy coal-tar distillates	Creosoting of wood, roofers, road makers
Coal-tar pitch	Conduit makers, briquette makers, electrical apparatus insulators
Chlornaphthalenes	Electrical insulators
Chlordiphenyls	Electrical insulators
Chlordiphenyloxide	Electrical insulators
Solid chlorbenzols	Chemical workers
Solid chlorphenols	Chemical workers

By far the largest number of workers with occupational acne are those who are exposed to the insoluble cutting oils. This is accounted for not by the fact that the cutting oils are the most potent acne-formers, but because more workers are exposed to their actions and fewer precautions are taken to protect them. The most potent of all these chemicals, as far as their acne-forming properties are concerned, are the chlornaphthalenes, chlordiphenyls, and chlordiphenyloxides. Every worker sufficiently exposed to these three substances for a few months will develop acne-like lesions on the exposed parts unless the most stringent rules of cleanliness for clothes and body are observed. However, fewer workers are exposed to these chlor compounds than to any of the other acne producers. Therefore, the cases of so-called chloracnes reported in the past have been relatively infrequent. The acceleration of shipbuilding that has occurred since the war has increased the use of wires insulated with these chlor compounds and, with this, the number of so-called chloracnes.

The acneform lesions caused by the chlor compounds are more striking than those produced by the other acne-forming substances. Only from the chlor compounds has acne occurred not only in the worker but also in his immediate family and even among those who wash his soiled work-clothes. Although the acnes caused by these organic chlor compounds have been called "chloracnes," yet chlorine gas itself causes no acne-like lesions. Neither do the inorganic compounds of chlorine cause them, either by external contact or internal administration. Nor do the acneform lesions occur among workers with the solvent chlorinated hydrocarbons although all of the solvents can injure the skin by direct contact and can cause systemic poisoning when absorbed. Naphthalene, diphenyl, benzol, or phenol without chlorination do not cause acneform lesions. Only when they are combined with chlorine do they have this effect upon the skin. While benzol and phenol alone can cause systemic poisoning, naphthalene and diphenyl have only been observed to cause it when combined with chlorine. Moreover, only the highly viscid or amorphous solid combinations of these substances have been observed to cause acneform lesions.

Solid Chlornaphthalenes

These chemicals are made by the chlorination of naphthalene, the hydrogen of the naphthalene being replaced by chlorine. Any number of the hydrogen atoms can be replaced, forming mono-di, etc., chlornaphthalenes. Those that cause occupational acnes begin with trichlornaphthalene and go on to higher chlorinations of naphthalenes and are used as dielectrics on condensers and insulators of wires. They may be combined with the chlordiphenyls.*

Workers engaged in manufacturing the chlornaphthalenes, those engaged in coating wires or condensers with it, and those who strip wires insulated with it are the ones who have been found to be affected with acne. Some workers engaged in coating wires and condensers with it have been reported to have died of yellow atrophy of the liver.[1,2,3,4]

Workers with the chlornaphthalenes usually develop acne on the face after a month or more of

Read by invitation at the Annual Meeting of the Medical Society of the State of New York, Buffalo, May 5, 1943.

From the Dermatoses Investigations Section, Division of Industrial Hygiene, National Institute of Health, U.S. Public Health Service.

Medical Director and Senior Surgeon (R), respectively, of the U.S. Public Health Service.

* Known by the trade name "Halowax." Under this trade name are included many combinations for insulating, some of which do not contain chlorinated hydrocarbons.

WATER_PCB-SD0000039080

Da To	Age	Location			
Acne vulgaris	11-25 years	Face Shoulders Back Chest	Nothing specific; no industrial exposure	Comedones, follicular papules and pustules; skin greasy and usually associated seborrhea capitis	Widely distended follicular orifice filled with keratinous material and sebaceous material. Cocci in keratin plug. Sebaceous glands hypertrophied. Foreign-body granuloma may be present
Cutting oil Soluble (rare) Insoluble Crude petroleum	Any age	Usually on exposed parts Extensors of forearms and thighs in contact with soiled clothes	Occupational exposure, such as in machinists in oil fields and oil refineries, and paraffin pressmen	Folliculitis, pustules, furuncles, and even carbuncles. Inflammation around and in acne-like lesions. Comedones on fingers, back of hands, forearms, and back of neck	Comedo formation but inflammatory reaction around hair follicles and in epidermis and throughout cutis is a striking feature. No cocci seen
Coal tar Heavy coal-tar distillates Coal-tar pitch	Any age	Usually on extensor surfaces of arms and thighs and where soiled work clothes touch skin	Found in makers and distillers of coal tar, in workers creosoting wood and in roofing and road workers. Workers such as conduit makers, briquette makers	Melanosis, comedones, and small yellowish cysts. Not inflammatory except when scratched and infected	Melanin in epidermis and in chromatophores below it. Relatively little inflammatory reaction. No cocci. Widened follicular openings plugged with keratinous material. Cysts filled with keratinous and some sebaceous material
Chlornaphthalenes Chlordiphenyls Chlordiphenyloxide	Any age	Face, back of ears, shoulders, abdomen, around navel, groin, genitalia	Occupational exposure in the manufacture of chemicals for insulating wires and condensers. Electricians using heat and flame-proof wires; machinists exposed to cutting oil containing chlorinated hydrocarbons	Comedones not so prominent as straw-colored cysts. Not inflammatory except when secondarily infected	Cystic lesions predominate, with the absence of cocci in the keratinous material filling widened follicular openings. Otherwise can resemble acne vulgaris but cysts have more keratin than sebaceous material
Solid chlorbenzols Solid chlorphenyls	Any age	Face Anterior surface of body	Occupational exposure in chemical workers	Comedones not prominent. Cysts less prominent than from chlornaphthalenes. There may be an inflammatory allergic dermatitis	Except for allergic dermatitis, essentially that of the chlornaphthalenes

exposure. The covered parts of the body are also often affected because of contact with soiled workclothes. It is not at all unusual to find comedones and acne-like lesions around the umbilicus, the thighs, and in the groin.

The individual lesions may be from pinhead to pea size. They are pale, straw-colored cysts and usually do not show inflammatory changes, unless they have been infected by scratching or other trauma (Fig. 1). They usually remain stationary in size after a few months and show no tendency to involution. While secondary infections resulting in pus formation may occur, they are not nearly so frequent as they are in acne vulgaris.

Chlordiphenyls

Diphenyl ($C_{12}H_{10}$) is a light-yellow crystalline solid made from benzol. It is chlorinated in a manner somewhat similar to that described for naphthalene. The chlordiphenyls* are dielectrics and may be used alone or in combination with the chlornaphthalenes for this purpose. Workers who are exposed to them develop lesions similar to those described under the chlornaphthalenes.

Chlordiphenyloxide

Chlordiphenyloxide is a light, straw-colored semisolid compound made by chlorinating diphenyloxide ($C_{12}H_{10}O$). It is used as a dielectric and causes, in workers who are exposed to it, acne-like lesions similar to those described under the chlornaphthalenes.

* Known by the trade name "Aracldor."



FIG. 1. Acne from chlornaphthalenes and chlordiphenyls (Halowax).

That the acne-like lesions produced by these compounds are caused by contact is borne out by the fact that the lesions occur on the parts exposed either directly to the substances themselves or to clothes soiled with them. Experimental local reproduction of the lesions has been accomplished by long-continued application of these substances.[4,5]

The mechanism of the formation of comedones and cysts is probably as follows: The fine particles of these chlor compounds arising from the actual substance or condensation on the skin from hot vapors and solutions mechanically plug the pores and lead to the formation of a comedo by the keratogenous action of the material on the endothelial lining of the gland. As this action continues it leads to the formation of the cyst.

Histopathology of Acne from Mixture of Chlornaphthalenes and Chlordiphenyls.—The histology has been described in previous publications.[7] Characteristic of the pathologic picture was the sebaceous cyst rather than the comedo. In sections from typical lesions many large sebaceous glands can be seen, some of them forming huge



FIG. 2. Lesion produced by chlornaphthalenes and chlordiphenyls. Large sebaceous cyst filled with keratinous material.

cysts filled with keratinous material and very little sebaceous material (Fig. 2). Associated with such cysts are wide follicular openings filled with keratinous material and hyperplastic follicular walls. Cocci are not evident in the follicular plugs. Just as in acne vulgaris, foreign-body granulomas occur. They are due to the same mechanism—a rupture of the wall of a cyst and contact of the sebum with the collagen. When this occurs, the same type of foreign-body granuloma as that seen in acne vulgaris is noted—that is, foreign-body giant cells or Langerhans' cells, leukocytes, lymphocytes, and fibroblasts. Leukocytes can also be seen in the comedo itself. The striking feature, however, is the cyst formation with keratinization which extends to include the cyst wall.

Histopathology of Chlordiphenyloxide Acne.—In the sections which we have studied,* the follicular hyperkeratosis with the enlargement of the follicular openings and keratinous material filling the orifice was much more prominent than the changes in the sebaceous glands, evidently young lesions. In such markedly large follicular openings many lanugo hairs were sometimes seen

* These sections were made by Earl D. Osborne, M.D., Buffalo, from cases which the authors saw with him.

WATER_PCB-SD0000039081



FIG. 3. Aceneform lesions from coal-tar pitch.

so that several follicles seemed to have a common opening. The surrounding epidermis also showed a hyperkeratosis but no acanthosis. Around many of these hypertrophied follicles, especially when the hairs were of the more adult type, there was an inflammatory exudate, consisting of lymphocytes, polymorphonuclears, and eosinophils. While clinically the same yellowish cyst-like lesions were seen, in many of the cases the sections represent changes in very early lesions. Otherwise the histology is like that of acne from chlorinated naphthalene compounds.

Coal Tar, Coal-Tar Pitch, and Heavy Coal-Tar Distillates

From the volatile substances derived from the distillation of coal there are taken off benzol, toluol, solvent naphtha, and ammonium sulfate. The remaining product is subjected to fractional distillation and is divided into light, medium, and heavy coal-tar oils. The residue after distillation is known as coal-tar pitch.

Workers in coal-tar plants sometimes develop aceneform lesions but not so frequently as do workers who handle the heavy coal-tar distillates and coal-tar pitch. This is true because the distillation process is almost totally enclosed and only a few workers come in contact with that portion of the coal tar that is active in producing aceneform lesions. Melanosis and photosensitivity, however, occur fairly frequently among workers who break up the coal-tar pitch and

In manufacturing processes in which heavy coal-tar oils and coal-tar pitch are used, there is a high incidence of aceneform lesions, melanosis, and photosensitization. In such manufacturing processes as in conduit making, where paper cylinders are impregnated with coal-tar creosote, in roofing, where paper impregnated with heavy coal-tar distillate is handled, and in road making, where coal-tar pitch is heated, the incidence of aceneform lesions, photosensitivity, and melanosis is high.

The aceneform lesions caused by coal tar and its distillate are accompanied by melanosis. The individual lesions are smaller than those caused by the chlorinated hydrocarbons, but they still have the same essential characteristics (Fig. 3). The distribution of the lesions, however, is somewhat different. They usually affect the face, the arms, and the thighs; rarely, if ever, are they found around the umbilicus, in the groin, or other regions where acne-like lesions occur from exposure to the chlorinated hydrocarbons. The keratogenous changes caused by coal tar and its distillates sometimes go on to epithelioma.

Histopathology of Pitch Acne.—Three lesions were studied: A comedo from the chest, a papule on the back of the left arm surrounding a comedo, and a lesion on the left thigh which appeared clinically as an inflammatory papule. In each instance the predominant lesion was a comedo with its wide follicular opening filled with keratinous material and having thickened walls. The epidermis seemed normal. No cocci could be seen in this keratinous material. There was very little surrounding inflammation. The melanin formation was a striking feature. It was not only found in the basal cells and in the cells above them but it was also found in chromatophores just below the epidermis (Fig. 4). No foreign-body granuloma was seen in any of the sections. Enlarged sebaceous glands were not a striking feature.

Crude Petroleum and Cutting Oils

Crude petroleums have a varied composition depending upon their source. For chemical purposes they can be classified as follows: paraffin base, naphthenic base, asphaltic base, and mixed bases. The different varieties of crude petroleum however, have many substances in common —namely, a mixture of hydrocarbons, nitrogen, oxygen, sulfur, and organic and inorganic substances held in suspension or solution.

The workers employed in oil fields where the wells are free-flowing are not so frequently affected by dermatoses as are those employed in fields where there is pumping. This is because in free flowing wells or gushers workers have com-

the wells are pumped, it is often necessary to remove the casing from the well in order to clean it and the pumps. However, even among such workers, aceneform lesions are much less frequent than they are among workers who use specially treated mineral oils for industrial purposes.

There are keratotic lesions seen on the skin of workers in oil fields located in tropical or subtropical climates. These are as likely to be due to the solar radiation as to contact with the oil.

Cutting Oils

Cutting oils are divided into two classes: the soluble and the insoluble.

Soluble oils usually consist of sulfonated petroleum oils highly diluted with water and are used mainly for cooling the cutting tool. The oil is added for its antirust properties. Although aceneform lesions occur on workers exposed to the soluble cutting oils, they are nevertheless infrequent as compared to those seen among workers with the insoluble cutting oils.

The insoluble cutting oils are by far the principal causes of so-called occupational acnes (and folliculitis). The oils are universally used on machine tools. Their composition varies according to the type of machinery that they are used for and according to the secret formulas of their manufacturers. However, basically they usually consist of a large percentage of a more or less refined petroleum oil to which are added a comparatively small amount of animal or vegetable oil (so-called lard oil), sulfur, and an inhibitor for the purpose of preventing the deterioration of the fatty oil content. To some oils a chlorine compound may be added.[7]

Most of the cutting-oil acnes occur on the extensor surfaces of the forearms and the thighs because the men work with bare arms and lean against the machines and because the anterior surface of the thighs are in contact with the oil-soaked trousers.

The lesions usually begin as a folliculitis. Inflammatory reactions are the rule in contradistinction to the aceneform lesions from tar and chlorinated hydrocarbon. Comedones are often present, but so are pustules, furuncles, and even carbuncles (Fig. 5). It has long been thought that the inflammation was caused by pathogenic bacteria in the cutting oils, but repeated attempts to culture pyogenic organisms from these oils have failed. Secondary infections of the lesions can occur but not from bacteria in the oils.* Rather, they occur from the bacteria on the skin or on the clothes (see Table 1).

From oils which contain solid chlorinated hydrocarbons, aceneform lesions can appear which

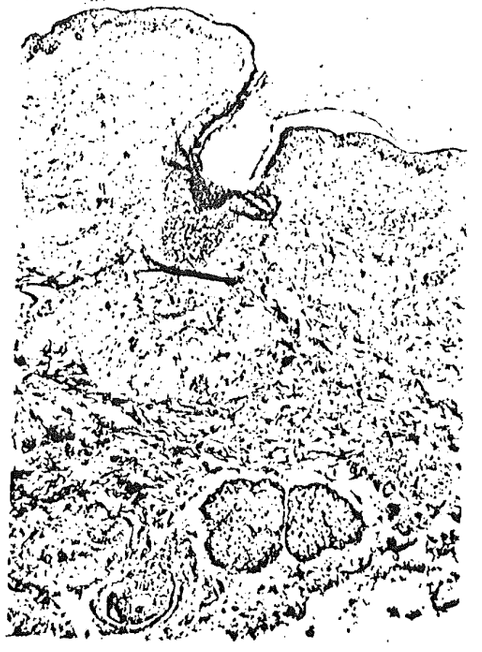

FIG. 4. Histopathology of pitch acne. A comedo is seen. There is melanin in epidermis in chromatophores.

are similar to those described under the chlorinated hydrocarbons, especially if the cutting operation generates sufficient heat to vaporize the chlorinated hydrocarbon.

The folliculitis caused by cutting oils is due either to the sulfur, the chlorine, the inhibitor, or the sulfur dioxide, hydrogen sulfide, or other compounds generated by the heat of the cutting operation.

Allergic eczemas may occur because of sensitivity to any of the ingredients in the cutting oil. These manifest themselves in the form of a dermatitis and not an acne. Its occurrence is relatively infrequent. The sensitivity can be demonstrated in such cases by patch testing with the oil. A folliculitis may be produced if an insoluble cutting oil is permitted to remain on the skin under a patch for many days, but this is not a reaction of sensitivity.

Histopathology of Oil Folliculitis (Acne).—Three sections were studied: What seemed to be a typical oil folliculitis with a pustular reaction on the anterior thigh; a comedo on the thigh which did not look especially inflammatory; and

WATER_PCB-SD0000039082



FIG. 5. Oil acne on forearms.



FIG. 6. Section of a follicular lesion on thigh produced by insoluble cutting oils. Marked inflammatory reaction adjacent to a follicle with an epidermal vesicle filled with leukocytes.



FIG. 7. Section of chloracne from chlorinated cutting oils.

1. Pustular Folliculitis from the Thigh (Three Months' Duration): There was a follicular hyperkeratosis as well as a generalized hyperkeratosis and acanthosis throughout the section. The mouth of the follicle was widened, and it was filled with keratinous material. The walls of the follicles were also hypertrophied. Around such follicles there was a marked inflammatory exudate consisting of leukocytes and lymphocytes. On occasions accumulations of lymphocytes and leukocytes could also be seen forming small abscesses deep in the cutis. Even some of the sweat glands showed involvement by invasion of their walls with leukocytes and an inflammatory reaction consisting of edema and an accumulation of lymphocytes and leukocytes around them. The sebaceous glands did not seem to be hypertrophied. No bacteria could be found.

2. A Comedo of the Thigh: The section showed a number of large follicular openings filled with keratinous material. The epidermal walls of the openings were hypertrophied. There is a marked inflammatory reaction around the hair follicles. The cutis for quite a distance from the follicle showed areas of inflammatory reaction with aggregations of leukocytes and lymphocytes. The capillaries and lymphatics were dilated and were found to be engorged with white cells. Adjacent to the comedo could be seen a small epidermal vesicle filled with leukocytes (Fig. 6). No bacteria could be found.

3. Typical Oil Folliculitis on the Back of the Hands: There were a widening of the follicular opening and a thickening of its walls, and the mouth of the follicle was filled with keratinous material. The surrounding epidermis showed an acanthosis and hyperkeratosis. Around the follicles and diffusely throughout the cutis there was a marked inflammatory reaction, which in some instances extended to the deeper layers of the cutis. The sweat glands were not involved, but there was a striking absence of sebaceous gland hypertrophy.

In contradistinction to what has been seen in the changes due to pitch and the chlorinated hydrocarbons, the process in oil folliculitis was much more inflammatory, not only around the involved hair follicles but also in the cutis quite a distance from the follicles. While there was a stimulus to keratin formation, just as in other acneform lesions previously described, it was more extensive and there was acanthosis of the surrounding epidermis. Pustule formation could be seen in the epidermis, as well as the formation of small abscesses in the deep cutis. The sweat glands were involved as part of the general inflammatory reaction. No cocci were demonstrable in any of the sections. This fact, plus the previous observation that the insoluble cutting oils are sterile in so far as pus-forming bacteria are concerned, demonstrates that oil folliculitis is due to the chemical composition of the insoluble cutting oils and not to bacteria, which they are said by some to contain.

Chlorinated Cutting Oils—The lesions from the chlorinated cutting oils combine the characteristics of the lesions seen after exposure to the chlorinated hydrocarbons and those described as oil folliculitis. The histopathology also is a combination of both.[7]

Prevention

The prevention of occupational acnes can be divided into (1) general measures and (2) personal measures:

1. The manufacture of the chlorinated hydrocarbons and the coating of wires and condensers with insulating materials containing the chlorinated hydrocarbons should be done by totally enclosed processes so that the fumes of the insulating substances and of the solvents, if any are used, do not come in contact with the workers.

2. The workers should be provided with clean coveralls and underclothes daily. These should be laundered at the plant and cleaned in such a way that no chlorinated hydrocarbons remain on them.

Shower baths after work should be compulsory and supervised, and there should be sufficient shower facilities provided so that the workers are not unduly delayed after work. Suitable cleansers should be provided to remove efficiently the insulators from the skin. The synthetic wetting-agents are said to be better for this purpose than ordinary soaps.

A suggested cleanser is: duponol or nacconol or santomerse—2 per cent; and a sulfonated oil—castor, peanut, soy bean, corn, or linseed—98 per cent.

A scrubber of corn meal may be added to this or may be available for use as needed in conjunction with it. A mixture of butyl stearate and sulfonated castor oil has also been suggested.[8]

If exposure of the face and neck to fumes or contact with soiled hands is unavoidable, trans-

WATER_PCB-SD0000039083

parent hoods covering the head and neck can be provided. These can be made of cellophane, pliofilm, or other transparent resin film.

If for any reason these cannot be had, protective ointments of the invisible glove type may be used. Types 2a and 2b, and type 4, as described by Schwartz,[9] are suitable for this purpose.

Periodic liver function tests should be performed every month on the workers. In addition to this, monthly dermatologic examinations should be made to detect early evidence of acne.

The above protective measures should also apply to electricians and others who work with wire and condensers insulated with the chlorinated hydrocarbons.

Workers with coal tar, heavy coal-tar distillates, and coal-tar pitch should be protected against the tar fumes, if any, by exhaust ventilating apparatus. The preventive measures as to cleanliness and clothing described above also apply to these workers.

A protective application of a light screen to the face is advisable for use by those who have become photosensitized. Suggested light screens are: menthyl salicylate, 10 per cent, or cycloform, 10 per cent, in a zinc oxide ointment base.

The prevention of cutting-oil acne consists in shielding the machines so that splashes of oil do not strike the workers and in filtering the insoluble cutting oils after one hundred and fifty hours of use. Fuller's earth or activated carbon used in the filters will improve the odor and calcium oxide will lessen the acidity. Disinfectants should not be added to insoluble cutting oil, for they only increase the skin hazard.

Personal cleanliness and protective clothing, as outlined above, should be encouraged. In addition to these, impervious sleeves and aprons[10] should be provided.

Treatment

The treatment of the occupational acnes must be governed by the stage and extent of the lesions, but in general it consists of the expression of comedones, evacuation of abscesses and cysts, and the frequent use of skin cleansers.

X-ray should be used only in special cases and with great caution because the rationale of its use in the treatment of acne vulgaris does not hold for the occupational acnes.

The personal measures of prevention described above are also measures for treatment.

References

1. Schwartz, Louis: Public Health Bulletin No. 229, Part II, p. 9.
2. Drinker, Cecil K., *et al.*: Symposium, Harvard School of Public Health, Boston, June 30, 1937.
3. Fulton, Wm. B., and Mathews, J. L.: Pennsylvania Dept. Labor and Ind., Spec. Bull. No. 43, 1936, pp. 1–15.
4. Mayers, May R., and Silverberg, Mabel G.: J. Indust. Hyg. & Toxicol. 20: 244 (March) 1938.
5. Schwartz, Louis, and Tulipan, Louis: A Text-Book of Occupational Diseases of the Skin, Philadelphia, Lea and Febiger, 1939, p. 306.
6. Nakauchi, Y.: Jap. J. Dermat. & Urol. 48: 87 (Oct.) 1940.
7. Schwartz, Louis, and Barlow, Frank A.: Public Health Reports 57: 1747 (Nov. 20) 1942. Reprint No. 2421.
8. Morris, George E., and Tabershaw, Irving R.: J.A.M.A. 121: 192 (Jan. 16) 1943.
9. Schwartz, Louis: M. Clin. North America, July, 1942, pp. 1195–1212.
10. Schwartz, Louis, Warren, Leon H., and Goldman, Frederick H.: Public Health Reports 55: 1158 (June 28) 1940. Reprint No. 2383.

Discussion

Dr. Louis Tulipan, *New York City*—The presentation by Dr. Schwartz and Dr. Peck on "Occupational Acne" was both enlightening and interesting. It was especially enlightening because of the histopathology presented by Dr. Peck.

Recently, because of the occurrence of a large number of acneform eruptions, I was asked to investigate a defense factory in which oil-containing chlorine was being used. Quite a variety of lesions had been produced.

Out of 144 such cases, some showed comedones only, others milia only; some had cysts as large as hazelnuts; one had a picture of acne conglobata; and many showed a combination of lesions like those found in the acne vulgaris of puberty. In many cases, in addition to the face, there was involvement of the chest, back, forearms, thighs, buttocks, and scrotum.

I agree with Dr. Schwartz that cases in which the lesions are limited to milia and cysts will not respond to x-ray therapy. However, when the eruption simulates an acne vulgaris of puberty, x-ray therapy is definitely indicated and must be employed to get any results.

I also agree that besides the advice on the use of x-ray, all other advice as to cleanliness, protective clothing, proper ventilation, etc., should be followed

TRAINING PROGRAM FOR HOSPITAL ORDERLIES

New York's 100 voluntary nonprofit and municipal hospitals are faced with the most serious personnel situation in their history—a condition that can be remedied only by the immediate recruiting of 3,000 volunteer workers—according to Roy E. Larsen, president of the United Hospital Fund of New York.

Five New York hospitals are ready to inaugurate a training program similar to that being used at New York Hospital. The hospitals which have set up such a program and are waiting only for volunteers in order to get under way are St. Luke's, Mount Sinai, The Bronx, Lenox Hill, and Presbyterian.

Persons wishing to volunteer should call at the Fund's Hospital Volunteers Bureau, at 370 Lexington Avenue, between 11:00 A.M. and 4:30 P.M. any day except Saturday and Sunday. The bureau is open until 7:30 P.M. Mondays and Thursdays.

WATER_PCB-SD0000039084