MAR 29 1973

Tissue Distribution of Polychlorinated Biphenyls (Aroclor 1254) in Cockerels: Relation to the Duration of Exposure and Observations on Pathology

N. S. Platonow, L. H. Karstad
and
P. W. Soschenbrecker*

ABSTRACT

Day old cockerels were given a ration containing 500 ppm of polychlorinated biphenyls (PCB) as Aroclor 1254. Mortality was recorded and various tissues analysed for PCB levels. Tissue concentrations of PCB increased in direct relation with the time of the experiment and with the survival period of birds. The PCB ratios between liver, kidney and muscle to that in the brain were constant through the duration of the study. Pathological examination revealed extensive hydropericardium and edema in the lung, muscle and subcutis; hemorrhages in muscles, digestive tract, lung and kidney; myocarditis; kidney and liver necrosis and hepatitis.

RÉSUMÉ

On a servi à des cockets d'un jour une ration contenant 500 ppm de diphényles polychlorés (PCB), sous la forme d'Aroclor 1254. On enregistra les mortalités et on détermina la teneur en PCB de plusieurs organes. L'augmentation de la teneur en PCB de ces différents organes était directement proportionnelle au stade de l'expérience et au temps de survie des sujets. La concentration de PCB dans le foie, les reins et les muscles, comparativement à celle du cerveau, s'avéra constante tout au long de l'expérience. L'examen pathologique révéla: un hydropéricarde marqué, de l'oedème pulmonaire, musculaire et sous-cutané; des hémorragies dans les muscles le système digestif, les poumons et les reins; de la myocardite; de la nécrose rénale et hépatique, ainsi que de l'hépatite.

INTRODUCTION

The presence of polychlorinated biphenyls (PCB) in wildlife and human samples was first detected by Jensen (6). Subsequently numerous reports confirmed their existence in various terrestrial and aquatic forms in global ubiquity (2, 3, 5, 7, 8, 11, 14).

McCune *et al* (9) described accidental poisoning of chickens by PCB. In these birds the gross lesions were hydropericardium, hydroperitoneum, enlarged heart, liver and kidneys, and hemmorhages in internal organs. Microscopically the kidneys had marked tubular dilatation and numerous casts. Flick *et al* (4) fed cockerels rations containing PCB, which produced signs simulating those of chick-edema disease. These signs included growth depression in direct proportion to the dietary concentration of PCB and edema fluids in the pericardial sac and in the abdominal and subcutaneous areas. The effects of PCB in causing porphyria, edema, liver necrosis and tissue residues in chicken were recently reported by Vos and Koeman (17). The levels of PCB in these poisoned birds

*Departments of Biomedical Sciences and Pathology, University of Guelph, Guelph, Ontario (Platonow and Karstad) and Animal Pathology Division, Health of Animals Branch, Canada Department of Agriculture, Guelph Area Laboratory, 620 Gordon Street, Guelph, Ontario (Soschenbrecker).

This work was supported by the Ontario Department of Agriculture and Food.

Submitted January 21, 1972.

MONS 085625

varied between 120 and 2,900 ppm in the liver and between 40 and 700 ppm in the brain. In a recent paper of Rehfeld *et al* (12) on toxicity studies of PCB in the chick, the maximum tolerance in feed was found to be approximately 50 ppm. Symptoms and lesions included depressed body weight, edema, respiratory distress, increased hydropericardial fluid, internal hemorrhages and decrease in the development of comb and wattles.

Since PCB possess certain physico-chemical similarities to the DDT pesticide group (13, 15), particularly strong lipophilic properties, they have a strong tendency to accumulate in the body lipids and consequently increase in concentration through the trophic levels of the food chain (7).

The residual significance of PCB is virtually uninvestigated in lethally poisoned birds, chickens in particular. In order to obtain some insight and understanding of the problem in the present study, the relationship between lesions, tissue levels of PCB and the time of death was investigated in experimentally poisoned chickens.

MATERIALS AND METHODS

White *Leghorn* cockerels, one day old at the beginning of the experiment, were used. Sixty birds were fed a commercial ration[1] containing 500 ppm of PCB as Aroclor 1254[2] and tapwater *ad libitum*. The Aroclor 1254 was dissolved in olive oil, and this solution was mixed with the ration at a rate of 0.1%. Twenty control birds were given the ration containing the same amount of olive oil as the PCB-treated ones.

Three groups of five cockerels each were selected for tissue residue analysis from the total of 60 birds, representing average cumulative mortalities of 25%, 50% and 75%, respectively. Mortality reached 25% when the 15th bird died, hence the 25% mortality group was cockerels which died 13th to 17th, inclusive. Similarly, the 50% cumulative mortality group consisted of the 28th to the 32nd birds to die and the 75% mortality group was cockerels dying 43rd to 47th in the experiment.

Five control birds were killed when the average cumulative mortalities reached 25, 50 and 75%, respectively. The remaining controls were killed at the end of the experiment.

Samples of liver, kidney and pectoral muscle as well as whole brain were removed from these birds and were stored at −20°C until analyzed. The PCB were extracted from samples and subsequently analysed by the method of Saschenbrecker and Ecobichon (16) using a Micro Tek, Model MT-220°, gas chromatograph, equipped with a ^{63}Ni high temperature electron capture detector. The quantitation and separation of the PCB was performed as described by Armour and Burke (1).

The birds that died after 75% mortality was reached were examined by necropsy and the following tissues were subjected to histopathological study: striated muscle, brain, heart, lung, spleen, liver, pancreas, intestines, testicle and kidney.

RESULTS

Time-Mortality Relationship

The mortality curve of treated birds is shown in Fig. 1. Twenty-five percent of the birds died within 34 days; 50 and 75% of the treated cockerels were dead by 43

[1]Trouw Inc., Austin, Texas.

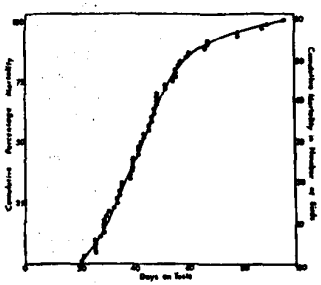

Fig. 1. Time-mortality responses of cockerels given ration containing 500 ppm of polychlorinated biphenyls (Aroclor 1254).

[1]20% chick starter containing 0.0125% Zoalene. United Co-Op, Weston, Ontario.

[2]Aroclor 1254 (mixture of chlorinated biphenyls containing 54% chlorine) was generously supplied by Monsanto Canada Ltd., Toronto, Ontario.

MONS 085626

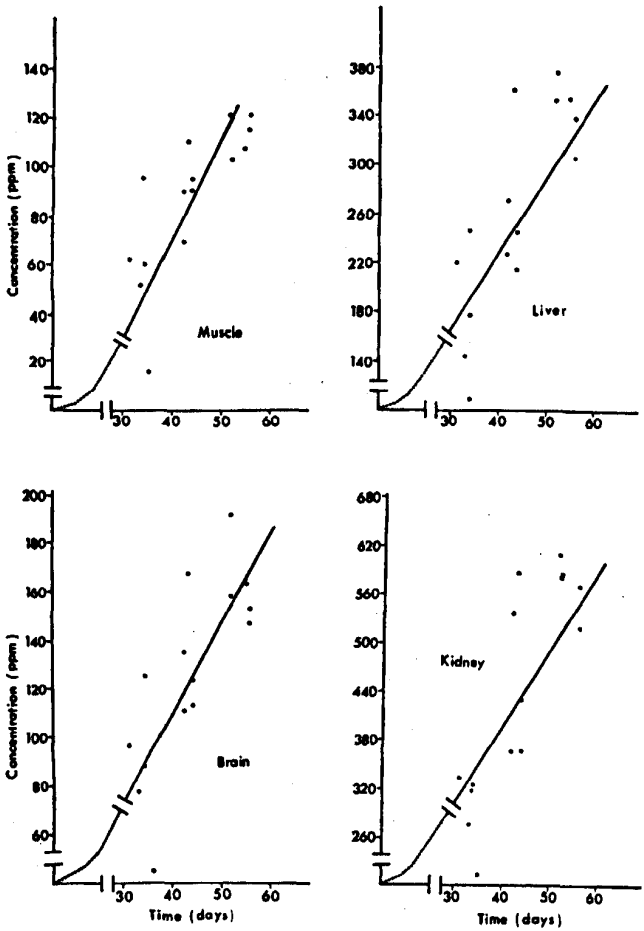

Fig. 2. The concentrations of the polychlorinated biphenyls with the respective regression line in the brain ($y = 9.1x - 181.7$), kidney ($y = 12.6x - 111.1$), muscular tissue ($y = 2.7x - 58.8$) and liver ($y = 15.6x - 197.8$). The dashed curve between the theoretical zero intercept and the regression line was drawn by hand.

MONS 085627

TABLE I. The Ratios of the Concentration of Polychlorinated Biphenyls (Aroclor 1254) Between Liver, Kidney or Muscular Tissue to That in the Brain

Group	Ratio		
	Muscle / Brain	Liver / Brain	Kidney / Brain
25% Mortality	0.70 ± 0.06	2.00 ± 0.06	3.50 ± 0.10
50% Mortality	0.69 ± 0.07	2.00 ± 0.06	3.52 ± 0.26
75% Mortality	0.70 ± 0.07	2.01 ± 0.09	3.48 ± 0.23

and 55 days, respectively. The first death occurred on the 21st day of feeding the treated ration, whereas the last chicken survived for 96 days.

The form of the curve is that of an "accumulated normal curve" and is a reasonably good sigmoid except the upper portion which is slightly skewed. When the data were replotted as log-mortality or log-time, it did not change the shape of the curve significantly.

Two control birds died during the experiment.

Tissue Distribution of PCB

The concentrations of PCB in selected tissues from the groups of 25, 50 and 75% mortality are given in Fig. 2. The data indicate that the levels of PCB in all tissues investigated increased in direct correlation with time in the experiment. The increase of PCB was not quite linear, however, since the plotted data had a slight hyperbolic tendency of cumulation.

The kidney tissue always had the highest levels of total PCB, followed by the liver, brain and muscular tissues.

The relationship of the concentration of PCB between hepatic, renal or muscular tissues to that in the brain was examined for each group of birds. The data are shown in Table I. These ratios remained constant throughout the duration of the experiment.

The resolution by gas-chromatography of Aroclor 1254 standard, as well as the tissue extracts resulted, under the operating conditions used in the present study, in 14 distinct peaks and two shoulders (on peaks 2 and 6) on each chromatogram. The percentage of each chromatographic fraction on the tissue chromatogram was compared with the same fraction of the standard sample. No significant changes occurred in the percentage distribution of the chromatograms from the various tissue extracts.

Pathology

Twelve principal chickens were examined by necropsy. These were taken either moribund or at death, on days 45 to 87 of the experiment. The most consistently found gross lesions were accumulations of yellowish or blood stained fluids in the pericardial sac (Fig. 3) and abdominal cavity; edema of lungs; hemorrhages in the muscles of the neck; petechial hemorrhages



Fig. 3. Massive hydropericardium in a polychlorinated biphenyls-poisoned cockerel.

MONS 085628



Fig. 4 Myocardium infiltrated with heterophils and lymphocytes in a pectoral dead of polychlorinated biphenyls-poisoning. H & E X100.



Fig. 5. Perivascular hemorrhage in the myocardium of a polychlorinated biphenyls-poisoned cockerel. H & E X100.

on the epicardium and in the mucosa of the gastro-intestinal tract; and breast muscles either shrunken or soft and edematous. Edema fluids were sometimes semi-gelatinous. Some birds had bled into the lungs and fresh blood was often found in the gastro-intestinal tract. Pale or hemorrhagic foci were sometimes present in the liver.

Histopathology on formalin-fixed, paraffin-embedded tissues revealed evidence of edema also in other sites; eg. striated muscles, myocardium, interstitial tissues of the kidney and lungs, the brain and the liver, where it caused widening of the spaces of Disse.

Microscopic liver lesions were present in all cases, limited in some of the earliest cases to distention of sinusoids with blood and granular material which stained like fibrin, edema, and dissociation of hepatic cells. Livers of birds which died after 48 days of Aroclor 1254 feeding had changes in hepatic cells which resembled acute focal necrosis, or transformation of cells into hyaline masses as in amyloidosis. This hyaline material did not have the characteristic birefringence of amyloid in Congo Red-stained sections examined with polarized light, nor did it produce yellowish fluorescence in thioflavine S-stained sections examined with ultraviolet illumination. Two chickens which died on days 56 and 87, respectively, had infiltrations of large mononuclear lymphoid cells into portal areas, with associated hepatic cell destruction and fibrosis.

Most birds had heart lesions. Basophilic mononuclear leukocytes and heterophiles infiltrated the myocardium, in irregular or patchy distribution (Fig. 4). The media of arteries and veins in the myocardium had a disorganized appearance. Perivascular hemorrhages were common (Fig. 5).

Nephrosis was found in half the birds examined, marked by dilatation of renal tubules, the presence of hyaline casts, vacuolation of epithelial cells, interstitial edema, and proliferation of glomerular epithelial cells. The gross and microscopic lesions are

TABLE II. Lesions Found in Chickens Poisoned with Polychlorinated Biphenyls (Aroclor 1254)

Gross Lesions		Microscopic Lesions	
Hydropericardium	11/12[a]	Edema, various tissues	12/12
Hemorrhages, gastro-intestinal	7/12	Myocardium infiltrated with leukocytes; perivascular hemorrhages	10/12
Hemorrhages in neck muscles	7/12	Nephrosis	6/12
Hemorrhages, petechial on heart	6/12	Focal necrosis, liver	3/12
Hemorrhages, lung	6/12	Hepatitic cell loss; fibrosis; leukocyte infiltrates	2/12
Gizzard lining soft or eroded	6/12		
Edema and atrophy, breast muscles	4/12		
Edema, lungs	3/12		
Edema, subcorninal air sac	3/12		
Liver focal white or red lesions	3/12		
Hydroperitoneum	2/12		
Hemorrhages, kidney	2/12		
Edema, subcutaneous	1/12		

[a]Numerator = number of birds with lesion; denominator = total number examined

MONS 085629

listed in Table II.

Controls subjected to gross examinations did not reveal any noticeable lesions, but tissues were not examined microscopically.

DISCUSSION

The ratios of the concentrations of PCB between liver, kidney or muscular tissues to that in brain remained unchanged during the experiment, thus indicating that the cumulative tendency of PCB in fatally poisoned chicks is constant, whatever the duration of survival. However, this observation may apply only at the treatment level of PCB used in the present study. It is important to determine whether these cumulative tendencies will remain constant ratios also with varying PCB levels in the diet.

Changes occurred in the percentage distribution on the chromatograms of various peaks from tissue extracts. However, these changes were not significant. Similar observations were made by Platonow and Funnell (10), who investigated prolonged non-fatal exposure of chickens to Aroclor 1254. However, the data of the present study differ from those of Koeman *et al* (8). These authors gave Japanese quail (*Coturnix coturnix*) PCB (as Phenoclor DP6) at 2000 ppm level. The birds died between the sixth and the 55th day of exposure. The chromatograms of their liver and brain extracts showed a reduction from the original 13 fractions to seven fractions. The fractions with lower retention time, which are presumably the less chlorinated PCB compounds, were the ones mostly affected.

In their report on the toxicity of PCB in wild birds, Prestt and associates (11) described the concentrations of PCB (Aroclor 1254) in experimental, fatally poisoned Bengalese finches. The range of the PCB in the liver of these birds varied from 70 to 697 ppm. This range is about twice as high as in the present study: in our cases liver concentrations varied from 86 to 360 ppm. In the work of Prestt *et al* (11), the relationship of the PCB levels in the brain of dying birds to that in the liver, expressed in percentages, was 83.7 ±7.4%. Corresponding figures were substantially lower in our birds: 50 ±3%. They were also constant from animal to animal, whatever the time of death.

None of the lesions found could be considered pathognomonic for PCB poisoning. The various edematous and hemorrhagic lesions seen in this study are consistent with the lesions described by others. Of particular interest in this study are the high frequency of hemorrhages in neck muscles, myocarditis and nephrosis. The pathogenetic association of these lesions is not clear.

ACKNOWLEDGMENTS

The authors acknowledge the excellent technical assistance of Mrs. N. Y. Chen, Mr. A. Binnington and Mr. G. Boa.

REFERENCES

1. ARMOUR, J. A. and J. A. BURKE. Method for separating polychlorinated biphenyls from DDT and its analogs. J. Ass. off. Analyt. Chem. 53: 761-768. 1970.
2. BAGLEY, G. E., W. L. REICHEL and E. CROMARTIE. Identification of polychlorinated biphenyls in two bald eagles by combined gas-liquid chromatography-mass spectrometry. J. Ass. off. analyt. Chem. 53: 281-291. 1970.
3. DUKE, T. W., J. I. LOWE and A. J. WILSON. A polychlorinated biphenyl (Aroclor 1254) in the water, sediment, and biota of Escambia Bay, Florida. Bull. envir. Contam. Toxic. 5: 171-180. 1970.
4. FLICK, D. F., E. G. O'DELL and V. A. CHILDS. Studies of the chick edema disease. Similarity of symptoms produced by feeding chlorinated biphenyl. Poult. Sci. 44: 1460-1465. 1965.
5. HOLMES, D. C., J. E. SIMMONS and J. O. TATTON. Chlorinated hydrocarbons in British wildlife. Nature, Lond. 216: 227-229. 1967.
6. JENSEN, S. Report of a new chemical hazard. New Scient. 32: 612. 1966.
7. JENSEN, S., A. G. JOHNELS, M. OLSSON and G. OTTERLIND. DDT and PCB in marine animals from Swedish waters. Nature, Lond. 224: 247-250. 1969.
8. KOEMAN, J. H., M. C. TEN NOEVER DE BRAUW and R. M. DE VOS. Chlorinated biphenyls in fish, mussels and birds from the river Rhine and the Netherlands coastal area. Nature, Lond. 221: 1126-1128. 1969.
9. MCCUNE, E. L., J. E. SAVAGE and R. L. O'DELL. Hydropericardium and ascites in chicks fed a chlorinated hydrocarbon. Poult. Sci. 41: 895-899. 1962.
10. PLATONOW, N. S. and H. S. FUNNELL. The distribution and some effects of polychlorinated biphenyls (Aroclor 1254) in cockerels during prolonged feeding trial. Can. J. comp. Med. 33: 56-58. 1971.
11. PRESTT, I., D. J. JEFFERIES and N. W. MOORE. Polychlorinated biphenyls in wild birds in Britain and their avian toxicity. Environ. Pollution 1: 3-26. 1970.
12. REMFELD, B. M., R. L. BRADLEY and M. L. SUNDE. Toxicity studies of polychlorinated biphenyls in the chick. I. Toxicity and symptoms. Poult. Sci. 50: 1899-1904. 1971.
13. REYNOLDS, L. M. Pesticide residue analysis in the presence of polychlorobiphenyls (PCB's). Residue Rev. 34: 27-37. 1971.
14. RISEBROUGH, R. W., P. RIECHE, S. D. HERMAN, D. B. PEAKALL and M. N. KIRVEN. Polychlorinated biphenyls in the global ecosystem. Nature, Lond. 220: 1098-1102. 1968.
15. RISEBROUGH, R. W., P. RIECHE and H. S. OLCOTT. Current progress in the determination of the polychlorinated biphenyls. Bull. envir. Contam. Toxic. 4: 196-201. 1969.
16. SASCHENBRECKER, P. W. and D. J. ECOBICHON. Extraction and gas chromatographic analysis of chlorinated insecticides from animal tissues. Agric. Food Chem. 19: 188-170. 1967.
17. VOS, J. D. and J. H. KOEMAN. Comparative toxicologic study with polychlorinated biphenyls in chickens with special reference to porphyria, edema formation, liver necrosis and tissue residues. Toxic. appl. Pharmac. 17: 656-668. 1970.

MONS 085630