MORPHOLOGICAL CHANGES IN THE LIVERS OF RATS RESULTING FROM EXPOSURE TO CERTAIN CHLORINATED HYDROCARBONS

BY

GRANVILLE A. BENNETT, CECIL K. DRINKER, AND
MADELEINE FIELD WARREN

Department of Pathology, Harvard Medical School, and the Department of Physiology, Harvard School of Public Health, Boston, Massachusetts

Reprinted from THE JOURNAL OF INDUSTRIAL HYGIENE AND TOXICOLOGY
Vol. 20, No. 2, February, 1938

EXHIBIT
K-4

GBRN001964

Reprinted from THE JOURNAL OF INDUSTRIAL HYGIENE AND TOXICOLOGY
Vol. 20, No. 2, February, 1938

MORPHOLOGICAL CHANGES IN THE LIVERS OF RATS RESULTING FROM EXPOSURE TO CERTAIN CHLORINATED HYDROCARBONS*

GRANVILLE A. BENNETT, CECIL K. DRINKER, AND MADELEINE FIELD WARREN

Department of Pathology, Harvard Medical School, and the Department of Physiology, Harvard School of Public Health, Boston, Massachusetts

CHLORINATED hydrocarbons, particularly chlorinated naphthalenes and chlorinated diphenyl, have been used extensively in certain industries. Their use in the manufacture and preparation of many types of electrical equipment is constantly increasing. Although it is known that some of these compounds cause acne, only recently has the possibility of more serious systemic effects been recognized.

During the spring of 1936 we were informed of the occurrence of three fatal cases of jaundice in workmen using chlorinated naphthalenes and chlorinated diphenyl. At the request of the manufacturers of these compounds, we undertook an investigation to determine what systemic effects, if any, would result from the administration of a number of these compounds to experimental animals.

The known findings in the three fatal cases of jaundice, together with a review of the pertinent literature have already been reported (1).

The present paper describes the pathological changes observed in rats that had been exposed to various chlorinated naphthalene compounds and to chlorinated diphenyl.

MATERIALS AND METHODS

A detailed description of the apparatus and technic employed by the authors in this investigation has been published (1). White rats, maintained on a diet of Purina Dog Chow, supplemented by lettuce, eggs, milk, and cod liver oil, were used throughout the experiments.

* Received for publication September 5, 1937.

This is the second of three papers read at a symposium on chlorinated hydrocarbons given at the Harvard School of Public Health, Boston, June 30, 1937. The third paper will appear shortly.

GBRN001965

TOWOLDMON0001530

The chlorinated hydrocarbons tested were the following:

Compound A. A mixture of tri- and tetrachlornaphthalenes.* Chlorine content 49.4 per cent.

Compound B. A mixture of tetra- and pentachlornaphthalenes. Chlorine content 56.4 per cent.

Compound C. A mixture of tetra- and pentachlornaphthalenes plus chlorinated diphenyl. Chlorine content 43.5 per cent.†

Compound D. A mixture of penta- and hexachlornaphthalenes. Chlorine content 62.6 per cent.

Compound E. A mixture of penta- and hexachlornaphthalenes. Chlorine content 62.6 per cent.

Compound F. A mixture of 90 per cent penta- and hexachlornaphthalenes, plus 10 per cent chlorinated diphenyl. Chlorine content 63 per cent.

Compound G. Chlorinated diphenyl. Chlorine content 65.0 per cent.

These preparations were selected because of their relative importance in industry. It should be noted that they also represent a wide range of chlorination.

All of the above materials were administered orally in varying doses. Compounds A, D, F, and G were selected for the inhalation experiments.

* This compound contained only small amounts of tetrachlornaphthalenes. In this paper it will therefore be referred to as trichlornaphthalenes.

† This compound consisted of a mixture of compounds B and G but in addition contained two plasticizers which have been considered to be inert. Without these materials the chlorine content of this compound would be between that of compounds B and D.

Inhalation Experiments

We were most interested in the results of the inhalation experiments because they more nearly simulate the type of exposure to which the workmen are subjected (1). The inhalation experiments were carried out in air-tight wooden compartments through which air, containing the volatilized compound being tested, was driven by electrical blowers. With this apparatus we were able to test simultaneously the effect of four compounds. Eighty rats were exposed to each compound. The methods for determining the daily air concentration (mgms. per cu. m.) of the chlorinated hydrocarbon being used, as well as the rate of airflow have been described (1).

Compound A (trichlornaphthalenes) was administered by inhalation to two groups of animals. In the first of these experiments, the rats were exposed to low air concentrations (average 1.31 mgms. per cu. m.) 16 hours daily for 134 days. In the second experiment the concentration was increased to an average of 10.97 mgms. per cu. m. This 16 hour daily exposure was continued for 102 days.

Compound D (hexa- and pentachlornaphthalenes) was administered to three groups of rats. In the first experiment the exposure consisted of 16 hours daily for 134 days, with an average air concentration of 1.16 mgms. per cu. m. In a second experiment the average air concentration was 1.44 mgms. per cu. m. This was maintained 8 hours daily for 143 days. In the final experiment, the average air concentration was increased to 8.88 mgms. per cu. m. and exposure, 16 hours daily, was continued over a period of 52 days.

GBRN001966

TOWOLDMON0001531

Compound F (hexa- and pentachlornaphthalenes 90 per cent plus chlorinated diphenyl 10 per cent) was administered in low concentrations to two groups of rats. In the first experiment an average air concentration of 1.37 mgms. per cu. m. was maintained 16 hours daily for 134 days. In the second experiment, an average air concentration of 1.66 mgms. per cu. m. was inhaled 8 hours daily for 143 days.

Compound G (chlorinated diphenyl) was administered to two groups of animals in low concentrations. An average concentration of 0.57 mgms. per cu. m. was employed 16 hours daily for 134 days in the first experiment. In the second experiment (employing an average air concentration of 0.93 mgms. per cu. m.) the animals were exposed 8 hours daily for 143 days.

Feeding experiments

All compounds tested were employed in the feeding experiments. A weighed amount of finely ground material was mixed with rat food. This mixture was placed daily in one food container to supply the rats in a given cage. Thus each animal had an equal opportunity to ingest the compound supplied. As the number of rats per cage was reduced, the dosage supplied was proportionately decreased. Most compounds were supplied in large and small amounts.

Supplementary experiments were conducted on a smaller number of rats by feeding several of these compounds in small known amounts by stomach tube or by injecting them subcutaneously as suspensions in gum acacia.

Carbon tetrachloride and alcohol administration to experimental animals

Seemingly the incidence of acute yellow atrophy in workers exposed to chlorinated naphthalenes and chlorinated diphenyl is very low. This single fact is of some importance in that it suggests that certain individuals may be more susceptible to the compounds or that in these instances the liver damage may have been intensified by some other agent. With this in mind, groups of animals that had been exposed for varying periods of time to certain chlorinated naphthalene compounds and chlorinated diphenyl were subsequently given a sublethal dose* of carbon tetrachloride and ethyl alcohol by stomach tube (0.75 cc. of each per kgm.). This dosage did not result in a single death among the 16 control animals and the degree of liver damage produced was quite constant and never very great. Administration of carbon tetrachloride and alcohol to rats exposed to the more highly chlorinated naphthalene compounds and chlorinated diphenyl caused extensive liver damage and proved widely fatal. Therefore, the use of carbon tetrachloride and alcohol has been employed regularly on representative groups of rats from each inhalation experiment.

Examination of tissues

Animals were sacrificed for pathological examination after varying periods of exposure. Complete autopsies were performed. Liver weights were recorded. In representative animals

* One cubic centimeter of carbon tetrachloride plus 1.0 cc. ethyl alcohol per kilogram when administered orally to normal white rats causes a 14 per cent mortality (2).

GBRN001967

TOWOLDMON0001532

from each experiment, all organs excepting the central nervous system were examined microscopically. The livers of all animals were studied microscopically. Tissues were fixed in Zenker's fluid, 10 per cent formaldehyde solution, and absolute alcohol. The routine paraffin sections were stained with eosin methylene blue. Other stains employed were hematoxylin and eosin, phosphotungstic acid hematoxylin (Mallory), Foot's modification of Bielschowsky's stain (reticulum), Best's carmine stain, and Iron reaction with ferrocyanide of potassium (Mallory). In addition, frozen sections from certain liver specimens were stained with scarlet red, Lugol's solution, and methyl violet.

Results

Compound A. Trichlornaphthalenes

(a) *Exposure by inhalation to low concentrations (average 1.31 mgms. per cu. m.) 16 hours daily.*—The 80 rats subjected to these conditions showed no ill effects. Autopsies were performed on groups of 3 to 8 animals after 37, 72, 105 and 134 days' exposure. There were no significant abnormalities in liver weights.* Macroscopically the majority of the livers appeared normal although an occasional one was paler than normal. Rarely slight mottling was observed. Microscopically, the liver cells often appeared slightly enlarged, more granular than normal, and occasionally they were vacuolated. These slight abnormalities and the presence of a rare mitotic figure suggested that very slight injury to the liver cells had occurred. There was no demonstrable increase in the above changes after the first exposure period (37 days). Occasional livers of rats exposed for the total period showed

* Calculations pertaining to the weights of livers in these and subsequent animals are based on data in H. H. Donaldson's book "The Rat." 2nd ed. The Wistar Institute, Philadelphia, 1924 (p. 211).

PLATE I

FIGS. 1 AND 2. Camera lucida drawings showing the portal areas of the livers of two rats that were fed large doses of a mixture of tetra- and pentachlornaphthalenes and chlorinated diphenyl. The changes illustrated in figure 1 occurred within 48 days after exposure was begun. One should note the marked accumulations of hyaline globules in the cell cytoplasm, and the marked swelling of liver cells. Increased numbers of mitotic figures were also present. Similar changes are apparent in figure 2 which was made from the liver of a rat exposed 125 days. Degeneration in the central portions of the liver lobules is also present.

FIGS. 3 AND 4. These drawings illustrate the marked swelling and fatty vacuolization of liver cells observed in all rats that were fed small doses of tetra- and pentachlornaphthalenes. The changes shown in figure 3 were present after 26 days' exposure, those in figure 4 after 48 days' exposure. Note the mitotic figures in figure 3. The compound responsible for the changes contained no chlorinated diphenyl. Otherwise it was similar to the compound responsible for the lesions illustrated in figures 1 and 2.

FIGS. 5 AND 6. Camera lucida drawings of the portal areas of the livers of two rats fed moderate sized daily doses of a mixture of penta- and hexachlornaphthalenes for 14 and 29 days respectively. In the first of these figures one notes swelling of liver cells with narrowing and distortion of the sinusoids. The liver cells show an increased granularity of the cytoplasm with a massing of basophilic granules near the nuclei. There is also an excess of fat in small and medium sized vacuoles. This was more prominent in the central portions of the liver lobules. An increased spacing between liver cells and between liver cells and sinusoidal endothelium is present. After 29 days' exposure (fig. 6) the above changes are greatly increased. Numerous large intercellular spaces containing serous precipitate, strands of fibrin and leucocytes had developed between liver cells. These spaces were bounded by distorted liver cells. See also plate III, fig. 1.

Camera lucida drawings × 395.

GBRN001968

TOWOLDMON0001533

showed
re per-
animals
days'
nificant
Mac-
he livers
an occa-
normal.
bserved.
lls often
re gran-
sionally
e slight
nce of a
hat very
ells had
demon-
changes
riod (37
rats ex-
showed

ne weights
nt animals
naldson's
ne Wistar
211).

esponsible
s 1 and 2.
drawings
f two rats
a mixture
nes for 14
he first of
liver cells
the sinu-
increased
a massing
he nuclei.
small and
was more
ns of the
acing be-
liver cells
present.
the above
Numerous
ing serous
leucocytes
s. These
rted liver

3.

PLATE I

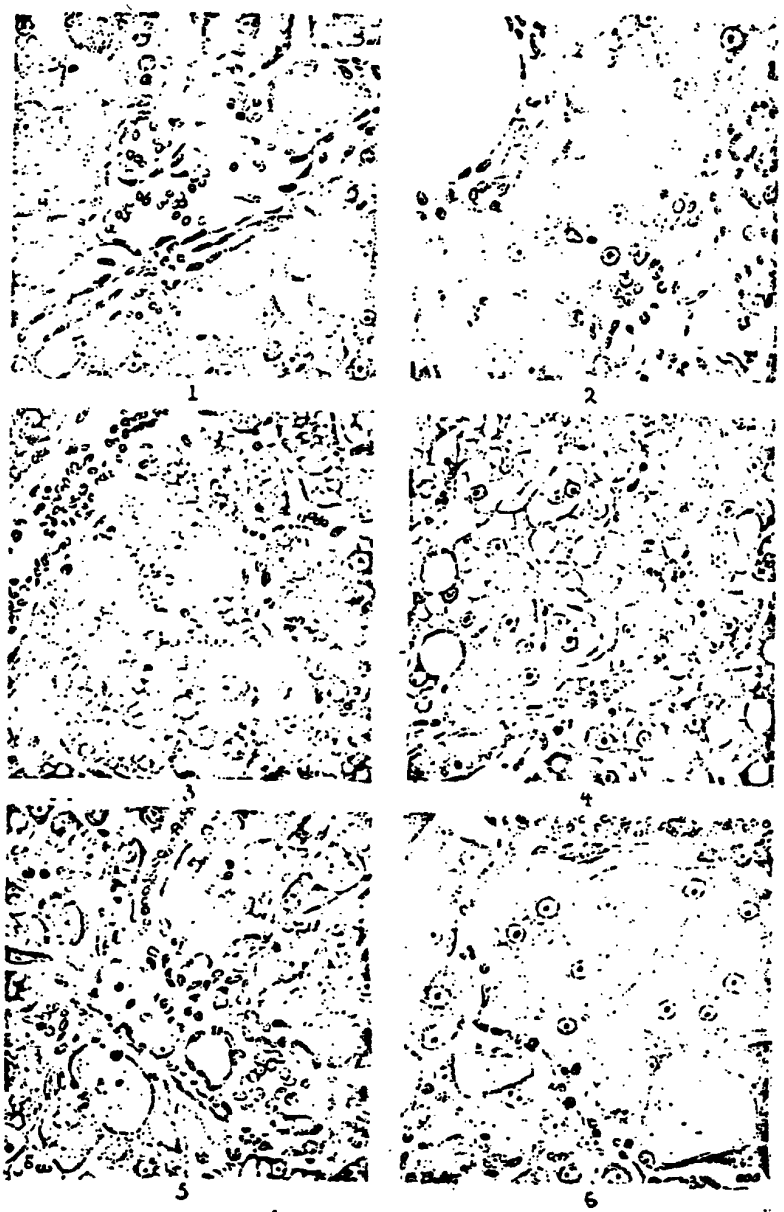

GBRN001969

TOWOLDMON0001534

no definite microscopic change. (See fig. 3, plate II.) All other organs were normal.*

Further evidence that the liver tissue injury had been very slight was obtained from the carbon tetrachloride and alcohol test. Of 10 rats exposed for 144 days in the above manner and then fed 0.75 cc. per kgm. each of carbon tetrachloride and ethyl alcohol by stomach tube, none died. At autopsy and on microscopic examination there was little or no evidence of liver injury greater than that produced by the same dose of carbon tetrachloride and alcohol in normal control rats. (See plate IV, figs. 1 and 2, and plate V, fig. 1.)

The livers of 8 animals exposed to trichlornaphthalenes for 105 days and autopsied after a 2 month recovery period showed no definite pathological change. This is further evidence that this compound is only slightly toxic. These findings represent a marked contrast to the persistent hepatic lesions resulting from exposure to the compounds of higher chlorination.

(b) *Exposure by inhalation to high concentration (10.97 mgms. per cu. m.) 16 hours daily.*—In this experiment, the concentration of trichlornaphthalenes was approximately eight times that previously employed. Exposure was continued for 102 days. The 50 animals subjected to this concentration appeared normal. Groups of 3 to 17 rats were sacrificed after exposure periods of 31, 48, 59, 72 and 102 days. Most of the livers were pale yellow in color and slightly mottled. There was, however, no significant variation in liver weight. Microscopic examination revealed swollen liver cells with slightly increased granularity and vacuolization of the cytoplasm. Occasional degenerating and regenerating cells were observed. These changes, which were slightly more marked in the central portion of the liver lobules, were present after the first month of exposure. They

* In none of the experiments to follow were significant changes found in any organ other than the liver.

PLATE II

FIGS. 1, 2, AND 3. Liver changes resulting from the administration of trichlornaphthalenes are illustrated in these camera lucida drawings. In figures 1 and 2 are shown the most marked changes observed after prolonged (100 and 136 days respectively) feeding in daily doses of 3 gm. per 10 rats. The changes observed consisted of slight to moderate swelling of liver cells, increased granularity of the cytoplasm and finally, after prolonged exposure, fatty vacuolization of the majority of cells and complete fatty degeneration of occasional cells. Figure 3 is a drawing from a section of the liver of a rat exposed by inhalation to low concentrations of trichlornaphthalenes for 106 days. No striking or constant changes were observed in rats so treated. Occasional cells are slightly swollen and show increased granularity of the cytoplasm. A rare mitotic figure was observed in occasional sections.

FIGS. 4, 5, AND 6. Microscopic changes observed following the administration of a mixture of penta- and hexachlornaphthalenes are illustrated in these three drawings. Figure 4 shows the changes observed after feeding this preparation in 3 gm. daily doses per 10 rats, for a period of 30 days. The liver cells are markedly swollen and vacuolated. There is also necrosis and degeneration of scattered cells. Large intercellular spaces are observed. (See plate VI, figs. 1 and 2). Less marked but similar changes are observed in the livers of rats fed smaller doses of this preparation (see fig. 5). (26 days' exposure.) Figure 6 illustrates the liver cell changes that occurred after inhalation of low concentrations, of penta- and hexachlornaphthalenes for 75 days. Note the swelling of the liver cells, the increased vacuolization and presence of large numbers of hyaline globules within cells. Mitotic figures were frequently observed.

Camera lucida drawings × 395.

GBRN001970

TOWOLDMON0001535

ent hepatic
osure to the
orination.

tion to high
per cu. m.)
experiment,
hlornaphtha-
eight times
l. Exposure
ays. The 50
s concentra-
Groups of 3
l after expo-
, 72 and 102
rs were pale
htly mottled.
o significant
ight. Micro-
aled swollen
ly increased
zation of the
degenerating
ere observed.
were slightly
ntral portion
present after
osure. They

---

nistration of a
achlornaphtha-
se three draw-
anges observed
tion in 3 gm.
a period of 30
arkedly swollen
also necrosis
l cells. Large
bserved. (See
s marked but
i in the livers
is preparation
re.) Figure 6
nges that oc-
ow concentra-
rnaphthalenes
ng of the liver
ation and pres-
aline globules
es were fre-

395.

PLATE II

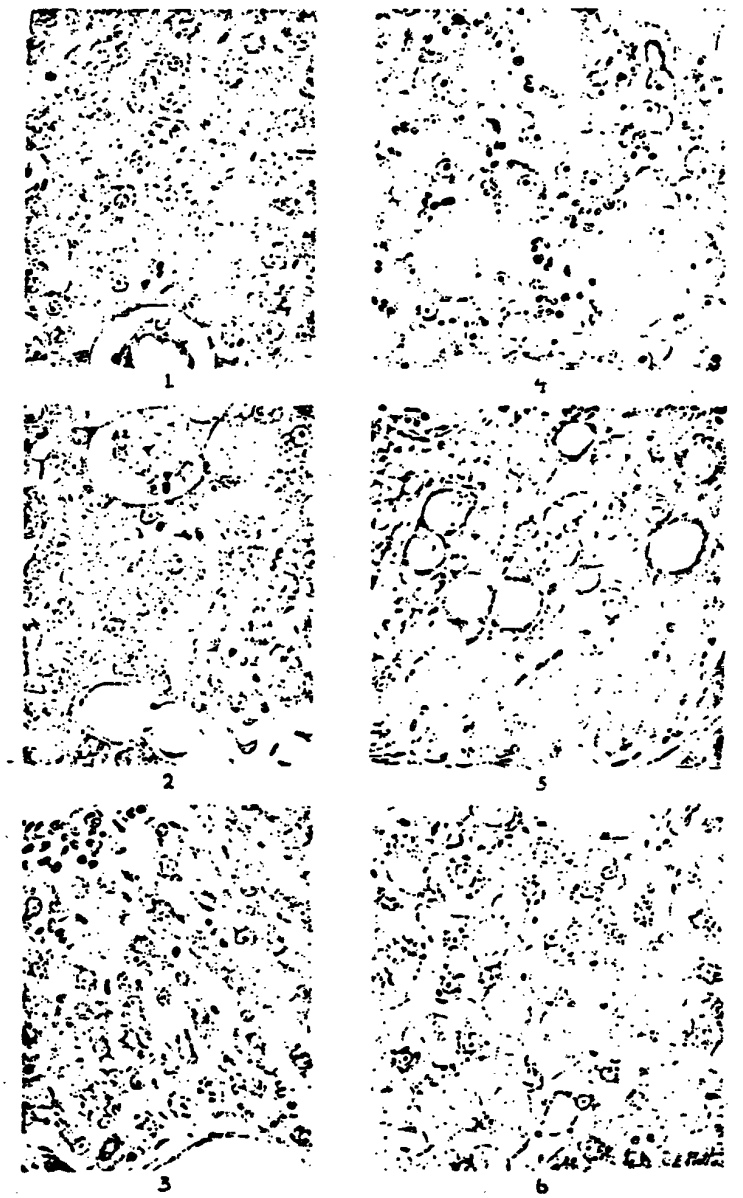

GBRN001971

TOWOLDMON0001536

were somewhat increased with longer exposure. After 102 days the liver cells were more markedly swollen and contained large and small fat vacuoles. Small hyaline droplets in the cell cytoplasm were occasionally observed. Mitotic figures, although never numerous, were increased in number. No structural changes had occurred in the liver lobules.

Carbon tetrachloride and ethyl alcohol were administered by stomach tube to 9 rats kept under these conditions. At autopsy their livers were slightly to moderately enlarged. They were yellow in color and the majority of them were mottled. The microscopic findings were variable. In one animal the observed necrosis was no greater than that seen after the administration of a similar dose of carbon tetrachloride and alcohol to normal control rats. The livers of 4 animals showed increased fatty degeneration in the central portions of the lobules with small necrotic foci. In the 4 remaining animals extensive central necrosis had occurred. In the most marked of these (fig. 2, plate V), the central one-half or two-thirds of each liver lobule was necrotic and in occasional areas two or more adjacent lobules had undergone degeneration. Hemorrhage and extensive leucocytic infiltration had occurred in these necrotic areas. The less damaged liver cells at the periphery of the lobules showed large numbers of mitotic figures, indicating accelerated regenerative activity.

(*c*) *Exposure by feeding.*—Nine of the 10 rats fed trichloronaphthalenes in doses of 3 gm. per day per 10 rats were sacrificed at varying periods of time from 9 to 136 days. The tenth rat died of a respiratory infection after 182 days' exposure. There was no significant abnormality in the weights of the livers of these animals. After 2-months' exposure, microscopic examination of the livers showed slight swelling of liver cells. This was accompanied by increased vacuolization of the cytoplasm due to the accumulation of abnormally large

PLATE III

FIGS. 1, 2, AND 3. Liver changes resulting from the administration, by feeding and inhalation, of a mixture of penta- and hexachloronaphthalenes (90%) and chlorinated diphenyl (10%) are illustrated in these drawings. Figure 1 is a drawing made from a section stained with P.T.A.H. In addition to other changes it demonstrates the presence of large and small intercellular spaces, interpreted as dilated bile capillaries. These spaces contained serous precipitate, fibrin, and occasional leucocytes. Note the sharply outlined boundaries of the spaces and the manner in which these spaces ramify between cells. This rat was exposed by the feeding of large daily doses for 12 days. Similar but less marked changes resulted from the feeding of small doses over a period of 28 days (see fig. 2). After 75 days' exposure by inhalation to low concentrations of this preparation, marked liver changes, consisting of cellular swelling, vacuolization, and hyalinization were apparent (fig. 3).

FIGS. 4, 5, AND 6. The microscopic changes resulting from exposure to chlorinated diphenyl are illustrated in these figures. Figure 4 was made from the liver of a rat fed large daily doses for only 6 days. Marked swelling of cells and rapid regenerative activity are apparent. Figure 5 illustrates the changes that were uniformly produced by the feeding of small doses of this preparation. Note the extremely numerous hyaline inclusions in liver cells. This rat was exposed for 29 days. Very similar changes were produced by the administration of this compound by inhalation methods (fig. 6). The rat from which this drawing was made had been exposed to low concentrations for a period of 107 days.

FIG. 1. Camera lucida drawing × 95.
FIGS. 2 TO 6. Camera lucida drawings × 395.

GBRN001972

TOWOLDMON0001537

l. 20, no. 2

2, plate V),
-thirds of
tic and in
adjacent
eneration.
leucocytic
in these
damaged
ry of the
mbers of
accelerated

.—Nine of
thalenes in
per 10 rats
periods of
The tenth
fection after
re was no
the weights
mals. After
scopic exam-
owed slight
This was
l vacuoliza-
due to the
mally large

pparent (fig.
microscopic
ure to chlor-
ted in these
from the liver
for only 6
ds and rapid
nt. Figure
t were uni-
ing of small
Note the ex-
nclusions in
posed for 29
were produced
compound by
The rat from
ole had been
s for a period

awing × 95.
ids drawings

PLATE III

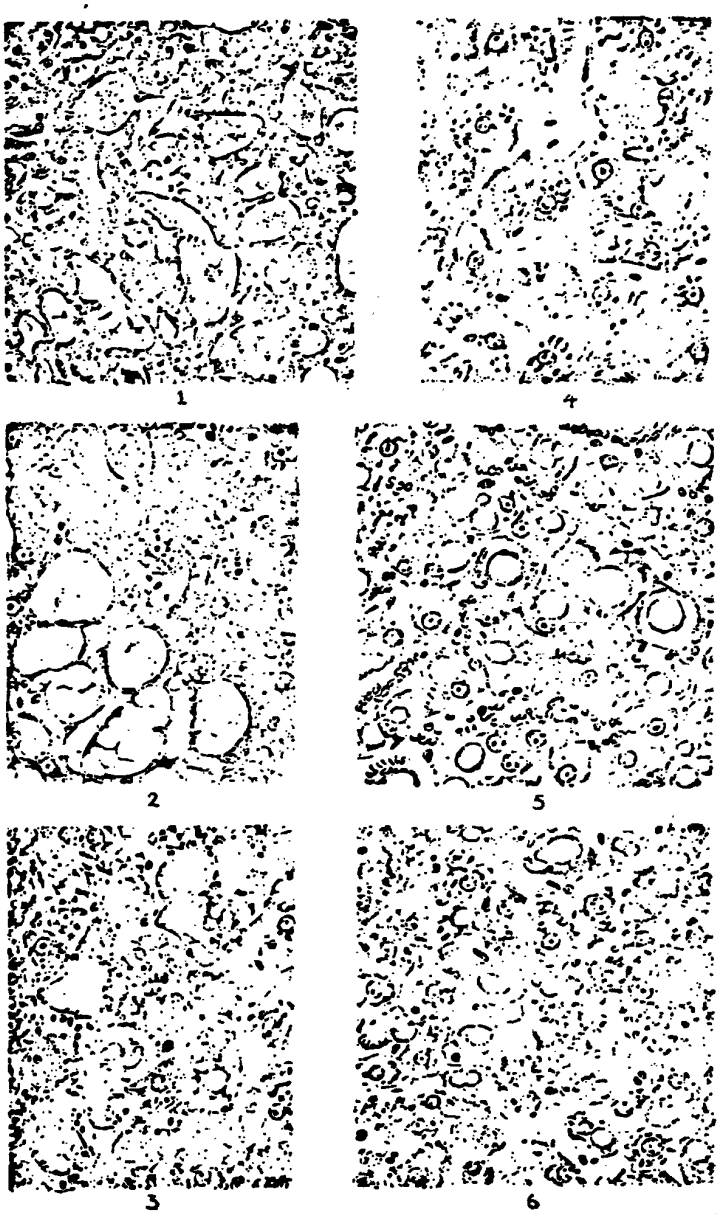

GBRN001973

TOWOLDMON0001538

amounts of fat. These changes increased slightly with longer exposure. (See plate II, figs. 1 and 2.) There were no architectural changes in the liver.

Because the effects resulting from large doses of trichlornaphthalenes were slight, this compound was not fed in small amounts.

Compound B. Tetra- and pentachlornaphthalenes

Exposure by feeding.—This preparation was employed only in feeding experiments. The daily food ration for 10 rats contained 0.5 gm. of this compound. All animals fell ill and either died or were sacrificed by the sixty-third day.

The livers were pale yellow in color, friable, and occasionally showed mottling. There were no significant variations in weights. On microscopic examination the same changes were observed in all rats. These consisted of moderate to marked swelling and rounding of the liver cells. The sinusoids were markedly narrowed. The majority of the liver cells contained large numbers of small fat vacuoles. This finding was most marked and first observed in the central portions of the lobules. In the least altered cells there was prominent massing of basophilic granules near the nuclei. Occasional necrotic cells were observed. Mitotic figures were present in increased numbers, indicating accelerated regenerative activity. The microscopic changes resulting from the feeding of tetra- and pentachlornaphthalenes are illustrated in plate I, figures 3 and 4. They are those of diffuse fatty infiltration and fatty degeneration.

Compound C. Tetra- and Pentachlornaphthalenes plus Chlorinated Diphenyl

Exposure by feeding.—Feeding (3 gm. doses daily per 10 rats) was continued with but one 4 day interruption for 130 days. Ten rats were so treated. Seven rats were sacrificed at varying periods of 47 to 124 days. Three rats died after exposure periods of 122 to 130 days. In all animals the livers were enlarged (33 to 90 per cent). The average weight increase was 71 per cent. They were also friable, pale yellow in color, and somewhat mottled. On microscopic examination, constant changes were observed. Practically every liver cell was swollen and rounded. Their cytoplasm contained large numbers of hyaline bodies. These were circular or oval in shape and varied in size from about half the size of a red blood corpuscle to twice the size of the nucleus of a liver cell. (See figs. 1 and 2, plate I.) In numerous instances, many small hyaline bodies had fused, forming large circular masses as large or larger than a normal

PLATE IV

FIG. 1. Photomicrograph × 45 illustrating the extent of the liver damage produced in 48 hours by 0.75 cc. per kgm. each of carbon tetrachloride and ethyl alcohol when administered by stomach tube to a normal control rat. The degenerative changes were limited to the central portion of the lobules.

FIG. 2. Photomicrograph × 220 of a section of liver tissue from a rat exposed by inhalation methods to trichlornaphthalenes in low concentration for 150 days. Following this exposure 0.75 cc. per kgm. each of carbon tetrachloride and ethyl alcohol was administered by stomach tube. The animal survived and was sacrificed 17 days later. No significant liver changes are demonstrable.

GBRN001974

TOWOLDMON0001539

PLATE IV



FIG. 1



FIG. 2

GBRN001975

TOWOLDMON0001540

liver cell. These bodies stained brilliantly with eosin dye. They were often laminated and occasionally contained small clear fat vacuoles in their central portions. Mitotic figures in liver cells were sufficiently numerous to indicate an increased rate of regeneration (fig. 1, plate I). In the livers of 2 rats exposed for 124 and 125 days respectively, there were, in addition to the above changes, large areas of complete liver cell degeneration (fig. 2, plate I). For the most part this was limited to the central half or third of the liver lobules. Occasionally, however, there was complete degeneration of all liver cells except for a narrow zone of cells around the portal areas. In such livers there was a heavy polymorphonuclear and mononuclear inflammatory cell infiltration in the necrotic areas where liver cells were being removed.

The most conspicuous feature of the microscopic changes in the livers of these rats was the presence of large numbers of circular hyaline droplets in the cytoplasm of the liver cells. This material did not stain in a manner characteristic of amyloid and its staining properties were not like those of the hyaline observed in alcoholic cirrhosis. In frozen sections stained with Scharlach R, the staining reaction of these bodies was inconstant. The larger vacuolated hyaline bodies contained small droplets of fat while the majority of the smaller droplets did not stain red. Although similar hyaline droplets were observed in livers of rats exposed to various chlorinated naphthalenes, this type of degeneration occurred much earlier and to a much more marked degree in those rats that were exposed to preparations containing chlorinated diphenyl (figs. 1 and 2, plate I) or to chlorinated diphenyl alone (figs. 4, 5, and 6, plate III).

Compound D. Penta- and hexachlornaphthalenes

(a) *Exposure by inhalation to low concentrations (average 1.16 mgms. per cu. m.) 16 hours daily.*— Eighty rats living under these conditions appeared normal throughout the exposure period (134 days). Representative animals were sacrificed in groups of 3 to 15 animals after varying exposure periods as described in the experiments employing trichlornaphthalenes. There were no significant alterations in liver weights. Macroscopically the majority of the livers were light yellow in color and slightly mottled. After the initial exposure period of 37 days there was evidence of slight injury to

PLATE V

FIG. 1. A photomicrograph × 120 showing small areas of necrosis in central areas of the liver lobules. This rat had been exposed by inhalation to low concentrations of trichlornaphthalenes for 134 days following which carbon tetrachloride and ethyl alcohol were administered by stomach tube in doses of 0.75 cc. each per kgm. The rat was sacrificed 5 days later. The extent of necrosis is similar to that resulting from carbon tetrachloride and alcohol alone.

FIG. 2. In this photomicrograph × 45 are shown the most marked liver changes that were observed following the administration of carbon tetrachloride and alcohol (0.75 cc. of each per kgm.) to rats which had been exposed by inhalation methods to high concentrations of trichlornaphthalenes. This rat had been exposed to trichlornaphthalenes for 1 month. Very extensive necrosis was present in the central areas of each liver lobule. In occasional areas the major portion of several adjacent lobules were necrotic. This rat was autopsied 48 hours after the administration of carbon tetrachloride.

GBRN001976

TOWOLDMON0001541

PLATE V



FIG. 1



FIG. 2

GBRN001977

TOWOLDMON0001542

liver cells which appeared swollen and more granular than normal. The cytoplasm of occasional cells contained small acidophilic hyaline droplets and there was a moderate excess of fat in the form of tiny vacuoles (fig. 6, plate II). All microscopic abnormalities increased slightly during the second period (37 to 72 days) but no significant advance was detected between the 72nd and 134th day of exposure.

The livers of rats exposed for 105 days and then removed from exposure for a period of 2 months still showed cellular changes similar to those observed at the beginning of the recovery period. In a few of the specimens they appeared slightly less marked, indicating that some repair had taken place. In no instance was there evidence of increased damage.

Carbon tetrachloride and ethyl alcohol administered to rats exposed in the above manner for 144 days proved highly fatal, 9 out of 10 rats dying within the first 6 days—6 within 72 hours. At autopsy the livers of these rats were yellow and mottled and they were increased in weight (16 to 44 per cent). Microscopic examination showed widespread central necrosis similar to that observed in early acute yellow atrophy of man (see figs. 1 and 2, plate VII). The central one-half or two-thirds of each liver lobule showed complete liver cell necrosis and degeneration. Diffuse extravasation of erythrocytes had occurred and numerous polymorphonuclear and mononuclear leucocytes had invaded the necrotic areas. In the narrow periportal zones where the liver cells were less markedly damaged, there were large numbers of mitotic figures (fig. 2, plate VII).

(b) *Exposure by inhalation to low concentrations (average 1.44 mgms. per cu. m.) 8 hours daily.*—Animals were subjected to these conditions for 143 days. Groups of animals sacrificed after 42, 77, 98, 119, and 143 days' exposure showed liver changes that were essentially like those seen in rats exposed 16 hours daily. The carbon tetrachloride and alcohol test was uniformly fatal and produced liver changes that were identical to those already described and illustrated (figs. 1 and 2, plate VII).

(c) *Exposure by inhalation to high concentrations (average 8.88 mgms. per cu. m.) 16 hours daily.*—Penta- and hexachlornaphthalenes when administered in this concentration proved highly toxic. Eighty animals were

PLATE VI

FIG. 1. Photomicrograph × 220 of the liver of a rat exposed to penta- and hexachlornaphthalenes by the feeding of large daily doses for 16 days. The liver cells are swollen and markedly vacuolated. There is distortion of the liver cell columns. In frozen section preparations stained with Scharlach R, there was evidence of marked fatty degeneration. In addition to these changes, numerous oval, round and irregular intercellular spaces are present throughout the liver lobules. Such spaces contain a granular serous precipitate, strands of fibrin and occasional leucocytes. These spaces, insofar as could be determined, were due to dilatation of the bile capillaries and canaliculi.

FIG. 2. This photomicrograph × 215 when compared with the above figure demonstrates the similarity of the liver changes produced by the same compound administered in a different manner. In this instance the rat inhaled high concentrations of penta- and hexachlornaphthalenes for 38 days.

GBRN001978

TOWOLDMON0001543

PLATE VI



FIG. 1



FIG. 2

GBRN001979

TOWOLDMON0001544

used, all of which lost weight and appetite. Four died by the end of the first month, 55 within 52 days. Most of these were markedly jaundiced. The remainder were sacrificed for pathological examination or succumbed to the effects of carbon tetrachloride and alcohol. Only 8 animals survived the 52 day exposure. The majority of livers were moderately or markedly enlarged. They were all yellow and in addition the majority were markedly mottled. Occasionally they were granular and their cut surfaces showed minute spaces which became more prominent after fixation. After an 8 day exposure, the liver cells were markedly swollen and moderate fatty degeneration was present. This was most marked in the central areas although all portions of the liver lobules were affected. The extent of liver injury rapidly increased so that after 30 days' exposure, marked structural as well as cellular changes were apparent. The microscopic appearances were identical to those to be described in rats fed large doses of penta- and hexachlornaphthalenes (figs. 1 and 2, plate VI) and in rats fed similar doses of 90 per cent penta- and hexachlornaphthalenes plus 10 per cent chlorinated diphenyl (see fig. 1, plate III and figs. 1 and 2, plate VIII).

Rats removed from exposure between the third and fifth week continued to die, the longest survival time being 35 days. Microscopic examination of the livers of these animals revealed no evidence of recovery.

Administration of carbon tetrachloride and alcohol again proved fatal to animals exposed in the above manner. The livers of such animals showed the characteristic massive necrosis previously described and illustrated.

(d) *Exposure by feeding.*—When fed in doses of 3 gm. daily to a group of 10 rats, penta- and hexachlornaphthalenes produced marked cellular and structural changes in the liver in a short period of time. All rats lost weight and appeared ill from the beginning. The longest survival time was 33 days. Although the liver edges were blunt and rounded, there were no significant weight variations. The livers were friable, yellow and mottled. Microscopically they showed marked swelling and vacuolization of the cells. There was also complete degeneration of scattered cells. Occasional mitotic figures were observed (see fig. 4, plate II). Suitable stains revealed very marked fatty degeneration. Occasional cells contained oval shaped or circular acid-

PLATE VII

FIG. 1. A low power photomicrograph × 45 illustrating the marked degree of degeneration of liver tissue resulting from the administration of a small dose of carbon tetrachloride and ethyl alcohol (0.75 cc. of each per kgm.) to an animal that had been exposed previously by inhalation methods to low concentrations of penta- and hexachlornaphthalenes for 134 days. This animal died within 24 hours after the administration of carbon tetrachloride.

Similar degrees of necrosis resulted from the administration of carbon tetrachloride and alcohol to rats which had been exposed to a mixture of 90% penta- and hexachlornaphthalenes and 10% chlorinated diphenyl or to refined chlorinated diphenyl.

FIG. 2. A higher power photomicrograph × 225 of the liver illustrated in the above figure.

GBRN001980

TOWOLDMON0001545

PLATE VII



FIG. 1



FIG. 2

GBRN001981

TOWOLDMON0001546

ophilic hyaline inclusions. In addition to these cytological changes there were numerous varying sized intercellular spaces throughout the livers (see figs. 1 and 2, plate VI and fig. 1, plate III). These spaces were usually circular or oval in shape, although many of them ramified between cells in the liver columns or between liver cells and the sinusoidal endothelium in such a way as to suggest that they represented greatly dilated bile capillaries or canaliculi (fig. 1, plate III). They contained serous precipitate, a few strands of fibrin, and occasionally a few leucocytes. Rarely one observed one or two degenerating liver cells within these spaces. In some of the more markedly damaged livers, red blood corpuscles were also present. The above microscopic changes appeared identical to those observed in the livers of rats subjected to high concentrations of this compound by inhalation methods (figs. 1 and 2, plate VI). They were also similar to the changes that resulted from the feeding of another penta- and hexachlornaphthalene compound (figs. 5 and 6, plate I) and from the feeding of a mixture of penta- and hexachlornaphthalene (90 per cent) and chlorinated diphenyl (10 per cent).

When this preparation of penta- and hexachlornaphthalenes was fed in smaller amounts (0.5 gm. every second day to a group of 4 rats) the above described liver changes occurred less rapidly and to a lesser degree (see fig. 5, plate II).

Compound E. Penta- and Hexachlornaphthalenes

Exposure by feeding.--Feeding in doses of 1 gm. daily for 10 rats was continued with but one 4 day interruption. All 10 rats had died or had been sacrificed by the fifty-fifth day. These livers were friable and yellowish, and exhibited moderate to marked mottling. One animal was jaundiced. Of the 5 animals that were sacrificed, three showed enlargement of the liver (30 to 40 per cent); the remaining livers were normal in size. On microscopic examination the livers of rats exposed for 2 weeks showed marked cellular changes that appeared to be degenerative in nature. Although the liver cell injury was somewhat greater in the central portions of the liver lobules, no portion of the liver was spared. The liver cells showed varying degrees of swelling, increased granularity and vacuolization of the cytoplasm. Early injury was indicated by a massing of basophilic granules and small rod-shaped structures near the cell nuclei. The peripheral portions of such cells were acidophilic and vacuolated. Small irregular spaces were present between

PLATE VIII

FIG. 1. A photomicrograph × 95 of the liver of a rat fed a mixture of 90% penta- and hexachlornaphthalenes and 10% chlorinated diphenyl, in 3 gm. doses per 10 rats for 12 days. This rat survived for 23 days after feeding was stopped. A comparison of the liver of this rat with those of rats sacrificed earlier indicated that the liver changes had progressed considerably after administration of the compound had been terminated. One should note the marked change in the liver architecture. The spaces like those previously illustrated (figs. 1 and 2, plate VI) are very large and the remaining liver tissue is compressed. The liver cells show marked fatty degeneration.

FIG. 2. A higher power photomicrograph × 235 from another area in the liver illustrated in the above figure.

GBRN001982

TOWOLDMON0001547

PLATE VIII

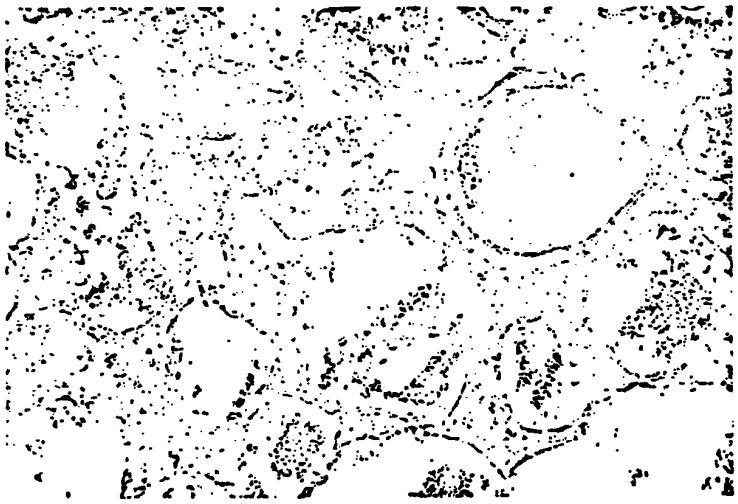

FIG. 1



FIG. 2

GBRN001983

TOWOLDMON0001548

liver cells and between the columns of liver cells and the sinusoidal endothelium (see fig. 5, plate I). These were interpreted to be the early stages in the formation of large intercellular spaces (fig. 6, plate I) which subsequently developed and which were identical to the spaces described in the foregoing section. After longer exposure the liver cells showed very marked swelling and fatty infiltration. Occasional degenerating and regenerating cells were observed.

Compound F. 90 per cent Penta- and Hexachlornaphthalenes and 10 per cent Chlorinated Diphenyl

(a) *Exposure by inhalation.*—Inhalation experiments were carried out on two groups of rats. The first of these groups of 80 animals were exposed to low concentrations (average 1.37 mgms. per cu. m.) 16 hours daily for 134 days. The second group, also comprised of 80 rats, was exposed to low concentrations (average 1.66 mgms. per cu. m.) 8 hours daily for 143 days. No evidence of illness was noted in the living animals in either group. In each experiment representative groups of animals were sacrificed after exposure periods corresponding to those used in low concentration inhalation experiments with trichlornaphthalenes and penta- and hexachlornaphthalenes.

Since there were no recognizable differences in the amount or type of liver change observed after similar exposure periods in these two groups of rats, the second group (exposed 8 hours daily) will not be discussed.

Macroscopically the livers were usually light yellow. After prolonged exposure, this abnormality was more marked and in many instances mottling was present. There were no very significant alterations in the weights of livers although the majority were slightly swollen (average of 20 per cent increase in weight). Microscopically the livers showed constant changes after 37 days of exposure. These increased somewhat during the second period of 35 days. Longer exposure produced little if any increase in liver damage. The observed pathological changes consisted of swelling and rounding of liver cells accompanied by a definite increase in the prominence of the cytoplasmic granules. Hyaline droplets in the altered cytoplasm were a conspicuous feature (see fig. 3, plate III). Mitotic figures were present in abnormally large numbers. In an occasional liver, as was the case with similar exposure to both penta- and hexachlornaphthalenes alone and refined chlorinated diphenyl, there was a marked deposit of finely divided granular and refractile yellow or yellow brown pigment. This was present within liver and Kupffer cells. Larger amounts were found in the central portions of the liver lobules. It failed to stain in a manner characteristic of either hemosiderin or hemofuscin.

The livers of rats removed from exposure for 2 months after an exposure period of 105 days were similar to those of animals sacrificed at the end of 105 days' exposure. There was, however, no evidence of any increase in the pathological changes.

The administration of carbon tetrachloride and alcohol was almost uniformly fatal. Macroscopic examination of livers of these rats revealed marked enlargement (approximately

GBRN001984

TOWOLDMON0001549

50 per cent). Such livers were yellow and mottled. Again there was extensive and widespread liver necrosis on microscopic examination (see figs. 1 and 2, plate VII).

(b) *Exposure by feeding.*—When fed in large doses (3 gm. daily for 10 rats) this compound proved to be very toxic. All animals appeared ill and feeding of the compound was stopped after 12 days. Despite this the rats continued to die, the last dying on the 35th day. Subsequent microscopic examination revealed that the liver changes had continued to progress after feeding was stopped. Macroscopically, the majority of the livers were enlarged, the largest showing an increase in weight of 118 per cent; the average increase was approximately 40 per cent. All livers were yellow, friable, and many of them were markedly mottled. Subsequent microscopic examination indicated that much of the mottling was due to hemorrhage into spaces within the liver tissue. In addition, the external and cut surfaces of the livers appeared slightly pitted or granular. The microscopic changes observed in the livers of the animals autopsied after 10 to 14 days' exposure consisted of moderate to marked swelling of liver cells accompanied by marked fatty vacuolization. Occasional liver cells showed additional signs of injury such as nuclear degeneration and polymorphonuclear leucocytic invasion. Scattered circular or oval shaped intercellular spaces (fig. 1, plate III) like those previously described in experiments where penta- and hexachlornaphthalenes were employed (figs. 1 and 2, plate VI) were obeerved. In the less markedly damaged livers, such spaces contained serous precipitate, strands of fibrin, and small numbers of leucocytes. In rats surviving 18 to 35 days, these spaces were much larger and often had attained the size of a normal liver lobule (see figs. 1 and 2, plate VIII). In these more severely damaged specimens, extensive hemorrhage had occurred (fig. 2, plate VIII). In sections stained with P.T.A.H. these spaces were seen to be bounded by flattened liver cells which showed sharp cell borders. Liver cells between such spaces were distorted, swollen, and showed marked fatty degeneration. In many of these livers there was a slight increase in connective tissue between the remaining cords of liver cells and around recognizable portal areas. Proliferative changes were occasionally observed in the bile ducts. This was indicated by increased numbers of ducts in certain areas and by mitotic figures in the bile duct epithelial cells. No recognizable dilatation of medium sized or large bile ducts was present. In many sections the architecture of the liver was so completely altered that it was difficult to recognize the portal areas. In all sections there was evidence of fatty and hyaline degeneration of the remaining liver cells. Slight polymorphonuclear leucocytic infiltration was present. This was somewhat more marked in the periportal areas.

Feeding of this mixture of penta- and hexachlornaphthalenes and chlorinated diphenyl in smaller doses (0.5 gm. every second day for 4 rats) resulted in liver damage that developed less rapidly. The rats were sacrificed after exposure periods of

GBRN001985

TOWOLDMON0001550

21, 34, 58, and 81 days. Their livers were yellow, increased in size and showed slight mottling. Microscopically, the chief abnormality observed was marked fatty vacuolization of liver cells. No intercellular spaces like those described above were present.

Compound G. Chlorinated Diphenyl

(a) *Exposure by inhalation.*—Exposure by inhalation methods to low concentrations of chlorinated diphenyl was carried out on two groups of animals, each comprised of 80 rats, in a manner identical to that described in the foregoing sections. In the first group a 16 hour daily exposure, with an average concentration of 0.57 mgms. per cu. m., was employed. The second group of animals was exposed 8 hours daily to an average concentration of 0.93 mgms. per cu. m. Neither group of rats appeared ill. Representative animals were sacrificed in groups of 3 to 21 rats, after varying periods of exposure. In the first experiment, the animals were sacrificed after 37, 72, 105, and 134 days of exposure, in the second experiment after 42, 77, 98, 119, and 143 days. The livers were pale or slightly yellow and somewhat mottled. There were no constant variations in the weights of the livers. The microscopic findings in the two groups indicated that the different exposures had resulted in the same degree of liver injury. The pigmentation of the liver and Kupffer cells was somewhat greater in animals exposed 8 hours daily. In both experimental groups the carbon tetrachloride and alcohol test was highly fatal and led to the same extensive central necrosis of liver tissue that was observed in rats exposed to the toxic chlorinated naphthalene compounds (figs. 1 and 2, plate VII). The microscopic changes resulting from exposure to low concentration of chlorinated diphenyl alone were similar to those resulting from inhalation of penta- and hexachlornaphthalenes, plus 10 per cent chlorinated diphenyl. The most conspicuous change was hyaline degeneration (fig. 6, plate III) although swelling of liver cells, increased prominence of cytoplasmic granules and increased vacuolization were present. Mitotic figures were present in increased numbers. No microscopic evidence of recovery was found in the livers of rats exposed for 105 days and then removed from exposure for a period of 2 months.

(b) *Exposure by feeding.*—When fed in large daily doses (3 gm. for groups of 10 rats), chlorinated diphenyl proved highly toxic. Feeding was discontinued after 6 days. Seven rats died within the first 8 days. The 3 remaining rats gained in weight after the feeding was stopped and were finally sacrificed. The last animal was sacrificed 63 days after feeding was begun. The majority of livers showed a moderate increase in weight. Microscopically there was evidence that liver injury had occurred within the first few days. The cells were swollen, at times sufficiently to obscure the sinusoids. The cytoplasm of the liver cells was acidophilic in staining quality and contained small vacuoles. Small eosin-stained hyaline granules and globules were present. Mitotic figures were numerous (see fig. 4, plate III). There was little inflammatory cell infiltration and no structural changes were observed.

GBRN001986

TOWOLDMON0001551

When smaller doses (0.5 gm. every second day) of this compound were administered to 10 rats, the first death occurred after 9 days. Two additional deaths occurred after 12 days and two more by the end of the fifth week. The remaining animals were sacrificed between the 40th and the 190th day. The livers were enlarged, the average increase in liver weight being 33 per cent. They were pale and slightly mottled. The most outstanding microscopic abnormality was the presence of large numbers of varying sized acidophilic hyaline globules in the cytoplasm (see fig. 5, plate III). These hyaline globules, although larger and more numerous, appeared identical to those encountered in the livers of rats exposed to other chlorinated diphenyl preparations. The liver cells were markedly swollen and showed fatty vacuolization. There was also increased regenerative activity. No structural changes were observed in any of the livers.

Discussion

Published reports concerned with the possible systemic effects of chlorinated naphthalenes have been few in numbers. Lehmann (3) in 1919 reported that animals exposed to chlorinated naphthalenes by inhalation or feeding refused to eat and at death showed "peculiar" lesions in the liver. In 1936, Flinn and Jarvik (4) reported the results observed following the daily subcutaneous injections into 30 rabbits of enormous doses (30 mgm.) of certain chlorinated naphthalene compounds dissolved in paraffin oil. The rabbits receiving a mixture of tri- and tetrachlornaphthalenes lived and when sacrificed, after a 2 months' exposure, no pathological changes attributable to the compound injected were demonstrable. The mixtures of tetra- and pentachlornaphthalenes and of penta- and hexachlornaphthalenes proved highly fatal and degeneration of liver tissue was observed. From their findings Flinn and Jarvik concluded that certain chlorinated naphthalenes or impurities contained in them are capable of producing yellow atrophy of the liver in the rabbit. It is noteworthy, in the light of the present experiments, that the compound of lowest chlorination (a mixture of tri- and tetrachlornaphthalenes) had no apparent effect on the well being of the animals and did not produce demonstrable changes in the liver although injected daily for a period of 2 months.

The present experiments demonstrate that chlorinated naphthalene compounds and chlorinated diphenyl are capable of producing marked liver damage in the white rat without demonstrable microscopic changes appearing in the other organs. Furthermore, the characteristics of the liver lesions resulting from comparable amounts of any given compound are the same, regardless of the method of administration (inhalation, feeding, or subcutaneous injection).

An attempt has been made throughout this study to grade the toxicity of each of the several compounds tested in accordance with the severity of the liver damage produced. Although some of these compounds appeared to produce similar degrees of liver injury, the toxicity of each compound seemed directly related to its degree of chlorination. Thus, a mixture of trichlornaphthalenes (chlorine content 49.4

GBRN001987

TOWOLDMON0001552

per cent) proved to be the least toxic of any of the compounds tested, whereas chlorinated diphenyl (chlorine content 65.0 per cent) was highly toxic even in very low concentrations.

Trichlornaphthalenes, when compared to other naphthalene compounds of higher degrees of chlorination, were relatively innocuous. Even after prolonged feeding of large amounts of this material, the rats showed no evidence of ill health. After 2 months' exposure, microscopic examination of the livers revealed only slight to moderate degrees of fatty infiltration and degeneration of liver cells (plate II, figs. 1 and 2). These changes were slight when compared to those resulting from short exposures to compounds of higher chlorination. Exposure by inhalation to low concentrations of trichlornaphthalenes produced liver cell alterations that were never more than minimal (see fig. 3, plate II). Such animals withstood additional liver injury from carbon tetrachloride and alcohol in a manner indistinguishable from that of the normal animal. Somewhat greater liver injury resulted from inhalation when the air concentration of this compound was increased more than eight times that used in the previous experiment but again the liver changes were slight compared to those produced by comparable exposure to the more highly chlorinated compounds.

The mixture of tetra- and pentachlornaphthalenes employed in these experiments appeared to be considerably more toxic than was the mixture of trichlornaphthalenes. Animals fed small doses of the former of these preparations fell ill and died or were sacrificed by the 63rd day. Their livers showed extensive fatty infiltration and fatty degeneration (figs. 3 and 4, plate I).

Feeding of tetra- and pentachlornaphthalenes in combination with chlorinated diphenyl resulted in pronounced liver changes. These livers had increased in weight (average 71 per cent). Microscopic examination revealed a peculiar type of hyaline degeneration involving practically every liver cell (see figs. 1 and 2, plate I). This type of cell degeneration was more marked and occurred earlier after exposure to preparations containing chlorinated diphenyl than to any other compounds tested. Furthermore, it was most marked in the livers of animals exposed to refined chlorinated diphenyl (figs. 4, 5, and 6, plate III).

Comparable exposure of rats to penta- and hexachlornaphthalenes (Compound D), penta- and hexachlornaphthalenes (Compound E), and penta- and hexachlornaphthalenes (90 per cent) plus chlorinated diphenyl (10 per cent) (Compound F), resulted in liver changes having few detectable differences. The morphological changes were slightly greater in the livers of rats exposed to the last named compound. In these instances the hyalin degeneration of the cell cytoplasm was more marked. Although rats inhaling low concentrations of compounds D and F showed no demonstrable signs of ill health, microscopic examination of their livers revealed marked liver cell injury (fig. 6, plate II, and fig. 3, plate III). These lesions were still demonstrable after a 2 months' recovery period. Further evidence that liver damage had resulted from inhalation in low concentrations of these compounds was obtained from the carbon tetra-

GBRN001988

TOWOLDMON0001553

chloride and alcohol test. Such tests were almost uniformly fatal and resulted in widespread liver necrosis (figs. 1 and 2, plate VII). These three compounds proved to be very toxic and resulted in a most unusual type of liver change when administered in large amounts by feeding (see fig. 1, plate III, fig. 1, plate VI, and figs. 1 and 2, plate VIII). Identical changes were observed following inhalation in high concentrations of compound D (see fig. 2, plate VI). In such livers the most conspicuous feature was the presence of large intercellular spaces. Examination of routine sections, supplemented by specially stained preparations indicated that these spaces had resulted from dilatation of bile canaliculi. The reason for such dilatation was not apparent. There was no corresponding dilatation of the large and small bile ducts at the periphery of the liver lobules and no inspissated bile was ever observed. The organically combined chloride in the livers of these rats was no greater than that observed in the normal animal. Although serious liver damage results from exposure to high concentrations of these compounds, the resulting changes are most unusual and do not resemble those of acute yellow atrophy on microscopic examination.

Of the various chlorinated hydrocarbons tested, chlorinated diphenyl gave evidence of being the most toxic. When administered by inhalation in very low concentrations (average 0.57 to 0.93 mgms. per cu. m.) liver cell changes were very pronounced after the first exposure period. The most striking change was the hyalinization of the cell cytoplasm (see fig. 6, plate III). Such cellular alterations were essentially unchanged after a 2 month recovery period. In these animals small sublethal doses of carbon tetrachloride and alcohol uniformly produced extensive liver necrosis and was highly fatal to them (figs. 1 and 2, plate VII). Chlorinated diphenyl fed in small doses produced similar but more marked liver injury (see fig. 5, plate III). In large doses this compound was highly fatal. The liver changes in animals dying after short exposures were inconspicuous and consisted mainly of swelling of cells and active regeneration (see fig. 4, plate III). However, animals removed from exposure before being fatally poisoned, subsequently developed hyaline degeneration of liver cells similar to that produced by prolonged administration of small doses of this compound.

Thus the results of the present study, as well as certain field studies that have been made (1) suggest that the solution of the industrial hazard involved is dependent largely on a reduction of the air concentration of these compounds to a level that will not produce liver damage. The present experiments indicate that lower air concentrations must be obtained in the case of the more highly chlorinated naphthalene compounds and chlorinated diphenyl than for trichlornaphthalenes if a safe environment for workmen is to be assured. Because of the pronounced toxic effect of small doses of carbon tetrachloride on the livers of animals already injured by exposure to chlorinated naphthalenes and chlorinated diphenyl, its use as a solvent for these compounds would appear to be very hazardous.

Although this investigation was designed to determine what systemic

GBRN001989

TOWOLDMON0001554

effects, if any, would be produced in experimental animals by a group of chlorinated hydrocarbons, the pathological changes produced have been of such a nature as to justify further comment. Exposure of rats to highly chlorinated naphthalene compounds and chlorinated diphenyl results in a type of liver injury differing considerably from the liver lesions resulting from carbon tetrachloride (5, 6) and chloroform poisoning (7). The changes resulting from exposure to the compounds employed in this study involve all portions of the liver lobule. This is true despite the fact that the initial morphological changes are more pronounced in the liver cells nearest the hepatic veins. The changes observed are degenerative in nature. The successive degenerative changes were cloudy swelling, fatty infiltration and fatty degeneration and finally, the complete disintegration of the cell. Degeneration characterized by the accumulations of large amounts of acidophilic hyaline material was also observed. This feature was much more marked in the livers of animals exposed to the compounds containing chlorinated diphenyl. It is of interest that widespread degenerative changes of all liver cells can exist for several months without producing any evidence of ill health in the animals or without causing important structural changes in their livers. Such findings suggest that the alterations take place slowly and that the scattered necrotic cells are efficiently removed and replaced by new cells which also become injured. There was no observable morphological evidence to indicate that the regenerating liver cells had acquired an increased resistance to the injurious effects of the compound being used (8). The fact that liver cell changes were still present after a 2 month period during which the animals were removed from exposure to the more highly chlorinated compounds is further evidence that this type of injury is persistent and only slowly recovered from.

The administration in high concentrations of two compounds of intermediate degrees of chlorination resulted in marked structural changes in addition to marked degenerative changes in liver cells. The most conspicuous change was the occurrence of progressively enlarging intercellular spaces. These were interpreted as markedly dilated bile canaliculi. We are unaware of such changes having been previously described.

From the above it is apparent that exposure to highly chlorinated naphthalenes and chlorinated diphenyl not only results in liver changes having marked differences from those caused by other well known toxic agents, but also that the characteristics of the liver changes produced can be markedly altered quantitatively and qualitatively by varying the degree of exposure. For these reasons one would seem justified in suggesting that detailed studies on animals in which the types of liver injury observed in these experiments had been produced might further our understanding of liver cell function.

Summary

1. Studies concerning the effect upon white rats of a group of chlorinated naphthalene compounds and chlorinated diphenyl are reported. This investigation was undertaken because of the recent occurrence of 3 fatal cases of jaundice in men work-

GBRN001990

TOWOLDMON0001555

ing in industrial plants where these compounds were being used. The compounds tested were selected as representative of a certain range of chlorination and because of their relative industrial importance.

2. Four of the compounds tested were administered by inhalation. The air concentration and exposure periods were varied. All compounds were tested by feeding in large and small amounts. In addition three of them were tested on small numbers of animals by subcutaneous injections. The effects of any given compound did not appear to be influenced by the method of administration. However, marked quantitative and qualitative differences in the effects of each of several compounds resulted from varying the air concentrations in inhalation experiments and the dosage employed in feeding experiments.

3. Macroscopic and microscopic examination of the tissues of rats exposed to these compounds indicated that the injurious effects are manifested solely in the liver. Blood examination during life revealed no significant abnormalities.

4. The liver changes resulting from exposure to the chlorinated hydrocarbons employed have been described and illustrated. As indicated by their ability to injure liver tissue the toxicity of these compounds increases with increasing degrees of chlorination. Thus a mixture of trichlornaphthalenes is relatively innocuous in low concentrations and when compared with compounds of higher chlorination, its toxic properties even in higher concentrations are relatively slight. Chlorinated diphenyl appears to be the most injurious compound of all those tested.

5. Administration of small sublethal doses of carbon tetrachloride and ethyl alcohol to rats whose livers have already been injured by the compounds under consideration is highly fatal and produces massive necrosis of the liver.

6. The significance of this study in relation to the industrial problem involved is discussed.

7. It is suggested that the types of liver injury observed in this study might be employed in experiments designed to study liver cell function.

BIBLIOGRAPHY

1. Drinker, C. K., Warren, M. F., and Bennett, G. A.: The problem of possible systemic effects from certain chlorinated hydrocarbons. This J., *18*, 263 (1937).
2. Lamson, P. D.: Personal communication.
3. Lehmann, K. B.: Kurzes Lehrbuch der Arbeit und Gewerbehygiene. S. Hirzel, Leipzig, 1919 (p. 251).
4. Flinn, F. B., and Jarvis, N. E.: Action of certain chlorinated naphthalenes on the liver. Proc. Soc. Exp. Biol. and Med., *35*, 113 (1936).
5. Gardner, G. H., Grove, R. C., Gustafson, R. K., Marrs, E. D., Thompson, M. J., Wells, H. S., and Lamson, P. D.: Studies on the pathological histology of experimental carbon tetrachloride poisoning. Bull. Johns Hopkins Hosp., *36*, 107 (1925).
6. Cameron, G. R., and Karunaratne, W. A. E.: Carbon tetrachloride cirrhosis in relation to liver regeneration. J. Path. and Bact., *42*, 1 (1936).
7. Whipple, G. H., and Sperry, J. A.: Chloroform poisoning. Liver necrosis and repair. Bull. Johns Hopkins Hosp., *20*, 276 (1909).
8. MacNider, W. A.: A study of the acquired resistance of the fixed tissue cells morphologically altered through processes of repair. J. Pharm. and Exp. Therap., *56*, 359 (1936).

GBRN001991

TOWOLDMON0001556