LABORATORY INVESTIGATION
Copyright © 1977 by the International Academy of Pathology

File

Vol. 36, No. 2, p. [illegible]
Printed in U.S.A.

Interaction of Crocidolite Asbestos with Hamster Respiratory Mucosa in Organ Culture

BROOKE T. MOSSMAN, M.S., JUDITH B. KESSLER, B.S., BRENDA W. LEY, AND

R- CCVE — DR. Wm. C. Waggoner
CC RM — JBP Res., Raritan, N.J.

J&J-0008793

Protected Document--Subject to Protective Order

LABORATORY INVESTIGATION
Vol. 36, No. 2, p. 131, 1977
Copyright © 1977 by the International Academy of Pathology
Printed in U.S.A.

Interaction of Crocidolite Asbestos with Hamster Respiratory Mucosa in Organ Culture

BROOKE T. MOSSMAN, M.S., JUDITH B. KESSLER, B.S., BRENDA W. LEY, AND JOHN E. CRAIGHEAD, M.D.

Department of Pathology, University of Vermont College of Medicine, Burlington, Vermont 05401

Organ cultures of hamster trachea were used to study the effects of crocidolite asbestos on the respiratory epithelium and the uptake of asbestos by cells of the mucosa. International Union Against Cancer (U. I. C. C.) crocidolite was suspended in medium over a range of concentrations and precipitated on the epithelial surface for 1 hour. At intervals during the ensuing 4 weeks, morphologic changes were documented by light, scanning electron, and transmission electron microscopy.

Cytotoxic alterations in differentiated mucosal cells appeared to relate to the amount of crocidolite added to the cultures. Necrosis and desquamation of surface cells were accompanied by basal cell hyperplasia. These proliferating cells phagocytosed the dust and incorporated it into lysosomes. Crocidolite was also found interposed between cells of the hyperplastic basal cell layer. Transport of asbestos particles to the submucosa and uptake by mesenchymal cells was apparent after 1 week.

Additional key words: Environmental dusts, Tracheobronchial epithelium.

During the past decade the ubiquitous presence of asbestos in the environment has become a matter of increasing public health concern. Airborne exposure to asbestos dusts is associated epidemiologically with pulmonary fibrosis (22, 23, 31), bronchogenic carcinoma (10, 17), and mesotheliomas of the pleural and peritoneal cavities (26, 38).

After inhalation, insoluble foreign matter is phagocytosed by alveolar macrophages and eliminated by the mucociliary escalator mechanism of the airways (15, 30). Although the deposition of environmental dusts within the lung parenchyma has been the subject of many studies (12, 13, 20), the interaction of particulates with cells of the differentiated tracheobronchial epithelium has not been examined. Since asbestos appears to act as a cocarcinogen in bronchogenic neoplasms of man (32), study of its interaction with the differentiated mucociliary epithelium is relevant to an understanding of carcinogenesis in the bronchial tree. The experimental *in vitro* system described in this report allowed us to evaluate the effects of crocidolite on the tracheal epithelium and its uptake by cells of the respiratory mucosa.

MATERIALS AND METHODS

Explants of tracheobronchial mucosa were prepared from 6- to 8-week-old female hamsters (87.20 TELACO strain, Bar Harbor, Maine) by methods described previously (24). The intact trachea was removed from the animal, opened along the anatomical defect in the cartilagenous rings, and sectioned using a sharp scalpel into 1- by 2-mm. hemisections.

International Union Against Cancer (U. I. C. C.) reference samples of crocidolite were suspended in Eagle's minimal essential medium at 1.0, 4.0, 8.0, and 40.0 mg. per ml. After grouping of explants in 35-mm. plastic Petri dishes, the suspensions were added to the cultures so that the tracheal epithelium was submerged for 1 hour. The dust-containing medium was then removed, and the tissues were transferred to dishes that had been scored to allow adherence of the nonepithelial surface (24). Scanning electron microscopic (SEM) studies at this juncture showed that the mucus blanket was intact. Asbestos fibers ranging in diameter from 0.125 to 1 μm. and in length from 0.75 to 53 μm. were generally cleared from the mucosal surface by mucociliary action.

Organ cultures were maintained at 35° C. in a humid, 95 per cent air and 5 per cent CO_2 environment in Eagle's minimal essential medium containing 2 per cent fresh chicken serum, 100 μg. per ml. of gentamicin and 25 units per ml. of nystatin. The medium was changed twice weekly using a volume sufficient to moisten the mucosal surface but not immerse the culture.

At predetermined intervals ranging from 1 hour to 4 weeks, representative specimens were fixed in culture dishes using 4 per cent glutaraldehyde in 0.1 M cacodyl-

J&J-0008794

Protected Document--Subject to Protective Order JNJ 000053377

ate buffer. After 18 hours the tissues were postfixed in 1 per cent osmium tetroxide, dehydrated, and embedded in Epon by standard methods. Sections of 1 μm. thickness were prepared with an ultramicrotome and stained with toluidine blue. These preparations were used for routine light microscopic studies and the selection of areas of ultrastructural evaluation.

Ultrathin sections were prepared with diamond knives, stained with uranyl acetate and lead citrate, and examined with a Philips 300 transmission electron microscope (TEM). Explants also were fixed in 2 per cent formalin and 1 per cent glutaraldehyde in a 200 mOsM phosphate buffer and incubated with 0.05 M Na-β-glycerophosphate for 1 hour. Acid phosphatase was demonstrated ultrastructurally using the technique of Trump *et al.* (37).

After fixation in glutaraldehyde, selected specimens were dehydrated in ethyl alcohol and in Freon prior to critical-point drying in a Bomar apparatus. The tissues were coated with gold-palladium in a vacuum evaporator and viewed with a JEOL JSM-35 scanning electron microscope. Sections that showed intracellular deposits of asbestos by TEM were examined by energy-dispersive x-ray spectrometry (Kevex Corporation, Burlingame, California) to determine the elemental composition of the fibers.

At 1 week, a 5-hour pulse of tritiated thymidine (1 μCi. per ml. of medium) was added to cultures before fixation. Alternate 1-μm. sections were stained with toluidine blue or prepared on gelatin slides for autoradiography using the emulsion dipping technique (3). Autoradiograms were developed after 1 week of exposure in light-tight boxes at 4° C. and stained with equal volumes of 1 per cent azure blue and 1 per cent methylene blue.

RESULTS

Crocidolite sedimented on the epithelial surfaces of the tracheal explants within 1 hour after its addition to cultures. As observed with a dissecting microscope (×5), much of the asbestos was cleared by mucociliary action. However, SEM studies at 3 hours showed that relatively short fibers (<10 μm.) often were lodged on the surfaces of nonciliated and mucin-secreting cells (Fig. 1) whereas longer fibers (≥10 μm.) occasionally remained suspended in, or on, the ciliary network of the epithelium (Fig. 2).

Cytologic alterations in superficial epithelial cells were observed by TEM in tracheal cultures exposed to asbestos for 1 hour. These changes became prominent during the 1st week after exposure. Their extent and severity appeared to relate directly to the relative amounts of crocidolite precipitated on the epithelial surface (Table 1).

Mucin-secreting and ciliated cells initially developed apical "blebs" and vesiculations of the cytoplasm. Often these cells exhibited more striking cytotoxic alterations and sloughed from the mucosa. Asbestos fibers were found in the cytoplasm of many of the epithelial cells by SEM and occasionally fibers appeared to protrude through the plasma membrane (Fig. 3).



FIG. 1. Surface of a tracheal explant 3 hours after precipitation of asbestos (1 mg. per ml. of medium). Small fibers (*arrow*) often are observed between groups of ciliated cells and in intimate contact with mucin-secreting cells. ×2,500.

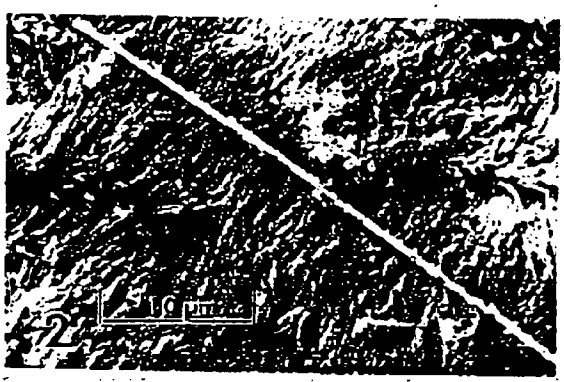

FIG. 2. SEM of densely ciliated mucosa 24 hours after precipitation of asbestos (4 mg. per ml. of medium). Large fibers of crocidolite are usually cleared by ciliary action, but occasionally remain suspended on the cilia. ×2,500.

Cytopathic changes also were present in the mucosa of cultures exposed to relatively low concentrations of crocidolite. Whereas mucin-secreting cells were contracted, the ciliated elements appeared distended (Fig. 4). These latter cells stained lightly, presumably due to the accumulation of intracellular fluid and a dispersion of cytoplasmic organelles. Asbestos was found infrequently in cultures demonstrating these changes.

Evidence of basal cell hyperplasia was noted as early as 24 hours (Fig. 4); it was prominent after 1 week (Fig. 5). At this juncture, autoradiography showed a marked increase in the numbers of cells labeled with tritiated thymidine. Ultrastructurally, the proliferating cells contained prominent accumulations of mitochondria. Complex interdigitations and desmosomes were found between them (Fig. 6). With the passage of time, superficial elements in focal areas of the mucosa acquired features of differentiated squamous cells.

Phagocytosis of crocidolite by cells of the hyperplastic basal layer was observed after the superficial necrotic epithelium had sloughed. Individual particles of relatively small size (<2 μm.) were encompassed by cyto-

Protected Document--Subject to Protective Order JNJ 000053378

TABLE 1. PERCENTAGE OF CULTURES WITH EPITHELIAL CHANGES AT INTERVALS AFTER EXPOSURE TO CROCIDOLITE ASBESTOS

	Crocidolite (mg./ml.)															
	0				4				9				40			
Time (hrs)	1	3	24–48	≥72	1	3	24–48	≥72	1	3	24–48	≥72	1	3	24–48	≥72
No. examined[a]	20	29	28	69	9	24	25	41	20	18	31	93	17	17	25	126
Cytoplasmic vesiculation[b]	0	3	7	25	11	4	24	10	5	17	42	43	24	35	52	39
Desquamation of superficial cells[c] (50% of epithelial surface)	0	3	0	0	22	38	8	2[d]	10	5	19	10	12	18	24	6
Focal basal cell hyperplasia[e]	0	0	0	6	0	0	36	41	0	6	3	48	0	0	16	53

[a] Epon-embedded 1-μm. tissue sections were examined for the indicated cytologic alterations. Technical imperfections in histologic sections precluded evaluation of equal numbers of specimens at each time interval. Observations of tissues maintained for 72 hours to 1 week were combined.

[b] Vesiculation of the cytoplasm in control cultures differed qualitatively from changes observed in cultures exposed to crocidolite.

[c] Slides were considered to exhibit desquamation if exfoliation of differentiated surface epithelial cells was observed over 50 per cent of the epithelial surface.

[d] Regeneration of the epithelium was prominent after 1 week. Accordingly, critical evaluation of desquamation was difficult or not possible by 72 hours.

[e] Focal hyperplastic lesions consisted of an accumulation of 10 or more proliferating basal cells adjacent to deposits of crocidolite.



FIG. 3. SEM of a sloughing cell 48 hours after precipitation of asbestos (4 mg. per ml. of medium). Several fibers protrude from the cytoplasm. The *arrow* indicates an intracellular fiber. ×8,000.



FIG. 4. Montage of an organ culture 24 hours after precipitation of asbestos (4 mg. per ml. of medium). Lightly staining edematous cells are observed in the epithelium. Although an occasional distended cell was seen in control cultures, the characteristic "ballooning" of many of these cells, as observed ultrastructurally, was never noted in cultures which were not exposed to asbestos. ×2,550.

plasmic extensions and entered the cells in membrane-bound vesicles (Fig. 7). Subsequently, asbestos-containing vesicles were found in a perinuclear location where fusion of phagosomes with primary lysosomes occurred (Fig. 8). X-ray energy-dispersive spectrometry showed that the particulates within lysosomes had the iron and silicon content characteristic of crocidolite asbestos.

Fibers of asbestos also were surrounded by newly proliferating cells (Fig. 9). As early as 1 week after exposure, these fibers were noted in, or between, basal cells adjacent to the basal lamina (Fig. 10*a* and *b*). At intervals thereafter, asbestos was found in the connec-

J&J-0008796

Protected Document--Subject to Protective Order JNJ 000053379



FIG. 5. Tracheal explant 2 weeks after exposure to crocidolite (40 mg. per ml. of medium). Basal cells are enlarged and increased in number. Superficial cells, some of which contain asbestos, are sloughed. ×2,000.

tive tissue of the submucosa and in the cytoplasmic vesicles of phagocytic mesenchymal cells (Fig. 11).

DISCUSSION

A complex sequence of events is observed in the tracheal mucosa after exposure to crocidolite asbestos. Initially, cytotoxic changes appear in the differentiated superficial epithelium. Necrosis and sloughing of these cells is accompanied by the proliferation of a subjacent layer of new basal elements. The latter cells phagocytose some fibers and proliferate around others. Subsequently, focal areas of squamous metaplasia appear adjacent to deposits of asbestos. With the passage of time, crocidolite is transported by intra- and extracellular routes to the submucosa where it is phagocytosed by mesenchymal cells.

The cytotoxic changes in the superficial epithelial elements occurred with the concomitant release of lysosomal enzymes from the cells. In preliminary experiments, we monitored acid phosphatase in the medium of



FIG. 6. TEM of hyperplastic basal cells 2 weeks after exposure to crocidolite (40 mg. per ml. of medium). Cells are interconnected by desmosomes (*arrows*) and entwining cytoplasmic projections. Note the prominent accumulations of mitochondria along the basal lamina (*arrowheads*). ×9,800.

Protected Document--Subject to Protective Order JNJ 000053380

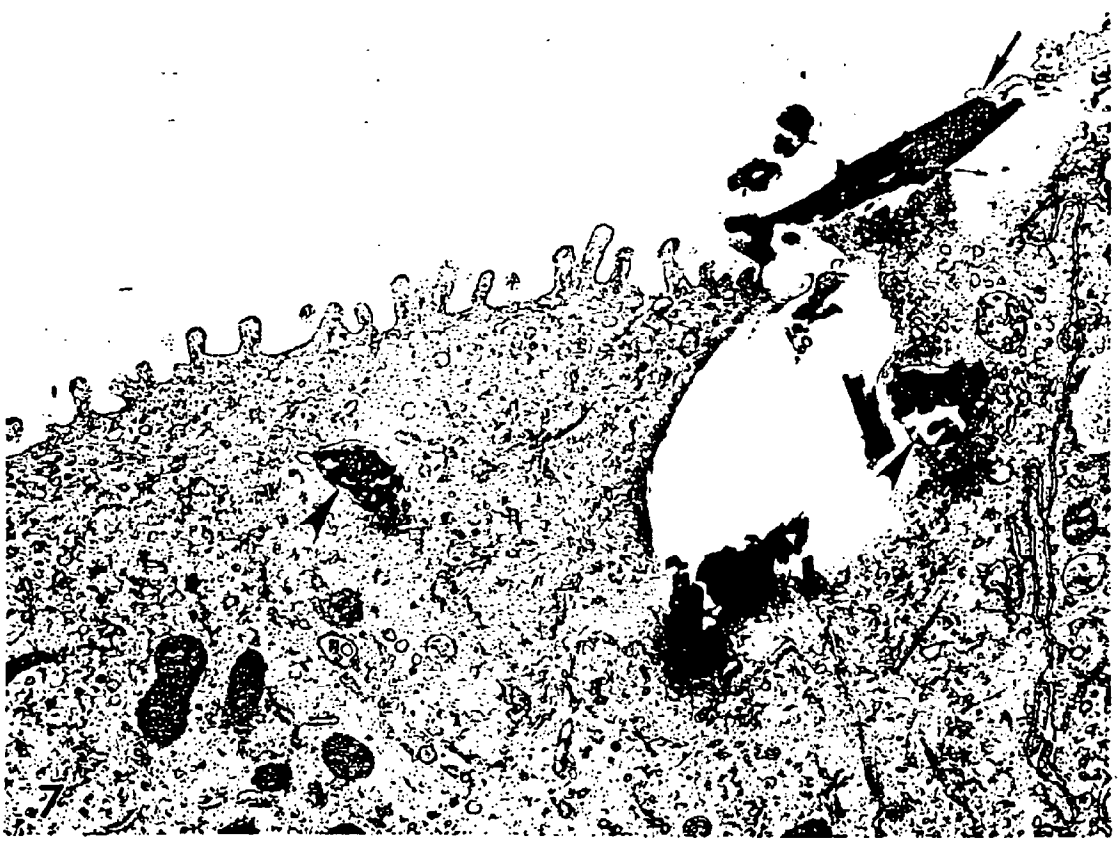

FIG. 7. TEM of an epithelial cell phagocytosing asbestos. Note the cytoplasmic projection encompassing the fiber (*arrow*). Small fibers are contained within membrane-bound vesicles (*arrowheads*). ×21,300.

tracheal cultures at intervals after exposure to crocidolite. Enzyme activity was increased 2- to 4-fold during the initial 72-hour period when obvious cytologic effects were observed. These increases were related in a dose-dependent fashion to the concentrations of dust in the medium added to the cultures. Although they are consistent with the findings of others in studies using cultured alveolar macrophages (1, 2, 8, 27), they fail to define the basic mechanism of cell injury.

Davies and colleagues (8) showed that cultured macrophages release lysosomal acid hydrolases into the medium promptly after exposure to chrysotile asbestos. Since the cytosol enzyme lactate dehydrogenase was not lost by the cells, cytotoxicity was thought to result from a selective damage to lysosomal membranes. This latter observation is not consistent with the studies of Parazzi *et al.* (27) and Klosterkotter and Robock (16). They suggest that cell damage is due to a nonspecific physical effect or mechanical irritation of cells by asbestos fibers (16).

Allison (1, 2) proposes that the magnesium ions of chrysotile ($3MgO$, $2SiO_2$, $2H_2O$) interact with the sialoglycoproteins of cell membranes, altering their integrity. Studies by Klosterkotter and Robock (16) indicate that magnesium ions leach from the fibers of this species of asbestos causing a shift in pH and a concomitant toxic effect. Although phagocytosis of silica (SiO_2) by alveolar macrophages results in death of the cells (2), it is unclear whether or not the other intrinsic elemental constituents of crocidolite (Na_2O, Fe_2O_3, $3FeO$, $8SiO_2$, H_2O) are cytotoxic. In addition, U. I. C. C. crocidolite is contaminated with trace amounts of heavy metals (*i.e.*, Co, Ni, Mn, Cr) and mineral oils of which polycyclic hydrocarbons are a minor constituent (14, 29, 35). Dixon *et al.* (9) and Harington and Roe (11) believe that these adsorbed materials could account for the carcinogenic or cocarcinogenic properties of asbestos *in vivo*. They might also be responsible for the cellular changes observed in our study.

For reasons that remain unclear, the cytopathic effects of asbestos in our studies were confined to superficial cells of the respiratory mucosa and were not apparent in the basilar elements. It is of interest that cytolysis and desquamation of the epithelium and luminal accumulations of cell debris are also noted in the tracheobronchial tree of guinea pigs exposed to aerosols of

Protected Document--Subject to Protective Order JNJ 000053381



FIG. 8. TEM of crocidolite asbestos within an epithelial cell at 2 weeks *in vitro*. The cytoplasm is replete with mitochondria and phagolysosomes (*arrows*). The *inset* demonstrates acid phosphatase histochemical staining of a secondary lysosome containing crocidolite. ×38,500; *inset*, ×42,000.

Protected Document--Subject to Protective Order JNJ 000053382

crocidolite (5). Proliferation of basal cells was prominent in the respiratory mucosa of organ cultures shortly after exposure. A similar change is noted in rodents after inhalation of crocidolite dust (7). Thus, our morphologic observations are consistent with findings in animal models.

Mechanical or chemical insults to epithelia of the respiratory tract have been shown to stimulate a response similar to that observed with crocidolite. Basal cells of the tracheobronchial mucosa exhibit a peak of mitotic activity as early as 24 hours after mechanical injury (18) and exposure to sulfur dioxide (39). One is obliged to conclude from these observations that hyperplasia is a fundamental response of the respiratory epithelium to a variety of nonspecific insults.

In our studies, newly proliferated basal cells were replete with mitochondria, presumably a morphologic indication of increased metabolic activity. Richards and colleagues (28) noted a similar prominence of mitochondria in lung fibroblasts exposed to chrysotile asbestos. Whereas Szmczykrewicz and Wozniak (34) showed that the bronchial epithelium increases oxygen consumption in the presence of asbestos and silica, Klosterkotter and



FIG. 9. TEM of an explant 2 weeks after exposure to crocidolite (40 mg. per ml. of medium). The necrotic superficial cells contain appreciable quantities of asbestos (*arrowheads*). A small fiber is observed between the subjacent proliferating cells (*arrow*). ×7,600.

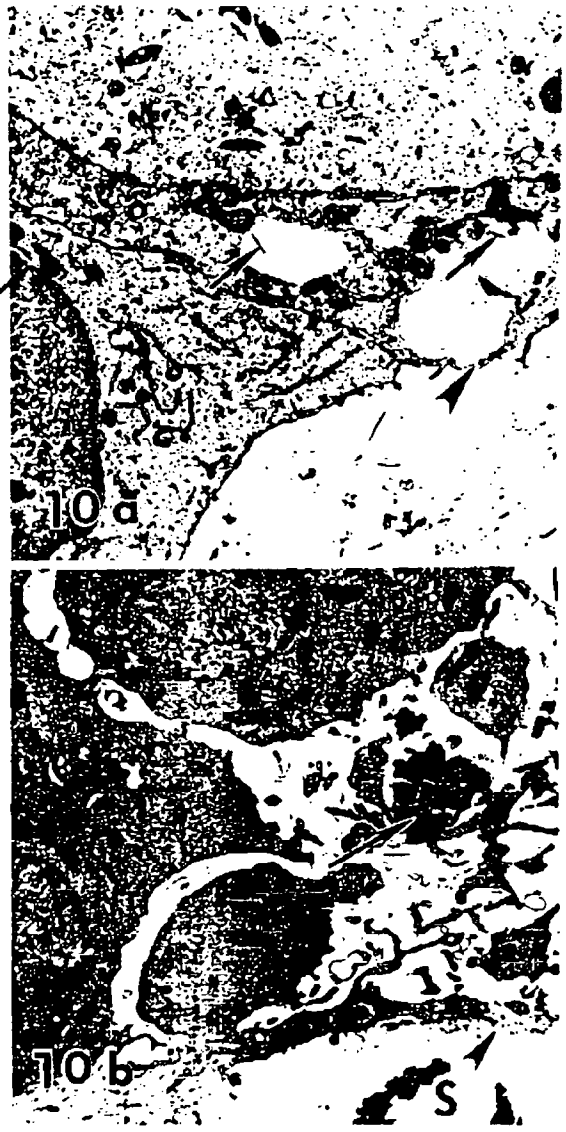

FIG. 10. TEM illustrating possible alternative routes of crocidolite transport to the submucosa. *a*, Intracellular asbestos (*arrows*) in a basal cell. Note the attenuated basal lamina (*arrowhead*) in close proximity to the fiber. *b*, Accumulation of asbestos (*arrow*) between widened intercellular spaces. The basal lamina is discontinuous (*arrowhead*). Asbestos is also present in the submucosa (S). Figure 10*a*, ×7,200; *b*, ×12,000.

Robock (16) observed a reduction in oxygen utilization by cultured macrophages exposed to asbestos.

Using organ cultures it was possible to demonstrate stages in the apparent movement of crocidolite fibers from the mucosa into the submucosa. Particles appeared to be transported to the basement membrane both within and between cells. This process, which occurred promptly after the introduction of asbestos into the

Protected Document--Subject to Protective Order JNJ 000053383



FIG. 11. TEM of a submucosal cell containing asbestos fibers (*arrows*). The fiber in *inset* is encompassed by the cytoplasm. ×4,600; *inset*, ×11,000.

cultures, may be a mechanism for transport of inhaled foreign particulates from the respiratory epithelium into the submucosa under natural circumstances. This conclusion is supported by experiments in which animals are exposed to aerosols of dust. Studies by Botham and Holt showed that fibers of a submicrometer diameter were deposited initially in the bronchioles of rodents 24 hours after inhalation of anthophyllite asbestos (6) or fiberglass (4). During the 1st week after exposure, the particulates were found in submucosal macrophages and in the muscular coat of the cartilaginous, terminal and respiratory bronchioles. We believe that this is evidence, although inconclusive, suggesting transport of fibers across the respiratory epithelium.

Uptake of dusts by alveolar epithelial cells (33) and Clara cells (19) has been noted in experimental animals. To our knowledge, phagocytosis of foreign particulates by cells of the tracheal epithelium has not been documented. It has been suggested that the carcinogenicity of asbestos is a function of the physical rather than the chemical structure of the fiber (21, 25, 36). Clearly, particles of small size selectively interact with basal cells, presumably the progenitors of neoplasia in the bronchial tree.

Acknowledgments: Dr. Arnold R. Brody provided valuable assistance with the scanning electron microscopy and x-ray energy-dispersive spectrometry.

Date of acceptance: October 6, 1976.

This study was supported by Contract PHS No. 1 CP 33360 from the National Cancer Institute.

Address reprint requests to: Brooke T. Mossman, Research Associate, Department of Pathology, A-151 Medical Alumni Building, University of Vermont College of Medicine, Burlington, Vermont 05401.

REFERENCES

1. Allison AC: Effects of silica and asbestos on cells in culture. Inhaled Part Vap 3:437, 1970
2. Allison AC: Lysosomes and the toxicity of particulate pollutants. Arch Intern Med 128:131, 1971
3. Baserga R: Autoradiographic techniques. In Methods in Cancer Research, edited by Busch H, Vol I, p 45. New York, Academic Press, 1967
4. Botham SK, Holt PF: The development of glass-fibre bodies in the lungs of guinea-pigs. J Pathol 103:149, 1971
5. Botham SK, Holt PF: Development of asbestos bodies on amosite, chrysotile and crocidolite fibers in guinea-pig lungs. J Pathol 105:159, 1971
6. Botham SK, Holt PF: Asbestos-body formation in the lungs of rats and guinea-pigs after inhalation of anthophyllite. J Pathol 107:245, 1972
7. Botham SK, Holt PF: The effects of inhaled crocidolites from Transvaal and North-west cape mines on the lungs of rats and guinea-pigs. Br J Exp Pathol 53:612, 1972
8. Davies P, Allison AC, Ackerman J, Butterfield A, Williams S: Asbestos induces selective release of lysosomal enzymes from mononuclear phagocytes. Nature 251:423, 1974
9. Dixon JR, Lowe DB, Richards DE, Cralley LJ, Stockinger HE: The role of trace metals in chemical carcinogenesis: asbestos cancers. Cancer Res 30:1068, 1970
10. Doll R: Mortality from lung cancer in asbestos workers. Br J Ind Med 12:81, 1955
11. Harington JS, Roe FJC: Studies of carcinogenesis of asbestos fibers and their natural oils. Ann NY Acad Sci 132:439, 1965
12. Hatch TF, Gross P: Pulmonary Deposition and Retention of Inhaled Aerosols. New York, Academic Press, 1964
13. Henry MC, Kaufman DG: Clearance of benzo(a)pyrene from hamster lungs after administration on coated particles. J Natl Cancer Inst 51:1961, 1973
14. Hillborn J, Thomas RS, Lao RC: The organic content of international reference samples of asbestos. Sci Total Environ 3:129, 1974
15. Kilburn KH: Cilia and mucus transport as determinants of the response of the lung to air pollutants. Arch Environ Health 14:77, 1967
16. Klosterkotter W, Robock K: New aspects on dusts and pneumoconiosis research. Am Ind Hyg Assoc J 36:659, 1975
17. Knox JF, Holmes S, Doll R, Hill ID: Mortality from lung cancer and other causes among workers in an asbestos textile factory. Br J Ind Med 25:293, 1968
18. Lane BP, Gordon R: Regeneration of rat tracheal epithelium after mechanical injury. I. The relationship between mitotic activity and cellular differentiation. Proc Soc Exp Biol Med 145:1139, 1974
19. Lauweryns JM, Baert JH: The role of the pulmonary lymphatics in the defenses of the distal lung: morphological and experimental studies of the transport mechanisms of intratracheally instilled particles. Ann NY Acad Sci 221:244, 1974
20. Leadbetter MR, Corn M: Particle size distribution of rat lung residues after exposure to fiberglass dust clouds. Am Ind Hyg Assoc J 33:511, 1972
21. McCullagh SF: The biological effects of asbestos. Med J Aust 2:45, 1974
22. McDonald JC, Becklake MR, Fournier-Massey G, Rossites CE: Respiratory symptoms in chrysotile asbestos mine and mill workers of Quebec. Arch Environ Health 24:358, 1972
23. Merewether ERA: A memorandum on asbestos: Tubercle 15:69, 109, 152, 1933-1934
24. Mossman BT, Craighead JE: Long-term maintenance of differentiated respiratory epithelium in organ culture. I. Medium composition. Proc Soc Exp Biol Med 149:227, 1975
25. Natusch DFS, Wallace JR: Urban aerosol toxicity: the influence of particle size. Science 186:695, 1974
26. Newhouse ML, Thompson H: Mesothelioma of pleura and peritoneum following exposure to asbestos in the London area. Br J Ind Med 22:261, 1965
27. Parazzi E, Pernis B, Secchi GC, Vigliani EC: Studies on *in vitro* cytotoxicity of asbestos dust. Med Lav 59:561, 1968
28. Richards RJ, Hext PM, Blundell G, Henderson WJ, Volcani BE: Ultrastructural changes in lung fibroblast cultures exposed to chrysotile asbestos. Br J Exp Pathol 55:275, 1974
29. Roy-Chowdhury AK, Mooney TF, Reeves AL: Trace metals in asbestos carcinogenesis. Arch Environ Health 26:253, 1973
30. Rylander R: Pulmonary defense mechanisms to airborn bacteria. Acta Physiol Scand[Suppl]306:1, 1968

J&J-0008801

Protected Document--Subject to Protective Order JNJ 000053384

31. Selikoff IJ, Churg J, Hammond EC: The occurrence of asbestosis among insulation workers in the United States. Ann NY Acad Sci 132:139, 1965
32. Selikoff IJ, Hammond EC, Churg J: Asbestos exposure, smoking and neoplasia. JAMA 204:104, 1968
33. Sorokin SP, Brain JD: Pathways of clearance in mouse lungs exposed to iron oxide aerosols. Anat Rec 181:581, 1975
34. Szmczykrewicz K, Wozniak H: Effect of certain industrial dusts on the oxygen uptake capacity of the pulmonary tissues of white mice. Med Pracy 17:185, 1966
35. Timbrell V: Progress in physics and chemistry. In Biological Effects of Asbestos, p 13. IARC Scientific Publication, No. 8, 1973
36. Timbrell V, Griffiths DM, Pooley FD: Possible biological importance of fibre diameters of South African amphiboles. Nature 232:55, 1971
37. Trump BF, McDowell EM, Barret LA, Frank AL, Harris CC: Studies of ultrastructure, cytochemistry, and organ culture of human bronchial epithelium. In Experimental Lung Cancer. Carcinogenesis and Bioassays, edited by Karbe E, Park JF, p 548. Berlin, Springer-Verlag, 1974
38. Wagner JC, Sleggs CA, Marchand P: Diffuse pleural mesothelioma and asbestos exposure in the North Western Cape Province. Br J Ind Med 17:260, 1960
39. Wells AB, Lamerton LF: Regenerative response of the rat tracheal epithelium after acute exposure to tobacco smoke: a quantitative study. J Natl Cancer Inst 55:887, 1975

J&J-0008802

Protected Document--Subject to Protective Order JNJ 000053385