TOXICOLOGY AND APPLIED PHARMACOLOGY 17, 656–668 (1970)

Comparative Toxicologic Study with Polychlorinated Biphenyls in Chickens with Special Reference to Porphyria, Edema Formation, Liver Necrosis, and Tissue Residues

J. G. Vos AND J. H. Koeman

Institute of Veterinary Pathology and the Institute of Veterinary Pharmacology and Toxicology, University of Utrecht, Utrecht, The Netherlands

Received November 3, 1969

Comparative Toxicologic Study with Polychlorinated Biphenyls in Chickens with Special Reference to Porphyria, Edema Formation, Liver Necrosis, and Tissue Residues. Vos, J. G. and Koeman, J. H. (1970). *Toxicol. Appl. Pharmacol.* 17, 656–668. In a comparative 60-day oral toxicity test (400 ppm) in chickens, three 60%-chlorinated commercial polychlorinated biphenyl (PCB) preparations were used: compound I (Phenoclor DP6), compound II (Clophen A60), and compound III (Aroclor 1260). Using mortality, mean survival time, mean weight, and pathological observations (hydropericardium, abdominal, and subcutaneous edema and centrolobular liver necrosis) as parameters, a significant difference in toxicity was found between the compounds: compounds I and II showed the highest, compound III the lowest, toxicity. Microscopically centrolobular liver necrosis was found in chicks fed compounds I and II. Atrophy of the spleen was found in all test groups. Chemical porphyria was found as a general PCB effect: increased fecal excretion of coproporphyrin and protoporphyrin and fluorescence of tissues occurred in all test groups. Additional experiments with compound I (2000 ppm) in Japanese quail and rats confirmed the porphyrogenic action. Gas chromatographic analyses of liver and brain of dead chicks gave PCB levels that varied between 120 and 2900 ppm. The relationship of hydropericardium (chick edema) and liver necrosis to the differences in toxicity observed between the technical PCB mixtures is discussed.

In recent years the presence of polychlorinated biphenyls (PCB) has been exhibited in fish and wildlife in many countries, including the United States, Great Britain, Sweden, and The Netherlands (Jensen, 1966; Holmes *et al.*, 1967; Holden and Marsden, 1967; Koeman *et al.*, 1967; Risebrough *et al.*, 1968; Koeman *et al.*, 1969).

Commercial PCB preparations are oily fluids consisting of a mixture of different chlorinated biphenyls. These chemicals are extremely stable with very low aqueous solubility. They are used as lubricants, as fluids for heat transfer and dielectric media, in protective coatings for wood, metal, and concrete, and for many other applications. Which of these applications has contributed to the present widespread environmental contamination has not been elucidated. The occupational hazards in the use of PCB have been known for years; normal handling of these compounds has not given rise to great difficulties (Irish, 1963).

Animal experiments with rats and guinea pigs have shown that the ingestion of PCB

MONS 206365

may give rise to liver injury (Miller, 1944). Hydropericardium and abdominal edema were found in chicks (McCune *et al.*, 1962; Flick *et al.*, 1965) and Japanese quail (Koeman *et al.*, 1969) after PCB ingestion. Risebrough *et al.* (1968) found that the rate of estradiol metabolism is markedly increased after PCB treatment in pigeons. This may indicate that these derivatives may induce hepatic hydroxylases. The data presently available do not permit a proper toxicologic evaluation of the amounts detected in wildlife specimens. Koeman *et al.* (1969) found a remarkable resemblance between the gas chromatograms and mass spectrometer analyses of purified extracts from eider duck tissues and the commercial PCB preparation Phenoclor DP 6. Similar gas chromatograms and identical mass numbers were obtained from other commercial preparations, Clophen A60 and Aroclor 1260. These 3 preparations, which contain on the average 6 chlorine atoms per molecule, were used in the present comparative toxicologic study, chicks, quail, and rats being used as the experimental animals.

METHODS

The PCB preparations were obtained from Prodelec in France (compound I, Phenoclor DP 6), Bayer in Germany (compound II, Clophen A60 Lot No. 912434), and Monsanto in the United States (compound III, Aroclor 1260 Lot No. AK-3). One-day-old cockerels (Hubbart laying breed) were used in these studies. The chicks were kept under a continuously operating heating lamp throughout the experiment. On the second day they were weighed, individually wing-banded, and distributed randomly into 4 groups. The birds received diets containing PCB as follows: group I, 400 ppm compound I; group II, 400 ppm compound II; group III, 400 ppm compound III; group IV served as control.

They were fed and watered ad libitum and were weighed twice weekly. The feed consisted of a common type of starter ration. The PCB was dissolved in acetone and mixed carefully into a premix. After this the acetone was evaporated and the premix was mixed into the ration. The chicks were kept on these rations for 60 days and killed. These birds and the animals that died during the experiment were necropsied. Two chicks from group II died during the first 3 days. At necropsy it appeared that they were not killed by the PCB treatment (no liver necrosis, no edema, no tissue fluorescence). They were discarded and not included in the calculations.

At necropsy hydropericardium volume was determined by inserting a blunt-tipped needle on a 2-ml syringe into a small slit in the pericardium. All the pericardial fluid was removed from the anterior part of the heart sac by intermittent aspiration. The volume of the fluid removed was measured to the nearest 0.05 ml. The incidence of abdominal and subcutaneous edema and the weights of the liver and spleen were recorded. The liver, spleen, and kidneys were fixed in 10% buffered formalin and processed in a conventional manner for histologic examination. Sections (7 μ) were stained with hematoxylin-eosin and Perls's iron stain. Moreover, selected sections were stained for amyloid with methyl violet according to Lillie (1965), with Congo red, with PAS, with PAS–Alcian blue, and with Fettrot for lipids. Prompted by experience obtained in parallel studies with hexachlorobenzene, observations were made in ultraviolet light using red fluorescence as an indicator for the presence of excess quantities of porphyrins. Fluorescence of liver, bile (after opening of the gall bladder), small intestine, and bone was

MONS 206366

recorded. Fecal coproporphyrin and protoporphyrin were determined by the method described by Rimington (1961), using a Beckman spectrophotometer.

PCB levels in livers and brains of selected birds were determined by gas chromatography. The tissues were extracted with petroleum ether in a Soxhlet extraction apparatus after drying with anhydrous sodium sulfate. Cleanup of the samples was carried out by liquid–liquid partition with dimethyl formamide and column chromatography using activated Florisil. The PCB preparations in the final extract were measured by gas–liquid chromatography (204-1B Varian Aerograph with electron capture detection). The Pyrex glass column (5 feet × ¼ inch), filled with 10% DC 200 on Gaschrom Q (80–100 mesh), was operated at 200°C with nitrogen as the carrier gas (about 50 ml/min).

Only an approximate quantitative determination of the residue from the chromatogram of the tissue extracts could be made, since the composition of the residue was not necessarily identical with the PCB compound used in the treatment. For quantification, 1 peak, considered to be representative, was selected. This was the peak with $rx = 1.45$ relative to dieldrin. The approximate amount of total PCB-residue was calculated from the height of this peak with compound I as the standard.

In a number of tissue extracts the amounts of PCB were measured also by a Dohrmann C 250 A microcoulometric detection system (with a T-300-S-halogen cell), coupled to a Microtek MT-220 gas chromatograph. The chromatograph was equipped with a Pyrex column (6 feet × ¼ inch) filled with a mixed-liquid column packing (QF 1 plus DC 200) described by Burke and Holswade (1966). With this system 0.6 μg of Phenoclor DP6 gave about a half-scale response on a 1-mV recorder (microcoulometer range: 200 ohms). By this method the content of chlorine in the extract is determined by addition of the chlorine contents of the different PCB peaks. Since the average chlorine content of our compounds was 60%, the total residue could be calculated. Here again, the result is an approximation since the residue may have a different chlorine content.

Additional experiments with special reference to porphyrin biosynthesis were made with compound I in 5 adult female Japanese quail weighing 112–130 g and 8 adult female Wistar rats weighing 173–212 g at a dose level of 2000 ppm in the dry food. Mortality of the animals in both tests was scored, and at necropsy, observations were made under ultraviolet light; occasionally cryostat sections of liver and kidneys were examined in a fluorescence microscope (Zeiss, exciting filters BG 38/2.5 and BG 12/4, barrier filters 53 and 33, Osram super pressure lamp HBO 200 W).

Statistical analyses, on a one-tail significance level, were done according the Wilcoxon test for 2 unrelated samples (van der Waerden, 1957).

RESULTS

Experiments with Chickens

All chicks from groups I and II died during the experiment, while the mortality in group III birds was only 15% (Table I). Death was accompanied by ruffled feathers and ataxia as the main signs; loss of feathers was often seen.

Hydropericardium (Flick *et al.*, 1965) with clear and straw-colored pericardial fluid, was a common finding in groups I and II and was rare (not statistically significant) in group III compared with the control group. Abdominal and subcutaneous edema was observed in groups I and II only, with the highest incidence in group II (Table I).

MONS 206367

TABLE 1

MORTALITY, MEAN SURVIVAL TIME AND PATHOLOGIC OBSERVATIONS OF CHICKS FED 400 ppm PCB FOR 60 DAYS AND OF CONTROL BIRDS

Groups	N	Number of deaths	Mean survival[a] time (days)	Number of birds with edema			Number of birds with liver necrosis
				Hydropericardium[b]	Abdominal	Subcutaneous	
I (Phenoclor)	24	24	24.3 (12–58)	18	8	5	9
II (Clophen)	22	22	20.5 (13–29)	20	9	7	9
III (Aroclor)	20	3	—	3	0	0	0
IV (Control)	20	0	—	0	0	0	0

[a] The range of values is shown in parentheses.
[b] Positive hydropericardium response was considered to be over 0.2 ml pericardial fluid in chicks 20 days of age and 0.4 ml in chicks 60 days of age, with interpolation for intermediate ages.

MONS 206368

Macroscopic red fluorescence, under ultraviolet light indicating porphyrins, was detected in all birds of the 3 test groups; fluorescence of liver, bile, small intestine, and bone were used as parameters. There was a remarkable difference in the location of the porphyrins. The chicks that died during the experiment (chiefly groups I and II) showed the highest incidence of fluorescence in the bile and small intestine followed by the liver and bone (Fig. 1). Only bone fluorescence was pronounced in the killed birds from group III (Fig. 1). This finding is in agreement with the excretion of coproporphyrin and protoporphyrin in the feces (Table 2). The excretion in group III reached a maximum at about 4 weeks followed by a gradual decrease to the level of the control birds. In the meantime, large amounts of porphyrin had been deposited in the bones.

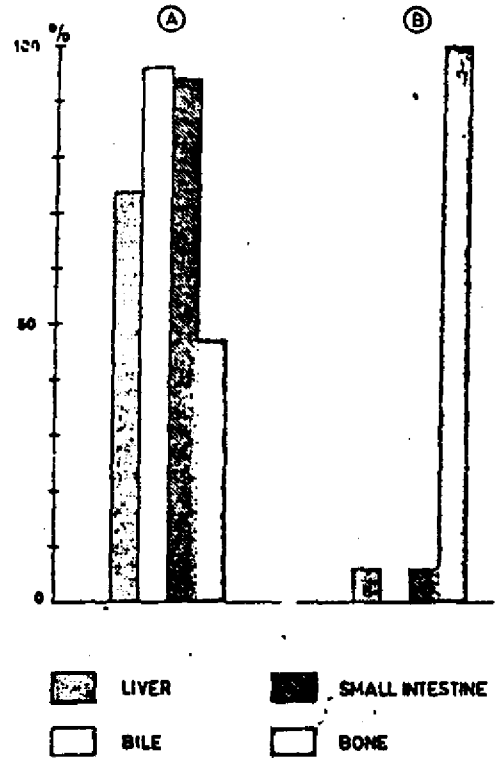

FIG. 1. Percentage of chicks showing fluorescence under ultraviolet light in liver, bile, small intestine, and bone. A: Chicks that died during the experiment; B: chicks killed at the end of the experiment.

Mean liver weight and relative liver weight of the killed birds from group III was significantly increased compared with group IV, mean body weight and mean spleen weight of chicks from group III were significantly reduced (Table 3).

Liver necrosis was observed in 9 birds from groups I and II (Table 1). It varied between slight (some lobules) and severe (nearly all lobules). The occurrence of liver necrosis was independent of survival time. The foci of centrolobular necrosis extended in many

MONS 206369

cases from one lobule to another lobule, resulting in a microscopic picture with the portal triad as the center of the viable tissue (Fig. 2). In some of these sections proliferation of mesenchymal cells between the necrotic liver parenchymal cells could be observed. Fatty degeneration could be seen also (positive for Fettrott). Protein droplets of different size were sometimes present in the sinusoids near damaged cells as well as in some central veins. Liver parenchymal cells with pycnotic nuclei could be observed in liver sections from all 3 experimental groups. A small amyloid deposit was seen in liver sections of 1 bird each from groups I and II.

TABLE 2

COPROPORPHYRIN AND PROTOPORPHYRIN CONTENTS (μg/g DRY WEIGHT) OF FECES OF CHICKS FED PCB FOR 60 DAYS AND OF CONTROL BIRDS

Days after start of feeding	Coproporphyrin				Protoporphyrin			
	Groups				Groups			
	I	II	III	IV	I	II	III	IV
7	4.2	4.1	2.7	0.8	8.3	15.2	4.5	2.8
11	3.2	3.7	2.2	0.8	19.4	20.0	8.9	4.5
14	7.1	6.0	—	—	13.2	11.5	—	—
19	9.4	9.8	4.4	0.6	25.0	16.1	25.2	2.3
26	12.6	36.7[a]	13.6	—	9.7	11.5[a]	14.2	—
36	13.4[b]	—	10.0	1.4	26.3[b]	—	13.7	6.1
58	—	—	2.5	2.4	—	—	5.8	8.1

[a] One bird still alive at the moment of sampling.
[b] Three birds still alive at the moment of sampling.

The spleens of all birds in the test groups were small, described already by Flick *et al.* (1965), compared with the controls. In general, in the spleens of all chicks of groups I, II, and III which died during the experiment a reduction in the amount of the red pulp, and atrophy of the white pulp and lymphoid foci (Fig. 3), caused by a suppressive or destructive action, could be observed, resulting in a small spleen with a wrinkled capsule.

In 2 birds from group III we found necrosis in the center of a lymphoid focus; in some birds from groups I and II eosinophilic deposits were seen in the center of the white pulp (Fig. 3). These deposits were purple with methyl violet, red with PAS, red purple with PAS–Alcian blue, and light brown with the Congo red stain. With Congo red stain they showed some green birefringence under polarized light, although fluorescence under the UV microscope was yellow instead of pink. These data are strong indications of amyloid.

Tubular dilatation in the kidneys, described already by McCune *et al.* (1962) was also common, usually to a slight degree, in most chicks from groups I and II, but rare in group III. This dilatation was sometimes accompanied by the presence of leukocytes and red blood cells in the lumen of the tubules.

Perls's iron stain gave the following results: the presence of iron in liver Kupffer cells test birds seemed to be about twice as much as that in control birds. In some birds

MONS 206370

TABLE 3

ORGAN WEIGHTS OF KILLED CHICKS FED PCB (COMPOUND III, AROCLOR) FOR 60 DAYS AND OF CONTROL BIRDS[a]

Groups	N	Body (g)	Liver (g)	Liver (g/100 g body weight)	Spleen (g)	Spleen (g/100 g body weight)
III (Aroclor)	17	703 (514–835)[a]	29.7 (22.6–35.9)[b]	4.31 (3.47–5.91)[d]	0.90 (0.40–1.50)[c]	0.136 (0.048–0.288)
IV (Control)	20	921 (820–1010)	24.6 (19.5–28.4)	2.67 (2.17–2.97)	1.35 (0.95–1.82)	0.146 (0.113–0.185)

[a] The range of values is shown in parentheses.
[b] $P < 0.025$.
[c] $P < 0.01$.
[d] $P < 0.005$.

MONS 206371

Fig. 2. [illegible] the portal [illegible] gin of [illegible]

Fig. 3. [illegible] The white [illegible] Hematox[illegible]



FIG. 2. Liver of a group I chick with severe centrolobular necrosis, resulting in a reversed picture with the portal triad becoming the center (arrow). Note the strong eosinophilic parenchymal cells at the margin of necrotic and vital tissue. Hematoxylin and eosin. ×125.

FIG. 3. Spleen of a group I chick with atrophy of a lymphoid focus and atrophy of the white pulp. The white pulp has been replaced by homogeneous eosinophilic material, probably amyloid (arrow). Hematoxylin and eosin. ×500.

MONS 206372

from all test groups we found iron in the cytoplasm of liver parenchymal cells, but this was absent in control livers. In 8, 7, 4, and 0 birds from groups I, II, III, and IV, respectively, iron was demonstrated in macrophages in the spleen and in 7, 2, 2, and 0 birds, respectively, in the cytoplasm of kidney tubular cells.

Approximate liver residues of PCB in 25 selected birds were determined by gas chromatography. This selection included birds which died in the first part of the test, birds which died later and birds with liver necrosis. Brain analyses were made in 12 chicks. In 7 liver extracts the approximate residue was measured by the microcoulometric detection system. The results are given in Table 4.

Experiments with Japanese Quail and White Rats

The feeding of compound I (2000 ppm) in 5 Japanese quail resulted in mortality between 5 and 13 days, associated with the following signs: slight tremor, ataxia, and ruffled feathers. Four quail showed positive fluorescence macroscopically at necropsy. The bird that died last showed a strong fluorescence of liver, kidney, small intestine, and muscles. Cryostat sections examined by fluorescent microscopy revealed an intensely red fluorescence of all liver parenchymal cells. Examination of the kidneys showed a strong fluorescence of tubular cells, especially in the cortex. Hydropericardium was observed in 3 birds. Sections of the enlarged livers showed lysis, pycnosis, and necrosis of liver cells. Proliferation of probably RES cells was a common finding. Perls's iron stain was positive for both Kupffer and parenchymal cells.

The feeding of compound I (2000 ppm) to 8 white rats caused a marked loss of weight as compared with control animals. The rats died between 12 and 56 days after the start of the experiment. At necropsy 4 rats that died within 3 weeks showed no fluorescence under UV light, the 2 rats that died next had fluorescence of the incisors and the small intestine, respectively, while the 2 rats that died last showed fluorescence both of incisors and the small intestine. An important finding was the presence of an enlarged liver, as was also found in Japanese quail fed compound I (2000 ppm), and a small spleen. Sections of the liver revealed a centrolobular degeneration (vacuolated, foamy cells with pycnotic nuclei near the central veins). In some sections focal necrosis could be seen. The disappearance of structure in the white pulp of the spleens, together with a reduction in the red pulp and the presence of green-brown pigment in macrophages was notable; Perls's stain for iron was strongly positive. Therefore siderosis could be diagnosed in the lespen together with its appearance in Kupffer and parenchymal cells of the liver and tubular cells of the kidney.

DISCUSSION

From the results it can be concluded that porphyria is a common finding in animals treated with PCB, so commercial polychlorinated biphenyls extend the already long list of compounds that produce chemical porphyria. Granick (1965, 1966) has presented evidence that the chemical pophyria is the result of the induction of δ-aminolevulinic acid synthetase in liver mitochondria in the case of 3,5-diethoxycarbonyl-1,4-dihydro-2,4,6-trimethylpyridine and allylisopropylacetamide. It is of interest to note that Risebrough *et al.* (1968) have demonstrated that PCB also induces steroid hydroxylases in the liver of birds.

MONS 206373

TABLE 4

CHEMICAL ANALYSES OF LIVER AND BRAIN IN CHICKS FED PCB FOR 60 DAYS[a]

Group I (Phenoclor)			Group II (Clophen)			Group III (Aroclor)		
History	Liver	Brain	History	Liver	Brain	History	Liver	Brain
Died on:			*Died on:*			*Died on:*		
12th day	2200	—	13th day	800	—	16th day	950	420
16th day	1300	490	14th day	1100	—		1100[c]	—
	1900[c]	—	17th day[b]	410	—	17th day	680	—
21st day[b]	120	—	17th day	1600	320	31st day	2400	270
22nd day[b]	210	70	19th day[b]	190	120	*Killed on:*		
	220[c]	—	20th day	610	—	60th day	250	40
22nd day[b]	310	210	22nd day	420	380		340[c]	—
	210[c]	—	22nd day	420	—	60th day	220	—
24th day[b]	180	—	23rd day	860	—	60th day	210	—
	150[c]	—	26th day	390	320			
28th day	1400	—						
	1400[c]	—						
31st day[b]	2100	380						
58th day	2900	700						

[a] The approximate contents are given in parts per million.
[b] Chicks with liver necrosis.
[c] Results obtained by microcoulometric detection; all other figures are results obtained by electron capture detection.

MONS 206374

In our experiments with compound III in the chicks it was noted that the excretion of coproporphyrin and protoporphyrin decreased to nearly normal values after a maximum effect at 26 days of treatment. Whether this is due to an adaptation which enables the animal to eliminate these compounds more efficiently, to an age-dependent change in elimination capacity or susceptibility, is not known. The high incidence of tissue fluorescence in the dead chicks from groups I and II is remarkable. The excretion of coproporphyrin and protoporphyrin is also high at that time. The possibility has to be considered that the presence of large amounts of porphyrins could have a toxic effect in its own, and may have contributed to the death of these birds

The earlier manifestation of porphyria in chicken and quail, compared with the rat, resembles the difference found in hexachlorobenzene-induced porphyria: early manifestation of porphyria in the Japanese quail, late manifestation in the rat (Vos *et al.*, 1968). Flick *et al.* (1965) observed that chicks fed PCB had lower hemoglobin levels than controls. This finding combined with the increased iron-positive staining of macrophages in the spleen, liver, and kidney parenchymal cells of chicks, Japanese quail, and rats found in our experiments are indicative of increased erythrocyte breakdown.

Besides the porphyria induced by the PCB preparations, there is a significant difference in their toxicity, in spite of the resemblance in the gas chromatograms and spectrometric analyses (Koeman *et al.*, 1969). The high incidence of edema and liver necrosis in the Clophen and the Phenoclor group, compared with the Aroclor-fed chicks, is striking.

In the case of our chicks fed Aroclor 1260 we found a lower incidence of edema compared with the chicks of McCune *et al.* (1962) and Flick *et al.* (1965). This could be explained by a difference in the PCB preparation (they used Aroclor 1242, which contains 42% of chlorine) or by differences in diet (Flick *et al.*, 1963) or strain of animals.

The relationship between the toxic nature of PCB and the chick edema factor (Anonymous, 1968) have already been discussed by Flick *et al.* (1965). Gas chromatograms of PCB fractions (Aroclor) obtained by thin-layer chromatography showed peaks with about the same retention times as reference chick edema factor samples (Huang *et al.*, 1967). One of the toxic substances of the chick edema factor has been isolated and characterized (hexachlorodibenzo-*p*-dioxin) by Cantrell *et al.* (Anonymous, 1968). Recently Higginbotham *et al.* (1968) found the presence of hexachlorodibenzo-*p*-dioxin in pyrolyzates of tetrachlorophenol. The related compound tetrachlorodibenzo-*p*-dioxin, which may be found under abnormal conditions in the synthesis of trichlorophenol, is known to cause a very potent "chloracne" and liver necrosis (Bauer *et al.*, 1961; Linn Jones and Krizek, 1962). The edema incidence and liver necrosis found with Clophen and Phenoclor, together with chloracne-like lesions observed in the experiments of von Wedel *et al.* (1943) with dermal application of a technical mixture of PCB and chlorinated naphthalene, suggests the hypothesis that in technical PCB mixtures a hydropericardium, liver necrosis, and "chloracne"-causing factor or factors are present. Also environmental contamination with this possible factor must be considered. Work is in progress to determine the compound(s) responsible for the severe edema formation and liver necrosis.

The residues of PCB in liver and in brain are high. Figures found with the coulometric detection system are in reasonable agreement with figures found with the electron capture system. Chromatograms of both systems are nearly identical. The approximate

MONS 206375

PCB residues in liver do not seem to be correlated with the duration of survival. Liver residues seem to be particularly low in animals which died with liver necrosis. Brain residues are lower than corresponding liver residues. The variation in the residue levels of crude PCB in both liver and brain is high. For the time being this limits the usefulness of these figures for the evaluation of crude PCB residue levels in tissues of wildlife specimen found in the field.

ACKNOWLEDGMENTS

We wish to thank Mr. H. L. van der Maas for his help with the chemistry of the PCB preparations and Mr. R. H. de Vos (Central Institute for Nutrition and Food Research, T.N.O., Zeist) for the microcoulometric analyses of the samples. We acknowledge the contributions of Mr. A. Musch, Mr. E. W. A. Kamperdijk and the technical assistance of Mr. J. H. Pennings.

REFERENCES

ANONYMOUS (1968). The chick edema factor. *Nutr. Rev.* 26, 28–30.

BAUER, H., SCHULZ, K. H., and SPIEGELBERG, U. (1961). Berufliche Vergiftungen bei der Herstellung von Chlorphenol-Verbindungen. *Arch. Gewerbepathol. Gewerbehyg.* 18, 538–555.

BURKE, J. ..., and HOLSWADE, W. (1966). A gas chromatographic column for pesticide residue analysis Retention times and response data. *J. Ass. Offic. Anal. Chem.* 49, 347–385.

FLICK, D. F., DOUGLASS, C. D., and GALLO, L. (1963). Studies of the chick edema disease. 1. Body water distribution and effect of diet. *Poultry Sci.* 42, 855–862.

FLICK, D. F., O'DELL, R. G., and CHILDS, V. A. (1965). Studies of the chick edema disease. 3. Similarity of symptoms produced by feeding chlorinated biphenyl. *Poultry Sci.* 44, 1460–1465.

GRANICK, S. (1965). Hepatic porphyria and drug-induced or chemical porphyria. *Ann. N. Y. Acad. Sci.* 123, 188–197.

GRANICK, S. (1966). The induction in vitro of the synthesis of δ-aminolevulinic acid synthetase in chemical porphyria: A response to certain drugs, sex hormones and foreign chemicals *J. Biol. Chem.* 241, 1359–1375.

HIGGINBOTHAM, G. R., HUANG, A., FIRESTONE, D., VERRET, J., RESS, J., and CAMPBELL, A. D. (1968). Chemical and toxicological evaluations of isolated and synthetic chloroderivatives of dibenzo-*p*-dioxin. *Nature* (*London*) 220, 802–703.

HOLDEN, A. V., and MARSDEN, K. (1967). Organochlorine pesticides in seals and porpoises. *Nature* (*London*) 216, 2174–1276.

HOLMES, D. C., SIMMONS, J. H., and TATTON, J. O. G. (1967). Chlorinated hydrocarbons in British wildlife. *Nature* (*London*) 216, 227–229.

HUANG, A., FIRESTONE, D., and CAMPBELL, A. D. (1967). Detection of chick edema factor and other chlorinated hydrocarbons in fats and oils by electron capture gas chromatography: use of TLC as a preliminary cleanup procedure. *J. Ass. Offic. Anal. Chem.* 50, 16–21.

IRISH, O. D. (1963). *Industrial Hygiene and Toxicology.* (F. A. Patty, ed.), 2nd ed., Vol. 2, pp. 1340–1343. Wiley (Interscience), New York.

JENSEN, S. (1966). Report of a new chemical hazard. *New Sci.* 32, 612.

KOEMAN, J. H., OSKAMP, A. A. G., VEEN, J., BROUWER, E., ROOTH, J., ZWART, P., v.d. BROEK, E., and VAN GENDEREN, H. (1967). Insecticides as a factor in the mortality of the sandwich tern (Sterna sandvicensis). *Meded. Rijksfac. Landbouwwetensch. Gent* 32, 841–854.

KOEMAN, J. H., TEN NOEVER DE BRAUW, M. C., and DE VOS, R. H. (1969). Chlorinated biphenyls in fish, mussels and birds from the river Rhine and the Netherlands coastal area. *Nature* (*London*) 221, 1126–1128.

LILLIE, R. D. (1965). *Histopathologic Technic and Practical Histochemistry*, pp. 518–519. McGraw-Hill, New York.

LINN JONES, E., and KRIZEK, H. (1962). A technic for testing acnegenic potency in rabbits, applied to the potent acnegen, 2,3,7,8-tetrachlorodibenzo-*p*-dioxin. *J. Invest. Dermatol.* 39, 511–517.

MONS 206376

McCune, E. L., Savage, J. E., and O'Dell, B. L. (1962). Hydropericardium and ascites chicks fed a chlorinated hydrocarbon. *Poultry Sci.* 41, 295–299.

Miller, J. W. (1944). Pathologic changes in animals exposed to a commercial chlorinated diphenyl. *Pub. Health Rep.* 59, 1085–1093.

Rimington, C. (1961). Quantitative determination of porphobilinogen and porphyrins in urine and faeces. Broadsheet No. 36 of the Association of Clinical Pathologists. Copies may be obtained from Dr. R. B. H. Tierney, Pathology Laboratory, 75, Boutport Street, Barnstaple, Devon.

Risebrough, R. W., Rieche, P., Peakall, D. B., Herman, S. G., and Kirven, M. N. (1968). Polychlorinated biphenyls in the global ecosystem. *Nature (London)* 220, 1098–1102.

van der Waerden, B. L. (1957). *Mathematische Statistik*, pp. 269–284. Springer, Berlin.

von Weidel, H., Holla, W. A., and Denton, J. (1943). Observations on the toxic effects resulting from exposure to chlorinated naphthalene and chlorinated phenyls with suggestions for prevention. *Rubber Age (New York)* 53, 419–426.

Vos, J. G., Breeman, H. A., and Benschop, H. (1968). The occurrence of the fungicide hexachlorobenzene in wild birds and its toxicological importance. *Meded. Rijksfac. Landbouwwetensch Gent.* 33, 1263–1269.

MONS 206377