Vos, J. G., J. A. Moore, and J. G. Zinkl. 1974. Toxicity of 2,3,7,8-tetrachlorodibenzo-p-dioxin (TCDD) in C57Bl/6 mice. Toxicology and Applied Pharmacology 29: 229-241.

MONS 200647

TOXICOLOGY AND APPLIED PHARMACOLOGY 29, 229–241 (1974)

Toxicity of 2,3,7,8-Tetrachlorodibenzo-p-dioxin (TCDD) in C57B1/6 Mice

J. G. Vos, J. A. Moore, and J. G. Zinkl

National Institute of Environmental Health Sciences, Research Triangle Park, North Carolina 27709

Received October 18, 1973; accepted January 2, 1974

Toxicity of 2,3,7,8-Tetrachlorodibenzo-*p*-dioxin (TCDD) in C57B1/6 Mice. Vos, J. G., Moore, J. A. and Zinkl, J. G. (1974). *Toxicol. Appl. Pharmacol.* 29, 229–241. Three-month-old male C57B1/6 mice were given single oral doses of 0, 100, 150, or 200 μg of 2,3,7,8-tetrachlorodibenzo-*p*-dioxin (TCDD)/kg. The LD50 was 114 μg kg. In mice that died, depletion of the thymus and spleen were consistently found and edema and terminal hemorrhages occurred frequently. In a second experiment, 4-month-old male mice were dosed po with 0, 0.2, 1.0, 5.0 or 25 μg kg, once a week for 2 or 6 weeks. Some deaths and growth retardation occurred in the 25 μg/kg dose group. Significantly increased liver and decreased thymus weights were found in the 1, 5 and 25 μg/kg dose groups. Total neutrophils were increased significantly, whereas hemoglobin values and mean corpuscular hemoglobin concentrations were decreased significantly after 6 doses of 25 μg/kg. Total serum protein and α-, β-, and γ-globulins were significantly decreased. TCDD was porphyrogenic. The hepatic porphyria was probably associated with liver damage. Degenerative and necrotic changes in the liver were essentially centrilobular and were accompanied by cellular infiltrates and ceroid pigment deposition. Proliferation of bile duct and bile duct epithelial cells occurred. Lipid accumulation was centrilobulary localized in the mice receiving 0.2 μg/kg, was more pronounced in the mice of the intermediate dose levels, and involved hepatocytes throughout the lobule in the 25 μg/kg dose group.

The compound, 2,3,7,8-tetrachlorodibenzo-*p*-dioxin (TCDD), one of the most toxic chemicals known, can appear under unfavorable conditions of high temperature and pressure as an impurity in the production of 2,4,5-trichlorophenol by alkaline hydrolysis of 1,2,4,5-tetrachlorobenzene. TCDD has been associated with occupational chloracne in workers engaged in the manufacture of technical chlorophenols and their derivatives, such as the herbicide 2,4,5-trichlorophenoxyacetic acid (2,4,5-T) (Kimmig and Schulz, 1957). Trace amounts of TCDD and other chlorinated dibenzo-*p*-dioxins were responsible for chick edema disease (Higginbotham *et al.*, 1968; Firestone, 1973), first encountered in the U.S. in 1957 when millions of broilers died. Characteristic lesions included the presence of excessive fluid in the pericardial sac and in the abdominal cavity. More recently, TCDD has been shown to be highly teratogenic and feticidal for

Copyright © 1974 by Academic Press, Inc.
All rights of reproduction in any form reserved.
Printed in Great Britain

NCNS 200648

rats and mice (Sparschu *et al.*, 1970; Courtney and Moore, 1971; Neubert and Dillmann 1972).

Parameters of toxicity as single oral LD50 dose, range of time interval from dosing until death and pathologic changes have been established for rats, guinea-pigs and rabbits (Harris *et al.*, 1973; Gupta *et al.*, 1973; Schwetz *et al.*, 1973; Greig *et al.*, 1973). Since marked species differences in the toxicity and pathology of TCDD occurred, the present study was conducted to establish these parameters for the laboratory mouse.

METHODS

The chemical, 2,3,7,8-tetrachlorodibenzo-*p*-dioxin (TCDD) (>99% purity, Dow Chemical Co., Midland, Michigan), was dissolved in reagent grade acetone and subsequently diluted with at least 6 parts of corn oil. All inbred mice (C57Bl/6 Sch strain, reared at the Institute) were given TCDD by gastric intubation and were dosed according to the weight of each mouse (0.1 ml/20 g). Control mice were treated with an acetone-corn oil mixture only. The mice were weighed at least once weekly, housed singly in plastic cages, and allowed free access to food and water.

In an acute toxicity study, 58 three-month-old male mice (mean weight 27.1 g; range 23.6 to 30.8 g), received single doses of 0, 100, 150 or 200 μg TCDD/kg. In a subacute study, 100 four-month-old male mice (mean weight 30.3 g, range 26.1 to 35.7 g) were divided into 5 groups that received weekly doses of 0, 0.2, 1.0, 5.0 or 25 μg/kg body weight. Half of the mice were killed after 2 weeks and the remaining mice after 6 weeks using carbon dioxide gas.

Blood was taken from the heart via cardiac puncture. Standard methods were used for hematologic determinations. Serum protein was determined by the biuret technique (Gornall *et al.*, 1949) and serum protein fractionation was done by cellulose acetate electrophoresis. Liver and thymus weights were recorded.

Necropsies were performed on mice that died and those that were killed when moribund. For histologic evaluation, tissue samples from liver, spleen, kidney, urinary bladder, heart, lung, thymus, brain, stomach, small and large intestines, pancreas, striated muscle, skin, testes and eyes were collected from most of the mice, fixed in 10% buffered neutral formalin and paraffin-embedded; sections were stained with hematoxylin and eosin. In the subacute study, only liver, thymus and gastrointestinal tract of the killed mice were processed for histopathologic studies because the lesions in the acute study were primarily restricted to these organs. Liver sections were also stained with Gomori's method for iron and with periodic acid–Schiff (PAS) reagent. Unstained paraffin-embedded liver sections were examined by fluorescence microscopy for the detection of ceroid pigment. Cryostat sections of formalin-fixed liver tissue were stained with Oil Red 0 for lipids.

In both experiments, the mice were examined under ultraviolet light and red fluorescence was used as indication for the presence of excess quantities of porphyrins.

The LD50 was calculated by the logit method (van der Waerden, 1957). Dunnett's multiple comparison test (Miller, 1966) or the distribution-free Wilcoxon test (van der Waerden, 1957) were used to make treatment-control comparisons, usually 2-sided, except for body weights (1-sided).

NONS 200649

RESULTS

Acute Toxicity Study

At the 200 μg/kg dose, weight loss was observed 3 days after dosing and was progressive in most mice. However, approximately 30% of the animals had a terminal increase of body weight, probably due to accumulation of fluid in tissues and body cavities (see gross lesions later). Mice died between 15 and 24 days (mean 20.0 days). Mortality after 150 μg/kg was 93%, and the mean survival time was 22.6 days (range 17 to 30 days). Mortality was 22% after 100 μg/kg. The survivors gradually lost body weight for 3 weeks and then body weight increased. After the 2-month observation period, the mean body weight was 11% lower than controls. The oral LD50 was calculated as 114 μg/kg.



FIG. 1. Severe subcutaneous edema (arrows) in a mouse that died after TCDD administration.

Clinical signs of toxicity were generally observed shortly before death and included hunched posture, inactivity and ruffled hair. In approximate one-fourth of the mice terminal edema was present (Fig. 1), which was primarily subcutaneous in location. Excessive thoracic and abdominal fluid was also observed. Unilateral or bilateral ocular lesions consisted of protruding, dry eyes and were due to intraorbital hemorrhages (Fig. 2). Grossly, there was severe atrophy of the thymus and spleen. The livers were yellowish with accentuation of the lobular pattern. The small intestine was distended with hemorrhagic fluid. All livers from dead or moribund mice had red fluorescence when examined macroscopically under ultraviolet light. Occasionally there was also fluorescence on the small intestine.

Microscopically, changes were found consistently in the liver, thymus and spleen. Changes in the gastrointestinal tract and ocular lesions were observed frequently. Atrophy of the thymic cortex with decreased cellularity was so severe that a distinction

MONS 200650

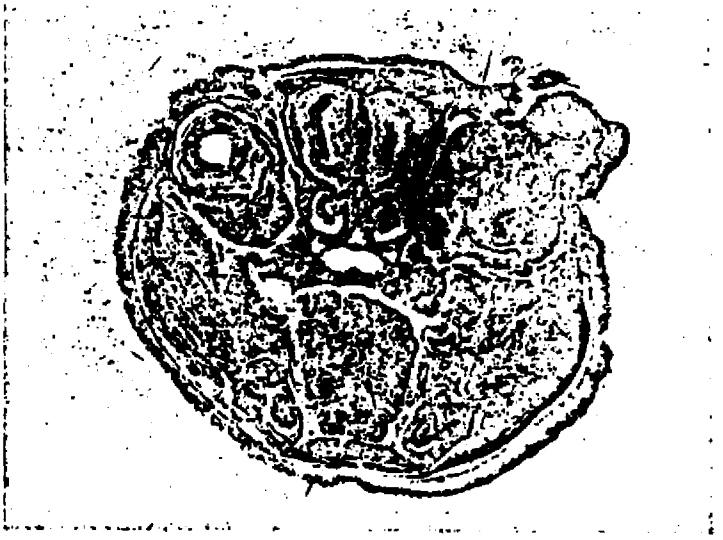

FIG. 2. Transverse section of the head from a mouse treated with a lethal dose (150 μg/kg) of TCDD showing severe unilateral intraocular, retroocular and subcutaneous hemorrhages. Hematoxylin : eosin. × 6.



FIG. 3. Liver from a mouse killed when moribund after a 200 μg/kg dose of TCDD. Note the enlar hepatocytes and the cellular infiltrations in the centrilobular area. cv, central vein. Hematoxylin eosin. × 50.

MONS 200651

could not be made between cortex and medulla. Spleens were also very small and had wrinkled capsules. There were depletion and destruction of lymphocytes ("starry-sky" appearance) in follicles and periarteriolar lymphocyte sheaths.

Hepatic lesions were seen in the centrilobular areas that frequently contained degenerated and necrotic hepatocytes (Figs. 3 and 4). Some hepatocytes were enlarged and had a foamy cytoplasm; enlargement of liver cell nuclei also occurred. In these areas, cellular infiltrates (predominantly lymphocytes and polymorphonuclear leucocytes) were often observed together with green-brown pigment deposits. Small foci of necrosis were seen, and were mostly located in the centrilobular region. Scattered single cell

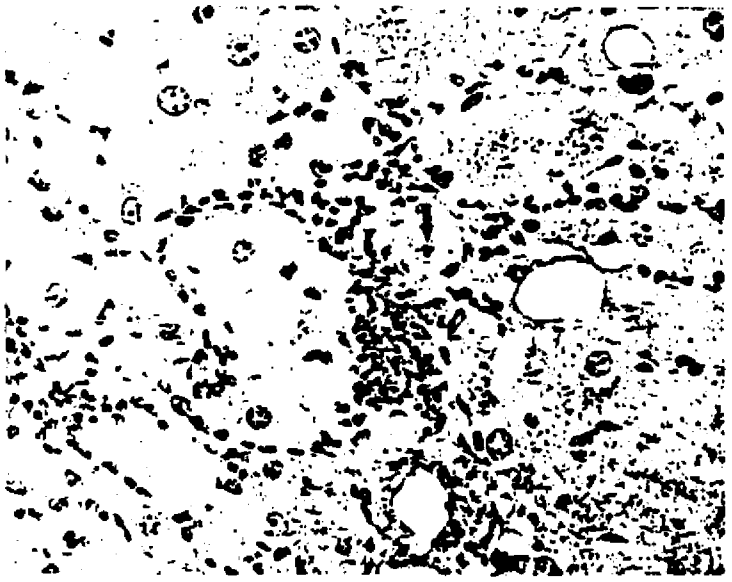

FIG. 4. Centrilobular area of liver from a mouse that was killed when moribund after treatment with 100 μg TCDD/kg. Many hepatocytes are enlarged and have a foamy or vacuolated cytoplasm. Nuclear pyknosis (arrow) and nuclear enlargement are also present. The cellular infiltration consists predominantly of lymphocytes. Hematoxylin and eosin. × 312.

necrosis was also present. There was a diffuse vacuolization of hepatocytes due to extensive lipid accumulation (Oil Red O stain). Apparently there was loss of hepatic glycogen. Proliferation of bile ducts and bile duct epithelial cells was observed in the periportal areas. There was no hepatic hemosiderosis.

In the gastrointestinal tract, submucosal edema was seen frequently in stomach and small and large intestine. The lamina propria of the small intestine was sometimes edematous and had increased cellularity. Blood was commonly seen in the lumen of the small intestine. Intraorbital blood (Fig. 2) was localized mainly behind the eye, in and around the Harderian gland, and often caused protrusion of the eye. Hemorrhages were also seen in the eyelids, especially the lower lid, and within the globe. Occasionally, dilatation of the convoluted tubules was observed in the kidneys; steatitis was an uncommon lesion.

NOAS * 200652

TABLE 1

BODY WEIGHT GAIN AND ORGAN WEIGHTS OF MICE TREATED WITH TCDD FOR 2 WEEKS[a]

Weekly dose of TCDD (μg/kg)	Body weight gain (g)	Liver weight (g)	Liver/body weight ratio (%)	Thymus weight (mg)	Thymus/body weight ratio (%)
0	+0.89 ± 0.69	1.88 ± 0.12	6.07 ± 0.11	39.9 ± 6.3	0.127 ± 0.018
0.2	+0.68 ± 1.28	1.80 ± 0.26	5.99 ± 0.71	36.2 ± 6.5	0.120 ± 0.017
1.0	+0.66 ± 1.95	2.14 ± 0.09[b]	6.75 ± 0.33[c]	34.9 ± 4.1[b]	0.110 ± 0.017[b]
5.0	−0.50 ± 0.88[c]	2.22 ± 0.39[b]	7.01 ± 0.87[b]	26.7 ± 4.5[c]	0.085 ± 0.015[c]
25.0	−2.40 ± 1.28[c]	1.93 ± 0.15	7.13 ± 0.41[c]	8.0 ± 2.8[c]	0.030 ± 0.010[c]

[a] Mean values ± SD; 9–11 animals per group..
[b] $p < 0.05$.
[c] $p < 0.01$.

TABLE 2

BODY WEIGHT GAIN AND ORGAN WEIGHTS OF MICE TREATED WITH TCDD FOR 6 WEEKS[a].

Weekly dose of TCDD (μg/kg)	Mortality	Body weight gain (g)	Liver weight (g)	Liver/body weight ratio (%)	Thymus weight (mg)	Thymus/body weight ratio (%)
0	0/9	+1.45 ± 1.58	1.97 ± 0.31	5.98 ± 0.70	56.4 ± 9.2	0.173 ± 0.031
0.2	0/9	+3.43 ± 2.30	2.08 ± 0.30	6.39 ± 0.55	54.4 ± 17.5	0.166 ± 0.042
1.0	0/9	+2.09 ± 1.61	2.37 ± 0.36[b]	7.03 ± 0.63[c]	46.0 ± 9.7[b]	0.137 ± 0.023[b]
5.0	0/9	+0.58 ± 1.19	2.35 ± 0.20[c]	7.56 ± 0.30[c]	30.7 ± 7.3[c]	0.098 ± 0.019[c]
25.0	3/17	−2.88 ± 2.87[c]	2.24 ± 0.25[b]	8.53 ± 0.81[c]	11.4 ± 6.8[c]	0.042 ± 0.021[c]

[a] Mean values ± SD.
[b] $p < 0.05$.
[c] $p < 0.01$.

NONS 200653

Subacute Toxicity Study

Three of 17 mice receiving 25 μg/kg died after 35, 37 and 40 days, respectively. The lesions were similar to those described in the acute toxicity study.

Body weight gain, liver and thymus weights of mice killed after 2 and 6 weeks are given in Tables 1 and 2. After 2 weekly doses there was a significant weight loss in the groups receiving 5 and 25 μg/kg. Liver weights were significantly increased at 1 and 5 μg/kg. Liver-to-body-weight ratios were increased significantly after 1, 5 and 25 μg/kg. Thymus weights and thymus-to-body-weight ratios were significantly decreased in these same groups. Mean thymus weight in the 25-μg/kg group was 20% of the control value. After 6 weekly doses of TCDD (Table 2), there was a significant loss of body weight in the 25-μg/kg group. Significantly increased liver weights and liver-to-body weight ratios as well as significantly decreased thymus weights and thymus-to-body weight ratios were recorded in the groups receiving 1, 5 and 25 μg/kg.

Hematologic parameters of the mice killed after 2 weekly doses were similar for the different groups. Results of the same hematologic determinations in mice killed after 6 weekly doses of TCDD are given in Tables 3 and 4. Total number of leucocytes and monocytes were similar for test and control groups. Neutrophils were increased significantly after 25 μg/kg. No significant reduction was seen in the number of lymphocytes and eosinophils. Total erythrocyte number, hematocrit and mean corpuscular volume (Table 4) were similar for all groups. Hemoglobin and mean corpuscular hemoglobin concentrations were significantly lower in the 25-μg/kg group. Since reticulocytosis was not present, hypochromasia was perhaps due to decreased hemoglobin synthesis.

Marked effects were found in serum proteins (Table 5). Total protein was significantly lower after 25 μg/kg. Alpha globulin was lower for the 1- and 25-μg/kg groups, β-globulin for all treated groups, and γ-globulin for the 5- and 25-μg/kg groups. Albumin values were significantly higher for the 0.2-μg/kg group.

The livers of the mice receiving 25 μg/kg that were killed after 6 weekly TCDD doses had a lobular pattern, were brown and all had a slight-to-intense red fluorescence under ultraviolet light.

Microscopically, depletion of the thymic cortex (Fig. 5) in mice from the 25-μg/kg group was nearly as severe as seen in mice from the acute experiment. This lesion was seen in mice treated with 2 weekly doses as well as in mice dosed for 6 weeks. Weekly treatment with 5 μg/kg decreased the size and sometimes the cellularity of the cortex. No thymic lesions were seen at the lower dose when compared with controls. The hepatic lesions increased in severity with dose and period of treatment, but the degree of hepatic damage varied considerably among animals of each dose group. After 2 weekly doses of 25 μg/kg, degenerated liver cells were found around the central vein. After 6 doses of 25 μg/kg, the area of degeneration was larger. In these mice, nuclear changes included polyploidy and vacuolization of nuclei; mitotic figures were regularly seen. Proliferation of bile ducts and bile duct epithelial cells with vesiculated nuclei was marked (Fig. 6). Inflammatory cell infiltrates in the central vein areas were seen in mice killed after 2 and 6 weeks. Brown pigment was observed in severely damaged cells of the centrilobular area and stained positive for iron. The pigment was PAS-positive and had a yellow-brownish fluorescence under ultraviolet light; these properties indicate

MONS 200654

TABLE 3

LEUCOCYTE COUNTS OF MICE TREATED WITH TCDD FOR 6 WEEKS[a]

Weekly dose of TCDD (μg/kg)	No. of animals	Total leucocytes ($\times 10^3$/mm^3)	Lymphocytes ($\times 10^3$/mm^3)	Neutrophils ($\times 10^3$/mm^3)	Eosinophils (mm^3)	Monocytes (mm^3)
0	9	11.14 ± 2.48	9.05 ± 2.44	1.38 ± 0.26	378 ± 258	301 ± 259
0.2	8	11.24 ± 2.54	9.40 ± 2.19	1.30 ± 0.52	175 ± 145	356 ± 312
1.0	9	11.11 ± 1.78	9.13 ± 1.81	1.60 ± 0.52	148 ± 64	231 ± 154
5.0	9	11.54 ± 1.90	9.82 ± 1.18	1.31 ± 0.62	119 ± 131	257 ± 200
25.0	14	11.63 ± 2.46	8.37 ± 1.69	2.84 ± 1.05[b]	76 ± 101	342 ± 191

[a] Mean values ± SD.
[b] $p < 0.01$.

TABLE 4

ERYTHROCYTE COUNTS, HEMATOCRIT, HEMOGLOBIN CONCENTRATION AND ERYTHROCYTE INDICES OF MICE TREATED WITH TCDD FOR 6 WEEKS[a]

Weekly dose of TCDD (μg/kg)	No. of animals	Erythrocytes ($\times 10^6$/mm^3)	Hematocrit (%)	Hemoglobin (g/100 ml)	Mean corpuscular volume (μm^3)	Mean corpuscular hemoglobin conc. (%)
0	9	9.26 ± 1.34	45.7 ± 2.9	11.87 ± 1.04	50.2 ± 11.1	26.0 ± 1.8
0.2	8	9.85 ± 1.00	45.3 ± 3.2	12.20 ± 1.08	46.2 ± [illegible]	27.0 ± 2.3
1.0	9	9.29 ± 1.16	44.7 ± 2.6	11.57 ± 0.71	48.8 ± [illegible]	26.2 ± 2.0
6.0	9	9.66 ± 1.10	45.4 ± 3.2	11.27 ± 0.76	47.5 ± 5.9	24.8 ± 2.0
25.0	14	9.26 ± 0.69	45.3 ± 2.7	10.80 ± 0.70[c]	49.3 ± 6.0	23.9 ± 1.7[b]

[a] Mean values ± SD.
[b] $p < 0.05$.
[c] $p < 0.01$.

NONS 200655

TABLE 5

SERUM ALBUMIN, GLOBULIN AND TOTAL PROTEIN VALUES OF MICE TREATED WITH TCDD FOR 6 WEEKS[a]

Weekly dose of TCDD (μg/kg)	No. of animals	Albumin	α-Globulin	β-Globulin	γ-Globulin	Total protein
0	7	24.4 ± 2.7	5.06 ± 0.42	5.94 ± 0.92	13.8 ± 2.0	49.1 ± 3.6
0.2	6	30.6 ± 3.3[b]	5.07 ± 0.67	3.28 ± 1.33[c]	11.6 ± 2.5	50.5 ± 3.9
1.0	7	28.2 ± 5.0	3.53 ± 1.04[b]	3.77 ± 1.58[c]	11.7 ± 1.3	47.1 ± 4.9
5.0	8	27.2 ± 2.1	4.71 ± 1.07	3.39 ± 1.13[c]	10.0 ± 1.5[c]	45.2 ± 2.4
25.0	12	24.3 ± 4.8	3.28 ± 1.16[c]	2.61 ± 0.93[c]	10.2 ± 2.6[c]	40.4 ± 7.3[c]

[a] Mean values ± SD. The results are expressed in g/liter.
[b] $p < 0.05$.
[c] $p < 0.01$.

MONS 200656



FIG. 5. Thymus from a mouse that received 6 weekly doses of 25 μg TCDD/kg, illustrating severe atrophy of the cortex. Hematoxylin and eosin. × 100.

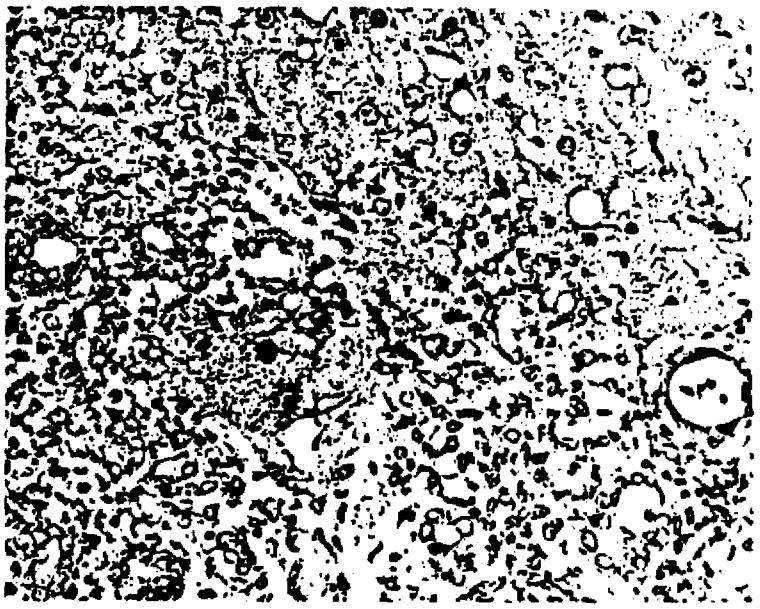

FIG. 6. Periportal area of liver from a mouse that received 6 weekly doses of 25 μg TCDD/kg. There is extensive proliferation of bile ducts and bile duct epithelial cells. A multinucleated cell can also be seen. Hematoxylin and eosin. × 250.

NONS 200657

that the pigment was ceroid (Porta and Hartroft, 1969). There was no hepatic hemosiderosis. Inflammatory cells along with necrotic hepatocytes were also seen in the centrilobular regions of the livers from mice receiving 5 μg/kg.

Lipid accumulation in the liver appeared to be a very sensitive parameter for TCDD exposure. At the lowest dose (6 weekly treatments with 0.2 μg/kg) there was slight but consistent centrilobular fatty change. At 1 μg/kg, moderate accumulation occurred both in centrilobular and midzonal hepatocytes, and was more pronounced in the 5-μg/kg group. At 25 μg/kg fatty change was severe and involved hepatocytes throughout the lobule. Representative areas of Oil Red O-stained liver sections are shown in Fig. 7. No lesions were seen in the gastrointestinal tracts of these animals.

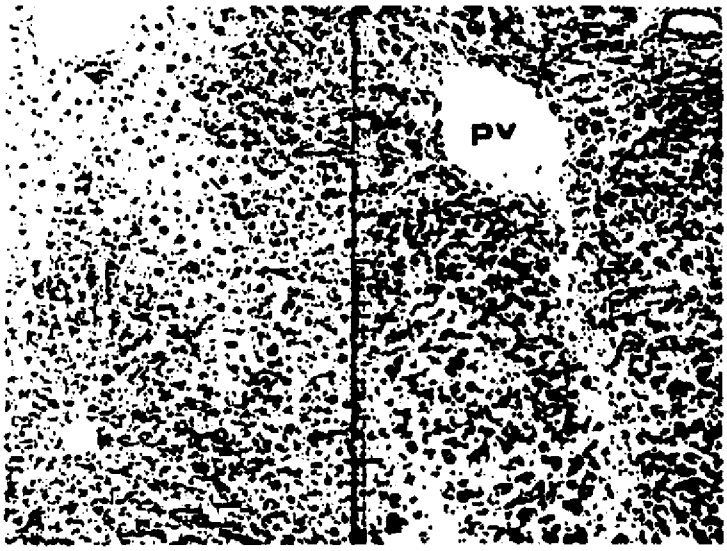

FIG. 7. Livers from mice that received 6 weekly doses of TCDD. Oil Red O. ×100. (A) 0.2 μg TCDD/kg treated animal showing centrilobular accumulation of small lipid droplets. (B) 25 μg TCDD/kg treated animal with severe accumulation of predominantly large lipid droplets throughout the lobule. pv, portal vein.

DISCUSSION

The LD50 of TCDD for 3-month-old male C57Bl/6 mice (114 μg/kg) is approximately the same as for male CD rats (Harris *et al.*, 1973), but much higher than the LD50 of 22 μg/kg found in male Sherman strain rats (Schwetz *et al.*, 1973). Of the animal species tested, male guinea-pigs are most sensitive to TCDD, and the single oral LD50 is 0.6 μg TCDD/kg (Schwetz *et al.*, 1973). In the present study, there was no mortality in 4-month-old mice after 4 weekly doses of 25 μg/kg. We have observed (unpublished data) that 17 and 44% of male C57Bl/6 mice that were 2 months old and 1 month old, respectively, died when given the same dose. An age dependency with respect to toxic dose is suggested by these data.

NONS 200658

TCDD is porphyrogenic in the mouse, but not in rats and guinea-pigs (Gupta *et al.*, 1973; Woods, 1973). However, TCDD is a potent inducer of ALA synthetase in chick embryo liver (Poland and Glover, 1973). The hepatic porphyria evoked by TCDD, probably associated with liver damage, is a uroporphyria. Uroporphyrin in livers of mice that died or were killed when moribund after a single dose of 150 μg/kg was increased 4000-fold (Goldstein *et al.*, 1973).

The most severe lesions were seen in thymus (Fig. 5) and liver with a no-effect level for their weights at the 0.2 μg/kg dose. Thymus atrophy was also consistently seen in rats and guinea-pigs (Harris *et al.*, 1973; Gupta *et al.*, 1973; Buu-Hoï *et al.*, 1972). Suppression of cell-mediated immunity was found in guinea-pigs (Vos *et al.*, 1973) and in young rats and mice after pre- and postnatal maternal treatment with TCDD (unpublished data). No effect was found on cell-mediated immunity of adult mice (unpublished data) as measured by the graft-versus-host activity of spleen cell suspensions, and the in vitro responsiveness of spleen cells to phytohemagglutinin. The decreased serum globulin values (Table 5) could suggest that humoral immunity was suppressed. Some depression in serum antibody titers against tetanus toxoid was found in guinea-pigs treated with TCDD (Vos *et al.*, 1973).

Severe TCDD-induced liver damage has been reported in rats (Gupta *et al.*, 1973), rabbits (Kimmig and Schulz, 1957), and chickens (Schwetz *et al.*, 1973), but not in guinea-pigs (Gupta *et al.*, 1973). Rats that died after exposure to TCDD were jaundiced and had diffuse degenerative and necrotic changes in the liver. At sublethal doses, transient degenerative liver changes were followed by megalocytosis, pleomorphism, regeneration and an increased number of multinucleated large hepatocytes (Gupta *et al.*, 1973). Liver damage in the mouse consists of centrilobular degeneration and necrosis, cellular infiltrations, ceroid pigment deposits, and extensive lipid accumulation (Fig. 7). Proliferation of bile ducts and bile duct epithelial cells (Fig. 6) was most pronounced after 6 weekly doses of 25 μg/kg. As a result of liver damage, depressed hepatic function (protein synthesis) could be responsible for edema formation (Fig. 1; Table 5), since there was a correlation between the presence of edema and low albumin concentrations. Edema was a consistent finding in chickens (Schwetz *et al.*, 1973), but was not observed in guinea-pigs and rats that died after exposure to TCDD (Gupta *et al.*, 1973). Defects in the clotting mechanism due to liver damage or thrombocytopenia (Zinkl *et al.*, 1973) were perhaps responsible for the hemorrhages. The predilection of the orbital tissues to hemorrhage (Fig. 2) is unclear, however. Massive hemorrhages in several organs were seen in rats that died from TCDD, whereas in guinea-pigs hemorrhages were primarily restricted to the gastrointestinal tract and the urinary bladder (Gupta *et al.*, 1973).

In view of the progressive proliferation of bile ducts and bile duct epithelial cells combined with the bizarre pleomorphism of hepatocytes seen in rat liver (Gupta *et al.*, 1973; Greig *et al.*, 1973), a long-term study to assess the role of TCDD as a possible carcinogen is indicated.

ACKNOWLEDGMENTS

The authors thank Dr. J. K. Haseman for statistical consultation and Mrs. L. D. Lawson, Mrs. M. T. Ebron and Mr. F. Talley for valuable technical assistance.

MONS 200659

REFERENCES

Bui-Hoi, N. P., Pham-Huu Chanh, Sesoue, G., Azum-Gelade, M. C. and Saint-Ruf, G. (1972). Organs as targets of "dioxin" (2,3,7,8-tetrachlorodibenzo-*p*-dioxin) intoxication. *Naturwissenschaften* 4, 174–175.

Courtney, K. D. and Moore, J. A. (1971). Teratology studies with 2,4,5-trichlorophenoxyacetic acid and 2,3,7,8-tetrachlorodibenzo-*p*-dioxin. *Toxicol. Appl. Pharmacol.* 20, 396–403.

Firestone, D. (1973). Etiology of the chick edema disease. *Environ. Health Perspec.* 5, 59–66.

Goldstein, J. A., Hickman, P., Bergman, H. and Vos, J. G. (1973). Hepatic porphyria induced by 2,3,7,8-tetrachlorodibenzo-*p*-dioxin in the mouse. *Res. Commun. Chem. Pathol. Pharm.* 6, 919-928.

Gornall, A. G., Bardawill, C. J. and David, M. M. (1949). Determination of serum proteins by means of the biuret reaction. *J. Biol. Chem.* 177, 751–766.

Greig, J. B., Jones, G., Butler, W. H. and Barnes, J. M. (1973). Toxic effects of 2,3,7,8-tetrachlorodibenzo-*p*-dioxin. *Fd. Cosmet. Toxicol.* 11, 585–595.

Gupta, B. N., Vos, J. G., Moore, J. A., Zinkl, J. G. and Bullock, B. C. (1973). Pathologic effects of 2,3,7,8-tetrachlorodibenzo-*p*-dioxin in laboratory animals. *Environ. Health Perspec.* 5, 125–140.

Harris, M. W., Moore, J. A., Vos, J. G. and Gupta, B. N. (1973). General biological effects of TCDD in laboratory animals. *Environ. Health Perspec.* 5, 101–109.

Higginbotham, G. R., Huang, A., Firestone, D., Verrett, J., Ress, J. and Campbell, A. D. (1968). Chemical and toxicological evaluation of isolated and synthetic chloro derivatives of dibenzo-*p*-dioxin. *Nature (London)* 220, 702–703.

Kimmig, J. and Schulz, K. H. (1957). Berufliche Akne (sog. Chlorakne) durch chlorierte aromatische zyklische Äther. *Dermatologica* 115, 540–546.

Miller, R. G. (1966). *Simultaneous Statistical Inference*. McGraw-Hill, New York.

Neubert, D and Dillmann, I. (1972). Embryotoxic effects in mice treated with 2,4,5-trichlorophenoxyacetic acid and 2,3,7,8-tetrachlorodibenzo-*p*-dioxin. *Naunyn-Schmiedebergs Arch. Exp. Pathol. Pharmakol.* 272, 243–264.

Poland, A. and Glover, E. (1973). 2,3,7,8-Tetrachlorodibenzo-*p*-dioxin: a potent inducer of *δ*-aminolevulinic acid synthetase. *Science* 179, 476–477.

Porta, E. A. and Hartroft, W. S. (1969). *Pigments in Pathology* (M. Wolman, ed.), p. 210. Academic Press, New York.

Schwetz, B. A., Norris, J. M., Sparschu, G. L., Rowe, V. K., Gehring, P. J., Emerson, J. L. and Gerbig, C. G. (1973). Toxicology of chlorinated dibenzo-*p*-dioxins. *Environ. Health Perspec.* 5, 87–99.

Sparschu, G. L., Dunn, F. L. and Rowe, V. K. (1970). Teratogenic study of 2,3,7,8-tetrachlorodibenzo-*p*-dioxin in the rat. *Toxicol. Appl. Pharmacol.* 17, 317–318.

van der Waerden, B. L. (1957). *Mathematische Statistik*, pp. 209–221, 269–284, Springer-Verlag, Berlin.

Vos, J. G., Moore, J. A. and Zinkl, J. G. (1973). Effect of 2,3,7,8-tetrachlorodibenzo-*p*-dioxin on the immune system of laboratory animals. *Environ. Health Perspec.* 5, 149–162.

Woods, J. S. (1973). Studies on the effects of 2,3,7,8-tetrachlorodibenzo-*p*-dioxin on mammalian hepatic *δ*-aminolevulinic acid synthetase. *Environ. Health Perspec.* 5, 221–225.

Zinkl, J. G., Vos, J. G., Moore, J. A. and Gupta, B. N. (1973). Hematologic and clinical chemistry effects of 2,3,7,8-tetrachlorodibenzo-*p*-dioxin in laboratory animals. *Environ. Health Perspec.* 5, 111–118.

NONS 290660