55

CEC - EPA - WHO PARIS JUNE 1974

INTERNATIONAL SYMPOSIUM - ENVIRONMENT AND HEALTH

BIOLOGICAL EFFECTS OF THE POLYCHLORINATED BIPHENYLS IN NONHUMAN PRIMATES

J.R. ALLEN, L.A. CARSTENS, and D.H. NORBACK

Department of Pathology, and Regional Primate Research Center

University of Wisconsin, Madison, Wisconsin 53706 U.S.A.

Summary

Daily ingestion of polychlorinated biphenyls (PCBs) at doses between 25 ppm and 300 ppm over a period of 2 to 3 months caused morbidity and mortality in nonhuman primates (Macaca mulatta). Changes included loss of body weight, alopecia, subcutaneous edema, acne, conjunctivitis, ascites, hydrothorax, gastric mucosal hyperplasia, liver hypertrophy, and bone marrow hypoplasia. Terminally, these animals had decreased hemoglobins, hematocrits, and serum protein, shifts in the serum albumin to globulin ratios and a neutrophilia. A dose of 2.5 ppm PCB in the diet was sufficient to cause alopecia, focal edema and conjunctivitis in monkeys within 2 months. Animals that have survived the ingestion of 250 to 300 mg of PCB over 2 months maintained levels of PCB in their adipose tissue for periods in excess of 1 year. In addition, offspring of these animals had detectable levels of PCBs in their tissues.

In contrast to the injurious effects experienced by adult nonhuman primates exposed to PCBs, one-month-old infant monkeys that were exposed to 1 g of PCB for 30 days were essentially free of any of the clinical, gross, and microscopic alterations of PCB intoxication. These observations as well as metabolic studies suggest that the metabolism of the PCBs is important in determining their toxicity.

1. Introduction

Although the polychlorinated biphenyls (PCBs) have been used extensively for industrial purposes for over 40 years, it has only been during the last decade that they have been regarded as environmental contaminants (Jensen [1]). These compounds are extremely stable, not hydrolyzed by water, acids or alkali, and are able to withstand temperatures up to 650°F without disintegrating. They have been used in elastomers adhesives, paints, varnishes, printing inks, putty, and as general fillers. Since they do not conduct electricity, they have also found widespread use in electrical equipment such as transformers. Their stability and low vapor pressures make them well suited as lubricants, hydraulic fluids, liquid seals, cutting oils, vacuum diffusion pump oils, and as vapor suppressants and insecticide formulations. The same properties that make them ideal for commercial use also enhance their resistance to degradation in the environment. The magnitude of PCB contamination is further exemplified by their presence in coho salmon, milk fat, poultry, eggs, and fish (Kolbye [2]).. Primarily as a result of food contamination, detectable levels of PCBs were found to be present in over 30% of randomly sampled inhabitants of the United States (Yobs [3]).

Early outbreaks of PCB intoxication were limited to industrial accidents where workers reported incidents of chloracne (Jones and Alden, [4], Good and Pensky [5]). It was not until 1968 that the greater health significance of PCB exposure became known. Following the consumption of PCB contaminated rice oil by over 1,000 Japanese, diverse symptoms and lesions developed. These persons became nauseated and lethargic, and developed chloracne and subcutaneous edema. Infants born to exposed mothers were small and exhibited discolored skin and had an abnormal eye discharge. Many of the symptoms and lesions that developed during the acute phase of the illness have persisted for years (Kuratsune [6], Kuratsune et al. [7]).

2. Experimental Studies

2.1 High Level PCB Exposure. In order to further clarify the biological effects of various levels of PCB exposure in primates, a series of experiments have been conducted. In these experiments, adult Macaca mulatta monkeys were given diets containing 25, 100, and 300 ppm of a PCB (Aroclor 1248, Monsanto Co., Inc., St. Louis, Missouri, U.S.A.) for periods of 2 to 3 months (Allen and Norback [8], Allen et al. [9],

MONS 042129

[10]). Although each of these dosages produced signs and lesions compatible with PCB intoxication within one month, the total PCB intake varied from 250 to 400 mg for the 25 ppm group, 0.8 to 1.0 g for the 100 ppm group, and 3.6 to 5.4 g for the 300 ppm group. Mortality occurred in the groups receiving the two larger doses within 2 months and within 4 months on the lower regime. Hematological changes developed gradually during the period of experimentation; however, they were most obvious in the 300 ppm group. These animals showed a decrease in hemoglobin (grams per 100 ml) from 13.0 ± 1.0 to 10.6 ± 0.3 within 12 weeks, and a corresponding decrease in hematocrit from 39.0 ± 2.0% to 32.0 ± 1.0%. Although the total white cell count was not appreciably altered, there was a decrease in the number of lymphocytes and a concomitant increase in the neutrophil population. Decreases in the level of serum protein were accompanied by a reduction in the percentage of albumin and increases in the globulin fraction. Reduced levels of serum lipids, cholesterol, and triglycerides accompanied the alterations in serum protein (Allen et al. [10]).

A gradual weight loss was recorded throughout the experimental period for all PCB-fed animals. The 25% decrease in body weight of the 300 ppm group was particularly striking. Following one month of exposure, there was moderate to marked loss of hair from the head, neck, and back, and edema of the mouth and eyelids. Loss of eyelashes, excessive lacrimation, and conjunctivial congestion were also apparent. Small pustules involving hair follicles were particularly obvious around the mouth and on the cheeks and neck.

Liver biopsies taken from the animals after a short period of exposure to PCBs showed a decided increase in the smooth endoplasmic reticulum of the hepatic cells (Figure 1). Biochemically, the liver homogenates contained decreased levels of DNA (mg/mg liver) and RNA (mg/mg DNA) and increased levels of protein (mg/mg DNA) and increased activity of microsomal mixed function oxidases. In those animals that were sacrificed, the enlarged livers continued to show proliferation of the endoplasmic reticulum. However, instead of the endoplasmic reticulum being distributed throughout the cytoplasm it was arranged in distinct packets of closely associated membranes (Figure 2). Microsomes prepared from those livers showed a decided decrease in activity of mixed function oxidases (Allen et al. [9]).

The most severe pathological changes recorded at necropsy were located in the stomach where marked hypertrophy of the mucosal lining and edema of the stomach wall, particularly of the fundic and pyloric regions, were apparent. Microscopically, the hypertrophic, gastric mucosa was several times thicker than the control mucosa and was comprised of greatly elongated hyperplastic glands containing mucous secreting cells (Figures 3 and 4). Prevention of discharges of the secretions owing to the depth and apposition of the glands predisposed to the development of large mucous cysts. There was also widespread penetration of the muscularis mucosae with invasion of the submucosa by the mucosal epithelium. There were microscopic lesions of the skin, particularly of the face, of PCB-exposed animals. Numerous intrafollicular cysts surrounded by edematous leukocyte-filled connective tissue were apparent.

At necropsy a portion of the tissues from the animals was obtained for the determination of PCB levels by the previously reported gas chromatographic procedures (Allen et al., [9]). Sites of major storage, in addition to fat, were the adrenals, liver, and pancreas.

The persistence of the PCBs in the tissues of exposed animals was demonstrated in the group receiving 25 ppm PCBs in the diet for 2 months (total intake approximately 300 mg). Immediately after the PCB-supplemented diet was discontinued, the subcutaneous adipose tissue contained an average of 127 μg per g fat (Allen et al. [11]). Even after one year, concentrations of PCBs in the fatty tissue averaged 30 μg per g fat. Additional distribution data were obtained from a PCB-fed female that delivered an infant eight months after being taken off the PCB diet. Levels of PCB (μg/g tissue) in the adipose tissue of this infant were approximately one-half that present in the tissues of the mother, thus indicating transplacental movement of these compounds (Allen et al., [11]).

2.2 Low Level PCB Exposure. Recently, experiments have been initiated to determine if levels of PCBs permitted in foods destined for human consumption would be toxic when consumed on a continuous basis. Adult rhesus monkeys are being given diets containing 2.5 and 5.0 ppm PCBs (Aroclor 1248). These levels are one-half and equal to the levels permitted in certain foods. Interestingly enough, these animals developed loss of hair and eyelashes within 2 to 3 months. They also have swollen upper eyelids and congested conjunctiva.

MONS 042131

2.3 Infant Studies. In order to determine if adult and infant primates would respond similarly to PCB exposure, one-month-old rhesus monkeys were given 1 g (35 mg/kg body weight) of PCB over a 30 day period. The total consumption of PCBs by these infants was essentially the same as that received by the adults given 100 ppm in the diet as mentioned previously. These animals were able to survive without any obvious ill effects at doses that had been fatal to adults (Abrahamson and Allen, [12]). When the tissues from the infant and adult monkeys were evaluated chromatographically it was established that the concentration of PCB was lower and fewer isomers were present in the adult tissues. Those isomers that were present in infants and absent in the adult tissues consisted primarily of those having lower chlorine levels (Table 1).

2.4 Metabolic Studies. Metabolic studies were conducted in adult rhesus monkeys that had been given a single intragastric dose of a PCB containing multiple isomers (Aroclor 1248) and a single isomer (2,5,2',5'-tetrachlorobiphenyl). It was demonstrated that approximately 90% of the compound was absorbed from the gastrointestinal tract. Ten percent of the original dose was detected chromatographically in the urine and feces within 14 days with the greatest percentage being excreted between the second and eighth day. When similar studies were conducted with tritiated 2,5,2',5'-tetrachlorobiphenyl, approximately 85% of the radioactivity was recovered, primarily in the feces within 2 weeks, and majority of it was eliminated by 72 hours. An additional 10% was detected in the animal tissues. Of the PCB that remained in the animal, the largest percentage was present in the adipose tissue and secondly in organs having high fat content.

3. Discussion

When nonhuman primates were exposed to levels of PCBs similar to that experienced by the Japanese in the 1968 PCB outbreak, they developed signs and lesions similar to those recorded in human cases. Subcutaneous edema, particularly around the eyes and lips, and hyperemic conjunctivitis with excessive secretion of the Meibomian glands were consistently present. There were also follicular accentuations of the skin characterized by dilatation of the sebaceous ducts and development of keratin cysts. The severely affected patients and primates had a decrease in erythrocytes, reduced hemoglobin, and a neutrophilia. Although not documented in the exposed humans, the nausea and anorexia

they experienced was suggestive of a gastritis as was the case in the experimental animals. Liver hypertrophy, proliferation of the hepatic endoplasmic reticulum, and increased microsomal enzyme activity were apparent in both species. In addition, the persistence of these lesions for extended periods following the discontinuation of PCB exposure was recorded in the Japanese outbreak and has also been observed in experimentally exposed nonhuman primates.

The data and observations cited in this report clearly indicate that PCBs are toxic to primates over a wide dose range. Particularly significant is the appearance of lesions within less than 2 months in monkeys that were fed diets containing 2.5 and 5.0 ppm. Although the intake of PCBs by these animals was on a continuous basis and the likelihood of the general population consuming a diet containing this quantity of PCBs is small, it does point out that only small amounts of these compounds are required to produce toxicity in primates. In addition, since PCBs accumulate in tissues of exposed mammals, continuous exposure to even very minute amounts may eventually reach a level sufficient to cause toxic manifestations.

It is of interest that the toxicity of PCBs in infant and adult monkeys is markedly different. Levels of exposure that were fatal to adults produced no gross effects in one-month-old infants. It has been shown that infant monkeys have a poorly developed mixed function oxidase system (Allen and Chesney[13]).These observations are further substantiated by the chromatographic data obtained on the tissues of the two age groups of animals. Adult tissues contained lower levels and fewer isomers of PCBs than did the infant tissues, thus indicating more rapid metabolism or excretion of these compounds by older animals. These data suggest that PCB metabolites are responsible for the deleterious effects produced by PCBs in monkeys.

Unlike primates, infants of lower animals suffered much more severely from PCB exposure than did adults (McLaughlin et al. [14], Keplinger et al. [15], Dahlstrom [16], Hays and Risebrough [17]; Ringer et al. [18], DeLong et al. [19]). Clarification of these findings was recently obtained in rats by the use of liver enzyme inhibitors (SKF 525-A -- p-dimethylaminoethyldiphenylpropylactate and chloramphenicol) and inducers (phenobarbital). In these experiments, rats pretreated with enzyme inhibitors, which may parallel the enzymatic status of the infant liver,

MONS 042133

experienced heavy mortality while animals pretreated with enzyme inducers suffered no deaths. Thus it would appear that the metabolism of PCBs may be necessary for toxicity in monkeys while the reverse may be true in rats.

Many of the lesions that develop in PCB intoxicated primates may be directly related to tissue exposure to the PCBs while other lesions may be secondary. The loss of weight, decrease in serum protein and moderate anemia could be related to the reduced food intake that occurs in the animals with severe hyperplastic gastritis which develops as a result of the irritating effects of the PCBs on the gastric mucosa. The hypertrophic hyperactive livers that develop in these animals are a result of the stimulatory effects of these compounds on the hepatic endoplasmic reticulum. However, when the liver exposure to the PCBs is sufficiently great, degenerative changes develop particularly in the organelle containing the majority of PCBs, the endoplasmic reticulum. The skin lesions may also be directly related to localization of high levels of PCBs in their tissue. Keratinization of the sebaceous gland ducts and hair follicles following the irritating exposure to PCBs leads to formation of keratin cysts. In addition, edema and inflammation that develops around the effected glands and hair follicles may be a direct result of injurious effects on these tissues by the PCBs.

Many of the lesions that develop following PCB exposure may result secondarily from the increased metabolism of endogenous substances by the hyperactive hepatic endoplasmic reticulum. Following PCB exposure there is enhanced metabolism of steroid and steroid-like compounds. Vitamin A which is steroid-like compositionally is deficient in quail, rats (Bitman et al. [20]) and monkeys (Allen, unpublished observations) following PCB exposure. Since vitamin A deficiencies resulting from an increased rate of metabolic decomposition have been reported to produce gastric hyperplasia (Cramer [21]), gastric carcinoma (Fujimaki [22]), an follicular dermatitis (Mason [23]), it is not unlikely that a deficiency of this vitamin may be responsible at least in part for many of the lesions resulting from PCB intoxication.

MONS 042134

Acknowledgements

This research was supported by the University of Wisconsin Sea Grant and United States Public Health Service grants ES-00472 and RR-00167 from the National Institutes of Health. Primate Center Publication No. 13-037.

References

1. JENSEN, S., "Report of a new chemical hazard", New Scient., 32, 612 (1966).

2. KOLBYE, A.C., "Food exposures to polychlorinated biphenyls", Environ. Health Persp., 1, 85 (1972).

3. YOBS, A.R., "Levels of polychlorinated biphenyls in adipose tissue of the general population of the nation", Environ. Health Persp., 1, 79 (1972).

4. JONES, J.W., ALDEN, H.S., "An acneform dermatergosis", Arch. Dermatol. Syphilol., 33, 1022 (1936).

5. GOOD, C.K., PENSKY, N., "Halowax acne (cable rash); cutaneous eruptions in marine electricians due to certain chlorinated naphthalenes and diphenyls", Arch. Dermatol. Syphilol., 48, 251 (1943).

6. KURATSUNE, M., "An epidemiologic study on "Yusho" or chlorobiphenyl poisoning", Fukuoka Acta Medica, 60, 513 (1969).

7. KURATSUNE, M., YOSHIMURA, T., MATSUZAKA, J., YAMAGUCHI, A., "Epidemiologic study of Yusho, a poisoning caused by rice oil contaminated with a commercial brand of polychlorinated biphenyls", Environ. Health Persp., 1, 119 (1972).

8. ALLEN, J.R., NORBACK, D.H., "Polychlorinated biphenyl and triphenyl-induced gastric mucosal hyperplasia in primates", Science, 179, 498 (1973).

9. ALLEN, J.R., ABRAHAMSON, L.J., NORBACK, D.H., "Biological effects of polychlorinated biphenyls and triphenyls on the subhuman primate. Environ. Res., 6, 344 (1973).

10. ALLEN, J.R., CARSTENS, L.A., BARSOTTI, D.A., "Pathological changes in nonhuman primates exposed to low levels of polychlorinated biphenyls", Toxicol. Appl. Pharmacol., accepted (1974).

11. ALLEN, J.R., NORBACK, D.H., HSU, I.C., "Tissue modifications in monkeys as related to absorption, distribution and excretion of polychlorinated biphenyls", Arch. Environ. Contam. Toxicol., in press (1974).

12. ABRAHAMSON, L.J., ALLEN, J.R., "The biological response of infant nonhuman primates to a polychlorinated biphenyl", Environ. Health Persp., 2, 81 (1973).

13. ALLEN, J.R., CHESNEY, C.F., "Effect of age on the development of cor pulmonale in nonhuman primates following pyrrolizidine alkaloid intoxication", Exp. Molec. Path., 17, 220 (1972).

14. MCLAUGHLIN, J., MARLIAC, J.P., VERRETT, M.J., MUTCHLER, M.K., FITZHUGH, O.H., "The injection of chemicals into the yolk sac of fertile eggs prior to incubations as a toxicity test", Toxicol. Appl. Pharmacol., 5, 760 (1963).

15. KEPLINGER, M.L., FANCHER, O.E., CALANDRA, J.C., WHEELER, E.P., "Toxicological studies with polychlorinated biphenyls", Proceedings of NIEHS Polychlorinated Biphenyl Meeting, December 20-21 (1971).

16. DAHLSTROM, N., as quoted by TINKER, J., "The PCB study: seagulls aren't funny anymore", New Scient.Science J., 16 (1971).

17. HAYS, H., RISEBROUGH, R.W., In Natural History, as reported in "Controversy continues over PCBs", Chem. Eng. News 49, 32 (1971).

18. RINGER, R.K., AULERICH, R.J., ZABIK, M.,"Effect of dietary polychlorinated biphenyls on growth and reproduction in mink", Proc. Amer. Chem. Soc., 12, 149 (1972).

19. DELONG, R.L., GILMARTIN, W.G., SIMPSON, J.G., "Premature births in California sea lions: association with high organochlorine pollutant levels", Science, 181, 1168 (1973).

20. BITMAN, J., CECIL, H.S., HARRIS, S.J., "Biological effects of polychlorinated biphenyls in rats and quail", Environ. Health Persp., 1, 145 (1972).

21. CRAMER, W., "Papillomatosis in the forestomach of the rat and its bearing on the work of fibiger," Amer. J. Cancer, 31, 537 (1937).

22. FUJIMAKI, Y., "Formation of gastric carcinoma in albino rats fed on deficient diets", J. Cancer Res., 10, 469 (1926).

23. MASON, K.E., "Effects of vitamin A deficiency in human beings", In The Vitamins, W.H. Sebrel, Jr., R.H. Harris (eds.), Academic Press, New York, 1, 137 (1954).

TABLE 1. CHROMATOGRAPHIC DATA ON ADIPOSE TISSUE OBTAINED FROM RHESUS MONKEYS EXPOSED TO AROCLOR 1248[a]

Retention Time (Sec)	Standard	Mother[b]	Newborn Infant[c]	Adult[d]	Infant[e]
57	0.12	7.70		1.56	0.17
73	2.85				
82	4.07				14.04
102	18.45				
130	6.91				14.27
146	1.52	2.80			
156	1.30				
201	40.12	10.49		19.33	47.56
236	2.86	7.58			7.93
306	10.61	0.30	11.34	63.52	11.63
392	7.65	50.96	4.14	15.57	3.92
472	3.46	20.14	76.79		0.47
507	0.03		7.17		

[a] Monsanto Co. Inc., St. Louis, Missouri U.S.A.

[b] Tissue taken from female monkey at time of cesarian section, 8 months after discontinuation of PCB diet (total PCB intake - 300 g).

[c] Infant tissue taken immediately following cesarian delivery.

[d] Tissuos of adult monkey taken after 1 month on PCB diet (total PCB intake - 1 g).

[e] Tissue from infant monkey taken after 1 month on PCB diet (total PCB intake - 1 g).

FIGURE LEGENDS

FIGURE 1. Hepatocytes obtained from a liver biopsy of a monkey that had received 300 ppm PCB in the diet for 2 weeks. Note the abundant smooth endoplasmic reticulum (SER) and short segments of rough endoplasmic reticulum (RER). Normal appearing mitochondria (M) are randomly dispersed among the ER. Small lipid droplets (L) appear as round lucent areas in the cytoplasm. X 8,420.

FIGURE 2. Large dense packets of smooth endoplasmic reticulum (SER) prevail in the cytoplasm of hepatocytes obtained from monkey exposed to 300 ppm PCB in the diet for 2 months. Microsomes prepared from liver cells having similar morphological features were hypoactive enzymatically. Abundant lipid droplets prevail in the cytoplasm not occupied by ER. The mitochondria (M) appear normal. X 6,920.

FIGURE 3. The gastric mucosa of a normal adult rhesus monkey is depicted. Note the narrow band of muscularis mucosae(M) and underlying submucosa (SM) and smooth muscle (S) components of the stomach wall; hematoxylin and eosin stain. X 25.

FIGURE 4. Stomach of a monkey that had received 300 ppm PCB in the diet for 2 months. Note the hyperplastic gastric mucosa and presence of dilated glands. The majority of the submucosa has been replaced by glandular elements of the mucosal epithelium. Note the large cystic spaces that have resulted from the stasis of mucous in these glands (C); hematoxylin and eosin stain. X 25.



1



2

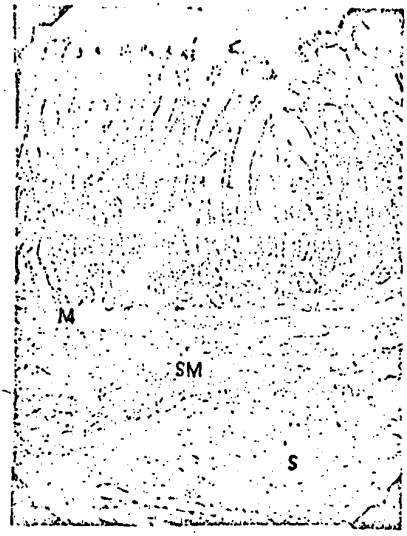

3



4

MONS 042140