ENVIRONMENTAL RESEARCH 6, 344–354 (1973)

Biological Effects of Polychlorinated Biphenyls and Triphenyls on the Subhuman Primate[1]

J. R. ALLEN, L. J. ABRAHAMSON, AND D. H. NORBACK

Department of Pathology, University of Wisconsin Medical School, and Regional Primate Research Center, University of Wisconsin, Madison, Wisconsin 53706

Received October 11, 1972

Rhesus monkeys were fed diets containing 300 ppm of a polychlorinated biphenyl (Aroclor 1246) or 5000 ppm of a polychlorinated triphenyl (Aroclor 5460) for 90 days. Both groups of animals developed alopecia, acneform lesions of the skin, subcutaneous edema, liver hypertrophy, and gastric mucosal hypertrophy and hyperplasia. Enlargement of the liver was associated with cell hypertrophy, proliferation of the endoplasmic reticulum, and an increased activity of certain microsomal enzymes.

The polychlorinated biphenyls and triphenyls have been known for nearly a century and used extensively during the past 40 years. These compounds can withstand extremely high temperatures without disintegrating, do not conduct electricity, and are resistant to fire. Such properties make them ideal for heat exchangers in electrical equipment, plasticizers in paints and adhesives, fire-resistant electrical and hydraulic fluids, protective coatings for wood, metal, and concrete, and vapor suppressants for insecticide formulations. Their chemical inertness also makes them highly resistant to degradation in the environment. Some of the injurious effects of these compounds on man have been known for many years. Acneform lesions of the skin have been reported on numerous occasions in persons associated with manufacture of chlorinated aromatic hydrocarbons (Herxheimer, 1899; Jones and Alden, 1936; Good and Pensky, 1943). Accidental contamination of edible products has led to serious outbreaks involving large numbers of people (Katsuki, 1969). Unfortunately, many of the symptoms and lesions that developed in these exposed persons have persisted for long periods after the removal of the toxic compounds from the diet.

The presently-reported research demonstrates the similarities in response of man and subhuman primates to the chlorinated biphenyls and triphenyls. In addition to acneform lesions and subcutaneous edema, the subhuman primates developed hypertrophy and hyperplasia of the gastric mucosa and penetration into the submucosa by the glandular epithelium. Liver hypertrophy was present in all of the experimental animals and was associated with a proliferation of the smooth endoplasmic reticulum and increased activity of certain microsomal enzymes.

[1] Supported in part by U. S. Public Health Service Grants ES-00472 and RR-00167 from the National Institutes of Health, and the University of Wisconsin Sea Grant Program.

Copyright © 1973 by Academic Press, Inc.
All rights of reproduction in any form reserved.

DSW 029226

STLCOPCB4013188

MATERIALS AND METHODS

Sixteen male, rhesus monkeys, ranging in age from 1½ to 2 years and having an average weight of 2.9 kg were placed in three groups. The control group consisted of four animals that were fed an unmodified diet.[2] A second group of six animals was fed a commercial diet to which 300 ppm of the chlorinated biphenyl (Aroclor 1248[3]) had been added. The third group of six animals received 5000 ppm of the chlorinated triphenyl (Aroclor 5460). Each animal was given access to 400 g of this diet daily. Throughout the course of the experiment, the physical status of the animals was evaluated daily and complete blood studies (WBC, Hb, Hct, differential white count, SGOT, SGPT, total protein, and serum electrophoresis) were done biweekly. Approximately 10 g of liver was removed from the animal during the 6th week (via laparotomy) and during the 12th week (at necropsy) for biochemical and microscopic evaluation. At the termination of the experiment during the 12th week, the animals were anesthetized, exsanguinated by severing the jugular vein, and tissues harvested immediately for microscopic and biochemical studies. For histologic evaluation, small sections of the tissues were placed in 10% neutral buffered formalin for 24 hr. They were subsequently dehydrated, embedded in paraffin, sectioned at 5 μm, and stained with hematoxylin and eosin. Selected sections of the stomach were also stained with mucicarmine (AFIP Manual, 1960). For the electron microscopic studies the hepatic tissue obtained at the time of liver biopsy or necropsy was cut into small cubes and fixed in osmium tetroxide, buffered with veronal acetate (Caulfield, 1957) for 1½ hr. They were subsequently dehydrated through a graded series of ethanol and embedded in an epoxy resin mixture (Mollenhauer, 1964). Sections of the tissues were cut on an ultramicrotome, placed on an uncoated copper grid, stained with uranyl acetate, and examined with an electron microscope.

Additional portions of the liver were homogenized at 0°C with 2 vol of .25 *M* sucrose with .010 *M* $MgCl_2$ and .015 *M* KCl. Levels of protein (Lowry *et al.*, 1951), DNA (Munro and Fleck, 1966) were determined on portions of the homogenate. Microsomes were isolated from the postmitochondrial supernatant fluid obtained by centrifugation at 9000*g* for 20 min, washed by homogenization with sucrose, and recentrifuged, resuspended in sucrose solution equal to 3 vol of liver and stored at −70°C. The activities of aromatic hydroxylase, nitroreductase, *N*-demethylase, esterase, and glucose-6-phosphatase, and concentrations of RNA, phospholipid, cholesterol, and protein were determined by methods previously reported (Norback and Allen, 1972).

RESULTS

Throughout the course of the experiment the animals ate the diet quite well. However, there was a gradual loss in the weight of all the experimental animals. In the chlorinated triphenyl (CT) group there was an average weight loss of 19% (11–26%) experienced in five of the six animals. The group of animals receiving chlorinated biphenyls (CB) had a weight loss of 26% (22–31%) in four

[2] Purina Monkey Chow, Ralston–Purina Company, St. Louis, MO.
[3] Monsanto Company, St. Louis, MO.

DSW 029227

STLCOPCB4013189

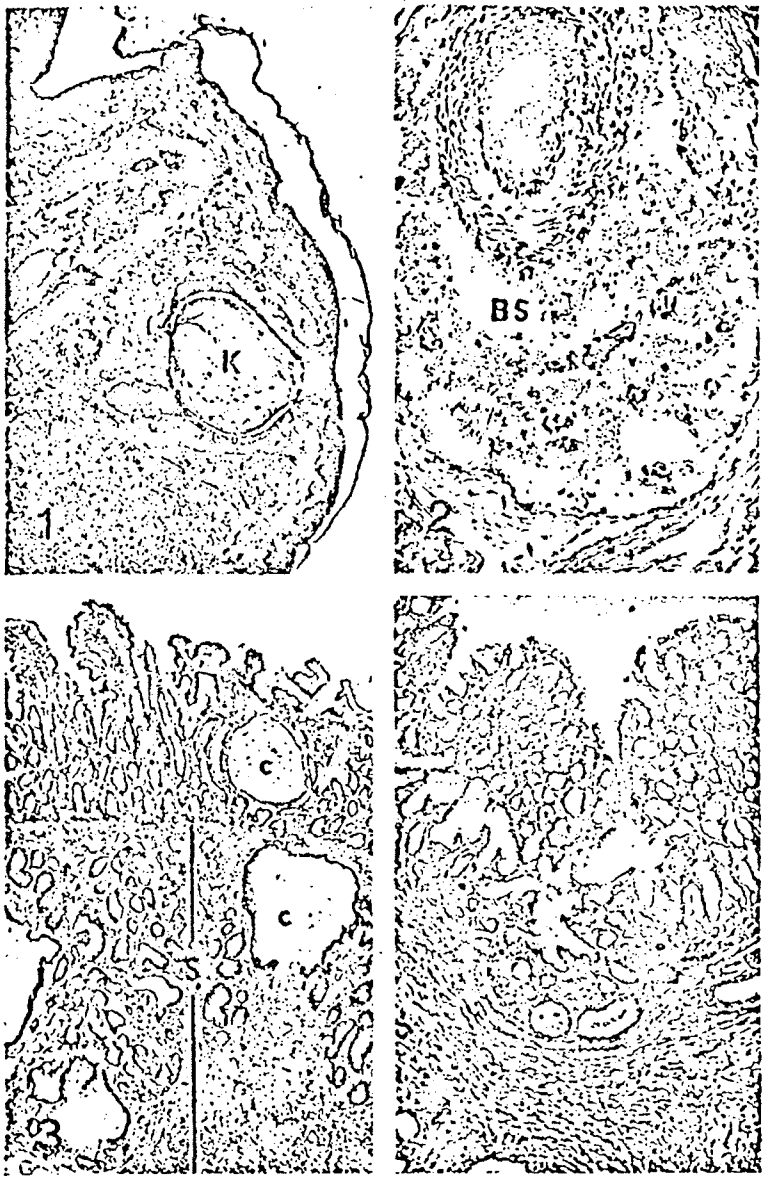

FIG. 1. Large keratin-filled cysts (K) develop in the skin, particularly on the face of monkeys fed CB and CT. Note the thick bands of connective tissue surrounding the follicles. Blood sinuses (→) are closely associated with many of the hair follicles. The surface epithelium is normal. The tissue is from the upper eyelid of a monkey given CB for 12 weeks. Hematoxylin and eosin; ×20.

FIG. 2. Blood sinuses (BS) that surrounded many of the hair follicles contained villus-like projections within the lumen. These appeared grossly as small focal hemorrhagic areas. Hematoxylin and eosin stain; ×140.

FIG. 3. Glandular epithelium was abundant within the submucosa of the stomach (—S—). Large epithelial-lined cysts (c) are present in the glandular elements on each side of the

DSW 029228

STLCOPCB4013190

TABLE 1
HEMATOLOGICAL CHANGES IN RATS PRODUCED BY POLYCHLORINATED BIPHENYLS AND TRIPHENYLS

Analysis	Aroclor 1248		Aroclor 5160	
	0 wk	12 wk	0 wk	12 wk
Hb (g/100 ml)	13.0 ± 1.0	10.6 ± .3	13.4 ± .7	11.8 ± .8
Hct. (%)	39 ± 2	32 ± 1	41 ± 2	33 ± 3
WBC ($\times 10^3$)	11.9 ± 2.6	17.7 ± 4.3	9.5 ± 3.7	10.4 ± 2.8
Neut. (%)	27 ± 5	73 ± 10	34 ± 5	61 ± 15
Lymph. (%)	69 ± 4	25 ± 8	64 ± 5	38 ± 16
SGOT (units)	47 ± 10	40 ± 11	45 ± 13	37 ± 7
SGPT (units)	43 ± 18	18 ± 8	27 ± 8	22 ± 5
BUN (mg/100 ml)	20.3 ± 5.1	22.7 ± 3.4	20.3 ± 5.1	19.7 ± 7.2
Protein (g/100 ml)	9.2 ± .3	5.7 ± .5	7.4 ± .2	6.3 ± .7
Albumin (%)	54.6 ± 3.5	43.5 ± 8.9	54.9 ± 2.8	46.0 ± 11.2

of the six animals. Rather constant weights were maintained in one of the CT-fed animals and two of the CB-fed animals. Within approximately 1 month, all of the CB-fed animals had lost considerable hair from their head, neck, and back regions. Their faces were puffy, the eyelids swollen, the lips edematous, and a purulent exudate was present around the eyes. Similar changes also occurred in the CT-fed animals at a somewhat slower rate.

Hematological changes in the animals developed gradually (Table 1). Over a period of 3 months there was a decrease in hemoglobin of approximately 2 g/100 ml and a decrease in hematocrit from approximately 40 to 33%. No major modifications in the total white cell count were noted. However, there was a gradual decrease in the number of lymphocytes and a concomitant increase in neutrophils. There was also a decrease in total serum protein of 1½–2 g/100 ml. A gradual shift in the albumin/globulin ratio of the serum protein also occurred.

The findings at necropsy included extensive alopecia that affected all of the experimental animals. There was also generalized subcutaneous edema that was particularly obvious about the face. Ascites was present in four of the six CB-fed animals and in three of the CT-fed animals. Pleural effusion was noted in two of the CT animals and one of the CB animals. Pericardial edema was obvious in seven of the 12 experimental animals (four from the CB group and three from the CT group). Marked hypertrophy of the mucosal lining and edema of the stomach wall was apparent in all of the experimental animals with the pyloric and fundic regions of the stomach being most severely affected. Hypertrophy of the liver was obvious in all animals with the livers from the CT-fed animals being 5.6% of the total body weight while those from the CB-fed animals were 4.5% of the body weight and the controls averaged 2.3% of the total body weight.

muscularis mucosae. Tissue from stomach of a monkey fed CT for 12 weeks. Hematoxylin and eosin stain; ×40.

FIG. 4. Glandular epithelium of the stomach penetrated the muscularis mucosae. Two portions of the muscularis mucosae (arrow) are separated by the epithelial ingrowth. Tissue from the stomach of a monkey fed CB for 12 weeks. Hematoxylin and eosin stain; ×40.

DSW 029229

STLCOPCB4013191

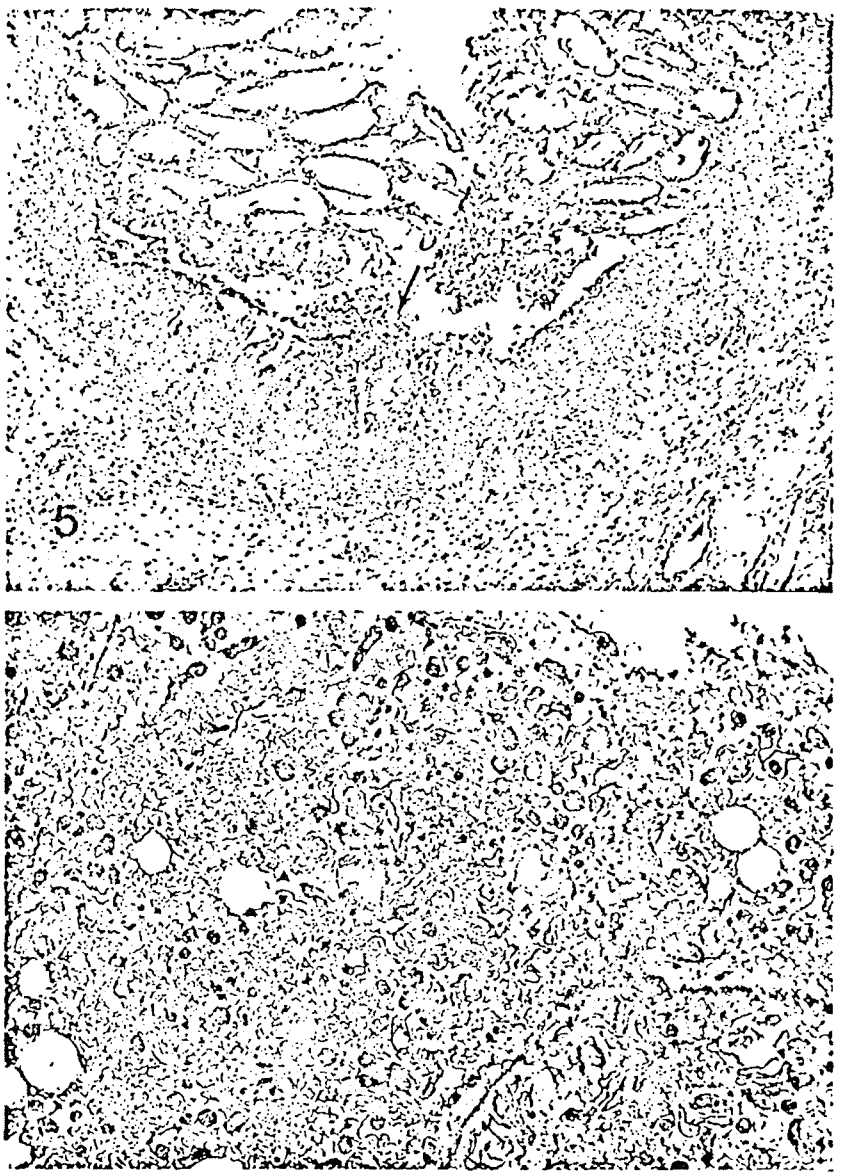

FIG. 5. Erosion of the gastric mucosa and necrosis of the underlying muscularis mucosae developed in the stomach wall. Acute inflammatory cells and necrotic debris prevail at the base of the ulcer (→). Tissue from stomach of monkey fed CB for 12 weeks. Hematoxylin and eosin stain; ×40.

FIG. 6. Hepatocytes of a monkey that had received CB in the diet for 6 weeks. Abundant smooth endoplasmic reticulum is present throughout the cytoplasm of these cells. All other organelles are normal. Uranyl acetate stain; ×3500.

DSW 029230

STLCOPCB4013192

Light microscopically, the major change in the skin of the affected animals was the development of large intrafollicular keratin cysts and epithelial hyperplasia of the hair follicles, particularly of the face (Fig. 1). Large, dilated blood sinuses surrounded the basalar portion of many hair follicles (Fig. 2). A moderate hypocellularity and edematous appearance of the bone marrow was a constant feature in these animals. This decrease in cellularity was not selective but involved all of the precursor cells.

There were major modifications in the morphological features of the stomach, particularly in the fundic and pyloric regions. In addition to the markedly thickened gastric mucosa, numerous large cystic areas filled with mucin (mucicarmine positive) and lined by epithelial cells were common throughout the mucosal lining (Fig. 3). Penetration of the muscularis mucosa into the underlying submucosa by the glandular epithelial cells was a constant feature of these affected stomachs (Figs. 3 and 4). Cystic areas similar to those present in the surface mucosa were much larger and more abundant in the submucosa. Occasionally these large cysts ruptured and an acute inflammatory reaction characterized by necrosis, edema and infiltration of neutrophils ensued. Ulceration of the gastric mucosa was prevalent in the affected stomachs (Fig. 5). These lesions developed after erosion of the mucosal epithelium or rupture of large mucinous cysts.

There was considerable variation in the morphological features of the affected gastric epithelium. The predominant cell type was of the surface-lining variety which contained round, basalar-positioned nuclei and abundant slightly acidophilic cytoplasm. In approximately one third of these cells there were large vacuoles that frequently comprised over one half of the cytoplasm. A villous surface was located along the apical border of these cells. The more cuboidal epithelial cells that lined the cystic spaces were quite similar to those of the surface epithelial cells. Other groups of cells, particularly in the submucosa, were decidedly hyperchromatic and contained large irregularly shaped nuclei.

The hypertrophic state of the liver was further clarified electron microscopically and biochemically. The liver biopsies taken at 6 weeks from the CT- and CB-fed animals showed a decided increase in the smooth endoplasmic reticulum (SER) of the hepatic cells (Fig. 6). In addition, there were occasional segments of the ER that formed elaborate concentric membrane arrays (Fig. 7). The latter frequently encircled lipid droplets, ER and mitochondria. There was a moderate increase in the lysosomes that contained numerous membrane fragments and lipid droplets. The other cytoplasmic organelles as well as the nucleus appeared normal. Kupffer cells invariably were filled with large lipid droplets. The latter had produced a displacement of the nuclear and cytoplasmic components of these cells. The hepatic tissue of the 12-week liver samples from both groups of animals were quite similar electron microscopically. A marked proliferation of the SER persisted; however, instead of the ER being distributed throughout the cytoplasm it was arranged in distinct packets of closely associated membranes (Fig. 8) which have been designated as hypertrophic, hypoactive SER (Hutterer *et al.*, 1968).

DSW 029231

STLCOPCB4013193

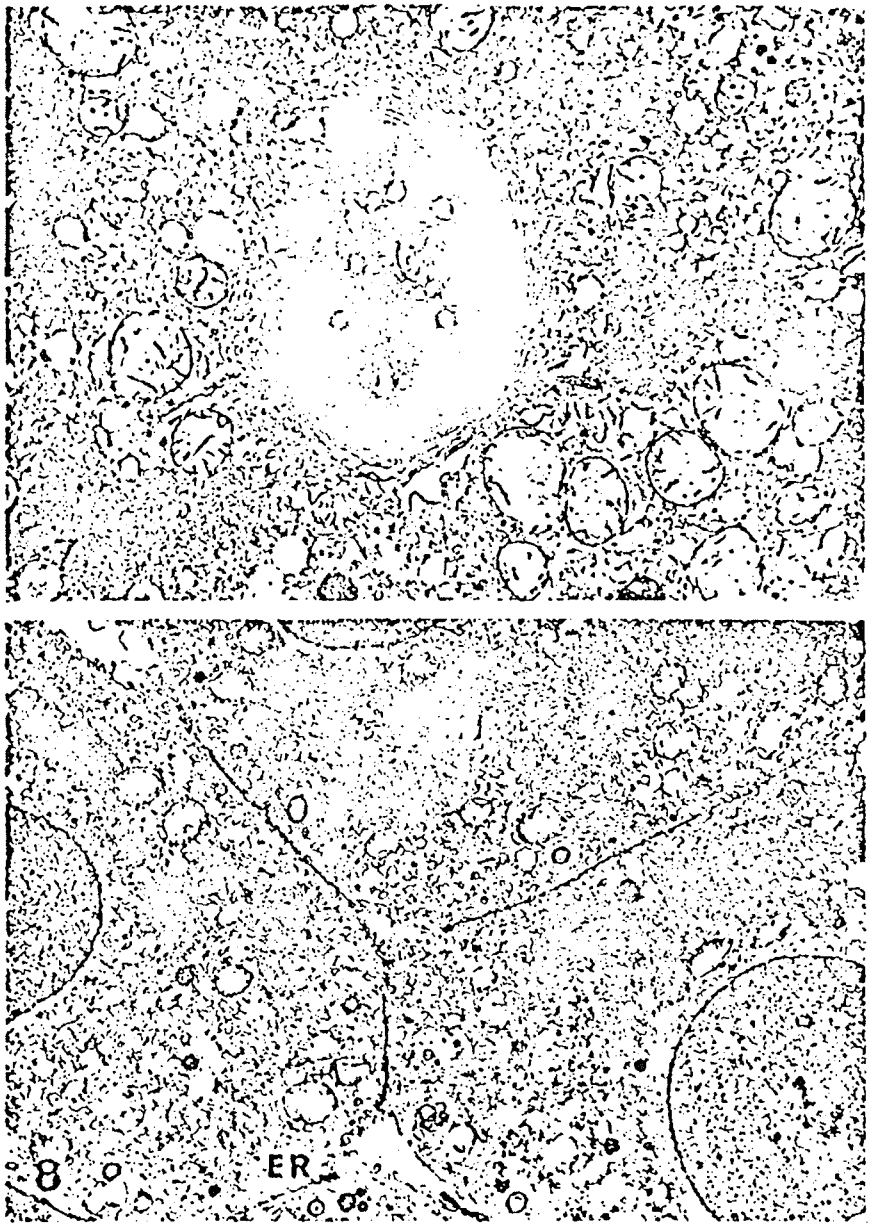

FIG. 7. Continuous with the proliferated endoplasmic reticulum are closely associated concentric arrays of membranes (arrow). These metabolically active membranes frequently encircled lipid droplets, mitochondria, and other cytoplasmic organelles. Uranyl acetate stain; ×10,000.

FIG. 8. A very fine network of smooth-surfaced membranes (SEM) present in the cytoplasm of hepatocytes from monkeys fed CB and CT for 12 weeks. Note the vesicular appearance of the remaining portions of the endoplasmic reticulum (ER). Contrast these membranes with the hypertrophic, normal-appearing smooth endoplasmic reticulum that is depicted in Fig. 6. Uranyl acetate stain; ×3300.

DSW 029232

STLCOPCB4013194

TABLE 2
HEPATIC MODIFICATIONS AFTER THE INGESTION OF POLYCHLORINATED BIPHENYLS AND TRIPHENYLS BY MONKEYS

Analysis	Control	Experimental	
		6 wk	12 wk
Total liver alterations			
DNA (mg/g liver)	3.18 ± .30	2.85 ± 0.29[a]	2.48 ± 0.17[a]
		2.42 ± 0.24[b]	2.25 ± 0.29[b]
RNA (mg/mg DNA)	1.61 ± .12	2.4 ± .1	2.3 ± .1
		2.2 ± .2	2.4 ± .3
Protein (mg/mg DNA)	89.4 ± 7.6	99.6 ± 2.0	119 ± 6
		127 ± 13	131 ± 19
Microsomal alterations			
Protein (mg/g liver)	25.7 ± 4.1	25.5 ± 7.8	23.6 ± 1.7
		25.4 ± 6.2	26.2 ± 4.4
RNA (μg)[c]	77.4 ± 21.2	81.7 ± 14.5	88.0 ± 8.2
		60.3 ± 17.8	80.2 ± 7.4
Phospholipid (μg)[c]	507 ± 41	398 ± 25	510 ± 41
		442 ± 147	534 ± 37
Cholesterol (μg)[c]	12.0 ± 2.1	11.8 ± 2.6	17.8 ± 6.1
		12.0 ± 4.7	16.5 ± 5.7
Glucose-6-phosphatase (μmole PO_4/15 min)[c]	2.57 ± .20	1.17 ± .12	0.95 ± .18
		0.80 ± .06	0.53 ± .17
Esterase (μmole p-nitrophenol/min)[c]	4.14 ± .44	1.65 ± .51	1.97 ± .29
		2.01 ± .77	2.14 ± .38
Aromatic hydroxylase (nmole p-aminophenol/30 min)[c]	31.3 ± 5.2	22.4 ± 4.4	14.1 ± 2.2
		8.5 ± 1.4	12.1 ± 5.2
N-demethylase (nmole formaldehyde/30 min)[c]	272 ± 67	313 ± 62	401 ± 87
		533 ± 266	528 ± 93
Nitroreductase (nmole p-aminobenzoate/hr)[c]	64.4 ± 12.7	15.2 ± 3.5	20.6 ± 9.8
		21.1 ± 3.7	17.1 ± 3.6

[a] Aroclor 1248.
[b] Aroclor 5460.
[c] Per milligram microsomal protein.

Biochemically, the decrease in the DNA content per gram liver of both experimental groups reflected the hypertrophic cells that were observed microscopically (Table 2). The increases in protein and RNA of the homogenates are compatible with the proliferated state of the ER. Levels of microsomal protein per gram liver and RNA, cholesterol, and phospholipids per mg protein displayed no marked alteration. A decrease in specific activities of esterase, aniline hydroxylase, nitroreductase, and glucose-6-phosphatase per mg of microsomal protein was apparent at 6 weeks and persisted throughout the period of examination. However, the *N*-demethylase activity was increased at both examination periods.

DISCUSSION

Many of the responses of the subhuman primates after ingestion of chlorinated biphenyls are similar to those reported for man. Clinically, both species develop subcutaneous edema, particularly around the eyes and lips, and hyperemic conjunctivitis with excessive secretion of the Meibomian glands (Goto and Higuchi,

DSW 029233

STLCOPCB4013195

1969). Although follicular accentuation of the skin characterized by cystic dilatation and formation of keratin cysts prevailed in both species, hyperpigmentation of the skin was peculiar only to man (Kuratsune, 1969). Marked alopecia, a constant observation in monkeys, was not a common occurrence in affected humans. Severely affected subjects of both species had a decrease in erythrocytes, reduced levels of hemoglobin, and leukocytosis developed. No appreciable changes were recorded in liver-function tests such as SGOT, SGPT, or serum bilirubin, and microscopically, the cells were hypertrophied with proliferated ER and areas of necrosis absent. Blood urea nitrogen levels were also normal. There was a slight decrease in serum protein and a shift in the A/G ratio of the severely affected monkeys; however, such was not the case in the human subjects.

Since none of the human patients died during the acute phase of the disease, only on biopsy material has a thorough microscopic study been conducted. Here again, these findings were quite similar to those noted in monkeys exposed to the polychlorinated biphenyls. Cystic dilatation, hyperkeratosis, and hyperplasia of the hair follicles were constant features of the skin in both species. However, increased melanin pigment in the basal epidermis was observed only in man.

Hypertrophy of the liver associated primarily with the proliferation of the SER occurred in both species (Hirayama *et al.*, 1969). In monkeys, these hepatic changes were related to an increased enzymatic activity of the liver. An increase in liver microsomal enzyme activity is associated with the proliferated SER and is also likely to occur in the livers of humans exposed to the PCBs, although specific data along these lines are not presently available. In subhuman primates the proliferative, hyperactive status of the liver gradually undergoes changes characteristic of degeneration. It remains to be established whether similar changes occur in the liver of man.

There were distinct modifications in the gastric mucosa of the affected monkeys. Hypertrophy and hyperplasia of the mucosal epithelium and an invasion of the underlying mucosa by these glandular elements occurred in all the experimental monkeys. Whether similar changes occur in the gastric mucosa of man is yet to be determined. However, humans consuming a diet containing the PCBs experienced nausea and vomiting which may suggest gastric irritation (Kuratsune, 1969). The above-mentioned changes in the gastric mucosa are likely due to chronic irritation produced by the PCBs. Whether this irritation is sufficient to cause neoplastic transformation in the affected epithelial cells remains to be established in more lengthy studies.

A majority of the experiments relating to the effects of CB on the liver microsomal enzymes have been done in rodents. Increases in nitroreductase, *N*-demethylase, esterase, glucose-6-phosphatase, and aniline hydroxylase occurred within 24 hr in the liver microsomes of rats fed CB (Norback and Allen, 1970, 1972; Allen and Abrahamson, 1972). However, the magnitude of these changes diminished as the experiments progressed. Fujita *et al.* (1971) also reported an increase in cytochrome P-450, and specific activities of *O*-dealkylase, *N*-demethylase, and aniline hydroxylase within 3 days after the administration of CB. In monkeys, liver hypertrophy with increased enzyme activities occurs; however, increase in specific activities is not as great and is subject to more individual

DSW 029234

STLCOPCB4013196

variation. In both species, reduced specific activities were recorded for certain hepatic enzymes; however, increased activity by all enzymes occurred when the data were extrapolated to represent activity per total liver.

In the hepatocytes of rats, large concentric membrane arrays (CMA) predominated. Associated with these structures were changes in the phospholipid–cholesterol ratios in the hepatic microsomes of rodents. Only isolated CMA were present in the monkey hepatocytes and the composition of the proliferated membranes was not altered. The presence of the CMA may represent species variation in the way these compounds are metabolized, stored, and excreted (Norback and Allen, 1972).

Rats that are maintained on CB diets tend to develop degenerative changes in the liver less rapidly than monkeys fed similar doses of the CB. Alopecia, acne, hyperkeratosis of the hair follicles, anasarca, conjunctival changes, hyperplastic gastritis with ulceration, and degenerative modifications of the hepatic endoplasmic reticulum were inapparent or present to a lesser degree in the rat than in the monkey.

In this discussion comparative data on the effects of the CB and CT in man, monkey and rat are presented. Changes that occur in man and subhuman primate are quite similar. The acute toxic effects of the compounds are well documented; however, there is a paucity of information on their long-term effects. Those data available on humans exposed to the chlorinated phenyl compounds would indicate that the symptoms and lesions persist for a long period after exposure. A more complete understanding of the toxicological and possible carcinogenic effects of the CBs will be forthcoming when data from chronic experiments conducted on appropriate experimental subjects are available.

ACKNOWLEDGMENTS

The authors express their appreciation to J. J. Scheffler, L. A. Carstens, and S. M. Edgerton for their technical assistance. Wisconsin Regional Primate Research Center Publication No. 13-003.

REFERENCES

Allen, J. R., and Abrahamson, L. (1972). Enzymatic changes in the liver of rats fed chlorinated biphenyls, triphenyls and DDT. Proceedings of the American Chemical Society, Division of Water, Air and Waste Chemistry 12, 97–111.

Armed Forces Institute of Pathology. (1960). "Manual of Histologic and Special Staining Techniques," 2nd ed. McGraw-Hill, New York.

Caulfield, J. B. (1957). Effects of varying the vehicle for OsO_4 in tissue fixation. *J. Biophys. Biochem. Cytol.* 3, 827–830.

Fujita, S., Tsuji, H., Kato, K., Saeki, S., and Tsukamoto, H. (1971). Effects of biphenyl chlorides on rat liver microsomes. *Fukuoka Acta Med.* 62, 30–34.

Good, C. K., and Pensky, N. (1943). Halowax acne (cable rash): Cutaneous eruption in marine electricians due to certain chlorinated naphthalenes and diphenyls. *Arch. Dermatol. Syphilol.* 48, 251–257.

Goto, M., and Higuchi, K. (1969). The symptomatology of Yusho (chlorobiphenyls poisoning). *Fukuoka Acta Med.* 60, 409.

Herxheimer, K. (1899). Chloracne. *Muenchener Med. Wochenschr.* 47, 278.

Hirayama, C., Iriisa, T., and Yamamoto, T. (1969). Fine structural changes of the liver in a patient with chlorobiphenyls intoxication. *Fukuoka Acta Med.* 60, 455–461.

DSW 029235

STLCOPCB4013197

HUTTERER, F., SCHAFFNER, F., KLION, F. M., AND POPPER, H. (1968). Hypertrophic, hypoactive smooth endoplasmic reticulum: A sensitive indicator of hepatotoxicity exemplified by dieldrin. *Science* 161, 1017–1019.

JONES, J. W., AND ALDEN, H. S. (1936). An acneform dermatergosis. *Arch. Dermatol. Syphilol.* 33, 1022–1034.

KATSUKI, S. (1969). Foreward, Report on the study group for "Yusho" (chlorobiphenyls poisoning). *Fukuoka Acta Med.* 60, 403.

KURATSUNE, M. (1969). An epidemiologic study on "Yusho" or chlorobiphenyls poisoning. *Fukuoka Acta Med.* 60, 513.

LOWRY, O. H., ROSEBROUGH, N. J., FARR, A. L., AND RANDALL, R. J. (1951). Protein measurement with the Folin phenol reagent. *J. Biol. Chem.* 193, 265–275.

MOLLENHAUER, H. H. (1964). Plastic embedding mixtures for use in electron microscopy. *Stain Technol.* 39, 111–114.

MUNRO, H. M., AND FLECK, A. (1966). The determination of nucleic acids. *In* "Methods of Biochemical Analysis" (D. Glick, ed.), Vol. 14, pp. 113–176. Interscience, New York.

NORBACK, D. H., AND ALLEN, J. R. (1970). Enzymatic and morphologic alterations of hepatic endoplasmic reticulum induced by chlorinated aromatic hydrocarbons. *Fed. Proc.* 29, 816.

NORBACK, D. H., AND ALLEN, J. R. (1972). Chlorinated triphenyl induced extensions of the hepatic endoplasmic reticulum. *Proc. Soc. Exp. Biol. Med.* 139, 1127–1131.

DSW 029236

STLCOPCB4013198