PLAINTIFF'S EXHIBIT

GP-2222

1974

AKRON, NY

GYPSUM-

ASBESTOS TESTING

MC CARGAR, Francis Employed: Georgia-Pacific

Frank McCargar 121-07 [illegible]

[illegible] 59 [illegible]

[illegible]

Alleges cough and shortness of breath and significant pipe and cigarette smoking for many years.

OCT 14 1974

[illegible]

[illegible]

Work on Ready Mix in the Jt Syst Dept for app. 3 or 4 yrs.

VENTILATION STUDY

FVC: 2000 cc
FEV1: 45%
FEV2: 65%
FEV3: 80%
FEF 25%-75%: 0.6 L/sec
M.V.V. 55 L/min

Marked evidence of both restrictive and and airway obstructive disease. Certainly compatible with any subjective complaint, although examinee indicates no disability.

[illegible]: 3843 #3843

Marked fibrosis of both roots and all lobes. Multiple small calcific densities noted in each root and in the right lower lobe. Fibrosis in the peripheral lung fields are characterized by the rounded and irregular densities generally distributed. Compatible with a diagnosis of pneumoconiosis but certainly not characteristic of exposure to fibrous silicates. There does

...SEE OTHER SIDE....

[illegible]: Examinee has well-advanced pulmonary emphysema by ventilation testing and by chest x-ray has significant pulmonary fibrosis.

...SEE OTHER SIDE...

[illegible]

[illegible]: 9/30/74

MLA/kl

Marvin L. [illegible]

SGP 0007727

CHEST X-RAY CONTINUED: not appear to be any pleural involvement. Trachea is in the midline. The diaphragms are reasonably smooth, present some minimal blunting and in the lateral projection are quite flat. The heart shadow does exhibit some minimal widening in the region of the thoracic aorta. The bony cage presents some emphysematous contour and in the lateral projection some increased areas of radiobility behind the sternum and behind the heart.

COMMENT: CONTINUED: It is not possible to exclude exposure to fibrous sillicates but this chest x-ray does not impress the examiner as being one of that class. I would suspect that this man may well have had prior occupational exposure and this will be investigated on the occasion of the re-examination next year. It should be noted that although there are marked changes by x-ray and ventilation study, the examinee does not allege any particular degree of disability.

OCT - 8 1974

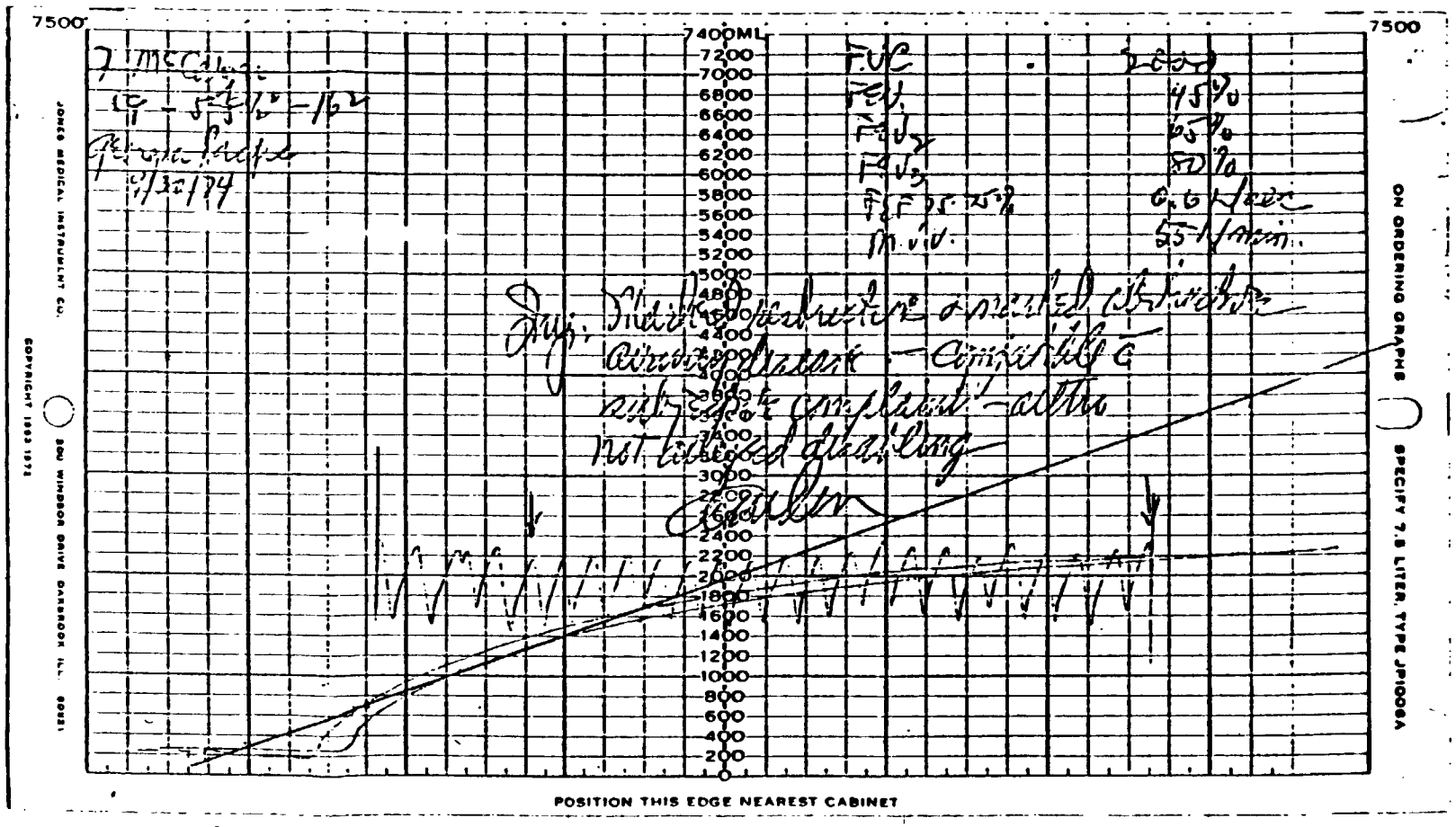
7500
7400ML
7200
7000
6800
6600
6400
6200
6000
5800
5600
5400
5200
5000
4800
4600
4400
4200
4000
3800
3600
3400
3200
3000
2800
2600
2400
2200
2000
1800
1600
1400
1200
1000
800
600
400
200
0
FVC
FEV1
FEV2
FEV3
FEF 25-75%
M.V.V.
45%
65%
80%
0.6 L/sec
55 L/min.
JONES MEDICAL INSTRUMENT CO.
ON ORDERING GRAPHS
SPECIFY 7.5 LITER, TYPE JP1006A
POSITION THIS EDGE NEAREST CABINET
COPYRIGHT 1963 1972

Walter Beglers 114-16-0653

13418 [illegible] Rd 52

Akron Ohio

[illegible]

[illegible]		✓
[illegible]		✓
[illegible]		✓
[illegible]		✓

no complaints -

no definite restrictions -

[illegible]

5. [illegible] Nil

cigars/ /day

pipe /month

cigarettes

pks/day /yrs.

[illegible]

[illegible]

	YES	NO
6. [illegible]		✓
7. TUBERCULOSIS		✓
8. [illegible]		✓
9. CHRONIC BRONCHITIS		
10. HEART DISEASE	✓	
11. HIGH BLOOD PRESSURE		

✓ Heart attack 3 years ago no Rx

[illegible]

Tracker 2 years (Jt Syst Dept)

VENTILATION STUDY

FVC: 4200 cc

FEV1: 70%

FEV2: 85%

FEV3: 95%

FEF 25%-75%: 2L/sec.

M.V.V. 80 L/min.

[illegible]

Evidence of mild airway obstructive change probably not disabling.

[illegible] 4008

Chest x-ray in multiple projections indicates normal root areas and peripheral lung fields. Trachea is in the midline. Heart shadow normal in size, position and configuration; though the diaphragms appear normal in the PA projection lateral projection does demonstrate distinct flattening with moderate accumulation of radiolucency in retrosternal area. Impression mild, nondisabling emphysema.

COMMENT: No subjective complaint. Mild ventilatory impairment. Chest x-ray suggests some emphysematous change.

[illegible]

DATE: 10/8/74

[signature]

SGP 0007730

ON ORDERING GRAPHS SPECIFY 7.5 LITER TYPE JMICORA
7500
7400ML
7200
7000
6800
6600
6400
6200
6000
5800
5600
5400
5200
5000
4800
4600
4400
4200
4000
3800
3600
3400
3200
3000
2800
2600
2400
2200
2000
1800
1600
1400
1200
1000
800
600
400
200
0
POSITION THIS EDGE NEAREST
JONES MEDICAL INSTRUMENT CO
700 WINDSOR DRIVE OAKBROOK ILL 60521
COPYRIGHT 1963 1972
7500

NAME: [illegible] SOC. SEC.

[illegible]: Georgia-Pacific [illegible]: 587

[illegible]: INDICATE

1. COUGH	yes	
2. CHEST PAIN		no
3. SHORT OF BREATH	yes	
4. EXPECTORATION		no
BLOODY		

AMOUNT/24 HRS.
1 tsp.
1 tbsp.
1 cup
1 cup

5. DO YOU SMOKE? yes
cigars/ /day
pipe /month
cigarettes
2 pks/day 35 /yrs.
IF NO - [illegible]

Alleges cough and shortness of breath.

Also, note smoking history.

DO YOU [illegible] HAVE YOU EVER HAD? IF YES - [illegible]

	YES	NO
6. PNEUMONIA		✓
7. TUBERCULOSIS		✓
8. ASTHMA		✓
9. CHRONIC BRONCHITIS	✓	
10. HEART DISEASE		✓
11. HIGH BLOOD PRESSURE		

OCCUPATIONAL [illegible]: [illegible] HOW LONG [illegible]

WORK: Worked in Jt. Syst. for 3 yrs. on Ready Emp. 39 yrs at Geo. Pac.

VENTILATION STUDY

FVC: 2800 cc
FEV_1: 62%
FEV_2: 78%
FEV_3: 85%

FEF 25%-75%: 0.8 L/sec

M.V.V. 90 L/min

[illegible]

Evidence of moderate restrictive and moderate airway obstructive disease.

[illegible] OF CHEST FILM [illegible]: 3838 #3838

The root areas are mildly prominent. There is noted to be some mild increase in radiability in both uppers. The horizontal fissure is slightly depressed upon the right. The lateral projection indicates moderate flattenning of both leaves of the diaphragm. Trachea is in the midline. There are proliferative changes over the dorsal spine. The heart shadow is normal.

COMMENT: Moderate evidence of pulmonary emphysema. Not particularly disabling.

[illegible]

DATE: 9/30/74

MLA/kl

Marvin L. Amdur, M. D.

SGP 0007732

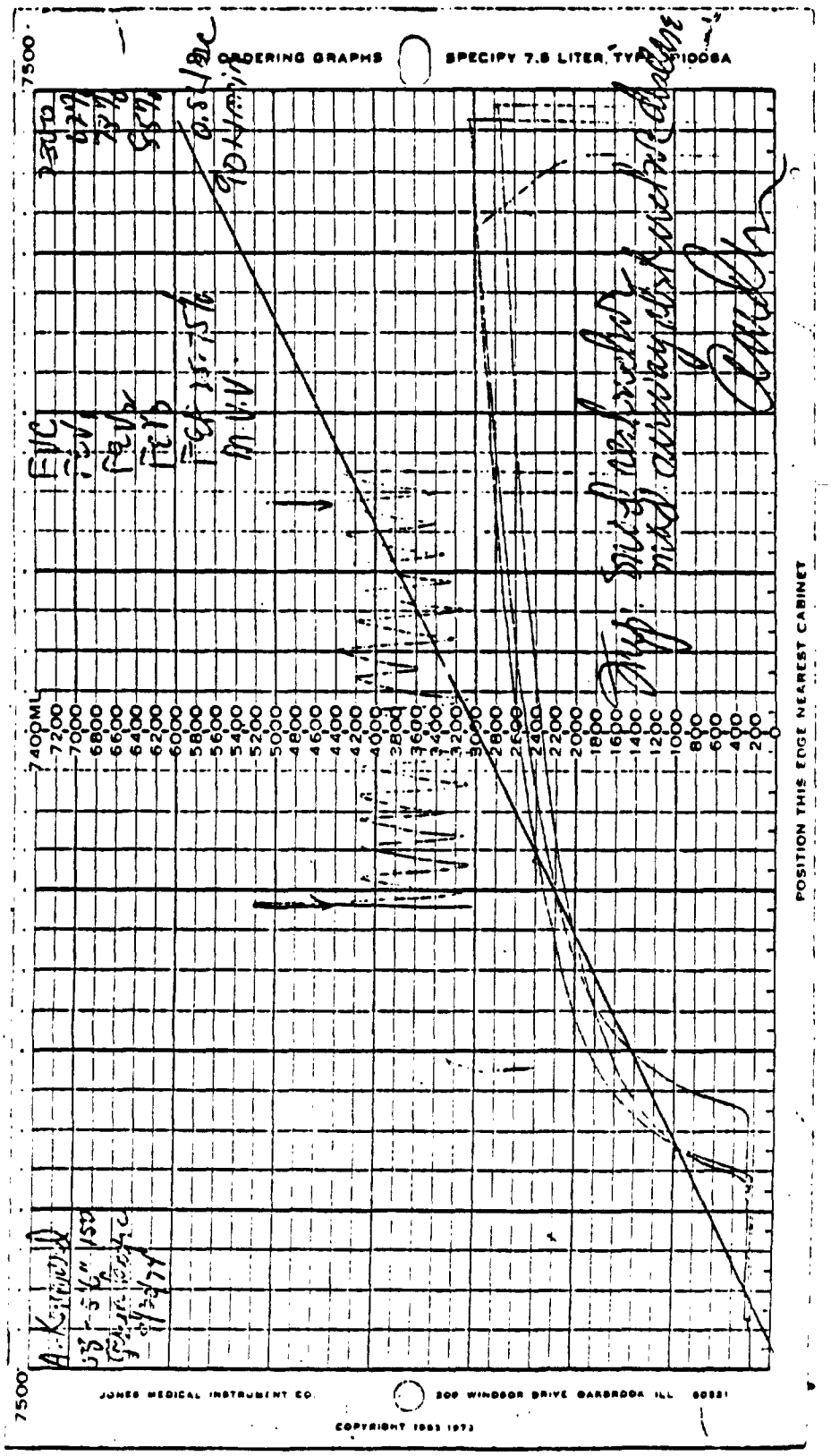
ORDERING GRAPHS
SPECIFY 7.5 LITER TYPE 1006A
7500
7400ML
POSITION THIS EDGE NEAREST CABINET
JONES MEDICAL INSTRUMENT CO.
300 WINDSOR DRIVE OAKBROOK ILL 60521
COPYRIGHT 1963 1973

SGP 0007733

[illegible]

NAME: Joseph John [illegible] DATE: 05-12-77

[illegible]: 138 [illegible] Building [illegible] 50 ✓

[illegible]

has cough & cold now -

[illegible]: INDICATE

1. COUGH
2. CHEST PAIN ✓
3. SHORT OF BREATH ✓
4. EXPECTORATION ✓
   BLOOD ✓
   AMOUNT/24 HRS.
   1 tsp.
   1 tbsp.
   ¼ cup
   ½ cup
5. DO YOU SMOKE? ✓
   cigars/ /day
   pipe /month
   cigarettes 1½ /day
   [illegible]

[illegible]

	YES	NO
6. PNEUMONIA		
7. TUBERCULOSIS		✓
8. ASTHMA		✓
9. CHRONIC BRONCHITIS		✓
10. HEART DISEASE		✓
11. HIGH BLOOD PRESSURE		✓

OCCUPATIONAL HISTORY: [illegible]

NOW: Yardman now 2 wk - Trucker 2½ yrs at Joint System

VENTILATION STUDY

FVC: 4200 cc
FEV1: 65%
FEV2: 82%
FEV3: 95%
FEF 25%-75%: 1.5 L/sec
M.V.V. 100 L/min

[illegible]

Mild airway obstructive change.

[illegible] OF CHEST FILM NUMBER: 4004

Mild prominence of the root areas, some increase in markings in both lower lobes. Heart shadow is normal. Bony cage exhibits some emphysematous configuration with some evidence of increased radiability behind the sternum. Impression minimal emphysema.

COMMENT: Absence subjective complaint. Ventilation studies indicate mild defect. Chest x-ray confirms minimal evidence of emphysema probably not disabling.

[illegible]

DATE: 10/5/74 [illegible]

SGP 0007734

ON ORDERING GRAPHS SPECIFY 7.5 LITER. TYPE JPIDDBA
7500
7400ML
7200
7000
6800
6600
6400
6200
6000
5800
5600
5400
5200
5000
4800
4600
4400
4200
4000
3800
3600
3400
3200
3000
2800
2600
2400
2200
2000
1800
1600
1400
1200
1000
800
600
400
200
0
POSITION THIS EDGE NEARGST CABINET
JONES MEDICAL INSTRUMENT CO.
200 WINDSOR DRIVE OAKBROOK ILL 60521
COPYRIGHT 1963 1972
7500

SGP 0007735

RIBBECK, Charles Employed: GEORGIA-PACIFIC

NAME Charles F Ribbeck Soc. Sec. # 118-05-54

ADDRESS AKRON RFD-1 Colgan Road 61 MXF

COPY

[illegible]

1. [illegible] yes
2. [illegible] no
3. [illegible] yes
4. [illegible] no
5. [illegible] yes
6. [illegible] 1 pack
7. [illegible] 3 D [illegible]
8. 1/3 [illegible] 45 yrs

under care
Dr Lengner for emphysema
past two years
also diabetic 1/80 42 U daily
also taking digitalis &
diuretic for cardiac
complaint.

[illegible]

1. [illegible]		✓
2. [illegible]		✓
3. [illegible]		✓
4. [illegible]		✓
5. [illegible]	✓	

[illegible] Worked in Jt-Syst Dept for 2 yrs.
26 yrs for Geo. Pac.

[illegible]

FVC:	1700cc
FEV1:	60%
FEV2:	78%
FEV3:	90%
[illegible]	0.5L/sec
[illegible]	50L/min

There is gross evidence of restrictive parenchymal disease and evidence of of substantial airway obstructive disease.

RECEIVED
OCT 14 1974
Bestwall Gypsum Co.
Akron, N.Y.

[illegible] 3890 #3890

Moderate prominence of both root areas. Some general increase in bronchovascular markings throughout all lobes. Horizontal fissure is noted in the usual position on the right. Some increased radiobility in both bases. The lateral projection indicates mild enlargement of the cardiac shadow posteriorly. Some increase in radiobility behind the sternum. There is but minimal flattening of the diaphragms in the lateral

...SEE REVERSE...

[illegible]: Examinee has a clinical diagnosis of emphysema and is evidently being treated for this by his personal physician. It may well

CONT'D ON REVERSE...

[illegible]: 10-2-74

MLA/kl
Atach.

Marvin L. Amdur, M. D.

CHEST X-RAY #3890 - Cont'd: projection. Heart shadow is otherwise not abnormal. The bony cage is normal.

COMMENT - Cont'd: be that his pulmonary emphysema is not particularly disabling but his associated cardiac difficulties are. There is nothing in the chest x-ray which would indicate that he has an occupational fibrosis. Certainly nothing to suggest that any fibrous silicate (asbestos) is causally related to his present complaint. See attached blood gas studies. Examinee should be under continued medical surveillance.

ATTACHED BLOOD GAS REPORT THOUGH INDICATING A MILD LOWERING OF ARTERIAL OXYGEN TENSION ACTUALLY IS NOT PARTICULARLY ABNORMAL FOR EXAMINEE'S AGE. MILD COMPENSATORY ALKALOSIS IS A NATURAL CONCOMITTANT OF EVIDENT MILD HYPERVENTILATION.
OVERALL IMPRESSION I STHAT OF MILD PERMANENT DISABILITY DUE TO EMPHYSEMA - ETIOLOGY OTHERWISE NOT DETERMINED

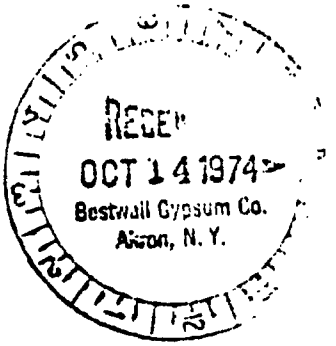

SGP 0007738

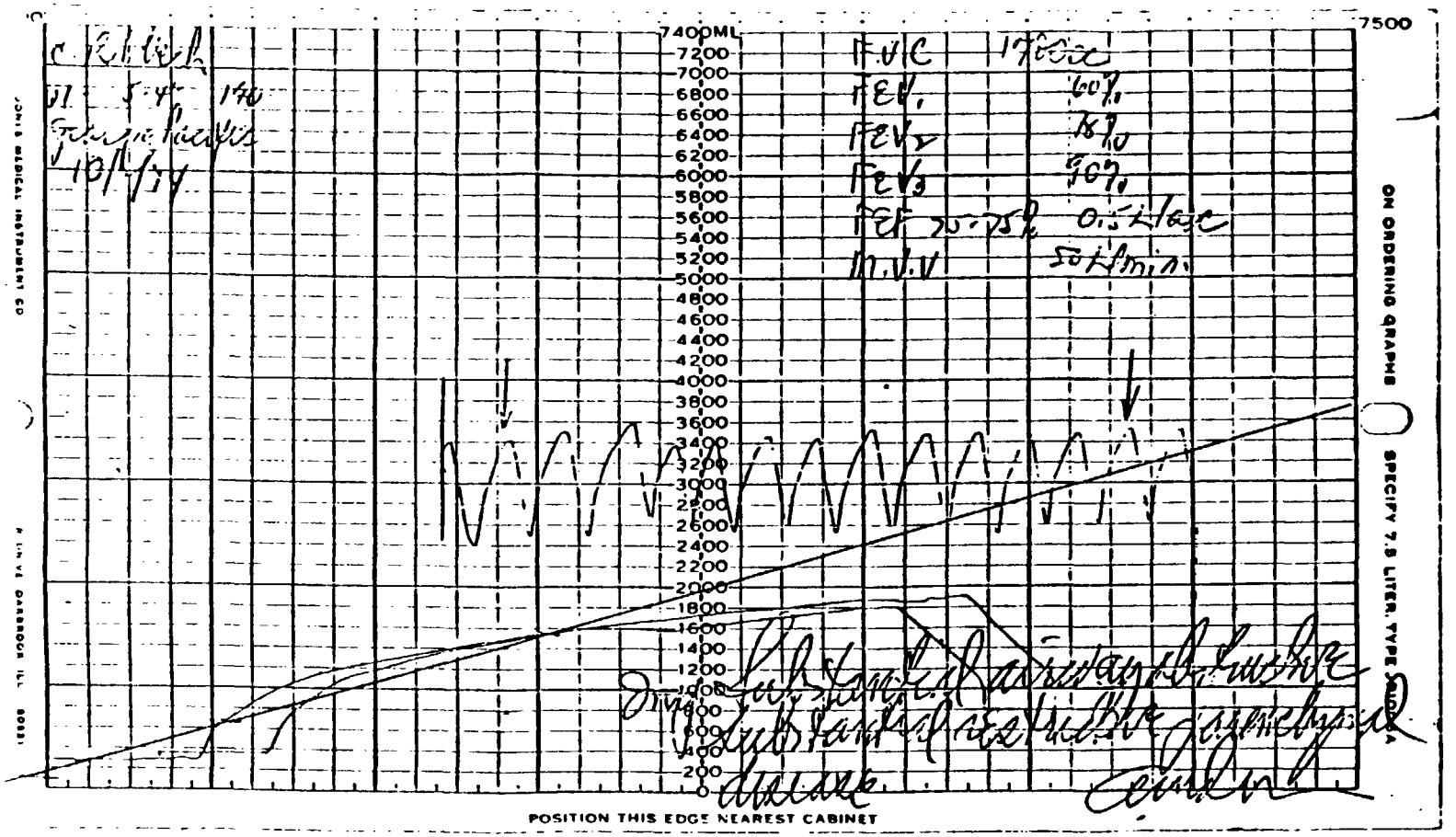
7400ML
7500
FVC 1760cc
FEV. 60%
FEV1 87%
FEV3 90%
FEF 25-75% 0.5 Liter
M.V.V 50 L/min.
POSITION THIS EDGE NEAREST CABINET


OCT 14 1974

KENMORE MERCY HOSPITAL

PULMONARY FUNCTION LABORATORY

COPY

PATIENT Rubbeck Charles

DATE 10 [illegible] 74

ROOM # CP

TIME 2 PM

DOCTOR Amber

O_2 THERAPY

SOURCE OF BLOOD Arterial

ACID - BASE STUDY(Astrup Method)

		Normal (arterial)		Actual
1.	PH	7.40	±0.03	7.44
2.	PCO_2	40 mm Hg	± 4	44 mmHg
3.	STD BIC RB	24 meq/l	± 2	25 meq/l
4.	BASE EXCESS	0 meq/l	± 2.5	+5 meq/l
5.	BUFFER BASE	46 meq/l	± 5	53 meq/l

OXYGEN TENSION

Normal (Arterial)	Actu
PO_2----80-100mm Hg	40 mm

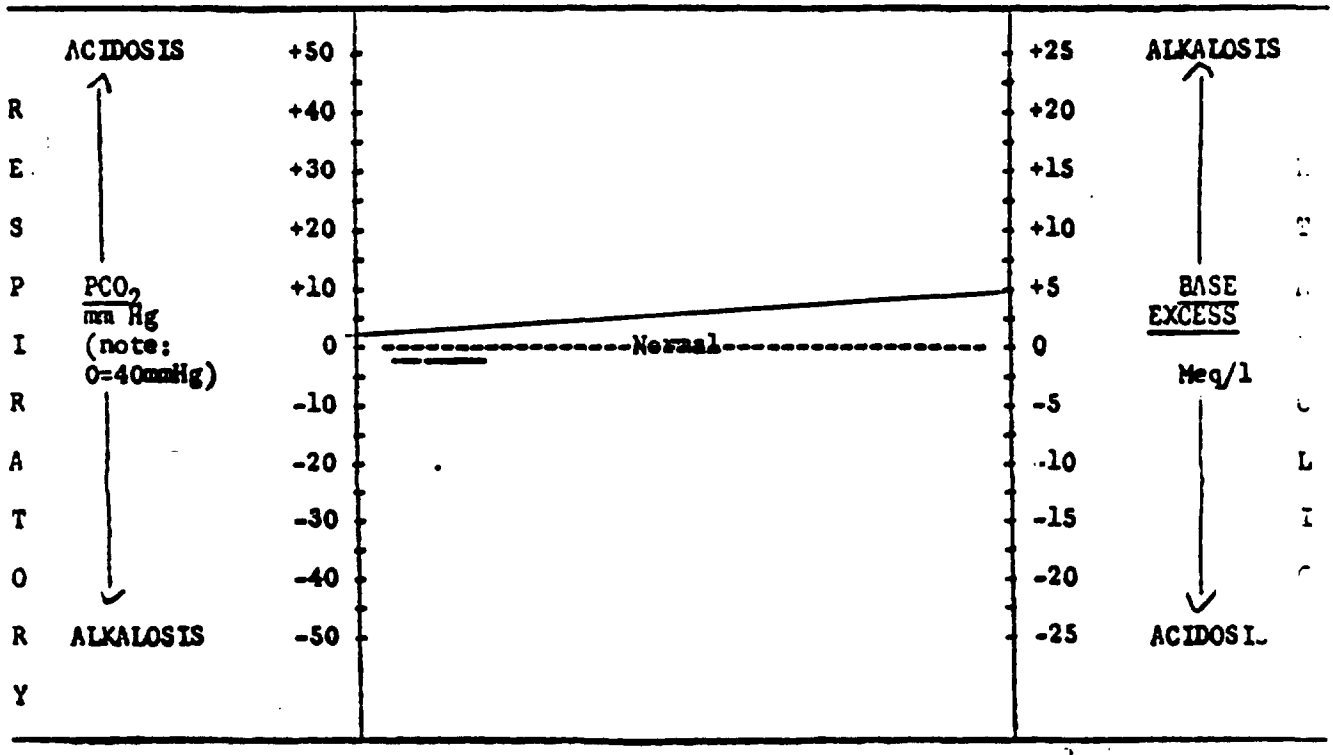

TECHNICIAN [illegible]

Carol Lingel

RECE OCT 14 1974 Bestwall Gypsum Co. Akron, N.Y.

F.Beerel, M.D.

SGP 0007739

L. RIBBECK 115-16-4477
15 2 SW.10 RD. 48 X
AKRON, N.Y.

Examinee has no subjective complaints whatsoever and medical history is noted to be negative.

JOINT SYSTEM MOONRAKER
1 1/2 YEARS

Values are low suggesting mild to moderate restrictive and some evidence of obstructive airway disease. Entire response is probably a reflection of inadequate effort in energy dependent test.

4006

Mild prominence of the root areas. Peripheral lung fields are generally not remarkable. The lateral view likewise demonstrates no significant evidence of disease.

History and chest x-ray are satisfactory. Ventilation studies would suggest some defect, referred for blood gas studies. (See Attached)

10/5/54

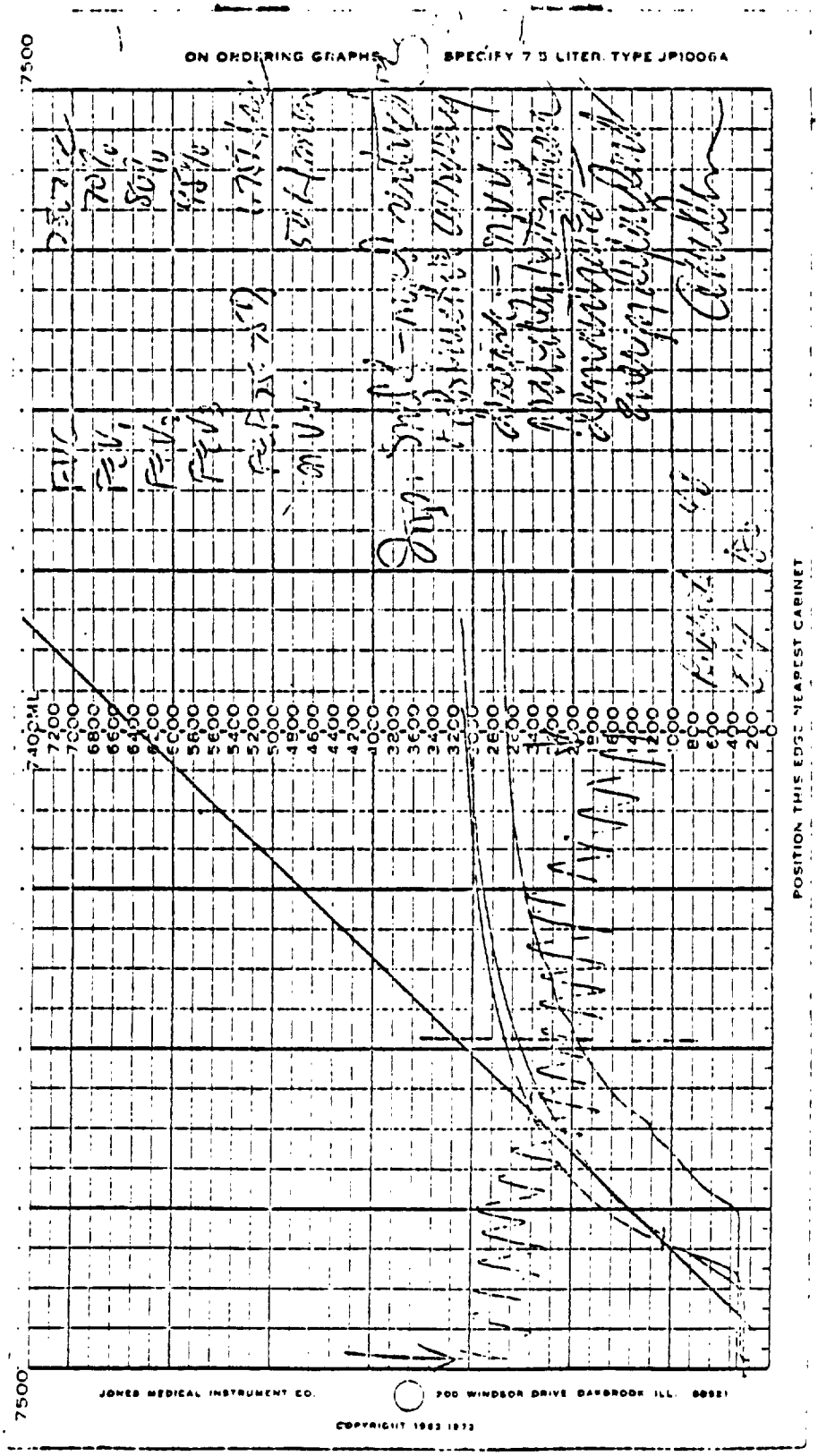
ON ORDERING GRAPHS SPECIFY 7.5 LITER TYPE JP1000A
7500
7400 ML
7200
7000
6800
6600
6400
6200
6000
5800
5600
5400
5200
5000
4800
4600
4400
4200
4000
3800
3600
3400
3200
3000
2800
2600
2400
2200
2000
1800
1600
1400
1200
1000
800
600
400
200
0
POSITION THIS EDGE NEAREST CABINET
7500
JONES MEDICAL INSTRUMENT CO.
200 WINDSOR DRIVE DARBROOK ILL. 60521
COPYRIGHT 1963 1973

SGP 0007741

PATIENT [illegible] Lawrence DOCTOR Amdur / Strader

ROOM # 0?

KENMORE MERCY HOSPITAL
PULMONARY FUNCTION LABORATORY
ACTUAL VALUES

NORMAL ARTERIAL VALUES		#1	#2	#3	#4	#5	#6
Day		10-8-74					
Time		NOON					
Source		ART					
A. Oxygen Tension PO_2 80 - 100 mm Hg		75					
Oxygen Therapy ____							
B. Acid Base Study (Astrup) PH	7.40 ± 0.03	7.41					
PCO_2	40 ± 4 mmHg	32					
Std HCO_3	24 + 2meq/L	21.5					
Base Exc.	0 ± 2.5meq/L	-3					
Buffer Base	46 ± 5meq/L	47					

FINDINGS OF A MILD RESPIRATORY ALKALOSIS IS COMPATIBLE WITH MILD PULMONARY DISABILITY BUT WITH ADEQAUTE COMPENSATION BY VIRTUE OF INCREASED RESPIRATORY RATE. PROBABLY REQUIRES NO TREATMENT - PLEASE ADVISE EXAMINEE

Amdur

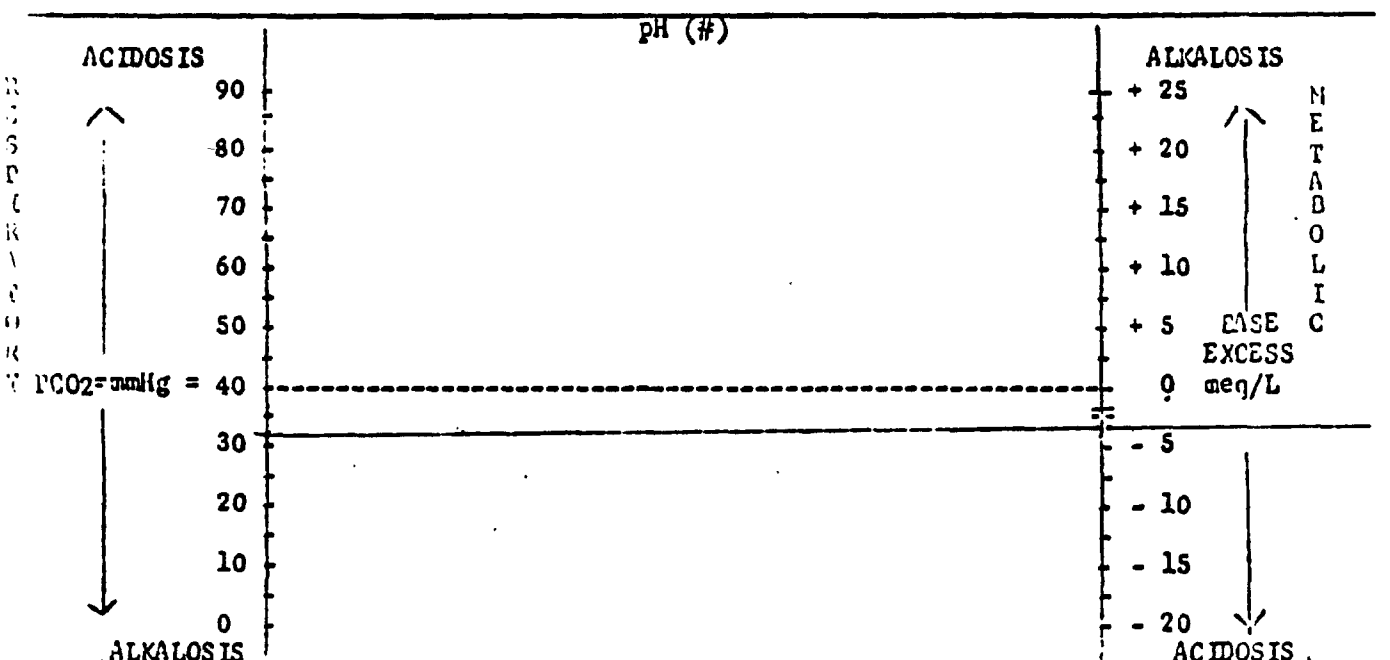

DATE 10/8/74 INTERPRETATION: Mild respiratory alkalosis

SGP 0007742

COPY

Leslie Quackenbush : 38 119 25-0540
RED 2
Middleport, NY

Stopped Smoking
Ingrs ago - Prev. 1½ pk/day
Has had Steroid Rx for
asthma - none post ten
years

10-25-63

Dr. Hans Lowenstein
Middleport, NY

work 20 years parker Stacker

VENTILATION STUDY

FVC:	4000cc
FEV1:	78%
FEV2:	90%
FEV3:	100%
FEF 25%-75%:	2.25 L/sec
M.V.V.	110 L/min

Quite satisfactory. No evidence of either obstructive airway disease or restrictive parenchymal disease.

3839 #3839

Moderate prominence of both root areas. Some general increase in broncho-vascular markings into both lower lobes. No evidence of specific parenchymal disease. No evidence of pleural disease. Heart shadow is normal in size and position. There appears to be some peculiar expansion superiorly but this may be sternal shadow. It certainly is not a reflection of lung pathology.

History of asthma with steroid treatment noted. No evidence of any disability at this time directed to the chest. Ventilation studies are quite satisfactory.

9/30/74
MLA/kl

Marvin L. Amdur, M. D.

SGP 0007743

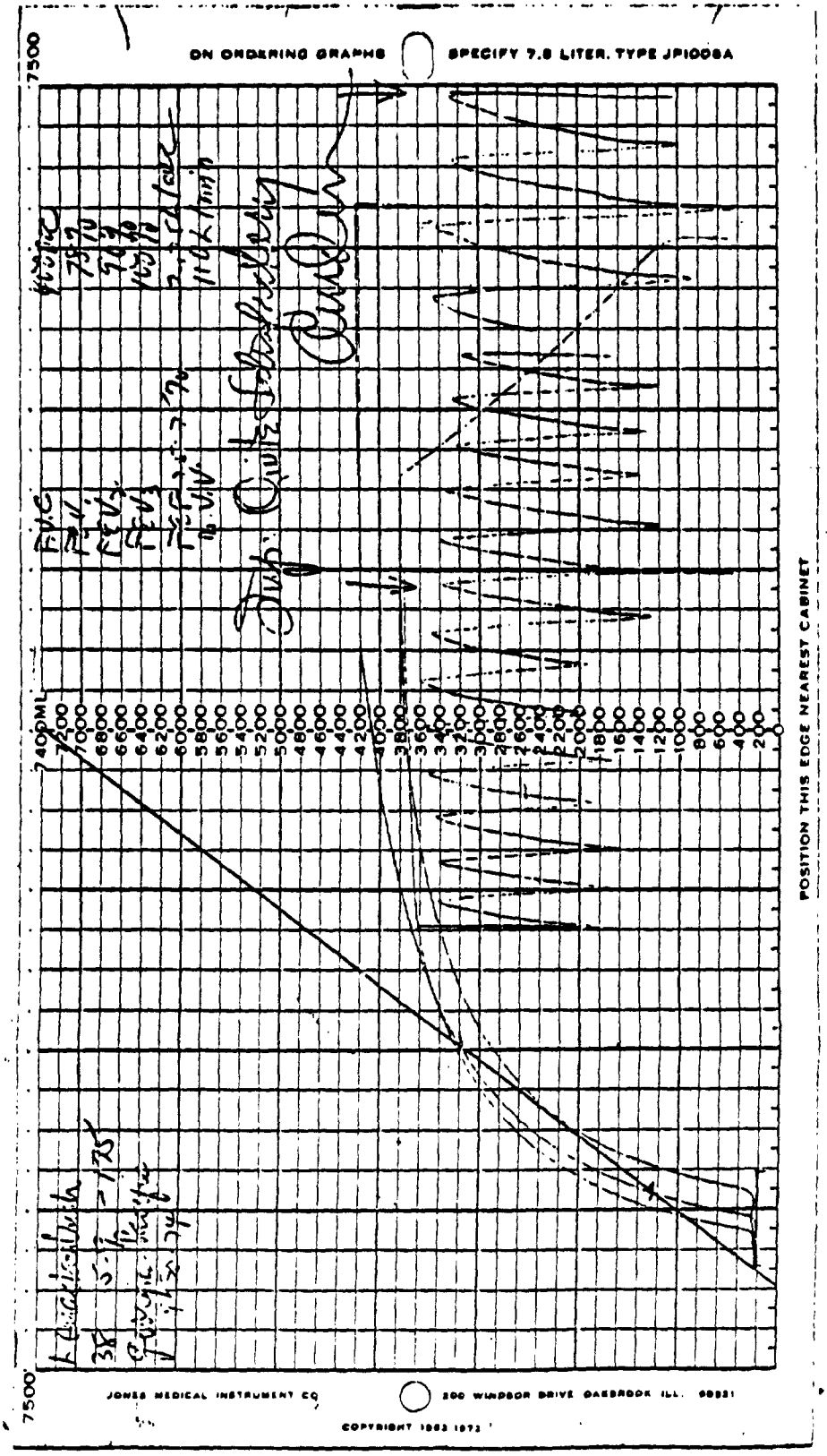
ON ORDERING GRAPHS SPECIFY 7.8 LITER, TYPE JP1008A
7500
7400ML
7200
7000
6800
6600
6400
6200
6000
5800
5600
5400
5200
5000
4800
4600
4400
4200
4000
3800
3600
3400
3200
3000
2800
2600
2400
2200
2000
1800
1600
1400
1200
1000
800
600
400
200
0
7500
POSITION THIS EDGE NEAREST CABINET
JONES MEDICAL INSTRUMENT CO
200 WINDSOR DRIVE OAKBROOK ILL. 60521
COPYRIGHT 1963 1972

SGP 0007744

GEORGIA - PACIFIC

[illegible] LAVERNE D LIEB [illegible] 062-[illegible]
[illegible]: 13875 Bloomingdale Rd. AGE: 54 M/F
AKRON N.Y. 14001

INQUIRY: INDICATE YES/NO

1. COUGH		
2. CHEST PAIN		No
3. SHORT OF BREATH		No
4. EXPECTORATION		No
BLOODY		No

AMOUNT/24 HRS.
1 tsp.
1 tbsp.
1 cup
1 cup

5. DO YOU SMOKE? No
cigars/ /day
pipe /month
cigarettes
pks/day / /yrs.
IF NO - HOW LONG

NO SUBJECTIVE COMPLAINT.

DO YOU NOW HAVE OR HAVE YOU EVER HAD?

	YES	NO
6. PNEUMONIA		No
7. TUBERCULOSIS		No
8. ASTHMA		No
9. CHRONIC BRONCHITIS	YES	
10. HEART DISEASE		No
11. HIGH BLOOD PRESSURE		

IF YES - DESCRIBE
Every so often get wheezing spells

OCCUPATIONAL HISTORY: WHAT DO YOU DO AND HOW LONG HAVE YOU WORK
Truck Driver 11 months in Joint System

REC'D OCT 29 1974 Bestwall Gypsum Co. Akron, N.Y.

VENTILATION STUDY

FVC: 2600 cc
FEV_1: 80 %
FEV_2: 100 %
FEV_3: 100 %
FEF 25%-75%: 1.8 L/sec
H.V.V. 60 L/min

INTERPRETATION

Moderate restriction - both as to total volume and ability to ventilate maximally suggests some defect but probably this is directed more to the examinee's obesity than it is to any evident pulmonary difficulty.

X-RAY OF CHEST FILM NUMBER: 4274 #4274

Mild promimence of the root areas. Minimal increase in broncho-vascular markings throughout all lobes but no evidence of any specific parenchymatous disease. Heart shadow and bony cage are normal. Narrow configuration of the chest indicating failure to fully inflate suggests the effect of obesity.

COMMENT: General health status seems satisfactory with regard to chest. I suspect that obesity may be responsible for any subjective complaint.

BUFFALO INDUSTRIAL MEDICAL CENTER

DATE: 10/23/74

Maurice [illegible]

SGP 0007745

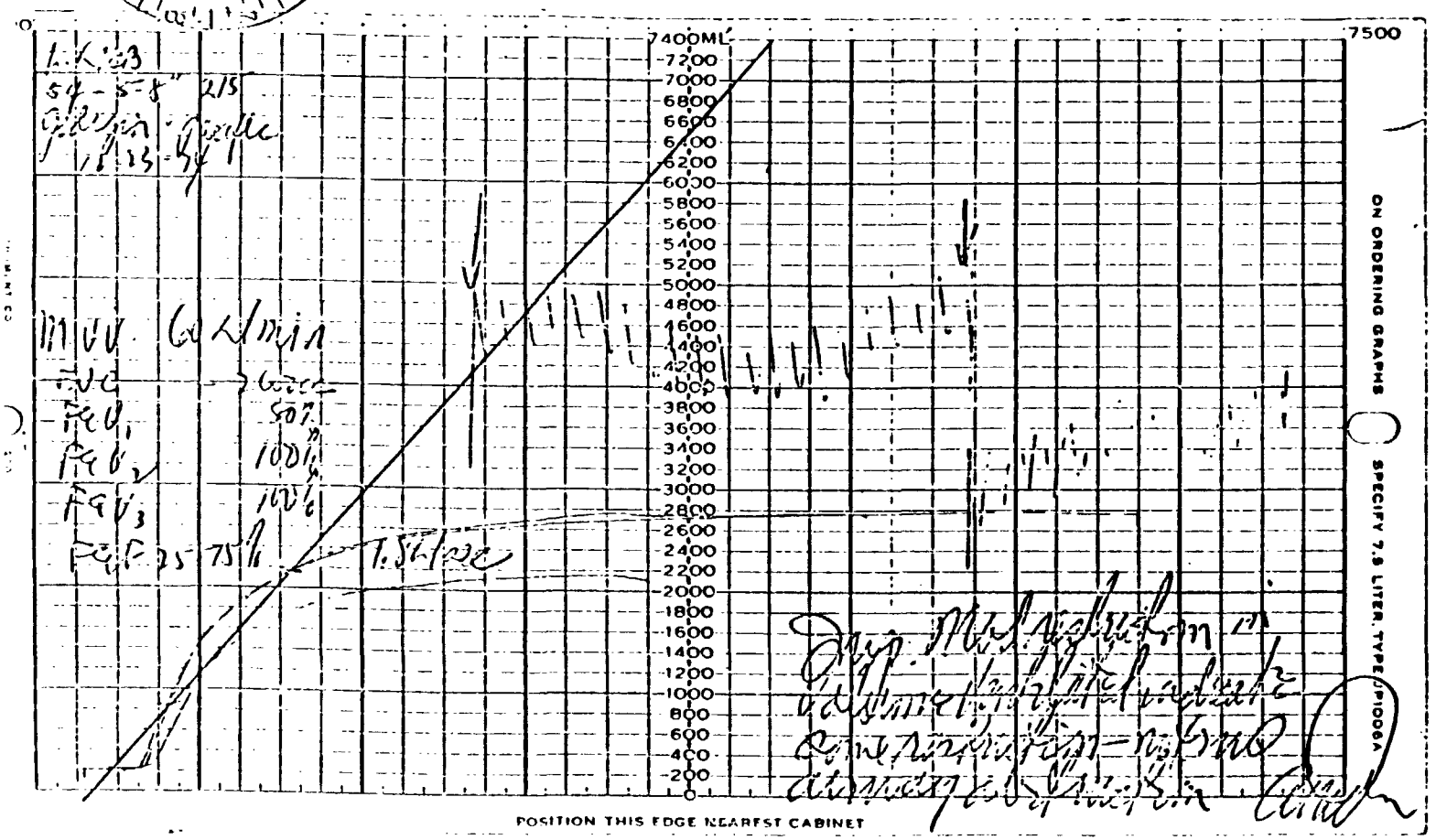
7400ML
7500
ON ORDERING GRAPHS SPECIFY 7.8 LITER TYPE P1000A
POSITION THIS EDGE NEAREST CABINET

SGP 0007746

JOHN G DARMSTEDTER 084-24-46
24 ALBERT CT 43 ✓
DEPEW, NY 14043

[illegible]: INDICATE [illegible]

1. COUGH		✓
2. CHEST PAIN		✓
3. SHORT OF BREATH		✓
4. EXPECTORATION		
BLOODY		✓

AMOUNT/24 HRS.
1 tsp.
1 tbsp.
1 cup
1 cup

5. DO YOU SMOKE? ✓
cigars/ /day
pipe /month
cigarettes
1 pk/day 20 yrs.
[illegible]

Satisfactory Inquiry

[illegible] YOU HAVE OR HAVE YOU [illegible]

	YES	NO
6. PNEUMONIA	✓	
7. TUBERCULOSIS		✓
8. ASTHMA		✓
9. CHRONIC BRONCHITIS		✓
10. HEART DISEASE		✓
11. HIGH BLOOD PRESSURE		✓

IN 1953 IN ARMY

OCCUPATIONAL HISTORY: WHAT DO YOU DO AND HOW LONG HAVE YOU WORK

QUALITY CONTROL SUPT 15 YRS

VENTILATION STUDY

FVC: 5600 cc
FEV_1: 75%
FEV_2: 88%
FEV_3: 100%
FEF 25%-75%: 3 L/sec
M.V.V. 128 L/min

[illegible]

Satisfactory.

[illegible] OF CHEST FILM NUMBER: 3971

Mild prominence of the root areas, some general increase in bronchovascular markings throughout all lobes but no evidence of specific parenchymatous disease. Trachea is in the midline. Diaphragms are smooth and sulci are clear. Heart shadow, bony cage are normal.

Impression: Chest x-ray satisfactory and compatible with examinee's age.
Ventilation studies satisfactory. Chest x-ray likewise satisfactory.
[illegible]: Impression: Overall status is good.

[illegible]

DATE: 10/7/94

[signature]

SGP 0007747

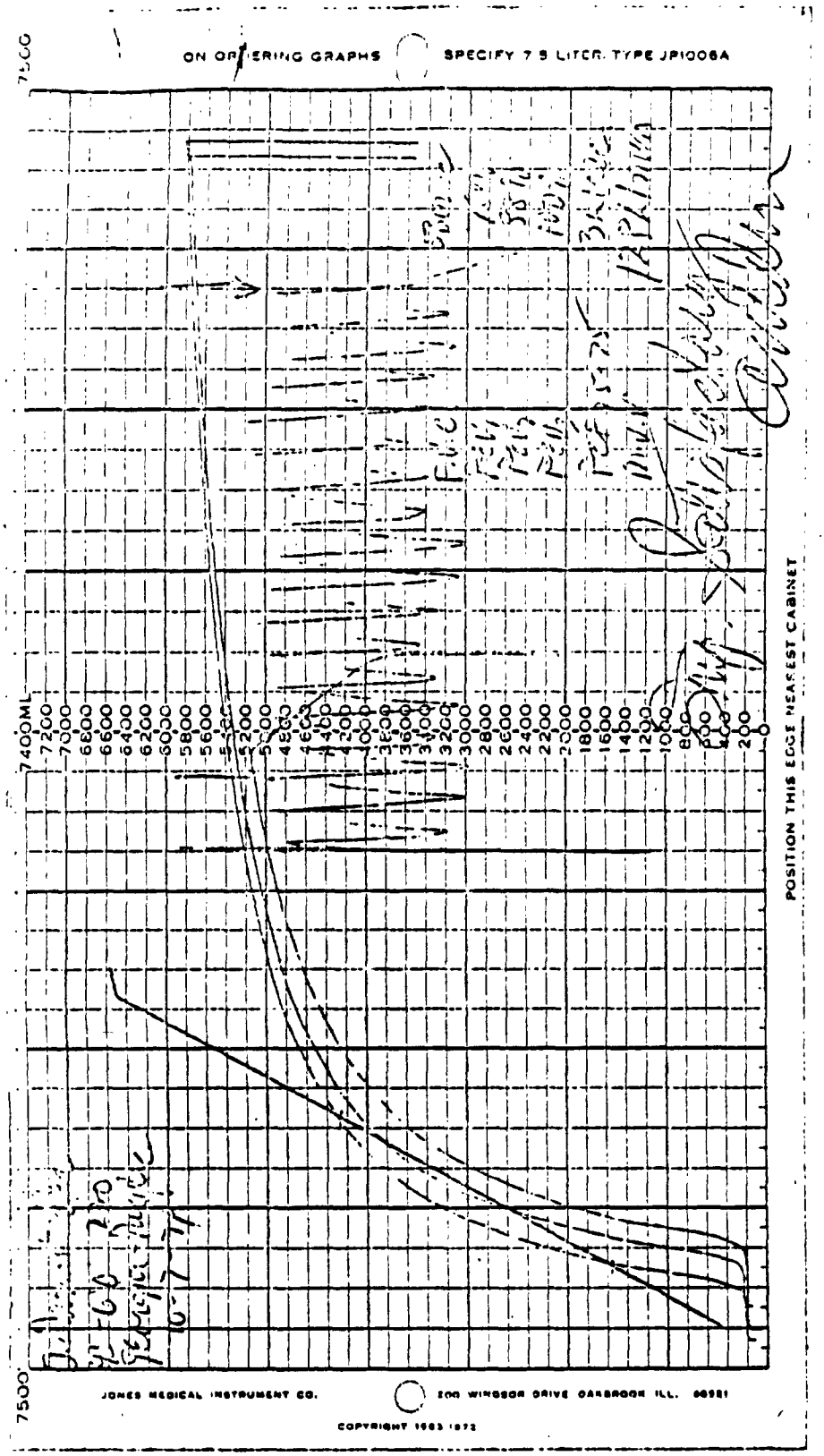
ON ORDERING GRAPHS SPECIFY 7.5 LITER. TYPE JP1006A
7500
7400ML
7200
7000
6800
6600
6400
6200
6000
5800
5600
5400
5200
5000
4800
4600
4400
4200
4000
3800
3600
3400
3200
3000
2800
2600
2400
2200
2000
1800
1600
1400
1200
1000
800
600
400
200
0
7500
POSITION THIS EDGE NEAREST CABINET
JONES MEDICAL INSTRUMENT CO.
200 WINDSOR DRIVE OAKBROOK ILL. 60521
COPYRIGHT 1963 1972

SGP 0007748

COMMENT - Cont'd: and I would appreciate an opportunity to repeat the chest x-ray to be certain that the finding demonstrated at this time is artificial and not within the lung fields.



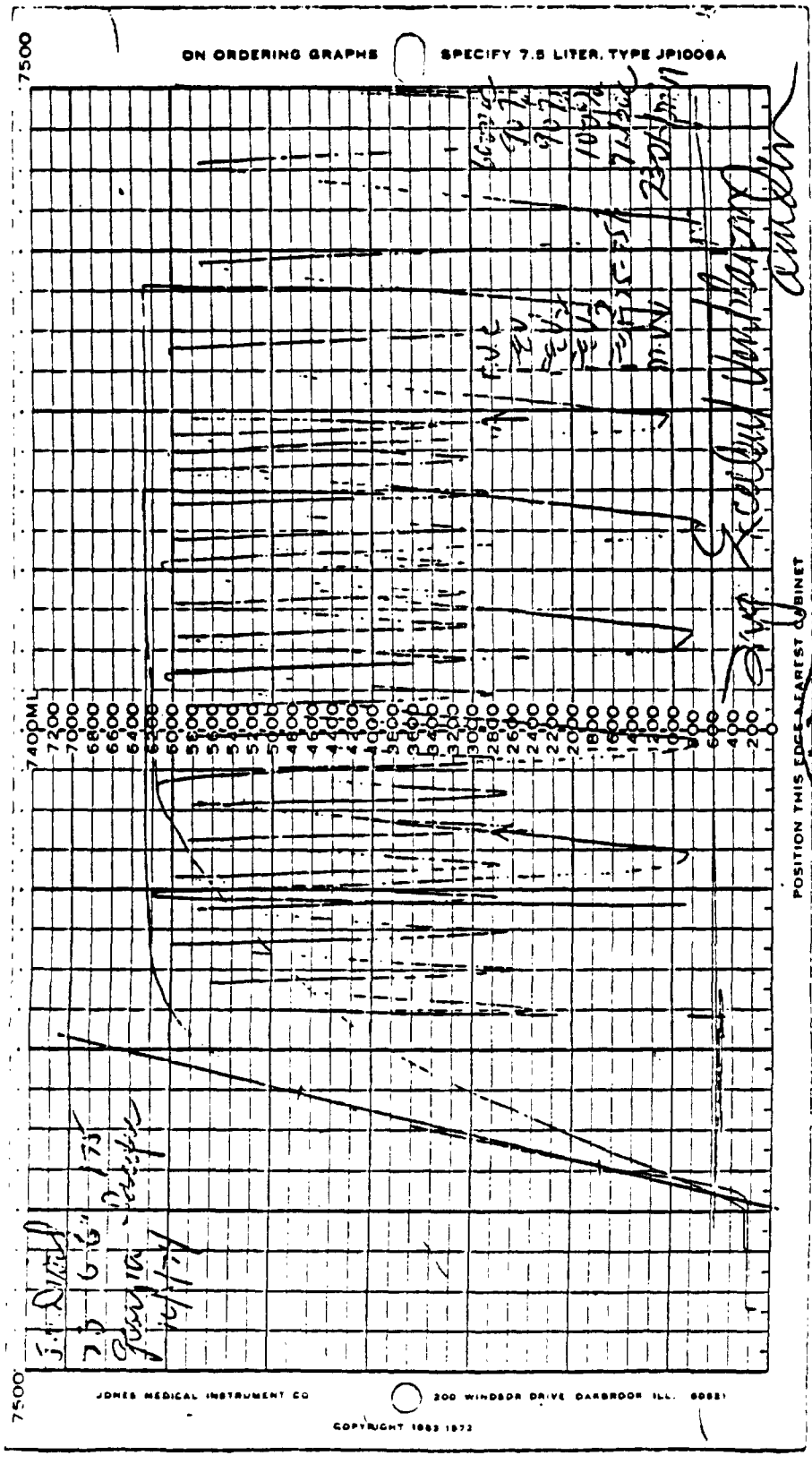

RECEIVED
OCT 14 1974
Beshwell Gypsum Co.
Akron, N.Y.

MARVIN L. AMDUR M.D.
ROBERT A. CAPUTI M.D.
HAROLD L. GRAFF, M.D.
JOHN N. STRACHAN, M.D.

BUFFALO INDUSTRIAL MEDICAL CENTER
LABORATORIES

BUFFALO INDUSTRIAL MEDICAL CENTER
755 TONAWANDA STREET
BUFFALO, N. Y. 14207
TELEPHONE: 875-1514

October 5th, 1974

Memo:

Mr. Schifferle
Georgia-Pacific

Re: DAVID, James W.
13869 Bloomingdale Road
Akron, New York

Chest x-ray #3898 - 10/2/74

Dear Sir:

Reviewing this chest x-ray suggests that there is a defect probably in the film and in the interests of diligence, I would appreciate an opportunity to repeat this chest x-ray.

Very truly yours,

Marvin L. Amdur, M. D.

MLA/kl

RECEIVED
OCT 14 1974
Bestwall Gypsum Co.
Akron, N. Y.

DAVID, James W. Employed: GEORGIA-PACIFIC

James W DAVID 115-44-3320

13869 Bloomingdale Rd 23 X

AKRON N.Y.

1. CHEST PAIN	✓	
2. SHORT OF BREATH	✓	
3. EXPECTORATION	✓	
BLOOD		✓

AMOUNT/24 HRS.

1 cup.

1 tbsp.

1 cup

1 cup

5. DO YOU SMOKE? yes

cigars/ /day

/month

1½ [illegible] 14 [illegible]

no complaints

6. [illegible]		✓
7. TUBERCULOSIS		✓
8. ASTHMA		✓
9. CHRONIC BRONCHITIS		✓
10. HEART DISEASE		✓
11. HIGH BLOOD PRESSURE		✓

OCCUPATIONAL HISTORY: [illegible]

Joint System

RECEIVED OCT 14 1974 Bestwall Gypsum Co. Akron, N.Y.

VENTILATION STUDY

FVC: 6000cc

FEV1: 90%

FEV2: 90%

FEV3: 100%

FEF 25%-75%: 7L/sec

M.V.V. 230L/min

Excellent level of function.

[illegible] 3898 #3898

The root areas are entirely normal. In the periphery of the right 3rd interspace there appears to be some area of density but I suspect that this is probably an artifact and that it does not represent parenchymal disease. The lung fields are otherwise quite satisfactory. Trachea is in the midline. Diaphragms are smooth and all sulci are clear. Heart shadow and bony cage are normal.

[illegible]: I find nothing to suggest any diseased state. The ventilation studies are normal. Chest x-ray, I suspect, is likewise normal. The area referred to in the right chest is probably an artifact.... CONT'D REVERSE..

10/2/74

MLA/kl

Marvin L. Amdur, M. D.

SGP 0007752

. . . . . M.D.
ROBERT A. CAPUTI, M.D
HAROLD L. GRAFF, M.D.
JOHN N. STRACHAN, M.D.

Telephone . . .

BUFFALO INDUSTRIAL MEDICAL CENTER
755 TONAWANDA STREET
BUFFALO, N.Y. 14207

X-RAY REPORT

NAME DAVID, James EMPLOYER ~~Georgia-Pacific~~

ADDRESS ~~13869 Bloomingdale Rd., Akron, N.Y.~~ INS. CARRIER

Date 10/23/74 Part Examined #4275 - Chest Film No. #4275

Radiographic Findings:

Repeat chest x-ray, in accordance with prior report, does not indicate same abnormality previously described as being present in the right upper lobe. It is the impression of this examiner, therefore, that the original defect was probably an artifact and that the examinee's chest x-ray is quite satisfactory.

MLA/kl

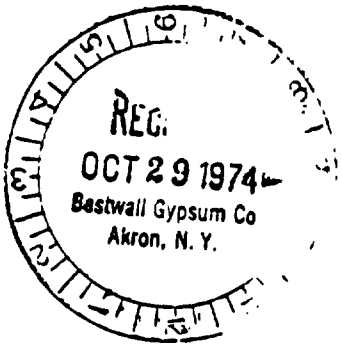

Marvin L. Amdur, M. D.

M.D.

SGP 0007753

[illegible] Georgia Pacific

[illegible]: Raymond C. Fisher [illegible]: [illegible]

[illegible]: 13555 [illegible] [illegible]: 25 [illegible]

[illegible]

1. COUGH		
2. CHEST PAIN		✓
3. SHORT OF BREATH		✓
4. EXPECTORATION		✓
BLOOD		✓

AMOUNT/24 HRS.
1 tsp.
1 tbsp.
1 cup
1 cup

5. DO YOU SMOKE? no

cigars/ /day
pipe /month
cigarettes
[illegible]

no complaints

[illegible]

[illegible]		
[illegible]		✓
[illegible]		✓
[illegible]		✓
[illegible]		✓
[illegible]		✓
[illegible]		✓

[illegible]

Plant work 4 yrs

VENTILATION STUDY

FVC: 4200 cc
FEV1: 90%
FEV2: 100%
FEV3: 100%
FEF 25-75: 6 L/sec
P.E.F.: 105 L/min

[illegible]

Ventilation studies quite satisfactory.

[illegible]: 3974

Mild prominence of both root areas. Peripheral lung fields are entirely normal. Trachea is in the midline. Diaphragms are smooth and sulci are clear. No evidence of any pleural reaction. Heart shadow and bony cage are normal.

Impression normal chest.

[illegible]: There are no physical complaints. Ventilation study and chest x-ray are quite satisfactory.

[illegible]

[illegible]: 4/7/74 Shawn [illegible]

SGP 0007754

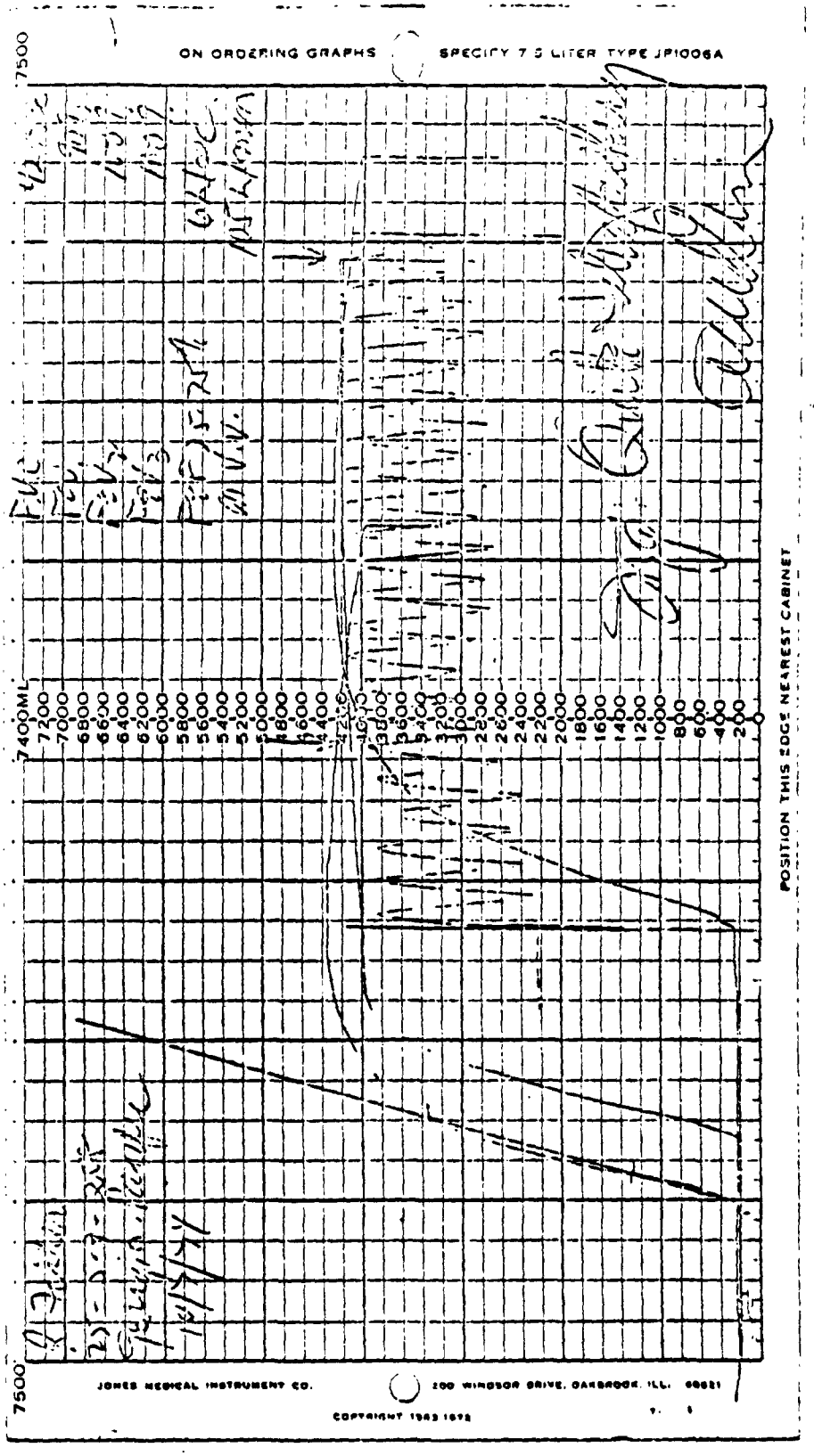
ON ORDERING GRAPHS SPECIFY 7.5 LITER TYPE JP1006A
7500
7400ML
7200
7000
6800
6600
6400
6200
6000
5800
5600
5400
5200
5000
4800
4600
4400
4200
4000
3800
3600
3400
3200
3000
2800
2600
2400
2200
2000
1800
1600
1400
1200
1000
800
600
400
200
0
POSITION THIS EDGE NEAREST CABINET
JONES MEDICAL INSTRUMENT CO.
200 WINDSOR DRIVE, OAKBROOK, ILL. 60521
COPYRIGHT 1963 1972

SGP 0007755

Employed Georgia Pacific

Arnold J Handrich

[illegible] 1200 [illegible] Ave. [illegible] AGE 43 [illegible]

[illegible] 14001

[illegible]

No subj complaint

[illegible] 6 mo.

[illegible]

[illegible] (G.P. 22 yrs.) tracker & packer stacker

joint system 6 yrs

VENTILATION STUDY

FVC: 5000 cc
FEV1: 80%
FEV2: 95%
FEV3: 100%
FEF 25%-75%: 3.5 L/sec
[illegible] 120 L/min

[illegible]

Ventilation study quite satisfactory.

[illegible] 3970

The root areas and peripheral lung fields are entirely normal beyond some minimal increase in markings in the right lower lobe. No evidence of pleural changes. Heart shadow, bony cage are normal.

General impression is that of a satisfactory chest x-ray.

[illegible]: No evidence objective complaint. Chest x-ray and ventilation studies are normal.

[illegible]

[illegible]: 10/7/74

[illegible]

SGP 0007756

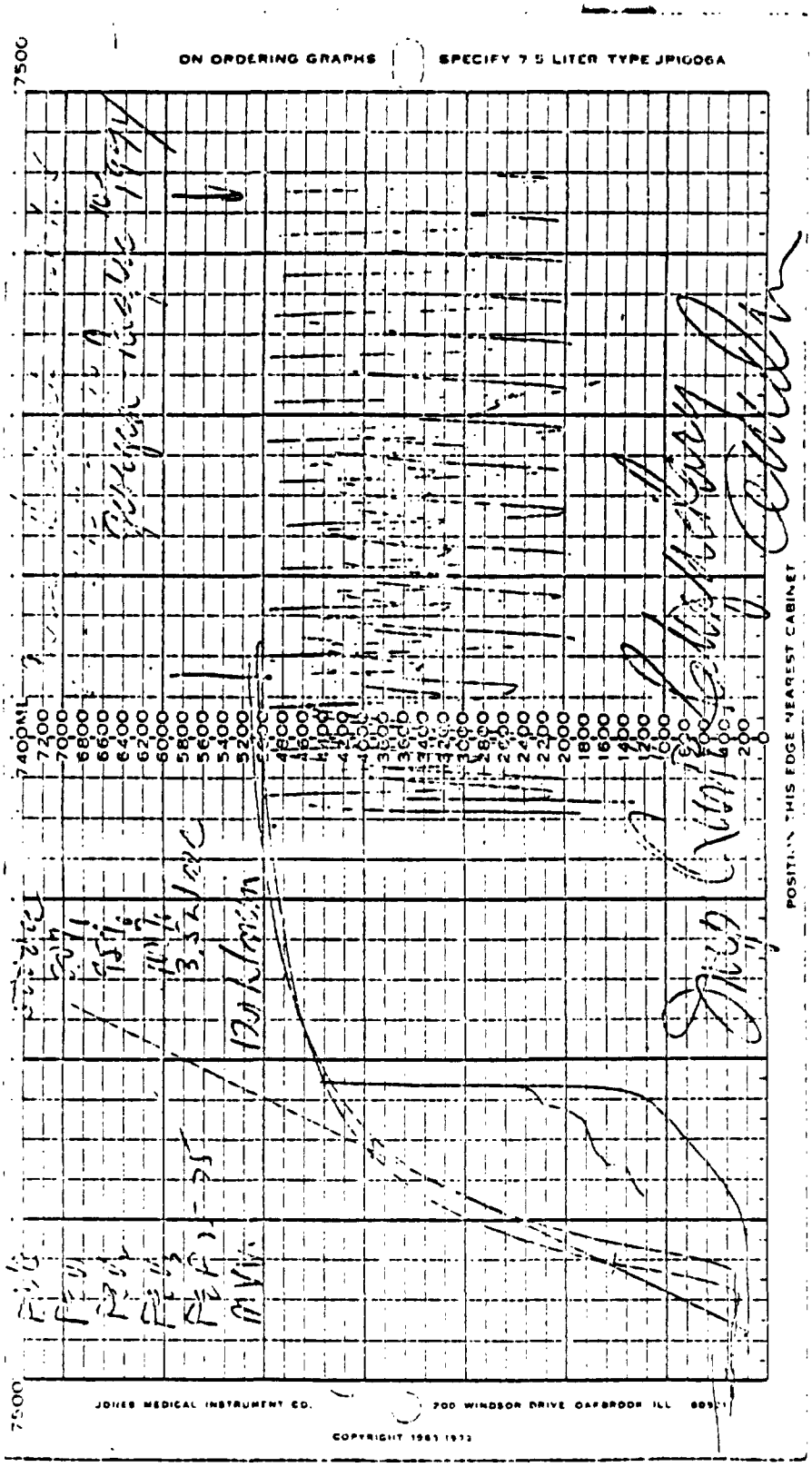
ON ORDERING GRAPHS SPECIFY 7.5 LITER TYPE JP1000A
7500
7400ML
7200
7000
6800
6600
6400
6200
6000
5800
5600
5400
5200
5000
4800
4600
4400
4200
4000
3800
3600
3400
3200
3000
2800
2600
2400
2200
2000
1800
1600
1400
1200
1000
800
600
400
200
0
POSITION THIS EDGE NEAREST CABINET
JONES MEDICAL INSTRUMENT CO.
700 WINDSOR DRIVE OAKBROOK ILL
COPYRIGHT 1963 1972

SGP 0007757

NAME Alton Hoste SOC. SEC. 095-03-112

69 Minard St. 63

Lockport N.Y. 14094

	YES	NO
[illegible]	✓	
[illegible]		
[illegible]	✓	
[illegible]		
[illegible]	✓	

Note: Some complaint of chest pain and expectoration. Examinee has been smoking for many years.

[illegible]		✓
[illegible]		✓
[illegible]		✓
[illegible]		✓
[illegible]		✓

General Plant work Joint System 39 yrs

VENTILATION STUDY

FVC: 4200cc
FEV1: 80%
FEV2: 90%
FEV3: 96%
FEF 25%-75%: 3 L/sec
M.V.V. 75 L/min

Quite satisfactory for the examinee's age. No significant evidence of either restrictive or obstructive disease.

[illegible] 3841 #3841

Moderate prominence of the right root with increased bronchovascular markings throughout the lower halves of both lung fields. Heart shadow and bony cage are normal.

Chest x-ray and ventilation studies compatible with examinee's age. No particular evidence of any pulmonary disability.

[illegible]: 9/30/74

MLA/kl

Marvin L. Amdur, M. D.

SGP 0007758

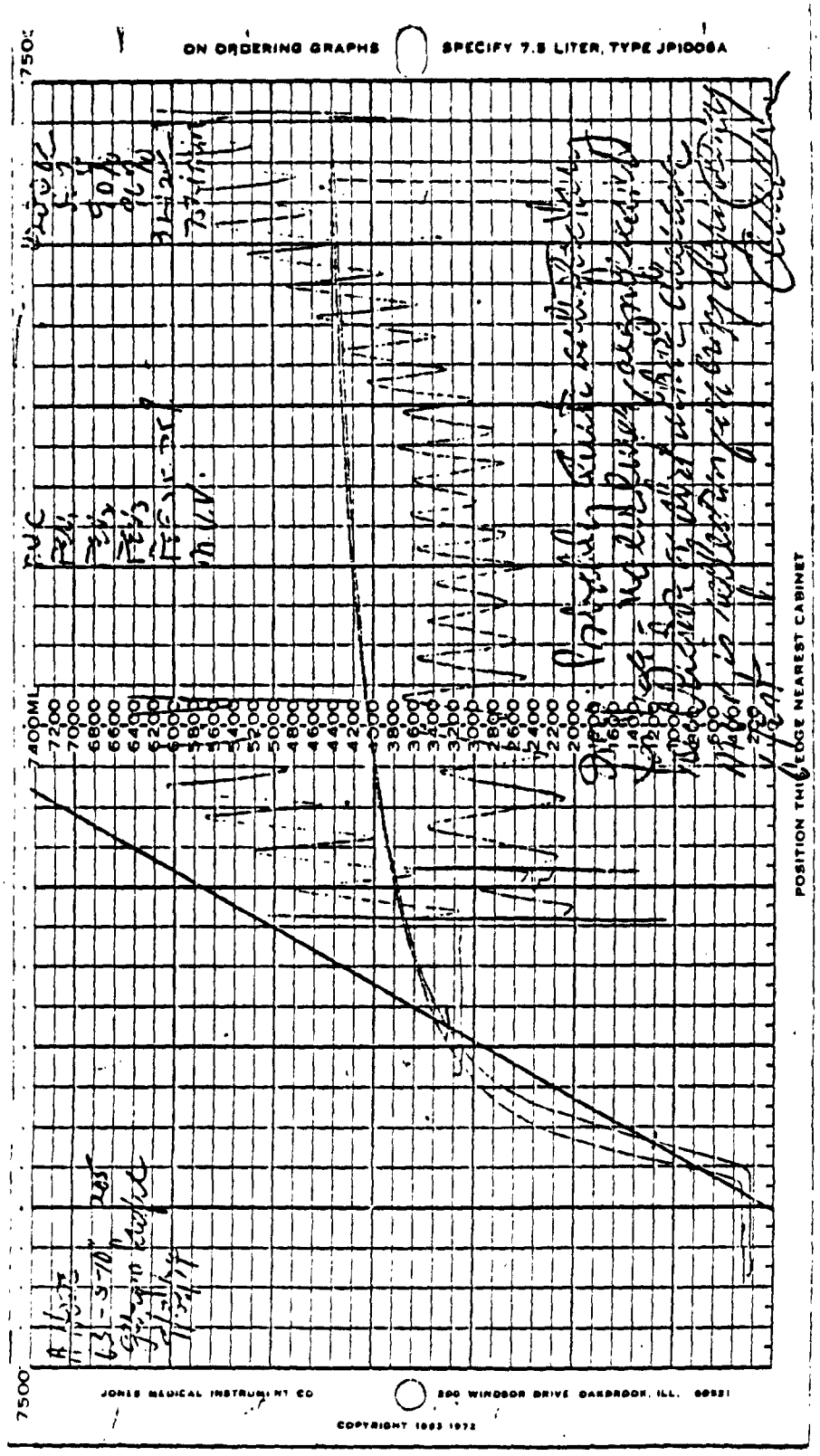
ON ORDERING GRAPHS SPECIFY 7.5 LITER, TYPE JP1006A
POSITION THIS EDGE NEAREST CABINET
JONES MEDICAL INSTRUMENT CO
200 WINDSOR DRIVE OAKBROOK, ILL. 60521
COPYRIGHT 1963 1972

SGP 0007759

KENWARD, Robert Employed: [illegible]

[illegible]: Robert A. Kenward

[illegible]: 912 [illegible] Drive [illegible] 31 [illegible]

[illegible]

[illegible]

1. COUGH		
2. CHEST PAIN		✓
3. SHORT OF BREATH		✓
4. EXPECTORATION		✓
BLOOD		✓

[illegible]

1 tbsp.

1 tbsp.

1 cup

1 cup

5. DO YOU SMOKE? ✓

cigars/ [illegible]

[illegible]

1/2 [illegible] 20 [illegible]

no complaints.

[illegible]

[illegible]		
6. [illegible]	✓	
7. TUBERCULOSIS		✓
8. [illegible]		✓
9. CHRONIC BRONCHITIS		✓
10. HEART DISEASE		✓
11. HIGH BLOOD PRESSURE	✓	

[illegible]

[illegible] 1 year on packer stacker joint system

RECEIVED OCT 14 1974 Bestwall Gypsum Co. Akron, N.Y.

VENTILATION STUDY

FVC: 5000cc

FEV1: 82%

FEV2: 92%

FEV3: 100%

FEF 25%-75%: 4 L/sec

M.V.V. 130 L/min

Quite satisfactory. No evidence of either restrictive or airway obstructive disease.

[illegible] OF CHEST FILM [illegible]: 3892 #3892

The root areas are normal. There is a mild increase in bronchovascular markings into the right lower lobe but no evidence of any specific parenchymatous disease. There are no pleural findings. Trachea is in the midline. Diaphragms are smooth and all sulci are clear.

Heart shadow and bony cage are normal.

[illegible]: Status appears to be quite good. Chest x-ray is quite satisfactory. Ventilation studies are entirely normal.

[illegible]

DATE 10-2-74

MLA/kl

Marvin L. Amdur, M. D.

SGP 0007760

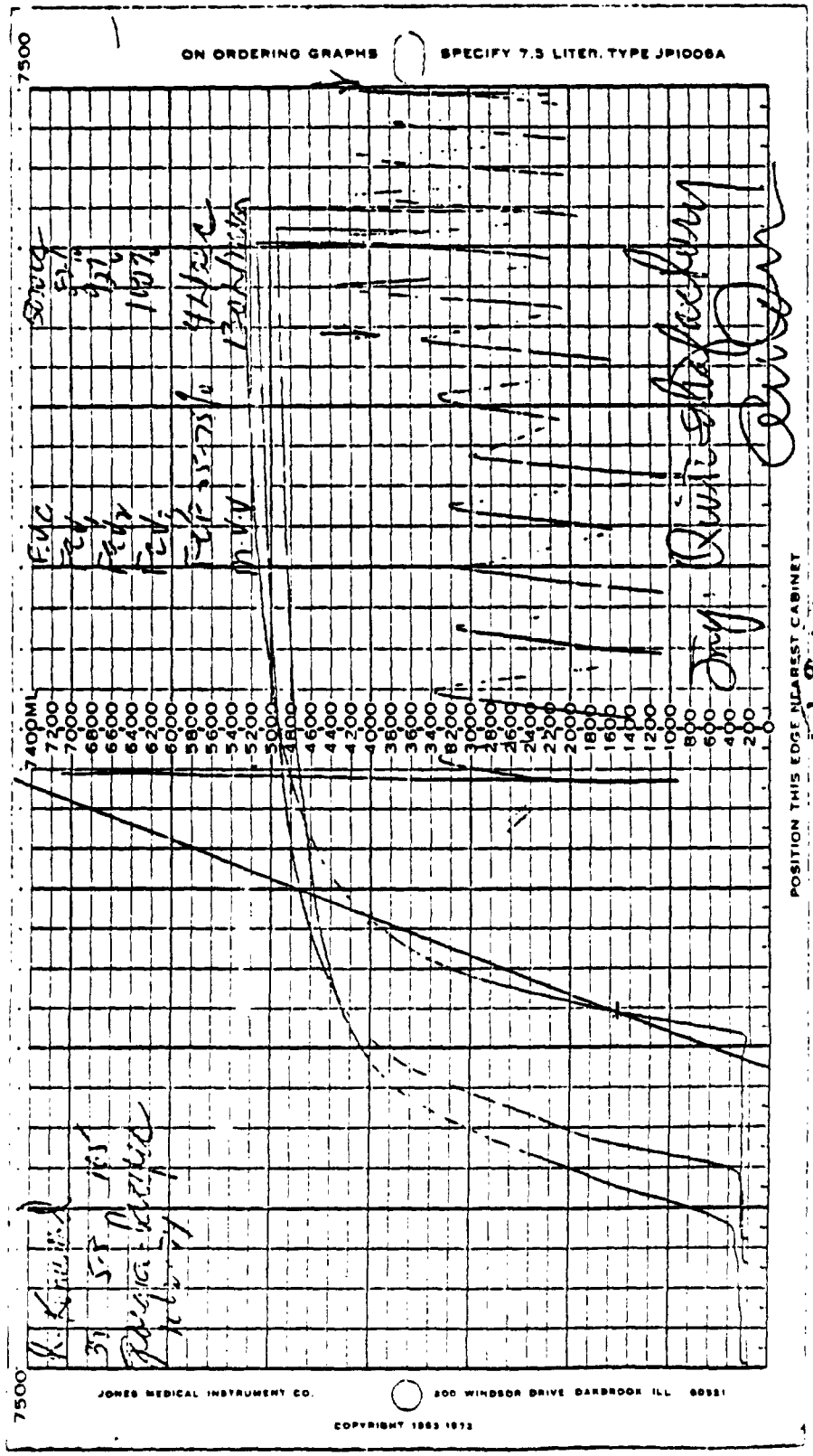

Eastern Gypsum Co
Akron, N. Y.
OCT 14 1974

Patrick Krantz

11 Washington St
Akron New York 14001

129-44-2[illegible]

20

[illegible]

2. CHEST PAIN		✓
3. SHORT OF BREATH		✓
4. [illegible]		✓
[illegible]		✓
[illegible]		
1 [illegible]		
1 [illegible]		
1 cup		
1 cup		
5. [illegible]	✓	[illegible]
[illegible]		
[illegible]		
[illegible]		
[illegible]		

Insignificant Complaint

[illegible]		
[illegible]		✓
[illegible]		✓
[illegible]		✓
[illegible]		✓
10. HEART DISEASE		✓
[illegible]		✓

[illegible] I am a Laborer in the mines for 1½ yrs.

VENTILATION STUDY

FVC:	4800 cc
FEV1:	84%
FEV2:	96%
FEV3:	100%
[illegible]	41 [illegible]
[illegible]	120 L/min

Ventilation studies are quite satisfactory.

[illegible] 3973

There are a few small calcific densities in the right root and in both lower lobes. Peripheral lung fields are otherwise entirely normal. Trachea in the midline. Diaphragms are smooth and sulci are clear. Heart shadow and bony cage are normal.

Impression: Satisfactory chest.

[illegible] Ventilation studies and chest x-ray are both quite satisfactory.

[illegible]

DATE: 10/7/74

[illegible]

SGP 0007762

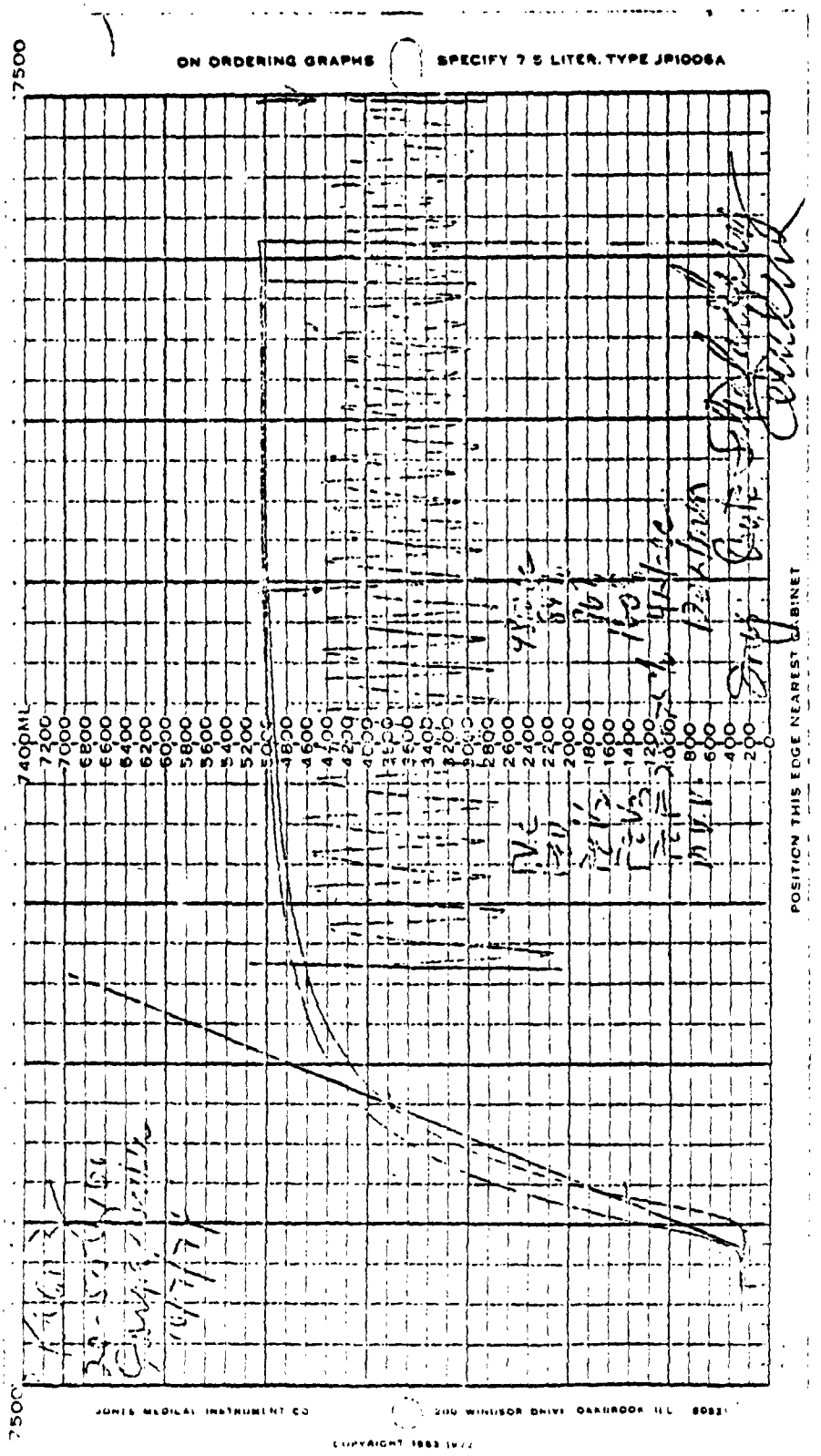
ON ORDERING GRAPHS SPECIFY 7.5 LITER, TYPE JP1006A
7500
7400ML
7200
7000
6800
6600
6400
6200
6000
5800
5600
5400
5200
5000
4800
4600
4400
4200
4000
3800
3600
3400
3200
3000
2800
2600
2400
2200
2000
1800
1600
1400
1200
1000
800
600
400
200
0
POSITION THIS EDGE NEAREST CABINET
7500
JONES MEDICAL INSTRUMENT CO
200 WINDSOR DRIVE OAKBROOK ILL 60521
COPYRIGHT 1963 1972

WILLIAM NALBONE 117-34-0922
619-20TH STREET 29 X
NIAGARA FALLS, N.Y. 14301

NO complaints

QUALITY CONTROL SUPERVISOR IN JOINT SYSTEM DEPT. 6 YEARS

FVC: 3600cc
FEV1: 85%
FEV2: 100%
FEV3: 100%
MMF 25-75: 44/sec
M.V.V. 120L/min

CHEST PA: 4007

Mild prominence of the right root markings, increased in the right lower lobe. Peripheral lung fields otherwise not remarkable. Heart shadow, bony cage are normal.

Impression: Chest x-ray satisfactory.

COMMENT: No complaints, ventilation studies satisfactory; chest x-ray satisfactory.

DATE: 10/8/74

SGP 0007764

7400ML
7200
7000
6800
6600
6400
6200
6000
5800
5600
5400
5200
5000
4800
4600
4400
4200
4000
3800
3600
3400
3200
3000
2800
2600
2400
2200
2000
1800
1600
1400
1200
1000
800
600
400
200
0
7500
POSITION THIS EDGE
JONES MEDICAL INSTRUMENT CO
200 WINDSOR DRIVE, DARROCK ILL 60521
COPYRIGHT 1963 1972

REUTER, Paul Employed: GEORGIA_PACIFIC

PAUL REUTER 078-42-053

10825 STAGE RD 24 ✓

CLARENCE, N.Y. 14031

No complaint

1½ .7

JT. SYSTEM

RECEI
OCT 14 1974
Bestwall Gypsum Co.

VENTILATION STUDY

FVC: 4800 cc
FEV1: 85%
FEV2: 95%
FEV3: 100%
FEF 25%-75%: 4.5L/sec
M.V.V.: 150 L/min

Excellent ventilatory function. No defects.

CHART OF CHEST FILM NUMBER: 3897 #3897

The root areas and peripheral lung fields are entirely normal. Trachea is in the midline. Diaphragms are smooth and all sulci are clear.

Heart shadow and bony cage are normal.

Health status seems excellent. Chest x-ray is satisfactory and Ventilation studies could not be better.

10-2-74

MLA/kl

Marvin L. Amdur, M. D.

SGP 0007766

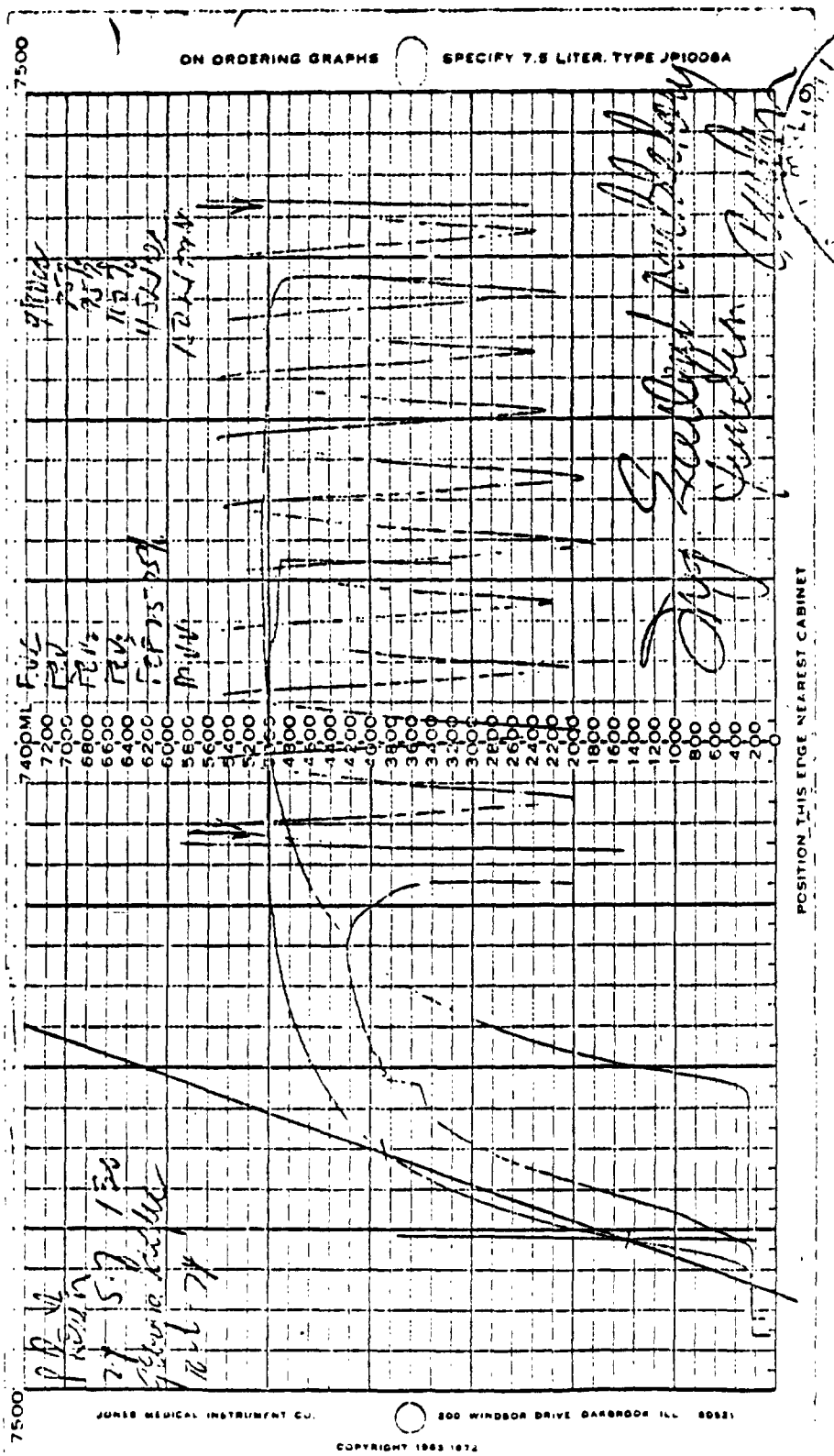
ON ORDERING GRAPHS SPECIFY 7.5 LITER. TYPE JP1008A
7500
7400ML
7200
7000
6800
6600
6400
6200
6000
5800
5600
5400
5200
5000
4800
4600
4400
4200
4000
3800
3600
3400
3200
3000
2800
2600
2400
2200
2000
1800
1600
1400
1200
1000
800
600
400
200
0
POSITION THIS EDGE NEAREST CABINET
JONES MEDICAL INSTRUMENT CO.
300 WINDSOR DRIVE OAKBROOK ILL. 60521
COPYRIGHT 1963 1972

OCT 14 1974

SCHEFFERLY, James L. Employed: Georgia-Pacific

James L. Schepperly 132-46-0029

29 Lewis Rd 21 ✓

Akron, New York 14001

1. COUGH		
2. CHEST PAIN		✓
3. SHORT OF BREATH		✓
4. EXPECTORATION		✓
BLOODY		✓
AMOUNT/24 HRS.		
1 tsp.		
1 tbsp.		
1 cup		
1 cup		
5. DO YOU SMOKE?	no	
cigars/ /day		
pipe /month		
cigarettes		
pkg/day /yr.		

No complaint.

6. [illegible]		✓
7. TUBERCULOSIS		✓
8. [illegible]	✓	✓
9. CHRONIC BRONCHITIS		✓
10. HEART DISEASE		✓
11. [illegible]		✓

Asthma when younger

Lab Tester — 3 years

VENTILATION STUDY

FVC:	5400cc
FEV1:	88%
FEV2:	96%
FEV3:	100%
FEF 25%-75%:	7 H/sec
M.V.V.	140L/min

Excellent function. No defect.

[illegible] 3844 #3844

Root areas and peripheral lung fields are entirely normal. Trachea is in the midline. Diaphragms are smooth and sulci are clear. Heart shadow, bony cage are normal.

Normal chest x-ray. Normal ventilation studies.

[illegible]: Health status would appear to be excellent.

[illegible]

[illegible]: 9/30/74

MLA/kl

Marvin L. Amdur, M. D.

SGP 0007768

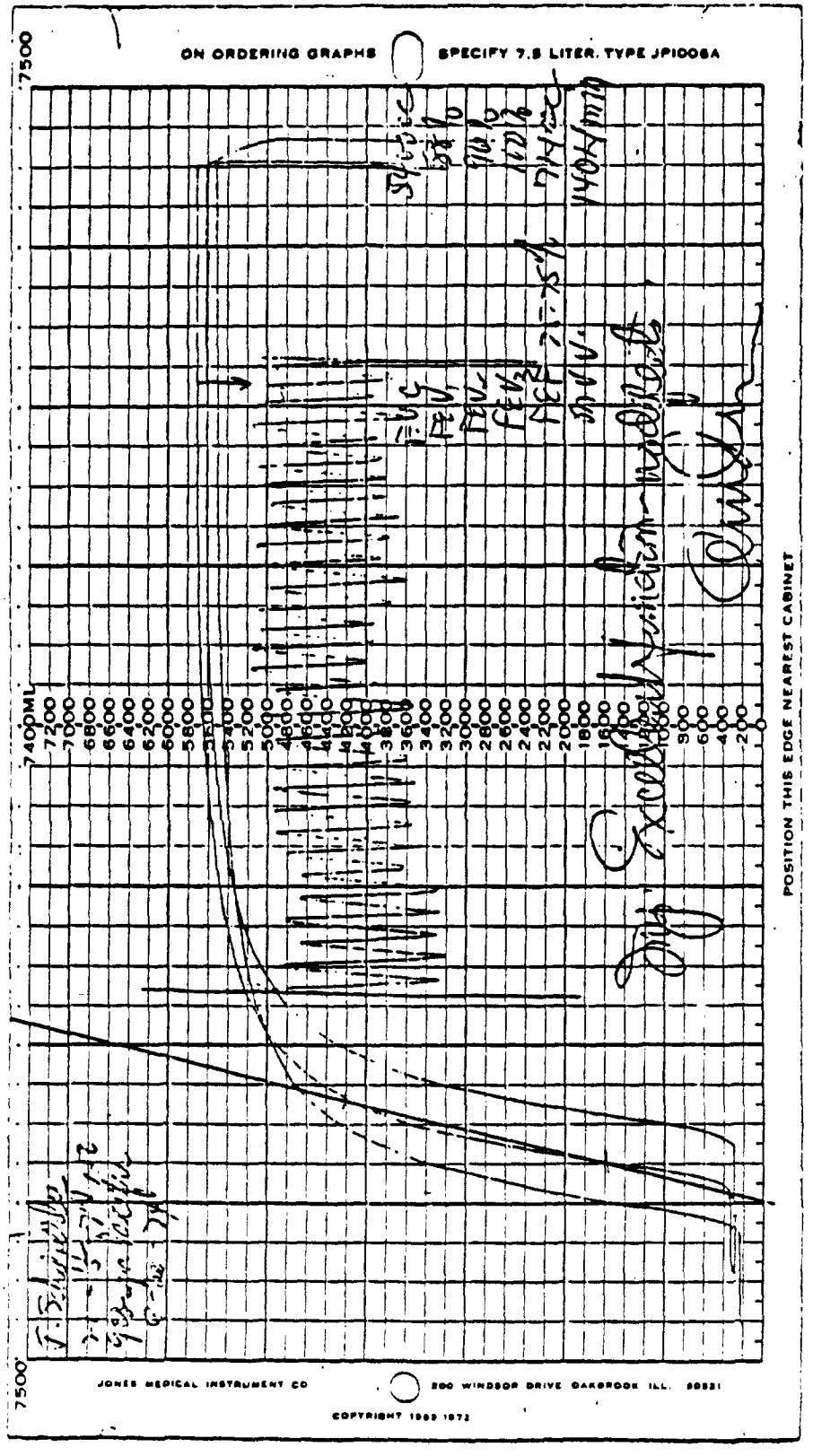
ON ORDERING GRAPHS SPECIFY 7.5 LITER. TYPE JPIOOGA
7500
7400ML
7200
7000
6800
6600
6400
6200
6000
5800
5600
5400
5200
5000
4800
4600
4400
4200
4000
3800
3600
3400
3200
3000
2800
2600
2400
2200
2000
1800
1600
1400
1200
1000
800
600
400
200
0
7500
POSITION THIS EDGE NEAREST CABINET
JONES MEDICAL INSTRUMENT CO
200 WINDSOR DRIVE OAKBROOK ILL. 60521
COPYRIGHT 1969 1972

Employed Georgia Pacific

[illegible] Robert G. Schiffele [illegible] 086-26-2264

[illegible] 175 Cleveland Dr. [illegible] 42 X

Kenmore N.Y.

[illegible]

1. COUGH		X
2. CHEST PAIN		X
3. SHORT OF BREATH		X
4. [illegible]		X
[illegible]		

[illegible]

[illegible] 3/day

[illegible] 175/month

[illegible]

No complaints

[illegible]

6. [illegible]		X
7. TUBERCULOSIS		X
8. [illegible]		X
9. CHRONIC BRONCHITIS		X
10. HEART DISEASE		X
11. HIGH BLOOD PRESSURE		X

OCCUPATIONAL HISTORY: [illegible]

Have worked in Jt Syst. Dept off and on as supervisor

VENTILATION STUDY

FVC: 4400cc
FEV1: 86%
FEV2: 95%
FEV3: 100%
FEF 25%-75%: 5L/sec
M.V.V. 120L/min

[illegible]

Ventilation studies quite satisfactory.

[illegible] OF CHEST FILM NUMBER: 4002

Mild prominence of the root areas, minimal increase in bronchovascular markings in both lower lobes. Multiple calcific densities in each root and in the right lower lobe. Heart shadow normal in size, position and configuration. The bony cage is normal. Impression satisfactory chest.

[illegible]: No subjective complaints. Ventilation studies satisfactory. Chest x-ray satisfactory.

[illegible]

[illegible]: 10-8-74

Shawn Klemkin

SGP 0007770


SPECIFY 7.5 LITER. TYPE JP1006A
7400ML
7500
POSITION THIS EDGE REAR EST CABINET
JONES MEDICAL INSTRUMENT CO
300 WINDSOR DRIVE OAKBROOK ILL 60521
COPYRIGHT 1963 1972

Employed Georgia Pacific

NAME Kenneth Snyder SEC. [illegible]

[illegible]: [illegible] AGE: 45 [illegible]

[illegible]: INDICATE [illegible]/NO

1. COUGH
2. CHEST PAIN — NO
3. SHORT OF BREATH — NO
4. EXPECTORATION — NO
   BLOODY — NO
   AMOUNT/24 HRS.
   1 tsp.
   1 tbsp.
   1 cup
   1 cup
5. DO YOU SMOKE? yes
   cigars* /day
   pipe L /month
   cigarettes 1-2 pack
   [illegible]/day /yrs.
   IF NO - [illegible] 35 yrs

no complaints

DO YOU NOW HAVE OR HAVE YOU [illegible] IF YES - DESCRIBE

EVER HAD?	YES	NO
6. PNEUMONIA		NO
7. TUBERCULOSIS		NO
8. ASTHMA		NO
9. CHRONIC BRONCHITIS		NO
10. HEART DISEASE		NO
11. HIGH BLOOD PRESSURE		

OCCUPATIONAL HISTORY: WHAT DO YOU DO AND HOW LONG HAVE YOU WORK

Load - unload 10 yrs JT. SYST. DEPT

VENTILATION STUDY

FVC: 4400 cc
FEV_1: 80%
FEV_2: 90%
FEV_3: 95%
FEF 25%-75%: 35 Hec
M.V.V. 190 L/min

INTERPRETATION

Ventilation studies quite satisfactory.

XRAY OF CHEST FILM NUMBER: 3972

Moderate fibrosis of both roots, slight fibrosis of all lobes except for the left upper lobe where there is moderate radiolucency. This is associated with some minimal downward displacement of the left hilar area probably as a consequence of some emphysematous changes in the left upper. There are no significant evidences of pleural disease. Heart shadow though full is not abnormally so. Bony cage is normal. Impression minimal emphysema left upper lobe. Despite the absence of complaint and minimal

COMMENT: x-ray changes ventilation studies are normal. General health status would seem to be satisfactory.

[illegible]

DATE: 10/7/74 Shawn L. [illegible] M.D.

SGP 0007772

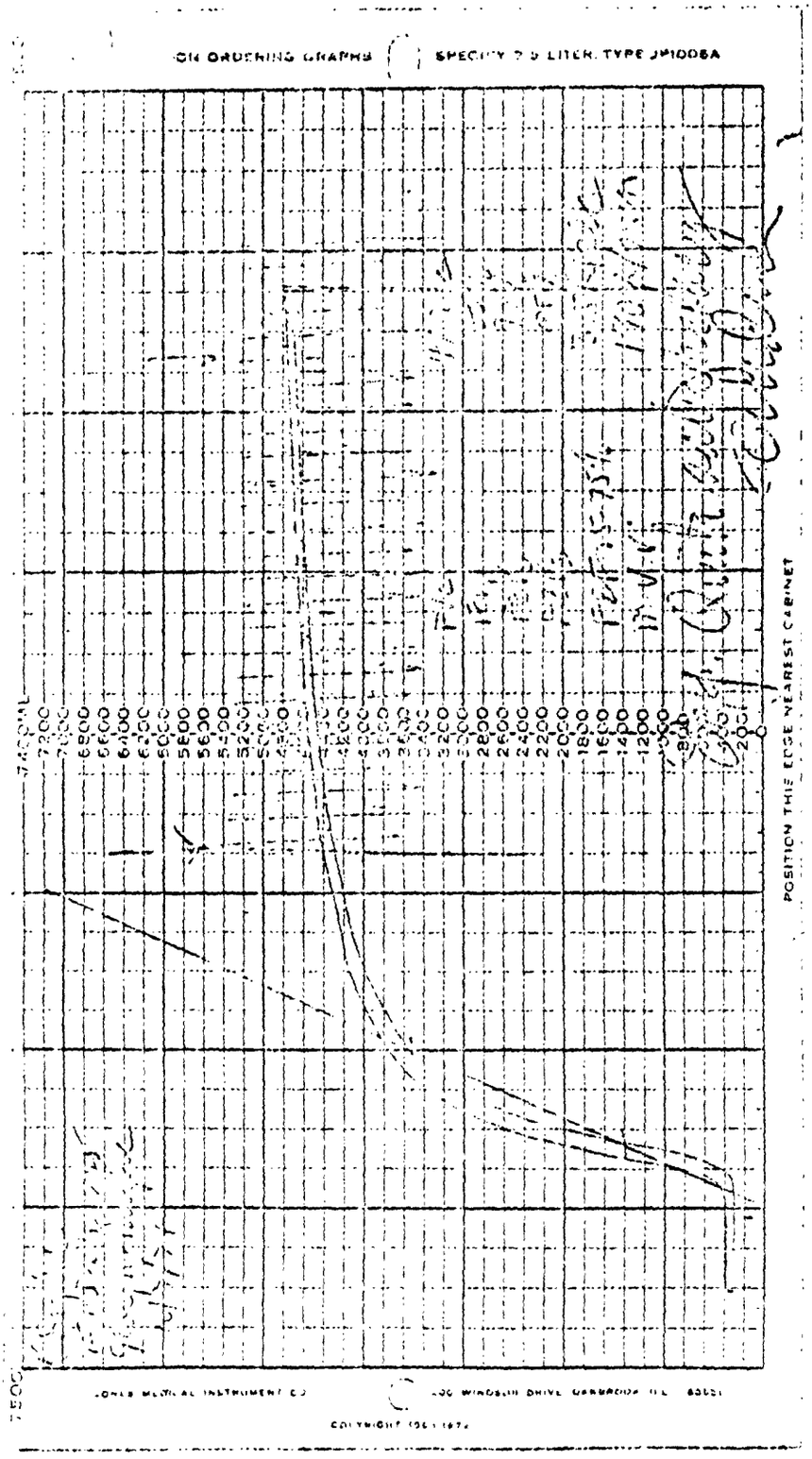
ON ORDERING GRAPHS
SPECIFY 2.5 LITER TYPE JP100SA
POSITION THIS EDGE NEAREST CABINET
JONES MEDICAL INSTRUMENT CO
COPYRIGHT 1961 1974

SGP 0007773

WEIBEL, Irvin Employed: GEORGIA PACIFIC

[illegible]: Irvin F. Weibel [illegible] 099-28-9757
[illegible]: 4406 S. Newstead Rd [illegible]: 36 X
Akron, New York 14001

INQUIRY: INDICATE [illegible]

1. COUGH		
2. CHEST PAIN	X	
3. SHORT OF BREATH		X
4. EXPECTORATION	X	
BLOODY		X

AMOUNT/24 HRS.
1 tsp.
1 tbsp.
1 cup
1 cup

5. DO YOU SMOKE? yes.
cigars/ /day
pipes /month
cigarettes
1½-2 pks/day /yrs.
IF NO - [illegible]

no spec. complaint

DO YOU HOW HAVE OR HAVE YOU [illegible] IF YES - [illegible]

	YES	NO	
6. PNEUMONIA	X		-PNEUMONIA AT 7 YRS OLD
7. TUBERCULOSIS		X	
8. ASTHMA		X	
9. CHRONIC BRONCHITIS		X	
10. HEART DISEASE		X	
11. HIGH BLOOD PRESSURE	X		- ON MEDICATION AT PRESENT

OCCUPATIONAL HISTORY: WHAT DO YOU DO AND HOW LONG HAVE YOU WORK

JOINT SYSTEM DEPT. SUPERVISOR - 9 YEARS.

VENTILATION STUDY

FVC: 4800 cc
FEV1: 80%
FEV2: 95%
FEV3: 100%
FEF 25%-75%: 3.5 L/sec
M.V.V. 110 L/min.

[illegible]

Studies are quite satisfactory. There is no evidence of either restrictive or airway obstructive disease.

[illegible] OF CHEST FILM NUMBER: 3896 #3896

The root areas and peripheral lung fields are generally not remarkable. There is no evidence of any parenchymal disease. Trachea is in the midline. Diaphragms are smooth. Sulci are clear. Heart shadow and bony cage are normal.

COMMENT: General status would seem to be good. Chest x-ray is satisfactory. Ventilation studies are normal.

[illegible]

DATE: 10-2-74

MLA/kl

Marvin L. Amdur, M.D.

RECEIVED
OCT 14 1974
Bestwall Gypsum Co.
Akron, N.Y.

SGP 0007774

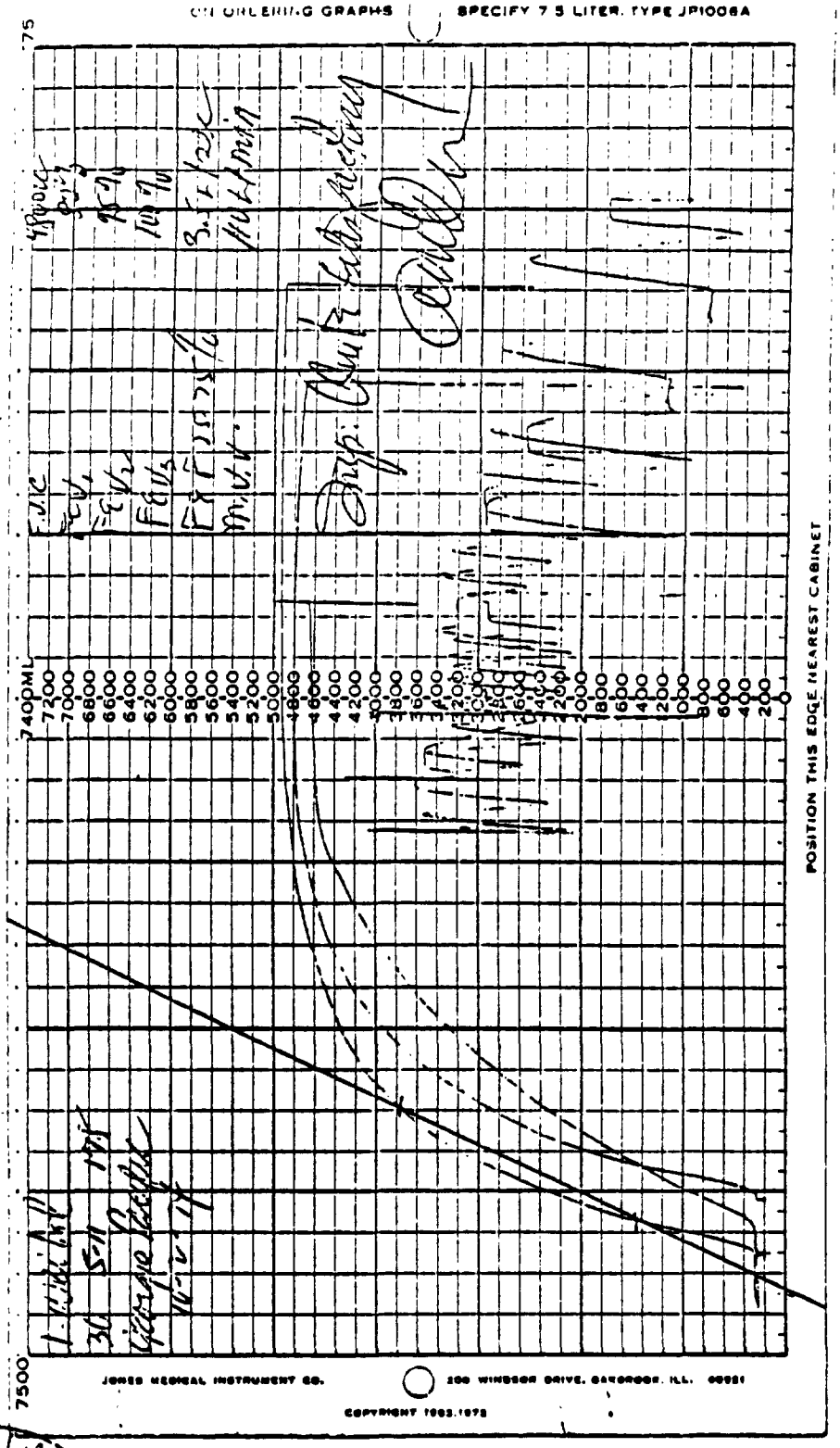

RECEIVED
OCT 14 1974
Bestwall Gypsum Co.
Akron, N. Y.