THE AMERICAN JOURNAL OF PATHOLOGY

Official Publication of
The American Association of Pathologists and Bacteriologists

BOARD OF EDITORS

CARL V. WELLER, Editor-in-Chief
MALCOLM H. SOULE, Assistant Editor

J. HAROLD AUSTIN
PAUL R. CANNON
HOWARD T. KARSNER
TRACY B. MALLORY
SHIELDS WARREN
HARRY M. ZIMMERMAN

VOLUME XXII

(January, March, and May)

1946

ANN ARBOR
MICHIGAN
U. S. A.

PLAINTIFF'S EXHIBIT #6 Ritterhoff

PLAINTIFF'S EXHIBIT SA-33

COEXISTENT PULMONARY ASBESTOSIS AND SARCOIDOSIS *

JOHN H. SKAVLEM, M.D., and ROBERT J. RITTERHOFF, M.D.
(From the Percy Shields Laboratory † of Dunham Hospital, Cincinnati 5, Ohio)

Pulmonary asbestosis, regarded as a "modern disease" by Gloyne and Merewether,[1] was first described by Murray [2] in 1900. Although Fahr [3] described a case in 1914, interest in this disease was not reawakened until the case of Cooke and McDonald was described in 1927.[4] Since that time, there have appeared in the available literature reports upon approximately 150 necropsies on cases of pulmonary asbestosis.[5-12] The paucity of proved cases, in comparison with those of silicosis, is not due wholly to failure to report such cases, for in large necropsy series asbestosis is apparently of infrequent occurrence.[5-13] Further, despite the widespread usage of asbestos products, there are comparatively few people engaged in the asbestos industry. As of October, 1944, only 19,700 people were employed in this industry in the United States.[14]

Much has been written about the clinical, roentgenologic, and biopsic aspects of sarcoidosis. However, because of the infrequency and relatively benign character of this disease there are only isolated detailed necropsy reports. From the available literature there have been found only 58 reports of necropsies on cases of sarcoidosis.[15-21] Most of these were summarized by Pinner.[15]

These two diseases present many clinical and roentgenographic similarities, and, also, their more frequent fatal complications are alike: pulmonary tuberculosis and cardiopulmonary insufficiency. Bronchogenic carcinoma, a frequent complication of pulmonary asbestosis, has not, however, been described as associated with sarcoidosis. Likewise, there has not been a previous description of asbestosis with coexistent sarcoidosis. It is the purpose of this report to present the findings in such a unique case, the only example of either pulmonary asbestosis or sarcoidosis in a series of 1870 necropsies done at this hospital.

REPORT OF CASE

The patient was a white male, 42 years of age. Subsequent to hemorrhoidectomy in December, 1943, he had noticed that slight activity produced shortness of breath. He did not experience nocturnal dyspnea and he was able to lie flat in bed without respiratory difficulty. There was no history of cough, hemoptysis, or cardiac embarrassment. Notwithstanding a good appetite and the absence of gastric

* Received for publication, May 9, 1945.

† A sub-department of the Department of Medicine, College of Medicine, University of Cincinnati.

symptoms, there was a weight loss of 22 pounds from December, 1943, to March, 1944, at which time he presented himself for medical care.

The patient had worked in an asbestos plant for 25 years, the last 10 years having been in a supervisory position. During this entire time he had worked in one department in which asbestos pipe was made. There was a slight but appreciable dust hazard associated with the sawing and splitting of the dried asbestos pipe, despite precautionary exhaust ventilation. The total time the patient had spent upon this final operation of sawing was unknown; nor was it learned whether he had been negligent in using the provided respirators. To the company's knowledge, this was their first case of asbestosis.

Physical examination revealed the following findings: Temperature, 37° C.; respiration, 22 per minute; arterial blood pressure, 105/70 mm. Hg; height, 170 cm.; weight, 67 kg. The chest was of increased anteroposterior diameter. Respiratory excursions were equal but decreased. The percussion note was resonant and auscultation revealed fine râles over the bases of the lungs, posteriorly. There were no evidences of cardiac enlargement, irregularity, or decompensation. Cyanosis and clubbing of the fingers were absent. The liver was barely palpable.

Report on the roentgenogram of the chest (Fig. 1) was as follows: "The bony framework is normal. The trachea is in the midline. The hilum shadows are moderately enlarged, bilaterally. One small calcified area is present in each hilum. There are numerous small nodular densities scattered throughout both lung fields, especially throughout the lower lobes. There is some confluence of these densities in the left lower lobe. Emphysema is present."

Examination of the blood showed erythrocytes, 5.5 million; leukocytes, 6.6 thousand; 73 per cent neutrocytes; 21 per cent lymphocytes; 5 per cent monocytes; 1 per cent eosinophils; sedimentation rate, 26 mm. No abnormality was found in the urine. The vital capacity, 2200 cc., was 51 per cent of normal. Tuberculin tests were not done.

The patient was seen at regular intervals and his only complaint was increasingly severe exertional dyspnea. A roentgenogram of the chest 4 months after the initial chest film revealed no new findings. Although the patient greatly limited his activities, dyspnea became progressively more severe so that eventually, even at bed rest, there was extreme air hunger. At no time were there evidences of cardiac failure. He died approximately 11 months after the onset of symptoms, apparently from respiratory failure.

Autopsy Findings

The necropsy was performed 5 hours after death. Superficially, there was considerable decrease in the subcutaneous tissues and the body musculature. There was no clubbing of the nailbeds or dependent edema. The mediastinum was in the midline. Each lung completely filled its hemithorax and extended far into the anterior mediastinal space. The domes of the diaphragm, anteriorly, were at the level of the fourth interspace and fifth rib, right and left respectively.

The lungs were encased in markedly thickened, tough, yellowish white, generally fused pleurae. The interlobar fissures were obliterated by easily broken adhesions. Lobation was normal. Hemorrhagic fibrinous material, present over the posterolateral aspect of the left lower lobe, loosely bound the thickened parietal pleura to the lung in this area.

The frontal section of the left lung (Fig. 3) revealed coarse, lacy, tannish brown, hypercrepitant tissue throughout both lobes. Innumerable slightly elevated, grayish green, irregular, firm nodules, 1 to 2 mm. in diameter, were present throughout the lung. Thin, radiating, fibrous bands surrounded and connected these nodules. Also, slightly thickened pleural septa extended into the lung substance for variable depths. In the lung tissue about the bronchi of the second and third interspaces these nodules were somewhat confluent and a similar change was noted in the subpleural tissues for a depth of 3 to 5 mm. Generally, these nodules, present in moderate numbers, were separated by wide zones of dry emphysematous lung tissue studded by numerous minute, grayish tubercles. Dissection of the bronchi of the lower lobe disclosed that they were moderately dilated, cylindrically and saccularly, and lined by glistening white mucosa.

In the right lung the same changes were observed as were present throughout the left. However, the grayish green, irregular nodules tended to be more numerous, larger, and more confluent. This was particularly true of the anterior portions of the lower and middle lobes. Also, the nodules were connected by thicker grayish black and grayish white interlacing bands of fibrous tissue. Extending deeply into the lung substance, thickened pleural septa communicated with the fibrous tissue in and about the clusters of tubercles. Except for more pronounced dilatation and thinning of the mucosa, the bronchi of the right lung were similar to those of the left.

The tracheobronchial lymph nodes were moderately enlarged and on section consisted of dense, rubbery, anthracotic centers and thin rims of yellowish white tissue. Calcification was not grossly demonstrable.

The embalmed heart weighed 280 gm. and had the following measurements: tricuspid valve, 120 mm.; pulmonary valve, 80 mm.; mitral valve, 85 mm.; aortic valve, 65 mm.; right ventricle wall, 3 to 8 mm.; left ventricle wall, 15 mm. The greatest transverse cardiac diameter was 13.5 cm. (The estimated normal heart weight on the basis of body length is 317 gm., plus or minus 40.[22]) The tricuspid/aortic valve and pulmonic/aortic valve ratios were 1.84 and 1.23, respectively. (These normally should be 1.68 and 1.05, respectively.[23]) The right ventricle was dilated and its columnae carneae and papillary muscles were more prominent than usual. No mural thrombi were demonstrable and the valvular endocardium was normal.

The enlarged spleen was of normal configuration and measured 18 by 9 by 6 cm. It was covered by a smooth capsule and the splenic

substance was firm and purplish red with normal markings. No tubercles were seen. The liver measured 22 by 16 by 10 cm. The remaining organs showed passive hyperemia and moderate generalized arteriosclerosis.

Microscopic Findings

Throughout the lung there was a conspicuous linear, interlacing, peribronchial and septal pulmonary fibrosis (Fig. 2). This was particularly prominent in the subpleural tissues. The intervening lung tissue was moderately emphysematous. Innumerable tubercles were present in the linear and peribronchial fibrotic areas and were present to a lesser extent in the walls of the respiratory bronchioles and the adjacent alveolar walls. Generally, these tubercles were of two types: sarcoidal and foreign body granulomas. The former predominated by approximately ten to one. Tubercles of these types were intimately associated and, in addition, many intermediate types were presented.

The sarcoidal tubercles (Fig. 4) were free of caseation, contained no demonstrable organisms and were, for the most part, in the same stage of development; however, a minimal number presented some peripheral fibrosis and there was an occasional, coarse, collagenous ball. Generally, the tubercles were sharply demarcated, surrounded by delicate reticulum, and did not present peripheral rims of lymphocytes. They consisted of peripherally arranged epithelioid cells surrounding central, loosely arranged epithelioid and monocytic cells. Giant cells were, for the most part, centrally located and often comprised over half of the bulk of the nodule. The giant cells appeared to be of two types: Langhans' cells and foreign body giant cells, with the former predominating. In many of the Langhans' cells there were numerous small vacuoles, each containing a pink, round body. Other Langhans' cells contained large, clear vacuoles; and, rarely, in those cells containing one large vacuole there was present an "asteroid" body, an intensely eosinophilic stellate mass, 15 to 20 μ in diameter (Fig. 5).

More frequently, the Langhans' cells contained round, oval, or suggestively budding, intracytoplasmic bodies of Schaumann,* 25 to 50 μ in diameter. Rarely, these bodies appeared to lie outside of giant cells, and some enclosed irregular yellowish material (Figs. 6 and 7). These bodies stained blue with hematoxylin and in ferrocyanide preparations were strongly positive for iron. Dr. Leroy U. Gardner,[24] who also studied this case, stated that these bodies stained "red with acid fuchsin of van Gieson-Weigert instead of black like elastic tissue"

* Schaumann, J. On the nature of certain peculiar corpuscles present in tissue of lymphogranulomatosis benigna. *Acta med. Scandinav.*, 1941, 106, 239–253.

and that "von Kossa's calcium stain is negative." Re-study of appropriately stained sections revealed, as pointed out by Gardner, that the Schaumann bodies did stain red; however, a moderate number also contained calcium in variable degrees, as demonstrated by von Kossa's stain. An occasional giant cell contained one or more clefts suggestive of cholesterol crystals. More frequently, however, doubly refractile, irregular spicules, plaques, and conchoidal masses were observed in giant cells. These doubly refractile masses were often about, or in, the Schaumann bodies, particularly the smaller and partially calcified forms.

The foreign body tubercles were indefinitely demarcated and consisted of rather closely packed, indefinitely arranged, large monocytes, and one or more foreign body giant cells. These tubercles, for the most part, were within the dense zones of fibrosis. Some, however, were present in alveoli and respiratory bronchioles. Golden yellow discoid, verruciform, and incompletely segmented asbestos bodies, many of which were in giant cells, were observed in and about the nodules (Fig. 8). Asbestos bodies, singly or in clusters and in moderate numbers, were present also in the dense fibrotic areas (Fig. 9) and occasionally within alveoli (Fig. 10). Rare, laminated, calcified masses, enclosing apparent asbestos bodies (Fig. 11) and other bodies which appeared to be of the Schaumann variety, were present in the linear fibrotic bands. Asbestos bodies were also encountered in and about the sarcoidal tubercles and in the associated sarcoidal giant cells of both varieties, but more frequently in those of foreign body type. Iron preparations clearly demonstrated the bizarre forms of the asbestos bodies.

In many areas it was difficult to distinguish between the two types of lesions. This was particularly true throughout the subpleural region where both the lesions and asbestos bodies were more numerous, clustered, and embedded in a dense matrix of collagen, masses of coarse elastic fibers, and fine reticulum.

The larger bronchi were remarkable only for slight chronic inflammation. The bronchioles and respiratory bronchioles, embedded in dense collagen and surrounded by tubercles, were moderately dilated and presented conspicuous focal squamous metaplasia and moderate chronic submucosal inflammation. In the subpleural regions where the asbestotic fibrosis and the granulomatous reaction were most intense, the bronchioles were irregularly dilated and lined by alternating strips of tall columnar and squamous epithelium. Only a few bronchioles contained neutrocytic exudate. The respiratory bronchioles were generally constricted, surrounded by masses of elastica, and

many contained asbestos bodies and the associated granulomatous reaction. Within the peribronchial fibrous tissue there was a moderate amount of hemosiderin in linearly disposed granules, and fine lipoid droplets. The small pulmonary arteries and arterioles presented slight intimal thickening, and those in the subpleural zone were surrounded by thick collars of elastic fibers.

The intervening alveoli were moderately dilated, the capillaries were congested, and there was a slight increase in collagen in the alveolar walls bordering the fibrous masses. Focally, clusters of alveoli contained lipoid-laden macrophages. "Heart lesion cells" were infrequent.

Sections of the pleura revealed dense, laminated, and oval fenestrated bundles of collagen. Focally, there were indefinitely demarcated nodules which consisted of circularly disposed lamellae of collagen. Superficially, the pleura presented slight fibroblastic activity and an occasional perivascular accumulation of lymphocytes and monocytes, some of the latter occasionally containing hemosiderin. No asbestos bodies were observed. The pleura over the left lower lobe, in addition, bore organizing fibrinous exudate on its visceral aspect.

Sections of the tracheobronchial lymph nodes presented a repetitious pattern of sarcoidal tubercles with almost complete replacement of the lymphoid tissue. Throughout the nodes there were minimal diffuse fibrosis and several nodular masses of coarse collagen. The tubercles were similar to those in the lung as to structure and stage of development. Inclusions of Schaumann were not observed and only a rare "asteroid" was present. Asbestos bodies were not identified. A moderate number of hemosiderin-containing macrophages were present in the remaining lymphoid tissue.

Similar sarcoidal tubercles were present to a slight degree in the spleen and liver, and to a lesser extent in the kidneys, diaphragmatic muscle, and the right and left ventricular myocardium. These sarcoidal tubercles, however, were not as compactly arranged as those in the lung and tracheobronchial lymph nodes, and were surrounded by and permeated by lymphocytes. "Asteroid bodies" and Schaumann bodies were not present in the giant cells of these tubercles. No asbestos bodies were found. Those in the right ventricular myocardium were associated with considerable fibrosis.

The results of chemical and spectrographic analysis of lung tissue, performed under the direction of Dr. Leroy U. Gardner,[24] are presented in Table I.

The final diagnoses were: Moderate pulmonary asbestosis; extensive sarcoidosis of pulmonary and tracheobronchial lymph nodes; marked chronic pulmonary emphysema; slight sclerosis of the small

arteries and arterioles in the lungs; marked nodular obliterative pleural fibrosis; focal organizing fibrinous pleuritis; minimal sarcoidosis of the heart, liver, spleen, and kidneys; right ventricular cardiac dilatation and relative right ventricular hypertrophy; acute passive hyperemia of the viscera; slight cirrhosis of the liver; slight generalized arteriosclerosis; minimal focal chronic adrenalitis and nephritis; chronic posterior urethritis and interstitial prostatitis.

TABLE I

Chemical and Spectrographic Analysis of Ash
(Dry Tissue, Approximately 14.2% of Moist Tissue. Ash, 6.70% of Dry Tissue.)

As oxides (except Cl)		As elements		
Chemical analysis			Chemical analysis	Spectrographic analysis
	Per cent		*Per cent*	*Arbitrary scale of relative amounts*
Cu, Ag, Hg				
Pb, Bi, Cd	<0.15	Na	4	75
Mo		K	36.7	100
SiO_2	2.76	Sr	None found	1.5
Fe_2O_3	8.03	Ba	None found	5
Al_2O_3	0.37	Ca	2.1	80
BeO	None found	Al	0.2	50
ZnO	0.39	Mg	0.7	75
MnO	0.03	P	8.0	60
CaO	2.92	Si	1.3	100
MgO	1.18	Fe	5.6	75
BaO	None found	Mn	0.02	3
SrO	None found	Ti	None found	5
TiO_2	None found	Cu		25
V_2O_5	None found	Ag		2
Cr_2O_3	0.07	Sn		3
NiO, CoO	<0.05	Cr	0.05	3
Na_2O	5.44	B		1
K_2O	44.40	Be	None found	0
P_2O_5	18.42	Pb		25
Cl	4.61	Zn	0.3	5
CO_2	Present	Bi		10
		Pt		3
		Cl	4.6	0
Total	88.82			

DISCUSSION

Clinically, in view of the significant history of exposure to asbestos, the possibility of sarcoidosis was never entertained. In retrospect, the rapidly progressive, disabling dyspnea, unaccompanied by evidences of enlargement of the right heart or cardiac failure, should have aroused suspicion that there was a concomitant pulmonary lesion. Asbestosis alone is not usually accompanied by such profound, rapidly developing, respiratory embarrassment. In this case, however, there were no collateral clinical evidences of sarcoidosis. It would seem that a clinical diagnosis of coexistent asbestosis and sarcoidosis would be justified only by biopsy of a lymph node or a skin lesion to demon-

strate sarcoid lesions and the discovery of asbestos fibers in the sputum, with a history of adequate exposure to asbestos fibers and roentgenographic evidences of diffuse pulmonary fibrosis. Asbestosis of the degree observed, alone should not have caused death, and sarcoidosis has generally been regarded as a benign process. Reisner,[18] however, on the basis of his observations on cases of pulmonary sarcoidosis, stated "that one is not justified in assuming too confident an attitude regarding the ultimate outcome." This statement is particularly true when, as in this case, sarcoidosis complicates pre-existing pulmonary disease.

Pathologically, there were evidences of right heart strain in that there was marked dilatation of the right heart, evidenced by increased tricuspid and pulmonic/aortic valve ratios and slight passive hyperemia of the viscera. The total heart weight, however, on the basis of body length,[22] was normal. As determined by the ratio of the left and right ventricular weights, it has been shown that there may be considerable relative right ventricular hypertrophy without an increase in the total heart weight. However, relative right ventricular cardiac hypertrophy in Higgins' series [23] was not usually accompanied by evidences of right ventricular failure. In view of the significant dilatation of the right side of the heart and the slight sclerosis of the pulmonary arterioles, there was, in all probability, some degree of pulmonary hypertension in this case. However, in the absence of an increase in total heart weight and in the absence of evidences of chronic passive hyperemia of the viscera there was probably no, or insignificant, exaggeration of air hunger due to heart failure.

It has been suggested that dyspnea in the pneumoconioses is due to capillary and arterial blockage by the fibrotic process. This, in all probability, is true to a variable degree in those persons with severe fibrosis of the conglomerate type with attendant extreme chronic emphysema. This hypothesis, however, does not explain the severe dyspnea that is seen in occasional cases of diffuse miliary studding of the framework of the lung by silicotic, tuberculous, sarcoidal, or neoplastic tubercles. It may be that the mechanism of dyspnea in such instances is due to irritation of the vagus nerve endings with reflex stimulation of the respiratory center (Hering-Breuer reflex). In view of the equivocal evidences of hypertrophy of the right heart in this case, mechanical obstruction to the blood flow would not appear to be the responsible factor but, more likely, because of the diffuse active inflammatory process throughout the lungs, the Hering-Breuer reflex was exaggerated. Presumably, there was either a severe re-

spiratory alkalosis or acidosis. Tissue changes suggestive of alkalosis, such as calcification of the renal tubules, were not found.

Microscopically, there was some difficulty in differentiating the two types of tubercles since there were many sarcoidal tubercles which contained asbestos fibers, and tubercles of indeterminate type, not containing fibers or inclusion bodies, were sometimes seen. It was difficult to determine how much of the fibrosis was due to asbestosis. Morphologically, since the majority, by far, of the sarcoidal tubercles were without evidences of fibrosis and apparently of the same age, it is suggested that this process was engrafted upon an established asbestosis. Further, on the basis of Gardner and Cummings' [26] experimental studies on asbestosis, the marked peribronchiolar fibrosis with sequestrated asbestos bodies, the marked pleural fibrosis and pleural septal fibrosis, and the metaplasia of the bronchiolar epithelium indicate that the asbestosis was well established and over 700 to 800 days old. Dr. Leroy U. Gardner, who kindly examined the material, stated: "In comparison with our other material the pigmented foci in your case seem to show more fibrosis and less localized emphysema. Histologically, this can probably be explained by the presence of sarcoid nodules within the asbestotic zones of reaction. I would infer that in your case the two conditions developed more or less simultaneously, but that probably the asbestosis was present to some degree before the sarcoid appeared. This opinion is based upon the occurrence of asbestos fibers and other iron-containing particles in the interior of the tubercle-like nodules and in some cases within the giant cells themselves. The number of asbestos bodies is smaller than seen in many cases."

Inclusions of the Schaumann variety, found only in the lung, occurred in 4 per cent of the giant cells. Some of these enclosed golden-yellow, irregular bodies suggesting asbestos bodies, but similar to organic material previously described within such bodies. Yet there were definite asbestos bodies enclosed by similar dark blue material. Schaumann inclusions have been described in only 4 per cent of the reported necropsies on sarcoidosis as summarized by Rubin and Pinner,[17] who did not regard these inclusions as specific for sarcoidosis. Rich,[27] who was impressed by the frequency of Schaumann inclusions in sarcoidal lesions and by their absence in unequivocal tuberculous lesions, noted that Metchnikoff reported the presence of calcified inclusions in the hyperplastic tuberculous lesions of experimentally infected Algerian rats. Kraus [20] stated that the presence of calcified inclusions was a feature not found in any known granuloma except

sarcoidosis. Gardner [24] pointed out that, in his sarcoid material, these bodies, regarded by many to consist of calcium or calcified remnants of elastica, do not, by the von Kossa method, contain calcium, but, by the ferrocyanide method, give a strong reaction for iron. Only a moderate number of the Schaumann bodies observed in the present case were either wholly or partially calcified, yet all gave a strong reaction for iron. Studies on sarcoid lesions of lymph nodes and spleen from another case revealed only a few iron-staining noncalcified Schaumann bodies. The presence of doubly refractile, nonlipoid substance in giant cells and frequently in close relation to Schaumann bodies has not been emphasized in the literature on sarcoidosis. It has been noted, however, that colorless and yellowish tinged refractile material is often enclosed by the Schaumann body. The fact that these masses are frequently doubly refractile has not been stressed. It has been suggested that these enclosed masses represent disintegrating elastica; however, van Gieson-Weigert stains do not confirm this suggestion. The origin of this refractile and doubly refractile material is not known. Being in and about many of the small, partially calcified bodies, this doubly refractile material appears to be associated with the development of the Schaumann body. The larger and more densely stained bodies were not as frequently associated with visible doubly refractile substance. However, fractured and fragmented, apparently old, Schaumann bodies, as seen in control sarcoid material from lymph node and spleen, usually contained moderate amounts of doubly refractile substance. Apparently then, the Schaumann body, which stains blue with hematoxylin and red with acid fuchsin, is formed in response to doubly refractile, nonlipoid substance and initially is impregnated by iron and later, in amounts demonstrable by von Kossa's stain, by calcium.

Wolbach,[21] in 1911, Jadassohn, in 1919,[23] and Friedman,[19] in 1944, have described a peculiar intracellular body in cases of sarcoidosis. This body, stellate in shape, varies in size up to 25 μ, generally lies in an intracytoplasmic giant cell vacuole, and stains intensely with acidophilic stains except the central area which is basophilic. Wolbach described them as lying free in tissue spaces, in endothelial leukocytes, and in giant cells. Friedman found such bodies in only 6 to 8 per cent of the giant cells in his case. Both investigators attempted to determine the chemical structure of this stellate body by specific stains; however, they were unsuccessful. Both considered the possibility of its being an extraneous organism, although questionable. Wolbach regarded it as a nonspecific biochemical alteration of the cytoplasm. He was never able to demonstrate stellate bodies in other

material and decided that they were not similar to inclusions sometimes seen in cases of sarcoma. Friedman regarded these bodies as nonspecific but highly characteristic of sarcoid lesions. Friedman proposed that these bodies be called "asteroids," but perhaps it would be better, eponymically, to call them Wolbach's asteroids. They have been described in 7 cases of sarcoidosis, and never in association with the Schaumann calcified inclusion body. In the present case asteroids were present in approximately 1 per cent of the giant cells in the lungs and tracheobronchial lymph nodes. Definite transition stages of asteroid formation were suggested by the presence of spicules on the pink, coccoid, intravacuolar, intracytoplasmic bodies, particularly in those giant cells in which the small vacuoles were clustered and disintegrating. In addition, an occasional Wolbach's asteroid, instead of lying in a large, clear vacuole, was surrounded by agminated ruptured vacuoles. In view of the presence of similar pink, coccoid, intravacuolar bodies, similar asteroids, and the same suggestive stages of asteroid formation in the giant cells of talcum powder granuloma, as observed in one case in this laboratory, these giant cell cytoplasmic changes must be regarded as Wolbach originally suggested, nonspecific biochemical cytoplasmic alterations. In addition, such an asteroid is depicted in the giant cells of leprous lesions by Mallory [29] who called them "spiculated" bodies. No transition stages between Wolbach's asteroids and Schaumann's inclusions were even remotely suggested.

The pathogenetic relationships of asbestosis and sarcoidosis are dependent upon the chronologic development of the lesions and the nature of the causative agents. Historically and histologically, in this case, it is most likely that asbestosis preceded the development of sarcoidosis. The predominant localization of the sarcoidal tubercles within asbestotic zones of fibrosis with attendant morphologic modification of both lesions, as evidenced by asbestos bodies within sarcoidal tubercles and lesions of indeterminate type, would suggest an analogy to the intimate relationship existent between tuberculosis and the pneumoconioses. It must be remembered, though, that even in uncomplicated sarcoidosis the lesions occur in the framework of the lung, and therefore the morphologic relationships of the two may be coincidental. This would be in agreement with those who believe that morphologically sarcoid is not reconcilable with tuberculosis. However, to those who regard sarcoidosis as a peculiar form of tuberculosis, this case then would be one of asbestosis with superimposed noncaseating tuberculosis.

The authors are indebted to Dr. Leroy U. Gardner who critically examined the gross and microscopic material of this case and supplied the chemical analysis.

REFERENCES

1. Gloyne, S. R., and Merewether, E. R. A. Asbestos. Occupation and Health Supplement. International Labour Office, Geneva, 1938. (Cited by Sayers, R. R., and Dreessen, W. C. Asbestosis. *Am. J. Pub. Health*, 1939, 29, 205–214.)
2. Murray, M. Cited by Egbert.[5] (*Charing Cross Hosp. Gaz.*, 1900. Also: Departmental Committee on Compensation for Industrial Diseases. Minutes of Evidence, Appendices and Index, 1907. Cd. 3496, p. 127; Report, 1907. Cd. 3495, p. 14.)
3. Fahr, T., and Feigel. Kristallbildung in der Lunge. *Deutsche med. Wchnschr.*, 1914, 40, 1548–1549. (Cited by Egbert.[5])
4. Cooke, W. E. Pulmonary asbestosis. *Brit. M. J.*, 1927, 2, 1024–1025. McDonald, S. Histology of pulmonary asbestosis. *Ibid.*, 1927, 2, 1025–1026. (Cited by Egbert.[5])
5. Egbert, D. S. Pulmonary asbestosis. Report of a case with necropsy findings. *Am. Rev. Tuberc.*, 1935, 31, 25–34.
6. Shull, J. R. Asbestosis. A roentgenological review of 71 cases. *Radiology*, 1936, 27, 279–292.
7. Lanza, A. J. Asbestosis. *J. A. M. A.*, 1936, 106, 368–369.
8. Lynch, K. M. Pulmonary asbestosis. IV. The asbestosis body and similar objects in the lung. *J. A. M. A.*, 1937, 109, 1974–1978.
9. Williams, E. The presence of "curious bodies" in the lungs of South African goldminers. *J. Path. & Bact.*, 1939, 48, 475–477.
10. Sutherland, C. L. Tuberculosis in the silica-risk industries. *Lancet*, 1940, 1, 893–896.
11. Hannesson, H. A case of pulmonary asbestosis accompanied by pulmonary tuberculosis. *Tubercle*, 1941, 22, 40–44.
12. Homburger, F. The co-incidence of primary carcinoma of the lungs and pulmonary asbestosis. Analysis of literature and report of three cases. *Am. J. Path.*, 1943, 19, 797–807.
13. Auerbach, O. The pathology of the pneumoconiosis. *Quart. Bull., Sea View Hosp.*, 1936–37, 2, 3–27.
14. Monthly Labor Review, U.S. Department of Labor, Bureau of Labor Statistics, 1946, 62, p. 153, table 2.
15. Pinner, M. Noncaseating tuberculosis. An analysis of the literature. *Am. Rev. Tuberc.*, 1938, 37, 690–728.
16. Horton, R., Lincoln, N. S., and Pinner, M. Noncaseating tuberculosis. *Am. Rev. Tuberc.*, 1939, 39, 186–203.
17. Rubin, E. H., and Pinner, M. Sarcoidosis. One case report and literature review of autopsied cases. *Am. Rev. Tuberc.*, 1944, 49, 147–169.
18. Reisner, D. Boeck's sarcoid and systemic sarcoidosis (Besnier-Boeck-Schaumann disease): study of 35 cases. *Am. Rev. Tuberc.*, 1944, 49, 289–307; 437–462.
19. Friedman, M. Sarcoidosis of the spleen. Report of a case with autopsy and a study of intracellular "asteroid bodies." *Am. J. Path.*, 1944, 20, 621–635.
20. Kraus, E. J. Sarcoidosis (Boeck-Besnier-Schaumann disease) as the cause of a pituitary syndrome. *J. Lab. & Clin. Med.*, 1942, 28, 140–146.
21. Wolbach, S. B. A new type of cell inclusion, not parasitic, associated with disseminated granulomatous lesions. *J. M. Research*, 1911, 24, 243–257.
22. Zeek, P. M. Heart weight. I. The weight of the normal human heart. *Arch. Path.*, 1942, 34, 820–832.
23. Mallory, F. B. Pathological Technique. W. B. Saunders Co., Philadelphia & London, 1938, p. 374.

24. Gardner, L. U. Personal communication.
25. Higgins, G. K. The effect of pulmonary tuberculosis upon the weight of the heart. *Am. Rev. Tuberc.*, 1944, 49, 255–275.
26. Gardner, L. U., and Cummings, D. E. Studies on experimental pneumonokoniosis. VI. Inhalation of asbestos dust: its effect upon primary tuberculous infection. *J. Indust. Hyg. & Toxicol.*, 1931, 13, 65–81.
27. Rich, A. R. The Pathogenesis of Tuberculosis. C. C. Thomas, Springfield & Baltimore, 1944, p. 722.
28. Jadassohn. Zur Frage der "Sarcoide," des Lupus pernio und des Lupus miliaris in Kombination mit "Acnitis." *Cor.-Bl. f. schweiz. Aerzte*, 1919, 49, 455–458.
29. Mallory, F. B. The Principles of Pathologic Histology. W. B. Saunders Co., Philadelphia & London, 1918, p. 207.

[*Illustrations follow*]



1

DESCRIPTION OF PLATES

PLATE 103

FIG. 1. Initial roentgenogram of the chest.

FIG. 2. Photomicrograph of lung and adherent pleura showing subpleural, septal, peribronchiolar, and marked and focally nodular pleural fibrosis. × 4.



PLATES

1

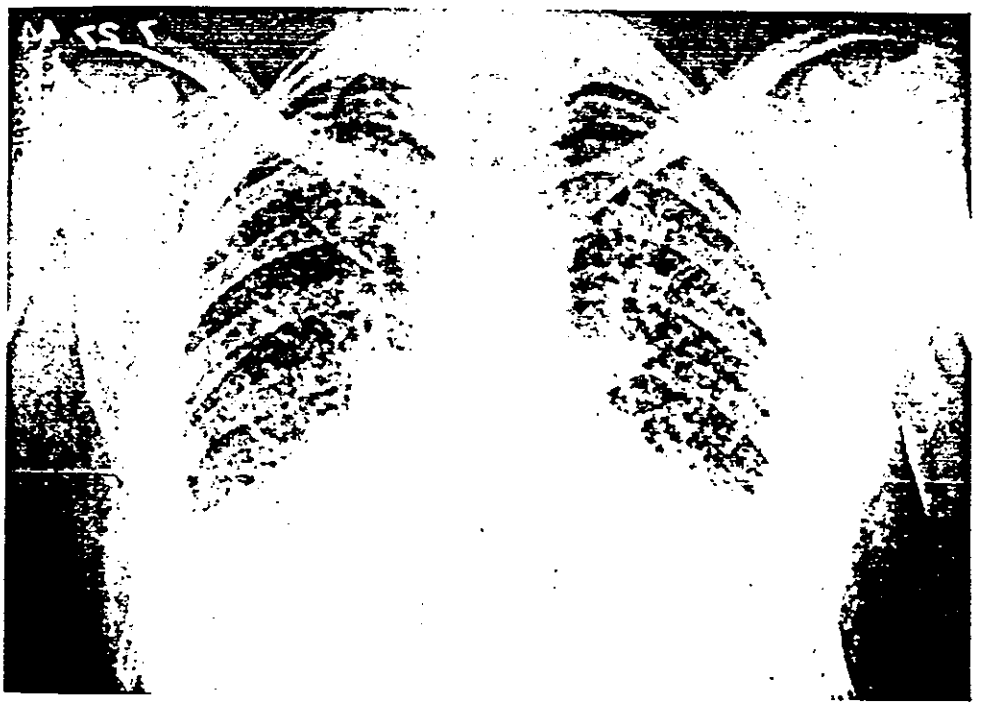

t ra showing subpleural, septal, ocular pleural fibrosis. × 4.

2



Skavlem and Ritterhoff

Coexistent Asbestosis and Sarcoidosis



PLATE 104

FIG. 3. Frontal section of left lung.

Skavlem and Ritterhoff

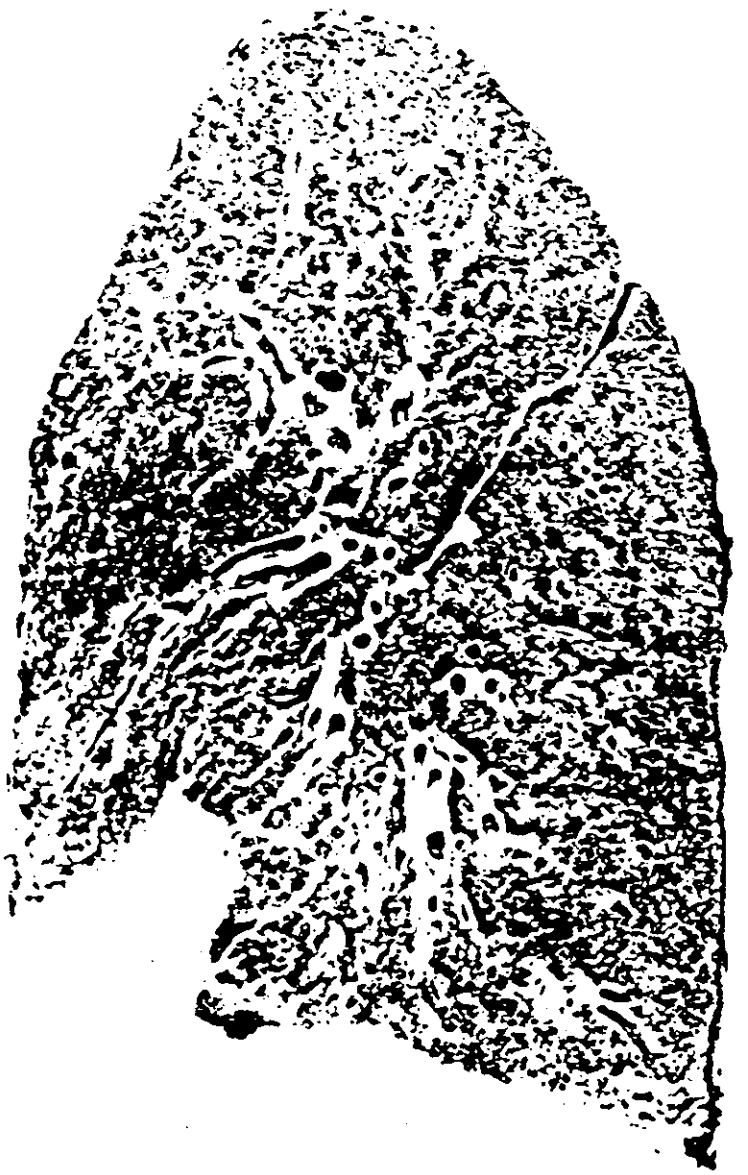

Skavlem and Ritterhoff

3

Coexistent Asbestosis and Sarcoidosis



4



5

PLATE 105

FIG. 4. Lung, showing a cluster of sarcoidal tubercles. × 160.

FIG. 5. Lung. The giant cell which nearly fills the field contains an "asteroid" in an intracytoplasmic vacuole. × 1090.

Skavlem and Ritterhoff



4

× 160.

d contains an "asteroid" in



5

Skavlem and Ritterhoff Coexistent Asbestosis and Sarcoidosis



6

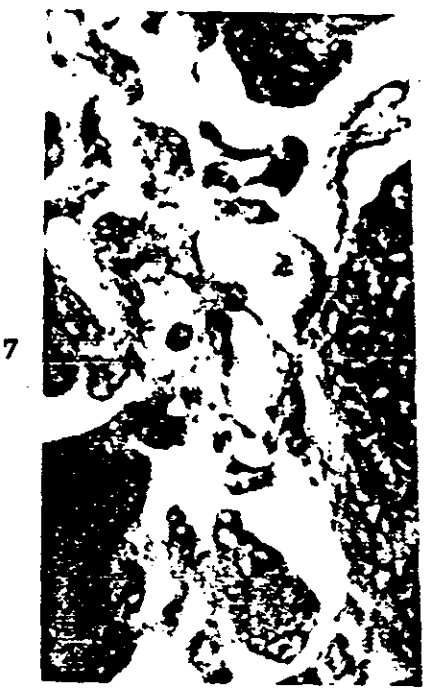

7

PLATE 106

FIG. 6. Lung. An inclusion of Schaumann encloses an oval yellow body. With polarized light, doubly refractile material surrounds this calcified mass. × 725.

FIG. 7. A giant cell from the lung with inclusions of Schaumann. × 725.

Skavlem and Ritterhoff

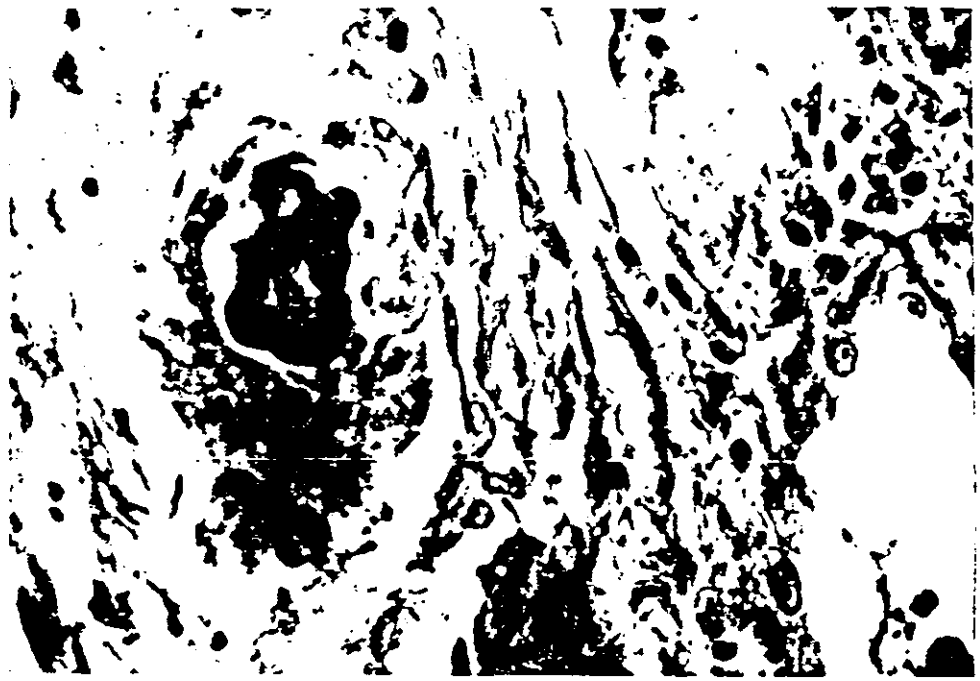

6

es an oval yellow body. With
unds this calcified mass. × 725.

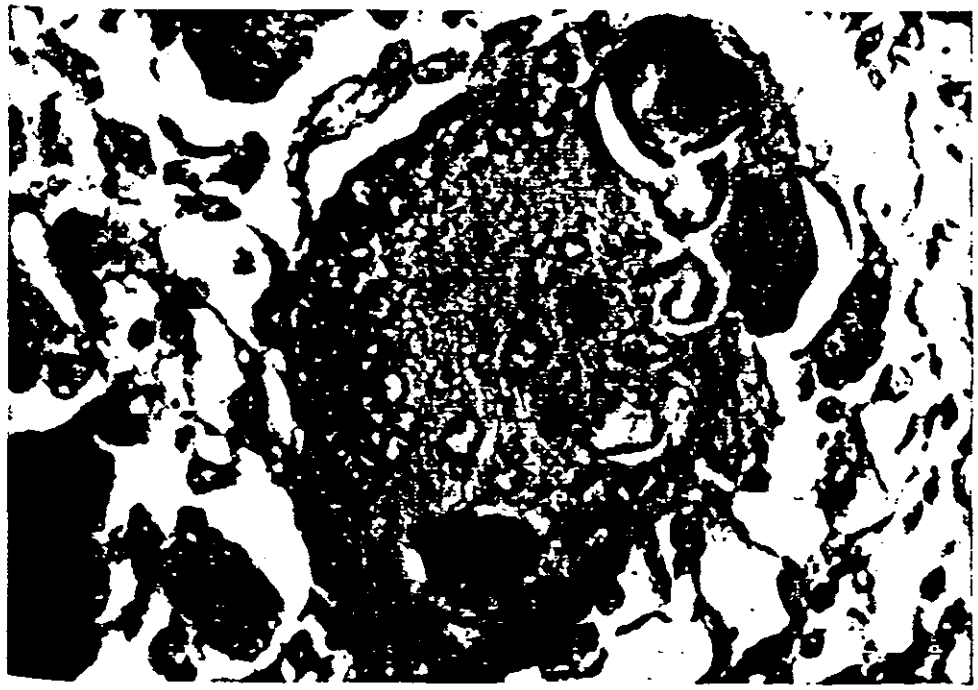

7

of Schaumann. × 725.

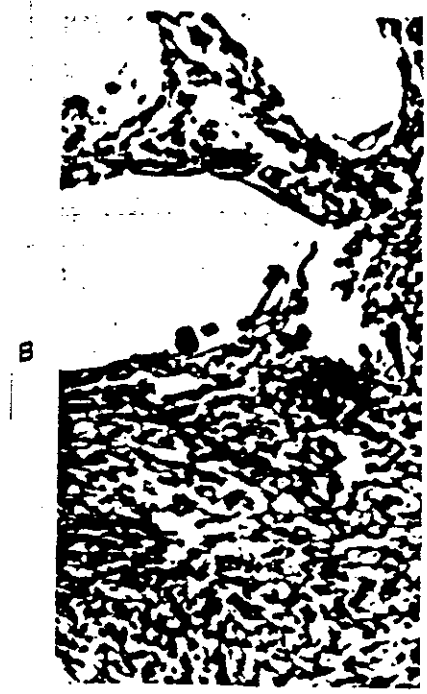

8



9

Skavlem and Ritterhoff

PLATE 107

FIG. 8. Lung with tubercles of foreign body type. The central tubercle has an asbestos body at its periphery. × 160.

FIG. 9. Lung showing asbestos bodies and clusters of hemosiderin-laden macrophages within an area of fibrosis. × 725.



8



9

Skavlem and Ritterhoff

Coexistent Asbestosis and Sarcoidosis



10



11

PLATE 108

FIG. 10. Lung. An asbestos body is shown in an alveolus. × 725.

FIG. 11. Lung showing an asbestos body encrusted with iron and calcium. × 725.

Skavlem and Ritterhoff

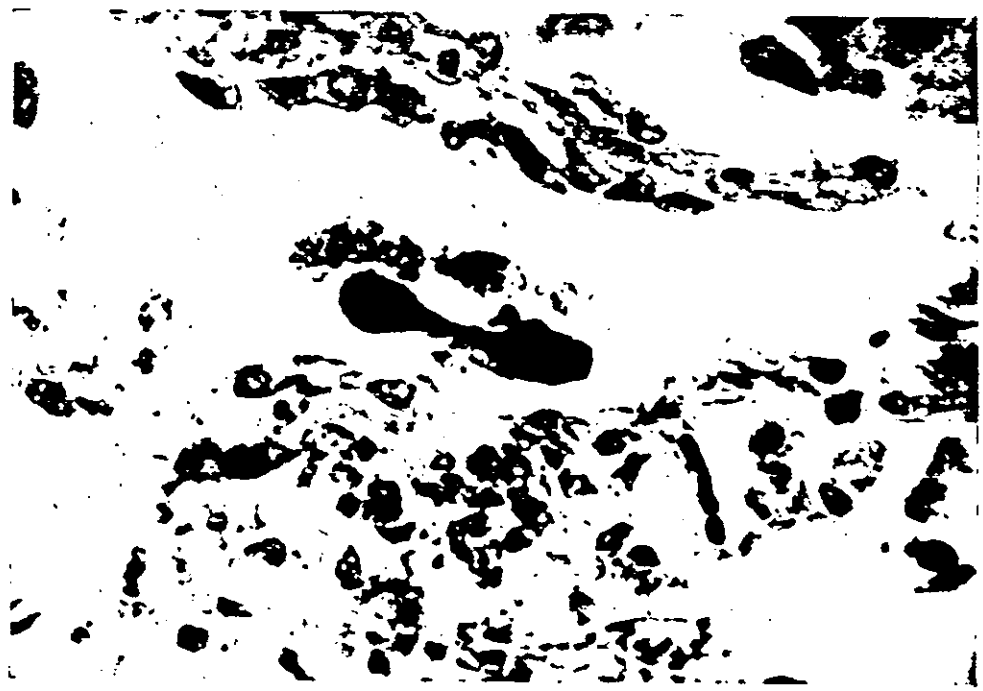

10

alveolus. × 725.

ed with iron and calcium. × 725.

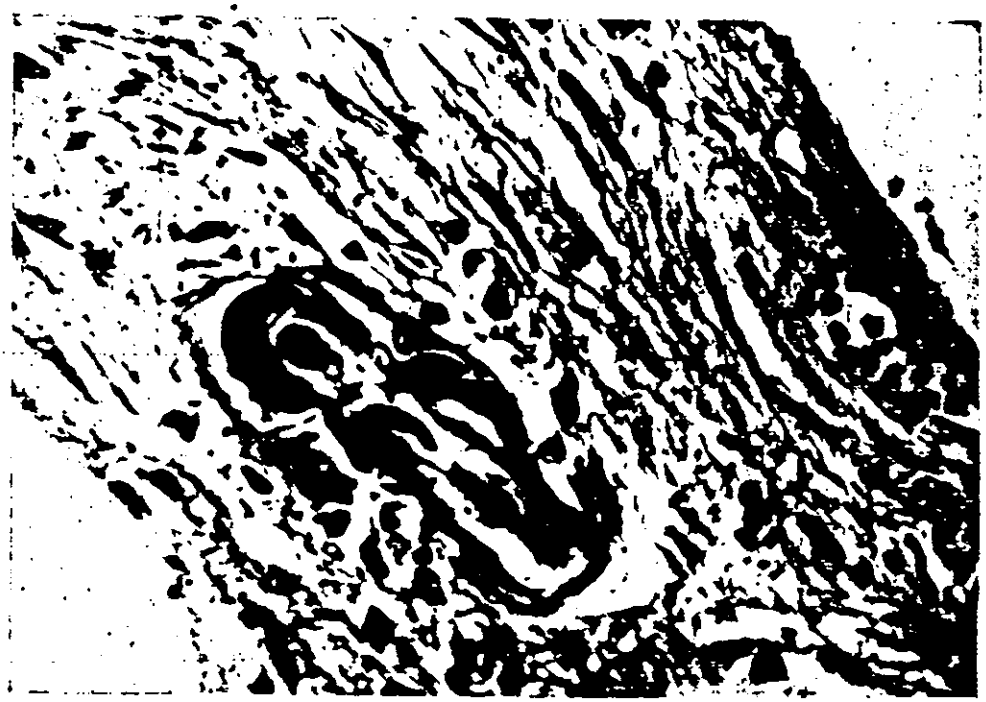

11

Skavlem and Ritterhoff Coexistent Asbestosis and Sarcoidosis