Industrial BIO-TEST Laboratories, Inc
1810 FRONTAGE ROAD
NORTHBROOK ILLINOIS 60062

REPORT TO

MONSANTO COMPANY

TWO - YEAR CHRONIC ORAL TOXICITY STUDY WITH AROCLOR 1260 IN ALBINO RATS

HISTOPATHOLOGICAL EVALUATION OF ADDITIONAL LIVER SECTIONS

MARCH 24, 1975

IBT NO. 641 - 06672

Industrial BIO-TEST Laboratories, Inc

REPORT TO

MONSANTO COMPANY

TWO - YEAR CHRONIC ORAL TOXICITY STUDY WITH AROCLOR 1260 IN ALBINO RATS

HISTOPATHOLOGICAL EVALUATION OF ADDITIONAL LIVER SECTIONS

MARCH 24, 1975

IBT NO. 641 - 06672

I. Introduction

At the request of Dr. Levinskas of the Monsanto Company, additional sections of liver from a two - year chronic oral toxicity study of Aroclor 1260 in rats (IBT No. 622-07298) were processed into H & E stained sections and evaluated by light microscopy. The following report presents the results of this study.

II. Summary

In most instances, the spectrum of treatment-related histopathological findings in the liver from this re-evaluation did not differ significantly from that previously reported in our original report dated November 12, 1971. There were seven hepatomas detected among seven of the animals at the highest treatment level (100 ppm) of the 24-Month Sacrifice. No hepatocellular carcinomas were observed. The other treatment-related lesions reported are regarded as degenerative or hyperplastic in nature and they are morphologic manifestations of an adaptive response of the liver associated with biotransformation of the test material. In general, the latter findings were confined primarily to test animals of the 6-, 12- and 24-Month Sacrifices, and they were dose-related in incidence and severity.

In conclusion, Aroclor 1260 does not appear to be carcinogenic in rats fed for two years at levels up to and including 100 ppm.

Respectfully submitted,

INDUSTRIAL BIO-TEST LABORATORIES, INC.

Report Prepared and Reviewed by:

D. E. Gordon, D.V.M., Ph.D.
Section Head, Pathology

Report Approved by:

M. L. Keplinger, Ph.D.
Manager, Toxicology

IBT No. 622-07298
Monsanto

I have examined additional sections of liver from rats of IBT No 622-07298 and have re-evaluated them for evidence of carcinogenesis. I have tabulated my findings for Aroclor 1260 on the following pages.

There is evidence of a chemical effect on the liver which was most evident at time of the 12-Month and terminal (24-Month) sacrifices. This consists of a hepatocellular alteration beginning as focal hypertrophy which progresses to nodular hyperplasia, and in a few animals, to hepatoma or cholangiohepatoma The hypertrophic cells contain large amounts of light staining cytoplasm which is probably rich in glycogen and endoplasmic reticulum. In some cases, ring-shaped structures, probably representing whorls of proliferative endoplasmic reticulum, were seen in the cytoplasm of these cells.

The hyperplastic nodules occupied larger areas and often compressed surrounding cells of the normal liver parenchyma. They also contained the same hypertrophic cells.

Those lesions classified as hepatomas or cholangiohepatomas were larger nodules which showed evidence of confluence or some variation in cell size, shape, staining or a ductular or adenomatous pattern of growth. In the absence of metastasis, invasiveness, severe basophilia, mitoses or other evidence of anaplasia, these are benign tumors rather than malignant carcinomas. There was no evidence of metastasis or invasiveness of these tumors in this study.

With exception of the vacuolar changes in the cytoplasm of hepatocytes, the more severe hepatocellular alterations were confined to animals of the 12- and 24-Month Sacrifice periods.

Ward R. Richter

Ward R. Richter D. V. M., M. S.
Diplomate American College of
Veterinary Pathologists

Primary Liver Lesions - Aroclor 1260

3 Month Sacrifice - Rats

Lesion	Group			
	TI	TII	THI	Contro
Vacuolar Change	0/11	4/10	3/10	2/10
Focal Hypertrophy	0/11	0/10	2/10	0/10
Nodular Hyperplasia	0/11	0/10	0/10	0/10
Hepatoma	0/11	0/10	0/10	0/10
Ductular Hyperplasia	0/11	1/10	0/10	0/10
Cholangio-Hepatoma	0/11	0/10	0/10	0/10
Hepatocellular Necrosis	0/11	0/10	0/10	0/10

Primary Liver Lesions - Aroclor 1260

6 Month Sacrifice - Rats

Lesion	Group			
	TI	TII	TIII	Control
Vacuolar Change	1/6	2/5	5/9	1/10
Focal Hypertrophy	0/6	0/5	3/9	0/10
Nodular Hyperplasia	0/6	0/5	0/9	0/10
Hepatoma	0/6	0/5	0/9	0/10
Ductular Hyperplasia	0/6	0/5	0/9	0/10
Cholangio-Hepatoma	0/6	0/5	0/9	0/10
Hepatocellular Necrosis	0/6	1/5	0/9	1/10

Primary Liver Lesions - Aroclor 1260

12 Month Sacrifice - Rats

Lesion	Group			
	TI	TII	TIII	Control
Vacuolar Change	2/9	5/10	3/9	1/10
Focal Hypertrophy	0/9	0/10	4/9	0/10
Nodular Hyperplasia	0/9	0/10	1/9	0/10
Hepatoma	0/9	0/10	0/9	0/10
Ductular Hyperplasia	1/9	0/10	2/9	1/10
Cholangio-Hepatoma	0/9	0/10	0/9	0/10
Hepatocellular Necrosis	0/9	0/10	0/9	0/10

Primary Liver Lesions - Aroclor 1260

Terminal Sacrifice - Rats

Lesion	Group			
	TI	TII	TIII	Control
Vacuolar Change	5/25	6/23	10/27	1/23
Focal Hypertrophy	3/25	10/23	11/27	0/23
Nodular Hyperplasia	0/25	9/23	7/27	1/23
Hepatoma	0/25	0/23	5/27	0/23
Ductular Hyperplasia	6/25	5/23	14/27	5/23
Cholangio-Hepatoma	0/25	0/23	2/27	0/23
Hepatocellular Necrosis	4/25	2/23	6/27	1/23

AROCLOR 1260

Tabulation of Individual Liver Lesions in Rats

Sacrifice Interval	Dose Level	Animal No and Sex	Liver Lesions								
			Vacuolar Change	Focal Necrosis	Focal lymphoid infiltrations	Focal hypertrophy of hepatocytes	Nodular hypertrophy of hepatocytes	Focal Bile Duct Hyperplasia	Hepatoma	Cholangio-hepitoma	
3 Month	AI	116M									
		117"									
		118"									
		119"									
		120"									
		147F									
		156"									
		157"									
		158"									
		159"									
		160"									
	AII	195M	++								
		196 "	++								
		198 "	+								
		200 "	++								
		Extra"									
		236F									
		237 "									
		238 "									
		239"									
		240 "									
	AIII	276M									
		277"	++								
		278"	++			+					
		279"				++					
		280"	++								
		315F									
		317"									
		318"									
		319"									
		320"									

MONS 219488

AROCLOR 1260

Tabulation of Individual Liver Lesions in Rats

Sacrifice Interval	Dose Level	Animal No. and Sex	Liver Lesions							
			Vacuolar Change	Focal Necrosis	Focal lymphoid infiltrations	Focal hypertrophy of hepatocytes	Nodular hypertrophy of hepatocytes	Focal Bile Duct Hyperplasia	Hepatoma	Cholangio-hepatoma
6 Month	AI	832M								
		834"			+					
		835"								
		846F								
		848"	+							
		849"			+					
	AII	864M	+		+					
		865"	+		+					
		873"		+						
		878F								
		879"								
	AIII	891M	+			++				
		893"	++			+				
		894"	+			+				
		895"	+							
		906F	+							
		907"								
		908"								
		909"								
		910"								

MONS 219489

AROCLOR 1260

Tabulation of Individual Liver Lesions in Rats

Sacrifice Interval	Dose Level	Animal No. and Sex	Liver Lesions								
			Vacuolar Change	Focal Necrosis	Focal lymphoid infiltrations	Focal hypertrophy of hepatocytes	Nodular hypertrophy of hepatocytes	Focal Bile Duct Hyperplasia	Hepatoma	Cholangio-hepatoma	
12 Month	AI	11M									
		12"	+					+			
		13"	+								
		14"									
		15"									
		16F									
		17"									
		18"									
		19"									
	AII	21M	+								
		22"									
		23"	+								
		24"	+								
		25"	++								
		26F									
		27"	+								
		28"									
		29"									
		30"									
	AIII	31M	++								
		32"									
		33"	++								
		34"	+								
		36F				+					
		37"				+					
		38"				+		+			
		39"					P				
		40"				+		+			

MONS 219490

ARCCLOR 1260

Tabulation of Individual Liver Lesions in Rats

Sacrifice Interval	Dose Level	Animal No. and Sex	Liver Lesions								
			Vacuolar Change	Focal Necrosis	Focal lymphoid infiltrations	Focal hypertrophy of hepatocytes	Nodular hypertrophy of hepatocytes	Focal Bile Duct Hyperplasia	Hepatoma	Cholangio-hepatoma	
Final	AI	85M		+							
		86"	++	+		+					
		87"		++							
		101"									
		106"						+			
		112"									
		114"									
		105"	+								
		107"									
		109"		+		+		+			
		122F									
		125"						+			
		127"						+			
		129"						+			
		130"									
		138"	+++								
		141"									
		147"									
		151"									
		155"	+								
		144"									
		131"	+								
		132"									
		135"				+		+			
		139"									
	AII	167M			+						
		168"	+			+					
		179"				+		+			
		182"					P				
		194"	++								
		187"									
		Extra'				+		+			
		205F					P	+			
		208"									
		210"									

MONS 219491

AROCLOR 1260

Tabulation of Individual Liver Lesions in Rats

Sacrifice Interval	Dose Level	Animal No. and Sex	Liver Lesions								
			Vacuolar Change	Focal Necrosis	Focal lymphoid infiltrations	Focal hypertrophy of hepatocytes	Nodular hypertrophy of hepatocytes	Focal bile duct Hyperplasia	Hepatoma	Cholangio-hepatoma	
Final (continued)	AII	212F					P	+			
		213"	+			+					
		220"				+					
		221"									
		224"					P				
		233"									
		234"				++		+			
		219"	++	+		+					
		230"		++							
		203"				++					
		204"									
		206"	+								
		207"	+			++					
	AIII	241M		+			F	+			
		253"									
		261"				+		+			
		264"	+	+		++					
		270"				+		+			
		271"	++			+					
		272"	+++								
		275"	++				F				
		243"	+					++		P	
		244"		+							
		312"				+		+			
		231F				++	F	+			
		274"	+			+++					
		275"	+++	++		+++		++			
		294"							P		
		297"	++	+					P		
		302"					F				
		306"				+		+			
		308"					F	+			
		311"	++						P		
		314"							P		
		230"	++			+		+			

MONS 219492

AROCLOR 1260

Tabulation of Individual Liver Lesions in Rats

Sacrifice Interval	Dose Level	Animal No. and Sex	Liver Lesions								
			Vacuolar Change	Focal Necrosis	Focal lymphoid infiltrations	Focal hypertrophy of hepatocytes	Nodular hypertrophy of hepatocytes	Focal Bile Duct Hyperplasia	Hepatoma	Cholangio-hepatoma	
Final (continued)	AIII	245F				++		+			
		281"					P	+			
		287"					P	+			
		291"						++	P		
		309"		+						P	

Grading System

+ = minimal in severity
++ = mild in severity
+++ = moderate in severity
++++ = marked in severity
P = Present, no grade

THE EPPLEY INSTITUTE
for
RESEARCH IN CANCER

October 31, 1975

Paul L. Wright, Ph.D.
Monsanto Company
800 North Lindbergh Boulevard
St. Louis, Missouri 63166

Dear Dr. Wright:

Enclosed please find the report on Histopathological Re-evaluation of Tissues from Female Sherman Rats Fed Aroclor 1260. As mentioned in this report, there were about 20 animals with lesions, which on a morphological basis alone, could be interpreted as neoplastic. However, the definite malignant nature of these lesions cannot be proved in the presented material because of the factors mentioned in the section entitled "discussion" in the enclosed report.

I am sorry that I was not able to contact you by telephone. I was very much tied up with several visitors last week.

If you have any questions concerning the report, please contact me.

Sincerely,

P. Pour, M.D.
Professor

rmj

University of Nebraska Medical Center, 42nd and Dewey Avenue, Omaha, Nebraska 68105

MONS 219494

Report

On

Histopathological Re-evaluation of Tissues from Female Sherman Rats Fed Aroclor 1260

MONS 219495

INTRODUCTION

A preliminary feeding study in which the toxicities of two PCB mixtures (Aroclor 1254 and 1260) were compared by Dr. Kimbrough (CDC, Atlanta, Ga.) resulted in no carcinogenic effect in rats. However, according to another study using Sherman strain female rats fed 100 ppm Aroclor 1260, 170 out of the 180 animals examined showed neoplastic lesions, which were classified by Dr. Kimbrough and co-workers as "neoplastic nodules" and "hepatocellular carcinomas". It was therefore concluded that Aroclor 1260 has a hepatocarcinogenic effect in female Sherman strain rats. Another study in albino rats with Aroclor also showed inconclusive results; while no carcinogenic response could be observed in a preliminary study, Dr. Gordon (Bio-Test Laboratories Inc.) reported a slight tumorigenic property of Aroclor 1242, 1254 and 1260 in rats which were fed continuously at levels of 100 ppm for 2 years. The re-evaluation of material from the latter study by myself left much doubt about carcinogenicity of the compounds tested, however a dose-dependent hepatotoxic effect was confirmed (see Report on Histopathological Re-evaluation of Livers from Rats Treated With AROCLOR). Using the same diagnostic criteria in this report the material from Dr. Kimbrough's experiment was re-evaluated and described.

MATERIALS AND METHODS

More than 550 slides from 184 experimental rats and over 360 from 173 control rats were presented These slides consisted of tissues from the brain, pituitary gland, thyroid gland, parathyroid glands, trachea, esophagus, lungs, mammary glands, stomach, heart, liver, spleen, adrenal glands, kidneys, ovaries, uterus and bladder Several tissues (3-5) were placed on each slide. For the most part, several liver sections were placed on 2 or 3 slides. All slides were stained with hematoxylin and eosin; additional liver sections (more than 150) were stained with AZURE eosin, Masson's trichrome, PAS and reticulum stains. The quality of all slides were sufficient for diagnosis.

For the present report, liver, lung, and mammary gland sections were of major interest in evaluating the hepatic lesions and determining possible metastases from the mammary gland or into the lungs. The slides were evaluated in the same sequence as they were found in the plastic boxes.

The criteria for diagnostic evaluation was the same as we used in the previous report; however, two other alterations were found in the material, which were not seen in the previous material such as:

Hyperplastic nodule without atypia: This lesion was characterized by circumscribed areas of large hepatocytes (2-8 times larger than regular liver cells) showing mostly foamy, light eosinophilic, sometimes also basophilic cytoplasm occasionally with inclusion bodies (bile pigment, concentric lamellated or fibrillar structures, PAS-positive materials). These foci, in part corresponding to lesions termed "neoplastic nodules" by Dr. Kimbrough, usually occupied an area of the size of several lobules and were well-demarcated, partially suggesting a compression effect in the surrounding, regular-appearing liver parenchyma. Small foci of similar cell clusters of areas in which the altered cells blended with surrounding liver plates without obvious architectural demarcation were not included in this category and were diagnosed as areas of cell enlargement; these areas probably correspond to lesions termed "foci or areas" by Dr. Kimbrough.

Hyperplastic nodules with atypia: An alteration, similar to hyperplastic areas, occurred showing such atypical features in either cellular or architectural behavior as abnormal nuclei and nucleoli and papillary or trabecular formations of pleomorphic cells. Binucleation or mitotic figures did not account for this alteration, since they were also seen in many regenerating hepatocytes surrounding the hyperplastic nodules or in areas remote from them.

RESULTS

The results of evaluations of experimental and control rats are given in Table 1-20. The most common findings in both animal groups are summarized in Table 21, showing that remarkable differences occurred in the experimental animals with regard to vacuolization, single and focal granular alteration, cell necrosis, cell enlargement, ductal proliferation, and Stern cell proliferation These alterations, occurring most frequently in the experimental animals could be referred to as toxic, degenerative and regenerative effects. The degree and the extent of all lesions in experimentals was greater than that of the controls. However the extent and the degree of alteration of hyperplastic nodules in treated rats varied among the individual animals. In some sections they could be localized in small areas, while in others they were multiple and sometimes occupied more or less the entire section (i.e. 8347, 8356, 8375); in some cases the multiplicity of the lesions were so remarkable that they simulated invading lesions. However no cytologic criteria for malignancy could be found. The degree and the extent of hyperplastic nodules were greater in livers showing general toxic effects (see tables). The more advanced and severe the degenerative and regenerative process, the larger and more multiple were these nodules. Most hyperplastic nodules with atypia were associated with severe parenchymal damage. As a matter of fact among 43 animals with atypical nodules, 19 showed diffuse or almost diffuse cell alterations of the liver.

In animals with fewer and smaller nodular lesions, morphologic signs of parenchymal repair (Stern cell proliferation, pigment deposition in macrophages, basophilia of the liver cells) were obvious. In many instances, the hyperplastic nodules were surrounded by basophilic, small liver cells, which had the tendency to penetrate into the hyperplastic nodules, thus giving rise to indistinct demarcation of the nodules: this phenomenon was also seen frequently in larger nodules and was interpreted as a repair-process, rather than a sign of malignancy in terms of invasion. Such a phenomenon was also seen in a few hyperplastic

nodules with atypia; in such instances regenerating areas were also found within the hyperplastic foci giving rise to lesions corresponding to "nodules within the nodule" . In about 20 animals the nodules were large and showed such a degree of atypia that they could be considered as neoplastic;however some of these nodules showed proliferation of bile ducts of definitely normal appearance on the borderline or within the nodules. In no case were definite signs of invasion or metastases observed in the available material.

In several animals the liver lesions were moderately or only slightly demaged (i.e., 8388, 839, 8400, 8401, 8431, 8460, 8477, 9479, 8385, 8387 and 8385). In other rats (i.e., 8454, 8457, 8458, 8462, 8489) the morphologic patterns of the tissue resembled more or less regenerated liver parenchyma and in still others, the sections taken from different lobes presented different pictures. For example, in one lobe the regenerative process was dominant while in other sections, degeneration was still in process. In sections lacking degeneration, the liver plates, which were composed of small basophilic liver cells, were smaller and separated by ectatic sinuses. This feature could be observed either within o in the margin of some hyperplastic nodules.

Cholangiomatous lesions were found exclusively in experimentals and were often associated with hyperplastic alterations.

Metastatic liver lesions originating from other sites (mammary glands, uterus) were not found.

DISCUSSION

Among 148 Aroclor 1260-treated animals, 136 hyperplastic nodules without atypia were found (43 of those with atypical structures). These contrast with Dr Kimbrough's findings of 170/184 neoplastic lesions, among which 26/184 were supposed to represent hepatocellular carcinomas. Hyperplastic nodules diagnosed by myself in controls also contrast with 28/173 reported by Dr. Kimbrough. The difference is obviously due to varying criteria used in classifying the lesions "Focal cell enlargement" in this report obviously corresponds to lesions termed "foci or areas" by Dr. Kimbrough; however hyperplastic nodules, by my definition, encompass both "neoplastic nodules" and "hepatocellular carcinoma" of Dr. Kimbrough's terminology. The criteria used by myself in distinguishing hyperplastic nodules (with or without atypia) is of pure cyto-morphologic character and unrelated to the biologic behavior, which cannot be determined in the presented material. However, with one exception, all alterations found in control animals were, in my opinion, benign and represented foci of cell degeneration and regeneration, a process which spontaneously occurs in many rat strains. However according to Dr. Kimbrough, these lesions, termed "foci or areas" as well as lesions termed "neoplastic nodules" represent a carcinogenic response.

I cannot follow this interpretation, since there is no way to demonstrate the definite malignant nature of said lesions in the available material. Therefore many pathologists, including myself, do not agree with the recent terminology of the liver lesions proposed by a group of pathologists in a workshop on rat liver tumors. Without morphologic evidence of malignancy, such as invasion and metastasis it is irrelevant to designate a lesion as malignant, unless it could be proven that its further development and progression results in malignancy. This cannot be said as to be relevant in Dr. Kimbrough's study. In contrast there is some evidence that the "neoplastic nodules" are not and cannot be precursors of carcinoma, since they may regress more or less completely under certain experimental procedures.

as shown by Dr. N. Ito of Nagoya City University in Japan and by Dr. G. M. Williams of the American Health Foundation in New York. According to Dr Ito (personal communication) a feeding experiment, conducted for a certain period of time resulted in regression of hyperplastic lesions in mice liver if the α-BHC (alpha-isomer of Benzene Hexachloride) as well as PCB, were removed from food and the animals were kept for life. A high incidence of hepatic lesions however was induced by continous feeding (2-years) of high concentration of both compounds (1500 ppm resulted in 30%, 1000 ppm in 7-8% and 500 ppm in 0%). The results of Dr. Ito's experiment will be published shortly in JNCI. By going through the material from Dr. Kimbrough's experiment and by comparison of various lesions in treated and untreated rats, I gained the strong impression that many detectable alterations represented a degenerative and reparative, rather than a neoplastic process. Smaller hyperplastic nodules often without atypia were found in those animals, in which morphologic signs of toxic effect were minimal and that of the reparative process predominant. In contrast, larger lesions with or without atypia, (often multiple) were present in livers showing a definite diffuse toxic response. In my opinion, many of these hyperplastic lesions would have regressed if the animals had been sacrificed at a later time. Dr. Kimbrough had the same thought, however neither possible regression nor the eventual progression of these lesions can be proven in the presented material. Concerning the most hyperplastic nodules with atypia I had also the impression, that cellular atypia reflected greater liver damage, since with a few exceptions, they failed to fullfill the proposed morphologic criteria for malignancy, such as atypical structures (thickening of liver plates, forming trabecular or papillary patterns). The basophilic cells found within some of the hyperplastic nodules were morphologically and cytologically different from basophilic foci described by Bannasch in hepatocellular carcinomas. The basophilic areas seen in the presented material were composed of small basophilic cells of unique sizes and shapes forming narrow liver plates separated by ectatic sinusoids, thus giving rise to pseudopapillary structures. This type of atypia is, with high

probability, a regenerative process and was seen also remote from hyperplastic nodules within the normal-appearing liver segment. Also other atypical features such as large and bizarre cells, binucleated cells and mitotic figures (which were all of regular form) did not account for malignancy, since they were observed both within and remote from the hyperplastic nodules. The same is true for hyperplastic nodules showing regeneration or new formation of definitely normal-appearing bile ducts, the presence of which contradicts the concept of malignancy. The undefined limitation of some hyperplastic nodules in many cases was caused by the beginning of progressive cell regeneration at the periphery, or less frequently in the centrum, of hyperplastic areas, and in my opinion should not be considered invasiveness. Twenty cases of the atypical hyperplasia, I observed, presented such morphologic criteria as to be considered neoplasia, although a most significant criteria for malignancy, namely the invasion was missing and the sign of ongoing toxic, degenerative and regenerative processes in the rest of the tissues was evident. At present, the statement that these lesions may have metastasized if the treatment had been continued is as much as unreliable as the possibility that they might have been regressed if the animal would have been kept longer or for life.

In summary, it is difficult at present to conclude whether or not some of the examined lesions represent a malignant lesion, because of the lack of invasion and metastases. In the case of such organs, as the liver with its marked tendency toward regeneration, it is, in my opinion, difficult and some times even impossible to distinguish between regeneration, hyperplasia and neoplasia, particularly when the tissue is continously exposed to a toxic substance.

In this context, Dr. Kimbrough's study (Arch. Environ. Health 27: 390-396, 1973) seems of particular interest, in that polychlorinated compounds may be retained in the body, even in higher concentrations for several months after feeding has been stopped. This finding may explain the continuing degenerative and regenerative

processes in the livers of most experimental rats, even 2 months after Aroclor was removed from their diet. One should also bear in mind that some animal strains may react more specifically to a compound because of common endogenous diseases, as in the case of the Sherman rats used in this experiment which tend toward spontaneous liver lesions. In my opinion, many of the lesions induced were of a degenerative nature, and without further studies, the induced liver lesions could not be definitely designated as neoplasia.

The different results obtained in experiments with albino and Sherman strain rats are obviously not only due to the enviromental and genetic background but also to the matter of experimental methods used in the different experiments.

Number of slides	8320	8321	8324	8324	8325	8326	8327	8329	8331	8332	8333	8334	8335	8336	8337	8339	8339	8341	8342	8343
[illegible]	(+)	+	+	+	+	+	+		+	+	+	+	+	+	+		+	+	+	+
[illegible] ilic alteration						+														
S[illegible] ilic alterations	+	+	+	+	+	+	+	+	+	+	+	+	+	+	+	+	+		+	+
[illegible] er alteration			+		+		+	+	+	+	+	+		+	+		+			+
S[illegible] ular alteration	+	+		+	+		+				+		+	+		+			+	
[illegible]												+								
[illegible] hyperplasia																				
S[illegible] cell necrosis		+	+	+	+		+	+			+			+	+	+	+			
[illegible] cell necrosis									+	+							+			+
[illegible]		+	+	+	+	+	+		+	+	+	+	+	+	+	+	+	+	+	
Ductal proliferation		+	+			+		+			+	+	+					+		
Periductal fibrosis																				
C[illegible]ocytosis													+							
Stem cell proliferation							+							+	+				+	
Epithelioid cell granuloma										+										
Periportal inflammation	+	+	+				+	+		+	+			+	+	+	+	+	+	+
[illegible] periportal nodules with [illegible]		+				+							+				+			
[illegible] hyperplastic nodules without [illegible]			+	+	+	+	+	+	+	+		+	+		+	+	+	+	+	
C[illegible] lesions																				
[illegible]				+											+					

MONS 219504

Number of slides	8344	8345	8346	8347	8350	8351	8352	8353	8354	8355	[illegible]	8357	[illegible]	[illegible]	[illegible]	[illegible]	[illegible]	[illegible]	[illegible]	[illegible]
[illegible]	+	+	+	+	+	+	+	+	+			+	+	+	+	+	+	+	+	-
[illegible] cystic alteration				+																
[illegible] cystic alterations	+	+	-	+	+	+	+	+	+		+	+	+	+	+	+	+			+
Focal granular alteration	+	+	+	+	+	+	+	+	+	+	+	+	+	+	+	+	+	+	+	+
[illegible] granular alteration	+	+	+	+	+	+	+	+	+		+	+		+	+	+	+			+
Perinuclear halo				+																
Eosinophilic [illegible]																				
Single cell necrosis	+	+		+	+	+		+	+		+					+	+			
Group cell necrosis		+			+									+						
Cell enlargement	+	+	+	+D	+AD	+AD		+	+	+	+AD	+D	+	+AD		+AD	+AD	+	+	
Ductal proliferation		+		+																
Periductal fibrosis																				
Cholangiofibrosis		+			+										+					
Stem cell proliferation			+		+		+								+	+	+	+	+	
Epithelioid cell granuloma																				
Periportal inflammation	+	+	+		+			+			+			+		+	+	+		
Hyperplastic nodules with atypia					+															
Hyperplastic nodules without atypia	+	+	+		+		+	+		+	+		+		+	+		+		
Cholangiocellular lesion					+															
Lymphocytic [illegible]						+														

* [illegible]
[illegible] diffuse

MONS 219505

[illegible] slides	8365	8366	8367	8369	8370	8371	8372	8373	8374	8375	8376	8377	8378	8380	8381	8382	8383	8384	8385
[illegible]	+	+	+	+	+	+	+	+	+	+				+	+	+		+	+
Focal [illegible] hyperplastic alteration							+												
Single [illegible] basophilic alterations		+	+	+	+	+		+	+	+	+	+	+	+	+	+	+	+	+
Focal granular alteration							+	+	+	+	+	+	+		+				
[illegible] eosinophilic alteration	+	+	+	+	+	+	+	+	+	+	+	+	+	+	+	+	+	+	+
Perinuclear halo																			
Eosinophil homogenization																			
Single cell necrosis		+	+	+	+	+	+	+	+	+	+	+	+						
Group cell necrosis						+			+	+		+							
Cell enlargement	+	+	+	+AD	+	+	+	+D	+D	+AD	+	+AD	+AD	+	+AD	+	+	+	(+)
Ductal proliferation			+							+	+	+	+		+	+	+		
Periductal fibrosis																			
Cholangiofibrosis								+											
Stem cell proliferation	+	+	+	+		+	+			+	+	+	+	+	+	+	+	+	+
Epithelioid cell granuloma																			
Periportal inflammation		+		+															
Hyperplastic nodules with [illegible]																			
Hyperplastic nodules without atypia	+	+	+		+		+					+		+			+		
Carcinomatous lesion			+				+					+					+		
[illegible]																			

Localized
Non-localized diffuse

MONS 219506

Number of slides	8386	8387	8388	8389	8390	8391	8392	8393	8394	8395	8396	8397	8398	8399	8400	8401	8402	8403	8404
[illegible]	+	+		+	+	+	+	+		+		+	+	+	+	+	+		+
[illegible] alteration																			
[illegible] alterations	+	+	+	+	+	+	+	+	+	+	+	+	+	+	+	+	+		+
[illegible] alteration	+					+	+	+					+	+		+			+
[illegible] alteration	+	+	+	+	+	+	+	+	+	+	+	+	+	+	+	+	+	+	+
Perinuclear halo																			
[illegible] homogenization																			
Single cell necrosis					+	+		+	+	+	+		+	+	+	+	+		
Group cell necrosis								+				+		+					
Cell enlargement	+AD	(+)	+		+AD	(+)	+	+	+	+AD	+	+AD	+D	+	+	+	+	+	+AD
Ductal proliferation	+			+					+			+			+	+		+	+
Periductal fibrosis																			
Cholangiofibrosis																			
Stem cell proliferation	+	+	+	+	+	+			+	+		+		+	+	+	+	+	+
Epithelioid cell granuloma																			
Periportal inflammation		+		+							+	+				+			
Hyperplastic nodules with atypia					+			+		+				+					
Hyperplastic nodules without atypia	+				+		+	+	+	+	+			+	+		+	+	+
Cholangiomatous lesion	+											+			+				
[illegible]																			

MONS 219507

	8405	8406	8407	8408	8411	8412	8413	8414	8415	8416	8417	8418	8419	8420	8421	8422	8423	8424	8425
[illegible]	+	+	+	+	+	+	+	+		+	+		+			+	+	+	
[illegible]																			
[illegible]	+	+	+	+		+	+		+	+	+	+	+	+	+	+		+	
[illegible]	+	+	+	+		+	+	+				+				+			
[illegible]	+	+	+	+		+	+	+	+	+	+	+	+	+	+	+		+	+
Perinuclear halo																			
[illegible]																			
Single cell necrosis	+	+	+	+	+	+	+	+	+	+	+	+							
Group cell necrosis	+				+		+												+
[illegible]	+	+	+AD	+	+AD	+	+	+	+	+	+	+	+	+	(+)	+	+	+	
Ductal proliferation		+	+	+														+	
Periductal fibrosis																			
Cholangiofibrosis		+	+		+														
Stem cell proliferation	+	+	+			+			+	+			+			+	+		
Epithelioid cell granuloma																			
Periportal inflammation																			+
Hyperplastic nodules with [illegible]	+	+	+		+		+	+			+							+	
Hyperplastic nodules without [illegible]	+	+	+	+	+	+	+	+	+	+	+	+	+	+	+	+	+	+	+
Cholangiomatous lesion		+	+											+					
[illegible]																			
[illegible] diffuse																			

MONS 219508

[illegible] of [illegible]des	8426	8427	8428	8429	8430	8431	8432	8433	8434	8435	8436	8437	8438	8439	8440	8441	8442	8443	8444
[illegible]lization	+	+	+	+			+	+	+	+	+	+	+	+	+	+	+		+
[illegible] alteration																			
Single [illegible] alterations	+	+	+	+	+	+	+	+	+	+	+	+	+	+	+	+	+	+	+
Focal granular alteration	+								+	+		+	+		+		+		+
Single granular alteration	+	+	+	+	+	+	+	+	+	+	+	+	+	+	+	+	+	+	+
Perinuclear pale																			
Eosinophil homogenization																			
Single cell necrosis	+		+	+	+	+	+	+	+	+	+	+	+	+	+	+	+	+	+
Group cell necrosis	+	+						+											
Cell enlargement	+	+	+AD	+	+	+	+	+AD	+	+	+AD	+	+	+	+	+AD	+	+	+
Ductal proliferation			+	+			+	+	+	+				+	+	+			
Periductal fibrosis																			
Cholangiofibrosis								+											
Stern cell proliferation	+	+	+	+	+	+	+			+		+			+	+	+		+
Epithelioid cell granuloma																			
Periportal inflammation	+			+	+														
Hyperplastic nodules with atypia		+					+	+		+				+					+
Hyperplastic nodules without atypia	+	+		+	+	+	+		+	+		+	+	+	+	+	+		+
[illegible] lesion			+											+					
[illegible]																			

[illegible] diffuse

MONS 219509

	8445	8446	8447	8449	8451	8452	8453	8454	8455	8456	8457	8458	8459	8460	8461	8462	8463	8465	8466
[illegible]	+		+		+	(+)	+		+	+	(+)	+	+	+	+	+	+	(+)	+
Focal basophilic alteration																			
Single basophilic alterations	+	+	+	+	+	+	+	+	+	+	+	+	+	+	+	+	+	+	+
Focal granular alteration	+		+				+						+	+					+
Single granular alteration	+	+	+	+	+	+	+	+	+	+	+	+	+	+	+	+	+	+	+
Perinuclear halo																			
Eosinophilic homogenization																			
Single cell necrosis	+		+		+	+			+	+			+	+	+	+	+		
Group cell necrosis			+			+				+			+					+	
Cell enlargement	+AD		+AD	(+)	(+)	+AD	+AD		+	+	+	+	+	+	+	+	+	+	+
Ductal proliferation													+						
Periductal fibrosis																			
Cholangiofibrosis																			
Stem cell proliferation	+	+		+	+	+	+	+	+	+	+	+			+	+	+		+
Epithelioid cell granuloma																			
Periportal inflammation						+			+										
Hyperplastic nodules with atypia		+			+														
Hyperplastic nodules without atypia	+			+	+		+		+	+				+	+		+	+	+
Cholangiomatous lesion																			
[illegible]																			

AD=almost diffuse

D=[illegible]

MONS 219510

	[illegible]	8468	8469	8470	8471	8472	8473	8474	8475	8476	8477	8478	8479	8480	8481	8482	8483	8484	[illegible]
[illegible]ation	+	+	(+)	+	+	+	+	+	+	+	+		(-)	+		+	+	+	+
[illegible] alteration																			
S[illegible] alterations	+	+	+	+	+	+	+	+	+	+	+	+	+	+	+	+	+	+	+
Focal granular alteration	+		+	+	+		+				+	+		+			+		+
S[illegible] alteration	+	+	+	+	+	+	+	+	+	+	+	+	+	+	+	+	+	+	+
Perinuclear halo																			
Rosettes [illegible]rogenization																			
Single cell necrosis	+	+	+	+	+	+	+	+			+	+		+			+	+	+
Group cell necrosis				+							+							+	+
Cell enlargement	+	+	(+)	+AD	+	+AD	+	+	+	+	+	+	+	+AD	+	+AD	+	+AD	+AD
Ductal proliferation						+			+					+				+	
Periductal fibrosis																			
Cholangiofibrosis																			
Stem cell proliferation		+	+	+	+		+		+	+		+	+	+	+	+	+	+	+
Epithelioid cell granuloma																			
Periportal inflammation	+		+	+	+		+		+					+	+	+	+	+	
Hyperplastic nodules with atypia			+					+	+					+		+	+	+	
Hyperplastic nodules without atypia	+	+	+	+	+	+	+	+	+	+	+	+		+	+	+	+	+	+
Cholangiocellular lesion						+			+										
[illegible]																			

[illegible] diffuse

MONS 219511

	8486	8488	8489	8490	8491	8492	8493	8494	8495	8496	8497	8498	8499	8500	8501	8502	8504	8505	8506
[illegible]	+	+	(+)	+			(+)	+	+		+	+	+	+	+	+	+	+	+
[illegible] alteration																			
[illegible] alterations	+	+	+	+	+	+	+	+	+	+	+	+	+	+	+	+	+	+	+
Focal granular alteration	+	+		+	+	+	+	+	+	+		+	+			+			
[illegible]	+	+	-	+	+	+	+	+	+	+	+	+	+	+	+	+	+	+	+
Perinuclear halo																			
Eosinophilic homogenization																			
Single cell necrosis	+	+		+	+	+	+	+	+	+	+	+	+	+	+		+	+	
Group cell necrosis		+	.			+													
Cell enlargement	+AD	+AD	(+)	+AD	+	+	+AD	+	+	+	+	+	+AD	+	+	+AD	+AD	+	+
Ductal proliferation	+	+		+											+	+			
Periductal fibrosis																			
Cholangiofibrosis																	+		
Stem cell proliferation	+	+	+	+	+	+		+	+	+		+	+	+	+	+			+
Epithelioid cell granuloma																			
Periportal inflammation			+						+						+				
Hyperplastic nodules with atypia		+					+			+				+		+	+		
Hyperplastic nodules without atypia	+	+		+	+	+	+	+	+	+	+	+	+	+	+	+	+	+	+
Choangiocarcinomatous lesion																+			
Lymphoma lesion																			

[illegible] diffuse

MONS 219512

[illegible]	8507	8508	8509	8510	8512	8513	8514	8515	8516	8517	8518	[illegible]
[illegible]	+	+	+		+	+	+	+	+	+	+	+
[illegible] alteration												
[illegible] alterations	+	+	+	+	+	+	+	+	+	+	+	+
[illegible] alteration			+	+		+	+		+	+	+	+
Single granular alteration	+	+	+	+	+	+	+	+	+	+	+	+
Perim clear halo												
Eosinophil homogenization												
Single cell necrosis	+			+	+	+	+	+	+	+	+	+
Group cell necrosis									+		+	+
Cell enlargement	+AD	+	-AD	+	+	+	+AD	+D	+AD	+	+AD	+AD
Ductal proliferation	+						+				+	
Periductal fibrosis												
Cholangiofibrosis												
Stem cell proliferation	+		+	+	+	+	+	+	+	+	+	+
Epithelioid cell granuloma												
Periportal inflammation								+	+	+	+	+
Hyperplastic nodules with atypia	+						+		+		+	+
Hyperplastic nodules without atypia	+	+	+		+	+	+		+	+		
Cholangiomatous lesion											+	
[illegible]												

[illegible] diffuse

MONS 219513

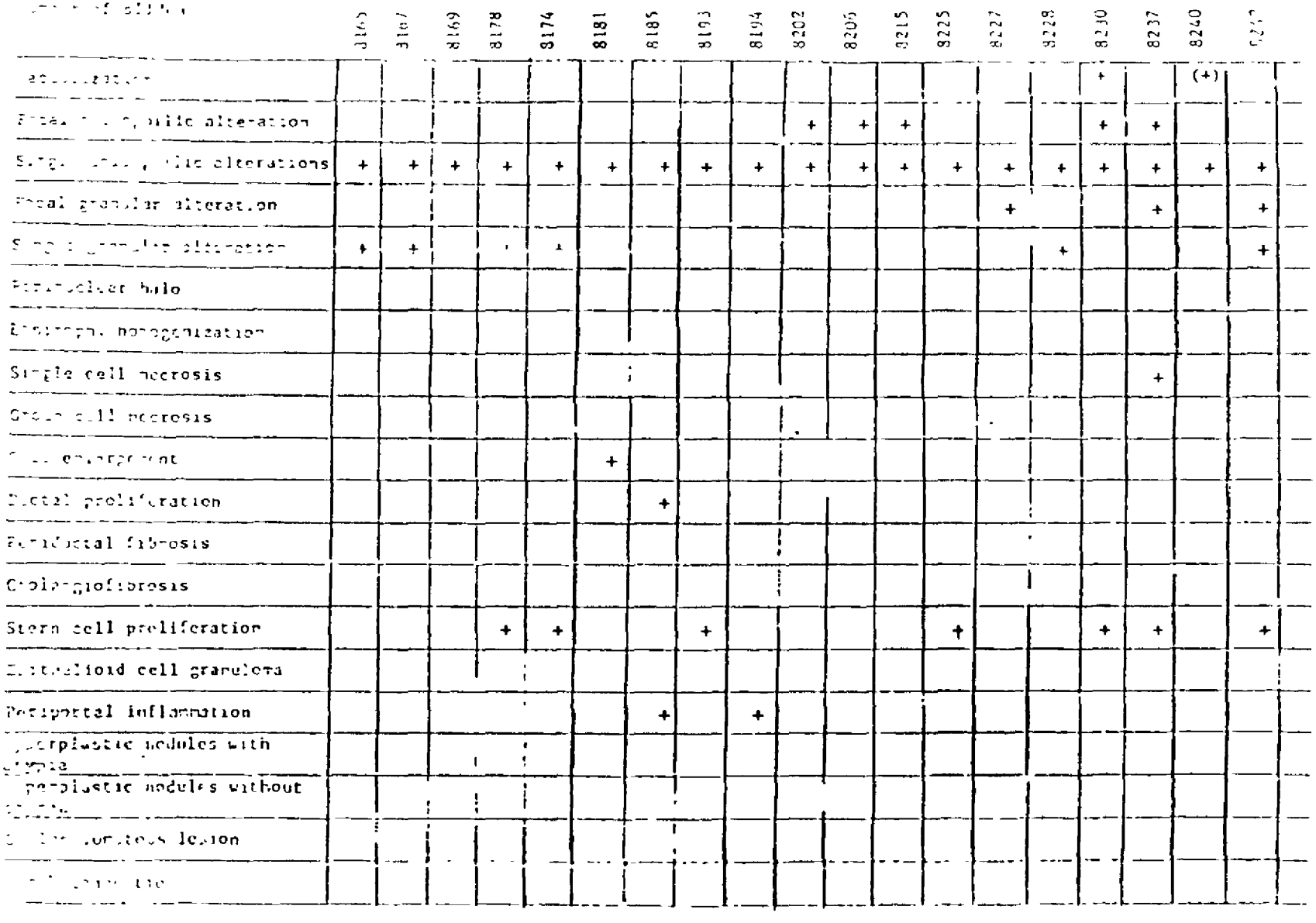

[illegible]	8165	8167	8169	8178	8174	8181	8185	8193	8194	8202	8206	8215	8225	8227	8228	8230	8237	8240	[illegible]
[illegible]																+		(+)	
[illegible] alteration										+	+	+				+	+		
[illegible] alterations	+	+	+	+	+	+	+	+	+	+	+	+	+	+	+	+	+	+	+
Focal granular alteration														+			+		+
[illegible] alteration	+	+		[illegible]	+										+				+
Perinuclear halo																			
[illegible] homogenization																			
Single cell necrosis																	+		
Group cell necrosis																			
[illegible] enlargement						+													
Ductal proliferation							+												
Periductal fibrosis																			
Cholangiofibrosis																			
Stern cell proliferation				+	+			+					+			+	+		+
Epithelioid cell granuloma																			
Periportal inflammation							+		+										
[illegible]erplastic nodules with [illegible]																			
[illegible]perplastic nodules without [illegible]																			
[illegible] lesion																			
[illegible]																			

MONS 219514

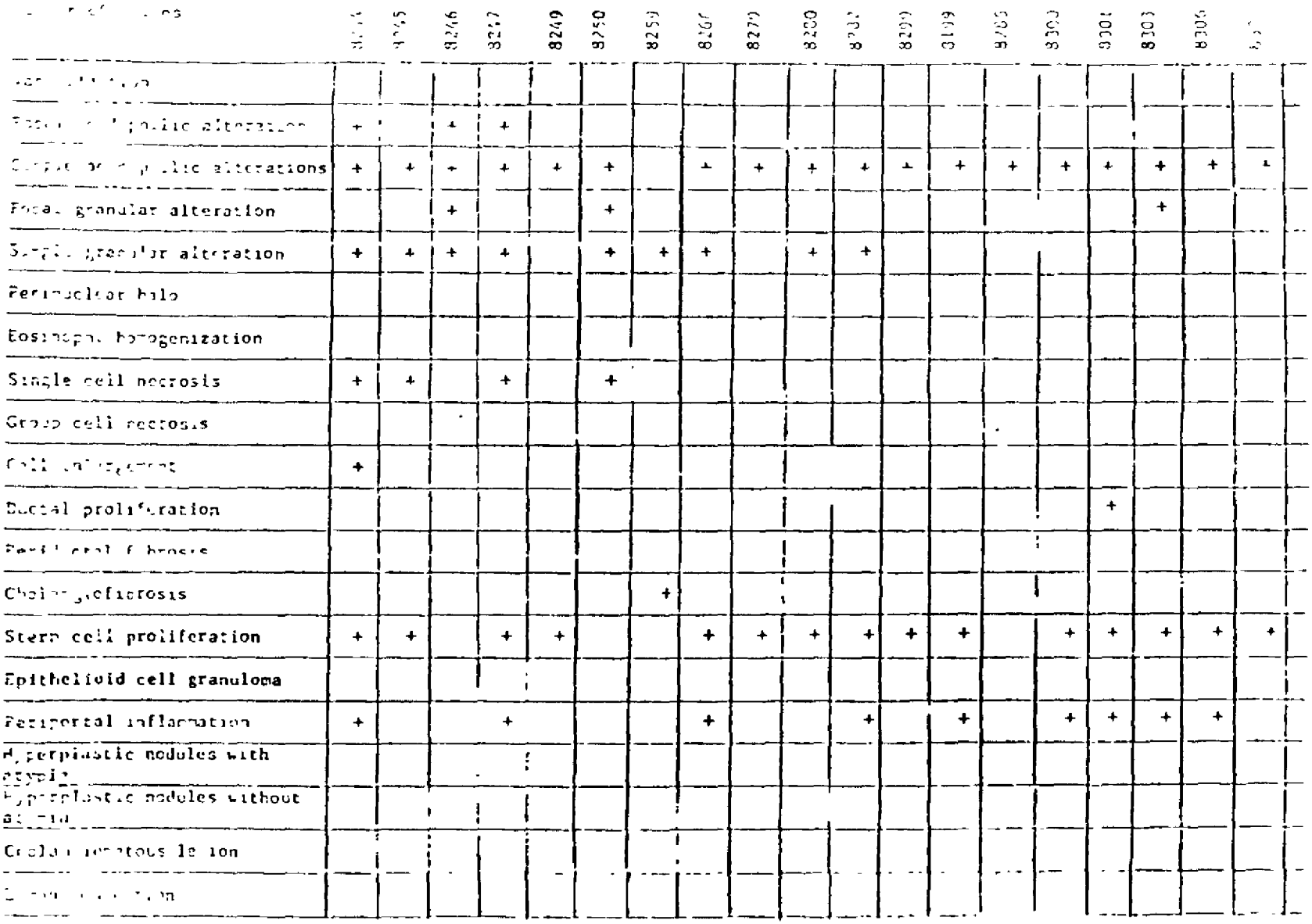

[illegible]	[illegible]	[illegible]	8246	[illegible]	8249	8250	8259	[illegible]	[illegible]	8280	[illegible]	[illegible]	[illegible]	[illegible]	[illegible]	[illegible]	[illegible]	[illegible]	[illegible]
[illegible]																			
[illegible] alteration	+		+	+															
[illegible] alterations	+	+	+	+	+	+		+	+	+	+	+	+	+	+	+	+	+	+
Focal granular alteration			+			+											+		
Simple granular alteration	+	+	+	+		+	+	+		+	+								
Perinuclear halo																			
Eosinophil homogenization																			
Single cell necrosis	+	+		+		+													
Group cell necrosis																			
Cell enlargement	+																		
Ductal proliferation																+			
Periductal fibrosis																			
Cholangiofibrosis							+												
Stern cell proliferation	+	+		+	+			+	+	+	+	+	+		+	+	+	+	+
Epithelioid cell granuloma																			
Periportal inflammation	+			+				+			+		+		+	+	+	+	
Hyperplastic nodules with atypia																			
Hyperplastic nodules without atypia																			
Cholangiomatous lesion																			
[illegible]																			

MONS 219515

Number of rat(s)	8309	8310	8311	8312	8313	8314	8315	8316	8317	8318	8321	8151	8231	8260	8261	8263	8264	8265
[illegible]													+					
Foci of cellular alteration				+					+							+		
Centrilobular hypertrophy	+	+	+	+	+	+	+	+	+	+	+	+	+	+	+	+	+	+
Eosinophilic cytoplasmic alteration			+					+		+			+					
Simple granular alteration				+			+	+			+		+	+	+		+	+
Perinuclear halo																		
Ectopic hepatocellular proliferation																		
Single cell necrosis					+		+	+										
Group cell necrosis													+					
Cell enlargement			+										+					
Ductal proliferation													+					
Periductal fibrosis																		
Cystic glomerulosis													+					
Stem cell proliferation		+	+	+	+	+	+	+	+	+	+			+	+			+
Epithelioid cell granuloma																		
Periportal inflammation		+	+		+	+	+				+							
Hyperplastic nodules with stroma													+					
Hyperplastic nodules without stroma			+										+					
Cellular foci/cystic lesion													+					
[illegible]																		

MONS 219516

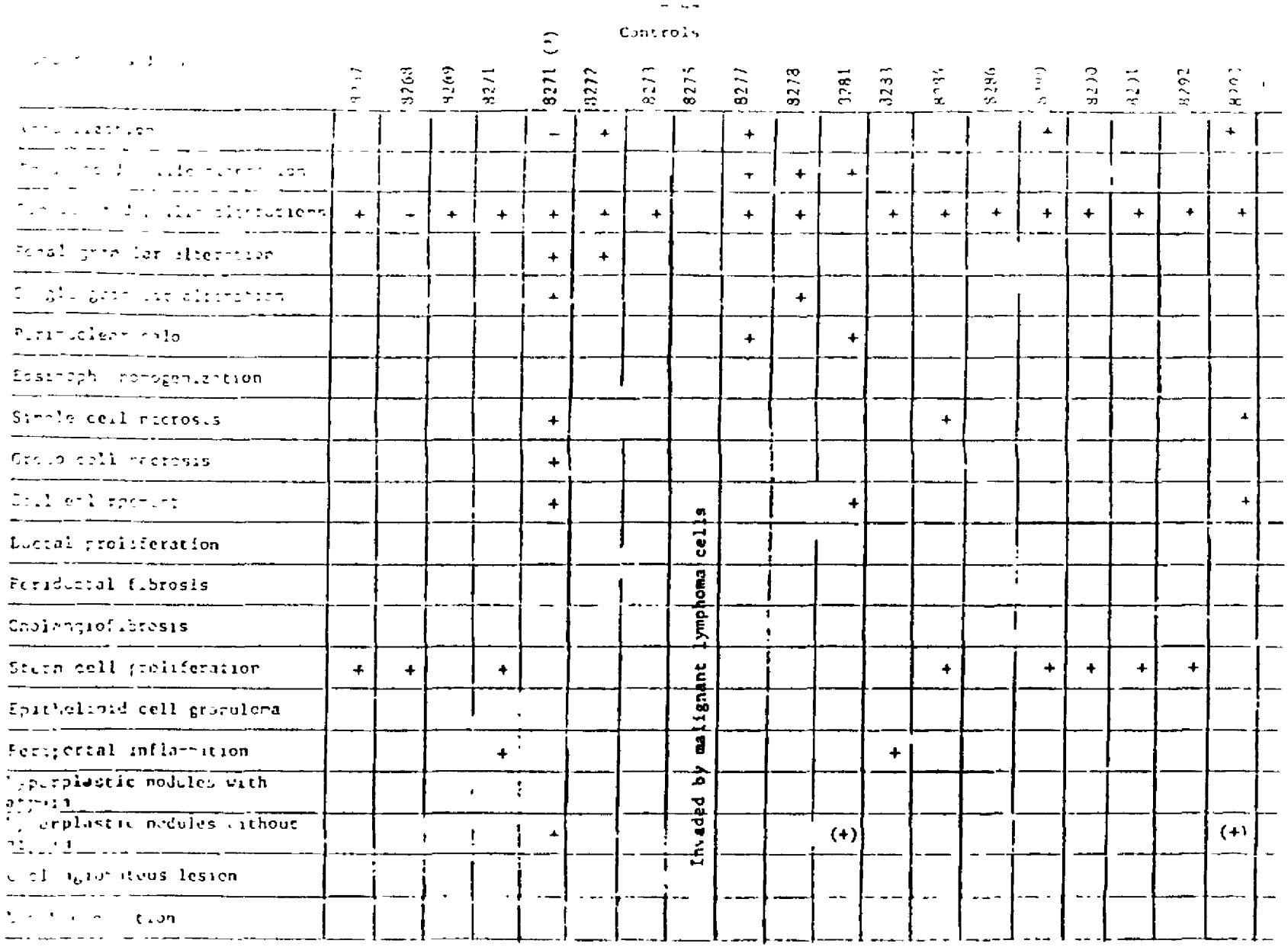
Controls
8271 (*)
Invaded by malignant lymphoma cells
Simple cell necrosis
Stem cell proliferation
Hyperplastic nodules without
(+)
(+)

MONS 219517

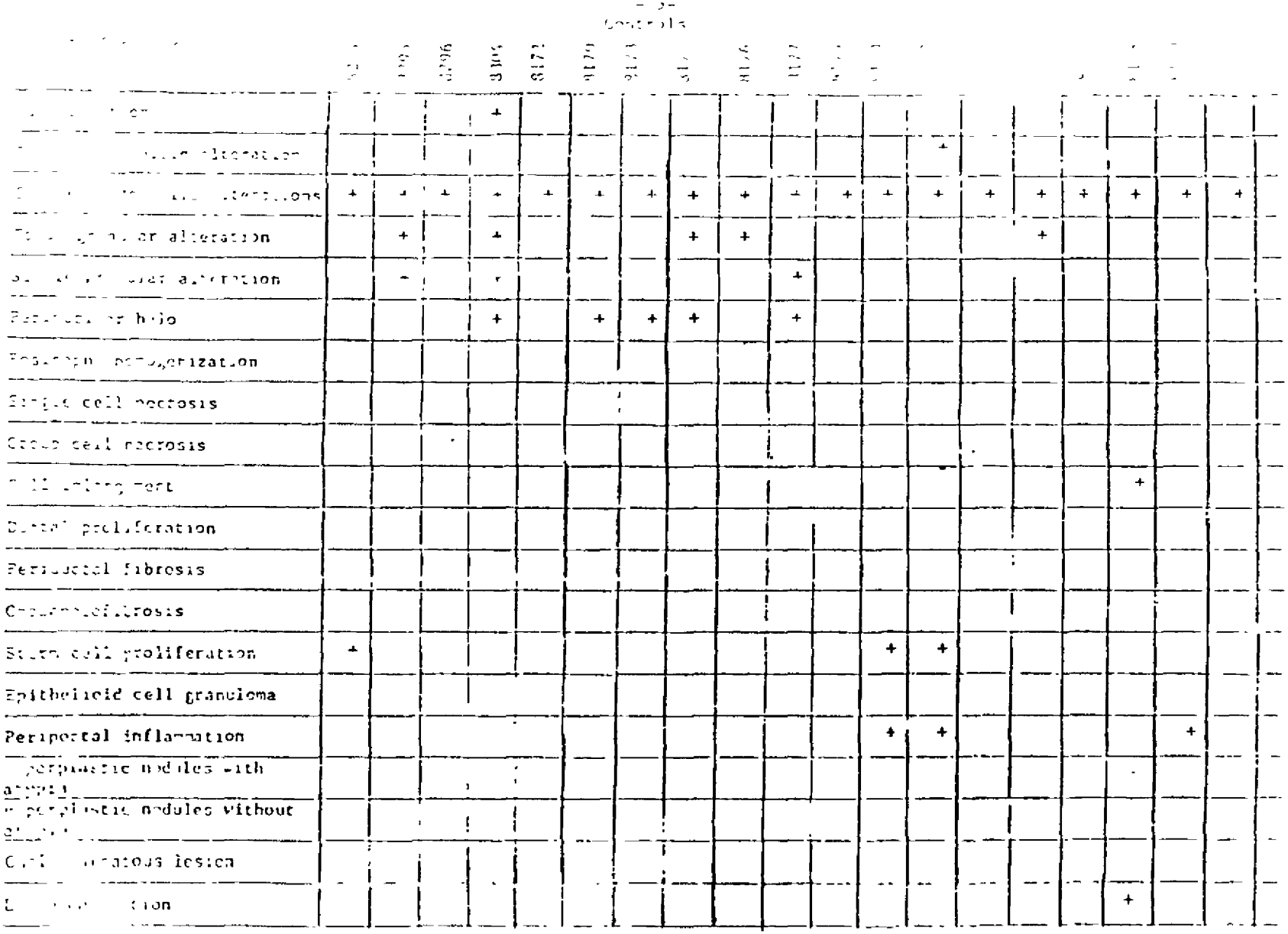

MONS 219518

Control

	8192	8195	8196	8197	8198	8200	8201	8203	8204	8207	8208	8209	8210	8211	8212	8213	8214	8217	8218
[illegible]																			
Focal [illegible] alteration													+						
Single vacuolic alterations	+	+	+	+	+	+	+	+	+	+	+	+	+	+	+	+	+	+	+
Focal granular alteration								+										+	
Single granular alteration				+		+	+	+					+					+	
Perinuclear halo				+															
Eosinophil homogenization																			
Single cell necrosis																			
Cluster cell necrosis																			
Cell [illegible]	+																		
Ductal proliferation																			
Portal-induced fibrosis																			
Cholangiofibrosis																			
Stem cell proliferation			+	+					+	+	+		+	+		+	+	+	
Epithelioid cell granuloma																			
Periportal inflammation					+											+			
Hyperplastic nodules with [illegible]																			
Hyperplastic nodules without [illegible]	(+																		
Cholangiocellular lesion																			
[illegible]																			

MONS 219519

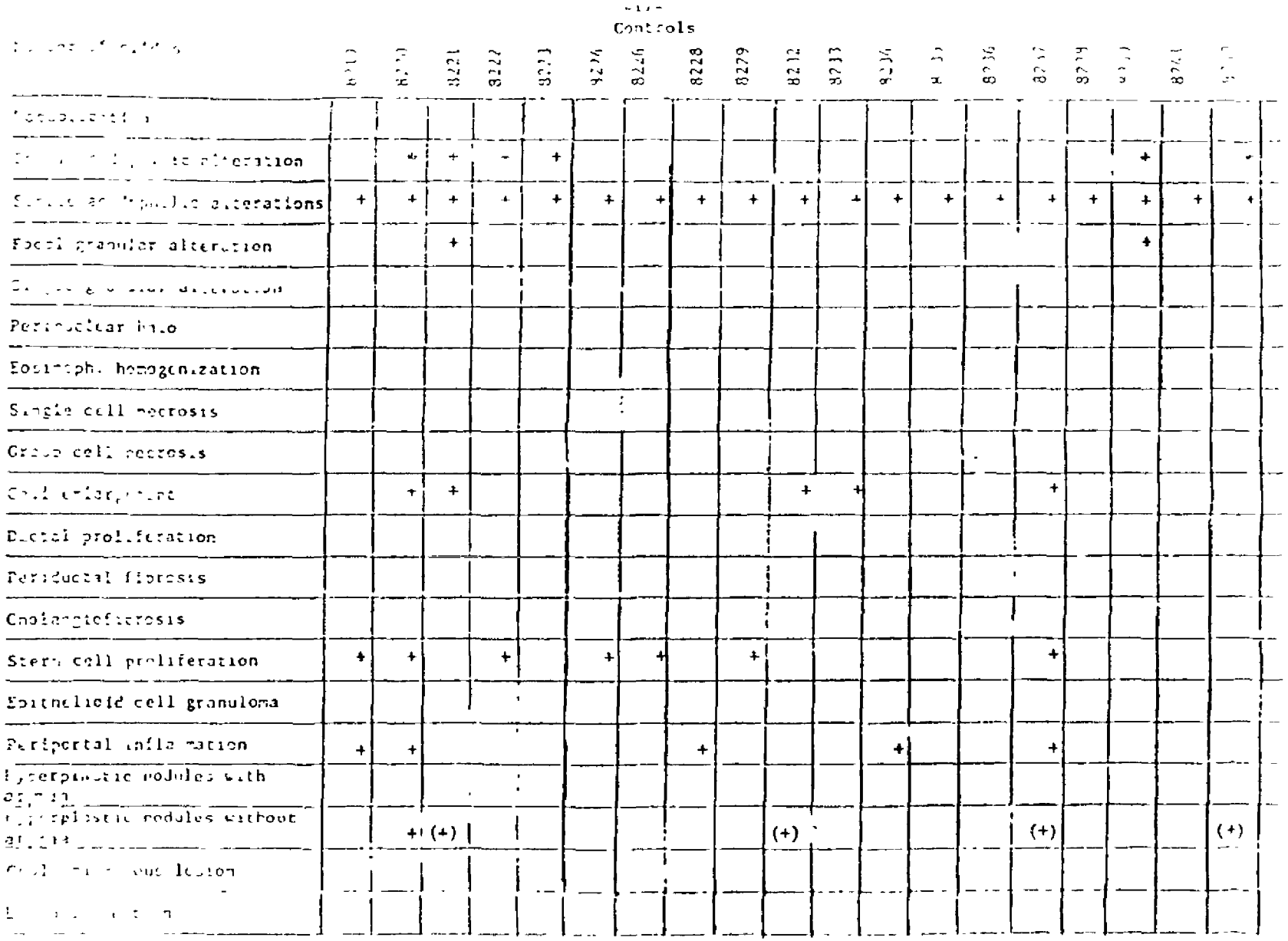

MONS 219520

Controls

[illegible] of [illegible]	8245	8249	8251	8252	8253	8254	8255	8257	8258	8119	8120	8122	8123	8124	8126	8127	8128	8129	8130
[illegible]					+				(+)									+	
Fo[illegible] alteration	+									+		+		+	+		+		
S[illegible] alterations	+	+	-	+		+	+	+	+	+	+	+	+	+	+	+	+	+	+
Focal granular alteration	+		+															+	
[illegible] granular alteration	+												+						
Perinuclear halo										+						+		+	
Eosinoph. homogenization																			
Single cell necrosis							+												
Group cell necrosis																			
Cell enlargement																		+	
Ductal proliferation																			
Periductal fibrosis																			
Cholangiofibrosis																	+		
Storm cell proliferation		+	+			+	+	+	+			+	+	+	+				
Epithelioid cell granuloma																			
Periportal inflammation	+						+	+			+	+							
Hyperplastic nodules with atypia																			
Hyperplastic nodules without atypia																			
C[illegible] lesion																			
I[illegible]																			

Diffuse Kupffer cell hyperplasia

[illegible] fibrosis (+)

MONS 219521

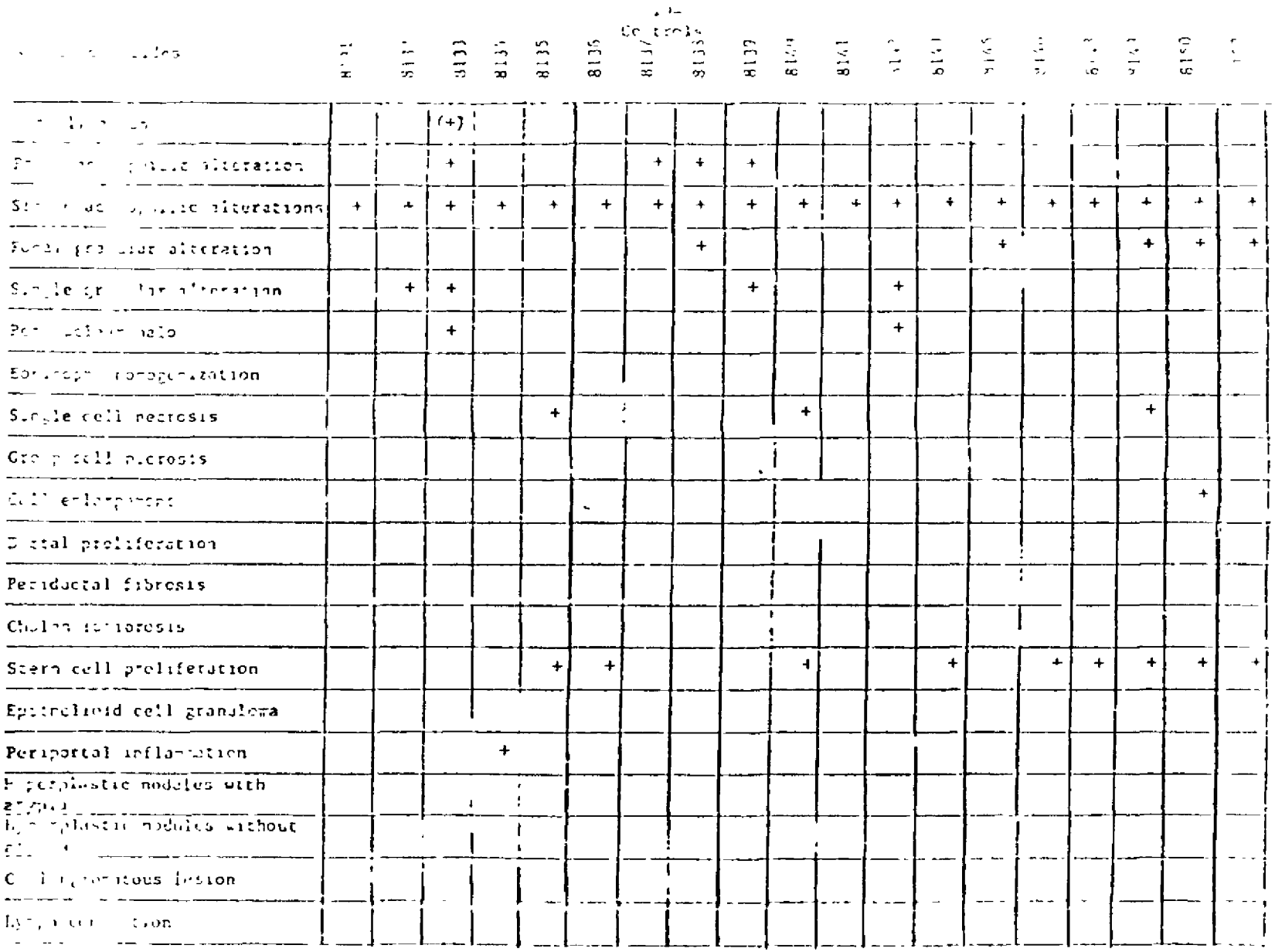

MONS 219522

Controls

	8154	8155	8156	8157	8158	8160	8162	8163	8164	8166	8167										
[illegible]																					
[illegible] alteration			+	+		+															
[illegible] alterations	+	+	+	+	+	+	+	+	+	+	+										
Focal granular alteration		+		+																	
[illegible]	+			+		+					+										
Periacinar halo																					
[illegible] homogenization																					
Single cell necrosis	+		+																		
Group cell necrosis																					
Cell enlargement				+																	
Duct proliferation																					
Periductal fibrosis																					
Cholangiofibrosis																					
Stem cell proliferation	+	+	+							+	+										
Epithelioid cell granuloma																					
Periportal inflammation																					
[illegible] nodules with atypia																					
Hyperplastic nodules without atypia				(+)																	
[illegible]																					
[illegible]																					

MONS 219523

Table 21. Differences of liver lesions in control and experimental rats treated with Aroclor 1260

	Experimentals	Controls
Vacuolization	155	13
Focal granular alteration	100	31
Single granular alteration	169	45
Single cell necrosis	125	17
Group cell necrosis	36	2
Cell enlargement	175	17
Ductal proliferation	52	3
Cholangiomatous lesion	7	-
Stern cell proliferation	121	87
Hyperplastic nodules:		
without atypia	136	9
with atypia	43	1

MONS 219524

3315 South 104th Street
Omaha, Nebraska 68124
August 1, 1975

Paul. L. Wright, Ph.D.
Monsanto Company
800 North Lindbergh Boulevard
St. Louis, Missouri 68166

Dear Dr. Wright:

Enclosed please find the report on histopathological re-evaluation of the slides you sent to me on May 30, 1975.

The report includes illustrations of my findings and my opinion regarding the interpretation of the results, as well as some recommendations for additional studies. If you have some questions in this regard, please don't hesitate to call me at your convenience.

Sincerely,

P. POUR, M.D.

Tel. (402) 541-4495

jfm

Report On

Histopathological re-evaluation of livers from rats treated with AROCLOR

MONS 219526

SUMMARY

A review of slides from rats fed chronically with three doses of AROCLOR 1242, 1254, and 1260 for different time intervals showed a dose-dependent hepatotoxic effect, characterized by degenerative and regenerative processes. With one exception, all lesions were considered non-neoplastic. Structures similar to cholangiocarcinomas and hepatomas were found in one rat. However, the possibility of metastases of a carcinoma into the liver has been also considered. The results are discussed and suggestions for further studies have been made.

INTRODUCTION

A total of 549 slides, submitted for consultation from Monsanto Company, were said to represent liver tissues from 540 alb no rats continuously fed diets containing 1 (T-I), 10 (T-II), or 100 (T-III) ppm AROCLOR 1242 (A group=157 liver sections), 1254 (B group=176 liver sections) and 1260 (C group=211 liver sections), and sacrificed at intervals of 3,8,14, and 24 months. A study with AROCLOR 1260 in albino rats revealed no carcinogenic effects. However, investigators conducted another experiment with AROCLOR 1260 and reported induction of hepatocellular carcinoma in 26 of 184 experimentals, while the ration in controls was 1 out of 173 In addition in the same study 146 of 184 experimental rats showed neoplastic nodules. From this study, Dr. Kimbrough and other NCI consultants (Dr. Robert Squire and Morton Levitt) concluded that AROCLOR 1260 had a hepatocarcinogenic effect when fed in the diet of female Sherman strain rats.

Histopathologic evaluation of additional liver sections from rats of a 2-year chronic oral toxicity study of AROCLOR 1242, 1254 and 1260 by Dr. Gordon of Industrial BIO-TEST Laboratories Inc. indicated that all 3 lots of AROCLOR were slightly tumorigenic at levels of 100 ppm, when fed continuously in the diet for 2 years. Additional material from the latter experiments has been submitted for re-evaluation as to whether there are apparent reasons for the varying results obtained by the two laboratories and suggestions regarding possible additional animal testing.

MATERIALS AND METHODS

For the most part, one slide per rat was submitted, and there were 1-3 slices of liver tissues per slide. However, in the case of 4 rats, there were 2 slides each. Therefore in the final accounting, the number of liver slides exceeded the number of animals by four. Tissues were stained with hematoxylin

and eosin, placed in conventional plastic slide boxes for transport, and were of sufficient quality for evaluation. Some slides were not adequately identified with regard to sex or treatment groups. In some cases, tissues other than of the liver (i.e., of the mammary glands or pancreas) were found in a few slides, and these were not subjected to histologic evaluation. Four of the liver slides could not be evaluated because of: (1) advanced autolysis in 2 cases ($A_2$230F and $A_3$272M) and (2) severe infiltration by malignant lymphoma cells in 2 other tissues ($C_1$569M, $C_1$589M). The slides were evaluated in the same sequence as they were found in the plastic slide boxes. However, the final analysis was performed according to the submitted information with regard to the groups of rats per each dose level and the data was summarized in tables.

The following criteria were used in the evaluation process:

Vacuolization: Small or large vacuolar changes in the hepatocytes (Fig. 1) indicative of fatty metamorphosis.

Focal acidophilic alteration: Focal degeneration of the hepatocytes characterized by intense eosinophilia of cytoplasm and pyknosis of nuclei (Fig. 2).

Single acidophilic alteration: Scattered eosinophilic alteration of hepatocytes (Fig. 3).

Focal granular alteration: Group of hepatocytes with a granular or vacuolar foamy appearance (Figs. 4 and 5).

Single granular alteration: The same cell alteration as above, but in scattered areas rather than in groups.

Perinuclear halo: Vacuolar alteration of cytoplasm in areas near the nuclei. This alteration was distinguishable from fatty metamorphosis, and seems to indicate the location of glycogen which was extracted by processing (Fig. 6). Such a change was often associated with

eosinophilic homogenization of the cytoplasm around the nuclei of the hepatocytes (Fig. 7) and seems to represent the cell-bounded glycogen.

Single cell necrosis Necrosis and degeneration of individual cells found throughout the tissue or as

group cell necrosis of a certain area. This alteration was found in 2 forms a lytic form (Fig. 8), indicative of acute toxic effect with or without minimal inflammatory reaction and coagulative form (coagulative necrosis) (Fig. 9) associated with epithelioid cell reaction (see below).

Cell enlargement: Enlargement of the hepatocytes up to 8-fold of their normal size in localized form as a so-called "hyperplastic nodule" (Fig. 10) or in a more or less diffuse form (Fig. 11, see also A_3: 311F, 287F, 241F, B_3: 982M, 983M, B_2x: 59F, 60F, B_3: 443F, 445F, 484M, 491M, 499M, 507F, 522F, 524F, 527F, 541F, Extra 1F, Extra 4F, 529F, Extra 1F, 2F, 3F). The enlarged cells showed usually eosinophilic, vacuolar or granular alterations (Figs. 12 and 13) and were often associated with bile duct formation (transformation) (Figs. 14 and 15), or with fibrosis (Fig. 16).

Ductual proliferation: Formation of new ducts or proliferation of principal ducts (Figs. 1, 12-16), sometimes associated with

periductal fibrosis in the form of connective tissue manchettes around the individual bile ducts, in contrast to

cholangiolithiasis, which was characterized by both bile duct proliferation and fibrosis (Fig. 17).

Kupffer cell proliferation: Activation or proliferation of Von Kupffer cells in localized area. Extramedullary hemopoetic foci were

included in this category.

Epithelioid cell granuloma: Focal inflammation, often with coagulative cell necrosis (Fig. 19). These lesions were often found in areas close to periportal triads or central veins (Figs. 18 - 20). In one case, this inflammatory reaction was present around a foreign body (Fig. 21), which probably represents a parasite. In another section, structures reminiscent of fungeal hyphen (aspergillus fumigatus?) were seen (Fig. 22).

Periportal inflammation: This inflammation occurred in varying degrees of severity, and often in cases with epithelioid cell granulomas (Fig. 18).

Lymph congestion: A peculiar lesion, characterized by formation of spaces lined with endothelial cells and filled with amorphous or granular material or erythrocytes (Fig. 23-25). These occurred in livers, without marked alteration of hepatocytes (Fig. 23), in livers with fatty metamorphosis (Fig. 24), or in areas with enlarged hepatocytes (Fig. 25). This alteration might correspond to fatty cysts or peliosis, as described by other investigators.

Crystal deposition: Light-polarizing material in the sinusoids, which probably represent fatty crystals.

Other lesions: In 4 animals, marked proliferation and cystic distention of the ducts (adenomatous ductal proliferation; cystic proliferation of bile ducts) were seen (Fig. 26). The non-neoplastic character of these lesions was evident by the uniform cytologic appearance of cells and identification of normal hepatocytes between the ducts, indicating a

glandular origin from the principal bile ducts. In one slide (B_3: 527Γ), atypical glands invading liver parenchyma were found. This lesion seems to represent a metastatic tumor (probably a mammary gland carcinoma of the same animal from which his tumor was submitted), rather than a cholangiocarcinoma. In the same animal localized cellular enlargements of hepatocytes were found, the cells showed a marked pleomorphism, and occasionally contained bile pigment (1+). There was no ductal proliferation and no periportal triad in this area, but there were hemopoietic foci.

RESULTS:

The histocytologic findings for individual slide(s) are listed on pages 13-37 and the summary of lesions, according to dose levels on pages 38-41 The grouping and subgrouping was based on the report of March 24, 1975, by Industrial Bio-Test Laboratories.

DISCUSSION.

The pathological changes in the livers of both experimental animals and controls varied in quantitative but not qualitative aspects. As the dose level increased, the lesions progressed in severity, indicating AROCLOR'S dose-dependent toxic effect. No marked differences could be found among rats treated with 3 different lots of AROCLOR.

The epithelioid cell granulomas often associated with coagulative cell necrosis and periportal round cell infiltration seem to reflect an endogenous disease, such as parasitic or fungal infestation (as found in 2 animals) in this colony of rats. The same might be true for the focal bile duct proliferation periductal fibrosis, and cholangiofibrosis. The apparently higher incidence of this inflammatory condition in the experimental animals might be sought as in

enhancing effect of the compound in the development and course of the dis[illegible]. However, since their incidence in 24-month-old control rats was even high[illegible] than in corresponding experimentals, such an iatrogenic effect of the compound should be ruled out. It should be also pointed out that much liver alteration in animals, as well as in man, is distributed unevenly in the parenchyma and therefore might not be detected in a single section. Examination and comparison of several different liver sections from the same rat will verify this fact. Besides their inflammatory reaction, many other liver lesions found seem unrelated to drugs, and represent, rather, spontaneous age-related alterations, since they appeared in a higher incidence in rats kept for 24 months. However, the more pronounced character of vacuolication and degenerative and regenerative changes is attributed to the toxic effect of the compound. The most frequent finding in rats treated with 100 ppm of compound was cell enlargement, mostly in localized areas which resembled so-called "hyperplastic nodules". We prefer the term "cell enlargement" to cell hypertrophy, since the enlargement of the hepatocytes in the submitted material is obviously due to degenerative effect( ) resulting in vacuolization, granulation and hydropic changes. The term hypertrophy should be reserved or describing regenerating or activated cells. The focal response of liver parenchyma to infectious or toxic agents is a known characteristic of the organ, and is in most cases, unspecific. Therefore, focal cell alterations do not always represent a "hyperplastic nodule" or premalignant and malignant lesions. The presence of many necrotic cells, sometime in form of pieceme[illegible] necrosis in areas of "hyperplastic nodules" definitely indicates their degenerative changes, associated with some regenerative process. The compression of surrounding tissue, due to focal enlargement of cells (which were sometimes 8 times larger than normal liver cells), is self-explanatory and is in no way indicative of malignant growth. A special staining would be of help in distinguishing non-neoplastic from neoplastic lesions, which usually destroy the normal structures, such as the reticular network. In our opinion, liver lesions should be

considered non-neoplastic, unless otherwise proven. Cytologic criteria, such as cellular pleomorphism and nuclear atypia, are uncharacteristic features and could be seen in any damaged cell, particular in those of organs with a tendency to rapidly regenerate. The criteria of the non-neoplastic lesions in the submitted slides can be summarized as follows:

1. No evidence of destruction

2. In several cases, cell enlargement was not limited to a certain area, but had largely or completely involved the entire liver lobe.

3. In many of the lesions, regular liver structures were found, such as periportal triads, central viens, sinusoids as well as bile ducts often showing a tendency to proliferate. These criteria are in favor of the benign character of these lesions (see Farber: Methods in cancer Research 7, 345, 1973). Since, as mentioned before, the liver lesions might show highly irregular distribution patters, the absence of some regular structures within the pathologic areas is anticipated, and the examination of step section(s) of such tissues pertinent.

4. The cells in an area encompassing enlarged cells (the so-called "hyperplastic nodules") show the same cytologic alteration, as in surrounding tissue or in areas remote from it. This is in contrast to the effect of well-known hepatogenic carcinogens, such as aflatoxin and ethionin in which following treatment, the tissue surrounding the hyperplastic nodules is little different from that of normal liver (Farber, Ibid.). In only one of the presented cases were there cytologic alterations which could justify a diagnosis of malignancy. However, even in that lesion regular sinusoids with hempoeitic foci (which are very unusual features for a hepatoma) were present, so that the malignant character of the lesion is questionable. It seems possible that the atypical cytologic alteration of this lesion is due to a response to a tumor metastasis, which was found in its borderline. The latter liver lesion could be interpreted as a cholangiocarcinoma. However, on comparing the histologic pattern of this tumor with the primary carcinoma from the same

rat, it becomes obvious that the liver lesion is a metastatic lesion, rather than a primary neoplasm. Nevertheless, interpretation of these particular lesions is difficult and further study is required. Other bile duct lesions, which we called adenomatous lesions, have been described and observed in many species and were considered cystic hyperplasia of the bile duct. The non-neoplastic character of these alterations is evident by their uniform histocytologic pattern and by the presence of normal liver cells between the ducts, indicating alteration of pre-existing ducts.

The question as to whether or not these lesions represent a premalignant alteration cannot be answered, using the present material, and further discussion could only be speculative. Since most liver carcinogens induce tumors during the 8-12 months from the beginning of the experiment, it seems doubtful that AROCLOR will cause neoplasms at a time later than 24 months, which is virtually the terminal age of many rat strains. However, additional study is needed to clarify the problem, particularly because different opinions exist about the nature of the liver lesions induced by AROCLOR. We might recommend the following.

1. Step-sectioning of the present material and special staining of some of the tissues. If this procedure would not clarify the situation, a new experiment should be started (see below).

2. The new set of experiments should compare findings in the same colony with those of other rat colonies, since apparently some strains of rats are unusually sensitive to certain compounds (Farber, Ibid.). For example the rats used in this study seemed to have an endogenous liver disease, which might influence the effect of the AROCLOR. The experiment should also include additional groups with different feeding periods - - (i.e., including rest periods as proposed by Tesbol and Becker (Cancer Res. 31, 1, 1971).

3. The use of special stains under certain experimental conditions might also deliver additional information (Epstein et al. Cancer Res. 27, 1702, 1967)

Legend:

Fig. 1: Vacuolization of hepatocytes and focal bile duct proliferation A3-275M, 250x.

Fig. 2: Focal eosinophilic alteration characterized by dense, ioseinophilic cytoplasm and pyknotic nuclei. B1-93ST, 250x

Fig. 3 Scattered, iosinophilic alteration of hepatocytes: B3-6PF, 250x.

Fig. 4: Focal granular alteration, associated with cell-enlargement Two hepatocytes showing eosinophilic alteration are seen within the granulated cells. Note atrophy of surrounding liver-tissue, probably due to compression of enlarge cells: B1x-43M, 250x.

Fig. 5. Different types of granular alteration of hepatocytes, interspersed with eosinophilic alteration. The granulated cells are often 8 times larger than normal hepatocytes: A3-271M, 250x.

Fig. 6: Perinuclear halo in hepatocytes: B1x-43M, 500x.

Fig. 7: Eosinophilic homogenization of cytoplasm. The eosinophilic material probably represents cell-bounded glycogen, which usually will be extracted during histologic processing, giving rise to structures shown in Fig. 6: B3-Extra 2F, 250x.

Fig. 8. Lyric form of group cell necrosis. No inflammatory reaction is seen B1-33FM, 250x.

Fig. 9 Coagulative group cell necrosis associated with inflammatory reaction B3-70L, 250x.

Fig. 10: Focal cell enlargement of hepatocytes. The sinusoidal structure is still present. Note pale nuclei with enlarged, but uniform nuclei B1-34 BM, 100x.

Fig. 11: Diffuse enlargement of hepatocytes with characteristic nuclei and nucleoli A portal triad is seen in middle of photo: A3-314F, 100x

Fig. 12: Focal cell enlargement with tendency toward bile-duct formation, A3-314F, 250x.

Fig. 13: Focal cell enlargement with vacuolic and granular alteration, as well as bile-duct formation: A3-275M, 250x.

Fig. 14. Focal cell enlargement showing proliferation of bile-duct epithelium B2-60F, 250x.

Fig. 15: Glandular structures of hepatocytes within areas of enlarged hepatocytes. Note apparent pleomorphisum of the cells; however no atypia is present: B3-Ext.F, 250x.

Fig. 16. Fibrosis and proliferation of bile-duct epithelium within area of regenerating and degenerating liver cells: A3-314F, 100x.

Fig. 17: Cholangiofibrosis surrounded by enlarged liver cells showing group cell necrosis (upper left corner): B3-541F, 100x.

Fig. 18: Epithelioid cell granuloma with coagulative cell necrosis, adjacent to a periportal triad, showing marked round cell infiltration. B3-70F, 250x.

Fig. 19: Epithelioid cell granuloma with a multi-nucleated giant cell. Vascular degeneration, cell necrosis and cell enlargement are seen in the surrounding tissue. B3-539F, 250x.

Fig. 20: Epithelioid cell granuloma with multiple giant-cells in area close to central vein (left lower corner): C2-707F, 250x.

Fig. 21: Foreign body probably representing a section of a parasite of the liver associated with cell necrosis and few inflammatory cells: C2-707F, 250x.

Fig. 22. Cystic degeneration containing structures similar to aspergillus fumigatus. B3-Extra 31, 250x.

MONS 219537

Fig. 23: Cystic degeneration. The cystic spaces are lined endothelial-like cells and are filled with homogenous eosinophilic or granular material. Minimal enlargement of the sourrounding liver cells. B3-489M, 250x.

Fig. 24. Cystic alteration resembling lymphangiectasia in a liver showing severe vacuolization: B3-459M, 250x.

Fig. 25: Cystic alteration in area of focal cell enlargement giving rise to papillary structures of the hepatocytes. Some of these spaces contain erythrocytes: A3-275M, 250x.

Fig. 26: Cystic proliferation of bile-ducts (adenomatous bile-duct proliferation) A3-243M, 100x.

Fig. 27: High magnification of the same lesion in Fig. 26 showing liver cell groups between proliferated ducts. Note completely benign appearance of the cells. 250x.

Fig. 28: Adenocarcinoma of the liver composed of tall columnar cells, interspersed with mucous-producing cells. Morphologically similar tumor was found in the mammary glands of the same rat: B3-527F, 250x.

Fig. 29: Area of focal cell enlargement displaying pleomorphism of the nuclei. B3-527, 500x.

Fig. 30: Another area of the same lesion showing intracytoplasmic bile-pigment (arrow). 500x.

MONS 219538

Code	C_1								C_2										C_3			
Sex	M	M	M	F	F	F	F	F	M	M	M	M	M	F	F	F	F	F	M	M	?	?
No	596	598	599	636	637	638	639	640	676	677	678	679	680	716	717	718	719	720	756	757	758	759
Vacuolization	+	+	+	+	+	+	+		+	+		+	+		+			+				
Focal acidophilic alteration																						
Single acidophilic alteration	+			+	+	+	+	+	+	+		+	+	+		+	+	+	+	+	+	+
Focal granular alteration																						
Single granular alteration		+											+	+			+	+		+	+	+
Perinuclear halo		+	+													+	+	+	+	+	+	+
Eosinophil homogenization	+		+							+	+	+	+			+			+	+	+	+
Single cell necrosis																						
Group cell necrosis																						
Cell enlargment																						
Ductal proliferation															+							
Periductal fibrosis																						
Cholangiofibrosis																						
Stern cell proliferation					+			+			+					+	+			+	+	+
Epithliod-cell granuloma								+							+							
Periportal inflamation					+	+		+			+	+			+	+	+	+	+	+		
Lymph congestion																						

MONS 219539

Co	C_3					C_2										C_1				
Sex	M		F	F	F	M	M	M	M	M	F	F	F	F	F	M	M	M	M	M
No	760	796	797	798	800	36	37	38	39	40	76	77	78	79	80	1011	1012	1013	1014	1015
Vacuolization					+				+	+						+	+	+		
Focal acidophilic alteration																				
Single acidophilic alteration	+	+	+	+	+		+	+	+	+	+	+	+	+	+	+	+	+	+	+
Focal granular alteration				+	+									+						
Single granular alteration	+	+	+	+	+		+	+	+	+	+	+	+	+	+					
Perinuclear halo	+	+	+		+	+	+	+	+	+	+	+	+	+	+	+				
Eosinoph. homogenization	+	+	+		+	+	+	+	+	+				+			+			
Single cell necrosis									+							+		+		
Group cell necrosis																				
Cell enlargment																				
Ductal proliferation	+						+													
Periductal fibrosis																	+			
Cholangiofibrosis																				
Stern cell proliferation		+		+		+			+		+				+					
Epithliod. cell granuloma													+			+	+	+	+	
Periportal inflamation													+			+	+	+	+	+
Lymph congestion																				

MONS 219540

Sex	C_1					C_2								C_3				
	F	F	F	F	F	F	M	M	M	F	F	F	F	M	M	1	M	F
	1026	1027	1028	1029	1030	1041	1042	1043	1045	1056	1057	1058	1059	1071	1072	1073	1075	1036
Vacuolization	+			+										+	+			
Focal acidophilic alteration																		
Single acidophilic alteration	+		+	+	+		+	+	+	+	+	+	+			+	+	+
Focal granular alteration	+					+	+	+	+	+	+	+	+			+		+
Single granular alteration	+	+		+	+									+	+		+	
Perinuclear halo	+	+	+	+	+	+	+	+	+	+	+		+		+	+	+	
Eosinoph homogenization						+		+	+							+		
Single cell necrosis					+	+	+	+	+			+				+		+
Group cell necrosis																		
Cell enlargment																		+
Ductal proliferation																		
Periductal fibrosis				+			+	+										
Cholangiofibrosis																		
Stern cell proliferation					+	+						+		+				
Epithliod cell granuloma	+		+		+	+	+		+	+	+	+						
Periportal inflamation	+	+	+	+	+			+	+	+	+	+	+					
Lymph congestion																		

MONS 219541

	C_3				C_0										C_1										C_2
	F	F	F	F	M	M	M	M	M	F	F	F	F	F	M	M	M	M	M	F	F	F	F	F	M
	1087	1088	1089	1090	801	802	803	804	805	816	817	818	819	820	71	72	73	74	75	76	77	78	79	80	81
[illegible]olization					+													+							
Focal acidophilic alteration																									
Single acidophilic alteration	+	+	+	+	+	+	+	+	+	+	+	+	+	+	+	+	+	+	+	+	+	+	+	+	+
Focal granular alteration	+			+														+							
Single granular alteration		+	+		+	+	+	+	+	+	+		+		+	+	+		+	+	+	+	+	+	+
Perinuclear halo					+	+	+	+	+	+	+	+	+	+	+	+	+	+	+	+	+	+	+	+	+
Eosinoph.homogenization					+		+	+	+							+	+	+	+	+				+	
Single cell necrosis	+		+	+	+	+	+	+					+	+		+	+	+		+		+	+	+	
Group cell necrosis																									
Cell enlargment	+																								
Ductal proliferation				+																					
Periductal fibrosis		+	+																						
Cholangiofibrosis																									
Stem cell proliferation		+			+	+	+																		
Epithlod cell granuloma	+					+								+			+			+		+		+	
Periportal inflamation					+	+			+	+			+	+	+		+	+	+	+		+		+	
[illegible] congestion																									

NONS 219542



	C_2									C_1																						
	M	M	M	M	F	F	F	F	F	M	M	M	M	M	F	F	F	F	M	M	M	M	M	F	F	F	F	M	M	M	M	M
	82	83	84	85	86	87	88	89	90	91	92	93	94	95	96	97	98	99	1	2	3	4	5	6	7	8	9	564	565	591	567	569
Vacuolization		+		+						+	+	+		+	+	+	+	+	+		+											
Focal acidophilic alteration																																
Single acidophilic alteration	+	+	+	+	+	+	+	+	+	+	+	+	+	+	+	+	+	+	+	+	+	+	+	+		+		+	+	+	+	
Focal granular alteration			+		+	+					+	+	+	+	+	+	+	+		+					+			+				
Single granular alteration	+	+		+			+	+	+	+	+	+	+	+	+	+	+	+	+	+	+	+	+	+	+	+	+	+		+		
Perinuclear holo	+	+	+	+	+	+				+	+	+					+	+	+	+	+	+	+	+	+	+	+	+	+	+	+	
Eosinoph homogenization			+	+								+	+	+	+			+	+	+	+	+	+						+	+		
Single cell necrosis	+	+	+	+	+	+	+	+	+	+	+	+	+	+	+	+	+	+	+	+	+	+					+			+		
Group cell necrosis																																
Cell enlargment											+	+	+		+	+	+	+														
Ductal proliferation			+	+	+						+	+					+										+	+	+	+	+	
Periductal fibrosis			+								+	+				+	+	+		+	+						+			+	+	
Cholangiofibrosis																																
Stern cell proliferation			+		+	+	+			+	+	+	+	+	+	+	+	+	+	+	+	+		+	+	+						
Epithilioa cell granuloma	+		+	+	+	+				+	+	+	+			+	+	+			+			+					+	+		
Per portal infiltration	+		+	+	+					+	+	+	+	+		+	+				+		+	+	+	+	+			+		
Lymph congestion											+																					

MONS 219543

Sex	M	M	M	M	M	M	F	F	F	F	M	F	F	F	F	F	F	F	F	F	F	F
No.	572	576	580	588	589	595	601	604	605	582	583	607	608	609	613	621	627	628	631	634	635	606	610
Vacuolization								+	+	+	+	+	+	+	+		-	+	+	+	+		+
Focal acidophilic alteration				+																			+
Single acidophilic alteration	+	+	+	+		+	+		+		+			+			+	+	+	+	+		+
Focal granular alteration								+		+		+		+						+			
Single granular alteration	+	+	+	+		+	+																
Perinuclear halo	+	+		+		+	+	+	+		+	+	+			+	+						
Eosinophil homogenization	+			+							+												
Single cell necrosis	+			+		+	+		+	+		+			+				+		+		-
Group cell necrosis																							
Cell enlargement																			+				
Ductal proliferation	+	+		+		+	+			+		+			+	+						+	+
Periductal fibrosis	+	+	+	+		+	+			+		+				+					+	+	+
Cholangiofibrosis				+			+																
Stem cell proliferation		+					+							+						+			-
Epithelioid cell granuloma		+																+					
Periportal inflammation		+					+							+					+				
Lung congestion																		+					

MILIARY LYMPHOMA

MONS 219544

	C_1			C_2													C_3						
	F	F	F	M	M	M	M	M	M	M	M	M	M	M	M	M	F	F	F	F	F	F	F
	620	626	633	655	657	662	667	640	641	643	644	645	646	649	651	673	775	Ext.	733	765	776	773	780
[illegible] solidation	+	+			+	+	+	+			+	+	+	+	+	+	+	+	+	+	+	+	+
Focal acidophilic alteration		+	+																				
Single acidophilic alteration	+	+	+	+		+	+	+					+	+	+		+	+	+		+	+	
Focal granular alteration			+			+			+	+							+	+			+	+	
Single granular alteration		+		+	+			+	+		+								+				
Perinuclear halo									+	+				+			+						
Eosinophil homogenization								+				+											
Single cell necrosis		+	+	+	+	+		+		+			+				+			+	+	+	
Group cell necrosis								+															
Cell enlargment								+				+					+	+	+	+	+	+	
Ductal proliferation			+	+	+		+	+			+	+	+				+		+		+	+	
Periductal fibrosis			+	+			+		+		+	+	+				+	+	+		+	+	
Cholangiofibrosis																			+		+	+	
Stem cell proliferation	+				+	+				+	+		+			+							
Epithelioid cell granuloma																				+			
Periportal inflamation			+	+		+		+		+		+	+									+	+
Lymph congestion						+					+												

MONS 219545

	C_5				
	M	F	F	F	F
No	724	766	767	771	789
Vacuolization	+	+	+	+	+
Focal acidophilic alteration					+
Single acidophilic alteration	+	+	+	+	+
Focal granular alteration		+	+	+	+
Single granular alteration	+	+	+	+	+
Perinuclear halo			+		+
Eosinophil homogenization					+
Single cell necrosis	+	+	+	+	+
Group cell necrosis			+		+
Cell enlargment		+	+	+	+
Ductal proliferation		+	+	+	+
Periductal fibrosis			+		+
Cholangiofibrosis			+		+
Stern cell proliferation	+		+	+	+
Epithliod.cell granuloma					
Periportal inflamation					
[illegible] congestion					
Fibrosis			+		+
[illegible]				+	

MONS 219546

	C_1		C_2							C_3															
Sex	F	F	M	M	M	M	M	M	M	F	F	F	F	F	F	F	F	F	F	F	F	F	F	F	F
	793	Ext.	8	8	11	12	21	23	33	686	687	689	685	690	695	697	700	703	707	708	711	712	682	683	691
Vacuolization	+	+	+			+		+		+	+	+	+	+		+	+	+	+	+	+	+	+		+
Focal acidophilic alteration																	+								
Single acidophilic alteration			+	+	+	+	+	+	+	+	+							+	+	+		+		+	+
Focal granular alteration		+		+			+	+	+			+							+			+	+	+	
Single granular alteration			+	+	+					+						+	+			+	+	+			
Perinuclear halo		+	+			+			+	+	+	+	+				+		+		+	+	+	+	+
Eosinophilic homogenization		+					+											+				+			
Single cell necrosis		+												+					+			+	+		
Group cell necrosis																				+					
Cell enlargment		+		+													+								
Ductal proliferation	+	+	+	+		+	+	+	+		+									+					+
Pericystal fibrosis			+	+	+		+	+	+	+			+							+		+			
Cholangiofibrosis		+			+																				
Stem cell proliferation		+	+		+						+					+	+				+	+		+	
Epithelioid cell granuloma									+					+		+	+		+		+	+		+	
Periportal inflamation																+	+	+			+	+		+	
Liver congestion																									

MOMS 219547

	C_2	C_0																									
Sex	F	M	M		F	F	F	F	F	F	F	F	F	F	F	F	F	F	M	M	M	M	M	M	F	F
	702	34	35	Exc.	46	47	49	51	52	56	59	62	63	64	66	70	71	Exc.	116	117	118	119	120	147	156	157
Vacuolization	+				+		+	+			+	+					+		+		+	+			+	+
Focal acidophilic alteration		+				+					+	+														
Single acidophilic alteration	+	+	+	+	+	+	+	+	+	+	+	+	+	+	+	+	+	+	+	+	+	+	+	+	+	+
Focal granular alteration	+				+		+	+							+									+		
Single granular alteration		+	+	+	+	+	+	+		+	+	+	+	+		+	+	+	+	+		+	+	+	+	+
Perinuclear halo	+	+	+	+	+	+	+	+	+	+	+	+	+	+			+	+	+	+	+	+	+	+	+	+
Eosinoph homogenization	+	+	+			+	+	+	+				+		+	+	+	+				+	+	+	+	+
Single cell necrosis		+	+	+	+		+	+				+	+	+		+	+						+	-		+
Group cell necrosis										+				+												
Cell enlargement										+		+														
Ductal proliferation		+			+		+	+	+	+			+		+	+	+	+							+	+
Periductal fibrosis		+					+	+	+	+		+	+	+	+		+							+	+	+
Cholangiofibrosis												+					+									
Stem cell proliferation		+	+	+	+		+	+				+	+		+			+	+							+
Epithelioid cell granuloma		+		+	+		+					+		+									+			
Periportal inflammation		+		+	+		+	+				+				+	+									
Liver congestion																		+								

MONS 219548

	A													A_3		A_2			A_3			
	F	F	F	M	M	M	M	M	F	F	F	F	F	M	M	M		F	F	F	F	F
	158	159	160	195	196	198	200	Ext.	236	237	238	239	240	276	277	279	280	315	317	318	319	320
Vacuolization	+			+	+	+	+						+		+							
Focal acidophilic alteration																						
Single acidophilic alteration	+	+	+	+	+	+	+	+			+	+	+	+	+	+	+	+	+	+	+	+
Focal granular alteration														+	+	+	+		+			
Single granular alteration		+	+	+	+	+	+		+	+	+	+	+	+	+	+	+	+	+	+	+	+
Perinuclear nolo	+	+	+	+	+	+	+	+		+	+	+	+		+	+	+	+	+	+	+	+
Eosinoph. homogenization				+	+	+	+	+		+	+	+	+	+	+	+		+				
Single cell necrosis		+		+	+	+	+				+	+	+		+		+			+		+
Group cell necrosis																						
Cell enlargrent														+	+	+				+		
Ductal proliferation										+	+	+		+		+			+			
Periductal fibrosis		+	+							+	+	+	+		+	+						
Cholangiofibrosis																						
Stern cell proliferation		+			+	+	+			+	+	+	+						+	+	+	+
Epithelioid cell granuloma		+							+	+	+											
Periportal inflamation						+															+	
Lymph congestion																						

MONS 219549

	?	?	?	?	?	?	?	?	?	?	?	M	M	M	M	?	F	F	F	F	M	M	M
	832	835	834	846	848	849	864	865	873	878	879	891	633	894	895	906	907	908	909	910	11	12	13
Vacuolization												+		+		+							+
Total acidophilic alteration																							
Single acidophilic alteration	+	+	+	+	+	+	+	+	+	+	+	+	+	+	+	+	+	+	+	+	+	+	+
Focal granular alteration	+							+	+	+		+	+	+		+						+	+
Single granular alteration	+	+	+	+	+	+	+	+	+	+		+	+	+	+	+	+	+	+	+	+	+	+
Perinuclear halo	+	+	+	+	+	+	+	+	+		+	+	+	+	+	+	+	+	+	+	+	+	+
Eosinoph homogenization			+		+	+	+	+	+			+	+	+	+	+	+			+	+	+	+
Single cell necrosis	+	+	+			+	+	+	+	+		+	+	+		+							+
Group cell necrosis																							
Cell enlargment								+					+	+									
Ductal proliferation		+				+		+	+			+			+								
Periductal fibrosis	+	+				+		+	+	+		+	+		+		+				+	+	
Cholangiofibrosis																							+
Stern cell proliferation	+	+	+	+	+		+	+	+														
Epithliod cell granuloma	+	+	+	+	+	+		+		+											+	+	+
Periportal inflamition	+	+	+	+		+	+	+	+				+							+	+		+
Lymphocytic infiltration																							
Crystal deposition									*+														

MONS 219550

		A_1			?	A_1						?								A_3					A_4		?		
	M	M	F	F	F	F	M	M	M	M	M	F	F	F	F	F	?	?	?	M	F	F	F	F	?	?	?	?	
	14	15	16	17	18	19	21	22	23	24	25	26	27	28	29	30	31	32	33	34	36	37	38	39	40	85	86	87	101
Vacuolization					+					+	+		+									+							
Focal acidophilic alteration																													
Single acidophilic alteration	+	+	+	+	+	+	+	+	+	+	+	+	+	+	+	+	+	+	+	+	+	+	+	+	+	+	+	+	+
Focal granular alteration	+	+		+		+	+	+	+	+	+	+	+			+	+	+	+	+		+	+	+	+	+	+	+	
Single granular alteration	+	+	+	+	+	+	+	+	+	+	+	+	+	+	+	+	+	+	+	+	+	+	+	+	+	+	+	+	+
Perinuclear halo		+	+	+	+	+	+	+	+	+	+	+	+	+	+	+					+	+	+	+	+	+	+		+
Eosinophilic homogenization		+	+				+		+	+	+	+	+		+	+		+		+	+	+	+	+	+	+	+		+
Single cell necrosis		+					+	+	+	+			+							+		+	+	+	+	+	+	+	
Group cell necrosis																												+	
Cell enlargment																		+		+	+	+	+	+	+				+
Ductal proliferation	+													+								+	+	+	+	+		+	+
Periductal fibrosis	+																+			+		+	+	+	+	+		+	+
Cholangiofibrosis																													
Stem cell proliferation		+	+	+				+		+			+				+		+	+							+		
Epithelioid cell granuloma		+						+			+		+							+						+	+		
Periportal inflamation	+	+		+				+			+		+	+												+	+		+
Liver congestion																										+			
*Crystal deposition						+							++																

MONS 219551

	?	?	?	A1 N	?	?	? F	?	?	?	A1 ?	?	F	F	F	F	F	F	F	F	F	?
	106	112	114	105	107	109	122	125	127	129	130	138	141	147	151	155	144	131	132	135	139	127
[illegible]olization					+		+					+				+						
Focal acidophilic alteration						+														+	+	+
Single acidophilic alteration	+	+	+	+	+	+	+	+	+	+	+	+	+	+	+	+	+	+	+	+	+	+
Focal granular alteration				+	+	+	+				+									+		+
Single granular alteration	+	+	+	+	+	+	+	+	+	+	+		+	+	+	+	+	+	+	+	+	+
Perinuclear holo	+	+	+	+	+	+			+	+	+		+	+	+	+	+	+	+			+
Eosinophilic homogenization	+	+	+	+	+	+			+	+	+			+	+	+						+
Single cell necrosis				+		+	+		+		+	+										
Group cell necrosis																						
Cell enlargment							+													+		
Ductal proliferation	+	+		+	+	+	+	+	+	+					+				+	+		+
Periductal fibrosis	+	+			+	+	+	+	+	+					+			+		+		+
Cholangiofibrosis	+		+					+		+										+	+	
Stern cell proliferation																		+	+			
Epithliod cell granuloma				+			+												+			
Periportal inflamation				+			+							+				+	+			+
Lymph congestion																						
* Crystal deposition											*+											

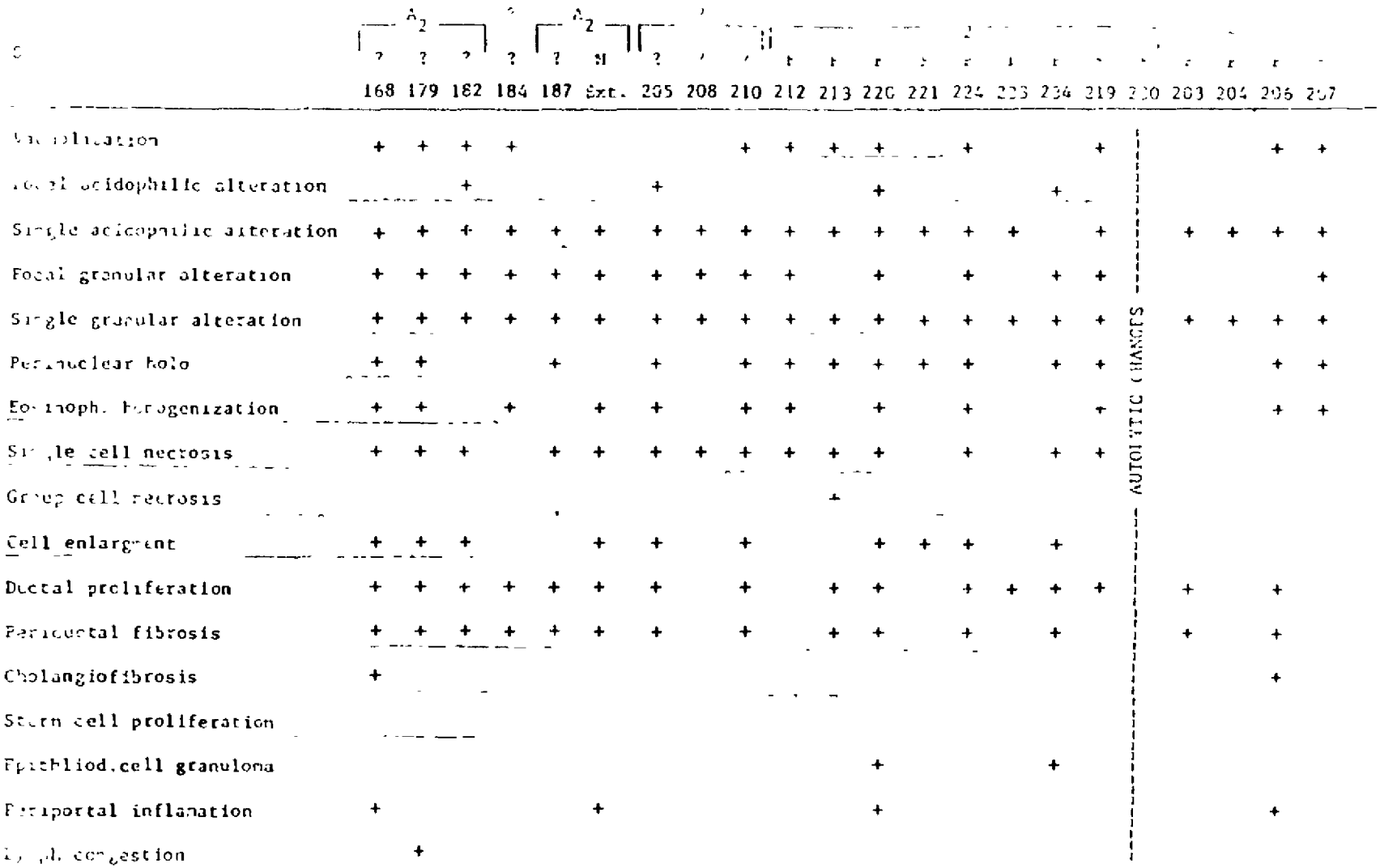
A2
A2
168 179 182 184 187 Ext. 205 208 210 212 213 220 221 224 233 234 219 220 203 204 206 207
Vacuolization
Focal acidophilic alteration
Single acidophilic alteration
Focal granular alteration
Single granular alteration
Perinuclear halo
Eosinoph. homogenization
Single cell necrosis
Group cell necrosis
Cell enlargement
Ductal proliferation
Pericuctal fibrosis
Cholangiofibrosis
Stern cell proliferation
Epithliod cell granuloma
Periportal inflamation
Hepat. congestion
AUTOLYTIC CHANGES

MONS 219553

	A3	?		?	A3		?				A3	?			?	?	A3						
	M	?	M	?	M	M	M	M	M	M	M	?	M	M	?	?	F	F	F	F	F	F	F
	241	253	261	264	270	271	272	275	243	244	312	231	274	275	294	297	302	305	308	311	314	210	245
Vacuolization	+	+		+	+		+			+	+		+	+	+	+			+	+	+	+	+
Focal acidophilic alteration		+																					
Single acidophilic alteration	+	+	+	+	+	+		+	+	+		+	+	+	+	+	+	+	+	+	+	+	+
Focal granular alteration	+	+	+	+	+	+		+	+		+	+	+	+	+	+	+	+	+	+	+	+	+
Single granular alteration	+	+	+	+	+	+		+	+	+	+	+	+	+	+	+	+	+	+	+	+	+	+
Perinuclear halo	+			+	+					+		+	+			+			+	+	+	+	+
Eosinoph homogenization	+			+	+	+				+		+	+			+	+		+	+	+	+	+
Single cell necrosis	+	+	+	+	+	+		+			+	+	+	+	+	+	+		+	+	+	+	+
Group cell necrosis	+	+	+	+										+	+	+	+			+	+	+	+
Cell enlargment	+	+		+	+	+		+	+	+	+	+	+	+	+	+	+		+	+	+	+	+
Ductal proliferation	+		+	+	+	+		+	+	+	+	+	+	+	+	+	+	+	+	+	+	+	+
Periductal fibrosis	+	+	+	+	+	+		+		+	+	+	+	+	+	+			+	+	+	+	+
Cholangiofibrosis	+		+		+						+				+						+	+	+
Stem cell proliferation						+																	+
Epithliod.cell granulona										+								+					
Periportal inflamation	+	+	+	+	+	+				+	+							+					
Lymph congestion	+	+		+						+				+									

AUTOLYTIC CHANGES

MONS 219554

[illegible]	[illegible]	[illegible]	?	?	[illegible]
[illegible]	F	F	?	?	F
[illegible]	281	287	291	291	309
[illegible]olization	+	+	+	+	+
Focal acidophilic alteration		+			
Single acidophilic alteration	+	+	+	+	+
Focal granular alteration	+	+	+	+	+
Single granular alteration	+	+	+	+	+
Perinuclear halo		+	+		+
Eosinoph. homogenization	+	+	+	+	
Single cell necrosis	+	+	+	+	+
Group cell necrosis			+	+	+
Cell enlargment	+	+	+	+	+
Ductal proliferation	+	+	+	+	+
Periductal fibrosis	+	+	+	+	+
Cholangiofibrosis	+	+	+		+
Stem cell proliferation					
Epithelioid cell granuloma					
Peri.portal inflamation					
Lymph congestion					+

MONS 219555

	G_1										G_2										G_3	
Sex	M	M	M	M	M	F	F	F	F	F	M	M	M	M	M	F	F	F	F	F	M	M
No.	356	357	358	359	360	396	397	398	399	400	436	437	438	439	440	476	477	478	479	480	516	517
Vacuolization	+	+											+								+	
Focal acidophilic alteration																						
Single acidophilic alteration	+	+	+	+	+	+	+	+	+	+	+	+	+	+	+	+	+	+	+	+	+	+
Focal granular alteration		+					+														+	
Single granular alteration	+	+	+	+	+	+	+		+		+	+	+	+	+	+	+	+	+	+	+	+
Perinuclear halo	+	+	+	+	+	+	+	+	+	+	+	+	+	+	+	+	+	+	+	+	+	+
Eosinoph. homogenization	+	+	+	+	+	+	+		+		+	+	+	+	+	+		+	+	+	+	+
Single cell necrosis																+					+	
Group cell necrosis																						
Cell enlargement																					+	
Ductal proliferation																						
Periductal fibrosis		+			+		+			+												
Cholangiofibrosis																						
Stem cell proliferation	+				+		+	+	+				+	+		+	+	+	+	+	+	
Epithlioid cell granuloma							+					+				+						
Periportal inflamation	+	+					+									+					+	
Liver congestion																						

MONS 219556

	B_3								B_1										B_2			
	M	M	M	F	F	F	F	F	M	M	M	M	M	F	F	F	F	F	M	M	M	M
	518	519	520	555	557	558	559	560	921	922	923	924	925	936	937	938	939	940	950	951	952	953
[illegible]ization	+	+	+													+	+					+
Focal acidophilic alteration																+						
Single acidophilic alteration	+	+	+	+	+	+	+	+	+	+	+	+	+	+	+	+	+	+	+	+	+	+
Focal granular alteration	+			+	+		+															
Single granular alteration	+	+	+	+	+	+	+	+	+	+	+	+	+	+	+	+	+	+	+	+	+	+
Perinuclear halo	+	+	+	+	+	+	+	+	+	+	+	+	+	+	+		+	+	+	+	+	+
Eosinophil homogenization	+	+	+				+	+	+	+	+	+	+	+	+	+	+	+	+	+	+	+
Single cell necrosis				+			+		+		+					+	+	+			+	
Group cell necrosis	+																					
Cell enlargment	+	+	+																			
Ductal proliferation											+						+					
Periductal fibrosis							+				+			+	+					+		
Cholangiofibrosis																						
Stem cell proliferation	+	+	+	+	+		+				+	+	+		+		+	+			+	+
Epithliod cell granuloma	+			+			+		+		+			+			+	+			+	
Periportal inflamation				+					+	+	+				+		+	+			+	
Lymph congestion																						

MONS 219557

	M	F	F	F	F	F	M	M	M	M	M	F	F	F	F	F	M	M	M	M	M	F	F	F
	954	966	967	968	969	970	981	982	983	984	985	996	997	998	999	1000	41	42	43	44	45	46	47	48
Hyperplasia	+						+	+	+	+	+	+					+	+	+					
Focal acidophilic alteration								+	+								+					+		
Single acidophilic alteration	+	+	+	+	+	+	+	+	+	+	+	+	+	+	+	+	+	+	+	+	+	+	+	+
Focal granular alteration									+		+		+	+	+		+	+	+	+	+	+	+	
Single granular alteration	+	+	+	+	+	+	+	+	+	+	+	+	+	+	+	+	+	+	+	+	+	+	+	+
Perinuclear halo	+				+	+	+	+	+															
Eosinophil homogenization	+				+	+	+	+	+	+	+	+					+	+	+	+	+		+	
Single cell necrosis	+		+	+		+	+	+	+	+	+	+	+		+									
Group cell necrosis										+														
Cell enlargement							+	+	+	+	+	+		+	+	+								
Ductal proliferation			+			+	+	+	+				+		+		+	+						-
Periductal fibrosis					+	+	+	+	+	+	+													
Cholangiofibrosis																								
Stem cell proliferation	+	+	+	+	+	+	+	+	+			+	+										+	
Epithelioid cell granuloma			+	+		+	+	+	+	+	+													
Periportal inflamation	+		+	+	+	+	+	+	+	+	+								+					
Lymph congestion																								

MONS 219558

	B_1 x		B_2 x							B_2					B_3							B_1					
Sex	F	F	M	M	M	M	M	F	F	F	F	F	M	M	M	M	M	M	F	F	F	F	M	..	.	M	M	M
No	49	50	51	52	53	54	55	56	57	58	59	60	61	62	63	64	65	66	67	68	69	70	326	333	335	338	351	523
Vacuolization	+	+		+	+	+	+	+	+		+	+	+			+	+				+		+		+	+	+	
Focal acidophilic alteration	+			+												+				+							+	
Single acidophilic alteration	+	+	+	+	+	+	+	+	+	+	+	+	+	+	+	+	+	+	+	+	+	+	+	+	+	+	+	+
Focal granular alteration	+	+	+	+	+	+	+		+	+	+	+	+	+	+	+	+	+		+	+	+	+	+	+	+	+	
Single granular alteration	+	+	+	+	+	+	+	+	+	+	+	+	+	+	+	+	+	+	+	+	+	+	+	+	+	+	+	+
Perinuclear halo	+	+	+	+	+	+	+	+	+	+	+	+	+	+	+	+	+		+	+	+	+	+	+	+	+	+	+
Eosinoph. homogenization			+	+	+	+	+	+	+	+	+		+		+	+	+	+			+		+	+	+	+	+	+
Single cell necrosis				+	+	+	+	+			+	+	+	+		+	+	+	+	+	+	+	+	+			+	
Group cell necrosis																+						+				+	+	
Cell enlargement											+	+					+											
Ductal proliferation	+					+			+			+					+		+			+		+	+		+	+
Periductal fibrosis									+													+	+	+	+			
Cholangiofibrosis																												
Stem cell proliferation			+	+		+	+		+					+			+		+		+	+	+				
Epithliod.cell granuloma						+	+	+				+	+	+					+	+		+						
Periportal infiltration				+		+	+	+					+	+			+		+			+	+					
Lymph congest.																		+										

MONS 219559

	B1																				
	M	M	M	F	F	I	F	F	F	F	F	F	F	F	F	F	F	F	F	F	F
	325	343	340	342	362	368	374	375	376	475	366	367	372	377	278	379	380	381	384	387	385
olization				+										+	+	+			+		
al acidophilic alteration		+																			
Single acidophilic alteration	+	+	+	+	+	+	+	+	+	+	+	+	+	+	+	+	+	+	+	+	
Focal granular alteration	+			+	+	+	+	+	+					+			+		+	+	
Single granular alteration	+	+	+	+	+	+	+	+	+	+	+	+	+	+	+	+	+	+	+	+	
Perinuclear halo	+	+	+	+			+	+	+	+	+		+		+	+	+	+	+	+	
Cytoplasmic homogenization	+	+	+				+	+			+				+	+	+	+	+	+	
Single cell necrosis	+	+	+	+	+	+	+	+	+	+				+		+				+	+
Group cell necrosis														+							
Cell enlargment		+	+				+		+						+			+			
Ductal proliferation		+	+	+		+	+	+		+	+		+			+					
Periductal fibrosis		+	+	+		+	+	+	+	+	+		+			+			+		
Cholangiofibrosis			+	+		+			+	+	+		+			+					
Stem cell proliferation									+					+		+					
Epithlioid cell granuloma			+		+		+		+											+	+
Periportal inflamation									+							+				+	+
Liver congestion														+	+						


E1
E2
F F F F M M M M M M M M M M M M F F F F
389 391 394 Ext. 415 417 418 419 423 426 427 431 402 403 405 410 434 456 451 452
Necrobiosis
Focal acidophilic alteration
Single acidophilic alteration
Focal granular alteration
Single granular alteration
Perinuclear halo
Eosinoph. homogenization
Single cell necrosis
Group cell necrosis
Cell enlargement
Ductal proliferation
Periductal fibrosis
Cholangiofibrosis
Stem cell proliferation
Epithelioid cell granuloma
Periportal inflamation
Lymph congestion
ADVANCED AUTOLYSIS
ADVANCED AUTOLYSIS

MONS 219561

	B_2									B_3												
Sex	F	F	F	F	F	F	F	F	F	M	M	M	M	M	F	M	M	M	M	M	F	F
	459	463	469	470	471	473	443	445	448	484	491	497	499	499	507	509	5 0	510	483	484	522	[illegible]
Vacuolization	+	+	+			+	+	+		+	+	+	+	+	+	+	+	+	+	+	+	+
Focal acidophilic alteration						+										+	+					
Single acidophilic alteration	+	+	+	+	+	+	+	+		+	+	+		+	+	+	+	+	+	+	+	+
Fine granular alteration	+	+	+	+	+	+		+		+	+	+	+	+	+	+	+	+	+	+	+	+
Single granular alteration	+	+	+	+	+	+	+	+	+	+	+	+	+	+	+	+	+	+	+	+	+	+
Perinuclear halo	+	+	+		+	+	+	+	+		+			+	+	+	+					
Eosinoph. homogenization	+	+	+		+	+	+	+	+													
Single cell necrosis		+	+			+		+		+	+	+	+	+	+	+	+	+	+	+	+	+
Group cell necrosis				+						+	+			+	+							
Cell enlargment	+	+				+	+	+	+	+	+	+	+	+	+	+	+		+	+	+	+
Ductal proliferation	+	+		+	+	+	+			+	+	+			+	+	+	+	+	+	+	
Periductal fibrosis			+			+				+	+	+				+	+	+		+	+	
Cholangiofibrosis						+					+							+	+	+	+	
Stem cell proliferation			+							+												+
Epithiod cell granuloma			+												+					+		
Periportal inflammation			+	+						+								+		+	+	
Blood congestion														+						+		
Portal fibrosis															+							

MONS 219562

Case																
Sex	F	F	F	1F	2F	3F	4F	5F	5F	F	F	F	F	1F	2F	3F
Day	527	541	547	Ext.	Ext.	Ext.	Ext.	Ext.	Ext.	536	537	539	441	Ext.	Ext.	Ext.
Vacuolization	+	+	+	+	+	+	+	+		+		+		+	+	+
Focal acidophilic alteration														+	+	
Single acidophilic alteration	+	+	+	+	+	+	+	+	+	+	+	+	+	+	+	+
Focal granular alteration	+	+	+	+	+	+	+	+	+	+			+	+	+	+
Single granular alteration	+	+	+	+	+	+	+	+	+	+	+	+	+	+	+	+
Perinuclear halo			+	+					+		+	+		+		+
Eosinoph homogenization									+					+		
Single cell necrosis	+	+	+	+	+	+	+	+		+	+	+		+	+	+
Group cell necrosis	+	+	+	+	+	+	+	+	+	+	+	+			+	
Cell enlargment	+	+	+	+	+	+	+	+				+		+	+	+
Ductal proliferation	+	+	+	+	+		+	+	+	+		+	+	+	+	+
Periductal fibrosis	+	+	+	+	+	+	+	+	+	+		+		+	+	+
Cholangiofibrosis		+		+			+	+		+		+	+	+	+	
Stem cell proliferation	+			+												
Epithliod.cell granuloma												+				
Peripertal inflamation	+			+												
Liver congestion																
[illegible](*)	+															
[illegible](*)	+															
[illegible] lesion					+										+	

MONS 219563

A GROUP

Sacrifice Interval	3 Months			8 Months			14 Months			24 Months		
Dose Level	AI	AII	AIII	AI	AII	AIII	AI	AII	AIII	AI	AII	AIII
No. of Animals	11	10	9	6	5	9	9	10	9	25	22(23)	27(28)
Vacuolization	6	5	1	0	0	3	2	3	1	4	12	20
Focal acidophilic alteration	0	0	0	0	0	0	0	0	0	3	5	2
Single acidophilic alteration	11	8	9	6	5	9	9	10	9	25	21	26
Focal granular alteration	1	0	5	1	3	4	6	8	8	9	16	26
Single granular alteration	7	9	9	6	4	9	9	10	9	24	22	27
Perinuclear halo	11	9	8	6	4	9	8	10	5	19	15	15
Eosinoph. homogenization	5	9	4	3	3	7	5	8	7	15	13	18
Single cell necrosis	4	7	4	4	4	4	2	5	5	9	14	24
Group cell necrosis	0	0	0	0	0	0	0	0	0	1	1	15
Cell enlargment	0	0	4	0	1	2	0	0	7	3	10	25
Ductal proliferation	2	3	3	2	2	2	1	1	4	15	17	26
Periductal fibrosis	5	4	2	3	3	4	3	0	6	14	15	24
Cholangiofibrosis	0	0	0	0	0	0	1	0	0	6	2	12
Stern cell proliferation	2	7	4	5	3	0	3	3	3	3	0	2
Epithlfod. cell granuloma	2	3	0	6	2	0	4	3	1	5	2	2
Periportal inflammation	0	1	1	5	3	2	5	4	0	8	5	9
Lung congestion	0	0	0	0	0	0	0	0	0	1	1	6
Cerebellar cavitation	0	0	0	0	1	0	1	2	0	1	0	0

MONS 219564

B GROUP

Sacrifice Interval	3 Months			8 Months			14 Months			24 Months		
Dose Level	1ppm	10ppm	100ppm	1ppm	10ppm	100ppm	1ppm	10ppm	100ppm	1ppm	10ppm	100ppm
No. of Animals	10	10	10	10	10	10	10	10	10	31	26	29
Vacuolization	2	1	3	2	2	6	5	8	4	11	15	26
Focal acidophilic alteration	0	0	0	1	0	2	3	1	2	3	3	4
Single acidophilic alteration	10	10	10	10	10	10	10	10	10	30	19	28
Focal granular alteration	2	0	5	0	0	5	9	9	9	17	13	27
Single granular alteration	8	10	10	10	10	10	10	10	10	31	23	29
Perinuclear holo	10	10	10	9	7	9	9	10	9	25	20	12
Eosinoph. homogenization	8	9	7	10	7	6	6	9	6	20	16	2
Single cell necrosis	0	1	3	5	5	8	0	7	9	19	10	26
Group cell necrosis	0	0	1	0	0	1	0	0	2	3	3	18
Cell enlargment	0	0	4	0	0	9	0	2	1	7	8	24
Ductal proliferation	0	0	0	2	2	5	4	3	3	16	14	24
Periductal fibrosis	4	0	1	3	3	5	0	1	1	17	6	22
Cholangiofibrosis	0	0	0	0	0	0	0	0	0	10	3	14
Stern cell proliferation	5	7	7	5	8	5	1	5	5	4	4	4
Epithlioid cell granuloma	1	2	3	4	4	6	0	4	5	7	5	2
Periportal inflamation	3	1	2	5	5	5	1	4	5	6	6	6
Lymph congestion	0	0	0	0	0	0	0	0	1	3	1	2

[illegible] fibrosis
[illegible]
[illegible] locarcinoma (?)
[illegible] ns

MONS 219565

C GROUP

Sacrifice Interval	3 Months				8 Months				14 Months			
Dose Level	1ppm	10ppm	100ppm	control	1ppm	10ppm	100ppm	control	1ppm	10ppm	100ppm	control
No. of Animals	8	10	9	10	10	8	9	10	10	10	9	9
Vacuolization	7	6	1	2	5	0	0	1	1	2	8	2
Focal acidophilic alteration	0	0	0	0	0	0	0	0	0	0	0	0
Single acidophilic alteration	6	8	9	9	9	7	7	10	10	10	9	7
Focal granular alteration	0	0	2	1	1	8	4	0	1	3	8	2
Single granular alteration	1	4	8	9	4	0	5	0	2	7	2	2
Pyrimuclear holo	2	7	8	10	5	7	3	10	10	7	9	9
Eosinoph. hocogenization	2	5	8	6	5	3	1	4	6	2	5	5
Single cell necrosis	0	0	0	1	3	4	5	6	7	9	9	5
Group cell necrosis	0	0	0	0	0	0	0	0	0	0	0	0
Cell enlargment	0	0	0	0	0	0	2	0	0	0	7	0
Ductal proliferation	0	1	1	1	0	0	1	0	0	3	3	1
Periductal fibrosis	0	0	0	0	2	2	2	0	0	1	5	3
Cholangiofibrosis	0	0	0	0	0	0	0	0	0	0	0	0
Stern cell proliferation	2	3	5	4	2	2	2	3	0	4	9	7
Epithliod. cell granuloma	1	1	0	1	7	6	1	2	4	5	7	2
Peraportal inflamation	3	6	2	1	10	6	0	6	7	4	7	6
Liver congestion	0	0	0	0	0	0	0	0	0	0	1	0

C GROUP

Sacrifice Interval	24 Months			
Dose Level	1ppm	10ppm	100ppm	control
No. of Animals	29(31)	30	14	24
Vacuolization	16	25	14	9
Focal acidophilic alteration	4	1	1	4
Single acidophilic alteration	22	16	10	24
Focal granular alteration	7	9	9	8
Single granular alteration	9	11	6	18
Perinuclear hole	12	15	4	20
Eosinoph homogenization	5	5	1	12
Single cell necrosis	14	10	10	11
Group cell necrosis	0	2	2	2
Cell enlargment	1	3	12	4
Ductal proliferation	16	11	10	17
Periductal fibrosis	15	10	7	16
Cholangiofibrosis	2	0	6	3
Stem cell proliferation	6	12	5	12
Epithlioid cell granuloma	4	7	1	7
[illegible] portal inflammation	7	6	2	8
[illegible]	1	2	0	1
[illegible]			2	
[illegible]			1	

MONS 219567

REVIEW OF THE TECHNICAL AND REGULATORY ASPECTS OF AROCLORS

On the basis of the results obtained in the chronic studies on the various PCB's at BIO-TEST, the conclusion has been reached that these materials are not carcinogenic. The slides have been reviewed three times by Drs. D. Gordon and W. Richter and their findings support this conclusion.

Certain liver changes occur in varying degree with the different Aroclors that are subject to several interpretations, as well as nomenclature and classification.

In the classical pathological sense the liver alterations seen with the Aroclors are benign in character. Lesions of this type have been shown to be reversible. Further, the benign features include lack of vascular invasion and lack of metastases as well as lack of transplantability.

The liver changes such as focal hyperplasia, hypertrophic nodules, and adenofibrosis may be induced by other chlorinated aromatic and aliphatic hydrocarbons. Some of the latter materials that may produce these lesions, such as dieldrin, aldrin, and carbon tetrachloride, are considered to be carcinogenic by the EPA and the National Cancer

MONS 219568

Institute. In fact, these groups have redefined these terms as well as the concept of benign and malignant lesions as they have been used traditionally.

The view of these groups is that any tumor induced by a chemical is malignant despite the absence of the classical histological features of malignancy. The legal division of the EPA has enthusiastically embraced this approach and has used it successfully to cancel the registration of dieldrin and aldrin and are about to launch litigation against chlordane and heptachlor. It is expected that the registration of the latter materials will be in due course cancelled.

In the case of liver changes, the EPA and the National Cancer Institute have adopted the view that in the extreme any material which induces liver microsomal enzymes is a suspect carcinogen. In addition, focal hyperplasia of the liver produced by chemicals is being classified as a premalignant change and the chemicals involved are being classified as suspect carcinogens. Additional histological effects such as nodular hyperplasia are also considered to be premalignant. The philosophy that has been adopted by these agencies is that substances which cause the above liver changes are in fact carcinogenic. This philosophy permeates the extensive EPA brief in the legal proceedings to cancel the registration of dieldrin and aldrin as well as in its preliminary legal presentation on chlordane and heptachlor.

The EPA is supported by the National Cancer Institute as represented by Drs. U. Saffiotti, R. Squires, and W. Heston. In addition, non-government affiliated pathologists such as Drs. E. Farber, and M. Reuber, H. Popper and S. Epstein support the agencies' views.

On the other hand, a number of pathologists such as Drs. J. Newberne, W. Butler, G. Jones, A. Stein, G. Kent, D. Gordon, and W. Richter do not agree with the agency definitions or with the presumed end-point of the liver lesions - cancer. In this regard, it should be mentioned that the FDA had the BIO-TEST Aroclor slides for 3 years and to this date no adverse comments have been received.

Without question the Aroclors as well as other PCB-like materials are directly involved in this situation. The opinion of Drs. Gordon, Richter, Calandra, Keplinger and Kinoshita, on the basis of their own studies on Aroclor and on their experience, is that Aroclors are not carcinogenic. However, the attitudes and findings of others must be placed in perspective and weighed, each according to its own merits in accord with the data generated.

The findings of Ito,[1,2] Kimbrough and others are relevant in this context. Ito conducted a study in mice and found "hyperplastic nodules and well-differentiated hepatocellular carcinomas" at a dose level of 50 ppm of Kanechlor 500. However, hepatocellular carcinomas were not induced by Kanechlor 400 and Kanechlor 300. No specific information about the purity or composition of the products tested is

available. For example, were chlorinated dibenzofurans present? It has been shown by Vos[3] that certain biological changes can be induced by Kanechlors that do not occur with Aroclors.

Ito's work involved feeding levels of 500 ppm, 250 ppm and 100 ppm of each of the three test materials for 32 weeks to groups of 6-12 male mice. The article is sketchy and it is not possible to evaluate the significance of the findings. No histological descriptions are presented. The study obviously does not meet the scientific requirements for a meaningful bioassay for carcinogenesis as defined by the National Cancer Institute. The groups are much too small and only male mice were used. Surprisingly, the Kanechlor 500 material produced hepatomas and the Kanechlor 400 and Kanechlor 300 materials did not. It is not possible from the article to ascertain that the hepatomas are in fact hepatocarcinomas. In general, this study as presented is not acceptable and cannot be used to properly evaluate the carcinogenic activity of PCB's without additional information.

With reference to the use of the mouse in carcinogenicity testing, Grasso and Compton[4] have reviewed the value of this animal in testing for effects in the liver as well as other various organ systems. They note that a number of covariables significantly influence the incidence of hepatomas in mice. These include diet, presence or absence of "germs," sex, age and strain susceptibility. They state, "It thus appears that factors unconnected with the administration of the

test compound may have a considerable influence on the incidence of hepatomas in mice, so that other evidence is required if claims of carcinogenicity based on the induction of this type of tumor are to be seriously considered."

A study conducted by Kimura[5] on Kanechen 400 utilized 20 rats aged 10 weeks in the test group and 10 rats in the control group equally divided as to sex. The dietary level for the single test group varied from a low of 38.5 ppm to a high of 616 ppm. Liver changes included hypertrophy and fatty degeneration. "Multiple adenomatous nodules" were seen in 6 test female rats and in 2 control female rats. Male rats in either the test or control groups did not develop the nodules. The authors speculated that the nodules "in the presence of other stimuli may progress" to malignant changes. Once again, this study does not meet the technical criteria for chemical carcinogenesis bioassay procedures despite the negative results. The results confirmed tne higher degree of susceptibility of females to the development of hyperplastic liver nodules. No specific conclusions, however, can be reached.

A short term study in mice (26 weeks) by Nishizumi[6] did not reveal liver changes consistent with either premalignant or malignant hepatocellular lesions.

A study by Kimbrough[7] in male and female Sherman rats fed Aroclor 1260 and 1254 at levels in the diet ranging from 0-1000 ppm for

8 months did not indicate the presence of hepatocellular carcinoma. Under light microscopy the changes seen were hypertrophy of the liver cells, inclusions in the cytoplasm, brown pigment in the Kupfer cells, lipid accumulation, and at the higher dietary levels, adenofibrosis.

Another study by Kimbrough[8] with Aroclor 1260 (Lot No. AK-3) in female Sherman rats at a dietary level of 100 ppm was conducted for 21 months. The results were strikingly different than those obtained earlier. In the latter study a high incidence of hepatocellular carcinoma was seen which is contrary to the findings of BIO-TEST. It is noteworthy that the incidence of hepatocellular carcinoma appears to be related to the new classification of liver lesions by NCI.

The results have some relevance in the resolution of the carcinogenic potential of PCB's; however, the study does not meet the criteria for a valid rat carcinogenicity bioassay. The evidence presented at this time is at best presumptive and does not take precedence over the chronic studies conducted in male and female rats at BIO-TEST. The liver slides from the latter study have been reviewed by a number of pathologists including Drs. Squires and Kimbrough, who agreed with the assessment that no hepatocellular carcinomas were present.

A number of questions can be raised about the Kimbrough study which raise serious doubt as to the value of the study as presently constituted. In and of itself, it is not the final answer and does not per se prove that PCB's are carcinogenic.

Kimbrough and Linder[9] conducted a study in BALB/cj male mice fed 300 ppm Aroclor 1254 for 11 and 6 months. The 6 months feeding group was maintained for an additional 5 month recovery period (transferred to control diet). The two significant histological findings were adenofibrosis of the liver and hepatomas. Adenofibrosis is not considered by experts in the field (Stewart and Snell[10]) to be a pre-cancerous lesion. The hepatomas were well differentiated and the authors (Kimbrough and Linder) are of the opinion that these are potentially carcinogenic; however, no direct evidence of malignancy was noted.

To further add to the confusion of the findings and relevance of the Kimbrough studies are the results obtained in still another experiment.[11] Fifty male Sherman strain rats were fed 500 ppm Aroclor 1254 for 6 months and at monthly intervals thereafter 5 rats were sacrificed and the livers examined by light and electron microscopy. Ten months after exposure 1192 ppm PCB was present in the adipose tissue and 22.65 ppm in the liver. In this study which used male Sherman rats only, no specific mention of focal hyperplasia or hyperplastic nodules is made. The principal lesion described is adenofibrosis. No evidence of hepatocellular carcinoma is presented.

Ito[12] confirmed this in a study in which male rats were fed Kanechlor 300, 400 and 500 for up to 52 weeks. These substances produced nodular hyperplasia but did not induce hepatocellular carcinomas in rats.

Norbeck and Allen[13] fed male rats 100 ppm of Aroclor 1248, 1254, or 1262 for up to 52 weeks and did not find evidence of hepatocellular carcinoma. However, hepatocellular hypertrophy associated with proliferation of the endoplasmic reticulum was seen. Mixed function oxidase microsomal enzymes were increased.

Additionally Makiura[14] fed rats PCB's alone and in conjunction with acetylaminofluorene, diethylnitrosamine and 3'methyl-4-dimethylaminozobenzene and found that "PCB's inhibited development of nodular hyperplasia, oval cell infiltration, and bile duct proliferation" (adenofibrosis).

Of special interest is the information that focal nodular hyperplasia is seen in the human being.[15] It is a rare benign tumor that has been studied and followed clinically in man without evidence of subsequent malignant transformation.

The issue of classification of the liver tumors and the presumption that focal hyperplasia and nodular hyperplasia are pre-malignant liver lesions and that these invariably lead to hepatocellular carcinoma needs to be discussed. A number of contrary opinions to this philosophy are available so thet this consideration need not be decisive. However, it is important to note that the legal branch of EPA has clearly adopted these definitions.

When the question at issue is reviewed in the light of the regulatory agencies that may be involved, several points must be considered.

The EPA, based on the dieldrin and aldrin registration cancellations and the impending litigation on heptachlor and chlordane, are committed to the NCI philosophy of liver tumorigenesis and also that chemical agents which produce benign tumors are considered to be carcinogenic for the purposes of regulatory procedures.

In addition,[16] the following 9 principles are being followed at the present time by the EPA to evaluate the cancer hazard of environmental chemicals:

1. A carcinogen is any agent which increases tumor induction in man or animals.

2. Well-established criteria exist for distinguishing between benign and malignant tumors; however, even the induction of benign tumors is sufficient to characterize a chemical as a carcinogen.

3. The majority of human cancers are caused by avoidable exposure to carcinogens.

4. While chemicals can be carcinogenic agents, only a small percentage actually are.

5. Carcinogenesis is characterized by its irreversibility and long latency period following the initial exposure to the carcinogenic agent.

6. There is great variation in individual susceptibility to carcinogens.

7. The concept of a "threshold" exposure level for a carcinogenic agent has no practical significance because there is no valid method for establishing such a level.

8. A carcinogenic agent may be identified through analysis of tumor induction results with laboratory animals exposed to the agent, or on a post hoc basis by properly conducted epidemiological studies.

9. Any substance which produces tumors in animals must be considered a carcinogenic hazard to man if the results were achieved according to the established parameters of a valid carcinogenesis test.

In contrast to this, the FDA in a letter[17] written by the Associate Commissioner of Science to Senator Hart, indicated, "Although the Agency (EPA) stated that 'the above principles represent the most advanced research findings and policy of both national and international cancer experts and agencies,' it should be emphatically emphasized that there is by no means universal acceptance of many of the above principles as well as classification of tumors."

A review of the status of PCB's by L. L. Ramsey,[18] Associate Director of Regulatory Programs of the FDA, includes a number of important observations which have a bearing on the range of strategy and the possibilities that are available to resolve the issue of PCB.

1. The overall average of PCB's in all packaged food was 0.1 ppm.

2. This survey probably reflects samples of at least one year old and the industry has furnished us with data on more recent samples indicating that the corrective action they have taken is already effective: these PCB residue data appear to be significantly lower both in food and in its paper packaging.

3. In light of all available data including animal feeding studies, the human data from the Japanese Yusho incident and a history of use for about 40 years without deleterious effects in many being reported, the FDA has concluded that there is no immediate hazard

to the public health from the low level of environmental contamination leading to residues in food, but that it is prudent to reduce the long term exposure of man. Steps have been taken which will reduce the long term exposure of man and all evidence to date points to a successful outcome.

The most recent market basket survey by the FDA did not show PCB's to be present in any of the foods analyzed.

Another very important aspect of the regulatory question can be inferred from the recommendations[19] proposed by the EPA for dieldrin and aldrin which they have concluded is a carcinogen according to their criteria. The EPA has recommended the continued use of these materials for application directly to soil in materials buried in soil, e.g., termite control in foundations and seed treatments when properly applied.

On the basis of this attitude it is apparent that PCB's may continue to be used in controlled situations including supervised disposal where the benefit to risk is obvious despite the outcome of the questions raised about the liver changes. The recent additional evidence concerning biodegradability lends further support to this approach. For the present it is recommended that the FDA and EPA (if necessary) be provided with the final Aroclor reports on the chronic oral toxicity studies including the last addendum of the pathologists without additional comment.

J. C. Calandra, Ph.D., M.D.

June 27, 1975

REFERENCES

1 N. Ito. Gann 63:805 (1972).

2 N. Ito. J. Nat. Canc. Inst. 51:1637 (1973).

3 J. Vos. Environ. Health Persp. 1:105 (1972).

4 P. Grasso, R. Crampton. Food Cosmetic Toxicology 10:418 (1974).

5 N. Kimura. Gann 64:105 (1973).

6 M. Nishizumi. Arch. Environ. Health 21:620 (1970).

7 R. Kimbrough. Ibid 25:354 (1972).

8 Private communication.

9 R. Kimbrough, R. Linder. J. Nat. Canc. Inst. 53:547 (1974).

10 H. Stewart, K. Snell. Acta Unio. Int. Contra. Cancrum 13:770 (1957).

11 R. Kimbrough. Arch. Environ. Health 27:390 (1973).

12 N. Ito. Gann 65:545 (1974).

13 D. Norbeck and J. Allen. Abstract. Am. Assoc. Path. & Bact. March 4, 1975.

14 S. Makiura. J. Nat. Canc. Inst. 53:1253 (1974).

15 G. Mangold. Dtsch. Med. Wschr. 100:241 (1975).

16 EPA Dieldrin/Aldrin Brief, Sept. 16, 1974.

17 Private communication, L. B. Tepper, Nov. 28, 1975.

18 L. Ramsey. FDA Officials of U. S. Quart. Bull. 37:157 (1973).

19 Fed. Reg. 39(203):Fri., Oct. 18, 1974, p. 37251.