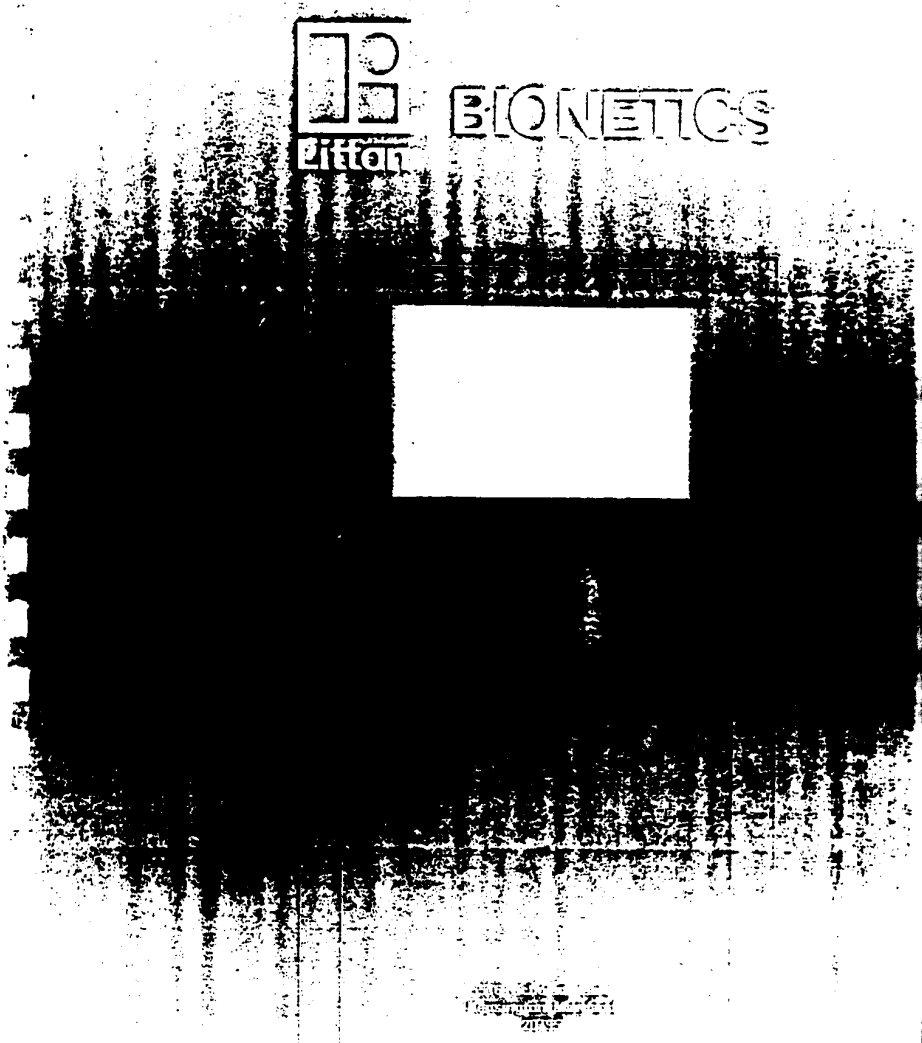

MONS 016807

LBI PROJECT 20771

FINAL REPORT

APPENDIX VOLUME III

APPENDIX G

EFFECTS OF PCB ON THE REPRODUCTIVE PERFORMANCE OF THE RHESUS MONKEY (Macaca mulatta)

APRIL 4, 1977 - DECEMBER 11, 1978

SUBMITTED TO

MONSANTO COMPANY
800 NORTH LINDBERGH BOULEVARD
ST. LOUIS, MISSOURI

SUBMITTED BY

LITTON BIONETICS, INC.
5516 NICHOLSON LANE
KENSINGTON, MARYLAND

APRIL 30, 1981

BIONETICS

APPENDIX G

APPENDIX G

Included herein are:

	Page
Table 1, Survey of Direct Morphologic Effects of Compound	G-1
Table 2, Summary of Direct Morphologic Effects of Compound	G-2
Table 3, Summary of Histologic Findings	G-12
Individual Animal Pathology Evaluations	
Group I, Adults	G-46
Group II, Adults	G-59
Group III, Adults	G-72
Group IV, Adults	G-84
Group I, Infants	G-102
Group II, Infants	G-110
Group III, Infants	G-116
Group IV, Infants	G-124

The following legend shall apply to all tables in this appendix:

LEGEND

1 = Lesion graded as "minimal."
2 = Lesion graded as "slight."
3 = Lesion graded as "moderate."
4 = Lesion graded as "marked."
5 = Lesion graded as "severe."
+ = Tissue was examined.
X = Identification of an ungraded lesion.
A = Tissue was too severely autolyzed for meaningful microscopic interpretation.
L = Tissue was lost during processing.
NH = Tissue not harvested.
N = Tissue not examined microscopically.
P = One of paired organs missing.
NP = Not present in plane of section.
U = Smear preparation unsatisfactory for microscopic interpretation.
T = Terminal kill.
D = Found dead.
K = Killed in a moribund state.
S = Stillborn.
FW = Fetal wastage (abortion before 151 days gestation).

LEIGH GENETICS, INC.
PROJECT NO. 20771

TABLE I

SURVEY OF DIRECT MORPHOLOGIC EFFECTS OF COMPOUND

GROUP 4 - HIGH DOSE					GROUP 3 - MEDIUM DOSE					GROUP 2 - LOW DOSE					GROUP 1 - CONTROL				
SEX	AGE	ANIMAL NO.	SCORE OF PATHOLOGIC ALTERATIONS SINGLE	SCORE OF PATHOLOGIC ALTERATIONS SINGLE/AVERAGE	SEX	AGE	ANIMAL NO.	SCORE OF PATHOLOGIC ALTERATIONS SINGLE	SCORE OF PATHOLOGIC ALTERATIONS SINGLE/AVERAGE	SEX	AGE	ANIMAL NO.	SCORE OF PATHOLOGIC ALTERATIONS SINGLE	SCORE OF PATHOLOGIC ALTERATIONS SINGLE/AVERAGE	SEX	AGE	ANIMAL NO.	SCORE OF PATHOLOGIC ALTERATIONS SINGLE	SCORE OF PATHOLOGIC ALTERATIONS SINGLE/AVERAGE
M	A	425J I	4		M	A	201 I	0		M	A	119N I	0		M	A	227G I	0	
M	A	427J I	0		M	A	461 I	0		M	A	428J I	0		M	A	418J I	0	
M	A	600E I	9		M	A	599I I	3		M	A	432J I	0		M	A	426G I	0	
M	A	706E K	16		M	A	599I I	0		M	A	516G I	0		M	A	739F I	0	
				7.25					0.75					0					0
F	A	226F I	10		F	A	273I I	0		F	A	241I I	0		F	A	200F I	0	
F	A	269I I	5		F	A	281G I	0		F	A	309I I	0		F	A	274F I	0	
F	A	287I I	7		F	A	307I I	2		F	A	483F I	0		F	A	569M I	0	
F	A	312I I	6		F	A	540M I	0		F	A	605F I	0		F	A	578M I	0	
F	A	152F D	8		F	A	757I I	0		F	A	624I I	0		F	A	604I I	0	
F	A	338I K	21		F	A	762E I	2		F	A	646E I	0		F	A	618I I	0	
F	A	486M K	10		F	A	763E I	0		F	A	701E I	0		F	A	764E I	0	
F	A	770I D	6		F	A	841M D	3		F	A	839M I	0		F	A	87F D	0	
				9.13					0.88					0					0
F	I	88542 D	20		M	I	88511 F	0		F	I	88527 I	0		F	I	88443 FM	0	
					F	I	88546 D	11		F	I	88562 I	0		M	I	88518 I	0	
					M	I	88559 I	2		M	I	88604 I	0		F	I	88532 I	0	
					F	I	88560 F	4		F	I	88754 I	0		F	I	88533 I	0	
					F	I	88592 F	0		M	I	88796 S	0		M	I	88557 I	0	
					M	I	88603 I	5		F	I	88815 I	2		M	I	88574 I	0	
					M	I	88960 I	0							F	I	88621 I	0	
				20.0*					1.14					0.33					0

FM = fetal wastage (abortion before 151 days gestation).
S = Stillborn.
I = Terminal kill.
D = Found dead.

K = Killed in a moribund state.
A = Adult.
I = Infant.

* This score has apparent validity because the single infant on which it is based represents the only conceptus in Group 4 adult females to develop to infancy.

MONS 016812

LITTON BIONETICS, INC.
PROJECT NO. 2077I

TABLE 2A

SUMMARY OF DIRECT MORPHOLOGIC EFFECTS OF COMPOUND - TERMINAL KILL

MALES - ADULT

GROUP NUMBER	1				2				3				4		
SEX	MALES				MALES				MALES				MALES		
ANIMAL NUMBER	227G	418J	426G	739F	139I	428J	432J	516G	20I	46I	595I	599I	425J	427J	600I
EYELIDS	+	+	+	+	+	+	+	+	+	+	+	+	+	+	+
Meibomian glands															
Atrophy, sebaceous elements															X
Squamous impaction, ducts															X
Mucinous metaplasia, ducts															X
LIPS	+	+	+	+	+	+	+	+	+	+	+	+	+	+	+
Subtotal atrophy, sebaceous glands															X
THYROID	+	+	+	+	+	+	+	+	+	+	+	+	+	+	+
Squamous metaplasia, focal													1		
HIP SKIN	+	+	+	+	+	+	+	+	+	+	+	+	+	+	+
Subtotal atrophy, sebaceous glands											X				X
Atrophy, sebaceous glands													X		
THIGH SKIN	+	+	+	+	+	+	+	+	+	+	+	+	+	+	+
Subtotal atrophy, sebaceous glands											X		X		X
MANDIBLE	+	+	+	+	+	+	+	+	+	+	+	+	+	+	+
Subgingival epithelial microcysts											X		X		
ABDOMINAL SKIN															+
Subtotal atrophy, sebaceous glands															X
TAILHEAD SKIN															+
Atrophy, sebaceous glands															X
Follicular keratosis															X
SCORE OF PATHOLOGIC ALTERATIONS	0	0	0	0	0	0	0	0	0	0	3	0	4	0	9

MONS 016813

LITTON BIONETICS, INC.
PROJECT NO. 20771

TABLE 20

SUMMARY OF DIRECT MORPHOLOGIC EFFECTS OF COMPOUND - TERMINAL KILL

FEMALES - ADULT

GROUP NUMBER	1							4			
SEX	FEMALES							FEMALES			
ANIMAL NUMBER	200F	274F	569H	578H	604I	618I	764E	226F	269I	287I	312I
EYELIDS	•	•	•	•	•	•	•	•	•	•	•
Meibomian glands											
Subtotal atrophy, sebaceous elements										X	
Atrophy, sebaceous elements								X	X		X
Mucinous metaplasia, ducts								X	X	X	X
Squamous impaction, ducts								X	X	X	X
LIPS	•	•	•	•	•	•	•	•	•	•	•
Subtotal atrophy, sebaceous glands									X	X	X
Atrophy, sebaceous glands								X			
TONGUE	•	•	•	•	•	•	•	•	•	•	•
Squamous metaplasia, glandular duct										X	
LEFT NIPPLE	•	•	•	•	•	•	•	•	•	•	•
Squamous cyst, skin								X			
Squames in deep mammary duct								X			
HIP SKIN	•	•	•	•	•	•	•	•	•	•	•
Subtotal atrophy, sebaceous glands											X
Atrophy, sebaceous glands								X		X	
THIGH SKIN	•	•	•	•	•	•	•	•	•	•	•
Subtotal atrophy, sebaceous glands									X		X
Atrophy, sebaceous glands								X		X	
LABIUM	•	•	•	•	•	•	•	•	•	•	•
BONE MARROW SMEAR	•	•	•	•	•	•	•	•	•	•	•
Decreased granulocyte maturation								X			
SKIN								•			
Follicular keratosis								X			
SUMMARY OF PARALOGIC ALTERATIONS	0	0	0	0	0	0	0	10	5	7	6

MONS 016814

LITTON BIONETICS, INC.
PROJECT NO. 20771

TABLE 28 (Continued)

GROUP NUMBER	2								3						
SEX	FEMALES								FEMALES						
ANIMAL NUMBER	2841	3091	4031	6091	6241	6461	7015	8391	2731	2815	3071	5401	7571	7625	7635
EYELIDS	+	+	+	+	+	+	+	+	+	+	+	+	+	+	+
LIPS	+	+	+	+	+	+	+	+	+	+	+	+	+	+	+
TONGUE	+	+	+	+	+	+	+	+	+	+	+	+	+	+	+
LEFT NIPPLE	+	+	+	+	+	+	+	+	+	+	+	+	+	+	+
HIP SKIN	+	+	+	+	+	+	+	+	+	+	+	+	+	+	+
Subtotal atrophy, sebaceous glands											X			X	
THIGH SKIN	+	+	+	+	+	+	+	+	+	+	+	+	+	+	+
Subtotal atrophy, sebaceous glands											X				
LABIUM	+	+	+	+	+	+	+	+	+	+	+	+	+	+	+
Squamous cysts														X	
BONE MARROW SMEAR	+	+	U	+	+	+	+	+	+	+	+	+	+	+	+
SKIN	+	+	+	+	+	+	+	+	+	+	+	+	+	+	+
SCORE OF PATHOLOGIC ALTERATIONS	0	0	0	0	0	0	0	0	0	0	2	0	0	2	0

MONS 016815

LITTON BIONETICS, INC.
PROJECT NO. 20771

TABLE 2C

SUMMARY OF DIRECT MORPHOLOGIC EFFECTS OF COMPOUND - INTERCURRENT DEATH

MALES AND FEMALES - ADULT

GROUP NUMBER	1	3	4	4			
SEX	FEMALE	FEMALE	MALE	FEMALE			
ANIMAL NUMBER	87F	841H	706E	152F	338I	486H	770I
TYPE OF DEATH	D	D	X	D	X	X	D
EYELIDS	+	+	+	+	+	+	+
Meibomian glands							
Subtotal atrophy, sebaceous elements		X				X	
Atrophy, sebaceous elements			X	X	X		X
Squamous metaplasia, sebaceous elements		X				1	
Squamous imparition, ducts		X	X	X	X	X	X
Mucinous metaplasia, ducts			X	X	X	X	
LIPS	+	+	+	+	+	+	+
Subtotal atrophy, sebaceous glands			X			X	
Atrophy, sebaceous glands				X	X		X
Squamous metaplasia, sebaceous glands			X				
Squamous metaplasia, glandular duct						X	
TONGUE	+	+	+	+	+	+	+
Squamous metaplasia, glandular ducts				X			
HEART	+	+	+	+	+	+	+
Squamous metaplasia, epicardium			X				
LIVER	+	+	+	+	+	+	+
Intrahepatic bile ducts (second order)							
Epithelial hyperplasia					4		
Mucoid content					X		
Ectasia					3		
EXTRAHEPATIC BILE DUCT	L	L	L	L	+	+	+
Mucosal hyperplasia					4		
Mucoid content					X		
GALLBLADDER	+	+	+	A	+	+	+
Mucosal hyperplasia					4		
Mucoid content					X		
Collapsed lumen					X		

MONS 016816

LITTON BIOMETICS, INC.
PROJECT NO. 20771

TABLE 2C (Continued)

GROUP NUMBER	1	3	4	4			
SEX	FEMALE	FEMALE	MALE	FEMALE			
ANIMAL NUMBER	87F	81H	70GE	152F	33M	48GH	77D
TYPE OF DEATH	D	H	K	D	K	K	D
PANCREAS	+	+	+	+	+	+	+
Main duct							
Epithelial hyperplasia					4		
Mucoid content					X		
LEFT NIPPLE	L	I	L	+	L	I	L
Squames in deep mammary duct				X			
HIP SKIN	+	+	+	L	+	+	+
Subtotal atrophy, sebaceous glands						X	
Atrophy, sebaceous glands			X		X		X
Follicular keratosis			X				
THIGH SKIN	+	+	+	L	+	+	+
Subtotal atrophy, sebaceous glands						X	
Atrophy, sebaceous glands			X		X		X
Follicular keratosis			X				
Squamous cyst			X				
FEMORAL MARROW*	+	+	+	+	+	+	+
Decreased granulocyte maturation				X	X		
STERNUM*	+	+	+	+	+	+	+
Decreased cellularity			X	X	X	X	
Decreased granulocyte maturation				X	X	X	X
BONE MARROW SHEAR*	L	+	+	+	+	L	L
Decreased granulocyte maturation			X	X	X		
MANDIBLE	+	+	+	+	+	+	+
Subgingival epithelial cysts					X		

* Bone marrow changes seen in 152F may not have been valid effects of the compound since the monkey died of systemic herpesvirus infection.

MONS 016817

LITTON BIONETICS, INC.
PROJECT NO. 20771

TABLE 2C (Continued)

GROUP NUMBER	1	1	4	4			
SEX	FEMALE	FEMALE	MALE	FEMALE			
ANIMAL NUMBER	87F	84H	70GE	152F	338I	406H	770I
TYPE OF DEATH	B	I	K	B	K	K	B
SKIN FROM MACULAR ERUPTION			+				
Atrophy, sebaceous glands			X				
Follicular keratosis			X				
Squamous cyst			X				
SKIN - THORACIC				+			
Atrophy, sebaceous glands				X			
Squamous cysts				X			
SCORE OF PATHOLOGIC ALTERATIONS	0	3	16	8	21	10	6

MONS 016818

LITTON BIONETICS, INC.
PROJECT NO. 2077I

TABLE 20

SUMMARY OF DIRECT MORPHOLOGIC EFFECTS OF COMPOUND - TERMINAL KILL AND INTERLUMBAR DEATH

MALES AND FEMALES - INFANT

GROUP NUMBER	1	1	1	1	1	1	1	4
SEX	FEMALE	MALE	FEMALE	FEMALE	MALE	MALE	FEMALE	FEMALE
ANIMAL NUMBER	88483	88518	88512	88533	88557	88574	88621	88542
TYPE OF DEATH	TW	T	T	T	T	T	T	D
EYELIDS	NH	+	+	+	+	+	+	+
Meibomian glands								
Atrophy, sebaceous elements								X
Squamous impaction, ducts								X
LIPS	NH	+	+	+	+	+	+	+
Subtotal atrophy, sebaceous glands								X
THYMUS	+	+	+	+	+	+	+	+
"Accidental" involution								X
Cystic Hassall's corpuscles								X
LIVER	+	+	+	+	+	+	+	+
Intrahepatic bile ducts (second order)								
Epithelial hyperplasia								3
Mucoid content								X
GALLBLADDER	N	+	+	+	+	+	+	+
Mucosal hyperplasia								3
PANCREAS	+	+	+	+	+	+	+	+
Ductal hyperplasia								5
Acinar atrophy								5
KIDNEYS	+	+	+	+	+	+	+	+
Retarded cortical maturation								4
STOMACH	N	+	+	+	+	+	+	+
Cystic mucinous metaplasia, mucosal glands								3
Submucosal glandular cysts								7

MONS 016819

LITTON BIONETICS, INC.
PROJECT NO. 20771

TABLE 2D (Continued)

GROUP NUMBER SEX ANIMAL NUMBER TYPE OF DEATH	1 FEMALE 00483 TU	1 MALE 00518 T	1 FEMALE 00532 T	1 FEMALE 00533 T	1 MALE 00557 T	1 MALE 00574 T	1 FEMALE 00621 T	4 FEMALE 00542 M
SMALL INTESTINE Crypt metaplasia, Brunner's glands	M	+	+	+	+	+	+	+ 4
HIP SKIN Atrophy, sebaceous glands Follicular keratosis	MM	+	+	+	+	+	+	+ X X
INGUINAL SKIN Subtotal atrophy, sebaceous glands Follicular keratosis	MM	+	+	+	+	+	+	+ X X
FEMORAL MARROW Decreased cellularity	MM	+	+	+	+	+	+	+ X
STERNUM	MM	+	+	+	+	+	+	+
BONE MARROW SMEAR	MM	L	+	+	+	+	+	M
MANDIBLE Subgingival squamous cysts	MM	+	+	+	+	+	+	+ X
SCORE OF PATHOLOGIC ALTERATIONS	0	0	0	0	0	0	0	20

MDNS 016820

LEFFOX BIOMETICS, INC.
PROJECT NO. 20771

TABLE 20 (Continued)

GROUP NUMBER	2	2	2	2	2	2	3	3	3	3	3	3	3
SEX	FEMALE	FEMALE	MALE	FEMALE	MALE	FEMALE	MALE	FEMALE	MALE	FEMALE	FEMALE	MALE	MALE
ANIMAL NUMBER	00527	00562	00604	00754	00796	00815	00511	00546	00559	00560	00592	00603	00607
TYPE OF DEATH	T	T	T	T	T	T	T	B	T	T	T	T	T
EYELIDS													
Meibomian glands	+	+	+	+	+	+	+	+	+	+	+	+	+
Localized atrophy, sebaceous elements													
Atrophy, sebaceous elements									X				
Localized squamous impaction, ducts								X		X		X	
Squamous impaction, ducts									X				
Mucinous metaplasia, ducts								X		X		X	
										X			
LIPS													
Subtotal atrophy, sebaceous glands	+	+	+	+	+	+	+	+	+	+	+	+	+
								X					
THYMUS													
"Accidental" involution	+	+	+	+	+	+	+	+	+	+	+	+	+
Cystic Hassall's corpuscles								X					
								X				X	
LIVER	+	+	+	+	+	+	+	+	+	+	+	+	+
GALLBLADDER	+	+	+	+	+	+	+	A	+	+	+	+	+
PANCREAS													
Ductal hyperplasia	+	+	+	+	L	+	+	+	+	+	+	+	+
Acinar atrophy												J	
												J	
KIDNEYS	+	+	+	+	+	+	+	+	+	+	+	+	+
STOMACH	+	+	+	+	+	+	+	+	+	+	+	+	+
SMALL INTESTINE	+	+	+	+	+	+	+	+	+	+	+	+	+
HIP SKIN													
Subtotal atrophy, sebaceous glands	+	+	+	+	I	+	+	+	+	+	+	+	+
								X					
THIGH SKIN													
Subtotal atrophy, sebaceous glands	+	+	+	+	+	+	+	+	+	+	+	+	+
								X					

MONS 016821

LITTON BIONETICS, INC.
PROJECT NO. 20771

TABLE 20 (Continued)

GROUP NUMBER	2	2	2	2	2	2	3	3	3	3	3	3	3
SEX	FEMALE	FEMALE	MALE	FEMALE	MALE	FEMALE	MALE	FEMALE	MALE	FEMALE	FEMALE	MALE	MALE
ANIMAL NUMBER	88527	88562	88604	88754	88796	88815	88511	88546	88559	88560	88592	88603	88860
TYPE OF DEATH	T	T	T	T	S	T	T	D	T	T	T	T	T
FEMORAL MARROW	+	+	+	+	+	+	+	+	+	+	+	+	+
Decreased granulocyte maturation								X					
STERNUM	+	+	+	+	+	+	+	+	+	+	+	+	+
Decreased granulocyte maturation								X					
Decreased cellularity								X					
BONE MARROW SMEAR	+	+	+	+	+	+	L	+	+	+	+	+	+
Decreased granulocyte maturation								X					
MANDIBLE	+	+	+	+	+	+	+	+	+	+	+	+	+
Subgingival squamous cysts						X				X			
Intraosseous squamous cyst						X							
SCORE OF PATHOLOGIC ALTERATIONS	0	0	0	0	0	2	0	11	2	4	0	5	0

MONS 016822

LITTON BIONETICS, INC.
PROJECT NO. 20771

TABLE 3A

SUMMARY OF HISTOLOGIC FINDINGS - TERMINAL KILL

MALES - ADULT

GROUP NUMBER	1				2				3				4		
SEX	MALES				MALES				MALES				MALES		
ANIMAL NUMBER	227G	418J	426G	739F	119H	429J	432J	516G	201	461	595I	599I	425J	427J	600I
CEREBRUM	+	+	+	+	+	+	+	+	+	+	+	+	+	+	+
CEREBELLUM	+	+	+	+	+	+	+	+	+	+	+	+	+	+	+
MID BRAIN	+	+	+	+	+	+	+	+	+	+	+	+	+	+	+
SPINAL CORD	+	+	+	+	+	+	+	+	+	+	+	+	+	+	+
Nerve fiber degeneration								1		1		1	1	1	
PITUITARY	+	+	+	+	+	+	+	+	+	+	+	+	+	+	+
Microcysts															
Degenerative focus								X		X					
EYELIDS	+	+	+	+	+	+	+	+	+	+	+	+	+	+	+
Meibomian glands															
Cyst/s		1													
Dilated duct/s		X													
Paraglandular cellular infiltration								X	X		X		X	X	
Atrophy, sebaceous elements									2			2	2		3
Squamous impaction, ducts															X
Mucinous metaplasia, ducts															X
															X
LIPS	+	+	+	+	+	+	+	+	+	+	+	+	+	+	+
Focal lymphocytic infiltration, submucosal glands	2														
Foreign body microgranuloma				X			2		2		2		2		
Focal epidermitis								1							
Microulcer															
Dilated ducts - submucosal glands												X			
Focal mucosal erosion													X		
Subtotal atrophy of sebaceous glands															X
															X
TONGUE	+	+	+	+	+	+	+	+	+	+	+	+	+	+	+

MDNS 016823

LITTON BIONETICS, INC.
PROJECT NO. 20771

TABLE 3A (Continued)

GROUP NUMBER SEX ANIMAL NUMBER	1 MALES 227G	418J	426G	739F	2 MALES 1190	421J	432J	516G	3 MALES 201	461	595I	599I	4 MALES 425J	427J	600I
AXILLARY LYMPH NODE	+	+	+	+	+	+	+	+	+	+	+	+	+	+	+
Foreign body reaction			2												
Hemorrhage	2											2			
PAROTID SALIVARY GLAND	+	+	+	+	+	+	+	+	+	+	+	+	+	+	+
Focal inflammation			1												
Localized lobular atrophy												2			
SUBMAXILLARY SALIVARY GLAND	+	+	+	+	+	+	+	+	+	+	+	+	+	+	+
Focal inflammation			1												
ESOPHAGUS	+	+	+	+	+	+	+	+	+	+	+	+	+	+	+
INTESTINE	+	+	+	+	+	+	+	+	+	+	+	+	+	+	+
Focal colloid degeneration			2												
Focal lymphocytic infiltration					2								2		
Microfollicular foci											3				
Squamous metaplasia, focal													1		
PARATHYROIDS	+	MP	+	+	+	+	+	+	+	+	+	MP	+	+	+
RIGHT LUNG	+	+	+	+	+	+	+	+	+	+	+	+	+	+	+
Pneumonyssus lesion/s	X		X		X		X	X	X		X	X	X	X	X
Pneumonyssus parasite/s			X				X		X						X
Congestion				X								X	X		
Edema				X								X	X		
LEFT LUNG	+	+	+	+	+	+	+	+	+	+	+	+	+	+	+
Pneumonyssus lesion/s	X		X	X			X	X	X		X			X	X
Pneumonyssus parasite/s	X		X	X			X								
Congestion				X								X	X		
Edema				X								X	X		
Localized hemosiderin deposition					2										
THYMUS	+	+	+	+	+	+	+	+	+	+	+	+	+	+	+

LITTON BIONETICS, INC.
PROJECT NO. 20771

TABLE 3A (Continued)

GROUP NUMBER	1				2				3				4		
SEX	MALES				MALES				MALES				MALES		
ANIMAL NUMBER	227G	418J	426G	739F	119H	429J	432J	516G	201	461	595I	599I	425J	427J	600I
HEART															
Focal necrosis (myocardial)								1							
LIVER															
Reactive foci	2		2	1											
EXTRAHEPATIC BILE DUCT															
GALLBLADDER															
SPLEEN															
PANCREAS															
KIDNEYS															
Focal calcification					1										
Focus of hemorrhage and plasma cells							X								
Pyelonephritic scars											2	2			
ADRENAL GLANDS															
Focal calcification			1			3	1	3	2	3	2		2	2	
Focal cortical lipidosis							1								
URINARY BLADDER															
STOMACH															
Chronic gastritis										3				2	
SMALL INTESTINE															
Hemorrhage, mucosal											2				
LARGE INTESTINE															

MONS 016825

LITTON BIONETICS, INC.
PROJECT NO. 20771

TABLE 3A (Continued)

GROUP NUMBER	1				2				3				4		
SEX	MALES				MALES				MALES				MALES		
ANIMAL NUMBER	227G	418J	426G	739F	119H	420J	432J	516G	201	461	595I	599I	425J	427J	600I
MESENTERIC LYMPH NODE	+	+	+	+	+	+	+	+	+	+	+	+	+	+	+
Hemorrhage				1											2
TESTES	+	+	+	+	+	+	+	+	+	+	+	+	+	+	+
Diminished spermatogenesis									2	2					
EPIDIDYMES	+	+	+	+	+	+	+	+	+	+	+	+	+	+	+
Focal lymphocytic infiltration, unilateral						2									
PROSTATE	+	+	+	+	+	+	+	+	+	+	+	+	+	+	+
Focal inflammation	1		1	1		2	2	2			1	2			
Acinar atrophy and dilation															3
SCIATIC NERVE	+	+	+	+	+	+	+	+	+	+	+	+	+	+	+
TIBIAL NERVE	+	+	+	+	+	+	+	+	+	+	+	+	+	+	+
Nerve fiber degeneration												1			
EPI NIPPLE	+	+	+	+	+	+	+	+	+	+	+	+	+	+	+
HIP SKIN	+	+	+	+	+	+	+	+	+	+	+	+	+	+	+
Subtotal atrophy, sebaceous glands											X				X
Atrophy, sebaceous glands													X		
Microgranuloma													X		
THIGH SKIN	+	+	+	+	+	+	+	+	+	+	+	+	+	+	+
Subtotal atrophy, sebaceous glands											X		X		X
FORESKIN	+	+	+	+	+	+	+	+	+	+	+	+	+	+	+
FEMORAL MARROW	+	+	+	+	+	+	+	+	+	+	+	+	+	+	+
Focal hemosiderin deposition					1				2						
STERNUM	+	+	+	+	+	+	+	+	+	+	+	+	+	+	+

MONS 016826

LITTON BIONETICS, INC.
PROJECT NO. 20771

TABLE 3A (Continued)

GROUP NUMBER	1				2				3				4			
SEX	MALES				MALES				MALES				MALES			
ANIMAL NUMBER	227G	418J	426G	739F	119H	428J	432J	516G	201	461	595I	599I	625J	427J	600I	
BONE MARROW SMEAR	•	•	•	•	•	•	•	•	•	•	•	•	•	•	•	
MANDIBLE	•	•	•	•	•	•	•	•	•	•	•	•	•	•	•	
Subgingival epithelial microcyst											X		X			
SKIN LESIONS										•			L			
Squamous papillomas										X						
SKELETAL MUSCLE											•					
ABDOMINAL SKIN															•	
Subtotal atrophy, sebaceous glands															X	
TAILHEAD SKIN															•	
Follicular keratosis															X	
Atrophy, sebaceous glands															X	
THORACIC SPINAL COLUMN					M											

MONS 016827

LITTON BIONETICS, INC.
PROJECT NO. 20771

TABLE 3B

SUMMARY OF HISTOLOGIC FINDINGS - TERMINAL KILL

FEMALES - ADULT

GROUP NUMBER	1							4			
SEX	FEMALES							FEMALES			
ANIMAL NUMBER	200F	274F	569M	578M	604J	618I	764E	226F	269I	287I	312I
CEREBRUM	+	+	+	+	+	+	+	+	+	+	+
CEREBELLUM	+	+	+	+	+	+	+	+	+	+	+
MID BRAIN	+	+	+	+	+	+	+	+	+	+	+
SPINAL CORD	+	+	+	+	+	+	+	+	+	+	+
Nerve fiber degeneration	2										
PITUITARY	+	+	+	+	+	+	+	+	+	+	+
Vacuolated basophils			X								
EYELIDS	+	+	+	+	+	+	+	+	+	+	+
Conjunctivitis		2									
Meibomian glands											
Cyst/s											
Dilated duct/s							X				
Paraglandular cellular infiltration									X		X
Atrophy, sebaceous elements					I			J	J	2	
Squamous impaction, ducts								X	X		X
Mucinous metaplasia, ducts								X	X	X	X
Subtotal atrophy, sebaceous elements								X	X	X	X
Paraductal cellular infiltration										X	
											J
LIPS	+	+	+	+	+	+	+	+	+	+	+
Focal lymphocytic infiltration, submucosal glands											
Focal mucosal erosion		X									1
Subtotal atrophy, sebaceous glands					X						
Focal submucosal lymphocytic infiltration									X	X	X
Atrophy, sebaceous glands					2			X			
TONGUE	+	+	+	+	+	+	+	+	+	+	+
Squamous metaplasia glandular duct										1	

MDNS 018828

LITTON BIONETICS, INC.
PROJECT NO. 20771

TABLE 3B (Continued)

GROUP NUMBER	1							4			
SEX	FEMALES							FEMALES			
ANIMAL NUMBER	200F	274F	569M	578F	604I	610I	764E	226F	269I	287I	312I
AXILLARY LYMPH NODE	+	+	+	+	+	+	+	+	+	+	+
Hemorrhage	1	2		2	2						
Amyloid foci	2										
PAROTID SALIVARY GLAND	+	+	+	+	+	+	+	+	+	+	+
Localized lobular atrophy									1		
SUBMAXILLARY SALIVARY GLAND	+	+	+	+	+	+	+	+	+	+	+
Lymphocytic foci	3										
Syncytial cells in ducts										X	
ESOPHAGUS	+	+	+	+	+	+	+	+	+	+	+
THYROIDS	+	+	+	+	+	+	+	+	+	+	+
Focal lymphocytic infiltration	3										
PARATHYROIDS	MP	+	+	+	+	+	+	+	+	+	+
RIGHT LUNG	+	+	+	+	+	+	+	+	+	+	+
Pneumonyssus lesion/s		X	X	X		X	X	X	X	X	X
Pneumonyssus parasite/s			X						X		
LEFT LUNG	+	+	+	+	+	+	+	+	+	+	+
Pneumonyssus lesion/s	X	X	X	X		X		X	X	X	X
Pneumonyssus parasite/s		X		X					X	X	X
THYMUS	+	+	+	+	+	+	+	+	+	+	+
HEART	+	+	+	+	+	+	+	+	+	+	+
Focal cellular infiltration						1					
LIVER	+	+	+	+	+	+	+	+	+	+	+
Bacterial foci					2	2					
Focal necrosis		2									
Localized superficial atrophy and fibrosis				2							
Congenital cyst/s								1			
Focal hemosiderin deposition								2			

MONS 016829

LITTON BIONETICS, INC.
PROJECT NO. 20771

TABLE 3B (Continued)

GROUP NUMBER	1							4			
SEX	FEMALES							FEMALES			
ANIMAL NUMBER	200F	274F	560M	578M	604F	618F	764F	226F	269F	287F	312F
EXTRAHEPATIC BILE DUCT	+	+	+	+	+	+	+	+	+	+	+
GALLBLADDER	+	+	+	+	+	+	+	+	+	+	+
Microconcretion								X			
SPLEEN	+	+	+	+	+	+	+	+	+	+	+
PANCREAS	+	+	+	+	+	+	+	+	+	+	+
Amyloid in islets	4										
KIDNEYS	+	+	+	+	+	+	+	+	+	+	+
Cortical microcysts								2			
Focal glomerulosclerosis								2			
ADRENAL GLANDS	+	+	+	+	+	+	+	+	+	+	+
Focal calcification		3	2			2			2		
Focal cortical lipidosis	2										
URINARY BLADDER	+	+	+	+	+	+	+	+	+	+	+
STOMACH	+	+	+	+	+	+	+	+	+	+	+
Subacute gastritis				2							
SMALL INTESTINE	+	+	+	+	+	+	+	+	+	+	+
LARGE INTESTINE	+	+	+	+	+	+	+	+	+	+	+
MESENTERIC LYMPH NODE	+	+	+	+	+	+	+	+	+	+	+
OVARIES	+	+	+	+	+	+	+	+	+	+	+
Endometriosis		2									
Cystic rete ovarii cyst							X			X	
								X			

MONS 016830

LITTON BIOMETICS, INC.
PROJECT NO. 20771

TABLE 3B (Continued)

GROUP NUMBER	1 FEMALES							4 FEMALES			
SEX											
ANIMAL NUMBER	200F	274F	569M	571M	604I	618I	764E	226F	269I	287I	312I
UTERUS	+	+	+	+	+	+	+	+	+	+	+
Endometriosis	2										
Adenomyosis			2								
Peritoneal adhesion				X							
CERVIX	+	+	+	+	+	+	+	+	+	+	+
Endometriosis	2										
VAGINA	+	+	+	+	+	+	+	+	+	+	+
SCIATIC NERVE	+	+	+	+	+	+	+	+	+	+	+
TIBIAL NERVE	+	+	+	+	+	+	+	+	+	+	+
LEFT NIPPLE	+	+	+	+	+	+	+	+	+	+	+
Squamous cyst, skin								X			
Squamous in deep mammary duct								X			
HIP SKIN	+	+	+	+	+	+	+	+	+	+	+
Subtotal atrophy, sebaceous glands											X
Atrophy, sebaceous glands								X		X	
THIGH SKIN	+	+	+	+	+	+	+	+	+	+	+
Subtotal atrophy, sebaceous glands									X		X
Atrophy, sebaceous glands								X		X	
LABIUM	+	+	+	+	+	+	+	+	+	+	+
Submucosal foreign body microgranulomas			X								
FEMORAL MARROW	+	+	+	+	+	+	+	+	+	+	+
Focal hemosiderin deposition								3			
SILIGRIM	+	+	+	+	+	+	+	+	+	+	+

MONS 016831

LITTON BIONETICS, INC.
PROJECT NO. 20771

TABLE 3B (Continued)

GROUP NUMBER	1							4			
SEX	FEMALES							FEMALES			
ANIMAL NUMBER	200F	274F	569M	5/10M	604I	618I	764E	276F	269I	287I	312I
BONE MARROW SMEAR											
Decreased granulocyte maturation	+	+	+	+	+	+	+	+ X	+	+	+
MANDIBLE											
Marginal gingivitis	+ 2	+	+ 1	+ 1	+	+	+ 2	+ 1	+	+ 1	+
SKIN											
Follicular keratosis								+ X			

LITTON BIONETICS, INC.
PROJECT NO. 20771

TABLE 3B (Continued)

GROUP NUMBER	2								3						
SEX	FEMALES								FEMALES						
ANIMAL NUMBER	2041	3091	483F	6051	6241	646E	701E	8390	2731	281G	3071	540M	7571	762E	763E
CEREBRUM															
Parasitic cyst							X								
CEREBELLUM															
MID BRAIN															
SPINAL CORD															
Nerve fiber degeneration		1				1				1	1	2			
Focal lymphocytic infiltration, meninges	2														
PITUITARY															
Microcyst										X					
EYELIDS															
Meibomian glands															
Cyst/s								X					X		
Dilated duct/s								X		X		X			
Paraglandular cellular infiltration				2		1	2		2	1			2	2	2
LIPS															
Focal lymphocytic infiltration, submucosal glands		2			2								2		
Focal mucosal erosion	X			X	X										
TONGUE															
AXILLARY LYMPH NODE															
Foreign body reaction		3		2		2							2		
Hemorrhage							2							2	
PAROTID SALIVARY GLAND															
Focal inflammation										1					

LITTON BIONETICS, INC.
PROJECT NO. 20771

TABLE 3B (Continued)

GROUP NUMBER	2								3						
SEX	FEMALES								FEMALES						
ANIMAL NUMBER	284I	309I	483F	605I	624I	646E	701E	839H	273I	281G	307I	540H	757I	762E	763E
SUBMAXILLARY SALIVARY GLAND	+	+	+	+	+	+	+	+	+	+	+	+	+	+	+
ESOPHAGUS	+	+	+	+	+	+	+	+	+	+	+	+	+	+	+
Parasitism			2												
THYROIDS	+	+	+	+	+	+	+	+	+	+	+	+	+	+	+
Focal colloid degeneration			2												
Focal lymphocytic infiltration		1													
Microfollicular foci			3										1		
PARATHYROIDS	+	+	+	+	+	+	+	+	+	+	+	+	+	+	+
RIGHT LUNG	+	+	+	+	+	+	+	+	+	+	+	+	+	+	+
Pneumonyssus lesion/s	X	X				X	X	X	X		X	X	X		
Pneumonyssus parasite/s	X	X				X	X	X	X			X			
Congestion			X										X	X	
Edema			X										X	X	
LEFT LUNG	+	+	+	+	+	+	+	+	+	+	+	+	+	+	+
Pneumonyssus lesion/s	X	X	X	X		X	X		X	X	X	X			
Pneumonyssus parasite/s	X					X			X						
Congestion			X										X	X	
Edema			X										X	X	
THYMUS	+	+	+	+	+	+	+	+	+	+	+	+	L	+	+
HEART	+	+	+	+	+	+	+	+	+	+	+	+	+	+	+
Focal cellular infiltration	1		1							1			1		

MONS 016834

LITTON BIONETICS, INC.
PROJECT NO. 20771

TABLE 3B (Continued)

GROUP NUMBER	2								3						
SEX	FEMALES								FEMALES						
ANIMAL NUMBER	284I	309I	483F	605F	624I	646E	701E	839H	273I	281G	307I	540H	757I	762E	763E
LIVER	+	+	+	+	+	+	+	+	+	+	+	+	+	+	+
Reactive foci					2			2							
Focal bile duct proliferation			1												
Telangiectatic focus				X											
Congenital cyst/s				X								X			
Focal hemosiderin deposition							2			2					3
Periportal infiltration												2			2
EXTRAHEPATIC BILE DUCT	+	+	+	+	+	+	+	+	+	+	+	+	+	+	+
Chronic cholangitis							3								
GALLBLADDER	+	+	+	+	+	+	+	+	+	+	+	+	+	+	+
Chronic cholecystitis							3								
SPLEEN	+	+	+	+	+	+	+	+	+	+	+	+	+	+	+
Parasitic cysts					X										
PANCREAS	+	+	+	+	+	+	+	+	+	+	+	+	+	+	+
KIDNEYS	+	+	+	+	+	+	+	+	+	+	+	+	+	+	+
Cortical microcysts			2												
Focal glomerulosclerosis												2	3		
ADRENAL GLANDS	+	+	+	+	+	+	+	+	+	+	+	+	+	+	+
Focal calcification					2			2			3	2	2	3	2
URINARY BLADDER	+	+	+	+	+	+	+	+	+	+	+	+	+	+	+
STOMACH	+	+	+	+	+	+	+	+	+	+	+	+	+	+	+
SMALL INTESTINE	+	+	+	+	+	+	+	+	+	+	+	+	+	+	+
LARGE INTESTINE	+	+	+	+	+	+	+	+	+	+	+	+	+	+	+

MONS 016835

LITTON BIONETICS, INC.
PROJECT NO. 2077I

TABLE 3D (Continued)

GROUP NUMBER	2								3						
SEX	FEMALES								FEMALES						
ANIMAL NUMBER	284J	309I	483F	605F	624I	646E	701E	839H	273I	281G	307J	549H	757I	762E	763E
MESENTERIC LYMPH NODE	+	+	+	+	+	+	+	+	+	+	+	+	+	+	+
Hemorrhage								2							
Parasitic larva	X														
OVARIES	+	+	+	+	+	+	+	+	+	+	+	+	+	+	P
UTERUS	+	+	+	+	+	+	+	+	+	+	+	+	+	+	+
Endometriosis								2							
Peritoneal adhesion															X
CERVIX	+	+	+	+	+	+	+	+	+	+	+	+	+	+	+
VAGINA	+	+	+	+	+	+	+	+	+	+	+	+	+	+	+
Submucosal cyst							X								
SCIATIC NERVE	+	+	+	+	+	+	+	+	+	+	+	+	+	+	+
TIBIAL NERVE	+	+	+	+	+	+	+	+	+	+	+	+	+	+	+
LEFT NIPPLE	+	+	+	+	+	+	+	+	+	+	+	+	+	+	+
Ductal hyperplasia, mammary gland				2											
HIP SKIN	+	+	+	+	+	+	+	+	+	+	+	+	+	+	+
Subtotal atrophy, sebaceous glands											X			X	
THIGH SKIN	+	+	+	+	+	+	+	+	+	+	+	+	+	+	+
Subtotal atrophy, sebaceous glands											X				
LABIUM	+	+	+	+	+	+	+	+	+	+	+	+	+	+	+
Submucosal microcyst				X											
Squamous cysts														X	

MONS 016836

LITTON BIONETICS, INC.
PROJECT NO. 20771

TABLE 3B (Continued)

GROUP NUMBER	2								3						
SEX	FEMALES								FEMALES						
ANIMAL NUMBER	2841	3091	483E	605F	6241	646E	701E	839F	2731	281G	3021	540M	757I	762E	763E
FEMORAL MARROW	+	+	+	+	+	+	+	+	+	+	+	+	+	+	+
Focal hemosiderin deposition						3	3			2					
STERNUM	+	+	+	+	+	+	+	+	+	+	+	+	+	+	+
Focal hemosiderin deposition										2					
BONE MARROW SMEAR	+	+	U	+	+	+	+	+	+	+	+	+	+	+	+
MANDIBLE	+	+	+	+	+	+	+	+	+	+	L	+	+	+	+
Marginal gingivitis			2							1			3	2	
LEFT EYE			+												
Detached retina			X												
Lenticular degeneration			X												
RIGHT EYE													+		
Corneal vascularization													X		
Cupped disk													X		
ABDOMINAL MUSCLE													+		
Scar tissue													X		
SKELETAL MUSCLE			+											+	
SKIN															+
Squamous papilloma															X

MONS 016837

LITTON BIONETICS, INC.
PROJECT NO. 20777

TABLE 3C

SUMMARY OF HISTOLOGIC FINDINGS - INTERCURRENT DEATH

MALES AND FEMALES - ADULT

GROUP NUMBER	1	3	4	4			
SEX	FEMALE	FEMALE	MALE	FEMALE			
ANIMAL NUMBER	87F	84M	70GE	152F	330I	486M	770I
TYPE OF DEATH	D	D	K	D	K	K	D
CEREBRUM							
Hemorrhage, meningeal	+	+	+	+	+	+	+
Basal ganglia				3		2	3
Isolated neuron degeneration	2						
Hemosiderin deposition	2						
CEREBELLUM							
Hemorrhage, meningeal	+	+	+	+	+	+	+
Focus of malacia, folium	X			3			
Focus of malacia, pons							
Isolated neuron degeneration, nucleus	2					X	
Hemosiderin deposition, nucleus	2						
MID BRAIN							
Hemorrhage, meningeal	+	+	+	+	+	+	+
Microglial focus				3		X	3
SPINAL CORD							
Focus of hemorrhage and microglial reaction	L	+	L	L	+	+	+ X
PITUITARY GLAND							
Hemorrhage, pars nervosa	+	+	+	+	+	+	+
Chromophobe adenoma	X						3
EYELIDS							
Conjunctivitis	+	+	+	+	+	+	+
Focal necrosis and hemorrhage	3						
Hemorrhage, subepidermal				X			
Meibomian glands						3	
Squamous metaplasia, sebaceous elements		X				X	
Subtotal atrophy, sebaceous elements		X				X	
Atrophy, sebaceous elements							
Squamous impaction, duct/s		X	X	X	X		X
Mucinous metaplasia, duct/s			X	X	X	X	X
Dilated ducts		X	X	X	X	X	
Paraglandular cellular infiltration		1	3	3	2	3	

LITTON BIOMETICS, INC.
PROJECT NO. 20771

TABLE 3C (Continued)

GROUP NUMBER	1	3	4	4			
SEX	FEMALE	FEMALE	MALE	FEMALE			
ANIMAL NUMBER	87F	84IH	706E	152F	338I	486H	770I
TYPE OF DEATH	D	D	K	D	K	K	D
LIPS	+	+	+	+	+	+	+
Squamous metaplasia, sebaceous glands			X				
Subtotal atrophy, sebaceous glands			X			X	
Atrophy, sebaceous glands				X	X		X
Squamous metaplasia, glandular duct						X	
Hemorrhage, focal						2	
Focal mucosal erosion	X						
Focal laceration mucosa		X					
Mucocutaneous ulcer					X		
Mucosal ulcer				X			
Abscess, mucocutaneous junction						X	
Gangrenous stomatitis			X				
TONGUE	+	+	+	+	+	+	+
Mucosal epithelium							
Focal hydropic degeneration			X				
Intranuclear inclusions (viral)			X				
Squamous metaplasia, glandular ducts				X			
AXILLARY LYMPH NODE	+	+	+	+	+	+	+
Hemorrhage	3	3		2	2	2	3
Hemorrhage, extracapsular						4	
Erythrophagocytosis			3		2	2	3
Hemosiderin deposition			3	3		2	
Foreign body reaction						3	
Extracapsular necrotic focus						X	
Necrosis and intranuclear inclusions (viral)				X			
PAROTID SALIVARY GLAND	L	+	+	L	+	+	L
Cytoplasmic vacuolation acinar cells			3				
SUBMAXILLARY SALIVARY GLAND	+	+	+	+	+	+	+
ESOPHAGUS	+	+	+	+	+	+	+
Candidiasis							X
THYROIDS	+	+	+	+	+	+	+
Focal colloid degeneration	2						

MONS 016839

LITTON BIONETICS, INC.
PROJECT NO. 20771

TABLE 3C (Continued)

GROUP NUMBER	1	3	4	4			
SEX	FEMALE	FEMALE	MALE	FEMALE			
ANIMAL NUMBER	87F	841H	706E	152F	338I	486H	770I
TYPE OF DEATH	B	B	K	B	K	K	B
PARATHYROIDS	NP	NP	+	+	+	+	+
RIGHT LUNG	+	+	+	+	+	+	+
Pneumonyssus lesion/s		X			X	X	X
Pneumonyssus parasite/s		X			X	X	
Congestion		X	X		X		
Edema		X	X		X	X	
Localized consolidation and intranuclear inclusions (viral)				X			
Hemorrhage						X	X
LEFT LUNG	+	+	+	+	+	+	+
Pneumonyssus lesion/s		X			X	X	X
Pneumonyssus parasite/s		X			X	X	
Congestion		X	X		X		
Edema		X	X		X	X	
Localized consolidation and intranuclear inclusions (viral)				X			
Hemorrhage						X	X
THYMUS	NP	+	L	+	NP	NP	NP
HEART	+	+	+	+	+	+	+
Hemorrhage, epicardial				3		3	3
Hemorrhage, myocardial		2		3		3	3
Hemorrhage, endocardial				3		3	3
Focal myocardial necrosis	1						
Myocardial fibrosis	2						
Squamous metaplasia, epicardium			X				
LIVER	+	+	+	+	+	+	+
Focal necrosis	1				4		2
Focal hemosiderin deposition				4			
Abscess formation					3		
Periportal inflammation					4		
Intrahepatic bile ducts (second order)							
Epithelial hyperplasia					4		
Ectasia					3		
Mucoid content					X		

MONS 016840

LITTON BIONETICS, INC.
PROJECT NO. 20771

TABLE 3C (Continued)

GROUP NUMBER	1	3	4	4			
SEX	FEMALE	FEMALE	MALE	FEMALE			
ANIMAL NUMBER	B/F	#41M	706E	152F	33BI	486M	770I
TYPE OF BEATH	B	B	K	B	K	K	B
EXTRAHEPATIC BILE DUCT	L	L	L	L	+	+	+
Mucosal hyperplasia					4		
Mucoid content					X		
GALLBLADDER	+	+	+	A	+	+	+
Mucosal hyperplasia					4		
Mucoid content					X		
Collapsed lumen					X		
SPLEEN	+	+	+	+	+	+	+
Focal necrosis and intranuclear inclusions (viral)				X			
PANCREAS	+	+	+	+	+	+	+
Localized lobular atrophy							2
Focal necrosis and intranuclear inclusions (viral)				X			
Main duct							
Epithelial hyperplasia					4		
Mucoid content					X		
KIDNEYS	+	+	+	+	+	+	+
Hemorrhage, renal papilla							3
Focal glomerulosclerosis	2						
Pyelonephritic scars	3						
ADRENAL GLANDS	+	+	+	+	+	+	+
Hemorrhage, cortical	1		2	3	2		4
Hemorrhage, medullary					2		
URINARY BLADDER	+	+	+	+	+	+	+
Hemorrhage, submucosal						3	
Hemorrhage, mural						2	
Hemorrhage, subperitoneal				1			

MONS 016841

LEMON BIOMETICS, INC.
PROJECT NO. 20771

TABLE 3C (Continued)

GROUP NUMBER	1	3	4	4			
SEX	FEMALE	FEMALE	MALE	FEMALE			
ANIMAL NUMBER	0JF	0411	706F	152F	338I	406H	770I
TYPE OF DEATH	D	D	K	D	K	K	D
STOMACH	+	+	+	+	+	+	+
Hemorrhage, focal, mucosal			2			2	
Hemorrhage, submucosal (cardiac orifice)						3	
Submucosal edema				3			
Hydropic degeneration (cardiac orifice epithelium)			X				X
SMALL INTESTINE	+	+	+	+	+	+	+
Hemorrhage, focal, mucosal						2	2
Hemorrhage, focal, submucosal						2	
Hemorrhage, focal, peritoneal							2
Hemorrhage, diffuse				4			
Thrombi in lacteals			X			X	
Localized mucosal necrosis and intranuclear inclusions (viral)				X			
LARGE INTESTINE	+	+	+	+	+	+	+
Colon							
Hemorrhage, mucosal						2	2
Hemorrhage at mesenteric attachment						2	
Venous thrombosis	X						
Infarction	X						
Mucosal ulceration	X						
Localized peritonitis	X						
Localized mucosal necrosis and intranuclear inclusions (viral)				X			
Cecum							
Hemorrhage, mucosal							2
Hemorrhage, submucosal							2
Chronic ulcers							X
MESENTERIC LYMPH NODE	+	+	+	+	+	+	+
Hemorrhage	3			4	2	1	3
Hemosiderin deposition			2	2		1	2
Sinusoidal leucocytosis	2						
Lipid granulomas	2						

MONS 016842

LIFTON BIOMETICS, INC.
PROJECT NO. 20771

TABLE 3C (Continued)

GROUP NUMBER	1	3	4	4			
SEX	FEMALE	FEMALE	FEMALE	FEMALE			
ANIMAL NUMBER	87F	84M	706F	152F	330I	486H	770I
TYPE OF DEATH	D	D	K	D	K	K	D
TESTES			+				
EPIDIDYMIDES			+				
PROSTATE			L				
OVARIES	+	+		+	+	+	+
UTERUS	+	+		+	+	+	+
Hemorrhage/s, endometrial		3				4	2
Placental site, endometrium							
Necrosis	X						
Hemorrhage	X						
Endometrial necrosis and intranuclear inclusions (viral)				X			
CERVIX	+	+		+	+	+	+
Necrosis and intranuclear inclusions (viral)				X			
VAGINA	+	+		+	+	+	+
SCIATIC NERVE	L	+	+	+	+	+	L
TIBIAL NERVE	L	L	L	L	L	L	L
LEFT NIPPLE	L	L	L	+	L	L	L
Squamous in deep mammary duct				X			
HIP SKIN	+	+	+	+	+	+	+
Subfocal atrophy, sebaceous glands						X	
Atrophy, sebaceous glands			X		X		X
Follicular keratosis			X		7		
Hyperkeratosis							

MONS 016843

LITTON BIONETICS, INC.
PROJECT NO. 20771

TABLE 3C (Continued)

GROUP NUMBER	1	3	4	4			
SEX	FEMALE	FEMALE	MALE	FEMALE			
ANIMAL NUMBER	07F	04M	706E	152F	330I	406H	770I
TYPE OF DEATH	S	S	K	S	K	K	S
THIGH SKIN	+	+	+	L	+	+	+
Subtotal atrophy, sebaceous glands						X	
Atrophy, sebaceous glands			X		X		X
Follicular keratosis			X				
Squamous cyst			X				
Hyperkeratosis					2		
LABIUM	L	L		L	L	L	L
FORESKIN			L				
FEMORAL MARROW	+	+	+	+	+	+	+
Fatty marrow						X	X
Hemorrhage			3		4		4
Focal hemosiderin deposition			4	4		2	
Decreased granulocyte maturation				X	X		
STERNUM	+	+	+	+	+	+	+
Hemorrhage			2				
Focal hemosiderin deposition			2	3		3	
Decreased granulocyte maturation				X	X	X	X
Decreased cellularity			X	X	X	X	
BONE MARROW SMEAR	L	+	+	+	+	L	L
Decreased granulocyte maturation			1	X	X		
Excess lymphoid elements			X				
MANDIBLE	+	+	+	+	+	+	+
Subgingival epithelial cysts					X		
Marginal gingivitis	3						
Localized necrosis, periosteum			X				
SKELETAL MUSCLE	+						
Hemorrhage	2						

MDNS 016844

LITTON BIONETICS, INC.
PROJECT NO. 20771

TABLE 3C (Continued)

GROUP NUMBER	1	3	4	4			
SEX	FEMALE	FEMALE	MALE	FEMALE			
ANIMAL NUMBER	02F	04III	70GE	152F	330I	406H	770I
TYPE OF DEATH	B	B	K	B	K	K	B
ADIPOSE TISSUE							
Focal steatitis	+						
	2						
CHEEK POUCH			+			+	
Hemorrhage, circumscribed, mucosa and submucosa						X	
Mucosal epithelium							
Hydropic degeneration			X				
Intranuclear inclusions (viral)			X				
Gangrenous stomatitis			X				
PLANTAR LESIONS			+				
Epidermal callosities			X				
BIOPSY ABDOMINAL INCISION			+			+	+
Indolent ulcer			X			X	
Small suture abscess							X
Scar tissue							X
SKIN FROM MACULAR ERUPTION			+				
Atrophy, sebaceous glands			X				
Follicular keratosis			X				
Squamous cyst			X				
BRONCHIAL LYMPH NODE				+			
Necrosis and intranuclear inclusions (viral)				X			
SKIN - THORACIC				+			
Atrophy, sebaceous glands				X			
Squamous cysts				X			
PERITONEUM					+		
Hemorrhage, subperitoneal					+		
Localized fibrinocellular exudate (surface)					1		

MONS 016845

LITTON BIOMETICS, INC.
PROJECT NO. 20771

TABLE 3C (Continued)

GROUP NUMBER	1	1	4	4			
SEX	FEMALE	FEMALE	MALE	FEMALE			
ANIMAL NUMBER	87F	84IN	706E	152F	338I	486H	770I
TYPE OF DEATH	B	B	K	B	K	K	B
INGUINAL AREA							
Hemorrhage, subcutaneous						+	
						3	
SKIN LESION							
Hemorrhage, localized						+	
Necrosis, localized						X	
Inflammation, localized						X	
						X	
LUMBAR LYMPH NODES							
Hemorrhage							+
Hemosiderin deposition							4
							3
CECUM AND COLON CONTENTS							
Occult blood (present outside established reference range)							+
							5
NODULAR ABDOMINAL LESION, SITE UNSPECIFIED							
Circumscribed fat necrosis							+
							2
CAUSE OF DEATH							
Acute gastric dilatation	+	+		+			+
Post placental hemorrhage		X					
Systemic herpesvirus infection	X						
Intestinal bleeding				X			
							X
CAUSE OF MORIBUND CONDITION							
Gangrenous stomatitis			+		+	+	
Biliary tract lesions (P.C.B.)			X		X		
Anemia (P.C.B.)						X	

MONS 016846

LITTON BIONETICS, INC.
PROJECT NO. 20771

TABLE 30

SUMMARY OF HISTOLOGIC FINDINGS - TERMINAL KILL AND INTERCURRENT DEATH

MALES AND FEMALES - INFANT

GROUP NUMBER	1	1	1	1	1	1	1	4
SEX	FEMALE	MALE	FEMALE	FEMALE	MALE	MALE	FEMALE	FEMALE
ANIMAL NUMBER	00483	00518	00512	00533	00557	00574	00621	00542
TYPE OF DEATH	TK	T	T	T	T	T	T	B
CEREBRUM	N	+	+	+	+	+	+	+
Cortical edema, localized								1
CEREBELLUM	N	+	+	+	+	+	+	+
MID BRAIN	N	+	+	+	+	+	+	+
SPINAL CORD	NN	+	L	+	+	+	+	+
PITUITARY	NN	+	+	+	+	+	+	+
EYELIDS	NN	+	+	+	+	+	+	+
Conjunctivitis				3				
Meibomian glands								
Atrophy, sebaceous elements								1
Squamous impaction, ducts								1
LIPS	NN	+	+	+	+	+	+	+
Submucosal glands								
Lymphocytic infiltration				2				
Focus of inflammation with intranuclear inclusions (viral)				1				
Subtotal atrophy, sebaceous glands								1
TONGUE	NN	+	+	+	+	+	+	+
Candidiasis								1
AUXILIARY LYMPH NODE	NN	+	+	+	+	+	+	+
Hemorrhage			3				2	2
Erythrophagocytosis			1					

MONS 016847

LITTON BIONETICS, INC.
PROJECT NO. 2077I

TABLE 3B (Continued)

GROUP NUMBER	1	1	1	1	1	1	1	4
SEX	FEMALE	MALE	FEMALE	FEMALE	MALE	MALE	FEMALE	FEMALE
ANIMAL NUMBER	00403	00510	00532	00533	00557	00574	00621	00542
TYPE OF DEATH	TM	T	T	T	T	T	T	D
PAROTID SALIVARY GLAND	NH	+	+	+	+	+	+	+
SUBMAXILLARY SALIVARY GLAND	NH	+	+	+	+	+	+	+
ESOPHAGUS	NH	+	+	+	+	+	+	+
THYMUS	NH	+	+	+	+	+	L	+
PARATHYROIDS	NH	+	+	+	+	+	L	NP
RIGHT LUNG	+	+	+	+	+	+	+	+
Fetal atelectasis	X							
Congestion						X		X
Edema						X		
LEFT LUNG	+	+	+	+	+	+	+	+
Fetal atelectasis	X							
Congestion						X		X
Edema						X		
THYMUS	+	+	+	+	+	+	+	+
"Accidental" involution								X
Cystic Hassall's corpuscles								X
HEART	+	+	+	+	+	+	+	+
LIVER	+	+	+	+	+	+	+	+
Congestion	X							
Periportal infiltration			2					
Reactive foci					2			
Hemosiderin deposition							3	
Focal necrosis and intranuclear inclusions (viral)								X
Intrahepatic bile ducts (second order)								3
Epithelial hyperplasia								X
Mucoid content								

MONS 018648

LITTON BIONETICS, INC.
PROJECT NO. 20773

TABLE 3D (Continued)

GROUP NUMBER SEX ANIMAL NUMBER TYPE OF DEATH	1 FEMALE B0483 TK	1 MALE B0518 T	1 FEMALE B0532 T	1 FEMALE B0533 T	1 MALE B0557 T	1 MALE B0574 T	1 FEMALE B0621 T	4 FEMALE B0542 B
EXTRAHEPATIC BILE DUCT	MM	L	L	L	L	L	L	L
GALLBLADDER Mucosal hyperplasia	M	+	+	+	+	+	+	+ 3
SPLEEN Congestion Focal leucocytic infiltration	+ X	+	+	+	+	+	+	+ X 4
PANCREAS Ductal hyperplasia Acinar atrophy Parapancreatic abscess	+	+	+	+	+	+	+	+ 5 5 X
KIDNEYS Congestion Hemorrhage Pyelonephritis Retarded cortical maturation	+ X 3	+	+	+	+	+	+	+ 3 4
ADRENAL GLANDS Congestion Hemorrhage, cortical Focal calcification	+ X 3	+ 3	+	+	+	+	+	+
URINARY BLADDER Hemorrhage, submucosal	MM	+	+	+	+	+	+	+ 4
STOMACH Cystic mucinous metaplasia, mucosal glands Submucosal glandular cysts Paragastric abscess	M	+	+	+	+	+	+	+ 3 2 X
SMALL INTESTINE Crypt metaplasia, Brunner's glands Thrombi in lacteals	M	+	+	+	+	+	+	+ 4 X

MONS 016849

LITTON BIONETICS, INC.
PROJECT NO. 20771

TABLE 3B (Continued)

GROUP NUMBER	1	1	1	1	1	1	1	4
SEX	FEMALE	MALE	FEMALE	FEMALE	MALE	MALE	FEMALE	FEMALE
ANIMAL NUMBER	88483	88518	88532	88533	88557	88574	88621	88542
TYPE OF DEATH	FU	T	T	T	T	T	T	D
LARGE INTESTINE	M	+	+	+	+	+	+	+
Hemorrhage, ileocecal valve				3		4		
MESENTERIC LYMPH NODE	MM	+	+	+	+	+	+	+
TESTES		+			+	+		
EPIDIDYMIDES		+			+	+		
PROSTATE		L			L	L		
OVARIES	MM		+	+			+	+
UTERUS	MM		+	+			+	+
CERVIX	MM		+	+			+	+
VAGINA	MM		+	+			+	+
Lymphocytic infiltration, mucosa and submucosa				3				
SCIATIC NERVE	MM	+	+	+	+	+	+	+
TIBIAL NERVE	MM	L	L	L	L	L	L	L
LEFT NIPPLE	MM	L	L	L	L	L	L	L
HIP SKIN	MM	+	+	+	+	+	+	+
Atrophy, sebaceous glands								3
Follicular keratosis								3

MONS 016850

LITTON BIONETICS, INC.
PROJECT NO. 2077I

TABLE 3D (Continued)

GROUP NUMBER SEX ANIMAL NUMBER TYPE OF DEATH	1 FEMALE 00403 TU	1 MALE 00518 T	1 FEMALE 00532 T	1 FEMALE 00533 T	1 MALE 00557 T	1 MALE 00574 T	1 FEMALE 00621 T	4 FEMALE 00542 B
THIGH SKIN	NM	+	+	+	+	+	+	+
Subtotal atrophy, sebaceous glands								X
Follicular keratosis								X
LABIUM	NM		I	L			L	L
FORESKIN		L			L	L		
FEMORAL MARROW	NM	+	+	+	+	+	+	+
Decreased cellularity								X
STERNUM	NM	+	+	+	+	+	+	+
BONE MARROW SMEAR	NM	L	+	+	+	+	+	U
MANDIBLE	NM	+	+	+	+	+	+	+
Subgingival squamous cysts								X
PLACENTAL DISKS	+							
Clotted blood on detached surfaces	X							
SKIN								+
Keratinizing squamous papilloma								X
Intraepidermal abscess								X
Suture scars		M						

LITTON BIONETICS, INC.
PROJECT NO. 2077I

TABLE 3D (Continued)

GROUP NUMBER	2	2	2	2	2	2	3	3	3	3	3	3	3
SEX	FEMALE	FEMALE	MALE	FEMALE	MALE	FEMALE	MALE	FEMALE	MALE	FEMALE	FEMALE	MALE	MALE
ANIMAL NUMBER	88527	88562	88604	88754	88796	88815	88511	88546	88559	88569	88592	88603	88660
TYPE OF DEATH	T	T	T	T	S	T	T	D	T	T	T	T	T
CEREBRUM													
Bacterial meningitis	+	+	+	+	+	+	+	+	+	+	+	+	+
								X					
CEREBELLUM													
Focal inflammation, meninges	+	+	+	+	+	+	+	+	+	+	+	+	+
Bacterial meningitis							1						
								X					
MID BRAIN													
Bacterial meningitis	+	+	+	+	+	+	+	+	+	+	+	+	+
								X					
SPINAL CORD	+	+	+	+	L	+	+	+	+	+	+	+	+
PITUITARY GLAND	+	+	+	+	+	+	+	+	+	+	+	+	+
EYELIDS	+	+	+	+	+	+	+	+	+	+	+	+	+
Meibomian glands													
Atrophy, sebaceous elements								X		X		X	
Squamous impaction, ducts								X		X		X	
Localized atrophy, sebaceous elements									X				
Localized squamous impaction, ducts									X				
Mucinous metaplasia, ducts										X			
Paraglandular cellular infiltration										3			
LIPS	+	+	+	+	+	+	+	+	+	+	+	+	+
Inflammation, mucocutaneous junction						2							
Subtotal atrophy, sebaceous glands								X					
Microabscesses										2			
Parafollicular microabscess												1	
TONGUE	+	+	+	+	+	+	+	+	+	+	+	+	+
Candidiasis								X					
Erosion, dorsal surface										1			

MONS 016852

G-41

LITTON BIONETICS, INC.
PROJECT NO. 2077I

TABLE 3D (Continued)

GROUP NUMBER	2	2	2	2	2	2	3	3	3	3	3	3	3
SEX	FEMALE	FEMALE	MALE	FEMALE	MALE	FEMALE	MALE	FEMALE	MALE	FEMALE	FEMALE	MALE	MALE
ANIMAL NUMBER	00527	00562	00604	00754	00796	00815	00511	00546	00559	00569	00592	00603	00660
TYPE OF DEATH	T	T	T	T	S	T	T	D	T	T	T	T	T
AXILLARY LYMPH NODE	+	+	+	+	L	+	+	+	+	+	+	+	+
Hemorrhage	3	2				2		4					
Erythrophagocytosis		2											
Congestion								4					
Bacterial colonies								X					
PAROTID SALIVARY GLAND	+	+	+	+	L	+	L	+	+	+	+	+	+
SUBMAXILLARY SALIVARY GLAND	+	+	+	+	L	+	+	+	+	+	+	+	+
ESOPHAGUS	+	+	+	+	+	+	+	+	+	+	+	+	+
THYROIDS	+	+	+	+	+	+	+	+	+	+	+	+	+
PARATHYROIDS	NP	+	NP	+	+	NP	NP	+	+	+	+	NP	+
RIGHT LUNG	+	+	+	+	+	+	+	+	+	+	+	+	+
Congestion								X		X			
Edema						X		X		X			X
Hemorrhage						X							
Localized collapse and organization										X			
Atelectasis					X								
LEFT LUNG	+	+	+	+	+	+	+	+	+	+	+	+	+
Congestion								X		X			
Edema								X		X			
Hemorrhage						X							X
Atelectasis					X								
THYMUS	+	+	+	+	+	+	+	+	+	+	+	+	+
"Accidental" involution								X					
Cystic Hassall's corpuscles								X				X	

MONS 016853

LITTON BIOMETICS, INC.
PROJECT NO. 20771

TABLE 3D (Continued)

GROUP NUMBER	2	2	2	2	2	2	3	3	3	3	3	3	3
SEX	FEMALE	FEMALE	MALE	FEMALE	MALE	FEMALE	MALE	FEMALE	MALE	FEMALE	FEMALE	MALE	MALE
ANIMAL NUMBER	88527	88562	88604	88754	88796	88815	88811	88546	88559	88560	88592	88603	88840
TYPE OF DEATH	T	T	T	T	S	T	T	B	T	T	T	T	T
HEART	+	+	+	+	+	+	+	+	+	+	+	+	+
Bacterial necrosis, atrial myocardium								2					
LIVER	+	+	+	+	+	+	+	+	+	+	+	+	+
Reactive foci	3												
Bacterial colonies								X					
Hemorrhage, diffuse					X								
EXTRAHEPATIC BILE DUCT	L	L	L	I	L	+	L	L	L	+	L	L	+
GALLBLADDER	+	+	+	+	+	+	+	A	+	+	+	+	+
SPLEEN	+	+	+	+	+	+	+	+	+	+	+	+	+
Congestion								X					
Increased hemosiderin deposition							3						
Bacterial colonies								X					
PANCREAS	+	+	+	+	L	+	+	+	+	+	+	+	+
Ductal hyperplasia												3	
Acinar atrophy												3	
KIDNEYS	+	+	+	+	+	+	+	+	+	+	+	+	+
Focal nephritis							2						
Bacterial colonies								X					
Focal glomerulonephritis												2	
ADRENAL GLANDS	+	+	+	+	+	+	+	+	+	+	+	+	+
Bacterial colonies								X					
URINARY BLADDER	+	+	+	+	+	+	+	+	+	+	+	+	+
STOMACH	+	+	+	+	+	+	+	+	+	+	+	+	+
SMALL INTESTINE	+	+	+	+	+	+	+	+	+	+	+	+	+

MONS 016854

LITTON BIONETICS, INC.
PROJECT NO. 2077I

TABLE 3D (Continued)

GROUP NUMBER	2	2	2	2	2	2	3	3	3	3	3	3	3
SEX	FEMALE	FEMALE	MALE	FEMALE	MALE	FEMALE	MALE	FEMALE	MALE	FEMALE	FEMALE	MALE	MALE
ANIMAL NUMBER	88527	88562	88604	88754	88796	88815	88511	88546	88559	88560	88592	88693	88860
TYPE OF DEATH	T	T	T	T	S	T	T	M	T	T	T	T	T
LARGE INTESTINE	+	+	+	+	+	+	+	+	+	+	+	+	+
Hemorrhage, ileocecal valve	3	2											
Acute necrotizing colitis								1					
MESENTERIC LYMPH NODE	+	+	+	+	MP	+	+	+	+	+	+	+	+
Intravascular bacteria								1					
TESTES			+		L		+		+			+	+
EPIDIDYMIDES			+		L		+		+			+	+
PROSTATE			L		+		L		L			L	MP
OVARIES	+	+		+		+		+		+	+		
UTERUS	+	+		+		+		+		+	+		
CERVIX	+	+		+		+		MP		+	+		
VAGINA	+	+		+		+		MP		+	+		
Focal inflammation				2									
SCIATIC NERVE	+	+	+	+	+	+	+	+	+	+	+	+	+
TIBIAL NERVE	L	L	L	L	+	+	L	L	L	+	L	L	+
LEFT NIPPLE	L	L	L	MP	L	+	L	L	L	+	L	L	+
HIP SKIN	+	+	+	+	L	+	+	+	+	+	+	+	+
Hyperkeratosis								2					
Dermatomycosis								2					
Subtotal atrophy, sebaceous glands								1					

LITTON BIONETICS, INC.
PROJECT NO. 20771

TABLE 3D (Continued)

GROUP NUMBER	2	2	2	2	2	2	3	3	3	3	3	3	1
SEX	FEMALE	FEMALE	MALE	FEMALE	MALE	FEMALE	MALE	FEMALE	MALE	FEMALE	FEMALE	MALE	MALE
ANIMAL NUMBER	00527	00562	00604	00754	00796	00815	00511	00546	00559	00560	00592	00603	00660
TYPE OF DEATH	T	T	T	T	S	T	T	M	T	T	T	T	T
SKIN	+	+	+	+	+	+	+	+	+	+	+	+	+
Hyperkeratosis								2					
Dermatomycosis								2					
Subtotal atrophy, sebaceous glands								X					
LABIUM	L	L		L		+		L		+	L		
FORESKIN			L		L		L		L			L	+
FEMORAL MARROW	+	+	+	+	+	+	+	+	+	+	+	+	+
Decreased granulocyte maturation								X					
STERNUM	+	+	+	+	+	+	+	+	+	+	+	+	+
Decreased cellularity								X					
Decreased granulocyte maturation								X					
BONE MARROW SMEAR	+	+	+	+	+	+	L	+	+	+	+	+	+
Decreased granulocyte maturation								X					
MANDIBLE	+	+	+	+	+	+	+	+	+	+	+	+	+
Intraosseous squamous cyst						X							
Subgingival squamous cysts						X				X			
PERITONEUM								+					
Acute peritonitis								X					
SUBPLEURAL LYMPHOID ACCUMULATION										+			
Hyperplastic lymphocytic tissue										X			
HEMORRHAGE BETWEEN SKIN AND FRONTAL BONES				M									

NDNS 016856

LITTON BIONETICS, INC.
PROJECT NO. 20771

INDIVIDUAL ANIMAL PATHOLOGY EVALUATION

ANIMAL NUMBER:	764-E	PM NUMBER:	78/1712
DOSAGE:	0 ug/kg	GROUP NUMBER:	1
DATE OF DEATH:	12/5/78	SPECIES:	Monkey - adult
DEATH:	Terminal kill	SEX:	Female
METHOD OF KILL:	Lethane		

GROSS FINDINGS:
Lungs - several pneumonyssus lesions.

Comment - carcass in good condition.

MICROSCOPIC FINDINGS:
Eyelids - meibomian gland: cysts.
Right lung - pneumonyssus lesion.
Ovaries - cystic rete ovarii.
Mandible - marginal gingivitis, slight.

LITTON BIONETICS, INC.
PROJECT NO. 20771

INDIVIDUAL ANIMAL PATHOLOGY EVALUATION

ANIMAL NUMBER:	87-F	PM NUMBER:	78/1192
DOSAGE:	0 ug/kg	GROUP NUMBER:	1
DATE OF DEATH:	3/31/78	SPECIES:	Monkey - adult
DEATH:	Spontaneous death	SEX:	Female
METHOD OF KILL:			

GROSS FINDINGS:

Pituitary - grayish elevation, cyst or mass, 6 mm, not incised.
Heart - area of epicardial/pericardial adhesion, 1 cm.
Lungs - numerous pleural adhesions, chronic; small amount of ingesta in trachea and bronchi (apparently recent).
Colon - peritoneal adhesions in area of cecum; contents of cecum and colon semifluid and foul; mucosa of cecum and upper colon swollen and had large irregular necrotic foci.
Kidneys - pale and irregularly scarred or pitted.
Uterus - uterus not involuted; uterine mucosa quite swollen and edematous.

Comment - carcass obese.

Gross interpretation - non-specific cecitis and colitis resulting in gastrointestinal malfunction and vomition; post placental hemorrhage treated by cesarean section; death from hypovolemia, shock and terminal pulmonary aspiration (of stomach content).

MICROSCOPIC FINDINGS:

Cerebrum - basal ganglia: isolated neuron degeneration, slight; hemosiderin deposition, slight.
Cerebellum - cerebellar folium: focus of malacia; cerebellar nucleus: isolated neuron degeneration, slight; hemosiderin deposition, slight.
Pituitary gland - chromophobe adenoma.
Eyelids - conjunctivitis, moderate.
Lips - focal mucosal erosion.
Axillary lymph node - hemorrhage, moderate.
Thyroid - focal colloid degeneration, slight.
Heart - focal myocardial necrosis, minimal; myocardial fibrosis, slight.

MICROSCOPIC FINDINGS (Continued):

Liver - focal necrosis, minimal.
Kidneys - pyelonephritic scars, moderate; focal glomerulosclerosis, slight.
Adrenal glands - cortical hemorrhage, minimal.
Large intestine - colon: mucosal ulceration; venous thrombosis; infarction; localized peritonitis.
Mesenteric lymph node - hemorrhage, moderate; sinusoidal leucocytosis, slight; lipid granulomas, slight.
Uterus - endometrium, placental site, necrosis, hemorrhage.
Mandible - marginal gingivitis, moderate.
Skeletal muscle - hemorrhage, slight.
Adipose tissue - focal steatitis, slight.
Lungs - no lesion recognized.
Cause of death - post placental hemorrhage.

MISSING TISSUES:

Spinal cord - lost in processing.
Parotid salivary gland - lost in processing.
Thymus - not present in plane of section.
Extrahepatic bile duct - lost in processing.
Parathyroid - not present in plane of section.
Sciatic nerve - lost in processing.
Tibial nerve - lost in processing.
Left nipple - lost in processing.
Labium - lost in processing.
Bone marrow smear (femur) - lost in processing.

LITTON BIONETICS, INC.
PROJECT NO. 20771

INDIVIDUAL ANIMAL PATHOLOGY EVALUATION

ANIMAL NUMBER:	200-F	PM NUMBER:	78/1716
DOSAGE:	0 ug/kg	GROUP NUMBER:	1
DATE OF DEATH:	12/6/78	SPECIES:	Monkey - adult
DEATH:	Terminal kill	SEX:	Female
METHOD OF KILL:	Lethane		

GROSS FINDINGS:
Lungs - several pneumonyssus lesions.
Gallbladder - several 1 mm dark brownish-green granules in bile.
Urinary bladder - adhesion with omentum.
Uterus - adhesion with omentum.

Comment - some hair loss chest and abdomen; carcass fat.

MICROSCOPIC FINDINGS:
Spinal cord - nerve fiber degeneration, slight.
Axillary lymph node - hemorrhage, minimal; amyloid foci, slight.
Submaxillary salivary gland - lymphocytic foci, moderate.
Thyroid - focal lymphocytic infiltration, moderate.
Lungs - pneumonyssus lesion, left lung.
Pancreas - amyloid in islets, marked.
Adrenal glands - focal cortical lipidosis, slight.
Uterus - endometriosis, slight.
Cervix - endometriosis, slight.
Mandible - marginal gingivitis, slight.
Gallbladder - no lesion recognized.
Urinary bladder - no lesion recognized.

MISSING TISSUES:
Parathyroid - not present in plane of section.

LITTON BIONETICS, INC.
PROJECT NO. 20771

INDIVIDUAL ANIMAL PATHOLOGY EVALUATION

ANIMAL NUMBER:	274-F	PM NUMBER:	78/1720
DOSAGE:	0 ug/kg	GROUP NUMBER:	1
DATE OF DEATH:	12/7/78	SPECIES:	Monkey - adult
DEATH:	Terminal kill	SEX:	Female
METHOD OF KILL:	Lethane		

GROSS FINDINGS:

Lungs - a few pneumonyssus lesions.
Ovaries - adhesion with omentum involving uterus also, left ovary.
Uterus - adhesion with omentum involving left ovary also.

Comment - sparse haircoat arms and thighs; eyelashes short; moderate dry scaly skin; carcass in fair condition.

MICROSCOPIC FINDINGS:

Eyelids - conjunctivitis, slight.
Lips - focal mucosal erosion.
Axillary lymph node - hemorrhage, slight.
Right lung - pneumonyssus lesions.
Left lung - pneumonyssus lesion and parasite.
Adrenal glands - focal calcification, moderate.
Ovaries - endometriosis, slight.
Uterus - no lesion recognized.
Liver - focal necrosis, slight.

LITTON BIONETICS, INC.
PROJECT NO. 20771

INDIVIDUAL ANIMAL PATHOLOGY EVALUATION

ANIMAL NUMBER:	569-H	PM NUMBER:	78/1724
DOSAGE:	0 ug/kg	GROUP NUMBER:	1
DATE OF DEATH:	12/6/78	SPECIES:	Monkey - adult
DEATH:	Terminal kill	SEX:	Female
METHOD OF KILL:	Lethane		

GROSS FINDINGS:

Comment - carcass fat; slight calculus on teeth.

MICROSCOPIC FINDINGS:

Pituitary gland - vacuolated basophils.
Right lung - pneumonyssus lesions and parasites.
Left lung - pneumonyssus lesions.
Adrenal glands - focal calcification, slight.
Uterus - adenomyosis, slight.
Labium - submucosal foreign body microgranulomas.
Mandible - marginal gingivitis, minimal.

MONS 016862

LITTON BIONETICS, INC.
PROJECT NO. 20771

INDIVIDUAL ANIMAL PATHOLOGY EVALUATION

ANIMAL NUMBER:	578-H	PM NUMBER:	78/1728
DOSAGE:	0 ug/kg	GROUP NUMBER:	1
DATE OF DEATH:	12/6/78	SPECIES:	Monkey - adult
DEATH:	Terminal kill	SEX:	Female
METHOD OF KILL:	Lethane		

GROSS FINDINGS:

Lungs - pleural adhesions on both lungs; several pneumonyssus lesions.

Liver - several irregular areas on diaphragmatic surface have thickened capsule and dilated vessels or ducts (dull, light-colored areas on surface).

Uterus - omentum adherent to uterus at dorsal and cranial aspect.

Comment - sparse haircoat (some hair loss) top of head, lower back, arms and legs; moderate calculus on teeth; carcass in fair condition.

MICROSCOPIC FINDINGS:

Axillary lymph node - hemorrhage, slight.
Right lung - pneumonyssus lesions.
Left lung - pneumonyssus lesions and parasites.
Liver - localized superficial atrophy and fibrosis, slight.
Stomach - subacute gastritis, slight.
Uterus - peritoneal adhesion.
Mandible - marginal gingivitis, minimal.

MONS 016863

LITTON BIONETICS, INC.
PROJECT NO. 20771

INDIVIDUAL ANIMAL PATHOLOGY EVALUATION

ANIMAL NUMBER:	604-I	PM NUMBER:	78/1732
DOSAGE:	0 ug/kg	GROUP NUMBER:	1
DATE OF DEATH:	12/8/78	SPECIES:	Monkey - adult
DEATH:	Terminal kill	SEX:	Female
METHOD OF KILL:	Lethane		

GROSS FINDINGS:

Lungs - several pneumonyssus lesions.

Comment - carcass in fair condition.

MICROSCOPIC FINDINGS:

Eyelids - meibomian glands: paraglandular cellular infiltration, minimal.
Lips - focal mucosal erosion; focal submucosal lymphocytic infiltration, slight.
Axillary lymph node - hemorrhage, slight.
Liver - reactive foci, slight.
Lungs - no lesion recognized.

LITTON BIONETICS, INC.
PROJECT NO. 20771

INDIVIDUAL ANIMAL PATHOLOGY EVALUATION

ANIMAL NUMBER:	618-I	PM NUMBER:	78/1736
DOSAGE:	0 ug/kg	GROUP NUMBER:	1
DATE OF DEATH:	12/8/78	SPECIES:	Monkey - adult
DEATH:	Terminal kill	SEX:	Female
METHOD OF KILL:	Lethane		

GROSS FINDINGS:

Lungs - several Pneumonyssus lesions.

Comment - most incisors missing; small healing wound below left eye; carcass fat.

MICROSCOPIC FINDINGS:

Right lung - pneumonyssus lesions.
Left lung - pneumonyssus lesions.
Heart - focal cellular infiltration, minimal.
Liver - reactive foci, slight.
Adrenal glands - focal calcification, slight.

MONS 016865

LITTON BIONETICS, INC.
PROJECT NO. 20771

INDIVIDUAL ANIMAL PATHOLOGY EVALUATION

ANIMAL NUMBER:	227-G	PM NUMBER:	78/1743
DOSAGE:	0 ug/kg	GROUP NUMBER:	1
DATE OF DEATH:	12/11/78	SPECIES:	Monkey - adult
DEATH:	Terminal kill	SEX:	Male
METHOD OF KILL:	Lethane		

GROSS FINDINGS:

Lungs - several pneumonyssus lesions.
Stomach - several grayish elevated foci, 1-2 mm, in pyloric area of stomach; two brownish foci of same size.

Comment - moderate calculus on teeth; anal area slightly soiled with feces; carcass fat.

MICROSCOPIC FINDINGS:

Lips - focal lymphocytic infiltration, submucosal glands, slight.
Axillary lymph node - hemorrhage, slight.
Right lung - pneumonyssus lesion.
Left lung - pneumonyssus lesions and parasites.
Liver - reactive foci, slight.
Prostate - focal inflammation, minimal.
Stomach - no lesion recognized.

LITTON BIONETICS, INC.
PROJECT NO. 20771

INDIVIDUAL ANIMAL PATHOLOGY EVALUATION

ANIMAL NUMBER:	418-J	PM NUMBER:	78/1749
DOSAGE:	0 ug/kg	GROUP NUMBER:	1
DATE OF DEATH:	12/5/78	SPECIES:	Monkey - adult
DEATH:	Terminal kill	SEX:	Male
METHOD OF KILL:	Lethane		

GROSS FINDINGS:
No gross lesion recognized.

Comment - carcass in good condition.

MICROSCOPIC FINDINGS:
Eyelids - meibomian gland: cyst; dilated duct.

MISSING TISSUES:
Parathyroid - not present in plane of section.

MONS 016867

LITTON BIONETICS, INC.
PROJECT NO. 20771

INDIVIDUAL ANIMAL PATHOLOGY EVALUATION

ANIMAL NUMBER:	426-G	PM NUMBER:	78/1746
DOSAGE:	0 ug/kg	GROUP NUMBER:	1
DATE OF DEATH:	12/7/78	SPECIES:	Monkey - adult
DEATH:	Terminal kill	SEX:	Male
METHOD OF KILL:	Lethane		

GROSS FINDINGS:

Lungs - several pneumonyssus lesions.
Stomach - stomach mucosa stripped easily.

Comment - some loss of hair on chest; carcass thin, in poor condition.

MICROSCOPIC FINDINGS:

Axillary lymph node - foreign body reaction, slight.
Parotid salivary gland - focal inflammation, minimal.
Submaxillary salivary gland - focal inflammation, minimal.
Thyroids - focal colloid degeneration, slight.
Right lung - pneumonyssus lesions and parasites.
Left lung - pneumonyssus lesions and parasites.
Liver - reative foci, slight.
Adrenal glands - focal calcification, minimal.
Prostate - focal inflammation, minimal.
Stomach - no lesion recognized.

LITTON BIONETICS, INC.
PROJECT NO. 20771

INDIVIDUAL ANIMAL PATHOLOGY EVALUATION

ANIMAL NUMBER:	739-F	PM NUMBER:	78/1740
DOSAGE:	0 ug/kg	GROUP NUMBER:	1
DATE OF DEATH:	12/7/78	SPECIES:	Monkey - adult
DEATH:	Terminal kill	SEX:	Male
METHOD OF KILL:	Lethane		

GROSS FINDINGS:

Lungs - several pneumonyssus lesions; slight pleural adhesion; frothy fluid in trachea and bronchi; plastic tube in place at thoracic duct, cannulation site.

Comment - moderate calculus on teeth; carcass in good condition.

MICROSCOPIC FINDINGS:

Lips - foreign body microgranuloma.
Right lung - congestion and edema.
Left lung - congestion and edema; pneumonyssus lesion and parasite.
Liver - reactive foci, minimal.
Mesenteric lymph node - hemorrhage, minimal.
Prostate - focal inflammation, minimal.

LITTON BIONETICS, INC.
PROJECT NO. 20771

INDIVIDUAL ANIMAL PATHOLOGY EVALUATION

ANIMAL NUMBER:	296-I	PM NUMBER:	77/1309
DOSAGE:	5 ug/kg	GROUP NUMBER:	2
DATE OF DEATH:	4/12/77	SPECIES:	Monkey - adult
DEATH:	Found dead	SEX:	Female
METHOD OF KILL:			

GROSS FINDINGS:

Acute gastric dilatation with rupture.

MICROSCOPIC FINDINGS:

No tissues saved.

LITTON BIONETICS, INC.
PROJECT NO. 20771

INDIVIDUAL ANIMAL PATHOLOGY EVALUATION

ANIMAL NUMBER:	284-I	PM NUMBER:	78/1729
DOSAGE:	5 ug/kg	GROUP NUMBER:	2
DATE OF DEATH:	12/6/78	SPECIES:	Monkey - adult
DEATH:	Terminal kill	SEX:	Female
METHOD OF KILL:	Lethane		

GROSS FINDINGS:

Lips - several small hemorrhages in mucosa.
Lungs - several pneumonyssus lesions; a few pleural adhesions.
Gallbladder - sand in bile.

Comment - some hair loss from skin of lower back and legs; carcass in fair condition.

MICROSCOPIC FINDINGS:

Spinal cord - focal lymphocytic infiltration, meninges, slight.
Lips - focal mucosal erosion.
Right lung - pneumonyssus lesions and parasite.
Left lung - pneumonyssus lesions and parasites.
Heart - focal cellular infiltration, minimal.
Mesenteric lymph node - parasitic larva.
Gallbladder - no lesion recognized.

LITTON BIONETICS, INC.
PROJECT NO. 20771

INDIVIDUAL ANIMAL PATHOLOGY EVALUATION

ANIMAL NUMBER:	309-I	PM NUMBER:	78/1737
DOSAGE:	5 ug/kg	GROUP NUMBER:	2
DATE OF DEATH:	12/7/78	SPECIES:	Monkey - adult
DEATH:	Terminal kill	SEX:	Female
METHOD OF KILL:	Lethane		

GROSS FINDINGS:
Lungs - several pneumonyssus lesions.
Duodenum - several minute greyish foci in mucosa.

Comment - haircoat ample, but hair of varying lengths as though animal was shedding; carcass fat.

MICROSCOPIC FINDINGS:
Spinal cord - nerve fiber degeneration, minimal.
Lips - focal lymphocytic infiltration, submucosal glands, slight.
Axillary lymph node - foreign body-type inflammatory reaction, moderate
Thyroids - focal lymphocytic infiltration, minimal.
Right lung - pneumonyssus lesions and parasite.
Left lung - pneumonyssus lesions.
Duodenum - no lesion recognized.

MONS 016872

LITTON BIONETICS, INC.
PROJECT NO. 20771

INDIVIDUAL ANIMAL PATHOLOGY EVALUATION

ANIMAL NUMBER:	483-F	PM NUMBER:	78/1733
DOSAGE:	5 ug/kg	GROUP NUMBER:	2
DATE OF DEATH:	12/11/78	SPECIES:	Monkey - adult
DEATH:	Terminal kill	SEX:	Female
METHOD OF KILL:	Lethane		

GROSS FINDINGS:

Heart - pink coloration of left atrioventricular and semi-lunar valves.
Lungs - pleural adhesion, right side, moderate; several pneumonyssus lesions.
Gallbladder - sandy-green precipitate, slight.
Sternum - cartilage missing between sternal segments 3-4.
Skeletal muscle - pale muscle in area between sternum and shoulder point.

Comment - short haircoat over arms and shoulders; left eye sunken and pupil dilated; condition fair.

MICROSCOPIC FINDINGS:

Esophagus - parasitism, slight.
Thyroids - microfollicular foci, moderate; focal colloid degeneration, slight.
Right lung - congestion and edema.
Left lung - congestion and edema; pneumonyssus lesion.
Heart - focal cellular infiltration, minimal.
Liver - focal bile duct proliferation, minimal.
Kidneys - cortical microcysts, slight.
Bone marrow smear (femur) - unsatisfactory smear.
Mandible - marginal gingivitis, slight.
Left eye - detached retina, lenticular degeneration.
Gallbladder - no lesion recognized.
Sternum - no lesion recognized.
Skeletal muscle - no lesion recognized.

MONS 016873

LITTON BIONETICS, INC.
PROJECT NO. 20771

INDIVIDUAL ANIMAL PATHOLOGY EVALUATION

ANIMAL NUMBER:	605-F	PM NUMBER:	78/1721
DOSAGE:	5 ug/kg	GROUP NUMBER:	2
DATE OF DEATH:	12/6/78	SPECIES:	Monkey - adult
DEATH:	Terminal kill	SEX:	Female
METHOD OF KILL:	Lethane		

GROSS FINDINGS:

Stomach - several minute, slightly raised, whitish spots in gastric mucosa.
Liver - one minute, 2 mm, cyst; one minute dark depression, 2 mm.
Vagina - rough mucosa.

Comment - hair loss lower back, right flank and right thigh; carcass fat.

MICROSCOPIC FINDINGS:

Eyelids - meibomian glands: paraglandular cellular infiltration, slight.
Lips - focal of mucosal erosion.
Axillary lymph node - foreign body granulomatous reaction, slight, focal.
Left lung - pneumonyssus lesions.
Liver - telangiectatic focus; congenital cyst (small).
Left nipple - mammary gland ductal hyperplasia, slight.
Labium - submucosal microcyst.
Stomach - no lesion recognized.
Vagina - no lesion recognized.

LITTON BIONETICS, INC.
PROJECT NO. 20771

INDIVIDUAL ANIMAL PATHOLOGY EVALUATION

ANIMAL NUMBER:	624-I	PM NUMBER:	78/1741
DOSAGE:	5 ug/kg	GROUP NUMBER:	2
DATE OF DEATH:	12/5/78	SPECIES:	Monkey - adult
DEATH:	Terminal kill	SEX:	Female
METHOD OF KILL:	Lethane		

GROSS FINDINGS:

Pituitary gland - appears lobulated.
Lips - erosion on inner margin of lower lip.
Lungs - several pneumonyssus lesions.
Stomach - numerous, 2 mm, slightly elevated pale areas, whitish, in fundus mucosa.
Duodenum - several minute whitish elevations in mucosa around opening of bile duct.
Spleen - sacs of echinococcus cysts in spleen and adjacent peritoneal ligaments.

Comment - carcass fat; haircoat on arms thin; moderate calculus on teeth.

MICROSCOPIC FINDINGS:

Lips - focal lymphocytic infiltration, submucosal glands, slight; focal mucosal erosion.
Liver - reative foci, slight.
Spleen - parasitic cysts (unidentified).
Adrenal glands - focal calcification, slight.
Pituitary gland - no lesion recognized.
Lungs - no lesion recognized.
Stomach - no lesion recognized.
Duodenum - no lesion recognized.

LITTON BIONETICS, INC.
PROJECT NO. 20771

INDIVIDUAL ANIMAL PATHOLOGY EVALUATION

ANIMAL NUMBER:	646-E	PM NUMBER:	78/1713
DOSAGE:	5 ug/kg	GROUP NUMBER:	2
DATE OF DEATH:	12/6/78	SPECIES:	Monkey - adult
DEATH:	Terminal kill	SEX:	Female
METHOD OF KILL:	Lethane		

GROSS FINDINGS:

Lungs - numerous pneumonyssus.
Uterus - several small peritoneal adhesions; minute whitish spots and streaks on peritoneal surface.

Comment - some loss of hair on arms and legs; carcass in good condition.

MICROSCOPIC FINDINGS:

Spinal cord - nerve fiber degeneration, minimal.
Eyelids - meibomian glands: paraglandular cellular infiltration, minimal.
Axillary lymph node - foreign body reaction, slight.
Right lung - pneumonyssus lesions and parasite.
Left lung - pneumonyssus lesions and parasite.
Femoral marrow - focal hemosiderin deposition, moderate.
Uterus - no lesion recognized.

MONS 016876

LITTON BIONETICS, INC.
PROJECT NO. 20771

INDIVIDUAL ANIMAL PATHOLOGY EVALUATION

ANIMAL NUMBER:	701-E	PM NUMBER:	78/1717
DOSAGE:	5 ug/kg	GROUP NUMBER:	2
DATE OF DEATH:	12/8/78	SPECIES:	Monkey - adult
DEATH:	Terminal kill	SEX:	Female
METHOD OF KILL:	Lethane		

GROSS FINDINGS:

Brain - at trimming - cestode larval cyst, right frontal lobe, 1 cm x 1 cm x 1 cm; photographed and cut.
Lungs - several pneumonyssus lesions.
Extrahepatic bile duct - dilated approximately four times.

Comment - nipples red, rough and nodular; incisors worn - not missing; sparse haircoat back and thighs; carcass in good condition.

MICROSCOPIC FINDINGS:

Cerebrum - parasitic cyst.
Eyelids - meibomian glands: paraglandular cellular infiltration, slight.
Axillary lymph node - hemorrhage, slight.
Right lung - pneumonyssus lesions and parasites.
Left lung - pneumonyssus lesion.
Liver - focal hemosiderin deposition, slight.
Extrahepatic bile duct - chronic cholangitis, moderate.
Gallbladder - chronic cholecystitis, moderate.
Vagina - submucosal cyst.
Femoral marrow - focal hemosiderin deposition, moderate.
Left nipple - no lesion recognized.

MONS 016877

LITTON BIONETICS, INC.
PROJECT NO. 20771

INDIVIDUAL ANIMAL PATHOLOGY EVALUATION

ANIMAL NUMBER:	839-H	PM NUMBER:	78/1725
DOSAGE:	5 ug/kg	GROUP NUMBER:	2
DATE OF DEATH:	12/8/78	SPECIES:	Monkey - adult
DEATH:	Terminal kill	SEX:	Female
METHOD OF KILL:	Lethane		

GROSS FINDINGS:

Lungs - pneumonyssus lesions; small area of increased density and dark coloration.
Gallbladder - irregular in contour but not thickened.
Uterus - adhesion with omentum.

Comment - tips of both nipples firm and white; carcass fat.

MICROSCOPIC FINDINGS:

Eyelids - meibomian glands: cyst; dilated ducts.
Right lung - pneumonyssus lesions and parasite.
Liver - reactive foci, slight.
Adrenal glands - focal calcification, slight.
Mesenteric lymph node - hemorrhage, slight.
Uterus - endometriosis, slight.
Gallbladder - no lesion recognized.
Left nipple - no lesion recognized.

LITTON BIONETICS, INC.
PROJECT NO. 20771

INDIVIDUAL ANIMAL PATHOLOGY EVALUATION

ANIMAL NUMBER:	119-H	PM NUMBER:	78/1747
DOSAGE:	5 ug/kg	GROUP NUMBER:	2
DATE OF DEATH:	12/7/78	SPECIES:	Monkey - adult
DEATH:	Terminal kill	SEX:	Male
METHOD OF KILL:	Lethene		

GROSS FINDINGS:
Lungs - several pneumonyssus lesions.
Thoracic spinal column - scoliosis.

Comment - carcass in good condition.

MICROSCOPIC FINDINGS:
Thyroids - focal lymphocytic infiltration, slight.
Right lung - pneumonyssus lesion.
Left lung - hemosiderin deposition, slight.
Kidneys - focal calcification, minimal.
Femoral marrow - focal hemosiderin deposition, moderate.

MISSING TISSUES:
Thoracic spinal column - not examined microscopically.

LITTON BIONETICS, INC.
PROJECT NO. 20771

INDIVIDUAL ANIMAL PATHOLOGY EVALUATION

ANIMAL NUMBER:	428-J	PM NUMBER:	78/1750
DOSAGE:	5 ug/kg	GROUP NUMBER:	2
DATE OF DEATH:	12/5/78	SPECIES:	Monkey - adult
DEATH:	Terminal kill	SEX:	Male
METHOD OF KILL:	Lethane		

GROSS FINDINGS:

Lungs - several pneumonyssus lesions; slight pleural adhesion.

Comment - carcass in good condition.

MICROSCOPIC FINDINGS:

Adrenal glands - focal calcification, moderate.
Epididymides - focal lymphocytic infiltration, unilateral, slight.
Prostate - focal inflammation, slight.
Lungs - no lesion recognized.

MONS 016880

LITTON BIONETICS, INC.
PROJECT NO. 20771

INDIVIDUAL ANIMAL PATHOLOGY EVALUATION

ANIMAL NUMBER:	432-J	PM NUMBER:	78/1752
DOSAGE:	5 ug/kg	GROUP NUMBER:	2
DATE OF DEATH:	12/11/78	SPECIES:	Monkey - adult
DEATH:	Terminal kill	SEX:	Male
METHOD OF KILL:	Letnane		

GROSS FINDINGS:
Lungs - several pneumonyssus lesions.
Stomach - several, 1 mm, grayish foci, fundic and pyloric regions.

Comment - carcass in good condition.

MICROSCOPIC FINDINGS:
Lips - focal lymphocytic infiltration, submucosal glands, slight.
Right lung - pneumonyssus lesions and parasite.
Left lung - pneumonyssus lesions and parasites.
Kidneys - focus of hemorrhage and plasma cell infiltration in cortex.
Adrenal glands - focal cortical lipidosis, minimal; focal calcification, minimal.
Prostate - focal inflammation, slight.
Stomach - no lesion recognized.

MONS 016881

LITTON BIONETICS, INC.
PROJECT NO. 20771

INDIVIDUAL ANIMAL PATHOLOGY EVALUATION

ANIMAL NUMBER:	516-G	PM NUMBER:	78/1744
DOSAGE:	5 ug/kg	GROUP NUMBER:	2
DATE OF DEATH:	12/7/78	SPECIES:	Monkey - adult
DEATH:	Terminal kill	SEX:	Male
METHOD OF KILL:	Lethane		

GROSS FINDINGS:

Lips - two rough areas on mucosa of lower lip.
Heart - irregular areas of left ventricular epicardium were opaque and gray, mostly adjacent to vessels.
Stomach - numerous minute grayish foci in pyloric mucosa.

Comment - fair condition.

MICROSCOPIC FINDINGS:

Spinal cord - nerve fiber degeneration, minimal.
Pituitary gland - microcysts, few.
Eyelids - meibomian glands: several dilated ducts.
Lips - focal epidermitis, minimal.
Right lung - pneumonyssus lesion.
Left lung - pneumonyssus parasite.
Heart - focal myocardial necrosis, minimal.
Adrenal glands - focal calcification, moderate.
Prostate - focal inflammation, slight.
Stomach - no lesion recognized.

MONS 016882

LITTON BIONETICS, INC.
PROJECT NO. 20771

INDIVIDUAL ANIMAL PATHOLOGY EVALUATION

ANIMAL NUMBER:	841-H	PM NUMBER:	78/1550
DOSAGE:	25 ug/kg	GROUP NUMBER:	3
DATE OF DEATH:	8/30/78	SPECIES:	Monkey - adult
DEATH:	Found dead	SEX:	Female
METHOD OF KILL:			

GROSS FINDINGS:

Lips - dark, apparently eroded area, approximately 0.5 cm, on inner surface, left side, of lower lip.
Thymus - not recognized.
Lungs - reddened, congested.
Stomach - markedly distended.
Bone marrow - fatty.

Comment - eyelids normal; abdomen distended; haircoat thin; well-marked postmortem changes in viscera.
Cause of death - apparent acute dilatation.

MICROSCOPIC FINDINGS:

Eyelids - meibomian glands: squamous metaplasia, sebaceous elements; squamous impaction, duct; subtotal atrophy, sebaceous elements; paraglandular cellular infiltration, moderate; dilated ducts.
Lips - focal laceration mucosa.
Axillary lymph node - hemorrhage, moderate.
Right lung - pneumonyssus lesions and parasite; congestion and edema.
Left lung - pneumonyssus lesions and parasites; congestion and edema.
Heart - myocardial hemorrhage, slight.
Uterus - endometrial hemorrhage, moderate.
Stomach - no lesion recognized.
Bone marrow - no lesion recognized.
Thymus - no lesion recognized.
Cause of death - acute gastric dilatation.

MISSING TISSUES:

Extrahepatic bile duct - lost in processing.
Tibial nerve - lost in processing.
Left nipple - lost in processing.
Labium - lost in processing.

MONS 016883

LITTON BIONETICS, INC.
PROJECT NO. 20771

INDIVIDUAL ANIMAL PATHOLOGY EVALUATION

ANIMAL NUMBER:	273-I	PM NUMBER:	78/1730
DOSAGE:	25 ug/kg	GROUP NUMBER:	3
DATE OF DEATH:	12/6/78	SPECIES:	Monkey - adult
DEATH:	Terminal kill	SEX:	Female
METHOD OF KILL:	Lethane		

GROSS FINDINGS:

Liver - large and soft.

Comment - carcass fat.

MICROSCOPIC FINDINGS:

Eyelids - meibomian glands: paraglandular cellular infiltration, slight; dilated ducts.
Right lung - pneumonyssus lesions and parasites.
Left lung - pneumonyssus lesions and parasites.
Liver - no lesion recognized.

LITTON BIONETICS, INC.
PROJECT NO. 20771

INDIVIDUAL ANIMAL PATHOLOGY EVALUATION

ANIMAL NUMBER:	281-G	PM NUMBER:	78/1722
DOSAGE:	25 ug/kg	GROUP NUMBER:	3
DATE OF DEATH:	12/11/78	SPECIES:	Monkey - adult
DEATH:	Terminal kill	SEX:	Female
METHOD OF KILL:	Lethane		

GROSS FINDINGS:
Lungs - several pneumonyssus lesions.
Stomach - numerous minute grayish foci in fundus mucosa.

Comment - sparse haircoat; carcass fat.

MICROSCOPIC FINDINGS:
Spinal cord - nerve fiber degeneration, minimal.
Pituitary gland - microcyst.
Eyelids - meibomian glands: paraglandular cellular infiltration, minimal; dilated ducts.
Parotid salivary gland - focal inflammation, minimal.
Left lung - pneumonyssus lesion.
Heart - focal cellular infiltration, minimal.
Liver - focal hemosiderin deposition, slight.
Femoral marrow - focal hemosiderin deposition, slight.
Sternum - focal hemosiderin deposition, slight.
Mandible - marginal gingivitis, minimal.
Stomach - no lesion recognized.

LITTON BIONETICS, INC.
PROJECT NO. 20771

INDIVIDUAL ANIMAL PATHOLOGY EVALUATION

ANIMAL NUMBER:	307-I	PM NUMBER:	78/1734
DOSAGE:	25 ug/kg	GROUP NUMBER:	3
DATE OF DEATH:	12/5/78	SPECIES:	Monkey - adult
DEATH:	Terminal kill	SEX:	Female
METHOD OF KILL:	Lethane		

GROSS FINDINGS:
Lungs - several pneumonyssus lesions and adhesions, pleural.

Comment - carcass fat; slight dry scaly skin; slight calculus on teeth.

MICROSCOPIC FINDINGS:
Spinal cord - nerve fiber degeneration, minimal.
Right lung - pneumonyssus lesions.
Left lung - pneumonyssus lesions.
Adrenal glands - focal calcification, moderate.
Hip skin - subtotal atrophy, sebaceous glands.
Thigh skin - subtotal atrophy, sebaceous glands.

MISSING TISSUES:
Mandible - lost during processing.

LITTON BIONETICS, INC.
PROJECT NO. 20771

INDIVIDUAL ANIMAL PATHOLOGY EVALUATION

ANIMAL NUMBER:	540-H	PM NUMBER:	78/1726
DOSAGE:	25 ug/kg	GROUP NUMBER:	3
DATE OF DEATH:	12/8/78	SPECIES:	Monkey - adult
DEATH:	Terminal kill	SEX:	Female
METHOD OF KILL:	Lethane		

GROSS FINDINGS:

Lungs - several pneumonyssus lesions.
Liver - fairly numerous minute grayish spots on liver, cysts.

Comment - crusty nipples, 2 mm white nodule on left nipple; area of hair loss over lower back and right flank; slight calculus on teeth; carcass in good condition.

MICROSCOPIC FINDINGS:

Spinal cord - nerve fiber degeneration, slight.
Eyelids - meibomian glands: dilated ducts.
Right lung - pneumonyssus lesion and parasite.
Left lung - pneumonyssus lesion.
Liver - periportal infiltration, slight; two congenital cysts, small.
Kidneys - focal glomerulosclerosis, slight.
Adrenal glands - focal calcification, slight.
Left nipple - no lesion recognized.

LITTON BIONETICS, INC.
PROJECT NO. 20771

INDIVIDUAL ANIMAL PATHOLOGY EVALUATION

ANIMAL NUMBER:	757-I	PM NUMBER:	78/1738
DOSAGE:	25 ug/kg	GROUP NUMBER:	3
DATE OF DEATH:	12/6/78	SPECIES:	Monkey - adult
DEATH:	Terminal kill	SEX:	Female
METHOD OF KILL:	Lethane		

GROSS FINDINGS:

Lungs - several pneumonyssus lesions; frothy fluid in trachea and bronchi.
Vagina - rough mucosa; blood in lumen.

Comment - corneal opacity, right eye; teeth had slight calculus; surface of nipples slightly rough and scaly; 2 cm x 1.5 cm x 0.8 cm subcutaneous mass in abdominal area right of midline. Carcass in good condition.

Subcutaneous abdominal mass proved to be slight omental herniation through previous surgical incision; eyes harvested, right eye had corneal opacity and the eyeball was unusually firm.

MICROSCOPIC FINDINGS:

Eyelids - meibomian glands: cyst; paraglandular cellular infiltration, slight.
Lips - focal lymphocytic infiltration, submucosal glands, slight.
Axillary lymph node - foreign body reaction, slight.
Thyroids - microfollicular foci, minimal.
Right lung - pneumonyssus lesions; congestion and edema.
Left lung - congestion and edema.
Heart - focal cellular infiltration, minimal.
Kidneys - focal glomerulosclerosis, moderate.
Adrenal glands - focal calficification, slight.
Mandible - marginal gingivitis, moderate.
Abdominal musculature - scar tissue in abdominal muscle.
Right eye - corneal vascularization; cupped disk.
Vagina - no lesion recognized.

MISSING TISSUES:

Thymus - lost during processing.

LITTON BIONETICS, INC.
PROJECT NO. 20771

INDIVIDUAL ANIMAL PATHOLOGY EVALUATION

ANIMAL NUMBER:	762-E	PM NUMBER:	78/1714
DOSAGE:	25 ug/kg	GROUP NUMBER:	3
DATE OF DEATH:	12/6/78	SPECIES:	Monkey - adult
DEATH:	Terminal kill	SEX:	Female
METHOD OF KILL:	Lethane		

GROSS FINDINGS:

Lungs - several pneumonyssus lesions, several pleural adhesions, apical lobes.
Ileum - some bloody discoloration of content of upper ileum, localized.
Vagina - rough mucosa, bloody content.
Skeletal muscle - pale areas in muscle, usually most noticeable beneath the muscle sheath, in neck, shoulder, arm and leg regions.

Comment - some hair loss from lower back, arms and legs; nipple skin rough and scurfy; bloody crust and moisture on skin around vulva; carcass in fair condition, very little depot fat.

MICROSCOPIC FINDINGS:

Eyelids - meibomian glands: paraglandular cellular infiltration, slight.
Axillary lymph node - hemorrhage, slight.
Right lung - congestion and edema, terminal.
Left lung - congestion and edema, terminal.
Adrenal glands - focal calcification, moderate.
Hip skin - subtotal atrophy, sebaceous glands.
Labium - squamous cysts, two.
Mandible - marginal gingivitis, slight.
Skeletal muscle - no lesion recognized.
Vagina - no lesion recognized.
Ileum - no lesion recognized.

LITTON BIONETICS, INC.
PROJECT NO. 20771

INDIVIDUAL ANIMAL PATHOLOGY EVALUATION

ANIMAL NUMBER:	763-E	PM NUMBER:	78/1718
DOSAGE:	25 ug/kg	GROUP NUMBER:	3
DATE OF DEATH:	12/7/78	SPECIES:	Monkey - adult
DEATH:	Terminal kill	SEX:	Female
METHOD OF KILL:	Lethane		

GROSS FINDINGS:

Lungs - few pneumonyssus lesions.
Gallbladder - submucous cyst, 5 mm.
Vagina - rough mucosa.
Uterus - omentum adherent to uterus.

Comment - slight hair loss from legs; 3 mm wart-like lesion in skin 2 cm lateral to right eye.

MICROSCOPIC FINDINGS:

Eyelids - meibomian glands: paraglandular cellular infiltration, slight.
Liver - focal hemosiderin deposition, moderate; periportal infiltration, slight.
Adrenal glands - focal calcification, slight.
Uterus - peritoneal adhesion.
Wart-like lesion in skin - squamous papilloma.
Lungs - no lesion recognized.
Gallbladder - no lesion recognized.
Vagina - no lesion recognized.

MISSING TISSUES:

Ovaries - one missing.

MONS 016890

LITTON BIONETICS, INC.
PROJECT NO. 20771

INDIVIDUAL ANIMAL PATHOLOGY EVALUATION

ANIMAL NUMBER:	20-I	PM NUMBER:	78/1742
DOSAGE:	25 ug/kg	GROUP NUMBER:	3
DATE OF DEATH:	12/5/78	SPECIES:	Monkey - adult
DEATH:	Terminal kill	SEX:	Male
METHOD OF KILL:	Lethane		

GROSS FINDINGS:

Lungs - several pneumonyssus lesions.

Comment - localized hair loss top of head, neck, left arm and right leg; eyelashes thin and short; some loss of tactile hairs around mouth; carcass in good condition.

MICROSCOPIC FINDINGS:

Eyelids - meibomian glands: several dilated ducts and paraglandular cellular infiltration, slight.
Lips - focal lymphocytic infiltration of submucosal glands, slight.
Right lung - pneumonyssus lesion and parasite.
Left lung - pneumonyssus lesion.
Adrenal glands - focal calcification, slight.
Testes - diminished spermatogenesis, slight.
Femoral marrow - focal hemosiderin deposition, slight.

LITTON BIONETICS, INC.
PROJECT NO. 20771

INDIVIDUAL ANIMAL PATHOLOGY EVALUATION

ANIMAL NUMBER:	46-I	PM NUMBER:	78/1745
DOSAGE:	25 ug/kg	GROUP NUMBER:	3
DATE OF DEATH:	12/7/78	SPECIES:	Monkey - adult
DEATH:	Terminal kill	SEX:	Male
METHOD OF KILL:	Lethane		

GROSS FINDINGS:

Heart - several minute grayish-yellow specks in endocardium of left ventricle.
Lungs - thoracic duct cannula in place; pleural adhesions in area; several pneumonyssus lesions.

Comment - some hair loss legs and arms; scattered small wart-like elevations on groin areas and lower abdomen; slight calculus on teeth; carcass fat.

MICROSCOPIC FINDINGS:

Spinal cord - nerve fiber degeneration, minimal.
Pituitary gland - degenerative focus.
Adrenal glands - focal calcification, moderate.
Stomach - chronic gastritis, moderate.
Testes - diminished spermatogenesis, slight.
Wart-like lesions on skin - squamous papillomas.
Heart - no lesion recognized.
Lungs - no lesion recognized.

LITTON BIONETICS, INC.
PROJECT NO. 20771

INDIVIDUAL ANIMAL PATHOLOGY EVALUATION

ANIMAL NUMBER:	595-I	PM NUMBER:	78/1748
DOSAGE:	25 ug/kg	GROUP NUMBER:	3
DATE OF DEATH:	12/11/78	SPECIES:	Monkey - adult
DEATH:	Terminal kill	SEX:	Male
METHOD OF KILL:	Lethane		

GROSS FINDINGS:

Lungs - several pneumonyssus lesions.
Stomach - several 1 mm grayish foci, elevated, at junction of fundic and pyloric areas of stomach.
Skeletal muscle - slightly pale coloration of superficial portion of muscle connecting thorax and arm.
Kidneys - scar in outer cortex of distal portion of each kidney, 3 mm x 1 mm.

Comment - some hair loss, shoulders, arms and right thigh; toenails and some fingernails elevated from nailbed by cornified material; carcass in good condition.

MICROSCOPIC FINDINGS:

Eyelids - meibomian glands: several dilated ducts.
Lips - focal lymphocytic infiltration, submucosal glands, slight.
Thyroids - microfollicular foci, moderate.
Right lung - pneumonyssus lesions.
Left lung - pneumonyssus lesions.
Kidneys - pyelonephritic scars, slight.
Adrenal glands - focal calcification, slight.
Small intestine - mucosal hemorrhage, slight.
Prostate - focal inflammation, minimal.
Hip skin - subtotal atrophy, sebaceous glands.
Thigh skin - subtotal atrophy, sebaceous glands.
Mandible - subgingival epithelial microcyst.
Stomach - no lesion recognized.
Skeletal muscle - no lesion recognized.

MONS 016893

LITTON BIONETICS, INC.
PROJECT NO. 20771

INDIVIDUAL ANIMAL PATHOLOGY EVALUATION

ANIMAL NUMBER:	599-I	PM NUMBER:	78/1751
DOSAGE:	25 ug/kg	GROUP NUMBER:	3
DATE OF DEATH:	12/7/78	SPECIES:	Monkey - adult
DEATH:	Terminal kill	SEX:	Male
METHOD OF KILL:	Lethane		

GROSS FINDINGS:

Lungs - numerous pneumonyssus lesions.
Stomach - numerous minute grayish foci in fundus mucosa.
Kidneys - scar-like depression on convex edge of right kidney.

Comment - slight calculus on teeth; lips slightly swollen; carcass in good condition.

MICROSCOPIC FINDINGS:

Spinal cord - nerve fiber degeneration, minimal.
Eyelids - meibomian glands; paraglandular cellular infiltration, slight.
Lips - microulcer at margin.
Axillary lymph node - foreign body reaction, slight.
Parotid salivary gland - localized lobular atrophy, slight.
Right lung - congestion and edema; pneumonyssus lesions.
Left lung - congestion and edema.
Kidneys - pyelonephritic scars, slight.
Prostate - focal inflammation, slight.
Tibial nerve - nerve fiber degeneration, minimal.
Stomach - no lesion recognized.

MISSING TISSUES:

Parathyroid - not present in plane of section.

LITTON BIONETICS, INC.
PROJECT NO. 20771

INDIVIDUAL ANIMAL PATHOLOGY EVALUATION

ANIMAL NUMBER:	152-F	PM NUMBER:	78/1033
DOSAGE:	100 ug/kg	GROUP NUMBER:	4
DATE OF DEATH:	1/22/78	SPECIES:	Monkey - adult
DEATH:	Found dead	SEX:	Female
METHOD OF KILL:			

GROSS FINDINGS:

Brain - hemorrhages in dura.
Eyelids - hemorrhages in mucosa.
Lips - hemorrhages in mucosa.
Heart - hemorrhages in epicardium.
Lungs - trachea and bronchi contain clear gelatinous exudate; multiple pleural adhesions; possible infarcts in one diaphragmatic lobe and pulmonary lymph node.
Stomach - possible infarction in gastrointestinal tract, area not specified.
Duodenum - possible infarction in gastrointestinal tract, area not specified.
Jejunum - possible infarction in gastrointestinal tract, area not specified.
Ileum - intussusception; possible infarction in gastrointestinal tract, area not specified.
Colon - possible infarction in gastrointestinal tract, area not specified.
Kidneys - firm (not a lesion).
Ovaries - corpus luteum in one ovary (not a lesion).
Bone marrow - abundant red marrow (not a lesion).
Peritoneal cavity - contained approximately 25-50 ml straw-colored fluid.

Comment - thin haircoat; marked edema of eyelids and lips.

MICROSCOPIC FINDINGS:

Cerebrum - meningeal hemorrhage, moderate.
Cerebellum - meningeal hemorrhage, moderate.
Mid brain - meningeal hemorrhage, moderate.
Eyelids - focal necrosis and hemorrhage; meibomian glands: atrophy, sebaceous elements; squamous impaction, ducts; mucinous metaplasia, ducts; paraglandular cellular infiltration, moderate.
Lips - atrophy, sebaceous glands; mucosal ulcer.

MICROSCOPIC FINDINGS (Continued):

Tongue - squamous metaplasia, glandular ducts.
Axillary lymph node - necrosis and intranuclear inclusions (viral); hemorrhage, slight; hemosiderin deposition, moderate.
Right lung - localized consolidation and intranuclear inclusions (viral).
Left lung - localized consolidation and intranuclear inclusions (viral).
Heart - epicardial hemorrhage, moderate; myocardial hemorrhage, moderate; endocardial hemorrhage; moderate.
Liver - focal hemosiderin deposition, marked.
Spleen - focal necrosis and intranuclear inclusions (viral).
Pancreas - focal necrosis and intranuclear inclusions (viral).
Adrenal glands - cortical hemorrhage, moderate.
Urinary bladder - subperitoneal hemorrhage, moderate.
Stomach - submucosal edema, moderate.
Small intestine - localized mucosal necrosis and intranuclear inclusions (viral); diffuse hemorrhage, marked.
Large intestine - localized mucosal necrosis and intranuclear inclusions (viral).
Mesenteric lymph node - hemorrhage, marked; hemosiderin deposition, slight.
Uterus - endometrial necrosis and intranuclear inclusions (viral).
Cervix - necrosis and intranuclear inclusions (viral).
Left nipple - squames in deep mammary duct.
Femoral marrow - focal hemosiderin deposition, marked; decreased granulocyte maturation.
Sternum - decreased cellularity; focal hemosiderin deposition, moderate; decreased granulocyte maturation.
Bone marrow smear (femur) - decreased granulocyte maturation.
Bronchial lymph node - necrosis and intranuclear inclusions (viral).
Thoracic skin - squamous cysts; atrophy, sebaceous glands.
Kidneys - no lesion recognized.
Ovaries - no lesion recognized.
Cause of death - systemic herpesvirus infection.

MISSING TISSUES:

Spinal cord - lost in processing.
Parotid salivary gland - lost in processing.
Extrahepatic bile duct - lost in processing.
Gallbladder - autolysis too severe for microscopic interpretation.
Tibial nerve - lost in processing.
Hip skin - lost in processing.
Thigh skin - lost in processing.
Labium - lost in processing.

MONS 016896

LITTON BIONETICS, INC.
PROJECT NO. 20771

INDIVIDUAL ANIMAL PATHOLOGY EVALUATION

ANIMAL NUMBER:	338-I	PM NUMBER:	78/1517
DOSAGE:	100 ug/kg	GROUP NUMBER:	4
DATE OF DEATH:	8/21/78	SPECIES:	Monkey - adult
DEATH:	Moribund kill	SEX:	Female
METHOD OF KILL:	Lethane		

GROSS FINDINGS:

Eyelids - somewhat swollen; many eyelashes missing.
Lips - two reddened eroded areas on inner surface of lower lip.
Heart - serous atrophy of epicardial fat; myocardial scar, small, at apex.
Lungs and trachea - numerous pneumonyssus lesions; ingesta in bronchi.
Liver - pale, firm; bile duct greatly distended; intrahepatic ducts distended; bile pale green in color and mucoid in consistency.
Gallbladder - shrunken, opaque, wall thickened.
Pancreas - pale.
Colon - numerous adhesions in area of cecum.
Bone marrow (femur) - fatty, but fat had serous atrophy.
Left thigh skin - some loss of hair and excess scurf.
Left hip skin - some loss of hair and excess scurf.
Muscle - much hemorrhage in thigh muscle at site of needle puncture.
Lesions - a few petechial hemorrhages beneath peritoneum.

Comment - emaciated carcass with considerable generalized hair loss and excess scurf; fingernails elevated by accummulation of cornified material underneath (between nail and nailbed).

MICROSCOPIC FINDINGS:

Eyelids - meibomian glands: atrophy of sebaceous elements; squamous impaction, ducts; mucinous metaplasia, ducts; paraglandular cellular infiltration, slight.
Lips - atrophy, sebaceous glands; mucocutaneous ulcer.
Axillary lymph node - hemorrhage, slight; erythrophagocytosis, slight.
Right lung - pneumonyssus lesions and parasites; congestion and edema.
Left lung - pneumonyssus lesions and parasites; congestion and edema.

MONS 016897

MICROSCOPIC FINDINGS (Continued):

Liver - focal necrosis, marked; abscess formation, moderate; periportal inflammation, marked; intrahepatic bile ducts (second order): epithelial hyperplasia, marked; ectasia, moderate; mucoid content.
Extrahepatic bile duct - mucosal hyperplasia, marked; mucoid content.
Gallbladder - mucosal hyperplasia, marked; mucoid content; collapsed lumen.
Pancreas - main duct: epithelial hyperplasia, marked; mucoid content.
Adrenal glands - cortical hemorrhage, slight; medullary hemorrhage, slight.
Mesenteric lymph node - hemorrhage, slight.
Hip skin - atrophy, sebaceous glands; hyperkeratosis, slight.
Thigh skin - atrophy, sebaceous glands; hyperkeratosis, slight.
Femoral marrow - hemorrhage, marked; decreased granulocyte maturation.
Sternum - decreased cellularity; decreased granulocyte maturation.
Bone marrow smear (femur) - decreased granulocyte maturation.
Mandible - subgingival epithelial cysts.
Peritoneum - subperitoneal hemorrhage, minimal; localized fibrinocellular exudate (surface), minimal.
Heart - no lesion recognized.
Colon - no lesion recognized.
Muscle - no lesion recognized.
Trachea - no lesion recognized.
Cause of moribund condition - biliary tract lesions (P.C.B.).

MISSING TISSUES:

Thymus - not present in plane of section.
Tibial nerve - lost in processing.
Left nipple - lost in processing.
Labium - lost in processing.

LITTON BIONETICS, INC.
PROJECT NO. 20771

INDIVIDUAL ANIMAL PATHOLOGY EVALUATION

ANIMAL NUMBER:	486-H	PM NUMBER:	78/1181
DOSAGE:	100 ug/kg	GROUP NUMBER:	4
DATE OF DEATH:	3/22/78	SPECIES:	Monkey - Adult
DEATH:	Moribund kill	SEX:	Female
METHOD OF KILL:	Somlethol®		

GROSS FINDINGS:

Brain - meningeal hemorrhage, right cerebral hemisphere.
Eyelids - hemorrhage.
Lips - hemorrhage.
Heart - epicardial and endocardial hemorrhage, right and left ventricles.
Lungs - pale pink edematous bronchi filled with clear fluid.
Liver - pale
Gallbladder - pale.
Spleen - pale.
Duodenum - multifocal mucosal hemorrhage or ulceration.
Jejunum - multifocal mucosal hemorrhage or ulceration.
Ileum - multifocal mucosal hemorrhage or ulceration.
Pancreas - pale.
Kidneys - pale.
Adrenal glands - pale.
Vagina - thick rough mucosa.
Biopsy incision - necrotic skin at site of biopsies.
Oral mucosa (cheek pouch) - hemorrhage.
Inguinal area - hemorrhage, subcutaneous.
Skin lesions - hemorrhage, subcutaneous.

Comment - multiple skin and subcutaneous hemorrhages, random sites, eyelids, cheek pouches, lips, back, arms and legs; necrotic skin at site of biopsies.

MICROSOPIC FINDINGS:

Cerebrum - meningeal hemorrhage, slight.
Cerebellum - focus of malacia, pons.
Mid brain - microglial focus.
Eyelids - meibomian glands: subtotal atrophy, sebaceous elements; squamous metaplasia, sebaceous elements; squamous impaction, ducts; mucinous metaplasia, ducts; paraglandular cellular infiltration, moderate; subepidermal hemorrhage, moderate.
Lips - subtotal atrophy, sebaceous glands; abscess at muco-cutaneous junction; focal hemorrhage, slight; squamous metaplasia, glandular duct.

MONS 016899

MICROSCOPIC FINDINGS (Continued):

Axillary lymph node - hemorrhage, slight; erythrophagocytosis, slight; hemosiderin deposition, slight; foreign body reaction, moderate; extracapsular necrotic focus; extracapsular hemorrhage, marked.
Right lung - hemorrhage; edema; pneumonyssus lesions and parasites.
Left lung - hemorrhage; edema; pneumonyssus lesions and parasites.
Heart - epicardial hemorrhage, moderate; myocardial hemorrhage, moderate; endocardial hemorrhage, moderate.
Urinary bladder - submucosal hemorrhage, moderate; mural hemorrhage, slight.
Stomach - focal mucosal hemorrhage, slight; submucosal hemorrhage, cardiac orifice, moderate.
Small intestine - focal mucosal and submucosal hemorrhage, slight; thrombi in lacteals.
Large intestine - mucosal hemorrhage, slight; hemorrhage at mesenteric attachment, slight.
Mesenteric lymph node - hemorrhage, minimal; hemosiderin deposition, minimal.
Uterus - endometrial hemorrhages, marked.
Hip skin - subtotal atrophy, sebaceous glands.
Thigh skin - subtotal atrophy, sebaceous glands.
Femoral marrow - fatty marrow; focal hemosiderin deposition, slight.
Sternum - decreased cellularity; decreased granulocyte maturation; focal hemosiderin deposition, moderate.
Cheek pouch (oral mucosa) - circumscribed hemorrhage, mucosa and submucosa.
Biopsy incision - indolent ulcer.
Skin lesion - localized hemorrhage, necrosis and inflammation.
Liver - no lesion recognized.
Gallbladder - no lesion recognized.
Spleen - no lesion recognized.
Pancreas - no lesion recognized.
Kidneys - no lesion recognized.
Adrenal glands - no lesion recognized.
Vagina - no lesion recognized.
Inguinal area - subcutaneous hemorrhage, moderate.
Cause of moribund condition - anemia (P.C.B.).

MISSING TISSUES:

Thymus - not present in plane of section.
Tibial nerve - lost in processing.
Left nipple - lost in processing.
Labium - lost in processing.
Bone marrow smear (femur) - lost in processing.

LITTON BIONETICS, INC.
PROJECT NO. 20771

INDIVIDUAL ANIMAL PATHOLOGY EVALUATION

ANIMAL NUMBER:	770-I	PM NUMBER:	78/1194
DOSAGE:	100 ug/kg	GROUP NUMBER:	4
DATE OF DEATH:	4/2/78	SPECIES:	Monkey - adult
DEATH:	Spontaneous death	SEX:	Female
METHOD OF KILL:			

GROSS FINDINGS:

Brain - meningeal hemorrhage in left hemisphere and at base of brain.
Heart - diffuse petechial hemorrhage on apical epicardium.
Lungs - some pleural adhesions.
Liver - cut surface pale.
Cecum and colon - cecum dilated and filled with dark reddish-brown semifluid material; contents of colon and rectum dark black and "tar"-like.
Kidneys - cut surface pale.

Comment - cecum and colon contents for occult blood test; carcass emaciated; haircoat thin; 3 cm abdominal scar; approximately 1.5 cc yellowish-brown fluid in peritoneal cavity.

MICROSCOPIC FINDINGS:

Cerebrum - meningeal hemorrhage, moderate.
Mid brain - meningeal hemorrhage, moderate.
Spinal cord - focus of hemorrhage and microglial reaction.
Pituitary gland - hemorrhage (pars nervosa), moderate.
Eyelids - meibomian glands: atrophy, sebaceous elements; squamous impaction, ducts.
Lips - atrophy, sebaceous glands.
Axillary lymph node - hemorrhage, moderate; erythrophagocytosis, moderate.
Esophagus - candidiasis.
Right lung - pneumonyssus lesions; hemorrhage.
Left lung - pneumonyssus lesions, hemorrhage.
Heart - epicardial hemorrhage, moderate; myocardial hemorrhage, moderate; endocardial hemorrhage, moderate.
Liver - focal necrosis, slight.
Pancreas - localized lobular atrophy, slight.
Kidneys - hemorrhage, renal papilla, moderate.
Adrenal glands - cortical hemorrhage, marked.

MONS 016901

MICROSCOPIC FINDINGS (Continued):

Stomach - hydropic degeneration, cardiac orifice epithelium.
Small intestine - focal mucosal hemorrhage, slight; focal peritoneal hemorrhage, slight.
Large intestine - cecum: chronic ulcers; mucosal hemorrhage, slight; submucosal hemorrhage, slight; colon: mucosal hemorrhage, slight.
Mesenteric lymph node - hemorrhage, moderate; hemosiderin deposition, slight.
Uterus - endometrial hemorrhage, slight.
Hip skin - atrophy, sebaceous glands.
Thigh skin - atrophy, sebaceous glands.
Femoral marrow - fatty marrow; hemorrhage, marked.
Sternum - decreased granulocyte maturation.
Lumbar lymph nodes - hemorrhage, marked; hemosiderin deposition, moderate.
Abdominal incision - scar tissue; small suture abscess.
Cecum and colon contents - occult blood (present outside established reference range), severe.
Nodular abdominal lesion, site unspecified - circumscribed fat necrosis, slight.
Cause of death - intestinal bleeding.

MISSING TISSUES:

Parotid salivary gland - lost in processing.
Thymus - not present in plane of section.
Sciatic nerve - lost in processing.
Tibial nerve - lost in processing.
Left nipple - lost in processing.
Labium - lost in processing.
Bone marrow smear (femur) - lost in processing.

MONS 016902

LITTON BIONETICS, INC.
PROJECT NO. 20771

INDIVIDUAL ANIMAL PATHOLOGY EVALUATION

ANIMAL NUMBER:	226-F	PM NUMBER:	78/1715
DOSAGE:	100 ug/kg	GROUP NUMBER:	4
DATE OF DEATH:	12/5/78	SPECIES:	Monkey - adult
DEATH:	Terminal kill	SEX:	Female
METHOD OF KILL:	Lethane		

GROSS FINDINGS:

Brain - periosteum at base of brain had brownish discoloration.
Eyelids - diminution of number and prominence of yellowish streaks beneath conjunctiva (those perpendicular to margins of lids).
Lips - tactile hairs missing.
Heart - circumscribed grayish pale areas at base of right ventricle and on right auricle; slight nodular thickening at border of bicuspid valve.
Lungs - adhesions and several pneumonyssus lesions.
Stomach - several small whitish nodular elevations, 1-2 mm, in mucosa.
Liver - surface slightly rough; several small cyst-like, 2-4 mm, lesions visible through capsule, dark bluish-green.
Gallbladder - sandy, dark material in bile, greenish-brown.
Ovaries - cyst on each ovary, 2-3 mm.
Vagina - corrugated; mucosa thick.
Skin of neck - nodule; also scurfy.

Comment - carcass thin; teeth discolored with black scale, unscaled portions had brownish discoloration, light; gums receding and bleeding; hair loss general but severe on lower back and thighs; skin generally scurfy, most severe at hairless areas; accumulation of keratin between nails and nailbeds; scattered grayish nodules, 0.5 mm to greater than 0.1 mm diameter, in skin, when incised, cheesy material was expressed; tactile hairs missing from lips; eyelashes missing; eyelids swollen slightly (?).

MICROSCOPIC FINDINGS:

Eyelids - meibomian glands: atrophy, sebaceous elements; squamous impaction, ducts; mucinous metaplasia, ducts; paraglandular cellular infiltration, moderate.
Lips - atrophy, sebaceous glands.

MONS 016903

MICROSCOPIC FINDINGS (Continued):

Right lung - pneumonyssus lesions.
Left lung - pneumonyssus lesions.
Liver - congenital cysts; focal hemosiderin deposition, slight.
Gallbladder - microconcretion.
Kidneys - focal glomerulosclerosis, slight; cortical microcysts, slight.
Ovaries - cyst.
Left nipple - squamous cyst, skin; squames in deep mammary duct.
Hip skin - atrophy, sebaceous glands.
Thigh skin - atrophy, sebaceous glands.
Femoral marrow - focal hemosiderin deposition, moderate.
Bone marrow smear (femur) - decreased granulocyte maturation.
Mandible - marginal gingivitis, moderate.
Skin lesions - follicular keratosis.
Brain - no lesion recognized.
Heart - no lesion recognized.
Stomach - no lesion recognized.
Vagina - no lesion recognized.

MONS 016904

LITTON BIONETICS, INC.
PROJECT NO. 20771

INDIVIDUAL ANIMAL PATHOLOGY EVALUATION

ANIMAL NUMBER:	269-I	PM NUMBER:	78/1719
DOSAGE:	100 ug/kg	GROUP NUMBER:	4
DATE OF DEATH:	12/6/78	SPECIES:	Monkey - adult
DEATH:	Terminal kill	SEX:	Female
METHOD OF KILL:	Lethane		

GROSS FINDINGS:

Eyelids - irregularity in length and diameter of meibomian glands, as seen through mucosa.
Stomach - several, 1-2 mm, slightly elevated graysish spots in gastric mucosa.
Vagina - rough mucosa.

Comment - eyelids thick at borders; partial loss of eyelashes, eyelashes short; small accessory nipple on right side.

MICROSCOPIC FINDINGS:

Eyelids - meibomian glands: atrophy of sebaceous elements; dilated ducts; squamous impaction, ducts; mucinous metaplasia, ducts; paraglandular cellular infiltration, moderate.
Lips - subtotal atrophy, sebaceous glands.
Parotid salivary gland - localized lobular atrophy, minimal.
Right lung - pneumonyssus lesions and parasite.
Left lung - pneumonyssus lesions and parasite.
Adrenal glands - focal calcification, slight.
Thigh skin - subtotal atrophy, sebaceous glands.
Stomach - no lesion recognized.
Vagina - no lesion recognized.

MONS 016905

LITTON BIONETICS, INC.
PROJECT NO. 20771

INDIVIDUAL ANIMAL PATHOLOGY EVALUATION

ANIMAL NUMBER:	287-I	PM NUMBER:	78/1723
DOSAGE:	100 ug/kg	GROUP NUMBER:	4
DATE OF DEATH:	12/6/78	SPECIES:	Monkey - adult
DEATH:	Terminal kill	SEX:	Female
METHOD OF KILL:	Lethane		

GROSS FINDINGS:

Eyelids - several meibomian glands appeared distended, as seen through mucosa.
Vagina - mucosa rough.

Comment - thin haircoat; partial hair loss arms, inner thighs and lower back; partial loss of eyelashes, remaining eyelashes short; moderate calculus on teeth; carcass in fair condition; eyelids slightly thickened at borders.

MICROSCOPIC FINDINGS:

Eyelids - meibomian glands: subtotal atrophy, sebaceous elements: squamous impaction, ducts; mucinous metaplasia, ducts; paraglandular cellular infiltration, slight.
Lips - subtotal atrophy, sebaceous glands.
Tongue - squamous metaplasia, glandular duct.
Submaxillary salivary gland - syncytial cells in ducts.
Right lung - pneumonyssus lesions.
Left lung - pneumonyssus lesions and parasite.
Ovaries - cystic rete ovarii.
Hip skin - atrophy, sebaceous glands.
Thigh skin - atrophy, sebaceous glands.
Mandible - marginal gingivitis, minimal.
Vagina - no lesion recognized.

MONS 016906

LITTON BIONETICS, INC.
PROJECT NO. 20771

INDIVIDUAL ANIMAL PATHOLOGY EVALUATION

ANIMAL NUMBER:	312-I	PM NUMBER:	78/1727
DOSAGE:	100 ug/kg	GROUP NUMBER:	4
DATE OF DEATH:	12/7/78	SPECIES:	Monkey - adult
DEATH:	Terminal kill	SEX:	Female
METHOD OF KILL:	Lethane		

GROSS FINDINGS:

Lungs - several pneumonyssus lesions.
Stomach - several vague whitish, 1-2 mm, spots in fundus mucosa of stomach.

Comment - lips swollen (?); sparse haircoat left arm and shoulder; several toenails and fingernails broken; sparse haircoat on hips and legs; a few eyelashes missing, others short; carcass in good condition.

MICROSCOPIC FINDINGS:

Eyelids - meibomian glands: atrophy, sebaceous elements; dilated ducts; squamous impaction, ducts; mucinous metaplasia, ducts; paraductal cellular infiltration, moderate.
Lips - subtotal atrophy of sebaceous glands; focal lymphocytic infiltration, submucosal glands, moderate.
Right lung - pneumonyssus lesions.
Left lung - pneumonyssus lesions and parasites.
Hip skin - subtotal atrophy, sebaceous glands.
Thigh skin - subtotal atrophy, sebaceous glands.
Stomach - no lesion recognized.

MONS 016907

LITTON BIONETICS, INC.
PROJECT NO. 20771

INDIVIDUAL ANIMAL PATHOLOGY EVALUATION

ANIMAL NUMBER:	425-J	PM NUMBER:	78/1735
DOSAGE:	100 ug/kg	GROUP NUMBER:	4
DATE OF DEATH:	12/8/78	SPECIES:	Monkey - adult
DEATH:	Terminal kill	SEX:	Male
METHOD OF KILL:	Lethane		

GROSS FINDINGS:
Lungs - several pneumonyssus lesions.

Comment - some hair loss, arms and legs; slight calculus on teeth; eyelashes short; lips slightly swollen; ulcer (shallow) on pubic skin; toenails elevated from nailbed by cornified material; carcass in good condition.

MICROSCOPIC FINDINGS:
Spinal cord - nerve fiber degeneration, minimal.
Eyelids - meibomian glands: dilated ducts; paraglandular cellular infiltration, slight.
Lips - submucosal glands: dilated ducts; focal lymphocytic infiltration, slight.
Thyroids - focal squamous metaplasia, minimal; focal lymphocytic infiltration, slight.
Right lung - pneumonyssus lesions; congestion and edema.
Left lung - congestion and edema.
Adrenal glands - focal calcification, slight.
Hip skin - atrophy, sebaceous glands; microgranuloma.
Thigh skin - subtotal atrophy, sebaceous glands.
Mandible - subgingival epithelial microcyst.

MISSING TISSUES:
Pubic skin - lost in processing.

MONS 016908

LITTON BIONETICS, INC.
PROJECT NO. 20771

INDIVIDUAL ANIMAL PATHOLOGY EVALUATION

ANIMAL NUMBER:	427-J	PM NUMBER:	78/1739
DOSAGE:	100 ug/kg	GROUP NUMBER:	4
DATE OF DEATH:	Terminal kill	SPECIES:	Monkey - adult
DEATH:	12/7/78	SEX:	Male
METHOD OF KILL:	Lethane		

GROSS FINDINGS:

Lungs - several pneumonyssus lesions.

Comment - several toenails raised from nailbed by dense cornified material; slight calculus on teeth; lips slightly swollen; carcass in good condition.

MICROSCOPIC FINDINGS:

Spinal cord - nerve fiber degeneration, minimal.
Eyelids - meibomian glands; dilated ducts.
Right lung - pneumonyssus lesions.
Left lung - pneumonyssus lesions and parasite.
Adrenal glands - focal calcification, slight.
Stomach - chronic gastritis, slight.
Lips - no lesion recognized.

MONS 016909

LITTON BIONETICS, INC.
PROJECT NO. 20771

INDIVIDUAL ANIMAL PATHOLOGY EVALUATION

ANIMAL NUMBER:	600-I	PM NUMBER:	78/1731
DOSAGE:	100 ug/kg	GROUP NUMBER:	4
DATE OF DEATH:	12/5/78	SPECIES:	Monkey - adult
DEATH:	Terminal kill	SEX:	Male
METHOD OF KILL:	Lethane		

GROSS FINDINGS:

Eyelids - diminution and irregular contours of yellowish streaks beneath conjunctiva perpendicular to lid margins.
Lips - tactile hairs around lips missing; lips appeared somewhat swollen; 3 mm red erosion on inner surface of upper lip.
Heart - gray, cloudy area on surface of each ventricle.
Lungs - thoracic duct cannula in place on right side (plastic tubing); several pneumonyssus lesions.
Stomach - several small, round, 1 mm, elevations in fundus mucosa.
Liver - appears swollen; dark, vague, irregular variation in coloration.
Lesions - tail-head skin and skin from midline.

Comment - general partial hair loss, haircoat irregularly thin; skin slightly scurfy; several small whitish nodules, 1 mm or less, in skin of abdomen at midline; skin at tail-head greatly thickened, corrugated and scaly; eyelids swollen somewhat and slightly reddened, eyelashes missing; moderate calculus on teeth.

MICROSCOPIC FINDINGS:

Eyelids - meibomian glands: atrophy, sebaceous elements; squamous impaction, ducts; mucinous metaplasia, ducts; paraglandular cellular infiltration, moderate.
Lips - focal mucosal erosion; subtotal atrophy, sebaceous glands.
Right lung - pneumonyssus lesions and parasites.
Left lung - pneumonyssus lesions.
Mesenteric lymph node - hemorrhage, slight.
Prostate - acinar atrophy and dilation, moderate.
Hip skin - subtotal atrophy, sebaceous glands.
Thigh skin - subtotal atrophy, sebaceous glands.
Midline abdominal skin - subtotal atrophy, sebaceous glands.
Tail-head skin - follicular keratosis; atrophy, sebaceous glands.
Heart - no lesion recognized.
Stomach - no lesion recognized.
Liver - no lesion recognized.

MONS 016910

LITTON BIONETICS, INC.
PROJECT NO. 20771

INDIVIDUAL ANIMAL PATHOLOGY EVALUATION

ANIMAL NUMBER:	706-E	PM NUMBER:	78/1459
DOSAGE:	100 ug/kg	GROUP NUMBER:	4
DATE OF DEATH:	7/19/78	SPECIES:	Monkey - Adult
DEATH:	Moribund kill	SEX:	Male
METHOD OF KILL:	Somlethol®		

GROSS FINDINGS:

Eyelids - swollen; eyelashes missing.
Lips - swollen; a 2 cm area of upper lip beneath left nostril was dark, necrotic in appearance and had superficial ulceration.
Heart - pericardium adherent to epicardium at apex; several fibrous "tags" on epicardium, also several 1 mm whitish firm nodules.
Lungs - bronchi contained frothy fluid; lungs reddened, heavy, and edematous on cut surface.
Stomach - petechial in mucosa.
Bone marrow (femur) - mostly fatty, but small amount of pale pink gelatinous material at epiphyseal areas.
Left hip skin - pale and much hair loss.
Left thigh skin - pale and much hair loss.
Bone marrow smears - difficult to make because of gelatinous consistency.

Comment - Carcass very pale and anemic in appearance; approximately 90% loss of hair; skin and visible mucosa white; eyebrows, neck and shoulders covered with a macular eruption (small red spots, some confluent and some crusted with scale); toenails absent; fingernails either absent or broken and elevated from nailbed by scale; necrosis of gum tissue in area of lip necrosis; left incisor teeth loose; mucosa of right cheek pouch necrotic; total absence of depot fat.

MICROSCOPIC FINDINGS:

Eyelids - meibomian glands; atrophy of sebaceous elements; squamous impaction, ducts; mucinous metaplasia, ducts; paraglandular cellular infiltration, moderate.
Lips - gangrenous stomatitis; subtotal atrophy, sebaceous glands; squamous metaplasia, sebaceous glands.
Tongue - mucosal epithelium; focal hydropic degeneration; intranuclear inclusions (viral).
Axillary lymph node - erythrophagocytosis, moderate; hemosiderin deposition, moderate.

MONS 016911

MICROSCOPIC FINDINGS (Continued):

Parotid salivary gland - cytoplasmic vacuolation of acinar cells, moderate.
Right lung - congestion, edema.
Left lung - congestion, edema.
Heart - squamous metaplasia, epicardium.
Adrenal glands - cortical hemorrhage, slight.
Stomach - focal mucosal hemorrhage, slight; hydropic degeneration, cardiac orifice epithelium.
Mesenteric lymph node - hemosiderin deposition, slight.
Hip skin - atrophy of sebaceous glands; follicular keratosis.
Thigh skin - atrophy of sebaceous glands; follicular keratosis; squamous cyst.
Femoral marrow - hemorrhage, moderate; focal hemosiderin deposition, marked.
Sternum - decreased cellularity; hemorrhage, slight; focal hemosiderin deposition, slight.
Bone marrow smear (femur) - decreased granulocyte maturation, excess lymphoid elements.
Mandible - localized necrosis, periosteum.
Cheek pouch - gangrenous stomatitis; mucosal epithelium: hydropic degeneration; intranuclear inclusions (viral).
Plantar lesions - epidermal callosities.
Biopsy incision - indolent ulcer.
Skin from macular eruption - squamous cyst; follicular keratosis; atrophy, sebaceous glands.
Small intestine - thrombi in lacteals.
Cause of moribund condition - gangrenous stomatitis.

MISSING TISSUES:

Spinal cord - lost in processing.
Thymus - lost in processing.
Extrahepatic bile duct - lost in processing.
Prostate - lost in processing.
Tibial nerve - lost in processing.
Left nipple - lost in processing.
Foreskin - lost in processing.

MONS 016912

LITTON BIONETICS, INC.
PROJECT NO. 20771

INDIVIDUAL ANIMAL PATHOLOGY EVALUATION

ANIMAL NUMBER:	B-8483	PM NUMBER:	78/1189
DOSAGE:	0 ug/kg	GROUP NUMBER:	1
DATE OF DEATH:	3/29/78	SPECIES:	Monkey - infant
DEATH:	Fetal wastage	SEX:	Female
METHOD OF KILL:			

GROSS FINDINGS:
Placental disks - hemorrhage in smaller disc.

MICROSCOPIC FINDINGS:
Right lung - fetal atelectasis.
Left lung - fetal atelectasis.
Liver - congestion.
Spleen - congestion.
Kidneys - congestion; hemorrhage, moderate.
Adrenal glands - congestion; cortical hemorrhage, moderate.
Placental disks - clotted blood on detached surfaces.

MISSING TISSUES:
Cerebrum - not examined microscopically.
Cerebellum - not examined microscopically.
Mid brain - not examined microscopically.
Spinal cord - not harvested.
Pituitary gland - not harvested.
Eyelids - not harvested.
Lips - not harvested.
Tongue - not harvested.
Axillary lymph node - not harvested.
Parotid salivary gland - not harvested
Submaxillary salivary gland - not harvested
Esophagus - not harvested.
Thyroids and Parathyroids - not harvested.
Extrahepatic bile duct - not harvested.
Gallbladder - not examined microscopically.
Urinary bladder - not harvested.
Stomach - not examined microscopically.
Small intestine - not examined microscopically.
Large intestine - not examined microscopically.

MONS 016913

MISSING TISSUES (Continued):
Mesenteric lymph node - not harvested.
Ovaries - not harvested.
Uterus - not harvested.
Cervix - not harvested.
Vagina - not harvested.
Sciatic nerve - not harvested.
Tibial nerve - not harvested.
Left nipple - not harvested.
Hip skin - not harvested.
Thigh skin - not harvested.
Labium - not harvested.
Femoral marrow - not harvested.
Sternum - not harvested.
Bone marrow smear (femur) - not harvested.
Mandible - not harvested.

LITTON BIONETICS, INC.
PROJECT NO. 20771

INDIVIDUAL ANIMAL PATHOLOGY EVALUATION

ANIMAL NUMBER:	B-8532	PM NUMBER:	78/1335
DOSAGE:	0 ug/kg	GROUP NUMBER:	1
DATE OF DEATH:	6/26/78	SPECIES:	Monkey - infant
DEATH:	Terminal kill	SEX:	Female
METHOD OF KILL:	Lethane		

GROSS FINDINGS:
No gross lesion recognized.

MICROSCOPIC FINDINGS:
Axillary lymph node - hemorrhage, moderate; erythrophagocytosis, moderate.
Liver - periportal infiltration, slight.

MISSING TISSUES:
Spinal cord - lost in processing.
Extrahepatic bile duct - lost in processing.
Tibial nerve - lost in processing.
Left nipple - lost in processing.
Labium - lost in processing.

MONS 016915

LITTON BIONETICS, INC.
PROJECT NO. 20771

INDIVIDUAL ANIMAL PATHOLOGY EVALUATION

ANIMAL NUMBER:	B-8533	PM NUMBER:	78/1336
DOSAGE:	0 ug/kg	GROUP NUMBER:	1
DATE OF DEATH:	6/26/78	SPECIES:	Monkey - infant
DEATH:	Terminal kill	SEX:	Female
METHOD OF KILL:	Lethane		

GROSS FINDINGS:
No gross lesion recognized.

MICROSCOPIC FINDINGS:
Eyelids - conjunctivitis, moderate.
Lips - submucosal glands, lymphocytic infiltration, slight, focus of inflammation with intranuclear inclusions (viral).
Large intestine - hemorrhage at ileocecal valve, moderate.
Vagina - lymphocytic infiltration, mucosa and submucosa, moderate.

MISSING TISSUES:
Extrahepatic bile duct - lost in processing.
Tibial nerve - lost in processing.
Left nipple - lost in processing.
Labium - lost in processing.

MONS 016916

LITTON BIONETICS, INC.
PROJECT NO. 20771

INDIVIDUAL ANIMAL PATHOLOGY EVALUATION

ANIMAL NUMBER:	B-8621	PM NUMBER:	78/1500
DOSAGE:	0 ug/kg	GROUP NUMBER:	1
DATE OF DEATH:	8/8/78	SPECIES:	Monkey - infant
DEATH:	Terminal kill	SEX:	Female
METHOD OF KILL:	Lethane		

GROSS FINDINGS:
No gross lesion recognized.

MICROSCOPIC FINDINGS:
Axillary lymph node - hemorrhage, slight.
Liver - hemosiderin deposition, moderate.

MISSING TISSUES:
Thyroids and parathyroids - lost in processing.
Extrahepatic bile duct - lost in processing.
Tibial nerve - lost in processing.
Left nipple - lost in processing.
Labium - lost in processing.

MONS 016917

LITTON BIONETICS, INC.
PROJECT NO. 20771

INDIVIDUAL ANIMAL PATHOLOGY EVALUATION

ANIMAL NUMBER:	B-8574	PM NUMBER:	78/1451
DOSAGE:	0 ug/kg	GROUP NUMBER:	1
DATE OF DEATH:	7/14/78	SPECIES:	Monkey - infant
DEATH:	Terminal kill	SEX:	Male
METHOD OF KILL:	Lethane		

GROSS FINDINGS:
No gross lesion recognized.

MICROSCOPIC FINDINGS:
Right lung - congestion and edema.
Left lung - congestion and edema.
Large intestine - hemorrhage, ileocecal valve, marked.

MISSING TISSUES:
Extrahepatic bile duct - lost in processing.
Prostate - lost in processing.
Tibial nerve - lost in processing.
Left nipple - lost in processing.
Foreskin - lost in processing.

MONS 016918

LITTON BIONETICS, INC.
PROJECT NO. 20771

INDIVIDUAL ANIMAL PATHOLOGY EVALUATION

ANIMAL NUMBER:	B-8557	PM NUMBER:	78/1419
DOSAGE:	0 ug/kg	GROUP NUMBER:	1
DATE OF DEATH:	7/6/78	SPECIES:	Monkey - infant
DEATH:	Terminal kill	SEX:	Male
METHOD OF KILL:	Lethane		

GROSS FINDINGS:
No gross lesion recognized.

Comment - carcass in good condition.

MICROSCOPIC FINDINGS:
Liver - reactive foci, slight.

MISSING TISSUES:
Extrahepatic bile duct - lost in processing.
Prostate - lost in processing.
Tibial nerve - lost in processing.
Left nipple - lost in processing.
Foreskin - lost in processing.

MONS 016919

LITTON BIONETICS, INC.
PROJECT NO. 20771

INDIVIDUAL ANIMAL PATHOLOGY EVALUATION

ANIMAL NUMBER:	B-8518	PM NUMBER:	78/1320
DOSAGE:	0 ug/kg	GROUP NUMBER:	1
DATE OF DEATH:	6/19/78	SPECIES:	Monkey - infant
DEATH:	Terminal kill	SEX:	Male
METHOD OF KILL:	Lethane		

GROSS FINDINGS:

Comment - two apparent suture scars, one on each side of lower abdomen, specimens preserved.

MICROSCOPIC FINDINGS:
Adrenal glands - focal calcification, moderate.

MISSING TISSUES:
Suture scars - not examined microscopically.
Extrahepatic bile duct - lost in processing.
Prostate - lost in processing.
Tibial nerve - lost in processing.
Left nipple - lost in processing.
Foreskin - lost in processing.
Bone marrow smear (femur) - lost in processing.

LITTON BIONETICS, INC.
PROJECT NO. 20771

INDIVIDUAL ANIMAL PATHOLOGY EVALUATION

ANIMAL NUMBER:	B-8527	PM NUMBER:	78/1325
DOSAGE:	5 ug/kg	GROUP NUMBER:	2
DATE OF DEATH:	6/23/78	SPECIES:	Monkey - infant
DEATH:	Terminal kill	SEX:	Female
METHOD OF KILL:	Lethane		

GROSS FINDINGS:
No gross lesion recognized.

Comment - bone marrow smears from humerus and femur.

MICROSCOPIC FINDINGS:
Axillary lymph node - hemorrhage, moderate.
Liver - reactive foci, moderate.
Large intestine - hemorrhage, ileocecal valve, moderate.
Bone marrow smear - no lesion recognized.

MISSING TISSUES:
Parathyroid - not present in plane of section.
Extrahepatic bile duct - lost in processing.
Tibial nerve - lost in processing.
Left nipple - lost in processing.
Labium - lost in processing.

MONS 016921

LITTON BIONETICS, INC.
PROJECT NO. 20771

INDIVIDUAL ANIMAL PATHOLOGY EVALUATION

ANIMAL NUMBER:	B-8562	PM NUMBER:	78/1426
DOSAGE:	5 ug/kg	GROUP NUMBER:	2
DATE OF DEATH:	7/10/78	SPECIES:	Monkey - infant
DEATH:	Terminal kill	SEX:	Female
METHOD OF KILL:	Lethane		

GROSS FINDINGS:
No gross lesion recognized.

MICROSCOPIC FINDINGS:
Axillary lymph node - hemorrhage, slight; erythrophagocytosis, slight.
Large intestine - hemorrhage, ileocecal valve, slight.

MISSING TISSUES:
Extrahepatic bile duct - lost in processing.
Tibial nerve - lost in processing.
Left nipple lost in processing.
Labium - lost in processing.

MONS 016922

LITTON BIONETICS, INC.
PROJECT NO. 20771

INDIVIDUAL ANIMAL PATHOLOGY EVALUATION

ANIMAL NUMBER:	B-8754	PM NUMBER:	78/1675
DOSAGE:	5 ug/kg	GROUP NUMBER:	2
DATE OF DEATH:	10/10/78	SPECIES:	Monkey - infant
DEATH:	Terminal kill	SEX:	Female
METHOD OF KILL:	Lethane		

GROSS FINDINGS:
Hemorrhage between skin and frontal bones on both sides.

MICROSCOPIC FINDINGS:
Vagina - focal inflammation, slight.

MISSING TISSUES:
Extrahepatic bile duct - lost in processing.
Tibial nerve - lost in processing.
Left nipple - not present in plane of section.
Labium - lost in processing.
Hemorrhage between skin and frontal bones on both sides - not examined microscopically.

MONS 016923

LITTON BIONETICS, INC.
PROJECT NO. 20771

INDIVIDUAL ANIMAL PATHOLOGY EVALUATION

ANIMAL NUMBER:	B-8815	PM NUMBER:	78/1786
DOSAGE:	5 ug/kg	GROUP NUMBER:	2
DATE OF DEATH:	12/6/78	SPECIES:	Monkey - infant
DEATH:	Terminal kill	SEX:	Female
METHOD OF KILL:	Lethane		

GROSS FINDINGS:
No gross lesion recognized.

MICROSCOPIC FINDINGS:
Lips - inflammation, mucocutaneous junction, slight.
Axillary lymph node - hemorrhage, slight.
Right lung - hemorrhage; edema.
Left lung - hemorrhage.
Mandible - intraosseous squamous cyst; subgingival squamous cysts.

MISSING TISSUES:
Parathryoid - not present in plane of section.

MONS 016924

LITTON BIONETICS, INC.
PROJECT NO. 20771

INDIVIDUAL ANIMAL PATHOLOGY EVALUATION

ANIMAL NUMBER:	B-8796	PM NUMBER:	78/1562
DOSAGE:	5 ug/kg	GROUP NUMBER:	2
DATE OF DEATH:	9/10/78	SPECIES:	Monkey - infant
DEATH:	Stillbirth	SEX:	Male
METHOD OF KILL:			

GROSS FINDINGS:

Lungs - dark reddish-purple in color and sank to bottom in fixative.

Comment - stillbirth, 171 gestation days with crown rump length of 19 cm and crown heel length of 31.5 cm, and with 17 cm of umbilical cord attached.

MICROSCOPIC FINDINGS:

Right lung - atelectasis.
Left lung - atelectasis.
Liver - diffuse hemorrhage.

MISSING TISSUES:

Spinal cord - lost in processing.
Axillary lymph node - lost in processing.
Submaxillary salivary gland - lost in processing.
Extrahepatic bile duct - lost in processing.
Testes - lost in processing.
Epididymides - lost in processing.
Left nipple - lost in processing.
Hip skin - lost in processing.
Foreskin - lost in processing.
Parotid salivary gland - lost in processing.
Pancreas - lost in processing.
Mesenteric lymph node - not present in plane of section.

MONS 016925

LITTON BIONETICS, INC.
PROJECT NO. 20771

INDIVIDUAL ANIMAL PATHOLOGY EVALUATION

ANIMAL NUMBER:	B-8604	PM NUMBER:	78/1490
DOSAGE:	5 ug/kg	GROUP NUMBER:	2
DATE OF DEATH:	7/27/78	SPECIES:	Monkey - infant
DEATH:	Terminal kill	SEX:	Male
METHOD OF KILL:	Lethane		

GROSS FINDINGS:

Comment - many small bruised areas on face, due to trauma by mother.

MICROSCOPIC FINDINGS:
No lesion recognized.

MISSING TISSUES:
Parathyroid - not present in plane of section.
Extrahepatic bile duct - lost in processing.
Prostate - lost in processing.
Tibial nerve - lost in processing.
Left nipple - lost in processing.
Foreskin - lost in processing.

MONS 016926

LITTON BIONETICS, INC.
PROJECT NO. 20771

INDIVIDUAL ANIMAL PATHOLOGY EVALUATION

ANIMAL NUMBER:	B-8546	PM NUMBER:	78/1491
DOSAGE:	25 ug/kg	GROUP NUMBER:	3
DATE OF DEATH:	7/28/78	SPECIES:	Monkey - infant
DEATH:	Found dead	SEX:	Female
METHOD OF KILL:			

GROSS FINDINGS:

Eyelids - swollen shut; skin of lids had several small yellowish elevations.
Thymus - not perceptible.
Lungs - irregularly reddened but apparently not consolidated; trachea and bronchi contained small amount of ingesta.
Spleen - somewhat enlarged.
Colon - cecal mucosa covered with yellowish adherent exudate; lower colon mucosa had several yellowish 1-2 mm spots with a red border.
Lesions - peritoneum covered with thin fibrinous exudate, viscera adherent.

MICROSCOPIC FINDINGS:

Cerebrum - bacterial meningitis.
Cerebellum bacterial meningitis.
Mid brain - bacterial meningitis.
Eyelids - meibomian glands; atrophy, sebaceous elements; squamous impaction, ducts.
Lips - subtotal atrophy, sebaceous glands.
Tongue - candidiasis.
Axillary lymph node - congestion, marked; hemorrhage, marked; bacterial colonies.
Right lung - congestion; edema.
Left lung - congestion; edema.
Thymus - "accidental" involution; cystic Hassall's corpuscles.
Heart - bacterial necrosis, atrial myocardium, slight.
Liver - bacterial colonies.
Spleen - bacterial colonies; congestion.
Kidneys - bacterial colonies.
Adrenal glands - bacterial colonies.
Large intestine - acute necrotizing colitis.
Mesenteric lymph node - intravascular bacteria.
Hip skin - subtotal atrophy, sebaceous glands; hyperkeratosis, slight; dermatomycosis, slight.
Thigh skin - subtotal atrophy, sebaceous glands; hyperkeratosis, slight; dermatomycosis, slight.

MONS 016927

MICROSCOPIC FINDINGS (Continued):
Femoral marrow - decreased granulocyte maturation.
Sternum - decreased cellularity; decreased granulocyte maturation.
Bone marrow smear (femur) - decreased granulocyte maturation.
Peritoneum - acute peritonitis.

MISSING TISSUES:
Extrahepatic bile duct - lost in processing.
Gallbladder - autolysis too severe for microscopic interpretation.
Tibial nerve - lost in processing.
Left nipple - lost in processing.
Labium - lost in processing.
Cervix - not present in plane of section.
Vagina - not present in plane of section.

MONS 016928

LITTON BIONETICS, INC.
PROJECT NO. 20771

INDIVIDUAL ANIMAL PATHOLOGY EVALUATION

ANIMAL NUMBER:	B-8560	PM NUMBER:	78/1787
DOSAGE:	25 ug/kg	GROUP NUMBER:	3
DATE OF DEATH:	12/11/78	SPECIES:	Monkey - infant
DEATH:	Terminal kill	SEX:	Female
METHOD OF KILL:	Lethane		

GROSS FINDINGS:

Lungs - mottled; slight frothy fluid in trachea and bronchi.
Lesions - all lymph nodes prominent; subpleural lymphoid accumulation, 8 mm x 4 mm at T-9-10.

Comment - eyelids and lips slightly swollen; several eyelashes missing; eyelid margins crusty; multiple abdominal scars.

MICROSCOPIC FINDINGS:

Eyelids - meibomian glands; atrophy, sebaceous elements; squamous impaction, ducts; mucinous metaplasia, ducts; paraglandular cellular infiltration, moderate.
Lips - microabscesses, slight.
Tongue - erosion, dorsal surface.
Right lung - congestion; edema; localized collapse and organization.
Left lung - congestion; edema.
Mandible - subgingival squamous cysts.
Subpleural lymphoid accumulation - hyperplastic lymphocytic tissue.

MONS 016929

LITTON BIONETICS, INC.
PROJECT NO. 20771

INDIVIDUAL ANIMAL PATHOLOGY EVALUATION

ANIMAL NUMBER:	B-8592	PM NUMBER:	78/1481
DOSAGE:	25 ug/kg	GROUP NUMBER:	3
DATE OF DEATH:	7/25/78	SPECIES:	Monkey - infant
DEATH:	Terminal kill	SEX:	Female
METHOD OF KILL:	Lethane		

GROSS FINDINGS:
No gross lesion recognized.

MICROSCOPIC FINDINGS:
No lesion recognized.

MISSING TISSUES:
Extrahepatic bile duct - lost in processing.
Tibial nerve - lost in processing.
Left nipple - lost in processing.
Labium - lost in processing.

MONS 016930

LITTON BIONETICS, INC.
PROJECT NO. 20771

INDIVIDUAL ANIMAL PATHOLOGY EVALUATION

ANIMAL NUMBER:	B-8860	PM NUMBER:	78/1788
DOSAGE:	25 ug/kg	GROUP NUMBER:	3
DATE OF DEATH:	12/11/78	SPECIES:	Monkey - infant
DEATH:	Terminal kill	SEX:	Male
METHOD OF KILL:	Lethane		

GROSS FINDINGS:
Thymus - small.
Lungs - pleural surface of anterior lobes dark red.

MICROSCOPIC FINDINGS:
Right lung - hemorrhage.
Left lung - hemorrhage.
Thymus - no lesion recognized.

MISSING TISSUES:
Prostate - not present in plane of section.

MONS 016931

LITTON BIONETICS, INC.
PROJECT NO. 20771

INDIVIDUAL ANIMAL PATHOLOGY EVALUATION

ANIMAL NUMBER:	B-8603	PM NUMBER:	78/1489
DOSAGE:	25 ug/kg	GROUP NUMBER:	3
DATE OF DEATH:	7/27/78	SPECIES:	Monkey - infant
DEATH:	Terminal kill	SEX:	Male
METHOD OF KILL:	Lethane		

GROSS FINDINGS:
No gross lesion recognized.

MICROSCOPIC FINDINGS:
Eyelids - meibomian glands: atrophy, sebaceous elements; squamous impaction, ducts.
Lips - parafollicular microabscesses.
Thymus - cystic Hassall's corpuscles.
Pancreas - ductal hyperplasia, moderate; acinar atrophy, moderate.
Kidneys - focal glomerulonephritis, slight.

MISSING TISSUES:
Extrahepatic bile duct - lost in processing.
Prostate - lost in processing.
Tibial nerve - lost in processing.
Left nipple - lost in processing.
Foreskin - lost in processing.
Parathyroid - not present in plane of section.

MONS 016932

LITTON BIONETICS, INC.
PROJECT NO. 20771

INDIVIDUAL ANIMAL PATHOLOGY EVALUATION

ANIMAL NUMBER:	B-8559	PM NUMBER:	78/1427
DOSAGE:	25 ug/kg	GROUP NUMBER:	3
DATE OF DEATH:	7/10/78	SPECIES:	Monkey - infant
DEATH:	Terminal kill	SEX:	Male
METHOD OF KILL:	Lethane		

GROSS FINDINGS:
Thyroids - minute hemorrhages (at trim).

MICROSCOPIC FINDINGS:
Eyelids - meibomian glands: localized squamous impaction, ducts; localized atrophy, sebaceous elements.
Thyroids - no lesion recognized.

MISSING TISSUES:
Extrahepatic bile duct - lost in processing.
Prostate - lost in processing.
Tibial nerve - lost in processing.
Left nipple - lost in processing.
Foreskin - lost in processing.

MONS 016933

LITTON BIONETICS, INC.
PROJECT NO. 20771

INDIVIDUAL ANIMAL PATHOLOGY EVALUATION

ANIMAL NUMBER:	B-8511	PM NUMBER:	78/1319
DOSAGE:	25 ug/kg	GROUP NUMBER:	3
DATE OF DEATH:	6/19/78	SPECIES:	Monkey - infant
DEATH:	Terminal kill	SEX:	Male
METHOD OF KILL:	Lethane		

GROSS FINDINGS:
No gross lesion recognized.

MICROSCOPIC FINDINGS:
Cerebellum - focal inflammation, meninges, minimal.
Spleen - increased hemosiderin deposition, moderate.
Kidneys - focal nephritis, slight.

MISSING TISSUES:
Parotid salivary gland - lost in processing.
Extrahepatic bile duct - lost in processing.
Parathyroid - not present in plane of section.
Prostate - lost in processing.
Left nipple - lost in processing.
Bone marrow smear (femur) - lost in processing.
Tibial nerve - lost in processing.
Foreskin - lost in processing.

MONS 016934

LITTON BIONETICS, INC.
PROJECT NO. 20771

INDIVIDUAL ANIMAL PATHOLOGY EVALUATION

ANIMAL NUMBER:	B-8542	PM NUMBER:	78/1496
DOSAGE:	100 ug/kg	GROUP NUMBER:	4
DATE OF DEATH:	8/5/78	SPECIES:	Monkey - infant
DEATH:	Found dead	SEX:	Female
METHOD OF KILL:			

GROSS FINDINGS:

Brain - edematous.
Eyelids - white flecks along conjunctival edge of both lids.
Thyroids - large.
Stomach - thick mucosa.
Duodenum - firm nodule at junction of pancreatic duct and duodenum, 1.5 cm x 1.5 cm.
Kidneys - mottled (white) and nodular.
Urinary bladder - mucosa irregularly reddened and possibly polypoid.
Bone marrow (femur) - firm and jelly-like; difficult to make smear.
Peritoneum - abscess (localized peritonitis) with adhesions of spleen, pancreas, stomach, duodenum, gallbladder, kidneys and adrenal glands.

Comment - puffy eyes, white flecks along conjunctival edge of both lids; teeth discolored, tannish.

MICROSCOPIC FINDINGS:

Cerebrum - edema, localized, cortical.
Eyelids - meibomian glands: atrophy, sebaceous elements; squamous impaction, ducts.
Lips - subtotal atrophy, sebaceous glands.
Tongue - candidiasis.
Axillary lymph node - hemorrhage, slight.
Right lung - congestion.
Left lung - congestion.
Thymus - "accidental" involution; cystic Hassall's corpuscles.
Liver - focal necrosis and intranuclear inclusions (viral); intrahepatic bile ducts (second order) - epithelial hyperplasia, moderate, mucoid content.
Gallbladder - mucosal hyperplasia, moderate.
Spleen - congestion; focal leucocytic infiltration, marked.
Pancreas - ductal hyperplasia, severe; acinar atrophy, severe; parapancreatic abscess.
Kidneys - areas of retarded cortical maturation, marked; pyelonephritis, moderate.

MONS 016935

MICROSCOPIC FINDINGS (Continued):
Urinary bladder - submucosal hemorrhage, marked.
Stomach - cystic mucinous metaplasia, mucosal glands, moderate; submucosal glandular cysts, slight; paragastric abscess.
Small intestine - crypt metaplasia, Brunner's glands, marked; thrombi in lacteals.
Hip skin - atrophy, sebaceous glands; follicular keratosis.
Thigh skin - subtotal atrophy, sebaceous glands; follicular keratosis.
Femoral marrow - decreased cellularity.
Mandible - subgingival squamous cysts.
"Scruffy" skin - keratinizing squamous papilloma.
Skin lesion - intraepidermal abscess.
Thyroids - no lesion recognized.

MISSING TISSUES:
Extrahepatic bile duct - lost in processing.
Tibial nerve - lost in processing.
Left nipple - lost in processing.
Bone marrow smear (femur) - smear preparation unsatisfactory for microscopic interpretation.
Parathyroid - not present in plane of section.
Labium - lost in processing.

MONS 016936