THE TOXICITY OF POLYCHLORINATED POLYCYCLIC COMPOUNDS AND RELATED CHEMICALS

Author: Renate D. Kimbrough*
Center for Disease Control
Atlanta, Ga.

Referees: M. M. Barnes
J. B. Greig
Medical Research Council
MRC Toxicology Unit
Medical Research Council Laboratories
Carshalton, Surrey
England

INTRODUCTION

Only the small group of the polychlorinated polycyclic compounds given in Figures 1 and 2 will be reviewed in this article. Several years ago when this laboratory was the Atlanta Toxicology Branch of the Food and Drug Administration, concern was voiced over the possible long-term effects of polychlorinated biphenyls, and we began to study the toxicity of Aroclor 1254 and Aroclor 1260. About this time a follow-up study was performed on a group of workers in New Jersey who were engaged in the production of 2,4,5-T.[1] These workers had very severe chloracne and had previously been shown to have porphyria.[2] During that same time, a petition was filed with the Food and Drug Administration for a residue level of hexachlorophene on certain food crops. Hexachlorophene, as well as 2,4,5-T, is made from trichlorophenol, although the chemical reactions are quite different. When we checked the available literature on the toxicity of hexachlorophene we felt that adequate toxicity data by present standards were not available, particularly not if the compound was meant to be ingested. Furthermore, Larson[3] had pointed out that hexachlorophene was more toxic than commonly acknowledged.

Hexachlorophene and similar chemicals behave differently from such polycyclic polychlorinated compounds as the chlorinated biphenyls (PCBs). Hexachlorophene in particular is acutely much more toxic than the PCBs and is fairly rapidly eliminated from the body, while the PCBs have a very low acute toxicity, but are very poorly metabolized, particularly those with more than four chlorine atoms on the phenyl rings. The long-term effects are therefore more critical for compounds such as PCBs. The chlorinated dibenzodioxins and furans, some of which are extremely toxic on an acute basis, may also show persistence and their long-term effects may be equally as important. These observations show that it would be erroneous to make predictions on long-term effects from results obtained in acute toxicity studies.

*Formerly with the Environmental Protection Agency, Chamblee Toxicology Laboratory, 4770 Buford Highway, Chamblee, Ga 30341.

MONS 200519

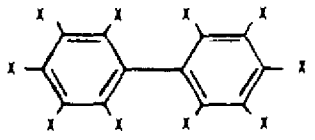

Polychlorinated Biphenyls (PCB's)

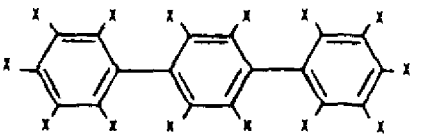

Polychlorinated Terphenyls

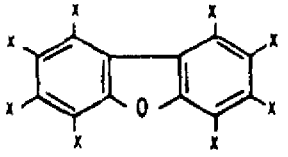

Chlorinated Dibenzofurans

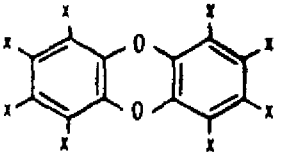

Chlorinated Dibenzodioxin

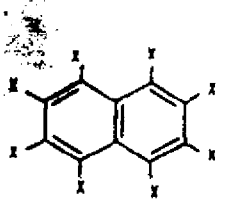

Polychlorinated Naphthalenes

FIGURE 1. The materials shown in this figure are mixtures of compounds in which several but usually not all of the positions (-X) are chlorine and the rest are hydrogen. The properties of the materials depend on the degree of chlorination of the mixture. All are insoluble in water but soluble in varying degrees in organic solvents and in fats. The trade name for the U.S. product (Monsanto) of the chlorinated biphenyls and terphenyls is Aroclor. The trade name is followed by the number. For the biphenyls, the first 2 digits of this number are 12, and for the terphenyls, 54. In each instance the last 2 digits give the percentage of chlorine.

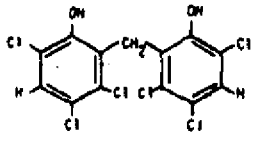

HEXACHLOROPHENE
2,2'-Methylene-bis(3,6,6-trichlorophenol)

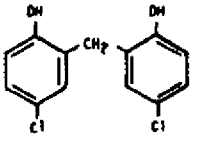

DICHLOROPHENE
2,2'-Methylene-bis(4-chlorophenol)

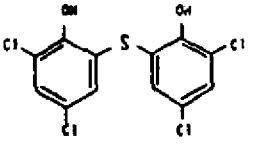

BITHIONOL
2,2'-Thio-bis(4,6-dichlorophenol)

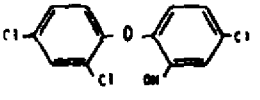

2,4,4' trichloro- 2' hydroxy-diphenyl ether
(Triclosan • Irgasan DP300)

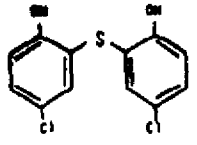

FENTICLOR
2,2'-Thio-bis(4-chlorophenol)

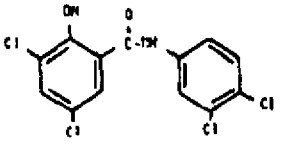

3,3',4,5'-Tetrachlorosalicylanilide (TCC)

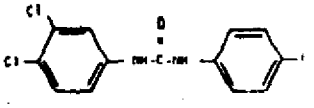

3,4,4'-Trichlorcarbanilide (TCB)

FIGURE 2. The compounds in this figure are white crystalline solids with clearly defined melting points above 160°C. They are practically insoluble in water and soluble in varying amounts in organic solvents and in fats. Those containing an -OH group, all the above excepting 3,4,4'-trichlorocarbanilide, are soluble in aqueous alkali.

MONS 200520

The present review is an attempt to correlate various toxic effects produced by the chemicals listed in Figures 1 and 2 in order to better understand and appreciate their behavior.

The subjects covered in this article have lately enjoyed great interest and a rapidly growing number of scientific reports are available. Since a number of the chemicals discussed produce similar or related effects, their toxicology is discussed together rather than listing each compound separately, which would have led to a great deal of repetition.

A detailed discussion of the various chemical reactions, analytical methods for the determination of the compounds, is not given. The review has been written with the toxic effects of the various compounds as the focal point and the literature cited serves to illustrate these points. No attempt has been made to present a complete review of the literature in this area.

DEVELOPMENT, USAGE, AND OCCURRENCE

A description of the synthesis of *chlorinated biphenyls* (PCBs) can be found in *Liebig's Annalen* as early as 1881.[4] Successful production of diphenyl in commercial quantities was not reported until 1930.[5] At that time the chlorination of technical biphenyl was also described.[6] Biphenyl itself is fungistatic and used as a preservative for citrus fruits.[7] Chlorinated biphenyls are very stable, and have been used for protective coatings, as plastic resins or gums for varnishes, and for waterproofing and flameproofing of wood.

The excellent dielectric properties of these compounds were noted as early as 1930. Until the advent of the PCBs, mineral oil was used as a cooling and dielectric liquid impregnant for high voltage electric apparatus such as transformers and capacitors. Since mineral oil is flammable and flammable gases could also be produced, restrictions for the use and installations of these transformers had to be set, particularly for indoor installation. When mineral oils were replaced by the Aroclors, the fire and explosion hazards were eliminated. This was recognized by the National Board of Fire Underwriters and the National Electric Code was modified.[8] Use of Aroclors also greatly reduced the physical size of the capacitors.[9]

A recent summary of the varied uses of PCBs has been provided by Broadhurst.[10] With a peak production of 42,527 short tons of PCBs in 1970, Monsanto is the sole producer of Aroclors (U.S. tradename for PCBs) in the U.S. Yearly PCB production figures for the period 1960-1971 were reported by Monsanto.[11] The production increased steadily until 1970 and dropped to 20,236 short tons in 1971 due to a voluntary restriction of the use of PCBs by the company. Trade names in other countries include Kanneclor and Santhaterm in Japan, Clophen, Flenclor, Phenoclor, and Sovol in Europe.

The polychlorinated capacitor liquids, commonly called askarels, are mixtures of chlorinated biphenyls and chlorinated benzenes. A variety of other industrial applications[10] have been found for PCBs. They have served as fluids for hydraulic, gas turbine, and vacuum pumps, as heat transfer fluids, as plasticizers, adhesives, textile coatings, surface coatings in paints and varnishes, as sealants, and as part of formulations to prepare pressure sensitive records and color copying papers. The extent of the current use of PCBs in printing processes is unknown. Other suggested uses over the years have included catalyst carrier for polymerization of olefins, conversion of water permeable soil to a nonpermeable state, and combined insecticide and bactericide formulations. Mixtures of chlorinated biphenyls and chlorinated naphthalenes have been employed to insulate electric wires and cables, particularly when they were used in the mining industry and on warships.[12]

Residues of polychlorinated biphenyls have been reported in the environment by a number of authors in different parts of the world. These reports were usually from areas where industrial pollution was responsible for the environmental contamination. Holden,[13] after finding PCBs in marine fish and mollusks from Scottish waters, noticed that they were generally highest in samples from the Firth of Clyde and he discovered that the PCB contamination probably originated from industrial sewage. The sewage sludge was transported from two Glasgow purification works by boats and dumped in deep water six miles south of Garroch Head. The disposal of sewage sludge on land could lead to the introduction of PCB residues into the terrestrial ecosystem by transfer through food chains. So far PCB residues have not been detected in fresh water fish in Scotland.

Polychlorinated biphenyls have also been found

MONS 200521

in wildlife samples collected along the Dutch coast and the Rhine River[14] and in fish and seal in different parts of the Baltic Sea along the Swedish coast.[15]

Risebrough et al.[16] compared the presence of PCBs with that of DDT and its metabolites in various birds. These authors found very low concentrations of PCBs in wildlife species in Baja, California, Mexico, and the Gulf of California, which are very remote areas with a high ratio of DDT to PCB of approximately 9 or 10. In sea birds from the Pacific, the ratio was between 5 and 10 and at that time, PCBs were not found in eggs of the Adelie penguin from Cape Crozier, Antarctica. Relatively high PCB concentrations were found in San Francisco Bay, Puget Sound, and San Diego Bay and the ratio of DDT to PCBs in wildlife samples from this area was between 1 and 2. This is again emphasized by the findings of Dustman et al.[17] Twelve Alaskan bald eagle eggs had median PCB residues of 1.65 ppm while 11 eggs collected in Maine, Michigan, Minnesota, and Florida showed a median concentration of 9.7 ppm.

Zitko[18] found low concentrations of PCBs in different types of fish taken from several lakes and the St. John River System, New Brunswick, Canada, and the Nova Scotia banks. Fish from the Milwaukee River and Lake Michigan in the midwest part of the U.S., where the river enters into the lake, contained varying amounts of PCBs[19] while fish taken from various small lakes in Wisconsin without industrial discharge failed to show PCBs. Large predators from Lake Michigan contained as much as 10 to 25 ppm PCBs on a fresh weight basis expressed as Aroclor 1254 and salmon eggs contained as much as 12 to 17 ppm PCBs on a fresh weight basis. Further studies by Veith[20] of the concentration of PCBs in different rivers emptying into Green Bay indicated a trend towards a decrease in PCB concentrations since the *voluntary* partial ban on PCB sales by Monsanto was implemented in September of 1970.

If PCB discharges are very high a fishkill may result such as the one in Escambia Bay, Florida in 1969.[21] In that particular episode the PCBs had entered a plant's effluent through accidental leakage of heat exchange fluid. The PCB found in this case resembled Aroclor 1254 most closely. The peak amount found in water of the Escambia River at the outfall amounted to 275 ppb and the peak concentration found in oysters from Escambia Bay was 3.0 ppm. Aroclor residues in sediment samples taken near the outfall reached 486 ppm. When the leakage from the plant was corrected, Aroclor levels gradually decreased in this area.

The wildlife portion of the U.S. National Monitoring Program analyzed starlings, mallard and black ducks, bald eagles, and fish of several species for PCBs. According to Stickel,[22] monitoring for terphenyls is also done but not for any of the other chlorinated compounds in this report. Research surveys that include fisheating birds, insectivorous birds, ospreys, woodcocks, and certain ducks also monitor only for PCBs and for pesticides. Oysters (*Crassostrea virginica*) are a good indicator of PCB and other chlorinated hydrocarbon concentrations in water and a national monitoring program in these mollusks in 15 coastal areas has been developed.[23] So far, mollusks have only very occasionally contained low levels of PCBs.

In summary, the PCB concentrations in water are low or nonexistent in remote lakes and fresh water streams and can be as high as 50 μg/l (5 ppb) or higher in polluted rivers such as the Hudson River.[24] The PCB concentration is usually higher in sediment from these polluted waters because PCBs are only very slightly soluble in water.[25] Since PCBs are stored in living matter, they are concentrated in the food chain and the usual "biomagnification" is encountered as we know it from other poorly metabolized and excreted substances. The concentration of PCBs in fish, particularly those in the upper end of the food chain from polluted rivers and lakes, is usually estimated in the ppm range and fisheating birds will have somewhat higher levels of PCBs than the fish from the same geographic location.[26] Young animals may contain less PCBs than their older counterparts of the same species in a particular location.

PCBs are also infrequently encountered in dairy products, meat, fish, and poultry in ready-to-eat human food.[27,28] Occasionally, human food and domestic animal feed have been more extensively contaminated with PCBs. In these instances, the contamination could usually be traced to local misuse of transformer fluid, leakage of PCBs from heat exchange fluid, or contamination of recycled paper with PCBs where the paper had been used for food packaging such as cereal boxes.[29] The U.S. Food and Drug Administration has recently set temporary tolerances for PCBs in certain food products (see Table 1).

NONS 200522

TABLE I

Temporary Tolerances Expressed as Parts per Million (ppm) Established by U.S. Food and Drug Administration

(1) Milk (fat basis)	2.5
(2) Dairy products (fat basis)	2.5
(3) Poultry (fat basis)	5.0
(4) Eggs	0.5
(5) Complete and finished animal feeds	0.2
(6) Animal feed components	2.0
(7) Fish and shellfish (edible portion)	5.0
(8) Infant and junior food	0.2
(9) Paper food-packaging material	10.0

Note: The tolerance for paper food-packaging material shall not apply to such material separated from the packaged food by a functional barrier impermeable to PCB migration.

The Food and Drug Administration will provide upon request the analytical methods it will use for enforcing the temporary tolerances.

All of these aspects of PCBs in the environment have been the subject of a number of reports, reviews,[30] and conferences.[31-35]

Terphenyls and chlorinated terphenyls are used as reactor coolants. The terphenyls consist of mixtures of ortho-, meta-, and paraterphenyls. Chlorinated terphenyls are produced by Monsanto and termed Aroclor, followed by numbers. The first 2 digits of these numbers are 54 and the last 2 indicate the percent of chlorine such as Aroclor 5460. Aroclor series 25 and 44 consist of mixtures of polychlorinated biphenyls and polychlorinated terphenyls.[36] According to Zitko et al.,[37] polychlorinated terphenyls have been found in environmental samples. Polychlorinated terphenyls do not elute from GLC columns under conditions used for PCBs,[38] which may explain why they have only been detected occasionally, but the way they are used probably also precludes their extensive spread in the environment.

Chlorinated dibenzodioxins and *chlorinated dibenzofurans* may occur as contaminants of cyclic chlorinated hydrocarbons.

In 1959 Tomita et al.[39] reported on the synthesis of polyhalodibenzo-p-dioxins. According to these authors, chlorophenols, when heated to about 200°C or more under alkaline conditions and pressure, will form chlorodibenzodioxins, as shown below.

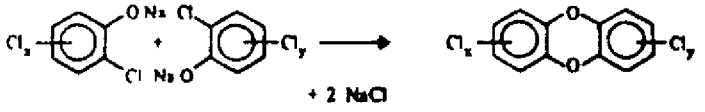

Under similar conditions a chlorodibenzofuran may also be formed.

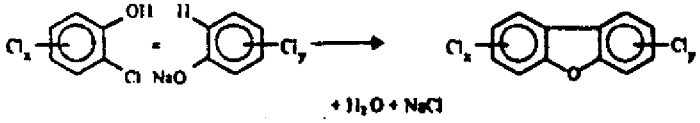

Chlorinated dibenzodioxins and chlorinated dibenzofurans are formed, or can be formed, as contaminants in the manufacture of a variety of products which use chlorophenols and chlorobenzenes as starting materials, such as 2,4,5-T, pentachlorophenol, nitrofen, hexa- and pentachlorobenzene, and tri- and tetrachlorophenol. Polychlorinated biphenyls may also be contaminated with chlorinated dibenzofurans,[40,41] and chlorinated dibenzofurans may result from polychlorinated biphenyls under UV irradiation.[42] The toxicity of these products varies depending on the position and number of chlorines attached to the phenyl ring. Products from different manufacturers may show a great deal of difference in the type and amount of contamination and different lots of the same product may vary in composition, making toxicological evaluations of these products very difficult. Rigorous production control and cleanup procedures need to be implemented so that the composition of different lots manufactured by the same company becomes more uniform.

Villanueva et al.[43] and Jensen and Renberg[44] reported the presence of chlorinated dibenzo-p-dioxin in pentachlorophenol. Hydroxynonachlorodiphenyl ether was also found and referred to as "predioxin" under the assumption that it represented a precursor of dioxin.

MONS 200523

According to Johnson et al.,[45] the predominant dioxin in a commercial pentachlorophenol was octachlorodibenzodioxin while trace amounts of hexachlorodibenzodioxin and no tetrachlorodibenzodioxin were found. Since the technical pentachlorophenol was in some respects more toxic in animal studies, than the pure product, the production process of pentachlorophenol was changed to minimize the dioxin concentration and a new product has now been registered under the Federal Insecticide Fungicide and Rodenticide Act with a lower dioxin content.

Technical 2,4,5-T has also been found to be contaminated with a dioxin. In this instance, unfortunately, the very toxic 2,3,7,8 tetrachlorodibenzodioxin,[46-48] was present. The contamination of the 2,4,5-T with 2,3,7,8-tetrachlorodibenzodioxin ranged from < 1 ppm to as much as 32 ppm over the years. In newly manufactured 2,4,5-T in the U.S. the content of tetrachlorodibenzo-p-dioxin has been substantially reduced and is usually kept below 0.1 ppm. Whether other dioxins or furans have ever been detected in 2,4,5-T in the U.S. has not been reported in the literature.

Chlorinated dioxins have also been found in so-called "toxic fat," which produces chick edema disease when fed to chickens. After several years of study by industry and the Food and Drug Administration, Flick et al.[49] were able to separate a purified crystalline product which produced chick edema disease. Two years later, Cantrell et al.[50] announced that 1,2,3,7,8,9-chlorodibenzo-p-dioxin was one of the toxic compounds that produced chick edema. The origin of the chlorinated dibenzodioxin in "toxic fat" was not clear. It was suspected that it arose from chlorophenols which were used to preserve hides for the manufacture of leather. Tallows and greases were obtained from these hides[51] and a more recent outbreak of chick edema disease was traced to the contamination with chlorophenols of soapstock used as feed fats. Higginbotham et al.[52] showed that chlorophenols and their salts, when heated, undergo condensation reactions and form chlorinated derivatives of dibenzo-p-dioxin; furthermore, chlorinated dioxins and predioxins were originally present in some of the chlorinated phenols. Generally no efforts have been made to determine whether *various chlorinated dioxins and furans* are present in the environment. However, Baughman and Meselson[53] recently reported the presence of dioxins in fish taken from four locations in Vietnam in Military Region III, which includes Saigon and several provinces to the north.[54] The concentrations ranged from 18 to 814 ppt.

Zitko[55] was not able to demonstrate chlorinated dibenzodioxins and dibenzofurans in aquatic animals from various locations in Canada.

Chlorinated naphthalenes may so far have remained unidentified since they interfere with other chlorinated compounds in any multiresidue analysis and are detected only when mass spectrometry is also performed.[56]

The various *germicides* given in Figure 2 have been used as antiseptics, deodorants, and particularly, as far as hexachlorophene is concerned, also as preservatives for various cosmetics, soaps, and lotions. A listing of different products that contained hexachlorophene prior to the new regulations was given by the American Pharmaceutical Association.[57] Registration of bithionol was cancelled in the U.S.[58] because it produced photosensitivity reactions in humans using soaps that contained this product. None of the polychlorinated polycyclic compounds used as germicides have been shown to accumulate in the environment. Hexachlorophene has additional uses as a fungicide on ornamental plants, on conveyor chains as a mildewstat, in laundry rinses as a mildewstat, in shoes and air filters and assorted industrial uses as a fungistat, and on leather, paper, and textiles.[59] It is also registered as a pesticide for use on cucumbers, peppers, and tomatoes,[60] and for cotton.

Dichlorophene is used as a mildew preventive on cotton and is recommended as a fungicide and bactericide for the protection of textiles and materials from molds.[61]

CHEMISTRY: METHODS FOR CHEMICAL DETERMINATION AND PHOTOLYSIS

Much of the chemistry of *polychlorinated biphenyls* has recently been reviewed.[33-34] Commercial chlorinated biphenyls are mixtures of biphenyl groups with different numbers of chlorine atoms (Figure 1). When hydrogen atoms are replaced by chlorine on the biphenyl ring, a large number of substitution combinations can arise since the number of chlorine atoms on the molecules can vary and the chlorines can also be

MONS 200524

attached to the molecule in different positions, resulting in a variety of isomers. Even if the chlorination may be the same, different commercial batches may vary in the relative concentration of isomers. The PCBs produced in the U.S. by Monsanto fall under the trade name Aroclor. The various Aroclor mixtures have a great number of constituents, and when the biphenyl is chlorinated, 210 different chemicals are theoretically possible. Aroclor 1254, for instance, yielded 69 constituents while the fractionation of Aroclor 1242 and 1260 yielded 45 and 78 components, respectively.[54]

The chlorinated biphenyls (PCBs) are chemically very inert, resistant to corrosive chemicals, insoluble in water, and have a low vapor pressure. Aroclor 1221, for instance, has a boiling point of 278°C. The boiling point increases with increasing chlorination. The chlorinated biphenyls are determined in biological and environmental samples by a combination of electron capture gas liquid chromatography and mass spectrometry. Nuclear magnetic resonance spectroscopy is used in addition to the above two procedures in some laboratories. PCBs were first identified in environmental samples by Jensen in 1966.[62] They were detected as interfering peaks on GLC analysis of environmental samples that were analyzed for chlorinated pesticide residues.[63]

The PCBs interfered with routine pesticide analyses for chlorinated hydrocarbons. Various authors have therefore published separation methods[64] and Reynolds[38] discussed this extensively in a review.

According to Safe and Hutzinger,[65] the use of mass spectrometry for structural studies of PCBs is limited because the chlorine atoms may be randomized between the phenyl groups when the PCBs are fragmented by electrons. The only exception to this is 2,2'-dichlorobiphenyl.

The quantitation of polychlorinated biphenyl in environmental samples has met with difficulty since the PCBs represent mixtures. Several workers have compared PCB components in field samples to Aroclor 1254 because the sample chromatograms were most similar to these mixtures.[66-68] Rote and Murphy[68] quantitated individual peaks of different Aroclors by means of a response curve. The semilogarithmic relationship of detector response (total peak area/16 ng) to average chlorine content was obtained for each Aroclor by the method of least squares. From this relationship the theoretical response of the detector to each chlorinated biphenyl was calculated. When this approach was used, the levels of PCBs were lower than when the PCB levels were compared to the Aroclor 1254 standard. Because of these difficulties in quantitation, the PCB levels reported from different laboratories may vary greatly. The various problems encountered in the analytical methodology of polychlorinated biphenyls and their quantitation are also described in a U.S. FDA report which can be obtained upon request from the U.S. Food and Drug Administration in Rockville, Md. The title of the report is *Analytical Methodology for Polychlorinated Biphenyls* (Feb. 1973).

Polychlorinated terphenyls (Figure 1) are not eluted from gas chromatography columns under conditions used for polychlorinated biphenyls.[38] By altering their gas chromatograph column, Zitko et al.[37] were able to detect polychlorinated terphenyls.

Chlorinated naphthalenes (Figure 1) elute at the same time and cause interference with the determination of chlorinated biphenyls and chlorinated hydrocarbon pesticides in general, unless mass spectrometry is performed to establish the identity of the various chemicals involved.[56]

The methods presently available for the determination of *trichlorocarbanilide* and *other germicides* (Figure 2) are not very well developed. Graber et al.[69] outlined a thin layer chromatography method for the determination of these chemicals in soap and very briefly mentioned other methods that have been employed in the past.

Several methods for the determination of *chlorinated dibenzodioxins* and *chlorinated dibenzofurans* have been described. The goal of these methods is two-fold. First of all, quite a number of technical polychlorinated organic compounds may contain one or several of these compounds[70-72] as contaminants and methods have been developed to determine them in various technical products. Other methods dealt primarily with toxic fats where many attempts were made to isolate and identify the compounds responsible for chick edema disease.[73] Some of these methods were described in the papers that will be cited in connection with the description of chick edema disease in this article.

When preparing the various chlorinated dibenzodioxins and dibenzofurans for toxicity studies in

MONS 208525

order to obtain pure products, methods also need to be available for their separation and identification.[74]

One of the problems with tetrachlorodibenzodioxin as well as tetrachlorodibenzofuran is their severe toxicity in the microgram range which will probably not result in an accumulation within the ppm in biological tissues, for instance, for residue analysis. Baughman and Meselson[53] have recently described a method for the determination of these materials, within the ppt range.

Hexachlorophene is made from trichlorophenol. A process for its production was patented by Gump.[75] Additional methods for the production and purification for hexachlorophene have been published and are cited in *Chemical Abstracts*.

Recently several methods[76-79] have been developed for the determination of small amounts of hexachlorophene in blood and biological tissues. Some methods were based on extraction of hexachlorophene with ether or ethanol or a mixture of ether and ethanol. An acetyl or methyl derivative was formed and the hexachlorophene was determined with electron capture gas chromatography.[79] In an earlier method described by Bachmann and Shetlar,[80] simple benzene extraction was used and no derivative of hexachlorophene was made, which led to very variable results. The various advantages and disadvantages of these methods were discussed by Ulsamer.[79] In earlier work my co-workers used ether for extraction and prepared a dimethyl ether derivative of hexachlorophene.[81] Recovery with this method was only about 75% and we have recently altered our method of extraction to obtain better recovery.[82] A method developed by Kabacoff et al.[78] for the determination of hexachlorophene is, according to the authors, also suitable for determination of dichlorophene and Gutenmann and Lisk[83] have described a method for the determination of hexachlorophene in several agricultural products.

The production of hexachlorophene from trichlorophenol proceeds at low temperature and under acidic conditions which makes the production of a chlorinated dibenzodioxin as an impurity highly unlikely.

Since chemicals that are found in the environment are exposed to sunlight, the effect of *UV light* on the compounds under discussion has been given considerable attention. Hustert and Korte[84] synthetized a few PCB isomers, namely, 2,4,6,2',4',6'-hexachlorobiphenyl, 2,4,5,2',4',6'-hexachlorobiphenyl, 2,4,2',4'-tetrachlorobiphenyl, 2,5,2',5'-tetrachlorobiphenyl, and irradiated the various isomers with UV light. A mercury vapor lamp with quartz filters was used as a light source. The UV spectrum of the synthetized chlorinated biphenyls only shows significant absorption below 300 nm. When these compounds were irradiated in a solvent such as hexane, acetone, methanol, or a mixture of methanol and water, dechlorination and polymerization of the compounds was observed. When the PCB isomers were irradiated in perfluorinated dimethylcyclohexane, an inert medium, isomerization, and chlorination dechlorination were observed. These experiments indicate that, under environmental conditions, photolysis products may result with a lower chlorine content but small amounts of higher chlorinated biphenyls may also occur in low concentrations. Safe and Hutzinger[85] reported that the irradiation of 2,4,6,2',4',6'-hexachlorobiphenyl at 310 nm resulted in compounds of lower chlorine content, such as di-, tri-, tetra-, and pentachlorobiphenyls. In these investigations hexane and methanol were used as solvents. It is possible that new compounds are formed by loss of chlorine. Rearrangement and condensation may lead to chlorobiphenyls in environmental samples that are not present in commercial PCB mixtures. The 24-hr irradiation of 3,3',4,4'-tetrachlorobiphenyl, 2,2',6,6'-tetrachlorobiphenyl, 2,2',5,5'-tetrachlorobiphenyl dissolved in hexane resulted in about 70% loss of the starting material, while with 2,2',4,4',5,5'-hexachlorobiphenyl, only 3.8% remained and less than 1% of 2,2',3,3',4,4',5,5'-octachlorobiphenyl remained. The irradiation of Aroclor 1254 in hexane resulted in a change of the composition of the Aroclor mixture. The gas chromatogram obtained from the irradiated Aroclor showed shorter retention times than the standard Aroclor 1254. The irradiation of Aroclor 1254 in a dioxane water mixture also containing sodium bicarbonate did not lead to the formation of chlorodibenzofurans or hydroxychlorobiphenyls. The compounds that were observed corresponded to PCB molecules to which water was added and a more polar "carboxylic" acid fraction. Irradiation of Aroclor as a thin film with a frequent addition of water led to newly formed hydroxylated compounds and a more polar "carboxylic" fraction. The results obtained from irradiating

NONS 200526

PCBs therefore depended greatly on the solvents used and the pH of the solution in addition to the light source used and may result in dechlorination, formation of polymers, hydroxylation, and carboxylic products.[86]

Exposure of various chlorinated dibenzodioxins to summer sunlight or fluorescent UV light with an intensity of roughly 100 $\mu w/cm^2$ in the presence of organic solvents such as methanol led to rapid photolysis of 2,3,7,8-tetrachloro- and 2,7-dichlorodibenzodioxin, while 1,2,3,4,6,7,8,9-octachlorodibenzo-p-dioxin produced a series of chlorinated dioxins with uniformly decreasing chlorine content. Some evidence was also found that reactions other than reductive dechlorination occurred.[87] When 2,3,7,8-tetrachlorodibenzodioxin was spread on a glass plate in a methanol solution and the methanol was allowed to dry, quantitative recovery of the dioxin was possible even after 14 days of UV irradiation. Similar results were obtained when 2,3,7,8-tetrachlorodibenzodioxin was dissolved in methanol, put on a glass plate, covered with soil, and irradiated.[87] These results demonstrated that under favorable environmental conditions, when organic hydrogen donors are present, photolysis will take place. Bare surfaces of soil, concrete, or water are not effective inducers of photolysis. Chlorinated dibenzodioxins could at times prove to be quite persistent. Partial dechlorination may also occur with chlorinated diphenyls or the higher chlorinated dibenzodioxins and may result in less chlorinated compounds.

The possible long lasting presence of the dioxins is also emphasized by Kearney et al.,[88] who recovered 56 and 63% of originally applied tetrachlorodibenzodioxin after one year in Hagerstown and Lakeland, Md. soils.

Tetrachlorosalicylanilide and similar compounds split off chlorine atoms when exposed to sunlight. This is briefly mentioned in connection with photosensitivity reactions of the skin. Shaffer et al.[89] irradiated *hexachlorophene* in absolute ethanol with UV light and obtained a number of dechlorinated bisphenols resulting from loss of chlorine in the ortho and para positions relative to the hydroxy group.

GENERAL TOXICITY AND EFFECT ON REPRODUCTION

Diphenyl itself, without any chlorine atoms, is a fungistatic agent which is used as a preservative for citrus fruits, and is usually impregnated into the wrapping paper. The protected citrus fruit contains a certain amount of biphenyl residue. In different countries the amount allowed as a residue on citrus fruit varies between 70 to 110 ppm of biphenyl. Booth et al.[90] found a reversible nephrotoxic effect of biphenyl on the rat kidney when rats were fed 0.5% or 1% (10,000 ppm biphenyl in the diet). None of these effects was observed on diets containing 0.1% (1000 ppm biphenyl). Deichmann et al.[91] showed that prolonged exposure to air containing diphenyl in high concentrations of 5, 40, and 300 mg/m^3 produced liver and kidney injury as well as bronchopulmonary lesions in mice and rats. In general, diphenyl has always been considered to be relatively nontoxic. In 1969, in Finland, a man who had been intensively exposed to diphenyl for 11 years became ill and died.[92] Diphenyl impregnated wrapping paper had been manufactured in Finland for about 15 years in the plant where the man was employed. The equipment used in the impregnating process was cleaned 5 to 10 times a year with tri- or tetrachloroethylene. The cause of death of the worker in this particular report was not satisfactorily explained and neither were the complaints of 31 other workers engaged in the same factory. Since chlorinated ethylene compounds were used for cleaning, it should be established whether organic solvents containing halogens could lead to the production of toxic substances when they are brought in contact with diphenyls. If this proves to be the case, then care should be taken that this situation is avoided.

The *PCBs* are also not very toxic when given as a single or a few repeated doses to birds and mammals. However, the juvenile pink shrimp is very sensitive to PCBs in water, while trout and catfish can tolerate higher doses; insects are also not very sensitive to PCBs. Pin fish are not quite as sensitive to a single dose, but will die when exposed for 14 to 45 days to 5 ppb of Aroclor 1254.[93] PCBs are of a low order of toxicity to rats and rabbits when given as a single dose. The acute oral toxicity decreases in rats with increasing chlorine content, while this is not as obvious when the dermal toxicity is tested in rabbits.[33] This may be due to poorer absorption of the higher chlorinated compounds. In studies with adult Sherman strain rats, we found that the oral LD_{50} for Aroclor 1254 and 1260 was somewhere in the

MONS 200527

range of 4 to 10 g. These two compounds proved to be more toxic in weanling rats. The single oral LD_{50} for weanlings was 1295 mg/kg, and 1315 mg/kg for Aroclor 1254 and 1260, respectively, and the lowest lethal doses were 1000 mg/kg for Aroclor 1254, and 1200 mg/kg for Aroclor 1260. The intravenous LD_{50} for Aroclor 1254 in adult female rats was 358 mg/kg.[94]

A number of short-term studies have been reported where the PCBs were given to animals over a period of one or two weeks. When the PCBs were given in this fashion they were somewhat more toxic than when they were given in a single dose. These studies are reviewed in great detail by Nelson et al.[32] and will not be reported here since they do not give a great deal of additional information.

Vos and Koeman[95] studied the toxicity of three PCB preparations in chickens, Phenoclor DB6, a French product, Clophen A60, a German product, and Aroclor 1260, a product from Monsanto in the U.S. The birds were fed 400 ppm of PCBs in their diets for 60 days; the Phenoclor and Clophen were much more toxic than Aroclor. The birds fed the two European samples died between 12 and 60 days after onset of exposure. The findings at autopsy consisted of hydropericardium, ascites, subcutaneous edema, and liver necrosis. Only 3 of 20 birds fed Aroclor 1260 died during this time with hydropericardium. None of the Aroclor fed birds showed liver necrosis.

With the help of mass spectrometric and microcoulometric analyses, the authors[95] determined that the two European samples were contaminated with tetra- and pentachlorodibenzofurans. As an additional contaminant, chlorinated naphthalenes were found.

Dermal toxicity studies with the three compounds, Clophen, Phenoclor, and Aroclor 1260, in rabbits[96] after two days led to reddening of the skin where the materials were applied. The skin reaction was more pronounced after one week, desquamation of the external epidermal layers of the skin was observed, the hair grew at a reduced rate, the skin became thickened, and prominent transverse wrinkles developed. The test animals showed a gradual loss of weight, and one of the rabbits given Phenoclor and three of those given Clophen died. All but one rabbit showed fluorescence of the liver under UV light, and microscopic changes were also observed in the livers and the treated skin.

Vos and Notenboom-Ram[97] compared the dermal toxicity of the isomer 2,4,5,2',4',5'-hexachlorobiphenyl with that of a PCB mixture (Aroclor 1260) in rabbits. Their dermal application resulted in early microscopic skin lesions in the Aroclor group. The lesions in the 2,4,5,2',4',5'-hexachlorobiphenyl group appeared later and were less severe. Both experimental groups showed liver changes. The liver damage was more pronounced in the animals that had been exposed to hexachlorobiphenyl than in those that had been exposed to the Aroclor.

In inhalation studies with Aroclor 1242 and 1254, rats, mice, rabbits, guinea pigs, and one cat were exposed to PCB vapors five days a week for several weeks. The concentration of Aroclor 1242 vapor was 1.90 to 8.63 μg/l and no ill effects were observed. The exposure of animals to the vapor of Aroclor 1254 in the concentration of 5.4 or 1.5 μg/l produced enlarged livers in rats. An intercurrent respiratory infection in some control as well as experimental rats made it difficult to interpret the results.[98] Since it is now known that the chronic toxicity of PCBs is a more important parameter in establishing their effects than short-term exposures, further studies with lower levels over longer periods of time would give more meaningful information. Fortunately, most of the compounds under discussion have a low vapor pressure so that exposure by inhalation probably does not present a great problem.

A number of reproduction studies in various species have been conducted with PCBs; usually, embryo toxicity was observed but there were no malformations. Heath et al.[99] were unable to demonstrate an effect on *reproduction* with dietary levels of 25 and 50 ppm of Aroclor 1254 in mallards and bobwhites. An increase in eggshell cracking or reduction in shell thickness was also not observed while DDE, which was used as a positive control, induced significant shell thinning and cracking and a reduction in hatching successes in mallards but not in bobwhite.

In field studies with brown pelican shells, it was found that thinning could be best correlated to DDE residues rather than dieldrin or PCBs. This finding indicates, according to Blus et al.,[100] the PCBs are not responsible for eggshell thinning in most birds following environmental exposure.

Peakall[101] fed ringdoves 10 ppm Aroclor 1254

MONS 200528

for 6 months. He injected others with 160 mg/kg intraperitoneally for 4 days, and evaluated the shell eggshell weights of these birds. He found no difference in eggshell thickness between the experimental and the control groups.

In a pheasant reproduction study with Aroclor 1254,[102,103] a significantly greater difference in the number of eggs that were pipped but not hatched was found in the group of hens that received 50 mg of PCBs weekly. Egg production and hatchability was lower in this group, the survival of chickens that did hatch at six weeks of age was reduced, and the ones that did survive were significantly lighter than the controls.

Aroclor 1242 at 10 ppm or 100 ppm and Aroclor 1254 at 100 ppm in the diets of chickens did reduce egg production and hatchability and caused thin eggshells, while Aroclor 1242 at 1 ppm, Aroclor 1254 at 10 ppm, and Aroclor 1260 at 100 ppm did not affect reproduction in chickens.[104] In a rat reproduction study, decreased survival of pups at a dietary level of 100 ppm of either Aroclor 1242 or 1254 was observed. The results obtained from the reproduction studies in birds particularly seem to indicate that the lower chlorinated biphenyls affect reproduction more than the higher chlorinated biphenyls, and it is very important to determine whether the lower chlorinated biphenyls that have been suggested as replacements for presently employed chlorinated biphenyls have an effect on reproduction.

In another rat reproduction study[94] the lowest dose of Aroclor 1254 that affected reproduction was 20 ppm (1.5 mg/kg/day) which manifested itself in a decreased number of litters and less pups per litter. Neither 1 ppm nor 5 ppm of Aroclor 1254 had an effect on reproduction in the Sherman strain rat; however, an exposure of the dams to the Aroclors at 5 ppm or higher increased the liver-to-body weight ratios in weanling rats of both sexes. At 1 ppm the increase in liver weight was observed only in F1a and F1b weanling *male* rats. The dietary levels of 100, 20, and 5 ppm of Aroclor 1260 did not affect reproduction; however, the liver-to-body weight ratio of 21-day-old pups was increased at all exposure levels.

Mink are highly susceptible to the toxic effects of PCBs. A daily dietary intake of 30 ppm resulted in death in about 6 months. Exposure to 5 ppm Aroclor 1254 in the daily diet severely affected reproduction.[105]

Unfortunately, it is often very difficult to compare the various dietary levels that affect different species, since the food consumption may vary decisively from one animal species to another and the daily food intake in g/kg body wt, is often not included in the scientific report. Some mice strains, for instance, will be exposed to as much of a given substance that is present in the diet at the concentration of 300 ppm as rats on a diet containing 600 ppm or more. With some species it is of course difficult or almost impossible to measure the food consumption, but a greater effort in establishing these very basic facts would be helpful for the interpretation of toxic effects in different species.

Not very much is known at present about the toxicity of *terphenyls* or *chlorinated terphenyls*. These materials have not been studied to any great extent. The few studies that are available only describe very specific effects such as microsomal enzyme induction in the liver and give no overall evaluation of their toxicity.

The most toxic of the various *chlorinated dibenzodioxins* and *dibenzofurans* is 2,3,7,8-tetrachlorodibenzodioxin which, in the German literature, is sometimes referred to as 2,3,6,7-tetrachlorodibenzodioxin. Single oral LD_{50} values are female rats: 44.7 μg/kg; male rats: 22.5 μg/kg; male guinea pigs: 0.72 μg/kg; rabbits: < 30 μg/kg; and dogs: between 30 and 300 μg/kg.[106] It is possible that young animals are more susceptible to the toxic effects of this compound than older animals and LD_{50} values should therefore also be determined in weanling animals. One of the characteristics of this compound was that it caused delayed death, sometimes as delayed as 40 days after a single dose. During the period of intoxication, the animals lost a great deal of weight.[106]

On the other hand, 2.0 g/kg of dichlorodibenzo-p-dioxin and 4.0 g/kg body weight octachlorodibenzo-p-dioxin were not lethal to rats. Hexa-, hepta-, and trichlorodibenzo-p-dioxin were more toxic.[106]

Schulz[107] in earlier experiments found that oral doses of 20 to 50 μg/kg/body weight of 2,3,7,8-tetrachlorodibenzodioxin resulted in fatal liver necrosis in rabbits. More recently Milnes[108] reported that 10 μg/kg was lethal to rabbits.

The 2,3,7,8-tetrachlorodibenzodioxin has a variety of specific toxic effects. Whether these effects vary in different species is presently not well defined. With the interest in this and the other related compounds, more information on

NOMS 200529

their toxicity probably will soon become available. The problems inherent in studying these compounds are the unavailability of some of them, the fact that they may not be completely pure, particularly the hex- and hepta- preparations, and of course with respect to the tetrachlorodibenzodioxin, its extreme toxicity, which makes it difficult to handle.

In contrast to PCBs, teratogenic as well as fetotoxic effects have been reported for 2,3,7,8-tetrachlorodibenzodioxin. Sparschu et al.[109] gave 0, 0.03, 0.125, 0.5, 2.0, and 8.0 μg/kg/day of 2,3,7,8-tetrachlorodibenzo-p-dioxin to pregnant rats on days 6 to 15 of pregnancy. With the 0.03 μg/kg dosage level, an effect on the fetus was not observed, but doses from 0.125 μg/kg on up resulted in fetal mortality, early and late resorptions, and fetal intestinal hemorrhage. Khera and Ruddick[110] gave doses ranging from 16 to 0.125 μg/kg to Wistar rats on days 6 to 15 of pregnancy. These authors also observed pronounced fetotoxicity at all dosage levels except 0.125 μg/kg. The affected fetuses showed cerebral and intestinal hemorrhage as well as subcutaneous edema at autopsy. The offspring of mothers given 0.5 and 1 μg/kg of the tetrachlorodibenzo-p-dioxin gained less weight during their suckling period and their survival to weaning was reduced. This could have been caused by the intrauterine effect of the dioxin or by excretion of the dioxin in the milk of the dams given the material during pregnancy. Courtney and Moore[111] observed cleft palates in 3 strains of mice given 3 μg/kg TCDD subcutaneously from days 6 to 15 of pregnancy and an increased incidence of kidney anomalies. Hydronephrotic kidneys were also produced in mouse pups that were nursed by dams treated with TCDD during pregnancy or at time of parturition.[112]

The 2,3,7,8-tetrachlorodibenzo-p-dioxin is extremely toxic in the chick embryo assay.[52] In the rat, hexachlorodibenzodioxin caused fetotoxic effects at 1 and 10 μg/kg and teratogenic effects at doses of 100 μg/kg.[106] Harris et al.[113] gave female rats daily doses of 0.1, 1, or 10 μg/kg TCDD for 31 days. Rats given 10 μg/kg lost weight and most of them were moribund within 3 weeks. Weight gain was also less at the 1 μg/kg dietary level. The rats receiving 0.1 μg/kg were not affected. In experiments with guinea pigs, 9 of 10 animals died after a single dose of 3 μg/kg TCDD, while guinea pigs receiving a single dose of 1 μg/kg gained less weight. All guinea pigs receiving 1 μg/kg/week died within 24 to 32 days and a weekly dose of 0.2 μg/kg depressed their weight. Of the various animal species tested, the guinea pig seemed to be most susceptible to the toxic effects of TCDD.

Reduced thymus and spleen weights were observed in rats that received a single dose of 25 μg/kg TCDD. The rats that died at the various dosage levels showed massive hemorrhages into the heart, liver, brain, adrenal glands, and gastrointestinal tract. Necrosis and ulceration of the glandular part of the stomach were observed. Occasionally organized thrombi were noted and the liver revealed necrosis of parenchymal cells. Sublethal doses of TCDD produced microscopic changes in liver, kidneys, and thyroid. In the kidneys the collecting tubules were primarily affected. Doses of 0.1 μg/kg/day for 31 days, a single dose of 5 μg/kg, and multiple weekly doses of 1.0 and 0.2 μg/kg did not produce changes in rats discernible with the light microscope.

Toxicity studies were conducted in our laboratory with *dichlorophene*.[114] The oral LD_{50} for adult female rats when the material was given in peanut oil by stomach tube was 1,660 mg/kg and in males it was 1,500 mg/kg. The only signs of toxicity observed in these rats were diarrhea and some depression. When 200 mg/kg was applied daily in propylene glycol to the skin of a clipped area of the back of male adult rats as a 12.5% solution, local irritation of the skin with some ulceration resulted but there was no systemic toxicity. The acute intravenous LD_{50} in adult male rats was 16.8 mg/kg when it was given in a saline lecithin suspension. In a two generation rat reproduction study, a dietary level as high as 1,000 ppm (50 mg/kg/day) had no effect. Gross and microscopic examination of the various organs including the brains of the parents as well as the offspring did not reveal any morphological changes that could be related to dichlorophene exposure. These findings indicated that dichlorophene was not very toxic to rats. The great difference between the oral and the intravenous LD_{50} suggested either poor absorption or rapid breakdown of the material in the gastrointestinal tract. Martins[61] lists the acute LD_{50} for guinea pigs as 1,250 mg/kg and for dogs, 2,000 mg/kg. Rats fed for 90 days on a diet containing 2,000 ppm showed no evidence of toxicity.

The acute toxicity of *hexachlorophene* is much greater and varies in different animal species and is

NONS 200530

also dependent on the route of administration and the solvent in which it is given. Gump[114] lists the acute oral LD_{50} in mice as 168 mg/kg and cites LD_{50} values reported by other investigators ranging from 80 mg/kg to 215 mg/kg. Dogs and sheep were more susceptible to the toxic effects of hexachlorophene. The interest in the effect of hexachlorophene on sheep in particular stemmed from the fact that it is effective against liver flukes[116] and advocated for its anthelmintic properties. This even led to the treatment of children with orally administered hexachlorophene in China.[117] Intravenously administered hexachlorophene in rats resulted in an LD_{50} value of 9.1 mg/kg and in rabbits of 8.5 mg/kg.

More recently we found that the oral LD_{50} (single dose) for adult male rats was 66 mg/kg and for adult female rats 56 mg/kg; for weanlings it was 120 mg/kg when the material was given in peanut oil by stomach tube to Sherman strain rats. The acute intravenous LD_{50} was 7.5 mg/kg in adult male rats.[118] Nakaue et al.[119] reported similar oral LD_{50} values in Wistar rats. The single oral LD_{50} for sheep and cattle lies between 30 and 60 mg/kg.[120]

Single dermal LD_{50} values have not been reported in the literature. We found in rats[118] that single applications of 600 mg/kg hexachlorophene in 95% ethyl alcohol solution caused death in 1 of 10 rats. Dermal application of 24 and 48 mg/kg/day for 30 days in propylene glycol or in a detergent as a 3% solution caused ulceration of the skin and affected the white matter of the central nervous system in at least half of the rats. A dose of 12 mg/kg/day as a 1.5% solution caused only mild erythema and desquamation of the skin of rats. No effect on the central nervous system was observed. Whether a single dose given in either propylene glycol or a detergent would be more toxic than one given in ethyl alcohol was not established.

The signs of acute hexachlorophene poisoning following a single oral dose varied with the age of the rats.[118] Adult rats suffered from severe depression and diarrhea, but showed few signs of leg weakness. Weanlings, on the other hand, developed posterior leg weakness as well as depression. The leg weakness became more apparent in the adults when they were given repeated doses of hexachlorophene. Death was usually preceded by convulsions in rats dosed intravenously. In rats killed with hexachlorophene, rigor mortis developed very rapidly and was very pronounced. Body temperature elevation following hexachlorophene poisoning has also been recorded in rats.[119] Both changes, the pronounced rigor mortis and the temperature elevation, may be related to the fact that hexachlorophene uncouples oxidative phosphorylation. Additional symptoms of hexachlorophene poisoning particularly in other species are discussed under neurotoxicity.

Nakaue et al.[119] fed 400 ppm hexachlorophene (28.9 mg/kg/day) to Wistar rats. They developed leg weakness within 5 days, diarrhea, emaciation, and they died in 7 to 10 days. No deaths occurred in the rats that were fed 200 ppm (about 13 mg/kg/day) for 16 weeks.

In a two generation rat reproduction study which we conducted in our laboratory, we found a reduced survival in the offspring of the F_1 generation fed 100 ppm (11.8 to 5.5 mg/kg/day) in their diet for 54 and 166 days. This was statistically significant in the second breeding of the F_1 generation. In the second generation the litters were slightly smaller, but the survival to weaning was not significantly reduced.[118] A dietary level of 20 ppm (2.3 to 1.1 mg/kg) did not influence reproduction. Thorpe[121] reported that the oral administration of hexachlorophene to male rats as well as single doses of 25 and 50 mg/kg hexachlorophene to sheep produced degeneration of spermatogenic cells; multinucleated cells were observed within the tubules of the testes. The doses given by Thorpe were higher than the ones we used in the reproduction study, and microscopic examination of the testes of the rats used in our reproduction study did not reveal any abnormalities. Toxic doses of hexachlorophene given to the dam during pregnancy may result in malformations of the offspring. Thus far, two studies have been reported in the literature; both studies were conducted in rats.[122,123] It should be determined whether malformations can also be produced in other species and with lower doses before any conclusion can be drawn from these findings.

A number of *human* poisoning cases have been reported in the literature and some of these were fatal. Most of the poisoning cases in humans have either been caused by accidental ingestion, because a hexachlorophene detergent solution was mistaken for milk of magnesia, or by the application of hexachlorophene to large areas of burned or otherwise damaged skin.[115,124] Larson[3] was

MONS 200521

the first to recognize that burned patients developed convulsions and other toxic symptoms after repeated exposure to hexachlorophene which was applied to burned areas of the skin. The incidence of convulsions in burned patients decreased when the use of hexachlorophene was discontinued.[125]

Eleven cases have been reported[126,127] in which a single dose of 3% hexachlorophene detergent solution had been taken orally. Gastrointestinal symptoms including nausea and vomiting were observed in ten of these cases; the eleventh case, a child who drank about 250 mg/kg hexachlorophene, became comatose and died. One additional death occurred in this group, however, this was most likely due to other causes. A 17-day-old infant was accidentally given daily oral doses of 37 mg/kg hexachlorophene for 7 days. On the third day the child started to have loose stools. On the fourth day of hexachlorophene administration the child developed spasms of the extremities with twitching of the face, sucking movements of the lips, and lateral shaking movements of the head. It was also noted in the case report that the child refused to take the medicine, there was drooling and frequent vomiting, and it is not quite clear whether the child received 37 mg/kg/day. The child survived. A week after the hexachlorophene suspension was discontinued, persistent spastic flexion of the fingers, hands, and arms was still observed. After a month the hands were slightly flexed at the wrists but were not spastic. Horizontal nystagmus was observed but cleared later. The child was discharged when it was two months and three weeks old. At this point it had shown great improvement and when checked at six months the child was healthy looking.[128] Pilapil mentioned in his discussion a number of other unpublished cases, some of which were reported to the National Clearing House for Poison Control Centers. Among these was the case of an infant who by mistake got a spoonful of PhisoHex in each feeding bottle for approximately two weeks, when it suddenly died.

Chung et al.[117] treated a total of 105 patients 5 to 15 years old with hexachlorophene for clonorchiasis sinensis infestation. Sixty of these patients received 1 dose of 20 mg/kg, 32 received 2 doses of 20 mg/kg/day, 8 patients received 3 daily doses of 20 mg/kg, and 5 patients received 20 mg/kg body weight on the first day and 10 mg/kg on the second day. The toxicity reactions observed in these patients were mainly confined to the central nervous system and to the gastrointestinal tract. The group that received 3 doses of 20 mg/kg/day had the most severe reaction. One patient in this group became comatose on the fourth day with loss of light reflex and positive pyramidal signs. Fundus examination of the eyes revealed mild papillary edema. A low grade fever was also observed. Complete recovery occurred within three days. One half to two thirds of the patients had diarrhea within 1 to 2 hr after medication and in some cases a marked depressive effect on the central nervous system was also observed. An additional case of poisoning after oral ingestion was reported by Korlof and Winsten[129] in Scandinavia and two fairly recent cases with fatal outcome occurred in the U.S.[130]

Herter[131] was probably the first to report a human poisoning case caused by the dermal absorption of hexachlorophene. Because of a language barrier, the mother of a newborn infant applied 3% hexachlorophene as a lotion after the infant's bath without rinsing the baby. After four days, excoriations appeared on the child's face and buttocks, the infant developed convulsions, his face twitched and his extremities jerked. A roving nystagmus was present. This child recovered within 16 days after exposure to hexachlorophene had been discontinued.

In addition to the two cases already mentioned in which poisoning occurred because of oral ingestion, Mullick[130] also reported four cases – children who died following the treatment for burns in two instances and the treatment for severe ichthiosis with a 3% hexachlorophene bath.

Larson[3] reported six burned patients who developed central nervous system symptoms following the dermal exposure to hexachlorophene. All six patients recovered. Korlof and Winsten[129] reported two cases of poisoning following the dermal application of hexachlorophene. Both patients were fairly extensively burned, and developed central and peripheral nerve damage as well as some kidney impairment.

Lockhart[132] mentioned six deaths that were reported to the FDA caused by the topical application of hexachlorophene on burned patients. In all of these cases the skin was damaged, probably enhancing absorption of hexachlorophene, and although skin does represent a barrier, it is not impermeable – a fact we tend to forget at times. Damaged or abnormal skin may be

MONS 200532

more permeable, and the skin of prematures, newborns, and children in general may have absorption characteristics other than those of adult human beings, another factor that is often neglected. Recently[133,134] 41 deaths due to hexachlorophene poisoning have been reported in France. The deaths occurred in infants who were treated with a powder to which 6% hexachlorophene had been added by mistake. This powder was mainly applied in the diaper area where the skin became inflamed, this as well as the diaper which served as an occlusive dressing, probably enhanced absorption. These cases will not be made public until litigation problems have been settled.

Little published information is available on the toxicity of the germicides in Figure 2 aside from hexachlorophene and dichlorophene. The acute oral LD_{50} for triclosan (TCC) in mice and rats is about 4,000 mg/kg.[135] The acute subcutaneous toxicity for rats was 14,700 mg/kg and the acute dermal toxicity was about 9.3 g in rabbits. Concentrations of 1 to 5% solutions caused eye irritation in rabbits. Daily oral doses of TCC up to 1,000 mg/kg/day for 4 weeks did not produce an effect in rats. When 2.5 and 5% suspensions in gum arabic were applied dermally to rats for 4 weeks, the animals did not gain as much weight. Unpublished material cited in the minutes of the OTC (Over the Counter Drugs) Panel listed a "no effect" level as 170 mg/kg/day in rats and for a 90-day feeding study in rabbits, 138 mg/kg/day. In baboons a daily oral dose of 100 mg/kg/day did not produce a toxic reaction. The minutes also mentioned some work where lower doses showed an effect on rats and dogs. Since some of these results are conflicting, further studies are indicated and should be performed with products used as ingredients in soaps; a chemical analysis of these products is necessary to determine whether impurities might be responsible for varying results. Chloroaniline as a result of heating during manufacture could be present as such an impurity. Of the anilines, according to Hamblin,[136] only p- and m-chloroaniline may cause methemoglobinemia if absorbed through the skin. The o- and m-chloroaniline may cause liver and kidney damage. Triclosan itself is also absorbed through the skin and absorption is greater when applied to damaged skin.

SPECIAL TOXIC EFFECTS

Skin Reactions

Chloracne

This occupational skin disease can be produced by a number of chemical compounds.[137] Polychlorinated biphenyls as well as the chlorinated naphthalenes, a few isomers of the chlorinated dibenzodioxins, and chlorinated dibenzofurans are all able to produce chloracne in a certain proportion of the human population. Oily skin and large pores seem to predispose to the disease while the opposite is true for smooth, tender skin and it is possible that young children might be less susceptible because of the nature of their skin.

Chloracne has also occurred in workers engaged in the production of 2,4,5-T[1]. During the industrial production of trichlorophenol a sudden rise in temperature within the reactor has occasionally resulted in accidents. In one instance this exothermic reaction caused an explosion.[138] When the rise in temperature occurred, 2,3,7,8-tetrachlorodibenzodioxin was formed and severe outbreaks of chloracne were observed among the workers.[137a]

The term chloracne was first used by Herxheimer in 1899,[138] who thought it was caused by free chlorine generated in certain factories. Wauer in 1918[139] and Teleky in 1927[140] suggested the term "Pernakrankheit." Another term sometimes used is halogenwaxacne.

As the word chloracne implies, part of the lesion of this occupational skin disease resembles adolescent acne; however, it is generally more severe and the distribution of the lesions is not consistent with adolescent acne, although it may be superimposed on adolescent acne. Chloracne is described in the literature as consisting of the formation of comedones with or without cysts and pustules. The follicular orifices are filled with sebaceous and keratinous material. Melanosis and a secondary inflammatory reaction may also exist. In addition to this description, skin changes occur that have been discussed less frequently in the more recent literature. These skin changes are usually referred to as cable rash or cable itch. Cable rash has been observed in workers who have insulated cables with various mixtures of chlorinated naphthalenes and chlorinated biphenyls and in workers handling these cables.[141] It has been observed also in factories that make condensers.[142,143] According to Braun,[142] a few days

MONS 200533

the cases with manifest chloracne started with changes in the skin of the face resembling photo sensitivity and the bearers of these lesions suffered severe pruritus in the areas of the skin lesions. This lesion termed cable rash occurred predominantly on the cheeks but also on the skin of the arms. The outcome of cable rash varied; it could either disappear or it could develop into full-blown chloracne.

In addition to the pustules and comedones of typical chloracne, brownish keratinization of the skin was observed in some patients. Braun[142] pointed out that the workers, particularly those with poor hygiene, transmitted the disease to their spouses and children through direct contact.

Many of the occupational cases of chloracne that have been reported in the literature have been reviewed previously.[137,144] Jones and Alden[145] reported one of the first outbreaks of chloracne in a company that was engaged in the manufacture of chlorinated biphenyls. They described one typical case and mentioned 24 men working on the manufacture of chlorinated biphenyls; 23 had had an acneform eruption on the face and body. Particularly during the 1930s and 1940s large outbreaks of chloracne occurred in a number of factories.

Much discussion has been devoted in the literature to the problem of whether the chloracne was produced by external contact alone or whether it was caused by systemic absorption, particularly the inhalation of vapors. One question asked was whether internal administration could cause chloracne, and if so what part it played in any particular case. As we know now from outbreaks of poisoning due to the consumption of rice oil that was contaminated with polychlorinated biphenyls in Japan (see under "Yusho"), chloracne can be produced by the systemic absorption of chlorinated biphenyls. The experiments by Shelley and Kligman[146] and Plewig[147] showed that the skin lesions could also be produced by applying the chloracnegenic compound to the skin.

After occupational chloracne manifested itself, the patients also complained of systemic effects such as loss of appetite, nausea, edema of the face and hands, abdominal pain, vomiting, and burning and soreness of the eyes. Particularly with the chlorinated naphthalenes, hepatotoxic effects have also been observed. Application of chemicals to the skin can lead to their absorption and cause systemic toxicity. Whether a systemic toxic effect results will depend on the skin surface area covered, the amount of the toxic substance applied, and the ability of the skin to absorb it. If dermal absorption is poor, a single application will usually not be very toxic. However, if the compound is not easily metabolized and excreted, repeated dermal application may result in sufficient accumulation in the body to cause systemic toxicity.

Crowe[144] has pointed out that chloracne due to chlorinated naphthalenes has decreased because these compounds have been used less since the Second World War. However, Weber in 1969[143] reported an outbreak of chloracne in a company engaged in the production of electric coils that were coated with a mixture of chlorinated naphthalenes with the trademark "Nibrenwax."

Detailed examination by several German investigators indicated that the capacity of 2,4,5-trichlorophenol as well as 2,4,5-T (2,4,5-trichlorophenoxyacetic acid)[149,150] to produce chloracne was due to contamination with 2,3,7,8-tetrachlorodibenzofuran or 2,3,7,8-tetrachlorodibenzodioxin.

Schwartz et al.[151] indicated that the most potent chloracne producing agents were the chlorinated naphthalenes, chlorodiphenyls, and chlorodiphenyloxides. Persons who worked with chlorinated naphthalenes usually developed acne after a month or more of exposure.

Light microscopic observations made of the chloracne lesions of humans varied somewhat, depending primarily on the length of time the lesions had existed at the time of examination. The earliest change encountered consisted of acanthotic widening of the external root sheath of the hair follicle. Above a layer of basal cells 6 to 10 layers of large round cells were observed, followed by a layer of 2 to 3 cell rows of granular cells. In later skin biopsies, folding of the basal layer occurred and comedo formation was observed, resulting in dilatation of the follicle and atrophy of the epithelium surrounding the comedo. The contents of the follicles consisted predominantly of keratinous material rather than sebum. The sebaceous glands also underwent changes. Within the alveoli of the glands the basophil cells increased in number and basal cell hyperplasia was noted. The ducts of the sebaceous glands were filled with a solid mass of basophil epithelial cells. The sebaceous glands gradually

NONS 200534

disappeared and in later secretions were only recognized as solid protrusions of the comedo wall. Aside from atrophy of the sebaceous glands, hyperplasia has also been described and many large sebaceous glands forming huge cysts filled primarily with keratinous material have been observed. Hyperkeratosis and acanthosis of the surrounding epidermis has usually accompanied these lesions. Foreign body granulomata which are thought to result from rupture of the follicular cysts have been found in the skin.[147,151] In the Japanese poisoning incident (Yusho), the predominant skin lesion was marked hyperkeratosis of the epidermis, cystic dilatation of the hair follicles, and an increase in the melanin pigment in the basal cells of the epidermis. Foreign body granulomata were also observed. The contents of the cysts consisted partially of keratin. In a stillborn child the hyperkeratosis was even more pronounced, accompanied by atrophy of the epidermis; cystic dilation of hair follicles was observed, especially in the skin of the head. According to earlier reports[151] some differences exist in the microscopic changes observed in the skin following exposure to the various chlorinated cyclic compounds that can produce the lesion. It is, of course, possible that these histopathologic variations are in reality only differences that exist between an early, a well-developed, and a subsiding lesion.

Many theories have been advanced to explain the development of chloracne. None is satisfactory. The concept of mechanical plugging of the hair follicles on skin exposure to polychlorinated polycyclic compounds is not supported by the fact that chloracne develops following ingestion of these compounds. It is possible that the skin lesions are caused by a toxic effect on the epithelium of the skin and its appendages which is manifested in proliferation and loss of normal function of the cell. Since the chemicals are lipid soluble they could occur in a more concentrated form in sebum and therefore affect sebaceous glands more than sweat glands or salivary glands. The reports on the Yusho outbreak suggest that proliferation of the epithelium of the mucous membranes may also occur. The increased pigmentation of the skin and mucous membranes may indicate a functional disturbance resulting in increased melanin production. Hyperpigmentation is also observed when the adrenals are damaged, as in Addison's disease, and adrenal function should be investigated in chloracne patients who manifest hyperpigmentation.

In none of the human case reports on chloracne have the mucous membranes been studied to any great extent. Vaginal smears in women and sputa, corneal, and nasal scrapings may give helpful information in this respect. Since in animals exposed to polychlorinated polycyclic compounds low vitamin A levels have been observed in the liver, it is possible that the compounds may affect vitamin A absorption and storage, and adequate utilization in the liver and elsewhere in the body. If the lesion is produced by inadequate utilization of vitamin A, then administration of vitamin A per se may not necessarily alter the course of the disease. Protein deficiency may also mimic hypovitaminosis A in that it affects transport of vitamin A. The liver stores 90% of the available vitamin A and these stores may be affected in liver disease. The microscopic appearance of the skin lesions resembles in some respects observations made in skin of patients suffering from vitamin A deficiency. In vitamin A deficiency, hyperkeratosis of the hair follicles is observed. Multiple firm papules may develop as a result of the keratin plugs in the sebaceous glands. Dryness and scaliness as well as furunculosis of the skin may also be present. In contrast, night blindness has not been reported as a symptom in patients suffering from chloracne. Unfortunately, chloracne outbreaks are often not well investigated and, because of problems with litigation, accounts are often only published many years after the outbreak has occurred if they are published at all.

Chloracne is a very persistent skin disease and in the Japanese outbreak of poisoning with chlorodiphenyls, the skin changes were still present in a number of patients three years after exposure to the chlorodiphenyls had been discontinued. What needs to be investigated is whether this persistence of the skin disease is caused only by the fact that once the lesion has developed it regresses very slowly, or whether it may be sustained by the chloracne-producing chemicals which have been absorbed and stored in the body, particularly the adipose tissue, and are only very gradually excreted. In patients with chloracne, adipose tissue biopsies should be analyzed for the presence of the offending polycyclic polychlorinated compounds. If adipose tissue is unobtainable, the sebum of the ear canal or the content of the skin lesions may represent a good substitute.

NOMS · 200535

Apparently there is no known effective treatment for chloracne and the best control measure is prevention. The manufacture of chlorinated hydrocarbons and the coating of wires and condensors with insulating materials containing them should be done in totally enclosed areas so that the fumes of the insulating substances and of the solvents if any are used do not come in contact with the workers. The workers should be provided with clean overalls and underclothes daily. These should be laundered at the plant and cleaned in such a way that no chlorinated hydrocarbons remain on them. Shower baths after work should be compulsory and supervised and there should be sufficient shower facilities provided so that the workers are not unduly delayed after work. Special synthetic wetting agents[151] seem to remove the material from the skin more effectively than ordinary soaps.

The experimental induction of chloracne in men has also been accomplished with 2 applications of 10 μg 2,3,7,8-tetrachlorodibenzo-p-dioxin[107] and with Halowax 1014, pentachloronaphthalene, and hexachloronaphthalene.[147]

Experimental work in animals has shown that most species do not develop the same type of dermatitis. The rabbit's skin,[152] particularly the inner aspect of the ear lobe, provides a good test medium for the development of acneform dermatitis. The rabbits, in addition to the development of hyperkeratosis of the ear, will also show a hepatotoxic effect.[150] Microscopic examination of the changes in the rabbit ear were described by Jones and Krizek.[153] Inagami and Koga[154] were able to produce hyperkeratosis in hairless mice that were fed rice oil contaminated with Kaneclor 400. These mice also showed hepatomegaly. Microscopic examination of the skin revealed cystic dilation and hyperkeratosis of hair follicles and sweat glands. Hairless mice may be another suitable experimental animal for testing the effect of these chemicals on the skin.

X-disease in Animals

Chloracne-type lesions do not usually occur in other species except for the rabbit and the hairless mouse, already mentioned. However, in 1947 Olafson[155] described a disease in cattle which was designated as *X-disease* or hyperkeratosis. Symptomatology included excessive lacrimation, diarrhea, polyuria, marked salivation, and discharge from the nostrils. The animals developed a chronic cough, poor appetite, numerous red maculae in the buccal mucosa; in addition, hyperkeratosis of the skin developed. The skin was hard and fissured particularly across the withers and sides of the neck. Many wart-like proliferations on the lips, tongue, and hard palate were also observed. The abomasum was greatly inflamed, swollen, and edematous with many superficial ulcers.[156] In the cows that had X-disease, a low vitamin A plasma level was also observed, which again indicates that vitamin A may play a role in the etiology of these various disease entities.

The disease was first thought to represent a virus infection and other factors were also suspected. After numerous investigations it was finally established that X-disease could be produced in cattle by the ingestion of highly chlorinated naphthalenes, and also by petroleum products such as crankcase oil. Bell[157] tested the ability of the various compounds of the chlorinated naphthalene group to produce X-disease. He demonstrated in his studies that dichlorinated and trichlorinated naphthalenes did not result in X-disease, while tetrachloronaphthalene had an effect and the higher chlorinated naphthalenes such as pentachloronaphthalene, hexachloronaphthalene, heptachloronaphthalene, and octachloronaphthalene caused severe disease. Octachloronaphthalene was less toxic than hexa- and heptachloronaphthalene. Wagener[158] reported the occurrence of hyperkeratosis in cattle in Germany between 1946 and 1948. The cause of this outbreak was traced to a wood preservative which was used in postwar Germany. The author proved experimentally that animals housed in cabins painted with the wood preservative developed typical X-disease. The poisonous ingredient in the wood preservative appeared only in certain lots of this product and later lots did not contain it. The poisonous ingredient was never identified by chemical analysis.

Animal experiments were conducted with the toxic ingredients of rice bran oil that produced Yusho in Japan. These toxic substances consisted of a mixture of chlorinated biphenyls containing 48% chlorine, with a trace of 0.01% of naphthalenes.[159] When mice were exposed to them for 3 to 4 months, they showed eczematous changes of the skin around the eyelids, erosion, ulceration and perforation of the ear lips, loss of hair, and erosion and ulceration of the skin around the neck, forelegs, and sides of the chest. The authors

MONS 200536

ported that, at the end of the experiment, some changes in the skin similar to those in the experimental mice were seen in some of the control mice also, which makes it difficult to interpret their findings.

In 1957 a disease that will be discussed in greater detail later in this article occurred in a large number of chickens. It was termed chick edema disease and was found to be caused by certain oils fed. Allen and Carstens[160] fed this substance to monkeys and found that, among other changes which will be discussed later, the monkeys developed a generalized alopecia and subcutaneous edema one to two months before death. Schoettle et al.[161] produced hyperkeratosis of the skin in cats by feeding them hexachloronaphthalene. Young swine[162] and sheep[163] did not develop skin lesions as a result of exposure to chlorinated naphthalenes.

Photocontact Dermatitis and Irritation of the Skin

As was pointed out earlier, the hyperpigmentation observed in patients with chloracne as well as the reaction described as cable rash could also be the result of a photosensitive reaction. This photosensitive reaction is the predominant lesion in the skin produced by a number of germicides, namely, bithionol (Figure 2), tetrachlorosalicylanilide (TCSA), and a number of other halogenated phenolic compounds including fentichlor. Patients who develop photodermatitis complain initially of a burning sensation, and this is followed by itching. A rash develops which in the beginning is erythematous and associated with varying degrees of edema. As it subsides, pigmentation is observed.[164] Wilkinson[165] was the first one to describe cases where patients developed a photo allergy which was due to the incorporation of TCSA into popular soaps. He observed that the outbreak of dermatitis was confined to the areas that usually were exposed to light. Most of the cases reported from England were transient and as soon as exposure to the compound was discontinued the reaction subsided. Jillson and Baughman[166] and Jillson,[167] on the other hand, reported that their cases were more persistent.

Willis and Kligman[168] demonstrated that the photocontact allergy of the skin with these various compounds was simply a contact sensitization. The reason that allergic reactions of the skin developed only after exposure to the sun was due to the photodecomposition of the various products to which the skin had been exposed. If various brominated and chlorinated salicylanilides were irradiated in vitro in an appropriate solvent, the resulting breakdown products caused an allergic reaction on contact, without exposure to UV light. These studies were performed because of information provided in earlier studies by Coxon et al.,[169] who had irradiated brominated and chlorinated salicylanilides and found that these compounds gave off halogens. With 3,5 substituted salicylanilides, the halogen substituted on the 3 position was lost. Tetrachlorosalicylanilide photosensitized subjects reacted to 3', 4', 5-trichlorosalicylanilide and to 3', 4'-dichlorosalicylanilide. A reaction to nonhalogenated salicylanilide was not observed. Halogens on the anilide ring were unaffected by UV radiation, while the halogens on the salicyl ring were replaced stepwise by hydrogen upon irradiation.

Among the patients who developed photosensitivity to tetrachlorosalicylanilide reported by Wilkinson,[165] a group of patients in a shop of a factory was also included. This same outbreak was reported by Jones,[170] who found that among 106 employees who used the same soap very frequently, 31% were affected by a dermatitis due to contact with tetrachlorosalicylanilide present in the soap.

Additional cases of photodermatitis due to the exposure to tetrachlorosalicylanilide were reported by Calnan et al.,[171] who pointed out that pronounced edema of the eyelids was also observed when involvement was severe. Some cases were persistent or developed acute relapses on further exposure to sunlight without further exposure to the offending chemical. Frenk[172] reported an additional nine cases of acute contact dermatitis of the hands due to tetrachlorosalicylanilide. Epstein[173] described a photoallergic reaction in two patients to tribromosalicylanilide (TBS). With patch tests these patients showed a cross reaction to TCSA. A similar cross reaction pattern to a number of halogenated salicylanilides was also observed by Osmundsen[174] in patients who had developed photodermatitis following exposure to tribromosalicylanilide.

Because of the photosensitivity reactions and the cross reactions that were also found with bithionol, which is similar in structure to tetrachlorosalicylanilide (Figure 2), the U.S. Food and Drug Administration, on October 24, 1967, withdrew all new drug applications of all drugs that

MONS 200537

contained bithionol. In the notice of withdrawal of approval in the Federal Register, the Commissioner of the Food and Drug Administration pointed out that bithionol may in some instances cause a very persistent photosensitization and severe dermatitis may occur with exposure to sunlight without further contact with the sensitizing articles, and that bithionol may produce cross photosensitization with other commonly used chemicals such as certain halogenated salicylanilides and hexachlorophene.

Hexachlorophene preparations may also cause irritation of the skin if these preparations are used frequently. A true allergic reaction to hexachlorophene is apparently rare.[175] The more severe reactions were usually confined to the skin of the scrotum and consisted of a primary irritant contact dermatitis.[176,177] The cases reported by Baker et al.[176] also included a 33-month-old Caucasian female who developed a rash around the buttocks, vulva, and upper thighs following the use of a hexachlorophene preparation in her bath water.

We observed severe skin irritation and ulceration in rats that were exposed dermally to a 3% hexachlorophene solution in propylene glycol or a detergent. The skin reaction was not as severe when the hexachlorophene concentration was reduced to 1.5%.[114] Boutwell et al.[178] reported considerable skin irritation in mice that had 5 mg/mouse applied twice weekly for 21 weeks. Harber et al.[179] were able to induce contact photosensitivity with TCSA or TBS. These authors also found that cross contact sensitivity and photosensitivity to hexachlorophene existed in guinea pigs with primary photosensitivity to TCSA and TBS. Photosensitivity to trichlorocarbanilide (TCC) was not produced in guinea pigs.

The guinea pig may represent a suitable animal species to study contact and photosensitivity of these and related compounds. After exposure to the photosensitizing agents has been discontinued, humans may still be sensitive to sunlight, a fact that needs further study. To a certain extent this could be due to a persistence of the chemical compound on or in the skin.

Dichlorophene used as an antimicrobial preservative may also cause contact dermatitis. Cross-sensitivity to hexachlorophene was not demonstrated.[180]

Chick Edema

Simpson et al.[181] and Sanger et al.[182] described a new highly fatal disease in chickens. The first outbreak occurred in 1957 in Georgia. Large numbers of birds from approximately three weeks of age to adult laying hens were affected. Clinical signs consisted of dyspnea, reduced body weight gain, stunting, subcutaneous edema, paleness, and sudden death. In young chickens, gasping was the first noticeable sign. This was followed by a waddling, unsteady gait. Gross inspection of the birds revealed a pale heart, fluid was noticed in the pericardial sac, and the livers were pale, mottled, and had an irregular granular surface. In advanced stages of the disease the chickens had large distended abdomens that were filled with fluid. Ecchymotic hemorrhages were present in the skin beneath the wings, on the legs, and over the Q bone in a few chickens. The kidneys were pale and swollen. Following the first outbreak, no additional cases were reported until late summer and early fall of 1957, when extensive losses of chickens and turkeys occurred throughout the southeastern part of the U.S. Suspicion soon developed that losses were caused by the consumption of rations containing certain lots of animal fat.[181] The animal fats contained tallows and greases obtained as by-products from hides preserved with chlorophenols prior to leather manufacture.[51]

This material was excluded from commercial poultry rations and no additional cases occurred where animal fats were responsible. Simpson et al.[181] came to the conclusion that the edema in the chickens was the result of vascular changes that seemed to be the primary lesion. The vascular lesion, or endotheliosis, consisted of proliferation and hypertrophy of the endothelial cells of arterioles and small arteries in most tissues. Pronounced proliferative changes in endothelium of the glomerular capillaries were observed, but no significant changes were noticed in the tubular epithelium of the kidney. Necrosis of the parenchymal cells of the liver was also noted.

In some reports it was pointed out that exposure to toxic fat resulted in a decrease of the total serum protein and a shift on the albumin to globulin ratio with a decrease in the albumin fraction. This could, of course, lead to edema formation, particularly when combined with malfunctioning glomerular capillaries. It has also been suggested that increased permeability of the cardiovascular bed contributed to the edema forma-

NCNS 200538

[illegible][184,185] In other studies the serum protein concentration did not differ from that of the controls[184,185] and increased permeability of the cardiovascular bed was advanced as the sole cause of the fluid accumulation. In addition, pulmonary edema was observed in diseased chickens and perivascular lymphocytic infiltration as well as edema of the cardiac muscle with interstitial lymphocytic infiltration has been noted.[186] Electron microscopic examination of the cardiac muscle revealed degeneration and loss of mitochondria.[184] It is possible that the heart may play a primary role in the development of chick edema, but a hepatorenal syndrome could be the underlying cause as well. Studies that investigate the development of the lesion more closely are needed to elucidate these problems. The type of diet also influenced the development of the disease. It could be brought on more rapidly with a semi-purified diet than with a natural grain ration; sodium chloride in the diet was a prerequisite for the development of the syndrome.[187]

If low rations of the toxic fat were fed to chickens they did not develop chick edema but egg production and hatchability were drastically reduced.

Toxic fat was not the only product that caused the chick edema syndrome. Chlorinated biphenyls caused the disease in chickens[188] and in Bengalese finches.[26] A mixture of pentachloronaphthalene and hexachloronaphthalene fed to chickens also resulted in chick edema disease.[189] Cantrell et al.[190] announced in 1967 that one of the toxic compounds capable of producing chick edema found in toxic fat was 1,2,3,7,8,9-hexachlorodibenzo-p-dioxin. Then Higgenbotham et al.[82] showed that the chick edema factor was produced by two principal compounds isolated from toxic fats: 2,3,7-trichlorodibenzo-p-dioxin, and 2,3,7,8-tetrachlorodibenzo-p-dioxin. They also suggested fats and fatty acids that contain commercial chlorophenols as possible sources of contamination. When crude fats and tallows are heated to produce fatty acids, chlorophenol residues may be converted to a chick edema factor. Whether these last three compounds mentioned are the only ones that produce chick edema disease is questionable unless the chlorinated naphthalenes as well as chlorinated biphenyls that produced chick edema were also contaminated with them. Another outbreak of chick edema disease occurred in 1969.[51] In this incident millions of birds in North Carolina were involved. The outbreak was traced to a vegetable oil refinery where feed fat became contaminated with "chlorophenols." The company formulated the chlorophenols as antimicrobial water treatment products. An underground pipeline from the "pesticide" plant led to traps used to collect by-product fatty acids held as feed fats.

Flick et al.[185] have recently shown that pyrolytic products of 2,3,4,6-tetrachlorophenol were toxic to chicks and produced chick edema if 50 ppb were fed for 21 days. The product fed consisted of 53% hexa-, 45% hepta-, and 25% octachloro-p-dibenzodioxin. The pyrolytic product of pentachlorophenol consisted of a mixture of 5% hexa-, 62% hepta-, and 33% octachlorodibenzo-p-dioxin that produced mild edema and increased mortality when fed a diet containing 1 ppm (200 μg total ingestion) of the material for 21 days. When a mixture of tri- and tetrachlorodibenzo-p-dioxin was fed to the animals at a dietary concentration of 0.01 ppm (a calculated intake level of 1.9 μg), the birds developed edema and 83% of them died. Further studies with pure compounds are necessary to confirm these findings.

The effect of PCBs on the chicken was again demonstrated when PCBs that were used in the U.S. as heat transfer fluids in food processing plants contaminated large quantities of fish meal that was processed for animal feed in a plant in Wilmington, North Carolina.[191] From about April 1971 until July 1971, PCBs leaked into the fish meal and 16 thousand tons of contaminated fish meal were distributed to more than 60 companies in 10 states. One of the purchasers of the fish meal, The Holly Farms, the nation's largest poultry producer, had to slaughter 77,000 fowls after discovering contamination of the chickens with PCBs. Some of the levels found in the adipose tissue of the animals were as high as 40 ppm. The Holly Farms first discovered that the chicken meal was contaminated because the hatchability of their eggs was drastically reduced to 18% of normal.

In February and March of 1968 an outbreak of chick edema also occurred in Japan, where more than 400,000 chickens reportedly died. The disease was traced to the contamination of animal feed with Kanechlor 400, a Japanese PCB. The chick edema disease occurred simultaneously with an outbreak of polychlorinated biphenyl poisoning in people that was due to the contamination of

rice bran oil, also contaminated with Kanechlor 400 and produced by the same company.[192]

Metcalfe[193] suggested that chick edema factor could be minimized if fleshings grease from hides preserved with technical pentachlorophenols containing chlorinated dibenzodioxins were no longer used for food products. It was also pointed out that the use of glue emulsions containing chlorophenols in rendering operations is another possible source of the toxic factor. Whether elimination of these sources from animal food products will prevent chick edema epidemics remains to be seen, since polychlorinated biphenyls that may be contaminated with chlorinated dibenzofurans have also produced chick edema disease.

Yusho

During the summer of 1968, 13 cases of chloracne were observed in the western part of Japan, centering around Fukuoka prefecture. The incidence of the disease seemed to be familial and it became apparent that all patients had used the same brand of cooking oil (canned Kanemi rice oil). These findings were picked up by the newspapers and a strong demand was voiced to elucidate the cause. Therefore, a Yusho study group was established by Kyushu University.[192] The term Yusho stands for rice oil disease. After extensive investigations it was found that several illnesses occurred in a number of households that had used common cans of rice bran oil.

When a total number of 89 males and 100 females that suffered from Yusho were examined, a variety of symptoms were found in these patients. The incidence of the different symptoms that varied a great deal is given in Table 2. The epidemic outbreak was finally, after very extensive investigation, pinpointed to Kanemi oil, manufactured on February 5, 1968. Chemical analysis of this oil established that it was contaminated with 2,000 ppm of Kanechlor 400, a chlorobiphenyl that contains 48% chlorine. It was also demonstrated that most of the components of the chlorobiphenyls were stored in adipose tissue of the patients for quite a long time and passed through the placenta into the fetus of a few women who happened to be pregnant.[194]

The amount of oil necessary to produce disease was found to be at least 2.5 l. The younger the patient, the higher the morbidity rate with a smaller total amount of ingested oil. The average amount of chlorobiphenyl consumed by individual patients was calculated to be a total of 2 g.[191] (Various reports written on this subject give different accounts of what actually was consumed, and the amount can at best only be estimated.)

When the rice bran oil was heated under reduced pressure, Kanechlor leaked from the old pipes in which holes were subsequently discovered.

The Yusho outbreak spread not only over Fukuoka, Japan, but also over 20 other prefectures in the western part of Japan. A total of 1,057 poisoning cases resulted according to the latest tabulation (August [redacted] Ministry of Welfare).[195,196] The most [redacted] initial symptom experienced by 136 [redacted] Yusho was increased eye discharge and [redacted] of the upper eyelids (38.3%) followed by acneform eruption, follicular accentuation (33.1%), and pigmentation of the skin (9.6%). Itching of the skin and "stiffening" of the soles of the feet and the palms of the hands were also observed. Pigmented mucous membranes were noticed in many of the patients; a small percentage of them developed jaundice. many complained of a feeling of weakness and headaches; occasionally vomiting, diarrhea, and fever also occurred. Various neurological symptoms manifested themselves such as transient visual disturbances, numbness and spasms in the limbs, and hearing difficulties. Most patients showed acnelike skin eruptions that resembled the chloracne observed after occupational exposure to chlorinated naphthalenes or chlorinated biphenyls. When the age and sex specific incidence rates were analyzed it was found that a significant sex difference was not present, but a lower risk for both males and females in the age groups over 60 years was noted. The proportion of severe cases among those age 13 to 29 was significantly larger than that of other age groups.

During the Yusho epidemic, 11 women with Yusho and 2 wives whose husbands had Yusho, but who themselves did not show the disease, delivered 10 liveborn and 2 stillborn babies. Nine of these babies had unusually greyish, dark brown stained skin, and dark pigmentation of the gingiva and nails was noted in five of them. Most infants also had heavy eye discharge. Histological examination of a stillborn fetus showed a marked hyperkeratosis and atrophy of the epidermis and cystic dilation of hair follicles, especially of those of the head. A marked increase of melanin pigment in the basal cells of the epidermis was also noted. Most fetuses that were born were smaller

NCMS 200540

TABLE 2

Symptoms (complaints) of Patients (89 males, 100 Females, as of October 31, 1968)*

Symptoms	Males %	Females %
Blackening of nails	83.1	75.0
Black spots in all pores	64.0	56.0
Excessive sweating in palms	50.6	55.0
Acnelike skin eruptions	87.6	82.0
Red spots on limbs	20.2	16.0
Itching	42.7	52.0
Change in skin color	75.3	72.0
Swelling of hands and feet	20.2	41.0
Hardening of backs and hands	24.7	29.0
Pigmentation of mucous membranes	56.2	47.0
Sebum (gum secretion in eyes)	88.8	83.0
Hyperemia of mucous membranes in eyes	70.8	71.0
Temporary failing of eyesight	56.2	55.0
Jaundice	11.2	11.0
Swelling of upper eyelids	71.9	74.0
Sense of weakness	58.4	52.0
Numbness of hands and feet	32.6	39.0
Fever	16.9	19.0
Hearing difficulty	18.0	19.0
Spasms of hands and feet	7.9	8.0
Headaches	30.3	39.0
Vomiting	23.6	28.0
Diarrhea	19.1	17.0

*Reprinted with permission from Kuratsune et al.[193]

than the national standards and four of them were small for gestational age babies. As they grew older their skin gradually became lighter over a period of three months.

Okamura and Katsuki[197] studied a group of 24 patients whose main complaint had been acneform skin eruptions and who had been diagnosed as definitely having Yusho. Eighteen of these were adults and six were children. Irrespective of the seriousness of the disease in all patients, the initial symptoms were eye discharge associated with edema of the eyelids, defects in vision, generalized fatigue, anorexia followed by comedo and acneform eruptions of the face, and pigmentation and flattening of the nails. The principal subjective symptoms were fatigue, numbness of the lower limbs, and intolerance for *sake*, which is a Japanese alcoholic beverage made from fermented rice. Three of twelve females had an irregular menstrual cycle. Seven of nine patients with serious disease showed a low grade fever. Most laboratory tests conducted on these patients were normal, including serum enzyme values. A slight elevation in alkaline phosphatase was observed in over half of the seriously ill groups. An increase in the α_2 globulin fraction of the serum protein was noted with a concomitant reduction of the albumin fraction, but the total serum proteins were within the normal range. These same 24 patients had abnormally elevated serum triglycerides ranging from 200 to 600 mg %. In 12 of 24 cases, while the total serum cholesterol remained unchanged, phospholipids tended to be somewhat lower.[198] Preliminary animal experiments in rabbits conducted by the same authors showed that lipemia was consistently induced within several days. The levels returned to their previously normal values several weeks after exposure had been discontinued.

The serum concentration of triglyceride is usually elevated in humans in glycogen storage disease (Von Gierke's disease). An increase in plasma triglyceride concentration is also observed in *essential hyperglyceridemia*, an apparent con-

PB 200841

genital anomaly. Essential hyperglyceridemia has been observed in siblings of a number of families, but the mode of transmission is not known. The course of this disease is generally benign and is consistent with a normal life span.[199] Observation of the familial cases shows that the mere elevation of triglyceride does not in itself increase the risk of arteriosclerosis.

Another interesting fact in this poisoning epidemic was that out of 23 cases with obvious Yusho, 10 showed symptoms or signs of a sensory neuropathy that included numbness, pain and hypoesthesia, and, in addition, 1 case also showed areflexia.[200,201] This effect on the sensory nerves would not be immediately obvious in animal experiments and probably should be investigated further.

Samples of sputa and adipose tissue collected from patients who suffered from Yusho contained chlorinated biphenyls on chemical analysis.[194] The concentration in adipose tissue was much higher than in sputa. Recently Kuratsune et al.[196] reported on the present status of the patients who suffered from Yusho. Many of the patients were still suffering from the illness. When the findings made in 159 patients in 1970 were compared with those observed in 1969, it was found that half of the patients had improved clinically, while the remaining half showed no such improvement and more than 10% of the patients had become worse.

Immunosuppression

Several reports have indicated that PCBs and possibly some of the chlorinated dibenzodioxins and furans may alter the immune response in animals. Atrophy of the thymus and reduced total white count were observed in rabbits following the dermal exposure to PCB fractions containing tetra- and pentachlorodibenzofuran.[96] In fish, exposure to Aroclor 1254 for 14 to 45 days led to emaciation and funguslike skin lesions.[93] However, no attempt was made to isolate organisms from these lesions. When 10-day-old mallard ducklings were fed diets containing PCBs (Aroclor 1254) and were subsequently injected interperitoneally with a duck hepatitis virus, significantly more ducklings died than when they received the virus alone.[202] In guinea pigs, sublethal dosage levels of 2,3,7,8-tetrachlorodibenzodioxin produced severe atrophy of the thymus with destruction of lymphocytes, lymphoid depletion in spleen and lymph nodes, as well as extensive hemorrhages into various organs including the adrenals. Reduced thymus and spleen weights were also observed in rats that received a single dose of 25 μg/kg TCDD and in mice the cell mediated immunity was found to be suppressed.[203] The various findings listed here do not conclusively prove that the immune response is specifically altered by these compounds as we encounter it following radiation exposure or therapy with alkylating agents. In most studies relatively high doses of the chemical compounds were given, resulting in general toxicity accompanied by weight loss. Weight loss in itself may lead to atrophy of the spleen. In humans maintained on a low caloric intake with negative nitrogen balance, a general reduction of lymphoid tissue results which is not specifically related to the immune response and vitamin A deficiency is also accompanied by a reduction in lymphatic tissue. In this respect it is also of interest that when monkeys were fed "toxic fat" containing polycyclic polychlorinated hydrocarbons. The germinal centers in the lymph nodes and spleen as well as islands of hematopoietic cells in bone marrow were extremely sparse.[160] This is more extensively discussed in connection with chick edema. The fact that a combination of duck hepatitis virus and PCBs is more toxic to 10-day-old ducklings than the virus alone suggests a reduced immune response but could also merely represent an additive damaging effect on the liver, made more susceptible to infection by the toxic effects of PCBs. So far no convincing evidence of "wasting disease" as a result of exposure to chlorinated polycyclic compounds has been reported in rodents or any other species in the literature.

Atrophy of the thymus in newborn rodents reduces the capacity of these animals to produce serum antibodies, resulting in wasting disease, also referred to as runt disease or homologous disease. Such animals are then incapable of rejecting foreign skin grafts,[204] which probably represents the most convincing evidence for homologous disease. A shift in the immune response could influence the development and growth of cancer and alter the defense mechanism in infections. In order to prove that PCBs as well as chlorinated dibenzodioxins and furans do indeed influence the immune response, the effect of these substances on newborn animals of several species should be tested with adequate parameters such as skin

MONS 200542

grafting and the measuring of the development of antibodies. Whether the other chlorinated polycyclic compounds in this article also affect the immune response has not been suggested or reported.

Biochemical Effects and Chemical Toxicology

Porphyria

Porphyria cutanea tarda in humans is an acquired defect in hepatic porphyrin metabolism, characterized by uroporphorinuria, photosensitivity as manifested by blisters, and mechanical fragility of the skin. The hepatic porphyria (Porphyria cutania tarda) which is responsible for the increase in porphyrins and the skin photosensitivity can be produced experimentally by a number of drugs; all of these have the ability to stimulate the activity of the initial enzyme in the heme synthesis δ-aminolevulinic acid synthetase (ALA). In addition to this acquired porphyria, an acute intermittent porphyria erthropoietica and an acute intermittent porphyria hepatica, which are both hereditary, exist together with a number of subgroups which will not be considered here.

In 1964, Bleiberg et al.[2] reported studies of 29 workers in a 2,4-D (2,4-dichlorophenoxyacetic acid) and a 2,4,5-T (trichlorophenoxyacetic acid) factory. Many of the workers had chloracne and 11 had abnormal excretion of urinary uroporphyrins. Many of the workers with uroporphyrinuria had hirsutism, hyperpigmentation, and increased skin fragility. Liver dysfunction was noted in two hospitalized patients. Poland et al.[1] reinvestigated the workers of the same plant studied by Bleiberg et al.[2] They studied a total of 73 male employees; chloracne was found in 80% of the workers. In this study six years after the first report, clinical porphyria was not observed and only one worker had persistent uroporphyrinuria. In the Japanese poisoning epidemic (Yusho), increased uroporphyrin excretion was not reported.

Apparently polychlorinated biphenyls, as well as tetrachlorodibenzodioxins, produce hepatic porphyria in animals. Experimental hepatic porphyria was observed in Sherman strain rats when the rats were exposed to Aroclor 1254 in the diet. The porphyria resembled hexachlorobenzene poisoning and human porphyria cutanea tarda.[205] When female rats were fed 100 ppm Aroclor 1254 in the diet (approximately 7.9 mg/kg/day) they became porphyric after a delay of about 2 to 4 months. At this time the urinary porphyrin excretion increased rapidly. Uroporphyrin excretion was elevated to a maximum of 550-fold, prophobilinogen 27-fold, and δ-aminolevulinic acid 18-fold. The major porphyrins found in urine from Aroclor treated rats were 8-carboxyporphyrin (73%) and 7-carboxyporphyrin (16%). Substantial increases in amounts of 5 and 6 carboxcylic porphyrins were also observed. A 10-fold increase in the excretion of coproporphyrins was observed, but the increase in uroporphyrin excretion was 1,400-fold. In control rat urines, coproporphyrin (81%) represented the major porphyrin fraction. A good correlation between urinary porphyrins and liver porphyrins was also observed. Only a trace of porphyrin was found in liver samples in control rats.

When feeding rats 100 ppm Aroclor 1254, δ-aminolevulinic acid synthetase was not increased in the first month of exposure. After this time δ-aminolevulinic acid synthetase was elevated 3- to 6-fold in porphyric rats but was normal in nonporphyric Aroclor treated rats. Cytochrome P-450 and microsomal heme were also increased throughout the study but the increase was maximal in one week despite the absence of an increase of the rate limiting enzyme in heme synthesis δ-aminolevulinic acid synthetase. When a large single dose of Aroclor 1254 (500 mg/kg) was given, a 4-fold induction of δ-aminolevulinic acid synthetase could be demonstrated in the liver 5 hr after dosing the animals. These results suggested that δ-aminolevulinic acid synthetase induction occurred when porphyria had developed if lower levels of Aroclor 1254 were fed over a period of time, but when high doses of Aroclor were given it was induced immediately.

Vos and Koeman[95] reported that chemical porphyria was produced by the two European PCB products, Phenoclor DP6 and Clophen A60, as well as the American product, Aroclor 1260. The porphyrogenic action was observed in chickens, quail, and rats. It has not been established so far whether only certain isomers of the polychlorinated biphenyls or contamination with a chlorinated dibenzofuran is responsible for the production of hepatic porphyria cutanea tarda.

Poland and Glover[206] used fertile chicken eggs at a developmental stage of 15 to 20 days and injected them with 25 μl of the *halogenated dibenzo-p-dioxins*. They found that 2,3,7,8-tetrachlorodibenzo-p-dioxin produced a dose-related

HONS 200543

increase in ALA synthetase activity. The lowest dose tested, 4.66×10^{-12} mol/egg (1.5 ng) doubled the enzyme activity. These results were statistically significant.

Studies with other halogenated dibenzo-p-dioxins gave the following results: the 2,3,7-trichloro and 2,3,6-tribromo isomers are potent inducers of ALA synthetase while 2,3-dichloro and 2,7-dichloro, 2,8-dichloro, 1,3,6,8-tetrachloro, and 1,2,3,4-tetrachloro isomers all failed to induce ALA synthetase at doses up to 2.5 mg/egg. Of the limited number of halogenated dibenzo-p-dioxins that have been tested for fetal toxicity and the ability to produce chloracne, those that are toxic at low doses also induce ALA synthetase. Whether some of the polyneurotic symptoms reported in Yusho and also in severe exposure to technical 2,4,5-T or technical trichlorophenol that were heavily contaminated with tetrachlorodibenzodioxin are caused by an effect on the porphyrin metabolism merits investigation since neurotoxic effects have been reported in acute intermittent porphyria.[207]

The dioxins that induce ALA synthetase in the liver of the chick embryo may also induce it in the mammalian system. Woods[208] was not able to induce δ-aminolevulinic acid synthetase (ALA synthetase) in the liver of male rats up to 30 days after oral doses of 2,3,7,8-tetrachlorodibenzodioxin. Guinea pigs and mice also did not show an increase of ALA synthetase following the administration of 2,3,7,8-tetrachlorodibenzodioxin. However, it was possible to demonstate an increase in ALA synthetase and uroporphyrins in the liver in C_{57} black male mice given 25 μg/kg/week for 4 weeks.[209] It is possible that ALA synthetase induction varies in time with age and sex and may show species variation. Induction in mammals may require longer dosing, since, for instance, porphyria and induction of ALA synthetase with moderate doses of Aroclor 1254 did not develop until 2 to 4 months after dosing was started.[205] Female animals and the embryo may be more susceptible than adult male animals.

Effect on Other Enzymes and on Vitamin A

A number of investigators have shown that the *polychlorinated biphenyls* induce liver microsomal enzymes.[210,211] Norback and Allen[211] correlated an increase of hepatic microsomal enzyme activity with smooth endoplasmic reticulum proliferation. Litterst et al.[212] studied the effect of four PCB mixtures, namely, Aroclor 1242, 1248, 1254, and 1260. The animals were fed the material for 4 weeks and dietary levels employed were 500, 50, 5 and 0.5 ppm. At higher dietary levels an increase in liver weights was observed. Elevation of triglycerides in the liver was seen at 500 ppm with a maximum effect occurring at approximately 50% chlorine content. An increase in cytochrome P-450 was observed at the 50 and 500 ppm dietary levels of all PCB mixtures. An induction of the pentobarbital hydroxylation and an increase in methylase activity were observed at the higher dietary levels. Induction of pentobarbital hydroxylation increased with increasing chlorine content of the PCBs. Nitroreductase activity was markedly stimulated with increasing doses of PCB and the induction was seen at levels as low as 0.5 ppm for all mixtures. It is difficult to evaluate the enzyme induction at these low dietary levels since the control animal food can be contaminated at times with PCBs.

Two types of inducers of drug-metabolizing enzymes of the liver have been reported; one group to which phenobarbital belongs resulted in increased P-450 content of the liver and induction of a variety of pathways including benzpyrene hydroxylase and demethylation of ethylmorphine. The polycylic hydrocarbons such as 3,4-benzpyrene belong to the second group, which resulted in the formation of an abnormal cytochrome, P-448, and increased benzpyrene hydroxylation, but not ethylmorphine demethylation. Alvares et al.[213] reported that PCB treatment produced an increase in cytochrome P-448, an increase in benzpyrene hydroxylation, and N-demethylation. Since the PCBs represent mixtures, it is possible that the type of induction may depend upon the isomers present. The various effects of PCBs on liver microsomal enzymes can be blocked by the prior administration of actinomycin D. When the effect of a number of PCBs on the beef heart mitochrondrial enzyme system was studied, it was found that they inhibited NADH-oxidase, succinoxidase, and cytochrome oxidase activity. It has not been established whether these same effects will occur in vivo. Benthe et al.[214] induced liver microsomal enzymes by intraperitoneal injection of a single dose of Aroclor 1248 or 1232.

Most of the microsomal enzymes have been studied in the rat, but they are affected in other species as well. Allen et al.[215] reported liver

MONS 208544

hypertrophy after feeding polychlorinated biphenyls (Aroclor 1248) or a polychlorinated triphenyl (Aroclor 5460) for three months to primates. The increase in liver size was attributed to the increase in smooth endoplasmic reticulum and induction of microsomal enzymes was observed. Proof of the induction of microsomal enzymes in birds is the finding made by Lucier and Peakall[216] that livers obtained from American kestrels exposed to either Aroclor 1254 or Aroclor 1262 showed an increase in the in vitro breakdown of oestradiol to a more polar metabolite. This effect on sex hormones is also emphasized by Platonow et al.[217] Aroclor 1254 given to Yorkshire boars reduced the urinary excretion of gonadal steroids.

Both the *polychlorinated biphenyls* as well as the *chlorinated naphthalenes* affect the vitamin A content of the liver. This was particularly studied with the chlorinated naphthalenes since hyperkeratosis and other abnormal keratin formation of the skin is often accompanied by vitamin A deficiency. Low vitamin A plasma levels were observed in cattle with X-disease and young swine.[155,167] A decrease in vitamin A storage in the liver of Japanese quail and rats that were fed Aroclor 1242 was also demonstrated.[218] Since vitamin A deficiency affects reproduction, this aspect should be further investigated to determine whether the effect of PCBs on reproduction is secondary to vitamin A deficiency.[219]

Goldstein and Johnstone[220] studied the effect of various PCB isomers on the hepatic enzyme system. Biphenyl itself did not cause induction of hepatic drug metabolizing enzymes and neither did monochlorobiphenyl (4-Cl). Substitution of chloro groups at the three and four positions of the di- and tetrachlorobiphenyls caused induction of microsomal monooxygenases. Induction of microsomal monooxygenases occurred also when hexa- and octachlorobiphenyls were given to the rats. Nitroreductase and carboxylesterase activities were not affected while all compounds produced a marked induction of the sulfobromophthalein conjugating system. *Terphenyls* as well as chlorinated terphenyls increased the pentobarbital metabolism in the rat with corresponding increase in smooth endoplasmic reticulum which suggested microsomal enzyme induction.[221,222]

Lucier et al.[223] reported that a single oral dose of 5 or 25 μg/kg body weight of *tetrachlorodibenzodioxin* induced cytochrome P-450 significantly in male rats for a period of up to 28 days. Cytochrome b-5 content was also increased. Hydroxylation of aniline was induced and aminopyrine demethylation rates were decreased. Microsomal proline was increased by approximately 15%. The induction of UDP glucuronyltransferase was most striking. Oxidative phosphorylation rates in rat liver mitochondria using succinate as a substrate were unchanged. The enzyme induction was observed as early as one day – the peak induction was reached between three and ten days after treatment. The enzyme induction was accompanied by an increase in smooth endoplasmic reticulum and a mild increase in rough endoplasmic reticulum.[224] These changes were first observed three days after the injection of the tetrachlorodibenzodioxin. Thus, enlargement of the liver during exposure to various chlorinated compounds is accompanied by an increase in smooth endoplasmic reticulum.

Furthermore, if "inclusions" or "hyaline bodies" are seen within the cytoplasm with the light microscope, concentrically arranged membranes that often surround lipid vacuoles can be seen with the electron microscope (Figure 6).

Hexachlorophene, on the other hand, does not increase the size of the liver.[118] The livers show no ultrastructural changes and probably microsomal enzymes are not induced. Whether other compounds listed in Figure 2 affect liver microsomal enzymes is not known. Hexachlorophene has an effect on a variety of other enzyme systems than those mentioned thus far. Cammer and Moore[225] and Caldwell et al.[226] have shown that hexachlorophene uncoupled oxidative phorphorylation, increased adenosine triphosphatase activity, but did not affect the activities of electron transport enzymes when compared to controls. Gould et al.[227] demonstrated that hexachlorophene inhibited succinoxidase activity of rat heart, liver, and kidney preparations. According to unpublished material cited by Gluck,[228] hexachlorophene is conjugated to the glucuronide conjugate which is excreted in bile. The proportion of conjugated hexachlorophene to unconjugated hexachlorophene in blood may be more significant in determining the toxicity of hexachlorophene than the hexachlorophene blood levels as they are presently determined.

Methemoglobinemia

In the early 1960s outbreaks of methemoglob-

MONS 200545

inemias were reported from hospital nurseries.[229,230] One outbreak involved a total of 18 infants with a level of methemoglobin from 4.9 to 30% of the total hemoglobin. An epidemiological investigation traced the outbreak to *3,4,4'-trichlorocarbanilide (TCC)* that was used as a 2% solution in a rinse in the laundering process, after which the laundry was neutralized with an acid and then dried in an autoclave. Twelve of the eighteen cases in this report were prematures who were probably longer exposed to the offending chemical than term infants since their hospital stay is usually longer. It is also possible that chemicals penetrate more easily through the skin of prematures.

In another outbreak, methemoglobinemia occurred among a group of custodial patients in an institution. These patients were given soap suds enemas with boiled soap that contained 2% TCC.[231]

It is possible that by heating TCC a breakdown product occurred which produced the methemoglobinemia. P-chloroaniline and 3,4-dichloroaniline have been suggested as breakdown products. None of the other compounds discussed in this article have thus far been shown to produce methemoglobinemia.

Storage, Distribution, Metabolism, and Excretion

As we progress further in our study on the distribution, metabolism, excretion, and absorption of compounds such as chlorinated biphenyls, chlorinated terphenyls, the chlorinated dibenzodioxins, and chlorinated naphthalenes, we will probably find that since they are lipid soluble they are stored in quite the same way as the more studied persistent pesticides such as DDT and dieldrin. From the evidence presently available on the chlorinated biphenyls it can be assumed that the turnover of these compounds in the body, particularly of those that have a high chlorine content, may be slower than some of the persistent pesticides. The turnover rate will vary with the degree of chlorination. Hexachlorophene, on the other hand, is fairly rapidly excreted and presently no information is available on bithionol and related compounds that have a germicidal effect. All of these compounds are not very well absorbed by the gastrointestinal tract or the skin.

Analysis of various tissues of rats given a single dose of the PCB Aroclor 1254[232] showed the highest concentration of PCBs in adipose tissue and the least in plasma. Brain, liver, and kidney had levels of the same order of magnitude but were lower. If, for instance, 1,600 mg/kg body weight of Aroclor 1254 were given by stomach tube, 24 hr later the mean concentration in adipose tissue was 1,146 ppm. The concentrations observed in individual animals varied greatly. Similar levels were found in adipose tissue when 3,200 mg/kg of Aroclor 1260 were given by stomach tube to adult female rats. The levels of Aroclor 1254 found in the brain showed a mean of 138 ppm and the values observed for Aroclor 1260 were 145 ppm. All of the values were calculated on a wet weight basis. The same concentrations in ppm were found with both compounds even though only half of the amount of Aroclor 1254 was given. This is probably due to the fact that only a certain amount of Aroclor is absorbed at a given time.

When 100 ppm of Aroclor 1254 was fed to male weanling rats for 58 days the mean concentration of Aroclor derived materials found in the feces varied roughly between 11 and 35 ppm. After the animals had been removed from the experimental diet for a week, the excretion in the feces was 8 ppm and after 16 days' recovery an average of 2.5 ppm was found in the feces. PCBs at the concentration of about 2 ppm were still observed in the feces 24 days after the animals were removed from the experimental diets. During the entire study the amount of PCB derived material recovered from the urine remained below 1 ppm. While PCBs were fed to the rats, the gas chromatogram obtained from the feces was superimposable on the one obtained from the standard Aroclor 1254 that was fed to the rats. Once the animals were no longer fed Aroclor 1254 the number of peaks observed in the gas chromatograms that resulted from the analysis of the fecal material decreased. Fewer peaks were also observed in the gas chromatograms obtained for the tissues and from urine. During the 58-day feeding period, a gradual increase in the concentration of the PCB derivatives was observed in tissues. The highest concentration was found in adipose tissue; after 58 days it reached mean values of about 500 ppm. The concentration in the liver only amounted to a mean of 12 ppm at that time. Following a recovery period of 71 days when the animals were fed plain chow, the concentration of the PCB derived material in adipose tissue had not decreased appreciably and

MONS 200546

still showed values in the neighborhood of about 400 ppm and 4.7 ppm was found in the liver. The concentration in the brain never reached very high proportions, it ranged from about 2 to 4 ppm. Following a 71-day recovery period the amount in the brain was still about 2 ppm. When Aroclor 1254 was fed for 240 days at the dietary level of 100 ppm, the concentration of the PCB derived material observed in adipose tissue had reached values of about 1,000 ppm. If, on the other hand, 100 ppm of DDT is fed to male rats for 2 years, the concentration in adipose tissue is about 95 ppm.[233] In a separate study where 500 ppm of Aroclor 1254 was fed to male rats for 6 months and the exposure to PCB containing diets was subsequently discontinued for an additional 10 months, the concentration of the PCBs ranged from 924 to 1,688 ppm in adipose tissue with an arithmetic mean of 1,192 ppm. The concentrations in the liver ranged from 17.3 ppm to 26.24 ppm with an arithmetic mean of 22.65 ppm.[234]

Further studies are necessary to determine whether PCBs are stored in tissues to a certain point when a steady state is reached and the concentration does not increase further. The given concentration at which this equilibrium is reached in adipose tissue would vary with the amount fed to the animals and the type of compound. The effect of starvation or illness when the amount of adipose tissue in the mammalian body is suddenly reduced also needs to be investigated further. Would this lead to increased excretion of the material or to redistribution or both? Dahlgren et al.[235] who determined PCB tissue levels in pheasants, found that a concentration of 300 to 400 ppm of the PCB derived material was usually found in the brains of birds that had died, while live birds that were fed the same amount of PCBs had much lower concentrations in their brain tissue.

Studies in bobwhite quail showed that relative peak heights and chromatograms for the tissue extracts were similar to the Aroclor standard after partitioning with acetonitrile-hexane when the birds were given a single capsule of Aroclor and their carcasses were analyzed soon after exposure. This suggests absorption of all components of Aroclor. The gastrointestinal tract, liver, skin, wings, and feet had been removed prior to analysis. When bobwhite quail were fed Aroclor 1254 for 14 days and then allowed to recover, the gas chromatograms showed a gradual reduction in the number of peaks and after 42 days on a control diet only 4 major PCB components remain, which suggested selective excretion and/or metabolism of some of the components of the Aroclor tested.[236] In a reproduction study, Heath et al.[99] analyzed 2 second-year eggs of mallards fed 25 ppm Aroclor 1254 in their diet for 2 years and found 56 and 33 ppm PCB by wet weight. The gas chromatogram showed a pronounced diminution of the early peaks when it was compared to the standard, suggesting again a selective reduction of the components with lower chlorine concentrations. This is also evident in environmental samples. Lower organisms such as mussels and fish contained a higher concentration of PCBs with lower chlorination than birds.[15]

In mammals, excretion of PCBs in milk and transplacental passage is also observed. Feeding cows 200 mg/day of Aroclor 1254 for 60 days[28] resulted in higher PCB levels in milk fat than in body fat. At 30 days' exposure, 45.6 ppm was found in milk fat and 21.9 ppm in body fat; at 60 days' exposure, 66.7 ppm was found in milk fat and 44 ppm in body fat. However, once exposure to PCBs was discontinued, the concentration in milk fat sank below that of body fat.

Transplacental passage of PCBs also occurred.[237,238] Sherman strain rats were given Aroclor 1254 in peanut oil by stomach tube during days 7 to 15 of gestation. A mean of 20.60 ppm PCB derived material was found in their milk when 10 mg/kg/day was given to the dams during pregnancy, while those given 50 mg/kg/day excreted a mean of 66.34 ppm in their milk on a wet weight basis. Fetuses taken by Caesarean section on day 20 of pregnancy contained a mean of 0.63 ppm and 1.38 ppm of PCBs, respectively. With a fivefold difference in dosage, the concentration in fetuses showed a twofold difference and in milk a threefold difference.[238]

The hyperpigmented babies observed in the Yusho incidents in Japan represent additional circumstantial evidence of transplacental passage of PCBs.

Polychlorinated biphenyls have also been detected in human adipose tissue. Biros et al.[239] analyzed two human adipose tissue samples which contained 200 and 600 ppm PCBs ranging from pentachlorobiphenyl to decachlorobiphenyl and Price and Welch[240] found 100 ppm PCBs in another human adipose tissue sample. According

MONS 200547

to Price and Welch,[240] 41 to 45% of the general population in the U.S. contain 1 ppm or more PCBs in their adipose tissue. Among PCB sources they discussed the food chain and house dust which, from residences in southwestern Michigan, contained up to 180 ppm PCBs. Polychlorinated biphenyls were found in 31% of 637 samples of human adipose tissue that were collected from the general population of the U.S., as part of the Human Monitoring Survey. Of the samples analyzed, 5% contained more than 2 ppm.[241] PCBs have also been found in human adipose tissues of the general population of Scandinavia[242] and Japan,[244,245] and in human milk and human adipose tissue of the general population of Germany.[243] In general, low concentrations of PCBs were stored in adipose tissue in a certain proportion of the general population. This is probably more prevalent in the highly industrialized countries and almost nonexistent in underdeveloped countries unless most of the food was imported from polluted areas. These low levels of PCBs are harmless, as far as we know at the moment; however, the occasional levels found in the 100 to 1,000 ppm range give rise to concern. It would be of interest to establish whether average adipose tissue levels increase with age and whether those in certain professions such as painters, printers, textile workers, workers in plastic factories, and those engaged in the manufacture of transformers and capacitors had higher PCB levels than the general population.

Reports on the absorption, storage, and metabolism of chlorinated naphthalenes, terphenyls, dichlorophene, bithionols, fenticlor, triclosan, and tetrachlorosalicylanilide are almost nonexistent in the literature. Some unpublished results on some of the compounds used as *germicides* are mentioned in the summary minutes of the Over the Counter Drug Panel on antimicrobials. Copies can be obtained by writing to Dr. Mary Bruch, Bureau of Drugs, Rockville, Md.

Approximately 9% of *triclosan*, also called Irgasan DP300 and CH 3565 (2,4,4'-trichloro-2'-hydroxydiphenyl ether), is absorbed when it is applied dermally in a soap solution. The halflife of the chemical was 20 hr when applied dermally and 10 hr when given intravenously. Humans excrete 65% in urine and 20% in feces after intravenous injection. It is excreted either as a free compound or as a glucuronide.

In dogs nearly 100% of the injected material is recovered as the glucuronide or sulfate in urine and feces over a 5-day period. It has been shown that TCC is absorbed through the skin.

Tissue levels of the *chlorinated terphenyl* Aroclor 5460 were determined in codfish.[246] In this study it was found that Aroclor 5460 was apparently poorly absorbed from the gastrointestinal tract, it was stored in all tissues that were analyzed. The highest concentration was found in the liver and following a single dose of 1 g some of it was still present in the codfish after 70 days, an indication of slow excretion. The authors pointed out that with the method used to determine the chlorinated terphenyls, it would be difficult to distinguish chlorinated biphenyls from chlorinated terphenyls. A comparison of the chromatograms of the standard with those obtained from chlorinated terphenyls extracted from tissues revealed more of the earlier peaks in material obtained from tissues and fewer of the later peaks. A variation in the intensity of the peaks was also observed. There seems to be a change in the chlorinated terphenyls within the living organism; however, part of this could also have been introduced as an artefact by the analytical methods or by differential absorption from the gastrointestinal tract.

Calves born to cows with X-disease developed hyperkeratosis and it was found that highly *chlorinated naphthalenes* were excreted in milk.[156] This suggests that chlorinated naphthalenes may well follow similar storage and excretion patterns as PCBs.

Chlorinated dibenzodioxins and *furans* are probably also stored in tissues of animals and men who are exposed to them, but again not much information is presently available. Firestone et al.[247] fed the unsaponifiable fraction isolated from "toxic fat" or 3% "toxic fat" itself to young cockerels. The "toxic fat" contained chlorodibenzodioxins with 2 to 8 chlorine atoms. When the excreta were analyzed it was found that a certain percentage of the hexachlorodibenzodioxins had been absorbed from the gastrointestinal tract, while all of the octachlorodibenzodioxins remained in the gastrointestinal tract, and only very little of the heptachlorodibenzodioxin was absorbed. Because of the presence of interfering components, the chick tissues and excreta could not be examined for the lower chlorinated dioxins. In the organs, the highest concentration was found in the liver and an appreciable amount

MONS 200548

were found in the bone and skin, while the liver samples contained very few dioxins. Some evidence for a possible metabolism of hexa- and hepta-chlorodibenzodioxin by the chick was also observed. Zinko and Wildish[248] fed di-, tri-, tetra-, and octachlorodibenzofuran to fish and detected only octachlorodibenzofuran in muscle and gut of dead fish. One problem with metabolism, storage, and distribution studies of chlorinated dibenzodioxins and furans is that not all of the compounds are readily available and, if they are available, any long-term feeding studies in large animals are expensive. The very toxic dioxin compounds can be given only at such low levels that they escape detection easily. In our laboratory we detected a chlorinated dibenzofuran in the urine of rats fed Aroclor 1254. We found this same chlorinated dibenzofuran in the Aroclor itself[40] as a contaminant.

Williams et al.[249] fed rats a total of 22.7 and 120.7 μg of octachlorodibenzodioxin. They recovered a great deal of the compound in the feces. Very small amounts were recovered in the liver at both dosage levels and in adipose tissue at the higher dosage level. Further studies are needed to establish the absorption, excretion, and storage of these compounds, and their persistence. Studies with labeled material may eventually give us some information on their metabolism. Piper et al.[250] gave a single oral dose of C^{14} labeled 2,3,7,8-tetrachlorodibenzo-p-dioxin to rats and found that about half of the radioactive material was recovered within 21 days in the feces and only 13% in urine and 3% in expired air. Most of the remaining radioactive material was found in the liver.

In another study[251] 100 μg of Cl^{36}-octachlorodibenzodioxin was given daily to rats by stomach tube for 21 days. Less than 0.3% of the material was absorbed. Subsequently the rats received a control diet for 7 weeks and still showed 20% of the absorbed material found at 21 days in their tissues.

The in vivo metabolites of the various compounds under discussion have in most instances not been identified. Block and Cornish[252] studied the urinary excretion of biphenyl and 4-chlorobiphenyl in rabbits. Biphenylglucosiduronic acid and 4-hydroxybiphenyl were isolated from urine of rabbits fed biphenyls. The rabbits fed the 4-chlorobiphenyl excreted 4-(p-chlorophenyl) phenol and 4-chlorobiphenyl glucosiduronide. Twice as much 4-chlorobiphenyl as biphenyl was excreted as the glucosiduronic acid derivative. It is possible that other low chlorinated biphenyls and naphthalenes are excreted in urine in a similar manner; whether they would be detected by present gas chromatographic methods would have to be checked by combining the identification of radio labeled material with gas chromatography.

Hutzinger et al[253] found evidence that some chlorinated biphenyls are hydroxylated by some species. Apparently trout is not able to hydroxylate 4-chlorobiphenyl, 4,4'-dichlorobiphenyl, and 2,2',5,5'-tetrachlorobiphenyl, while the rat and the pigeon both formed monohydroxychlorobiphenyl from 4-chlorobiphenyl. In addition, the rat also produced dihydrochlorobiphenyl. Large quantities of unchanged material were excreted by the rat when 4,4'-dichlorobiphenyl and 2,2',5,5'-tetrachlorobiphenyl were given to them and only a monohydroxyderivative was identified in their urine. Pigeons followed a similar pattern but no dihydrochlorobiphenyl was observed in the bird excreta fed 4-chlorobiphenyl. No hydroxy metabolites could be identified in the excreta of the three species when they were given 2,2',4,4',5,5'-hexachlorobiphenyl. No evidence of reductive dechlorination was observed in any species.

Only very few studies have been conducted with radiolabeled *hexachlorophene* to study its absorption, distribution, and metabolism. Wit and Van Genderen[254] gave rats and rabbits hexachlorophene-C^{14} (2,2'-methylene-C^{14} bis(3,4,6-trichlorophenol). Complete recovery of radioactivity in excreta after a single dose of 50 or 15 mg/kg of radioactive hexachlorophene was observed in rabbits within 5 days. Roughly one third was excreted in urine and feces, respectively, as unchanged hexachlorophene and the remainder was excreted in the feces as unidentified metabolites. The metabolites could not be extracted from the feces with ethanol. The biological halflife calculated from the experimental results was found to be approximately 17.8 hr. In rats, about two thirds of the radioactivity was recovered in feces within seven days and only very little in urine. A complete recovery of radioactivity was not obtained in these studies within seven days. Five cows given a single dose of 15 mg/kg body weight of hexachlorophene excreted about half to two thirds in their feces within five days. Very little was excreted in urine and none in milk.

NONS 200549

Metabolites were not identified and tissue levels were not determined in this study. The authors cited a study by Kok,[255] who did determine hexachlorophene in various organs of rats.

Carroll et al.[256] studied the absorption of C-14 labeled hexachlorophene on the tail skin of the rat. Hexachlorophene in a detergent solution was absorbed by the intact skin of the tail at the average rate of 1.7 $\mu g/cm^2$ of exposed surface area/hr. Immediately after the infliction of second degree burns, the absorption rate increased 2.5 times that of the normal skin surface. After 24 hr the absorption rate dropped to normal or subnormal levels. Immediately after traumatizing the tail, the absorption rate of hexachlorophene was even greater than following the infliction of a burn wound.

Manowitz and Johnston[257] found that hexachlorophene was deposited on the skin when used in various formulations and could be extracted from the skin by soaking the exposed areas (hands and forearms) in alcohol. The amount recovered increased in proportion to the amount applied. These authors were unable to confirm earlier investigations which suggested that the quantity of hexachlorophene retained by the skin reached a plateau level after a number of washings and remained relatively constant thereafter. Arms were washed and rinsed every 20 min. When extractions with alcohol were made on different arms after different numbers of washings, it was found that the amount of hexachlorophene recovered increased with the number of washings and no plateau was reached. A greater amount of hexachlorophene was also deposited on the skin with increasing length of time of a single washing. Since we now know that hexachlorophene is also absorbed from the intact skin and some of it is probably also lost from the surface of the skin, the time interval between the washings plays a role in the amount of hexachlorophene found to accumulate on the skin. Also of interest is that bathing water containing 4 mg/l of hexachlorophene deposited approximately the same amount of the chemical on the skin as a single washing with a 2% hexachlorophene soap.

Since hexachlorophene was used very extensively and often unknowingly by the general population, we investigated whether it was present in the blood of a few random samples of the general population. We found that the arithmetic mean concentration of hexachlorophene in adults was 0.028 ppm ($\mu g/g$) of whole blood of a total of 14 samples. In infants who were washed with hexachlorophene in the nursery the amount of hexachlorophene found in whole blood after the infants had anywhere from 2 to 14 washes averaged 0.109 ppm ($\mu g/g$ whole blood). Blood obtained from the cord at the time of birth contained an arithmetic mean of 0.022 ppm hexachlorophene.[258,259]

In the rats that were used in a reproduction study and were fed 100 ppm hexachlorophene in the diet for 258 days, the hexachlorophene blood levels averaged 1.21 ppm, while the blood levels of rats fed 500 ppm of hexachlorophene for 55 days who had severe symptoms of poisoning amounted to 8.5 ppm.[259,260] At the time we reported these blood levels, our recovery rate was only about 75%. All blood levels reported at that time were determined in whole blood. (It is assumed at the moment that blood levels are equivalent to half the amount of that found when plasma is analyzed.) A study undertaken at the request of Sterling Laboratories[132] illustrated that newborn rhesus monkeys following total body bathing with a 3% detergent solution for 1 week had blood levels of about 1.5μg/ml (ppm). In subsequent months a plateau effect was observed and at 90 days the blood level was equivalent to 1.1 μg/ml. These monkeys showed status spongiosus of the white matter of the brain. this indicates that at least in the monkey, blood levels of about 1.5 μg/ml whole blood were consistent with fluid accumulation in the myelin sheath of the central nervous system.

Lockhart[132] cited unpublished studies by Gluck, who found that hexachlorophene blood levels in term infants after washing with a 3% hexachlorophene detergent solution were somewhat higher than those reported by us with a mean concentration of 0.345 ppm ($\mu g/g$ whole blood). This difference could have been due to a difference in washing procedure and a better recovery rate in the analytical method in Gluck's study, or both.

Prenature infants apparently absorbed hexachlorophene more readily. In 15 premature infants that were washed with a 3% hexachlorophene detergent solution, the average blood concentration amounted to 0.475 ppm ($\mu g/g$).[261] Abbott et al.[262] using a different washing regimen found a mean hexachlorophene blood concentration 12 to 18 hr after the initial wash of 0.154 ppm ($\mu g/g$

MONS 200550

whole blood) and on the 7 to 9th day of life, 24 to 48 hr after the second or third application of hexachlorophene, the mean blood level amounted to 0.287 ppm (μg/g). The amount found in cord blood of 16 infants was 0.013 ppm (μg/g). When hexachlorophene was applied only on the day of delivery, the hexachlorophene blood levels gradually decreased from a mean of 0.145 ppm on the first day to a mean of 0.057 ppm on the ninth day, following an increase to 0.194 ppm on the fourth day. The authors suggested that premature infants may absorb more hexachlorophene through their skin since in one infant 29 weeks of gestation and weighing 1.42 kg the blood level was 1.17 ppm 24 hr after the initial wash and 0.655 ppm at 48 hours. Alder et al.[263] reported mean hexachlorophene blood levels of 0.18 ppm in infants who were dusted with a powder containing 0.33% hexachlorophene.

Adults using hexachlorophene preparations also absorbed it via the skin.[132] The blood levels obtained in adults that exposed their total body surface to a 3% hexachlorophene preparation twice daily for 60 days, 5 min each time, showed blood levels of approximately 0.68 ppm (μg/ml whole blood) with a range of 0.25 to 1.08 ppm (μg/ml whole blood). If only hand washing was employed for a period of 28 days, 4 times daily, a mean blood level of 0.07 ppm was reached and in a face hand washing study the mean blood level after 28 days was 0.196 μg/ml.

Blood levels obtained in a patient with burns who died between 24 and 48 hr after the last hexachlorophene application were 2.2 ppm (μg/g whole blood). The blood levels that have been reported all indicate that following dermal hexachlorophene exposure the chemical can be found in blood, and from information through animal studies as well as some human experience, levels of approximately 1.5 to 2 ppm (μg/g) in whole blood in humans are presently considered to represent toxic levels if the analysis for blood was performed with the methods mentioned elsewhere in this article.

Probably a better way of assessing a toxic dose would be to measure the amount of hexachlorophene in the brain, but for obvious reasons that is not possible. Female rats fed hexachlorophene at the rate of 500 ppm (25 mg/kg body weight/day) for 55 days with very definite lesions had about 4 ppm hexachlorophene in their brain and 3.91 ppm in the liver. Squirrel monkeys given 5 mg/kg body weight/day of hexachlorophene for 38 days showed a mean hexachlorophene concentration in the brain of 0.38 ppm and in adipose tissue the hexachlorophene concentration was 0.94 ppm.[264] The recovery rate in this study was only 75%. These squirrel monkeys had no overt clinical signs of toxicity, but showed mild status spongiosus of the white matter of the brain. Electroencephalographic changes had also been observed in these primates. Ulsamer et al.[265] found hexachlorophene brain levels of about 1 ppm in newborn rats with signs of central nervous system toxicity. In 1 suspected case of human hexachlorophene poisoning in a child, the hexachlorophene brain level was about 2.2 ppm.[261] Adult rats dying after the administration of a single dose of hexachlorophene showed concentrations of 6 to 9 ppm of hexachlorophene in the brain.[266] Some variation of the concentration of hexachlorophene in the brain which can be related to neurotoxic symptoms must be expected in different species and perhaps also with age and sex. Whether the fluid accumulation which may occur in the myelin sheaths after repeated exposure to hexachlorophene would alter hexachlorophene brain levels has thus far not been reported.

With present methods, we are probably only determining free hexachlorophene while the conjugated portion remains undetected. The toxicity of hexachlorophene will vary with the ability of the organism to conjugate, metabolize, and excrete this material.

We found in rats that hexachlorophene is excreted in milk of dams fed hexachlorophene at the rate of 20 and 100 ppm in the diet (2.3-1.1 mg/kg/day and 11.8-5.5 mg/kg/day, respectively, for 241 days). Electron capture, gas-liquid chromatographic determinations revealed levels of 0.07 and 0.33 ppm in the milk. Since hexachlorophene did not seem to accumulate to a great extent similar values would probably have been obtained, had the levels in milk in these animals been measured earlier. Although we now have some information on the absorption and distribution as well as excretion of hexachlorophene, the possible storage of the material as well as its metabolism needs further investigation. Since hexachlorophene was found in cord blood of infants, it can be assumed that transplacental passage also occurred.

Morphologic Effect on the Liver

Some of the chlorinated naphthalenes, chlori-

NONS 280551

nated dibenzodioxins, chlorinated dibenzofurans, the chlorinated biphenyls, as well as the chlorinated terphenyls have an effect on the liver in various species, including humans. Bennett et al.[267] compared the toxicity of differently chlorinated naphthalenes and a biphenyl that contained 65% chlorine. Tri-chloronaphthalene apparently was less hepatotoxic than the higher chlorinated compounds and the chlorinated diphenyl was the most toxic of all. The studies were done in rats and the exposure was by feeding as well as inhalation. The findings described in the liver consisted of liver necrosis, fat accumulation, and the presence of hyaline bodies in the cytoplasm of the liver cells. A marked deposit of finely divided granular yellow or yellow-brown pigment was observed in Kupffer cells, particularly in those animals that had been exposed to the chlorinated biphenyls. This pigment apparently did not stain characteristically for either hemosiderin or hemofuclesin. Of course, all livers were enlarged macroscopically; in addition, these authors described proliferative changes in occasional bile ducts, particularly after feeding mixtures of chlorinated naphthalenes and chlorinated biphenyls. The number of bile ducts was increased in certain areas and the epithelial cells lining the bile ducts showed mitotic figures.

In inhalation studies with low concentrations of PCBs which consisted of either a 16-hr daily exposure to average concentrations of 0.57 mg/m^3, or to 8 hr daily with an average concentration of 0.93 mg/m^3, neither group of rats appeared ill. The periods of exposure varied from 37 to 143 days. When the animals were sacrificed the livers were pale or slightly yellow and somewhat mottled. Microscopic examination of the livers revealed similar changes as had been observed after feeding the material, and an increased vacuolation of the liver cells. Microscopic evidence of recovery was not observed in the livers of rats that had been exposed to the chlorinated diphenyl for a total of 105 days and were removed from exposure for 2 months.

Similar findings were made by Miller[268] who studied the effect of a PCB which contained approximately 42% chlorine. This author observed varying degrees of liver damage after subcutaneous injection as well as oral ingestion of the toxic substance in guinea pigs, rats, and rabbits. The liver damage consisted of fatty degeneration and atrophy of the central lobular cells. In the rat, hyaline bodies within the cytoplasm of the liver cells were also noted. Most of the liver damage was found in the guinea pig, less in the rabbit, and least in the rat.

Nishizumi,[269] who studied the effects of a Japanese biphenyl Kaneclor 400 with 40% chlorine in monkeys and mice, described enlargement of liver, fatty changes, granular cytoplasm of the hepatocytes, increases in the size of Kupffer cells and hepatocytes, and a brown pigment in some of these cells. He also studied the livers under the electron microscope and found an increase in smooth endoplasmic reticulum, variation in the appearance of mitochondria, and an increase in the number of microbodies. In addition, "myelin figures" were observed in the cytoplasm of hepatocytes.

Vos and Koeman[95] observed liver necrosis in chickens that were dosed with European PCBs, while a Monsanto product with 60% chlorine did not produce this effect. Increased amounts of iron were demonstrated with Perl's iron stain in the livers of all chickens exposed to the European as well as the American PCB sample. Vos and Beems[96] studied the PCB-induced lesions in the liver of rabbits, following dermal exposure to Aroclor 1260, Phenoclor, and Clophen. The microscopic changes observed in the liver included fatty degeneration, focal necrosis, centrolobular liver cell atrophy, ceroid pigment in Kupffer cells, periportal fibrosis, and cytoplasmic hyaline degeneration.

The feeding of Aroclor 5460, a chlorinated terphenyl, Aroclor 1254, or a chlorinated dibenzo-p-dioxin, not further specified in the article, led to liver hypertrophy of Sprague-Dawley rats within eight days to three weeks. Ultrastructural alterations were similar in the three groups and consisted of numerous multilayered, concentric membrane arrays and proliferated smooth endoplasmic reticulum. In many instances these membrane arrays surrounded lipid droplets.[270] Rabbits given 300 mg of Aroclor 1242 and 1254 once a week for 14 weeks developed enlarged livers and the ones given Aroclor 1254 showed midzonal necrosis of the hepatic lobules. The livers of rabbits fed Aroclor 1221 in a similar fashion did not show any histologic changes.[271]

We conducted studies to compare the toxicity of Aroclor 1254 and Aroclor 1260 in Sherman strain rats. The acute effect of these two mixtures on the liver was negligible. If rats were given a

MONS 200552



FIGURE 3. Section of liver of a rat fed Aroclor 1260 for 90 days. This figure illustrates a mitotic figure and a hyperchromatic nucleus (arrows) H & E X 500.

single dose of 10,000 mg/kg in peanut oil by stomach tube, and were sacrificed the next day, the liver was essentially normal microscopically. Doses of 1,000 ppm (72 mg/kg) of Aroclor 1260 for 3 months produced only an increase in mitotic figures (Figure 3) and enlarged hepatocytes. When groups of rats were fed dietary levels of 20, 100, 500, and 1,000 ppm of Aroclor 1260 and 20, 100, and 500 ppm Aroclor 1254 for 8 months, the liver changes were pronounced.[272] The hepatocytes were enlarged in many of the rats of the experimental groups and lipid accumulation, foamy cytoplasm, and a brown pigment which stained partially positive for hemosiderin were observed in the livers. The pigment was primarily observed in macrophages and Kupffer cells. Inclusions (Figure 4) that stained slightly more eosinophilic than the surrounding cytoplasm were present in the cells. These inclusions within the cytoplasm have been described for many compounds such as mirex[273] (dodecachloro-octahydro-1,3,4-metheno-2H-cyclobuta[cd]pentalene), DDT[274], 1,1,1-(trichloro-2,2-bis(p-chlorophenyl) ethane dieldrin[275], 1,2,3,4,10,10-hexachloro-6,7-epoxy-1,4,4a-5,6,7,7,8a-octahydro-1,4-endo-exo-5,8-dimethanonaphthalene, and piperonyl butoxide[276] (α-(2(-butoxyethoxy)ethoxy)-4,5-methylenedioxy-2-propyltoluene). They are identical to the so-called hyaline bodies that were described in the earlier literature by Bennett et al.[267] and Miller.[268]

Aside from these general changes, extensive, grayish-white, firm, glistening areas were noticed in the livers of a number of the experimental animals, particularly at the high dietary levels. Microscopic examination of these grayish-white areas showed that the hepatic parenchyma had been replaced by glandular pale staining epithilial cells that formed ducts and were surrounded by proliferating fibrous tissue (Figure 5). Larger lesions often had extensive fibrosis and also contained collagen and the ducts that were formed by epithilial pale staining cells were markedly dilated and contained necrotic debris or mucus. The lesion has been classified as adenofibrosis for the time being. It has been described in detail by Edwards and White[276] who observed it in rats that were fed butter yellow (p-dimethylamino-azobenzene). These lesions enlarge peripherally by the formation of new glandular structures. Hepatic

NOMS 200553

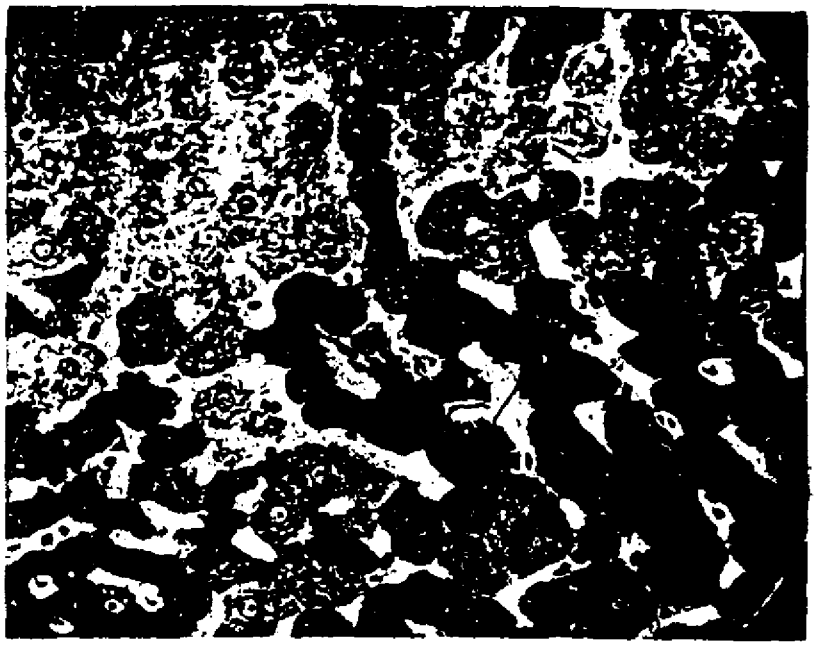

FIGURE 4. Section of liver from rat fed Aroclor 1254. A cluster of inclusions is present in the cytoplasm of one hepatocyte (arrow). Usually individual cells contain only one of these formations at a time. Toluidine blue stain of maraglass embedded material X 300.

tissue may be trapped between the glands of the peripheral area of adenofibrosis. The older central parts of the lesions sometimes contain pigmented avascular collagenized stroma with atrophic epithelial cells lining dilated ducts that appear atrophic and dead. The glands of actively growing adenofibrosis show atypical epithelium with large pleomorphic nuclei. The epithelium can occasionally become stratified. Parts of the lesion may be quite extensive, while in addition, in many areas of the same liver small foci of adenofibrosis exist simultaneously in close relationship to portal areas. It has therefore been assumed that these lesions arise from bile ducts, but they can also be primarily confined to the region of the hepatic veins. The absence of bile ducts around hepatic veins led to the conclusion[277] that a precursor, other than bile ducts, existed from which adenofibrosis developed. However some investigators of the lesions have assumed that it represented an atypical bile duct proliferation, also referred to as cholanginfibrosis.[278] In addition to this lesion we also observed small clusters of glandular cells within areas of adenofibrosis as well as adjacent to blood vessels that were surrounded by relatively normal appearing hepatic parenchyma with staining characteristics of salivary gland tissue. These clusters of cells very closely resembled pancreatic tissue.[279] The distinction between adenofibrosis and adenocarcinoma is difficult. The glands are quite atypical in adenofibrosis but it may be helpful to remember that in adenofibrosis, in contrast to adenocarcinoma, the irregularity observed is limited and duplicated with considerable exactness from lesion to lesion. Mucus is always present in adenofibrosis, but not always in adenocarcinoma. The stroma of adenofibrosis is concentrically arranged, young and cellular at the periphery and old and hyalinized towards the center of the lesion.[277] Of course a liver showing adenofibrosis may also contain carcinomatous lesions. So far conclusive evidence is lacking in the literature that adenofibrosis gives rise to carcinomas. However, it has been found to coexist with carcinoma of the liver in rats and some investigators feel that the lesion is in fact a precursor of cancer.[280] Choline deficient rats apparently, in addition to other changes in the liver, also develop

MONS 200554



FIGURE 5. Section illustrates an area of adenofibrosis of the liver of a rat fed Aroclor 1254. Note the epithelial cells forming small ducts. The ducts contain cellular debris and are surrounded by fibrosis which can become quite pronounced. H & E X 125.

adenofibrosis.[281] However, these rats were fed peanut meal and soymeal and therefore the possibility exists that the experimental diet was contaminated with a mycotoxin. Bennet et al.[267] also described the lesion (adenofibrosis) in rats when a mixture of chlorinated naphthalenes and chlorodiphenyls was fed to them. A critical review of the histopathogenesis of this lesion was made by Stewart and Snell.[277]

Ultrastructural changes of the livers of animals exposed to the Aroclor consisted of an increase in smooth endoplasmic reticulum and atypical mitochondria. Many lipid vacuoles were observed, particularly at the higher dietary levels. They were at times surrounded by concentrically arranged membranes. The "inclusions" or "hyaline" bodies observed in the cytoplasm with the light microscope correspond to these formations when they are examined under the electron microscope. Their ultrastructural appearance has led to their being referred to as "finger prints" (Figure 6). The epithelial component of the adenofibrosis outlined consisted of cuboidal or columnar cells with the free surface lined by microvilli, granular cytoplasm with many ribosomes, and a few endoplasmic membranes. Some of the cells contained a great deal of mucus and resembled goblet cells. Tonofilaments and terminal bars were also observed. These various observations suggested that the epithelial component of adenofibrosis had all the morphological characteristics of bile duct epithelium.

Chickens with chick edema disease and cattle with the X-disease, already mentioned, usually showed changes in the liver which consisted predominantly of liver cell necrosis and fat accumulation. The hepatotoxic effect of chlorinated naphthalenes has also been described in rats.[267]

In a number of reports on the occupational occurrence of chloracne in workers that were exposed to chlorinated naphthalenes, chlorinated diphenyls, or 2,4,5-T, and technical trichlorophenol, reference is made to the hepatotoxic effect of these compounds. This hepatotoxic effect can manifest itself only in a decreased tolerance for alcohol; it may also develop into hepatic deficiency with acute yellow atrophy and jaundice. Apparently the effect on the liver was

NONS 200555

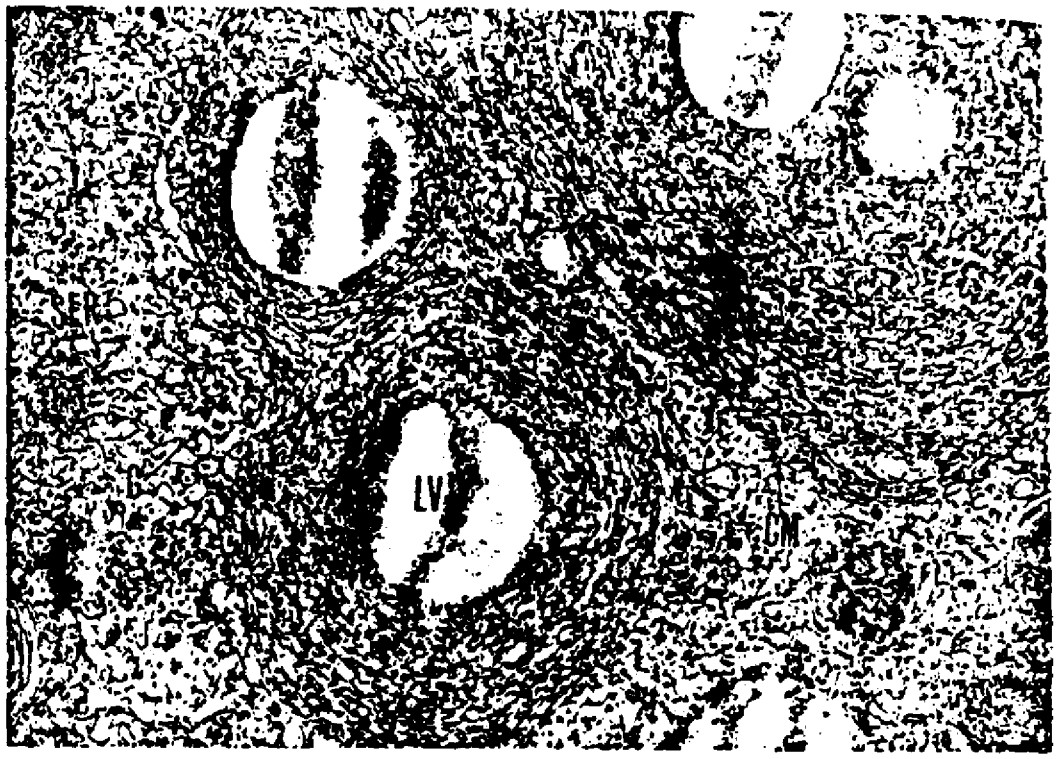

FIGURE 6. Electron micrograph of a portion of the cytoplasm of a hepatocyte. The section shows concentrically arranged arrays of membranes which surround vacuoles containing lipid. Lead citrate, uranyl acetate X 34,200

particularly bad following exposure to halo-waxes, which are chlorinated naphthalenes.[282]

Cotter[283] reported seven cases of pentachlorinated naphthalene poisoning in workers who were engaged in manufacturing wire cable during World War II for the navy. Four of the workers developed jaundice and two died. Microscopic examination of the liver of the two workers that died showed complete loss of liver cells in some areas, the centrolobular areas were hemorrhagic, and prominent bile duct proliferation was seen in the periphery.

Another group of compounds that have at least some representatives that cause a hepatotoxic effect are the chlorinated dibenzodioxins and chlorinated dibenzofurans.

Single oral doses of 1 to 10 μg/kg *2,3,7,8-tetrachlorodibenzodioxin* given to rabbits produced a hepatotoxic effect. At the higher dosage level the animals died and the lower doses caused serious liver damage.[108] Schulz[107] had reported earlier that single oral doses of 20-50 μg/kg body weight resulted in fatal liver necrosis in rabbits.

Weanling rabbits were treated with 2,3,7,8-tetrachlorodibenzo-p-dioxin by applying a dose of 1.67 μg daily to the inner aspect of both ears for three days. The total dose given was 7.05 μg/kg body weight. When these rabbits were sacrificed 18 days following the last application of the dioxin, their livers were significantly larger than those of the controls. Microscopic examination of the livers showed enlarged hepatocytes. Some of the hepatocytes were multinucleated. The cytoplasm was foamy or vacuolated. A light brown pigment in some liver cells as well as Kupffer cells was also observed. Inclusions were seen in the cytoplasm in some liver cells, slight interstitial fibrosis was present, and two of three rabbit livers examined showed foci of necrosis that were surrounded by fibrosis.[284]

Studies with "toxic fat," the cause of chick edema disease, showed that it had a necrotizing

MONS 200556

effect on the liver in chickens. As we now know, the toxic agents responsible for chick edema disease are chlorinated dibenzo-p-dioxins. Toxic fats also altered liver morphology in Macacca mulatta monkeys.[285] Hepatocytes were enlarged, multinucleated and focal necrosis in the centrolobular zone was observed. Many liver cells were vacuolated and stained positive for neutral fat.

In our studies of rats given *hexachlorophene*, we did not observe any liver pathology with the light microscope and no change with the electron microscope at the dosage levels that we employed.[118] Thorpe[121] on the other hand, observed periportal fatty changes in livers of sheep given three or four doses of 50 mg/kg hexachlorophene and histochemical changes were also observed in the hepatocytes. Pugh and Crowley[286] also observed hepatotoxicity in sheep after giving them hexachlorophene.

Of the other germicides discussed in this article, only triclosan (Irgasan DP-300) (2,4,4-trichloro-2'-hydroxydiphenyl ether) has been reported to have a toxic effect on the liver at a dose of 125 mg/kg and enlarged the liver of rats at a dose of 25 mg/kg, according to the summary minutes of the OTC Panel, U.S. Food and Drug Administration. It was not stated whether these were single or repeated doses. Oral administration of triclosan to beagle dogs produced jaundice and severe liver damage was observed. The effect that these compounds have on the liver will have to be studied further.

The accumulation of fat in the liver indicates that either fat transport or fat metabolism is impaired; if the insult to the liver is removed, the liver gradually recovers unless the lesion has become irreversible. The increase in smooth endoplasmic reticulum as well as the "inclusions" will also disappear after a certain amount of time if exposure to the material is discontinued.[287] The significance of the increase in smooth endoplasmic reticulum and the hyaline bodies with a concomitant rise in liver microsomal enzyme activity is presently not understood. These changes are considered adaptive and beneficial, but in addition to metabolizing unwanted chemicals at a higher rate, the stimulated liver also metabolizes some medications more rapidly,[288] as well as substances produced by the body such as steroids. Whether the inclusions within the cytoplasm represent the so-called inactive smooth endoplasmic reticulum which is deposited in the form of arrays of membranes within the cell is not known. The fact that smooth endoplasmic reticulum may become hypoactive was first postulated by Hutterer et al.[289]

Fibrosis of the liver as well as necrosis and the adenofibrosis observed after PCB exposure in rats should definitely be considered a very serious lesion. Usually adenofibrosis occurs concomitantly with hepatomas or hepatocarcinomas in rodent livers. A recent publication by Kimura and Baba[290a] showed that hepatomas can be induced in rats with Kanechlor 400. Chronic feeding studies may show that other PCBs will also induce hepatomas in rodents.

Neurotoxicity

In some of the reports on chloracne and also in the Yusho incident, peripheral neuropathy is mentioned as well as psychic alterations[1,290] as part of the symptomatology of poisoning, but in most reports not much emphasis was put on it. In the Yusho epidemic Murai and Kuroiwa[290] performed more detailed examinations in 21 cases admitted consecutively to Kyushu University Hospital in the northern part of Japan. Seven of the patients complained of numbness or pain in the peripheral portion of their extremities and in five cases, hypoesthesia, hypalgesia, and thermohypesthesia were noted. Slowing as well as reduction of the sensory nerve conduction velocity in the radial and sural nerve was observed in a number of these patients. Headache and peripheral nervous system symptoms were also reported in a poisoning episode which occurred in a Finnish company where paper was impregnated with biphenyl.[92]

The only chemical of the group of polychlorinated, polycyclic compounds discussed in this report that has a predominant central neurotoxic effect in animals as well as humans is hexachlorophene. Adult female rats that were fed 500 ppm hexachlorophene in the diet for 14 weeks (about 30 to 18 mg/kg body weight/day) developed leg weakness after 12 to 19 days of exposure. This leg weakness which was only evident in the hindlegs progressed to paralysis within 3 to 5 weeks.[291] At autopsy the brains of the exposed rats were enlarged; they weighed an average of 2.6 g while the control brains weighed an average of 1.99 g. Microscopic examination of the brains revealed normal gray matter throughout the brain and the spinal cord in the few instances that the spinal

MONS 200557

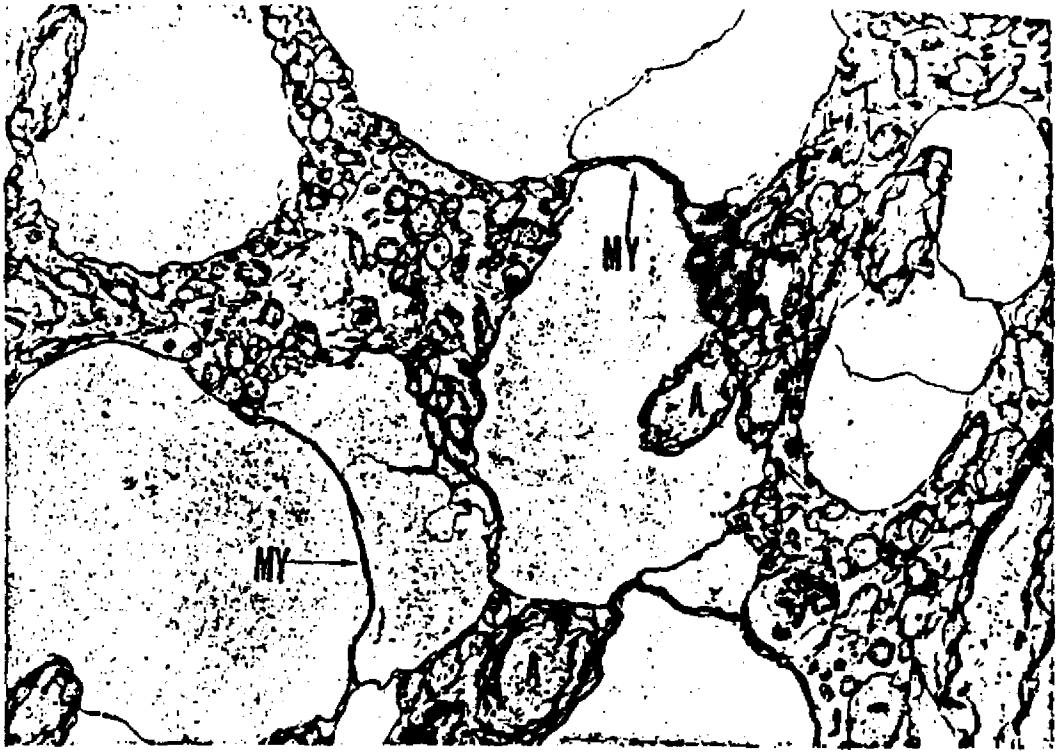

FIGURE 7. Electron micrograph from the white matter of the brain of a rat, illustrating status spongiosus. Note the large empty appearing vacuoles lined by myelin (MY = myelin, A = axon). Lead citrate, uranyl acetate X 34,200.

cord was examined. The white matter on the contrary seemed widened and showed many cystic spaces that appeared empty and were lined with strands of material that stained positive for myelin. The vacuoles were very numerous and varied greatly in size giving the tissue a spongy appearance. The brains in these studies were usually fixed in either Bouin's solution or buffered formalin for light microscopic study.

Brain tissue, particularly that of rodents, may normally show small vacuoles that are considered to represent an artefact.[292] These vacuoles are smaller, usually very uniform, and at times contain a homogeneous pink staining material. They are usually separated by a wider area of normal appearing white matter than the vacuoles in status spongiosus. Brains that show this artefact do not weigh significantly more than those that do not show it.

Electron microscopic examination of brains of rats given hexachlorophene showed that the vacuolation in the white matter of the brain revealed large vacuoles lined by myelin. The axons that were present appeared usually to be quite normal; occasionally strands of myelin had separated and traversed the vacuoles. The vacuoles were otherwise empty except for some electron dense granular material (Figure 7). No other alterations were observed in the white matter. This lesion is not unique for hexachlorophene: other chemicals that have produced status spongiosus as we have called the lesion include triethyltin,[293] isoniazid,[294] the halogenated benzanilide, 2-acetoxy-4-chloro-3,5-diiodobenzanilide,[295] and rafoxanide,[296] which is the 3,5-diiodo-3'-chloro-4'-(p-chloro-phenoxy) salicylanilide. Triethyltin seemed to produce the lesion at a much lower dietary level and more rapidly than the other chemicals mentioned, particularly hexachlorophene.

In an additional study, after feeding rats 500 ppm hexachlorophene in the diet for 10 weeks and then discontinuing the exposure to hexachlorophene, function began to return in the hindquarters of paralyzed rats after 2 weeks and within

MONS 200558

6 weeks the rats had almost completely recovered clinically. However, microscopic examination of the brains of these rats showed that a few cystic spaces were still present 12 weeks after the exposure to hexachlorophene had been discontinued. In weanling rats, but not in adult rats, the brain lesion and symptoms of paralysis could be produced with a single oral dose of 100 mg/kg of body weight given by stomach tube in peanut oil.[118] Part of the reason for being able to produce the brain lesion in the weanling rats with a single dose may be related to the fact that the weanling was able to survive a higher single dose than the adult rat.

Other species that have also shown paralysis and other neurological deficits after exposure to hexachlorophene are rabbits,[297] pigs,[298] and cats.[299] Sheep become blind according to Udall and Malone.[120] Hanig et al.[299] recorded the neurological deficits produced in cats in more detail. Early symptoms consisted of lassitude, weakness and ataxia of the hindlegs, impaired righting reflex, patellar hyperreflexia which later developed into hyporeflexia, urinary retention, and eventually complete flaccid paralysis. The cranial nerve functions remained intact except preterminally. In these cats an increase in cysternal cerebralspinal fluid pressure was observed.

In our first studies we continued exposure to hexachlorophene for a period of 14 weeks because we had designed the experiment to conduct an approximate 90-day feeding study. It is not necessary to feed rats for this length of time. As we determined later, microscopic changes can be observed in rats after a feeding period of two weeks when the animals were exposed to levels high enough to produce the lesion. Some vacuolation can already be observed 3 to 4 days after onset of exposure to hexachlorophene in some rats. When lower dietary levels were fed in a reproduction study,[118] the dietary level of 20 ppm (2.4–0.9 mg/kg body weight/day) had no effect on the brain. At the dietary level of 100 ppm (11.8–4.6 mg/kg body weight/day) focal areas of vacuolation of the white matter of the brain were observed in some of the rats, but they were never extensive. The rats in these lower dietary levels did not show any clinical neurological symptoms.

The brain lesion observed in rats was also described in monkeys following the exposure to hexachlorophene. Newborn monkeys washed with 3% hexachlorophene detergent solution developed a diffuse status spongiosus of the white matter of the brain.[300] Santolucito[264,301] was able to produce the vacuolation of the white matter, the so-called status spongiosus, by injecting squirrel monkeys daily subcutaneously with 5 mg hexachlorophene/kg of body weight for 37 days. When monkeys were *fed* hexachlorophene they did not develop the brain lesion but showed electroencephalographic changes which need further investigation. The monkeys that showed the vacuolation also demonstrated electroencephalographic changes. Sheep have apparently also shown status spongiosus of the white matter according to Hale and Reid.[303] Lampert et al.[302] were able to produce the lesion in mice as well as rats. These authors reported that the morphological changes were also observed in frozen sections of brains quenched in liquid nitrogen. Trypan blue injected intraperitoneally did not stain the brain, an indication that the blood brain barrier was intact as far as trypan blue was concerned.

The brain changes consistent with status spongiosus due to hexachlorophene exposure have also been described in humans, particularly children. Mullick[130] examined the brains of six human cases that died from hexachlorophene poisoning. The two adults in this group did not show vacuolation of the white matter of the brain. They had died less than 48 hr after exposure to hexachlorophene. The four children (two with congenital ichthyosis, two with burns) had at least three or more days of exposure to hexachlorophene baths in which a 3% hexachlorophene preparation was used. The final concentration of hexachlorophene in the bath water was not known. All four children showed status spongiosus of the white matter. The brain weight given in one of the cases, a 12-day-old child, was 425 g. The normal brain weight for a child that age is 382 g. Shuman et al.[304] in a retrospective blind study were able to demonstrate that the incidence of status spongiosus in the brain stem reticular formation in infants who had died from a variety of causes could be correlated to hexachlorophene exposure. The authors found 21 cases in a series of 250 autopsies of children. Of these cases, 18 were premature infants weighing less than 1,400 g and were of less than 30 weeks' gestation. All but 2 of the cases had 3 or more total washes with 3% hexachlorophene. In the group of cases that were studied were a number of stillborns who did not

MDNS 200559

show the lesion and of course had not had dermal hexachlorophene exposure. Shuman et al.[304] mentioned earlier cases of Letterer Siwe's disease in which they had observed status spongiosus of the white matter. Each of the children with Letterer Siwe's disease had had pronounced exposure to hexachlorophene because of the skin lesions which had been vigorously scrubbed with a detergent containing the chemical. The various observations show that, in patients with abnormal skin as well as the skin of the premature, hexachlorophene may be absorbed in sufficient amounts to cause status spongiosus. The fact that blood levels in premature infants washed with hexachlorophene tend to be higher than in mature infants also substantiates these findings.

Almost identical observations were made by Powell et al.[305] In premature infants weighing less than 1,400 g, 7 of 13 that had 4 or more exposures to hexachlorophene washes showed status spongiosus of the myelinated tracts of the brain stem. If this group was further subdivided according to the number of exposures, 6 of 9 infants that had 9 or more exposures to hexachlorophene washes showed the lesion, and 1 of 4 that was washed 4 to 8 times. Four stillborns and 13 infants washed 0 to 3 times with hexachlorophene and weighing less than 1,400 g did not show the spongy change. Electron microscopic examination showed that the spongy change observed in the premature infants was due to a split in the myelin sheaths.

In August of 1972 the press reported a number of deaths of infants in France that occurred because a baby powder to which hexachlorophene had accidentally been added at a concentration of 6% was used on the infants. The final death toll amounted to 41 infants and young children[306] (New York News, Dec. 13, 1972). Detailed accounts have not been published of this incident because of litigation problems. As we pointed out earlier, under acute toxicity, the higher the concentration of hexachlorophene is in a preparation applied to the skin, the more likely it is that skin damage will result. Skin damage also occurred in the French incident. In addition to this, the powder was probably used in many instances where some diaper rash already existed and was then well covered with a diaper, which may have contributed to increased absorption in this area. The brains and spinal cord of a few infants from the French poisoning outbreak that were examined microscopically showed status spongiosus of the white matter.[306]

These various accounts show that status spongiosus can also be produced in humans and probably represents a nonspecific reaction which can be elicited by a number of chemicals.

The lesion status spongiosus of the white matter as far as we now know seems to represent a specific or restricted type of brain edema where the fluid accumulation is confined to the inside of the myelin sheath and myelin is not actually damaged or at least breakdown products of myelin have not been observed. The term status spongiosus or spongy change has been used as a descriptive term and a spongy change of the gray matter may also occur in certain diseases. Status spongiosus together with other morphological changes can be observed in the brain in a variety of many etiologically different diseases and the reader is referred to Klatzo,[307] Ardonato and Lampert,[308] and a recent editorial in the British Medical Journal.[309] From clinically observed poisoning cases as well as animal experiments it is evident that the brain lesion is to a great extent reversible. However, in our own studies as well as those by Lampert et al.,[303] microscopic changes in rodents did not completely regress and the fact that sheep do not recover their eyesight after hexachlorophene poisoning[120] indicates that repair may not always be complete. No reasonable explanation exists at the moment to indicate why certain chemicals produce this very specific edema confined to certain structures of the central nervous system.

Gastrointestinal Lesions

Only two types of compounds under discussion have produced lesions in the gastrointestinal tract. We observed in our study with Sherman strain rats that high single oral doses of 3,000 mg/kg Aroclor 1254 and 1260 or more caused ulceration of the gastric and duodenal mucosa (Figure 8). Ulcers in the GI tract were not observed in the long-term feeding studies with 500 ppm or less. No other changes in the gastrointestinal tract were observed. Ringer et al.,[105] in their reproduction study with mink, observed that Aroclor 1254 produced hemorrhage in the gastrointestinal tract of the offspring.

Allen and Norback[310] observed hyperplasia and dysplasia of the gastric mucosa in rhesus monkeys. Six of these rhesus monkeys were fed

MONS 200560



FIGURE 8. Section of the glandular portion of the stomach of a rat given a single dose of 3,000 mg/kg of Aroclor 1254. This figure illustrates the focal loss of mucosa and the infiltration by inflammatory round cells. H & E X 50.

300 ppm Aroclor 1248 and six were given 5,000 ppm Aroclor 5460, a polychlorinated triphenyl. The glandular formations in this lesion were highly atypical; penetration of the muscularis mucosae and invasion of the submucosa by the mucosal epithelium were observed. Allen and Carstens[285] reported an effect of toxic fat on the gastric mucosa in 18 of 27 monkeys, *Macaca mulatta*, which consisted of hypertrophy of the gastric mucosa and small gastric ulcers within the mucosa. The toxic fat used in these studies, as we now know, contained chlorinated dibenzodioxins.

It has also been observed that hemorrhaging occurred into the gastrointestinal tract of rat fetuses who were exposed to 2,3,7,8-tetrachlorodibenzo-o-dioxin in utero. It was not stated in the reports whether the gastrointestinal hemorrhages were caused by ulceration of the mucosa.[110,111] Ulceration of the glandular portion of the adult rat stomach was also observed.[113]

Patients with chloracne frequently complained of loss of appetite, nausea, vomiting, and abdominal pain, and Goldmann[311] described a worker with a follicular dermatitis who died six months after exposure to 2,3,7,8-tetrachlorodibenzodioxin. At autopsy a ruptured duodenal ulcer and a gastric ulcer were found. Whether any relationship existed between the ulcers and the exposure to the poisonous chemical was not mentioned in the paper.

It should be established if these gastric lesions also occur at lower dietary levels and whether the contamination of the chemicals with various chlorinated dibenzodioxins and furans is responsible for them. Valuable information might be obtained from retrospective studies of workers following occupational exposure. Whether the ulcers are caused by a direct effect of the chemical on the mucosa of the gastrointestinal tract or whether stress plays a primary role in their etiology similar to ulcers that may occur in burned patients for instance (Curling's ulcer) is not clear.

COMMENTS

The acute toxicity of compounds such as the chlorinated biphenyls, the chlorinated naphthalenes, and the chlorinated terphenyls is very low.

MONS 200561

On the other hand, they are poorly broken down in the environment and the metabolism of the biphenyls with more than four chlorine atoms seems to be negligible. Because of these characteristics, the use, wherever possible, of chlorinated biphenyls that consist of mixtures of compounds with one to four chlorines has been proposed. Neither the chlorinated naphthalenes nor the chlorinated terphenyls have so far been shown to present a pollution problem.

Whether the various disease entities reviewed in this article are produced by all the different products mentioned in connection with them is not established with certainty. For instance, some of the compounds that produce chloracne or chick edema have been shown to be contaminated with various chlorinated dibenzodioxins and chlorinated dibenzofurans. The possibility remains that the compounds illustrated in Figure 1 are contaminated with these chemicals and the products themselves are not really responsible for the observed symptoms. On the other hand, a number of structurally unrelated compounds may produce the same disease entity.

Some of the chlorinated dibenzodioxins and the chlorinated dibenzofurans are highly toxic. The most toxic is 2,3,7,8-tetrachlorodibenzodioxins, while the dibenzodioxins without any chlorine and those with eight chlorines are much less toxic. The difference in toxicity of these compounds may be partly caused by the fact that they are very poorly dissolved and absorbed. Intravenous toxicity data are thus far not available on most of these compounds.

We also do not know at present if the porphyria which develops after prolonged exposure to a number of technical compounds such as hexachlorobenzene, chlorinated biphenyls, chlorinated dibenzodioxin, and 2,4,5-T is in many instances due to the contamination of these products with chlorinated dibenzodioxins; of course it may be possible that one or more chlorinated dibenzofurans also produce porphyria. It has also not been established whether all compounds that produce porphyria in animals will do so in humans as well.

In general, the exposure of the various population groups to chlorinated biphenyls and other cyclic chlorinated hydrocarbons is at too low a range to induce porphyria. Whether this can also be said for occupational exposure is not known. When production conditions and general hygiene of the workers are poor, porphyria cutanea tarda can apparently occur.[3] It is also not known if the combined effect of different porphyria inducing agents is cumulative. Whether the photosensitivity observed in humans with some of the germicides discussed in this paper is related to an effect on the porphyrin metabolism was not evident from the published literature.

So far the mechanism that causes chick edema, chloracne, X-disease, and liver disease has not been satisfactorily demonstrated. Chick edema disease has been thought to be caused by proliferation of the vascular endothelium. [redacted] explain the fluid accumulation observed [redacted] animals, but so far the sequence of events that led to this disease is not really clear and factors other than the embarrassment of the vascular system may play a role in its etiology such as a toxic myocarditis, decrease in serum proteins, and renal failure. More detailed study of the pathology of the various disease entities is needed for a better understanding of the development of the various lesions mentioned.

The chlorinated polycyclic hydrocarbons seem to alter the immune response of certain animal species and perhaps also of people. These very important findings need to be pursued further. Thus far it has not been established beyond doubt whether this is caused by a general debilitating affect on the animal of which atrophy of the lymphoendothelial system may be one manifestation, or whether this is a specific alteration, as we know it from the effects of radiation and exposure to certain alkylating agents. In this respect not enough attention has been paid to the function of the adrenal, and several of the observed symptoms in humans such as the hyperpigmentation suggest hypofunction of the adrenal cortex. Depending on the information obtained from these studies, a tolerance level of 5 ppm in some food products as set by the U.S. Food and Drug Administration may have to be revised particularly since no long-term low level feeding study has been reported in animals.

Many questions have recently been raised about the use of germicides in various toiletries, common soaps, etc. The objection to their use in the specific case of hexachlorophene is its neurotoxic effect, that can also occur in humans, particularly if the skin is defective in some way. Of course, limited localized exposure, such as handwashing or treatment of a small wound, will not produce neurotoxicity.

MONS 200562

In infant nurseries in hospitals, one of the greatest problems is the constant threat of a staphylococcus infection of epidemic proportions. In order to prevent outbreaks of staphylococcus infections, a routine was developed in many hospitals in the U.S. and elsewhere in the early 1960's where infants were washed once daily with a 3% hexachlorophene detergent solution, and in addition the diaper area was washed several times a day. The detergent was subsequently rinsed off more or less vigorously, depending upon the philosophy of the different nurses. In some hospitals the detergent was directly applied to the infant, in others it was first diluted in water. Since the neurotoxic effect of hexachlorophene has become known, many hospitals have changed their policies on the use of hexachlorophene. Another drawback to this routine, in addition to a possible neurotoxic effect, is that hexachlorophene keeps not only the staphylococcus of certain phage types from growing on the skin, but reduces all Gram-positive bacteria,[3,12] which is highly undesirable and may lead to disease. Recently Evans et al.[3,13] have pointed out that a marked annual variation exists in the prevalence of several bacteria in the nares as well as the umbilical cord of newborns. A decline of staphylococcus aureus was observed in the fall; the prevalence of *Escherichia coli* and streptococcus also varied. Staphylococcus epidermis and Enterobacter organisms did not show this fluctuation. Any studies of efficacy undertaken in a clinical setting should take these normal fluctuations into account and it is possible that good general housekeeping practices are ultimately more effective in preventing bacterial disease in newborns than various germicides. Unfortunately, breaks in technic do occur which in many hospitals makes the use of germicides on infants desirable.

The information reviewed in this article shows that the toxic effects of the polycyclic polychlorinated compounds are complex. The mere knowledge of an LD_{50} value in an animal species does not give us a great deal of information about the toxicity of a compound. Toxicity or toxic effects are a relative concept and such household items as table salt, vitamins, pepper, and allyl propyl disulfide volatilizing from onions to name a few are also toxic. Nevertheless, we have to learn not to use chemicals indiscriminately, without knowing a great deal about them, particularly their long-range effects, when they are persistent and poorly metabolized. The indiscriminate use of these products and discharge into the environment invariably lead to their restriction or ban, which is accompanied by a great deal of emotionalism, distorted facts, and often great economic loss. Prudence, better judgment, and a critical approach to the usage of chemicals and drugs, particularly an evaluation of whether in specific situations they are necessary or not, may help us avoid these situations in the future. Particular attention should be paid to avoiding unnecessary exposure of children to chemicals that we know little about. Children may react differently from adults and as far as long-term exposure is concerned, they would be the most vulnerable.

ACKNOWLEDGMENT

My sincere thanks go to my colleagues and former co-workers who have made this review possible, particularly to Drs. R. E. Zehr, J. E. Suggs, V. W. Burse, R. E. Jennings, R. E. Linder, V. E. Sedlak, J. A. Goldstein, E. C. Villaneueva, and T. B. Gaines for letting me incorporate some of the unpublished results into this manuscript.

REFERENCES

1. Poland, A. P., Smith, D., Metter, G., and Possick, P., A health survey of workers in a 2,4-D and 2,4,5-T plant, *Arch. Environ. Health*, 22, 316, 1971.
2. Bleiberg, J., Wallen, M., Brodkin, R., and Applebaum, T. L., Industrially acquired porphyria, *Arch. Dermatol.*, 89, 793, 1964.
3. Larson, D. L., Studies show hexachlorophene causes burn syndrome, *J. Am. Hosp. Assoc.*, 42, 63, 1968.
4. Schmidt, H. and Schultz, G., Uber Diphenylbasen, *Annalen*, 207, 338, 1881.
5. Penning, C. H., Physical characteristics and commercial possibilities of chlorinated diphenyl, *Ind. Eng. Chem.*, 22, 1180, 1930.
6. Jenkins, R. L., McCollough, R., and Booth, C. F., Syntheses in the diphenyl series, *Ind. Eng. Chem.*, 22, 31, 1930.

200563

7. Rajzman, A., Les résidus de biphenyle dans les agrumes, *Residue Rev.*, 8, 2, 1965.
8. Clark, F. M., Nonflammable dielectric organic compounds, *Ind. Eng. Chem.*, 29, 698, 1937.
9. Clark, F. M., The development and application of synthetic liquid dielectrics, *Trans. Electrochem. Soc.*, 65, 59, 1934.
10. Broadhurst, M. G., Use and replaceability of polychlorinated biphenyls, *Environ. Health Perspect.*, No. 1, 81, 1972.
11. Anon., Monsanto releases PCB data, *Chem. Eng. News*, 49, 15, Dec. 6, 1971.
12. Fairhall, L. T., *Industrial Toxicology*, Hafner Publishing Co., New York, N.Y., 1969, 188.
13. Holden, A. V., Source of polychlorinated biphenyl contamination in the marine environment, *Nature*, 228, 1220, 1970.
14. Koeman, J. H., TenNoever DeBrauw, M. C., and DeVos, R. H., Chlorinated biphenyls in fish, mussels and birds from the river Rhine and the Netherlands coastal area, *Nature*, 221, 1126, 1969.
15. Jensen, S., Johnels, A. G., Olsson, M., and Otterlind, G., DDT and PCB in marine animals from Swedish waters, *Nature*, 224, 247, 1969.
16. Risebrough, R. W., Rieche, P., Peakall, D. B., Herman, S. G., and Kirven, M. N., Polychlorinated biphenyls in the global ecosystem, *Nature*, 220, 1098, 1968.
17. Dustman, E. H., Stickel, L. F., Blus, L. J., Reichel, W. L., and Wiemeyer, S. N., The occurrence and significance of polychlorinated biphenyls in the environment, *Transactions of the 36th North American Wildlife Natural Resources Conference*, Wildlife Management Institute, Washington, D.C., 1971, 118.
18. Zitko, V., Polychlorinated biphenyls and organochlorine pesticides in some freshwater and marine fishes, *Bull. Environ. Contam. Toxicol.*, 6, 464, 1970.
19. Veith, G. D. and Lee, G. F., PCB's in fish from the Milwaukee region, *Proc. 14th Conf. Great Lakes Res.*, 157, 1971.
20. Veith, G. D., Recent fluctuation of chlorobiphenyls (PCB's) in the Green Bay Wisconsin region, *Environ. Health Perspect.*, No. 1, 51, 1972.
21. Duke, T. W., Lowe, J. I., and Wilson, A. J., Jr., A polychlorinated biphenyl (Aroclor 1254) in the water, sediment and biota of Escambia Bay, Florida, *Bull. Environ. Contam. Toxicol.*, 5, 171, 1970.
22. Stickel, C. F., personal communication, U.S. Dept. Interior, Patuxent Wildlife Research Center, Laurel, Md. 20810.
23. Buller, P. A., Residues in fish, wildlife and estuaries, *Pestic. Monit. J.*, 6, 238, 1973.
24. Stalling, D. L. and Mayer, F. L., Toxicities of PCB's to fish and environmental residues, *Environ. Health Perspect.*, No. 1, 159, 1972.
25. Papageorge, W. B., PCB's in the environment, Presented at a meeting sponsored by the National Water Quality Laboratory, FWQA, Duluth, Minn., March 17, 1970.
26. Prestt, I., Jefferies, D. J., and Moore, N. W., Polychlorinated biphenyls in wild birds in Britain and their avian toxicity, *Environ. Pollut.*, 1, 3, 1970.
27. Cornelissen, P. E., Residues in food and feed. Pesticide residues in total diet samples, VI. *Pestic. Monit. J.*, 5, 313, 1972.
28. Fries, G. F., Polychlorinated biphenyl residues in milk of environmentally and experimentally contaminated cows, *Environ. Health Perspect.*, No. 1, 55, 1972.
29. Kolbye, A. C., Food exposures to polychlorinated biphenyls, *Environ. Health Perspect.*, No. 1, 85, 1972.
30. Veith, G. D., Current levels of chlorobiphenyls in Lake Michigan fish, PCB Newsletter, U.S. Environmental Protection Agency, National Water Quality Laboratory, 6201 Carrollton Blvd., Duluth, Minn. 55804, 5th issue, 14, Jan. 29, 1973.
31. PCB Conference, Weiner Gren Center, September 29, 1970, National Environment Protection Board, Stockholm, Sweden.
32. Nelson, N., Hammond, B., Nisbet, C. T., Sarofim, A. F., and Drury, W. H., Polychlorinated biphenyls – environmental impact, *Environ. Res.*, 5, 249, 1972.
33. Fishbein, L., Chromatographic and biological aspects of polychlorinated biphenyls, *J. Chromatogr.*, 68, 345, 1972.
34. Zitko, V. and Choi, P. M. K., 43 FRB technical report, Fisheries Research Board of Canada, Biological Station, St. Andrews, N. B., 1971.
35. PCB Letters, U.S. Environmental Protection Agency, National Water Quality Laboratory, Duluth, Minn., 1970-1973.
36. Anon., Aroclor resins and plasticizers for chlorinated rubber, Tech. Bull. No. PL-311, Monsanto Chemical Co., April, 1962.
37. Zitko, V., Hutzinger, O., Jamieson, W. D., and Choi, P. M. K., Polychlorinated terphenyls in the environment, *Bull. Environ. Contam. Toxicol.*, 7, 200, 1972.
38. Reynolds, L. M., Pesticide residue analysis in the presence of polychlorobiphenyls (PCB's), *Residue Rev.*, 34, 27, 1971.
39. Tomita, M., Ueda, S., and Narisada, M., Dibenzo-p-dioxin derivatives. XXVII. Synthesis of polyhalodibenzo-p-dioxins, *Yakugaku Zasshi*, 79, 186, 1959.
40. Curley, A., Burse, V. W., and Jennings, R., Metabolite or contaminant of Aroclor 1254 found in rat urine, 163rd ACS Nat. Meeting, Boston, Mass., *Dir. Pest. Chem. Abstr.*, 5, 1972.

MONS 200564

41. Vos, J. G., Koeman, J. H., and Van Der Maas, H. L., Identification and toxicological evaluation of chlorinated dibenzofuran and chlorinated naphthalene in two commercial polychlorinated biphenyls, *Food Cosmet. Toxicol.*, 8, 625, 1970.
42. Crosby, D. G., Moilanen, K. W., and Wong, A. S., Environmental generation and degradation of dibenzo-dioxins and dibenzofurans, *Environ. Health Perspect.*, No. 5, 259, 1973.
43. Villanueva, E. C., Burse, V. W., and Jennings, R. W., Chlorodibenzo-p-dioxin contamination of two commercially available pentachlorophenols, *J. Agric. Food Chem.*, 21, 739, 1973.
44. Jensen, S. and Renberg, L., Contaminants in pentachlorophenol: chlorinated dioxins and predioxins, *Ambio*, 1, 62, 1972.
45. Johnson, R. L., Gehring, P. J., Kociba, R. J., and Schwetz, B. A., Chlorinated dibenzo-dioxins and pentachlorophenol, *Environ. Health Perspect.*, No. 5, 171, 1973.
46. Emerson, J. L., Thompson, D. J., Strebing, R. J., Gerbig, C. G., and Robinson, V. B., Teratogenic studies of 2,4,5-trichlorophenoxyacetic acid in the rat and rabbit, *Food Cosmet. Toxicol.*, 9, 395, 1971.
47. Courtney, K. D., Gaylor, D. W., Hogan, M. D., Falk, H. L., Bates, R. R., and Mitchell, I., Teratogenic evaluation of 2,4,5-T, *Science*, 168, 864, 1970.
48. President's Science Advisory Committee, Report on 2,4,5-T, 1971, U.S. Govt. Printing Office, Washington, D. C., 20402.
49. Flick, D. F., Firestone, D., and Marliac, J. P., Studies of the chick edema disease. II. Preparation and biological effects of a crystalline chick edema factor, concentrate, *Poult. Sci.*, 44, 1214, 1965.
50. Cantrell, J. S., Webb, N. C., and Mabis, A. J., Search for chick edema factor, *Chem. Eng. News*, 45, 10, 1967.
51. Firestone, D., Etiology of the chick edema disease, *Environ. Health Perspect.*, No. 5, 59, 1973.
52. Higginbotham, G. R., Huang, A., Firestone, D., Verrett, J., Ress, J., and Campbell, A. D., Chemical and toxicological evaluations of isolated and synthetic chloro-derivatives of dibenzo-p-dioxin, *Nature*, 220, 702, 1968.
53. Baughman, R. and Meselson, M., An analytical method for detecting TCDD (dioxin): levels of TCDD in samples from Vietnam, *Environ. Health Perspect.*, No. 5, 27, 1973.
54. Shapley, D., Herbicides: AAAS study finds dioxin in Vietnamese fish, *Science*, 180, 285, 1973.
55. Zitko, V., Absence of chlorinated dibenzodioxins and dibenzofurans from aquatic animals, *Bull. Environ. Contam. Toxicol.*, 7, 105, 1972.
56. Goerlitz, D. and Law, L. M., Chlorinated naphthalenes in pesticide analysis, *Bull. Environ. Contam. Toxicol.*, 7, 243, 1972.
57. American Pharmaceutical Association, Follow these guidelines for hexachlorophene, *Alpha Newslett.*, 11(21), 1, 1972.
58. Goddard, J. L., Drugs for human use containing bithionol, *Fed. Reg.*, 32, 211, 1967.
59. Annotated Index Reg. Fungicides and Nematocides, Agricultural Research Service, USDA, Supt. of Doc., U.S. Govt. Printing Office, Washington, D.C., 20240.
60. EPA Summary of registered agricultural pesticide chemical uses, USDA summary of registered agricultural pesticide chemical uses, 2, 3rd ed., Supt. of Doc., U.S. Govt. Printing Office, Washington, D.C.
61. Martin, H., *Pesticide Manual*, 3rd ed., British Crop Protection Council, Worcestershire, England, 1972, 178.
62. Jensen, S., A new chemical hazard, *New Sci.*, 32, 612, 1966.
63. Kinchrough, R. W., Reiche, P., and Olcott, H. S., Current progress in the determination of the polychlorinated biphenyls, *Bull. Environ. Contam. Toxicol.*, 4, 192, 1969.
64. Amour, J. A. and Burke, J. A., Method for separating polychlorinated biphenyls from DDT and its analogs, *J. Assoc. Off. Anal. Chem.*, 53, 761, 1970.
65. Safe, S. and Hutzinger, O., Chlorine randomization between phenyl groups in the electron impact induced fragmentation of polychlorinated biphenyls, *J. Chem. Soc.*, (Lond.), D9, 446, 1971.
66. Reynolds, L. M., Polychlorobiphenyls (PCB's) and their interference with pesticide residue analysis, *Bull. Environ. Contam. Toxicol.*, 4, 128, 1969.
67. Bagley, G. E., Reichel, W. L., and Cromartie, E. J., Identification of polychlorinated biphenyls in two bald eagles by combined gas-liquid-chromatography-mass spectrometry, *J. Assoc. Off. Anal. Chem.*, 53, 251, 1970.
68. Rote, W. J. and Murphy, P. G., A method for the quantitation of polychlorinated biphenyl (PCB) isomers, *Bull. Environ. Contam. Toxicol.*, 6, 377, 1971.
69. Graber, M. B., Domsky, I. L., and Ginn, M. E., A TLC method for the identification of germicides in personal care products, *J. Am. Oil Chem. Soc.*, 46, 529, 1968.
70. Elvidge, D. A., The gas chromatographic determination of 2,3,7,8-tetrachlorodibenzo-p-dioxin in 2,4,5-trichlorophenoxyacetic acid ("2,4,5-T"), 2,4,5-T ethylhexyl ester, formulations of 2,4,5-T esters and 2,4,5-trichlorophenol, *Analyst*, 96, 721, 1971.
71. Edmunds, J. W., Lee, D. F., and Nickels, C. M. L., Determination of 2,3,7,8-tetrachlorodibenzo-1,4-dioxin in 2,4,5-trichlorophenoxyacetic acid and 2,4,5-T alkyl ester herbicides, *Pestic. Sci.*, 4, 101, 1973.
72. Woolson, E. A., Thomas, R. F., and Ensor, P. D. J., Survey of polychlorodibenzo-p-dioxin content in selected pesticides, *J. Agric. Food Chem.*, 20, 351, 1972.
73. Ress, J., Higginbotham, G. R., and Firestone, D., Methodology for chlorinated aromatics in fats, oils, and fatty acids, *J. Assoc. Off. Anal. Chem.*, 53, 628, 1970.

NONS 200565

74. Williams, D. T. and Blanchfield, B. J., Thin layer chromatographic separation of two chlorodibenzo p-dioxins from some polychlorinated biphenyls and organochlorine pesticides, *J. Assoc. Off. Anal. Chem.*, 54, 1429, 1971.
75. Gump, W. S., 2-2-Dihydroxy-3,5,6,3',5',6'-hexachlorodiphenylmethane, U.S. Patent 2,2,50,480, 1941.
76. Browning, R. S., Grego, J., and Warrington, H. P., Jr., Gas chromatographic determination of hexachlorophene in blood and urine, *J. Pharm. Sci.*, 57, 2165, 1968.
77. Porcaro, P. J., Shubiak, P., and Manowitz, M., Determination of hexachlorophene in whole blood, *J. Pharm. Sci.*, 58, 251, 1969.
78. Kabacoff, B. L., Mohr, G., and Fairchild, C. M., Determination of hexachlorophene by gas-liquid chromatography of its trimethylsilyl derivative, *J. Soc. Cosmet. Chem.*, 21, 683, 1970.
79. Ulsamer, A. G., The determination of hexachlorophene in mammalian tissues by gas-liquid chromatography, *J. Assoc. Off. Anal. Chem.*, 55, 1294, 1972.
80. Bachmann, R. C. and Shetlar, M. R., The determination of hexachlorophene in biological tissue and fluids by gas liquid chromatography, *Biochem. Med.*, 2, 313, 1969.
81. Hawk, R. E. and Curley, A., Paper presented at 161st ACS National Meeting, Los Angeles, Cal., March 28 to April 2, 1971.
82. Sedlak, V., personal communication EPA, Bioeffects Branch, 4770 Buford Highway, Chamblee, Ga. 30341.
83. Gutenmann, H. W. and Lisk, D. J., GLC determination of hexachlorophene in animal agricultural samples, *J. Assoc. Off. Anal. Chem.*, 53, 522, 1970.
84. Hustert, K. and Korte, F., Beitrage zur ökologischen Chemie., *Chemosphere*, 1, 7, 1972.
85. Safe, S. and Hutzinger, O., Polychlorinated biphenyls: photolysis of 2,4,6,2',4',6'-hexachlorobiphenyl, *Nature*, 232, 641, 1971.
86. Hutzinger, O., Safe, S., and Zitko, V., Photochemical degradation of chlorobiphenyls (PCB's), *Environ. Health Perspect.*, No. 1, 15, 1972.
87. Crosby, D. G., Wong, A. S., Plimmer, J. R., and Woolson, E. A., Photodecomposition of chlorinated dibenzo-p-dioxins, *Science*, 173, 748, 1971.
88. Kearney, P. C., Woolson, E. A., and Ellington, C. P., Jr., Persistence and metabolism of chlorodioxins in soils, *Environ. Sci. Technol.*, 6(12), 1017, 1972.
89. Shaffer, G. W., Nitkawitz, E., Manowitz, M., and Daeniker, H. U., Photodegradation of hexachlorophene and related polychlorinated phenols, *Photochem. Photobiol.*, 13, 347, 1971.
90. Booth, A., Ambrose, A., DeEds, F., and Cox, A. J., The reversible nephrotoxic effects of biphenyl, *Toxicol. Appl. Pharmacol.*, 3, 560, 1961.
91. Deichmann, W. B., Kitzmiller, K. V., Dierker, M., and Witherup, S., Observations on the effects of diphenyl, o- and p-aminodiphenyl, o- and paranitrodiphenyl, and dihydroxyoctachlorodiphenyl upon experimental animals, *J. Ind Hyg. Toxicol.*, 29, 1, 1947.
92. Hakkinen, J., Siltanen, E., Hernberg, S., Seppalainen, A., Kadi, P., and Vikkula, E., Diphenyl poisoning in fruit paper production, *Arch. Environ. Health*, 26, 70, 1973.
93. Hansen, D. J., Patrick, P. R., Lowe, J. J., Wilson, A. J., Jr., and Wilson, P. D., Chronic toxicity, uptake and retention of Aroclor 1254 in two estuarine fishes, *Bull. Environ. Contam. Toxicol.*, 6, 113, 1971.
94. Linder, R. E., Gaines, T. B., and Kimbrough, R. D., The effect of polychlorinated biphenyls on rat reproduction, *Food Cosmet. Toxicol.*, in press.
95. Vos, J. G. and Koeman, J. H., Comparative toxicologic study with polychlorinated biphenyls in chickens with special reference to porphyria, edema formation, liver necrosis and tissue residues, *Toxicol. Appl. Pharmacol.*, 17, 656, 1970.
96. Vos, J. G. and Beems, R. B., Dermal toxicity studies of technical polychlorinated biphenyls and fractions thereof in rabbits, *Toxicol. Appl. Pharmacol.*, 19, 617, 1971.
97. Vos, J. G. and Notenboom-Ram, E., Comparative toxicity study of 2,4,5, 2',4',5'-hexachlorobiphenyl and a polychlorinated biphenyl mixture in rabbits, *Toxicol. Appl. Pharmacol.*, 23, 563, 1972.
98. Treon, J. F., Cleveland, F. P., Cappel, J. W., and Atchley, R. W., The toxicity of the vapors of Aroclor 1242 and Aroclor 1254, *Am. Ind. Hyg. Q.*, 17, 204, 1956.
99. Heath, R. G., Spann, J. W., Kreitzer, J. R., and Vance, C., Effects of polychlorinated biphenyls on birds, *Proc. 15th Intern. Ornithol Congr.*, 1972, Leiden, Holland, Brill, E. J., Ed., 476.
100. Blus, L. J., Heath, R. G., Gish, C. D., Belisle, A. A., and Prouty, R. M., Eggshell thinning in the brown pelican: implication of DDE, *Bioscience*, 21, 1213, 1971.
101. Peakall, D. B., Effect of polychlorinated biphenyls (PCB's) on the eggshells of ring doves, *Bull. Environ. Contam. Toxicol.*, 6, 100, 1971.
102. Dahlgren, R. B. and Linder, R. L., Effects of polychlorinated biphenyls on pheasant reproduction, *J. Wildl. Manage.*, 35, 315, 1971.
103. Dahlgren, R. B., Linder, R. L., and Carlson, C. W., Polychlorinated biphenyls: their effects on penned pheasants, *Environ. Health Perspect.*, No. 1, 89, 1972.
104. Keplinger, M. L., Fancher, O. E., and Calandra, J. C., Toxicologic studies with polychlorinated biphenyls, *Toxicol. Appl. Pharmacol.*, 19, 402, 1971.

NOMS 200566

105. Ringer, R. K., Aulerich, R. J., and Zabik, M., Effect of dietary polychlorinated biphenyls on growth and reproduction of mink, ACS Div. Water, Air and Waste Chemistry, preprints of papers 12, 149, 1972.
106. Rowe, V. K., Norris, J. M., Sparschu, G. L., Schwetz, B. A., and Gehring, P. J., Toxicology of chlorinated dibenzo-p-dioxins, Presented at 162nd ACS National Meeting, Washington, D.C., Sept. 1971, Abstr. #86.
107. Schulz, K. H., Klinische und experimentelle Untersuchungen zur Ätiologie der Chloracne, *Arch. Klin. Exp. Dermatol.*, 206, 589, 1957.
108. Milnes, M. H., Formation of 2,3,7,8-tetrachlorodibenzodioxin by thermal decomposition of sodium 2,4,5-trichlorophenate, *Nature*, 232, 395, 1971.
109. Sparschu, G. L., Dunn, F. L., and Rowe, V. K., Study of teratogenicity of 2,3,7,8-tetrachlorodibenzo-p-dioxin in the rat, *Food Cosmet. Toxicol.*, 9, 405, 1971.
110. Khera, S. and Ruddick, J. S., Perinatal effects of dibenzodioxins in Wistar rats, Presented at 162nd ACS National Meeting, Washington, D.C., Sept. 1971, Abstr. #87.
111. Courtney, K. D. and Moore, J. A., Teratology studies with 2,3,7,8-tetrachlorodibenzo-p-dioxin, *Toxicol. Appl. Pharmacol.*, 20, 396, 1971.
112. Moore, J. A., Gupta, B. N., Zinkl, J. G., and Vos, J. G., Postnatal effects of maternal exposure to 2,3,7,8-tetrachlorodibenzo-p-dioxin (TCDD), *Environ. Health Perspect.*, No. 5, 81, 1973.
113. Harris, M. W., Moore, J. A., Vos, J. G., and Gupta, B. N., General biological effects of TCDD in laboratory animals, *Environ. Health Perspect.*, No. 5, 101, 1973.
114. Gaines, T. B., Linder, R. E., and Kimbrough, R. D., unpublished material.
115. Gump, W. S., Toxicological properties of hexachlorophene, *J. Soc. Cosmet. Chem.*, 20, 173, 1969.
116. Hirschler, K., Inaugural Dissertation, College of Veterinary Medicine, Vienna, 1957.
117. Chung, H. L., Ts'ao, W. C., and Hsu, H. C., Hexachlorophene (G-11) as a new specific drug against chlonorchiasis sinensis: its efficacy and toxicity in experimental and human infection, *Chin. Med. J.*, 82, 691, 1963.
118. Gaines, T. B., Kimbrough, R. D., and Linder, R. E., The oral and dermal toxicity of hexachlorophene in rats, *Toxicol. Appl. Pharmacol.*, 25, 332, 1973.
119. Nakaue, H. S., Dost, F. N., and Buhler, D. R., Studies on the toxicity of hexachlorophene in the rat, *Toxicol. Appl. Pharmacol.*, 24, 239, 1973.
120. Udall, V. and Malone, J. C., Optic nerve atrophy after drug treatment, in *The Problems of Species Difference and Statistics in Toxicology*. Vol. XI. Excerpta Medica Foundation, Amsterdam, 1970, 224.
121. Thorpe, E., Some toxic effects of hexachlorophene in sheep, *J. Comp. Pathol.*, 79, 167, 1969.
122. Kimmel, C. A., Moore, W., and Stara, J. F., Hexachlorophene tetatogenicity in rats, *Lancet*, 2, 765, 1972.
123. Oakley, G. P. and Shepard, T. H., Possible teratogenicity of hexachlorophene in rats, *Teratology*, 5, 264, 1972, 12th Annual Meeting of Teratology Society, Abstr.
124. Kimbrough, R. D., Review of the toxicity of hexachlorophene, *Arch. Environ. Health*, 23, 119, 1971.
125. Larson, D. L., Abston, S., and Bachmann, R. C., Hexachlorophene absorption from the burn wound, in *Research in Burns*, Hans Huber, Bern, 1971, 619.
126. Wear, J. B., Jr., Shanahan, R., and Ratcliff, R. K., Toxicity of ingested hexachlorophene, *J.A.M.A.*, 181, 587, 1962.
127. Lustig, F. W., A fatal case of hexachlorophene (pHisoHex) poisoning, *Med. J. Aust.*, 50(1), 737, 1963.
128. Pilapil, V. R., Hexachlorophene toxicity in an infant, *Am. J. Dis. Child.*, 111, 333, 1966.
129. Kjerlof, B. and Winsten, J., The complications of pHisoHex, *Scand. J. Plast. Reconstr. Surg.*, 1, 78, 1967.
130. Mullick, F. G., Hexachlorophene toxicity – human experience at the AFIP, *Pediatrics*, 51, 395, 1973.
131. Herter, W. B., Hexachlorophene poisoning, *Kaiser Found. Med. Bull.*, 7, 228, 1959.
132. Lockhart, J. D., How toxic is hexachlorophene? *Pediatrics*, 50, 229, 1972.
133. Anon., Toxicity of hexachlorophene, *The Medical Letter on Drugs and Therapeutics*, 15, 1, Jan. 5, 1973.
134. Platte, B., Use of hexachlorophene linked to 15 U.S. deaths, brain lesions in 23 infants, *Skin Allergy News*, 3, 18, 1972.
135. Lyman, F. L. and Furia, T., Toxicology of 2,4,4' trichloro-2'-hydroxydiphenyl ether, *Ind. Med. Surg.*, 38, 64, 1969.
136. Hamblin, D. O., Aromatic nitro and amino compounds, in *Patt. Industrial Hygiene and Toxicology*. Interscience, New York, 1963, 2134.
137. Kimbrough, R. D., Toxicity of chlorinated hydrocarbons and related compounds, *Arch. Environ. Health*, 25, 125, 1972.
137a. May, G., Chloracne from the accidental production of tetrachlorodibenzodioxin, *Br. J. Ind. Med.*, 30, 276, 1973.
138. Herxheimer, K., Über Chloracne, *Munsch. Med. Wochenschr.*, 46, 278, 1899.
139. Wauer, H., Gewerbliche Erkrankungen durch gechlorte Kohlenwasserstoffe, *Zentralbl. Gewerbehyg.*, 6, 100, 1918.
140. Teleky, L., Die Pernakrankheit (Chlorakne), *Klin. Wochenschr.*, 6, 845, 1927.
141. Good, C. K. and Pensky, N., Halowax acne ("cable rash"), *Arch. Dermatol. Syphilol.*, 48, 251, 1943.
142. Braun, W., Klinische Beobachtungen Zur Entstehung der Chloracne, *Hautarzt*, 10, 126, 1959.
143. Mayers, M. R. and Silverberg, M. G., Skin conditions resulting from exposure to certain chlorinated hydrocarbons, *J. Indust. Hyg. Toxicol.*, 20, 244, 1938.
144. Crowe, K. D., Chloracne, *Trans. St. John's Hosp. Dermatol. Soc.*, 56, 79, 1970.
145. Jones, J. W. and Alden, H. W., An acneiform dermatergosis, *Arch. Dermatol. Syphilol.*, 33, 1022, 1936.

HONS 200567

146. Shelley, W. B. and Kligman, A. M., The experimental production of acne by penta- and hexachloronaphthalene, *Arch. Dermatol.*, 75, 689, 1957.
147. Plewig, G., Zur Kinetik der Comedonen-bildung bei Chloracne (Halowax-acne), *Arch. Klin. Exp. Dermatol.*, 238, 228, 1970.
148. Weber, G., Beitrag zur Atiologie und Prophylaxe der Chloracne, *Arbeitsmed. Sozialmed. Arbeitshyg.*, 36, 55, 1969.
149. Bauer, H., Schulz, K. H., and Spiegelberg, U., Berufliche Vergiftungen bei der Herstellung von Chlorphenol-Verbindungen, *Arch. Gewerbepathol. Gewerbehyg.*, 18, 538, 1961.
150. Kimmig, J. and Schulz, K. H., Berufliche Akne (Sog. Chlorakne) durch chlorierte aromatische zyklische Ather, *Dermatologica (Basel)*, 115, 540, 1957.
151. Schwartz, L., Tulipan, L., and Birmingham, D. J., *Occupational Diseases of the Skin*, 3rd ed., Lea and Febiger, Philadelphia, 1957, 336.
152. Adams, E. M., Irish, D. D., Spencer, H. C., and Rowe, V. K., The response of rabbit skin to compounds reported to have caused acne-form dermatitis, *Ind. Med. Surg.*, 2, 1, 1941.
153. Jones, E. L. and Kaizek, H., A technic for testing acnegenic potency in rabbits applied to the potent acnegen 2,3,7,8-tetrachlorodibenzo-p-dioxin, *J. Invest. Dermatol.*, 39, 511, 1962.
154. Inagami, K. and Koga, T., Experimental study of hairless mice following administration of rice oil used by a "Yusho" patient, *Fukuoka Acta Med.*, 60, 548, 1969.
155. Olafson, P., Hyperkeratosis (X-disease) of cattle, *Cornell Vet.*, 37, 279, 1947.
156. Sikes, D., Wise, J. C., and Bridges, M. E., The experimental production of "X-disease" (hyperkeratosis) in cattle with chlorinated naphthalenes and petroleum products, *J. Am. Vet. Med. Assoc.*, 121, 337, 1952.
157. Bell, W. B., Relative toxicity of the chlorinated naphthalenes in experimentally produced bovine hyperkeratosis (X-disease), *Vet. Med. Small Anim. Clin.*, 48, 135, 1953.
158. Wagener, K., Hyperkeratosis of cattle in Germany, *J. Am. Vet. Med. Assoc.*, 119, 133, 1951.
159. Nishizumi, M., Light and electron microscopic study of chlorobiphenyl poisoning, *Arch. Environ. Health*, 21, 620, 1970.
160. Allen, J. R. and Carstens, L. A., Light and electron microscopic observations in Macaca mulatta monkeys fed toxic fat, *Am. J. Vet. Res.*, 28, 1513, 1967.
161. Schoettle, C. E., Reber, E. F., Morrill, C. C., and Link, R. P., Experimental production of hyperkeratosis in rats and hamsters, *Am. J. Vet. Res.*, 16, 183, 1955.
162. Huber, W. G. and Link, R. P., Toxic effects of hexachloronaphthalene on swine, *Toxicol. Appl. Pharmacol.*, 4, 257, 1962.
163. Brock, W. E., Jones, E. W., Mac Vicar, R., and Pope, L. S., Chlorinated naphthalene intoxication in sheep, *Am. J. Vet. Res.*, 18, 625, 1957.
164. Burry, J. N., Photo-allergic contact dermatitis from halogenated phenolic compounds, *Australas. J. Dermatol.*, 9, 142, 1967.
165. Wilkinson, D. S., Photodermatitis due to tetrachlorosalicylanilide, *Br. J. Dermatol.*, 73, 213, 1961.
166. Jillson, O. F. and Baughman, R. D., Contact photodermatitis from bithionol, *Arch. Dermatol.*, 88, 408, 1963.
167. Jillson, O. F., The persistent light reactors, *Dermatol. Dig.*, 3, 59, 1964.
168. Willis, J. and Kligman, A. M., The mechanism of photoallergic contact dermatitis, *J. Invest. Dermatol.*, 51, 378, 1968.
169. Coxon, J. A., Jenkins, P. P., and Watti, D., The effect of light on halogenated salicylanilide ions, *Photochem. Photobiol.*, 4, 713, 1965.
170. Jones, W., Investigation of an outbreak of photodermatitis confined to one shop in a large factory, *Br. J. Ind. Med.*, 19, 100, 1962.
171. Calnan, C. D., Harman, R. R. M., and Wells, G. C., Photodermatitis from soaps, *Br. Med. J.*, 2, 1266, Nov. 11, 1961.
172. Frenk, E., Akute Putzmittelekzeme der Hande durch Tetrachlorsalicylanalid, *Dermatologica (Basel)*, 124, 433, 1962.
173. Epstein, S. and Eata, T., Photoallergic contact dermatitis, *J.A.M.A.*, 194, 168, 1965.
174. Osmundsen, P. E., Contact photodermatitis due to tribromosalicylanilide, *Dermatologica (Basel)*, 140, 65, 1970.
175. Bruun, J. N., Post-operative wound infection, *Acta. Med. Scand. Suppl.*, 514, 65, 1970.
176. Baker, H., Ive, F. A., and Lloyd, M. J., Primary irritant dermatitis of the scrotum due to hexachlorophene, *Arch. Dermatol.*, 99, 693, 1969.
177. McDonald, H. P. and Woodruff, M. W., Scrotal reaction of pHisohex, *J. Urol.*, 86, 266, 1961.
178. Boutwell, R. K. and Bosch, D. K., The tumor-promoting action of phenol and related compounds for mouse skin, *Cancer Res.*, 19, 413, 1959.
179. Harber, L. C., Targovnick, S. E., and Baer, R. L., Studies on contact photosensitivity to hexachlorophene and trichlorocarbanilide in guinea pigs and man, *J. Invest. Dermatol.*, 51, 373, 1968.
180. Schorr, W. F., Dichlorophene (G4) allergy, *Arch. Dermatol.*, 102, 515, 1970.
181. Simpson, C. F., Pritchard, W. R., and Harms, R. H., An endotheliosis in chickens and turkeys caused by an unidentified dietary factor, *J. Am. Vet. Med. Assoc.*, 134, 410, 1959.
182. Sanger, V. L., Scott, L., Hamdy, A., Gale, C., and Pounden, W. D., Alimentary toxemia in chicken, *J. Am. Vet. Med. Assoc.*, 133, 172, 1958.

MCMS 200568

183. Allen, J. R. and Carstens, L. A., Electron microscopic alterations in the liver of chickens fed toxic fat, *Lab. Invest.*, 15, 970, 1966.
184. Allen, J. R., The role of "toxic fat" in the production of hydropericardium and ascites in chickens, *Am. J. Vet Res.*, 25, 1210, 1964.
185. Flick, D. F., Firestone, D., and Higginbotham, G. R., Studies of the chick edema disease. 9. Response of chicks fed or singly administered synthetic edema-producing compounds, *Poult. Sci.*, 51, 2026, 1972.
186. Allen, J. R. and Lalich, J. J., Response of chickens to prolonged feeding of crude "toxic fat," *Proc. Soc. Exp. Biol. Med.*, 109, 48, 1962.
187. Anon., The chick edema factor, *Nutr. Rev.*, 26, 28, 1968.
188. McCune, E. L., Savage, J. E., and O'Dell, B. L., Hydropericardium and ascites in chicks fed a chlorinated hydrocarbon, *Poult. Sci.*, 41, 295, 1962.
189. Pudelkiewicz, W. J., Boucher, R. V., Callenbach, E. W., and Miller, R. C., Some physiological responses of New Hampshire chickens to a mixture of penta- and hexachloronaphthalenes, *Poult. Sci.*, 38, 424, 1959.
190. Cantieff, J. S., Webb, N. C., and Mabis, A. J., Search for chick edema factor, *Chem. Eng. News*, 45, 10, 1967.
191. Pichirallo, J., PCB's: Leaks of toxic substances raises issue of effects regulations, *Science*, 173, 899, 1967.
192. Kuratsune, M., Morikawa, Y., Hirohata, T., Nishizumi, M., Kohchi, S., Yoshimura, T., Matsuzaka, J., and Yamaguchi, A., An epidemiological study on "Yusho" or chlorobiphenyls poisoning, *Fukuoka Acta Med.*, 60, 513, 1969.
193. Metcalfe, L. D., Proposed source of chick edema factor, *J. Assoc. Off. Anal. Chem.*, 55, 542, 1972.
194. Kojima, T., Chlorobiphenyls in sputa and tissue, *Fukuoka Acta Med.*, 62, 25, 1971.
195. Yoshimura, T., Epidemiological analysis of "Yusho" with special reference to sex, age, clinical grades and oil consumption, *Fukuoka Acta Med.*, 62, 104, 1971.
196. Kuratsune, M., Yoshimura, T., Matsuzaka, J., and Yamaguchi, A., Epidemiologic study of Yusho, a poisoning caused by ingestion of rice oil contaminated with a commercial brand of polychlorinated biphenyls, *Environ. Health Perspect.*, No. 1, 119, 1972.
197. Okumura, M. and Katsuki, S., Clinical observation on Yusho (chlorobiphenyl poisoning), *Fukuoka Acta Med.*, 60, 440, 1969.
198. Urawa, H., Yasuo, J., Notomi, A., and Katsuki, S., Hyperglyceridemia resulting from intake of rice oil contaminated with chlorinated biphenyls, *Fukuoka Acta Med.*, 60, 449, 1969.
199. Nelson, W., *Textbook of Pediatrics*, W. B. Saunders, Co., Philadelphia, 1964, 313.
200. Kuroiwa, Y., Murai, Y., and Santa, T., Neurological and nerve conduction velocity studies on 23 patients with chlorobiphenyls poisoning, *Fukuoka Acta Med.*, 60, 462, 1969.
201. Murai, Y. and Kuroiwa, Y., Peripheral neuropathy in chlorobiphenyl poisoning, *Neurology*, 21, 1173, 1971.
202. Friend, M. and Trainer, D. O., Polychlorinated biphenyl: interaction with duck hepatitis virus, *Science*, 170, 1314, 1970.
203. Vos, J. G., Moore, J. A., and Zinkl, J. G., Effect of 2,3,7,8-tetrachlorodibenzo-p-dioxin on the immune system of laboratory animals, *Environ. Health Perspect.*, No. 5, 149, 1973.
204. Miller, J. F. A. P., Role of the thymus in immunity, *Br. Med. J.*, 2, 459, 1963.
205. Goldstein, J. A., Hickman, P., and Jue, D., Hepatic porphyria induced by polychlorinated biphenyls (PCB's): relationship between porphyria δ-amino-levulinic acid synthetase and cytochrome P-450, *Fed. Proc.*, 32, 702 (Abstr.), 1973, and *Toxicol. Appl. Pharmacol.*, in press.
206. Poland, A. and Glover, E., 2,3,7,8-Tetrachlorodibenzo-p-dioxin: a potent inducer of δ-aminolevulinic acid synthetase, *Science*, 179, 476, 1973.
207. Mathews, W. B. and Miller, H., *Diseases of the Nervous System*, Blackwell Scientific Publications, Edinburgh, 1972, 207.
208. Woods, J. S., Studies of the effects of 2,3,7,8-tetrachlorodibenzo-p-dioxin on mammalian hepatic δ-aminolevulinic acid synthetase, *Environ. Health Perspect.* No. 5, 221, 1973.
209. Goldstein, J. A., Hickman, P., Bergman, H., and Vos, J. G., Hepatic porphyria induced by 2,3,7,8-tetrachlorodibenzo-p-dioxin in the mouse, *Res. Commun. Chem. Pathol. Pharmacol.*, 6, 919, 1973.
210. Street, J. C., Umry, F. M., Wagstaff, D. J., and Blau, A. D., Comparative effects of polychlorinated biphenyl and organochlorine pesticides in induction of hepatic microsomal enzymes, presented at ACS 158th Annual Meeting, Sept. 1969, Div. Pesticide Chem. Abstr. #17.
211. Norback, D. H. and Allen, J. R., Enzymatic and morphologic alterations of hepatic endoplasmic reticulum induced by a chlorinated aromatic hydrocarbon, *Fed. Proc.*, 29, 816, 1970.
212. Litterst, C. L., Farber, T. M., Baker, A. M., and Van Loon, E. J., Effect of polychlorinated biphenyls on hepatic microsomal enzymes in the rat, *Toxicol. Appl. Pharmacol.*, 23, 112, 1972.
213. Alvarez, A. P., Bickers, D., and Kappas, A., Alteration of hepatic microsomal hemoprotein by polychlorinated biphenyls, *Fed. Proc.*, 32, 235 (Abstr.), 1973.
214. Benthe, H. F., Schmoldt, A., and Schmidt, H., Induction mikrosomaler Leberenzyme nach einmaliger Gabe von polychlorierten Biphenylen (PCB) und anschliessender Stress-Situation, *Arch. Toxicol.*, 29, 97, 1972.
215. Allen, J. R., Abrahamson, L. J., and Norback, D. H., Biological changes in primates produced by a polychlorinated biphenyl and triphenyl, *Fed. Proc.*, 32, 235 (Abstr.), 1973.

NONS 200569

216. Lincer, J. L. and Peakall, D. B., Metabolic effects of polychlorinated biphenyls in American kestrel, *Nature*, 228, 783, 1970.
217. Platonow, N. S., Liptrap, R. M., and Geisinger, H. D., The distribution and excretion of polychlorinated biphenyls (Aroclor 1254) and their effect on urinary gonadal steroid levels in the boar, *Bull. Environ. Contam. Toxicol.*, 7, 358, 1972.
218. Cecil, H. C., Harris, S. J., Bitman, J., and Fries, J. F., Polychlorinated biphenyl induced decrease in liver vitamin A in Japanese quail and rats, *Bull. Environ. Contam. Toxicol.*, 9, 179, 1973.
219. Cohrs, P., Jaffe, R., and Meessen, H., *Pathologie der Laboratoriumstiere*, 2, 281, 1958, Springer Verlag, Berlin, Gottingen and Heidelberg.
220. Ecobichon, D. J. and Johnstone, G. J., The influence of pure polychlorinated biphenyl compounds on hepatic function in the rat, presented at 12th Annual Meeting Soc. Toxicol., New York, New York, March 18-22, 1973.
221. Scopa, P., Effects of acute and chronic terphenyls and methylnaphthalenes administration on hepatic pento-barbital metabolism in the rat, *European Atomic Energy Community Eur.*, 3254e, Joint Nuclear Research, Italy, 1966.
222. Norback, D. H. and Allen, J. R., Chlorinated triphenyl-induced extensions of the hepatic endoplasmic reticulum, *Proc. Soc. Exp. Biol. Med.*, 139, 1127, 1972.
223. Lucier, G. W., McDaniel, O. S., Hook, G. E. R., Fowler, B., Sonawane, B. R., and Feeder, E., TCDD-induced changes in rat liver microsomal enzymes, *Environ. Health Perspect.*, No. 5, 199, 1973.
224. Fowler, B., Lucier, G. W., Brown, H., and McDaniel, O., Ultrastructural changes in rat liver cells following a single injection of TCDD, *Environ. Health Perspect.*, No. 5, 141, 1973.
225. Cammar, W. and Moore, C. L., The effect of hexachlorophene on the respiration of brain and liver, *Biochem. Biophys. Res. Commun.*, 46, 1887, 1972.
226. Caldwell, R. S., Nakano, H. S., and Buhler, D. R., Biochemical lesion in rat liver mitochondria induced by hexachlorophene [2,2' methylene bis (3,4,6-trichlorophenol)], *Biochem. Pharmacol.*, 21, 2425, 1972.
227. Gould, B. S., Frigerio, N. A., and Lebowitz, W. B., The action of the bis-phenolic compounds on succinoxidase, cytochrome c oxidase and lactic dehydrogenase of animal tissue, *Arch. Biochem. Biophys.*, 56, 476, 1955.
228. Glock, L. A., Perspective on hexachlorophene, *Pediatrics*, 51, 400, 1973.
229. Fisch, R. O., Berglund, E. B., Bridge, A. G., Finley, P. R., Oule, P. G., and Raße, R., Methemoglobinemia in a hospital nursery, *JAMA*, 185, 124, 1963.
230. Press, E., Cyanosis in premature and newborn infants, statement of subcommittee on accidental poisoning, *Am. Acad. Pediatr.*, June 26, 1962.
231. Johnson, R. R., Navone, R., and Larson, E. L., An unusual epidemic of methemoglobinemia, *Pediatrics*, 31, 222, 1963.
232. Curley, A., Burse, V. W., Grim, M. E., Jennings, R. W., and Linder, R. E., Polychlorinated biphenyls: distribution and storage in body fluids and tissues of Sherman rats, *Environ. Res.*, 4, 481, 1971.
233. Laug, E. P. and Fitzhugh, O. G., 2,2-Bis(p-chlorophenyl)-1,1,1-trichloroethane (DDT) in the tissues of the rat following oral ingestion for periods of six months to two years, *J. Pharmacol. Exp. Ther.*, 87, 18, 1946.
234. Kimbrough, R. D., Linder, R. E., Burse, V. W., and Jennings, R. W., Adenofibrosis in the rat liver with persistence of polychlorinated biphenyls in adipose tissue, *Arch. Environ. Health*, 27, 390, 1973.
235. Dahlgren, R. B., Bury, R. J., Linder, R. L., and Reidinger, R. F., Residue levels and histopathology in pheasants given polychlorinated biphenyls, *J. Wildl. Manage.*, 36, 524, 1972.
236. Bagley, G. and Cromartie, E., Elimination pattern of Aroclor 1254 components in the bobwhite, *J. Chromatogr.*, 75, 219, 1973.
237. Grant, D. L., Villeneuve, D. C., McCully, K. A., and Phillips, W. E. J., Placental transfer of polychlorinated biphenyls in the rabbit, *Environ. Physiol.*, 1, 61, 1971.
238. Curley, A., Burse, V. W., and Grim, M. E., Polychlorinated biphenyls: evidence of transplacental passage in the Sherman rat, *Food Cosmet. Toxicol.*, 11, 471, 1973.
239. Biros, F. J., Walter, A. C., and Medbery, A., Polychlorinated biphenyls in human adipose tissue, *Bull. Environ. Contam. Toxicol.*, 5, 317, 1970.
240. Price, H. A. and Welch, R. L., Occurrence of polychlorinated biphenyls in humans, *Environ. Health Perspect.*, No. 1, 73, 1972.
241. Yobs, A. R., Levels of polychlorinated biphenyls in adipose tissue of the general population of the nation, *Environ. Health Perspect.*, No. 1, 79, 1972.
242. Bjerk, J. E., Rester av DDT og polyklorerte bifenyler i Norsk humant materiale, *Tidsskr. Nor. Laegeforen.*, 92, 15, 1972.
243. Acker, L. and Schulte, E., Über das Vorkommen von chlorierten Biphenylen und Hexachlorbenzol neben chlorierten Insektiziden in Humanmilch und menschlichem Fettgewebe, *Naturwissenschaften*, 57, 497, 1970.
244. Curley, A., Burse, V. W., Jennings, R. W., Villanueva, E. C., Tomatis, L., and Akazaki, K., Chlorinated hydrocarbon pesticides and related compounds in adipose tissue from people of Japan, *Nature*, 242, 338, 1973.
245. Nishimoto, T., Ueta, M., Taue, S., Chikasawa, K., Nishiwaki, J., and Kondo, K., Organochlorine pesticide residues and PCB in human fat, *Igaku no Ayumi (Proc. Med. Sci.)*, 82, 515, 1972.
246. Addison, R. F., Fletcher, G. L., Ray, S., and Doane, J., Analysis of a chlorinated terphenyl (Aroclor 5460) and its deposition in tissues of cod, *Bull. Environ. Contam. Toxicol.*, 8(1), 52, 1972.

NONS 200570

247. Firestone, F., Flick, D. F., Ross, J., and Higginbotham, G. R., Distribution of chick edema factors in chick tissue, *J. Assoc. Off. Anal. Chem.*, 54, 1293, 1973.
248. Zitko, V., Wildish, D. J., Hutzinger, O., and Choi, P. M. K., Acute and chronic oral toxicity of chlorinated dibenzofurans to salmonid fishes, *Environ. Health Perspect.*, No. 5, 187, 1973.
249. Williams, D. T., Cunningham, H. M., and Blanchfield, B. J., Distribution and excretion studies of octachlorodibenzo-p-dioxin in the rat, *Bull. Environ. Contam. Toxicol.*, 7, 57, 1972.
250. Piper, W. N., Rose, J. Q., and Gehring, P. J., Excretion and tissue distribution of 2,3,7,8-tetrachlorodibenzo-p-dioxin in the rat, *Environ. Health Perspect.*, No. 5, 241, 1973.
251. Norback, D. H. and Allen, J. R., Biological responses of the non-human primate, chicken and rat to chlorinated dibenzo-p-dioxin ingestion, *Environ. Health Perspect.*, No. 5, 233, 1973.
252. Block, W. D. and Cornish, H. H., Metabolism of biphenyl and 4-chlorobiphenyl in the rabbit, *J. Biol. Chem.*, 234, 3301, 1959.
253. Hutzinger, O., Nash, D. M., Safe, S., DeFreitas, A. S. W., Norstrom, R. J., Wildish, D. J., and Zitko, V., Polychlorinated biphenyls: metabolic behavior of pure isomers in pigeons, rats and brook trout, *Science*, 178, 312, 1972.
254. Wit, J. G. and Van Genderen, H., Some aspects of the fate of hexachlorophene (2,2'-methylene-bis(3,4,6-trichlorophenol)) in rabbits, rats and dairy cattle, *Acta Physiol. Pharmacol. Neerl.*, 11, 123, 1962.
255. Kok, K. (1961) cited after Wit, J. G. and Van Genderen, H., Some aspects of the fate of hexachlorophene (2,2'-methylene-bis (3,4,6-trichlorophenol)) in rabbits, rats and dairy cattle, *Acta Physiol. Pharmacol. Neerl.*, 11, 123, 1962.
256. Carroll, F. E., Salak, W. W., and Howard, J. M. et al., Absorption of antimicrobial agents across experimental wounds, *Surg. Gynecol. Obstet.*, 125, 974, 1967.
257. Manowitz, M. and Johnston, V. D., Deposition of hexachlorophene on the skin, *J. Soc. Cosmet. Chem.*, 18, 527, 1967.
258. Curley, A., Hawk, R. E., Kimbrough, R. D., Nathenson, G., and Finberg, L., Dermal absorption of hexachlorophene in infants, *Lancet*, 2, 296, 1971.
259. Kimbrough, R. D., Review of recent evidence of toxic effects of hexachlorophene, *Pediatrics*, 51, 391, 1972.
260. Curley, A. and Hawk, R. E., Hexachlorophene. I. Analysis in body fluids and tissues of experimental animals, presented at 161st ACS National Meeting, Los Angeles, Cal., March 28-April 2, 1971.
261. Sedlak, V., EPA, 4770 Buford Highway, Chamblee, Ga. 30341, and Kopelman, A. E., University of Rochester, Rochester, N.Y. (personal communications).
262. Abbott, L. M., Buckfield, P. M., Ferry, D. G., Malcolm, D. S., and McQueen, E. G., Blood levels of hexachlorophene in neonates, *Aust. Paediatr. J.*, 8, 246, 1972.
263. Alder, V. C., Burman, D., Corner, B. D., and Gillespie, W. A., Absorption of hexachlorophene from infants' skin, *Lancet*, 2, 384, 1972.
264. Santolucito, J. A., Electroencephalograms and visual evoked potential of the squirrel monkey fed hexachlorophene, *Toxicol. Appl. Pharmacol.*, 22, 276, 1972.
265. Ulsamer, A. G., Yoder, P. D., and Marzulli, F. N., Determination of hexachlorophene in human and experimental animal tissues, *Toxicol. Appl. Pharmacol.*, 22, 276, 1972.
266. Zehr, R. D., EPA, 4770 Buford Highway, Chamblee Ga. 30341, personal communication.
267. Bennett, G. A., Drinker, C. K., and Warren, M. F., Morphological changes in the livers of rats resulting from exposure to certain chlorinated hydrocarbons, *J. Ind. Hyg. Toxicol.*, 20, 97, 1938.
268. Miller, J. W., Pathologic changes in animals exposed to a commercial chlorinated diphenyl, *Public Health Rep.*, 59, 1085, 1944.
269. Nishizumi, M., Light and electron microscope study of chlorobiphenyl poisoning: in mouse and monkey liver, *Arch. Environ. Health*, 21, 620, 1970.
270. Norback, D. H. and Allen, J. R., Chlorinated aromatic hydrocarbon induced modifications of the hepatic endoplasmic reticulum: concentric membrane arrays, *Environ. Health Perspect.*, No. 1, 137, 1972.
271. Kolter, L. D. and Zinkl, J. G., Pathology of polychlorinated biphenyls in rabbits, *Am. J. Pathol.*, 70, 363, 1973.
272. Kimbrough, R. D., Linder, R. E., and Gaines, T. B., Morphological changes in livers of rats fed polychlorinated biphenyls, *Arch. Environ. Health*, 25, 354, 1972.
273. Gaines, T. B. and Kimbrough, R. D., Oral toxicity of mirex in adult and suckling rats, *Arch. Environ. Health*, 21, 7, 1970.
274. Kimbrough, R. D., Gaines, T. B., and Hayes, W. J., Jr., Combined effect of DDT, pyrethrum, and piperonyl butoxide on rat liver, *Arch. Environ. Health*, 16, 333, 1968.
275. Kimbrough, R. D., Gaines, T. B., and Linder, R. E., The ultrastructure of livers of rats fed DDT and dieldrin, *Arch. Environ. Health*, 22, 460, 1971.
276. Edwards, J. E. and White, J., Pathologic changes with special reference to pigmentation and classification of hepatic tumors in rats fed p-dimethyl-aminoazobenzene (butter yellow), *J. Natl. Cancer Inst.*, 2, 157, 1941.
277. Stewart, H. L. and Snell, K. C., The histopathology of experimental tumors of the liver of the rat: a critical review of the histopathogenesis, *Acta Unio Int. Contra Cancrum.*, 13, 770, 1957.

MONS 280571

278. Reuber, M. D., Histogenesis of cholangiofibrosis and well differentiated cholangiocarcinoma in Syrian hamsters given 2-acetoamidofluorene or 2-diacetoamidofluorene, *Gann*, 59, 239, 1968.
279. Kimbrough, R. D., Pancreatic type tissue in livers of rats fed polychlorinated biphenyls, *J. Natl. Cancer Inst.*, 51 679, 1973.
280. Firminger, H. I., Histopathology of carcinogenesis and tumors of the liver in rats, *J. Natl. Cancer Inst.*, 15, 1455 1955
281. Salomon, W. D., Copeland, D. H., and Burns, M. J., Hepatomas in choline deficiency, *J. Natl. Cancer Inst.*, 15, 1549 1955
282. Flinn, F. B. and Jarvik, N. E., Actions of certain chlorinated naphthalenes on the liver, *Proc. Soc. Exp. Biol. Med.* 35, 118, 1936.
283. Cotter, L. H., Pentachlorinated naphthalenes in industry, *J.A.M.A.*, 125, 173, 1944.
284. Kimbrough, R. D. and Linder, R. E., EPA, 4770 Buford Highway, Chamblee, Ga. 30341, personal communication (unpublished material).
285. Allen, J. R. and Carstens, L. A., Light and electron microscopic observations in Macacca mulatta monkeys fed toxa fat, *Am. J. Vet. Res.*, 28, 1513, 1967.
286. Pugh, D. M. and Crowley, J., Some observations on the toxicity of hexachlorophene for sheep, *Vet. Rec.*, 78, 86, 1966.
287. Ortega, P., Hayes, W. J., Jr., Durham, W. F., and Mattson, A., DDT in the diet of the rat, *Public Health Monogr.* 43, P.H.S. Publ. No. 484, 1956.
288. Poland, A., Smith, D., Kuntzman, R., Jacobson, M., and Conney, A. H., Effect of intensive occupational exposure to DDT on phenylbutazone and cortisol metabolism in human subjects, *Clin. Pharmacol. Ther.*, 11, 724, 1970.
289. Hutterer, F., Schaffner, F., Klion, F. M., and Popper, H., Hypertrophic, hypoactive smooth endoplasmic reticulum a sensitive indicator of hepatotoxicity exemplified by dieldrin, *Science*, 161, 1017, 1968.
289a. Kimura, N. T. and Baba, T., Neoplastic changes in the rat liver induced by polychlorinated biphenyls, *Gann*, 64, 105, 1973.
290. Murai, Y. and Kuroiwa, Y., Peripheral neuropathy in chlorobiphenyl poisoning, *Neurology*, 21, 1173, 1971.
291. Kimbrough, R. D. and Gaines, T. B., The effect of hexachlorophene on the rat brain. Light microscopy and ultrastructure, *Arch. Environ. Health*, 23, 114, 1971.
292. Garner, F. M., Innes, J. R. M., and Nelson, D. H., in *Pathology of Laboratory Rats and Mice*, Cotchin, E. and Roe, F. J., Eds., F. A. Davis Co., Philadelphia, 1967, 337.
293. Magee, P. N., Stoner, H. B., and Barnes, J. M., The experimental production of edema in the central nervous system of the rat by triethyltin compounds, *J. Pathol. Bacteriol.*, 73, 107, 1957.
294. Adornato, B. and Lampert, P., Status spongiosus of nervous tissue, *Acta Neuropathol.*, 19, 271, 1971.
295. Kurtz, S. M., Schardein, J. L., Fitzgerald, J. F., and Kaump, D. H., Toxicologic studies with a halogenated salicylamide, *Toxicol. Appl. Pharmacol.*, 14, 81, 1969.
296. Brown, W. R., Rubin, L., Hite, M., and Zwickey, R. E., Experimental papilledema in the dog induced by salicylamide, *Toxicol. Appl. Pharmacol.*, 21, 532, 1972.
297. Balazs, T., Measurements of acute toxicity, in *Methods in Toxicology*, G. E. Paget, Ed., F. A. Davis Co., Philadelphia, 1970, 60.
298. Larson, D. L., Studies show hexachlorophene causes burn syndrome, *Hospitals*, 42, 63, 1968.
299. Hanig, J. P., Morrison, J. M., Jr., and Krop, S., Attenuation of CNS toxicity of hexachlorophene in the rat and the cat, presented at 12th Annual Meeting Soc. Toxicol., New York, March 18-22, 1973, Abstr. #3.
300. FDA Bulletin, Hexachlorophene and newborns, Dec. 1971.
301. Santoluccito, J. A., EPA, Research Triangle Park, N. C., personal communication.
302. Hale, G. A. and Reid, J. M., Hexachlorophene toxicity in sheep, *Lancet*, 2, 1251, 1972.
303. Lampert, P., O'Brien, J., and Garrett, R., Hexachlorophene encephalopathy, *Acta Neuropathol.*, 23, 326, 1973.
304. Shuman, R. M., Leech, R. W., and Alvord, E. C., Neurotoxicity of hexachlorophene in human infants: a clinico-pathologic study of 250 infants, submitted for publication to Pediatrics.
305. Powell, H., Swanner, O., Gluck, L., and Lampert, P., Hexachlorophene myelinopathy in premature infants, *J. Pediatr.*, 82, 976, 1973.
306. Leukhart, J., formerly Bureau of Drugs, U.S. Food and Drug Administration, personal communication.
307. Klatzo, I. and Seitelberger, F., Eds., *Brain Edema*, Springer, New York, 1967.
308. Adornato, B. and Lampert, P., Status spongiosus of nervous tissue, *Acta Neuropathol.*, 19, 271, 1971.
309. Anon., Spongy change in the brain, *Br. Med. J.*, 3, 433, 1972.
310. Allen, J. R. and Norback, D. H., Polychlorinated biphenyl- and triphenyl-induced gastric mucosal hyperplasia in primates, *Science*, 179, 498, 1973.
311. Goldmann, P. J., Schwerste acute Chlorakne durch Trichlorophenolzersetzungsprodukte, *Arbeitsmed. Sozialmed. Arbeitshyg.*, 7, 12, 1972.
312. Light, J. T. and Sutherland, J. M., What is the evidence that hexachlorophene is not effective, *Pediatrics*, 51, 345, 1973.
313. Evans, H. E., Akpata, S. O., Baki, A., and Glass, L., Flora in newborn infants, *Arch. Environ. Health*, 26, 275, 1973.

MCNS 200572