26. Handin RI, Stossel TP. Effect of corticosteroid therapy on the phagocytosis of antibody-coated platelets by human leukocytes. Blood 1978; 51: 771-9.
27. Aster RH, Keene WR. Sites of platelet destruction in idiopathic thrombocytopenic purpura. Br J Haematol 1969; 16:61-73.
28. Ries CA, Price DC. [$^{51}$Cr]platelet kinetics in thrombocytopenia: correlation between splenic sequestration of platelets and response to splenectomy. Ann Intern Med 1974; 80:702-7.
29. Ahn YS, Byrnes JJ, Harrington WJ, et al. The treatment of idiopathic thrombocytopenia with vinblastine-loaded platelets. N Engl J Med 1978; 298:1101-7.
30. Fehr J, Hofmann V, Kappeler U. Transient reversal of thrombocytopenia in idiopathic thrombocytopenic purpura by high-dose intravenous gamma globulin. N Engl J Med 1982; 306:1254-8.
31. Williams WJ, Beutler E, Erslev AJ, Lichtman MA. Hematology. 3rd ed. New York: McGraw-Hill, 1983:645.
32. Alexandrova AY, Vasiliev JM. Capping of cross-linked concanavalin A receptors on the surface of substrate-spread platelets. Cell Motil 1982; 2:163-71.
33. Cines DB, Wilson SB, Tomaski A, Schreiber AD. Platelet antibodies of the IgM class in immune thrombocytopenic purpura. J Clin Invest 1985; 75:1183-90.

# CASE RECORDS
## OF THE
# MASSACHUSETTS GENERAL HOSPITAL



**Weekly Clinicopathological Exercises**

FOUNDED BY RICHARD C. CABOT

ROBERT E. SCULLY, M.D., *Editor*
EUGENE J. MARK, M.D., *Associate Editor*
WILLIAM F. MCNEELY, M.D., *Associate Editor*
BETTY U. MCNEELY, *Assistant Editor*

## CASE 4-1987

### PRESENTATION OF CASE

*First admission.* A 48-year-old man was admitted to the hospital because of a pleural effusion.

He was well until 16 months earlier, when a routine x-ray film of the chest (Fig. 1) showed a nodule in the right lung and right pleural thickening or effusion; the patient was asymptomatic. Four months later tomographic examination of the lungs revealed that the nodule had an irregular border. He entered another hospital, where a right thoracotomy disclosed a fibrotic lesion, which was removed. He was discharged feeling well, with small bilateral pleural effusions. Three months before admission pleuritic pain developed abruptly in the left side of the chest and radiated to the left arm. He was admitted to another hospital, where an electrocardiogram was normal. X-ray films of the chest (Fig. 2) showed a left pleural effusion and an irregular opacity at the left base; right-sided pleural thickening was noted. A left-sided thoracentesis yielded bloody fluid that contained 79,000 red cells and 2000 white cells, of which 85 percent were mononuclear cells and 15 percent neutrophils; the glucose was 96 mg per 100 ml (5.3 mmol per liter), and the protein 5.1 g per 100 ml; microscopical examination of stained specimens disclosed no acid-fast bacilli or malignant-tumor cells. A venographic study of both lower extremities was reported to show bilateral thrombi. The patient was discharged on warfarin. Two weeks later x-ray films of the chest showed an increase in the left pleural effusion. A thoracentesis yielded 1400 ml of bloody fluid; microscopical examination of stained specimens was reported to show "reactive mesothelial cells." He entered another hospital, where a pulmonary angiographic examination was stated to be negative. He was then well until one month before entry, when progressive dyspnea, fatigue, and intermittent pleuritic chest pain at rest developed, without cough or hemoptysis. Three weeks before admission a thoracentesis yielded 1800 ml of bloody fluid. One week later x-ray films of the chest disclosed recurrence of the pleural effusion (Fig. 3). The patient was referred to this hospital.

There was a history of chest pain six years earlier, with a negative medical evaluation. He had a 20-pack-year history of cigarette smoking, which he discontinued 18 years before entry; he ingested alcohol occasionally. Until the age of 28 years he performed clerical work in a steel company. He continued in a clerical position during the next five years and resided 10 miles (16 km) from an asbestos plant; there was no other history of exposure to asbestos. From the age of 40 years to the time of admission he worked as a purchasing agent for a chemical manufacturer. Both parents were alive and well in their 80s. His brother had undergone a coronary-artery-bypass graft procedure. There was no history of fever, malaise, weight loss, tuberculosis, cardiac, renal, or hepatic disease, or exposure to heavy metals, and there was no family history of pulmonary disease.

The temperature was 37°C, the pulse was 76, and the respirations were 24. The blood pressure was 130/70 mm Hg.

On examination the patient appeared well. No rash or lymphadenopathy was found, and the head and neck were normal. There was dullness with diminished breath sounds at the base of the left lung. The heart and abdomen were normal. There was no peripheral edema, digital clubbing or cyanosis, or evidence of thrombophlebitis.

The urine was normal. The hematocrit was 48 percent; the white-cell count was 6500, with 66 percent neutrophils, 33 percent lymphocytes, and 1 percent

Blumberg No. 8113 PLAINTIFF'S EXHIBIT SA-316

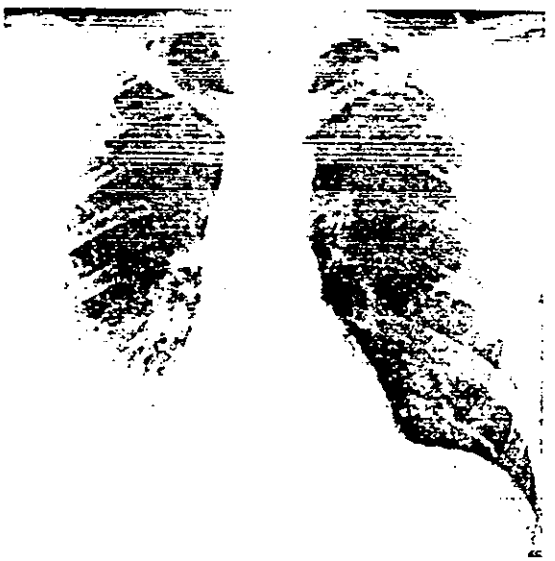

Figure 1. Roentgenogram of the Chest Obtained 16 Months before the First Admission, Showing Right-Sided Pleural Thickening and a Nodule in the Right Upper Lobe.

monocytes. The platelet count was 219,000, and the erythrocyte sedimentation rate 2 mm per hour. The prothrombin time was 12.4 seconds, with a control of 10.7 seconds; the partial thromboplastin time was 27.8 seconds. The urea nitrogen was 15 mg per 100 ml (5.4 mmol per liter), the glucose 110 mg per 100 ml (6.1 mmol per liter), the calcium 9.4 mg per 100 ml (2.4 mmol per liter), the phosphorus 3.8 mg per 100 ml (1.2 mmol per liter), and the protein 7.5 g (the albumin 4.5 g and the globulin 3.0 g) per 100 ml. The sodium was 139 mmol, the potassium 4.4 mmol, the chloride 105 mmol, and the carbon dioxide 28 mmol per liter. The serum aspartate aminotransferase (SGOT) was 13 U, the lactic dehydrogenase (LDH) 96 U, and the creatine kinase (CK) 13 U per liter; the amylase was 14 U per milliliter. An electrocardiogram was normal. X-ray films of the chest revealed bilateral pleural thickening that was greater on the left side. There was an irregular, spiculated nodule at the right-lung base that abutted the pleura; scarring and volume loss were noted in the right upper lobe, consistent with postoperative changes. The heart size was obscured by the left pleural effusion; the mediastinum appeared normal. Lateral decubitus views showed a free-flowing left pleural effusion; the right pleural abnormality did not change appreciably. A specimen of arterial blood, drawn while the patient was breathing ambient air, showed that the partial pressure of oxygen ($PaO_2$) was 87 mm Hg, the partial pressure of carbon dioxide ($PaCO_2$) 38 mm Hg, and the pH 7.45. Pulmonary-function studies demonstrated that the first-second vital capacity ($FEV_1$) was 2.74 liters (predicted, 3.94), and the total vital capacity 4.03 liters (predicted, 4.88). A skin test with mumps antigen was positive; a tuberculin skin test (PPD, 5 TU) was negative. Review of the pulmonary angiographic examination performed earlier confirmed that it was negative; review of the venographic examination showed no evidence of thrombi. A left-sided thoracentesis yielded 24 ml of bloody fluid that had a hematocrit of 7 percent and contained 3875 white cells, of which 6 percent were neutrophils, 73 percent lymphocytes, 5 percent eosinophils, and 16 percent nonhematic cells; the glucose was 95 mg per 100 ml (5.3 mmol per liter), the protein 5.4 g per 100 ml, and the LDH 78 U per liter; the amylase was 12 U per milliliter; microscopical examination of stained specimens of the fluid disclosed no acid-fast bacteria, fungi, or other microorganisms and no evidence of malignant-tumor cells. Microscopical examination of a biopsy specimen of the pleura showed chronic inflammation and fibrosis; aggregates of hemosiderin-laden macrophages were present; no granulomas or malignant-tumor cells were observed. X-ray films of the chest revealed that the left pleural effusion was markedly decreased, and the cardiomediastinal silhouette appeared normal; multiple calcified granulomas were seen in both lungs. The right pleural abnormality did not change on a decubitus view, suggesting that it represented pleural thickening rather than fluid; an irregular nodule was again noted at the right-lung base. A computed tomographic (CT) scan of the thorax showed sutures at the right apex and scarring in the right upper lobe, consistent with the previous operation; nodular and irregular pleural thickening extended laterally along the pleura and into the major fissure; a spiculated mass abutted the pleura at the right base and extended into the parenchyma of the right lower lobe; a large pleural effusion

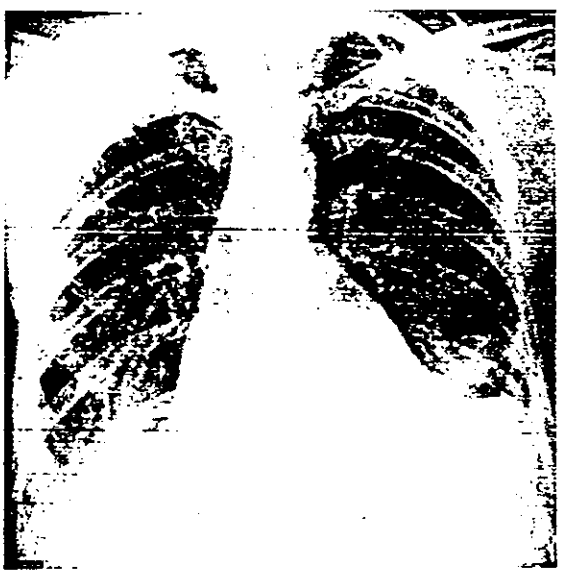

Figure 2. Roentgenogram of the Chest Taken Three Months before the First Admission, Showing a Left Pleural Effusion and an Irregular Opacity at the Left Base.
Postoperative changes are visible on the right side.

with pleural nodularity was seen on the left side. Abdominal scans through the level of the pancreas showed no abnormality; the spleen appeared enlarged. Fiberoptic bronchoscopic examination demonstrated a normal appearance of the vocal cords and trachea; the bronchus to the right upper lobe was retracted upward, consistent with volume loss. Microscopical examination of two transbronchial-biopsy specimens revealed focal interstitial fibrosis, without evidence of a malignant tumor. Examination of stained specimens of bronchial washings and brushings disclosed no acid-fast bacilli, fungi, or malignant-tumor cells, and routine cultures were negative. Cytologic examination of sputum for malignant-tumor cells was negative on four occasions. A test for antinuclear antibodies was positive in a titer of 1:64, with a homogeneous pattern. The CH50 was 188 U (normal, 150 to 250), and a test for rheumatoid factor was negative. Review of the biopsy specimen from the right upper lobe obtained one year earlier confirmed the presence of pleural and subpleural fibrosis, without evidence of a malignant tumor.

A left-sided thoracotomy was performed, with aspiration of 2200 ml of bloody fluid. Multiple linear pleural plaques were observed over the posterior aspect of the left upper lobe, and a rounded pleural plaque was seen on the posterior aspect of the superior segment of the left lower lobe; the parietal pleura was diffusely inflamed; it was not thickened except for a white pleural plaque over the diaphragmatic aspect, with adhesions to the base of the lung. Microscopical examination of biopsy specimens of the pleura disclosed hyaline plaques and chronic pleuritis with lymphoid aggregates and cellular fibrosis. Microscopic nodules of hyaline fibrosis with calcification were seen in specimens of lung taken from the left upper and lower lobes; no granulomas or evidence of diffuse pneumonitis was found. X-ray films of the chest again showed bilateral pleural thickening that did not change on decubitus views; the spiculated mass at the base of the right lung was unchanged; a new opacity was noted in the left-lung field, possibly reflecting irregular pleural thickening in the major fissure. An attempted right-sided thoracentesis yielded no pleural fluid. Prednisone was begun in a dose of 40 mg daily, and the patient was discharged on the 22nd hospital day.



Figure 3. Radiograph of the Chest Taken Two Weeks before the First Admission, Disclosing a Moderate-Sized Left Pleural Effusion and a Spiculated Nodule at the Right-Lung Base.
The right-sided pleural thickening is unchanged.

*Second admission* (21 months later). The dose of prednisone was tapered over a period of six months. All cultures for mycobacteria and fungi were negative except for the growth of a penicillium species in the bronchial washings. At follow-up examination nine months after discharge the patient was well aside from an occasional cough productive of clear sputum and bouts of precordial "pressure" that occurred only at rest, accompanied by mild dyspnea without nausea, and subsided in about 10 minutes. Physical examination was negative except for dullness at the base of the right lung. X-ray films of the chest, obtained elsewhere, disclosed little change. The patient continued to feel well and to work regularly until two months before admission, when he began to experience progressive exertional dyspnea and more frequent anterior chest "pressure" that worsened on exertion. He awoke frequently during the night with dyspnea and had bouts of flushing and sweating several times weekly. He again coughed up clear sputum. Evaluation by his personal physician included an x-ray film of the chest that was reported to be unchanged. An electrocardiogram remained normal. A blood count was normal. The alkaline phosphatase was 361 U per liter (normal, 90 to 287). A specimen of arterial blood, drawn while the patient was breathing ambient air, revealed that the $PaO_2$ was 90 mm Hg, the $PaCO_2$ 31.4 mm Hg, and the pH 7.44. Pulmonary-function studies disclosed that the $FEV_1$ was 2.25 liters and the VC 3.13 liters; the single-breath carbon monoxide diffusing capacity (DLCO) was 25.8 ml per minute per millimeter of mercury (normal, 29). A treadmill stress test was limited by dyspnea but showed 1-mm upsloping ST-segment depressions.

Five weeks before entry the patient returned to this hospital, where examination showed dullness and a few crackles at both lung bases; a Grade 1 systolic murmur was heard. The remainder of the physical examination was negative. X-ray films of the chest disclosed interval progression of bilateral pleural abnormalities, more marked on the right side. A specimen of arterial blood, drawn while the patient was breathing ambient air at rest, showed that the $PaO_2$ was 76 mm Hg, the $PaCO_2$ 36 mm Hg, and the pH 7.40. Pulmonary-function studies demonstrated that the $FEV_1$ was 1.55 liters, and the VC 2.32 liters. A cardiopulmonary exercise test revealed that the resting heart

rate was 101, with a left ventricular ejection fraction of 58 percent; on exercise the heart rate rose to 145, with a left ventricular ejection fraction of 62 percent; the maximal oxygen uptake was 1.3 liters per minute (50 percent of predicted), and the anaerobic threshold was 1.0 liter per minute. Four weeks before admission prednisone was resumed in a dose of 40 mg daily, and it was increased to 80 mg daily two weeks later, without improvement. The patient became too ill to work. Three days before admission he began to experience episodes of pain in his feet and legs. Two days before entry his sputum was yellow and then rusty. He was readmitted to this hospital.

The patient had continued to have periodic sweats. He had lost 3.2 kg in weight during the two weeks preceding entry, although his appetite was good. There was no history of chills, fever, rash, headache, arthralgia, abdominal or calf pain, or peripheral edema.

The temperature was 37.1°C, the pulse was 120, and the respirations were 18. The blood pressure was 150/95 mm Hg, without pulsus paradoxus.

On examination the patient was flushed and appeared tired, breathing oxygen by nasal prongs. No rash or lymphadenopathy was found. The head and neck were normal except that the jugular venous pressure was 8 cm, without a hepatojugular reflux. Diminished breath sounds were noted over both lungs, without rales or wheezes. No spinal tenderness was found. The heart sounds were decreased; no murmur or pericardial friction rub was heard. Abdominal examination was negative. The extremities were normal except that the posterior tibial and dorsalis pedis pulses were diminished bilaterally. Neurologic examination showed slight ptosis of the right upper eyelid; the right pupil was 2.5 mm and the left pupil 3.0 mm, and both were reactive. No other neurologic abnormality was found.

The urine was normal. The hematocrit was 50.2 percent; the white-cell count was 25,900, with 77 percent neutrophils, 6 percent band forms, 3 percent lymphocytes, 8 percent monocytes, and 6 percent eosinophils. The total eosinophil count was 1013 per cubic millimeter, and the platelet count 153,000; the erythrocyte sedimentation rate was 2 mm per hour. The urea nitrogen was 17 mg per 100 ml (6.1 mmol per liter), the glucose 92 mg per 100 ml (5.1 mmol per liter), the bilirubin 0.9 mg per 100 ml (20 μmol per liter), the uric acid 5.1 mg per 100 ml (0.30 mmol per liter), the calcium 9.3 mg per 100 ml (2.3 mmol per liter), the phosphorus 2.7 mg per 100 ml (0.87 mmol per liter), and the protein 6.4 g (the albumin 3.8 g and the globulin 2.6 g) per 100 ml. The sodium was 140 mmol, the potassium 4.3 mmol, the chloride 105 mmol, and the carbon dioxide 23 mmol per liter. The SGOT was 12 U, the LDH 254 U, the CK 8 U, and the alkaline phosphatase 178 U per liter; the amylase was 14 U per milliliter. An electrocardiogram demonstrated sinus tachycardia at a rate of 120, with nonspecific ST-segment and T-wave abnormalities.



Figure 4. Radiograph of the Chest Obtained on the Second Admission, Showing Bilateral Extensive Lobular Pleural Thickening Involving the Posterior, Lateral, and Mediastinal Pleural Surfaces.
The cardiac silhouette is enlarged.

X-ray films of the chest (Fig. 4) revealed marked progression of bilateral pleural thickening with a lobular contour, which involved the posterior, lateral, and mediastinal pleural surfaces; the cardiac silhouette was enlarged; lateral decubitus views showed no free-flowing pleural effusion. An ultrasonographic examination of the liver revealed a normal appearance of the liver and intrahepatic bile ducts; at least one stone was observed within the gallbladder; a right pleural effusion was seen; the kidneys and pancreas appeared normal. A specimen of arterial blood, drawn while the patient was breathing ambient air, showed that the $PaO_2$ was 62 mm Hg, the $PaCO_2$ 35 mm Hg, and the pH 7.46; while he was breathing 100 percent oxygen the $PaO_2$ was 410 mm Hg. Pulmonary-function studies showed that the $FEV_1$ was 1.35 liters, the VC 2.0 liters, and the total lung capacity (TLC) 4.17 liters (predicted, 7.03). The DLCO was 22.2 ml per minute per millimeter of mercury (71 percent of predicted). Both the inspiratory and the expiratory force were 130 mm Hg, a normal value for his lung volume. An echocardiographic examination showed a small to moderate pericardial effusion.

The patient reported increasing pain in both lower extremities, and examination revealed that both dorsalis pedis pulses and the right posterior tibial pulse were absent.

A diagnostic procedure was performed.

## Differential Diagnosis

Dr. W.B. Jerry Younger*: Dr. McLoud, may we begin with a review of the radiologic studies?

*Assistant physician, Massachusetts General Hospital; clinical instructor in medicine, Harvard Medical School.

DR. THERESA C. MCLOUD: A film of the chest obtained 16 months before the first admission (Fig. 1) reveals evidence of either pleural thickening or a small pleural effusion on the right side. An irregular nodule is visible in the right upper lobe. Tomograms obtained a few months later confirmed the presence of pleural thickening on the right side and an irregular spiculated nodule in the right upper lobe. The nodule was subsequently removed. Films taken three months before the first admission (Fig. 2) reveal persistent pleural thickening. There are postoperative changes in the right upper lobe, with the development of a left subpulmonic pleural effusion. In addition, an irregular opacity is seen at the left base, as well as an irregular, spiculated nodule at the right base. A film taken two weeks before the first admission (Fig. 3) shows reaccumulation of pleural fluid on the left side; the right side remained fairly stable. Pulmonary angiograms obtained at that time were reported to show no evidence of emboli.

A film taken on admission to this hospital shows a slight increase in the pleural thickening on the right side. There is a spiculated opacity at the right-lung base, which abuts the pleural surface. This film was taken about two weeks after a thoracentesis, and again there is evidence of reaccumulation of pleural fluid on the left side. On decubitus views the right pleural abnormality did not layer, indicating that it was caused by pleural thickening. There was a free-flowing effusion in the left side. A film obtained after the thoracentesis done during the first admission to this hospital demonstrates that the cardiac size had returned to normal. There is no evidence of pleural fluid, although there may be some residual thickening on the left side, and the previously noted opacity at the left base had resolved. The changes on the right side appeared stable — pleural thickening, postoperative change in the right upper lobe, and a spiculated opacity at the right base. A CT scan obtained later demonstrates reaccumulation of a large pleural effusion on the left side and pleural thickening on the right side. A subpleural irregular nodule at the right-lung base, with associated tethering of the vessels in the vicinity, suggests some loss of volume or atelectasis in the area of the nodule. A film taken after the left thoracotomy on the first admission shows evidence of postoperative pleural thickening on the left side, which extends into the major fissure. The right lung remains unchanged.

The films obtained at the time of the second admission demonstrate a striking change in the right-sided pleural abnormality, which had previously been stable for almost a year (Fig. 4). We see a marked increase in the degree of right pleural thickening, which has a lobulated contour. There may also be an effusion on that side. This lobulated pleural thickening extends along the mediastinal pleural surface. The cardiac silhouette had enlarged markedly. The same process is noted on the left side, with lobulated pleural thickening encasing the left lung and extending along both the lateral and the mediastinal pleural surfaces. The decubitus views do not show free pleural fluid.

In summary, the radiographs initially showed a nodule in the right upper lobe that was removed surgically. Before the initial operation there was evidence of longstanding pleural thickening on the right side. Over the course of the next few months recurrent pleural effusions developed on the left side. These developments led to a left-sided thoracotomy. At the time of the second admission 21 months later a striking change had occurred in the pleura on both sides, with evidence of lobulated, mass-like pleural thickening encasing both lungs.

DR. YOUNGER: This middle-aged man had a history of both pleural and restrictive lung disease of at least three years' duration. He initially presented with a fibrotic lung nodule and right pleural thickening but was asymptomatic at that time. When a left pleural effusion developed, a diagnostic thoracentesis revealed an exudate. An extensive evaluation that included a thoracotomy did not reveal a specific cause.

I shall start the discussion with an evaluation of the development of the left pleural effusion. During the first admission to this hospital it was exudative, as indicated by the elevated pleural-fluid protein level and the LDH fluid-to-serum ratio of more than 0.6. The distinction of a transudate from an exudate is helpful in defining the cause of a pleural effusion. Causes of transudates are relatively few, whereas the differential diagnosis of an exudative effusion is much more extensive.[1]

The most common cause of an exudative effusion is inflammation. Bacterial infection is excluded in this patient by the absence of pneumonia, cultures of the fluid that revealed no evidence of bacterial growth, and the absence of a large number of neutrophils in the fluid. Viral and mycoplasma infections would not have caused such a persistent effusion, and the fluid should not have been bloody. The more chronic infections, such as tuberculosis and fungal diseases, were obviously considered, and numerous tests were done to exclude them.

Tuberculous effusions most often occur within six months of the primary infection, concomitant with the development of cell-mediated immunity. Effusions are less common in patients with reactivation tuberculosis. Tuberculous effusions are thought to be a manifestation of delayed hypersensitivity, with a small number of tubercle bacilli able to elicit an acute inflammatory effusion. Recovery of the organisms from the pleural fluid is unusual. The intermediate-strength PPD skin test is positive in approximately two thirds of the patients. The fluid is exudative, with the majority of the cells being lymphocytes. A pleural biopsy shows granulomas in two thirds of the patients, and the performance of three biopsies increases the yield to approximately 80 percent. A diagnosis should be possible in more than 90 percent of the patients if sputum, pleural fluid, and a pleural-biopsy specimen are cultured for acid-fast organisms.

Among the nontuberculous mycobacteria *Mycobacterium kansasii* and *M. avium* predominate; however, effusions develop in only approximately 5 percent of patients with these infections. From a clinical standpoint these patients are similar to patients with tuberculosis, but the symptoms may be less severe and fever is usually absent. Symptoms are more common in older, chronically ill patients, especially those with chronic obstructive pulmonary disease. The PPD skin test is negative, and a distinction from *M. tuberculosis* is made by culture of the organisms. A pleural biopsy shows granulomas.

Fungal diseases account for approximately 1 percent of pleural effusions. The causes include histoplasmosis, coccidioidomycosis, blastomycosis, cryptococcosis, and aspergillosis. The diagnosis is made by the demonstration of the organisms in a pleural-biopsy specimen, by culture, or by serologic testing.

Two other bacteria that may result in effusions are actinomyces and nocardia. Actinomycosis may produce a chronic infection similar to tuberculosis. In one series of cases of actinomycosis 50 percent of the patients had pleural involvement. X-ray films of the chest should reveal a lung lesion with a mass density and surrounding consolidation extending to the chest wall and with a pleural effusion or thickening. Cavitation is a prominent finding. The diagnosis is made by identification of the organisms in the exudate or biopsy specimen, by culture, or by the finding of sulfur granules. Nocardia is not a part of the normal flora and is more likely to be found in immunosuppressed patients. The diagnosis of nocardiosis is made by identification of the organisms on microscopical examination.[2]

Pleural effusions may occur in association with malignant tumors as a result of infiltration of the mediastinal lymph nodes by tumor, because of infection, as a result of pulmonary emboli, or because of spread of tumor cells to the pleura. When the pleural surface is involved by tumor there may be marked shedding of malignant-tumor cells into the fluid. However, if the implants are subserosal few malignant-tumor cells may be found. The major mechanism for pleural-fluid formation appears to be impairment of lymphatic drainage from the pleural space. There is a strong relation to mediastinal-lymph-node involvement by tumor. The fluid is frequently serosanguineous. In fact, it is said that a red-cell count greater than 100,000 per cubic millimeter in the absence of thoracic trauma suggests the diagnosis of a carcinoma or a mesothelioma. The white-cell count is usually less than 4000 per cubic millimeter, and the lymphocytes are greater than 50 percent in half the cases. The cytologic examination is positive in approximately 60 percent of the cases. The fluid may have a low glucose content, a decreased pH of less than 7.3, and an LDH level greater than 500 U per liter, especially if the effusion is chronic.[3]

The immunologic disorders that involve the pleura include rheumatoid disease, systemic lupus erythematosus, sarcoidosis, postcardiac-injury syndrome, Wegener's granulomatosis, and immunoblastic lymphadenopathy. Pleural reactions associated with these diseases are generally accompanied by other findings of the immunologic disorder or by exacerbation of the underlying disease. Involvement of the pleura may antedate arthritis in patients with rheumatoid disease. The arthritis is generally severe, and subcutaneous rheumatoid nodules are found. The rheumatoid factor is usually present in a high titer in the serum. The fluid is said never to be grossly bloody. Systemic lupus erythematosus is much more common in women. LE cells may be found in the pleural fluid. The antinuclear antibody titer is generally greater than 1:160, and the hemolytic complement is reduced. Sarcoidosis should be manifested by noncaseating granulomas in a pleural-biopsy specimen, and x-ray films of the chest usually show bilateral hilar and mediastinal lymphadenopathy in addition to interstitial lung disease.[4]

Pleural effusions occur in 30 to 50 percent of patients with pulmonary embolism. The symptoms are usually those of the underlying disease, with chest pain in approximately 80 percent and dyspnea in 80 percent of the cases. Tachycardia and tachypnea are frequent. The effusions tend to be small unless associated with an infiltrate, and they tend to resolve within a week. Analysis of the fluid is not very useful other than to exclude other causes. The diagnosis is made by lung scans and pulmonary angiograms or by the finding of phlebitis.[5] For the clinicians who were caring for this patient this diagnosis must have been a strong consideration before the first admission to this hospital, since he was initially treated with warfarin.

The extensive evaluation of this patient gives little information to suggest any of the possibilities that I have discussed. There is, however, evidence suggesting the involvement of asbestos in the pleural disease that was recognized during the patient's first admission to this hospital.

Asbestos that is inhaled can cause either pleural reactions or pulmonary fibrosis, or both. The nonmalignant pleural changes can be divided into two types — pleural plaques and pleural inflammation with effusion and thickening. The pulmonary fibrosis is a diffuse pneumoconiosis characterized by diffuse interstitial fibrosis and restrictive lung disease. Pleural plaques occur on the parietal pleura, with the most common sites being the midzones of the costal pleura, the dome of the diaphragm, and the mediastinal pleura. Microscopical examination shows that the plaques consist of dense fibrous tissue with few cells. Asbestos fibers are rarely found in the plaques. Calcification of the plaques can be detected early chemically but is demonstrable radiologically only late in the course of the disease. On radiologic examination the plaques are best seen tangentially or when they are calcified. However, the diagnosis of asbestos pleural disease is made in only about 15 percent of the cases by the radiologist. Computed tomographic scanning improves the ability to see the plaques over routine x-ray

films of the chest. Pleural plaques are rarely seen before 15 years after the first exposure to asbestos, and most of them appear at 30 years or later.

The most common asbestos-related lesion during the first two decades after exposure is pleurisy. It usually results in the development of a moderate effusion, which can be either hemorrhagic or clear. There are no specific findings in the fluid that relate it to asbestos. Asbestos-related pleurisy must be distinguished from pleurisy due to infection, especially tuberculosis. It tends to recur for some months on the ipsilateral or the contralateral side. The symptoms may be mild, and the effusion may be noted on a routine x-ray film of the chest. Asbestos-related pleurisy may disappear without a trace, but more commonly remnants of it persist. Costophrenic-angle blunting is one of the most common sequelae.[6,7]

"Crow's feet" is a term first used by Mackenzie and Harries[8] to describe a finding on plain x-ray films of the chest resulting from asbestos-related pleurisy. It consists of fibrous strands converging to create the likeness of a bird's foot. On CT scanning the fibrous strands are seen to penetrate deeply into the lung. Rounded atelectasis is caused when a peripheral part of the lung has become atelectatic because of pleural adhesions or fibrosis, with bending of the small bronchi.[9] CT scanning is helpful in demonstrating that the lesion is in a pleural location. Most often, these abnormalities must be differentiated from changes due to a malignant tumor.[10] Diffuse pleural thickening is typically uneven and can surround the whole lung, although the lower and dorsal parts of the thorax are more frequently affected. The fissures may be involved, and calcification can occur.

Dr. McLoud, do you believe that the findings on the x-ray films of the chest, specifically the nodules, are consistent with the diagnosis of asbestos-related pleural disease in this patient?

DR. MCLOUD: The nodule that developed over a period of several months at the right-lung base has a radiographic appearance consistent with rounded atelectasis. It was spiculated and located against the pleural surface, and the pulmonary vessels in the area appeared tethered toward the area of atelectasis. Rounded atelectasis occurs when a peripheral portion of the lung is trapped by thickened pleura. The opacity on the right side is also consistent with that diagnosis.

DR. YOUNGER: Asbestos has been used in many products in industrialized societies, including insulation material, cement, flooring products, automobile brake linings, roof shingles, packing plastic, and textiles.[11] The risk of asbestos-related disease was recognized early in primary asbestos workers, but subsequently it has been identified also in bystanders working in asbestos industries, such as secretaries, clerks, and engineers. It has even been described in household members of asbestos workers who had brought the mineral home on their clothing. Finally, it has been reported in persons residing near asbestos mines and mills, usually within a half-mile (0.8 km) radius.[12]

It is difficult to determine a history of asbestos exposure because of the ubiquity of asbestos and the latency from the time of exposure to the development of disease. The amount of exposure required to produce disease is also unclear, although most of the patients have been exposed for long periods and the exposure has generally been heavy.[13]

Malignant tumors associated with asbestos exposure are pleural and peritoneal mesotheliomas,[14,15] bronchogenic carcinomas,[15-21] head and neck cancers,[15,22-25] and gastrointestinal cancers.[14,15,18,25] There have also been anecdotal reports of lymphoproliferative disorders.[26]

Diffuse pleural mesothelioma may present early in its course with discrete nodules of tumor, but as the disease advances the parietal and visceral pleural surfaces become adherent, with a diffuse distribution of tumor. The tumor encases the lung, producing volume loss. There may be invasion of the chest wall and pericardium. The patient usually dies from the local disease and its effect on pulmonary function. Distant metastases as a result of lymphatic or hematogenous spread are usually late manifestations and are overshadowed by the thoracic disease. In asbestos workers the lifetime risk of the development of a mesothelioma is approximately 10 percent, with an average latency period of approximately 35 years.[13,27]

Asbestos workers also have a higher than expected number of bronchogenic carcinomas, with some reports indicating a predilection for adenocarcinoma.[28] Nonsmoking asbestos workers have as high as a 5-fold risk of lung cancer, whereas those who smoke have up to a 90-fold risk of the development of bronchogenic carcinoma.[28] The lifetime risk of bronchogenic carcinoma in smoking asbestos workers is approximately 25 percent, with the risk rising about 10 years after exposure.[13]

The second admission of the patient under discussion to this hospital was prompted by increasing pleural abnormality, restrictive lung disease, and apparent thromboembolic phenomena. The findings during the second admission suggest the development of a mesothelial tumor. In 1982 Chahinian et al.[29] described 69 patients with malignant mesotheliomas. Dyspnea and chest pain were the most common symptoms of a pleural mesothelioma, occurring in 96 percent of the patients. Chest pain, cough, weight loss, and fever occurred in 33 percent, 16 percent, and 9 percent, respectively. A pleural effusion was present at some time during the course of the illness in 95 percent of the patients. As the tumor progressed, however, gradual thickening of the visceral and parietal pleura occurred, with obliteration of the pleural space and a predilection for the basal regions of the thorax. Echocardiographic examination revealed a pericardial effusion in three patients. Asbestos exposure was found in

70 to 80 percent of the patients, with a latency period from the exposure to the diagnosis of a pleural mesothelioma of approximately 35 years, with a range of 20 to 50 years.

From a microscopical viewpoint mesotheliomas may be divided into epithelium-like, sarcomatoid, and mixed histologic types. The differential diagnosis in this case must include pleural metastases from another primary tumor, especially one originating in the lung. The differentiation of adenocarcinoma from the epithelial type of mesothelioma may be difficult. Soft-tissue sarcomas metastatic to the pleura must be distinguished from the sarcomatoid variety of mesothelioma. In this case we have no evidence of metastatic tumor outside the thorax, as might be expected with one of these malignant tumors, and there had been extensive biopsies of lung nodules and the pleura, including those performed during two thoracotomies, which revealed no evidence of such a tumor. It therefore seems unnecessary to invoke the development of an adenocarcinoma or sarcoma metastatic to the pleura in what appears to have been progressive pleural disease over the course of three years, although we do not have biopsy data on the last admission to exclude those diagnoses.

Three days before the second admission the patient began to have pain in his legs, and during this admission increasing pain in both lower extremities developed, with loss of pulses, indicative of arterial thromboembolic disease. Chahinian et al.[29] commented on the frequency of thromboembolic episodes in patients with a mesothelioma; in 4 of 14 patients examined at autopsy thromboembolism was found. Antman and her colleagues[30] observed clotting abnormalities in 22 percent of the 23 patients with peritoneal mesotheliomas whom they studied; 2 had extensive thrombosis and pulmonary emboli, and 1 had a Coombs-positive hemolytic anemia and phlebitis. The association of thrombosis and malignant tumors has been recognized for many years. Trousseau[31] described migratory phlebitis associated with malignant tumors in 1865. Sack and his associates[32] reported a review of 182 patients with disseminated intravascular coagulation and malignant tumors in 1977; arterial emboli occurred in 45 of the patients and were associated with nonbacterial thrombotic endocarditis. The patient under discussion had no evidence of thrombocytopenia in the two platelet counts reported, but we do not have enough information to decide whether he had disseminated intravascular coagulation or other coagulopathies. It is easy to speculate that patients with a mesothelioma are susceptible to thromboembolic disease in view of the frequency of pericardial involvement, reduced blood flow, inactivity produced by a chronic disease, particularly a pulmonary disease, and perhaps a hypercoagulable state.

In summary, I believe that this patient had a malignant pleural mesothelioma as a result of exposure to asbestos. We have some evidence of asbestos exposure and radiologic evidence of asbestos-related pleural disease. Multiple pleural biopsies revealed histologic findings consistent with pleural disease from asbestos exposure, and multiple evaluations excluded other causes. The latency period is not clear since the time of exposure is not certain, but it probably was 25 to 30 years. On the second admission there was evidence of thromboembolic disease with arterial emboli. He could have had tumor embolism, although in my review of the literature I found no reports of that occurrence with a mesothelioma. He might also have had nonbacterial thrombotic endocarditis, but there are no data to support that diagnosis.

DR. L. CHRISTINE OLIVER: This patient presented with the difficult diagnostic problem of pleural thickening and effusion without an apparent cause. In such a situation asbestos-related disease should be considered, and asbestos exposure should be investigated. This patient had a history of work in a steel company until the age of 28 years and possibly 33 years. Steel-manufacturing companies commonly have coke ovens on site insulated with asbestos to convert coal to coke. Maintenance and repair of these ovens are likely to result in "bystander" exposure to asbestos and may well have been a source of exposure in this case. As Dr. Younger has discussed, asbestos-related diseases include pleuritis with effusion and malignant mesothelioma. The former is considered "benign" if there is no evidence of a mesothelioma or other malignant tumor three years after the diagnosis.

In the present case follow-up examination from the time of the initial diagnosis was 33 or 37 months, depending on whether an effusion was present when the patient came to medical attention 16 months before his first admission to this hospital. Dr. Younger, do you think that he had two processes — namely, asbestos-induced pleuritis with effusion and a malignant mesothelioma as a subsequent development? Alternatively, do you think that he had a mesothelioma from the beginning?

DR. YOUNGER: In my opinion this case demonstrates the natural progression of asbestos-related pleurisy with a pleural effusion to diffuse pleural thickening and eventually to a malignant mesothelioma. A benign asbestos-related pleural effusion is common, developing usually within the first 20 to 25 years after exposure. To be classifed as a benign effusion it should remain benign for at least three years.[6,7] The time course in this patient was too short for the effusion to be considered benign according to that definition. Pinpointing the time when the process became malignant in this patient is impossible.

DR. EUGENE J. MARK: Dr. Freeman, may we have the medical students' diagnoses?

DR. MASON W. FREEMAN: The medical students considered a wide variety of infectious and neoplastic diseases, but they similarly concluded that the patient had pulmonary and pleural disease due to as-

bestosis with the subsequent development of a mesothelioma.

### Clinical Diagnoses

Malignant mesothelioma.
Restrictive lung disease secondary to pleural thickening and effusion.
Thromboembolic disease, with peripheral thromboemboli.

### Dr. W.B. Jerry Younger's Diagnoses

Malignant pleural mesothelioma resulting from asbestos exposure.
Thromboembolic disease of lower extremities.

### Pathological Discussion

Dr. Mark: The patient was seen by consultants on the Pulmonary Medicine Service and the Thoracic Surgical Service.

Dr. Douglas C. Johnson: On the third hospital day the patient underwent an angiographic examination of the aorta and lower extremities, which demonstrated a thrombotic lesion in the lower portion of the aorta with multiple emboli to both legs. An embolectomy was performed, and examination of the specimen showed no evidence of tumor.

Dr. Mark: There was a discussion as to whether the patient should have a needle biopsy or an open biopsy of the pleura, but a thoracentesis proved to be the diagnostic procedure when cytologic examination of the fluid showed malignant-tumor cells consistent with either a mesothelioma or a metastatic carcinoma, and a pleural biopsy was believed to be unnecessary.




Figure 5. Transverse Section of the Superior Mediastinum and the Upper Lobe of the Right Lung.
Tumor encases the trachea (t), the esophagus, and the large blood vessels and thickens the pleura (p).



Figure 6. Diffuse Malignant Mesothelioma with Papillary Features (×125).

On the fifth hospital day the patient experienced increased tachypnea and tachycardia. It was thought that an increasing pericardial effusion might be causing pericardial tamponade. Pericardiocentesis was performed, and 75 ml of fluid was withdrawn. This procedure resulted in no change in the tachypnea or tachycardia. The pericardial fluid contained malignant-tumor cells identical to those in the pleural fluid. The patient died on the following day.

At autopsy the lungs were encased in a rind of firm, gray tumor 2 to 10 mm in thickness. The tumor diffusely infiltrated the mediastinum and encased the aorta, the vessels of the arch, the superior vena cava, the pulmonary arteries and veins, the esophagus, and the trachea (Fig. 5). Tumor tissue extended into the lung for a few centimeters along some interlobular septa and formed a few intrapulmonary nodules. Microscopical examination revealed that the tumor in the pleura and mediastinum was papillary (Fig. 6). The cells lining the papillae were epithelioid, with relatively small, regular nuclei and a moderate amount of cytoplasm. The tumor that invaded the mediastinum and the soft tissue of the chest wall formed small solid nests and gland-like structures (Fig. 7). These findings are characteristic of a diffuse malignant mesothelioma of the pleura. There was invasion of blood vessels and lymphatics in the lungs and mediastinum. Deposits of papillary tumor were found in the parietal and visceral

pericardium, in the soft tissue of the thoracic outlet, and in the serosa of the terminal ileum and cecum. In a few foci in the subpleural portions of the lungs the tumor spread in a papillary pattern along alveolar septa.

Pleural hyaline plaques were present. They were composed of poorly cellular hyaline tissue in a basket-weave configuration. Beneath some of the plaques was compressed atelectatic lung tissue, which had produced a scar. An unusual finding was the extension of strands of the poorly cellular collagen from two of the plaques into the subjacent lung to produce nodules (Fig. 8). Two such nodules were present at autopsy, and two had been present in the open-lung-biopsy specimen. These subpleural nodules correspond to the nodules demonstrated radiographically. Some of the

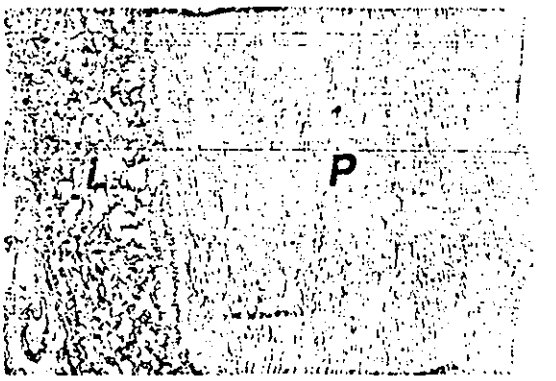


Figure 8. Pleural Hyaline Plaque (P) (Elastic-Tissue Stain, ×52). The lung (L) beneath the plaque is atelectatic.



Figure 7. Solid Nest of Tumor Invading the Intercostal Muscle (×200).

plaques were calcified; others were infiltrated by the malignant mesothelioma.

Histologic examination did not reveal either diffuse interstitial fibrosis or asbestos bodies, so that both criteria for the diagnosis of asbestosis were absent. We digested a portion of lung free of tumor according to the method of Smith and Naylor[33] to analyze the lung for asbestos fibers or asbestos bodies. With this technique we found occasional long, slender, uncoated asbestos fibers and partially coated asbestos bodies (Fig. 9). This morphologic proof of inhalation of asbestos correlates with the circumstantial evidence of exposure of this patient. Several studies have shown that environmental exposure to asbestos in the vicinity of asbestos plants, without direct occupational exposure to asbestos at the workplace, is sufficient to cause a diffuse malignant mesothelioma of the pleura.[34-36]

Review of the pleural-biopsy specimens obtained 37 and 21 months previously, when the patient had pleural effusions, disclosed hyaline plaques involving the pleura and extending into the lung. Mesothelial cells were hyperplastic but not malignant. Thus, the patient had a benign effusion lasting from at least 21 to 37 months before death and, according to clinical indexes, up to 2 months before death. For the last two months of his life the course of the disease suggests the development of the malignant mesothelioma. It has been said that so-called benign pleural effusions associated with exposure to asbestos do not predispose to a diffuse malignant mesothelioma,[7,37] but there is evidence that recurrent effusions that are initially cytologically benign may become malignant.[38-40] I have seen three examples of this sequence in addition to this case. I consider recurrent pleural effusions in patients exposed to asbestos premalignant rather than benign. The presence of atypical mesothelial cells in the cytologic examination of a pleural effusion indicates that the patient should be followed closely for the possible development of a malignant pleural tumor.[41]

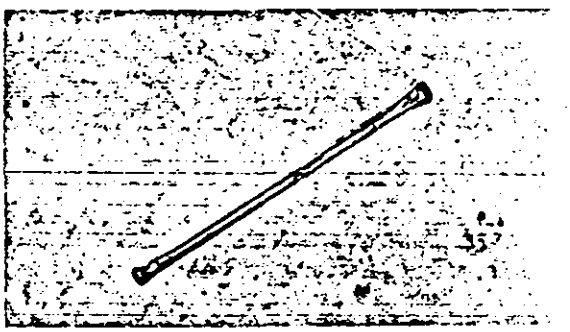

Figure 9. Partially Coated Asbestos Fiber from Lung Tissue after Digestion, Extraction, and Centrifugation (×788).

DR. YOUNGER: Was there evidence of thromboemboli in the lower extremities or of nonbacterial thrombotic endocarditis?

DR. MARK: There was no endocarditis or other source of thromboemboli. There were no tumor emboli in arteries. The occlusion of the arteries presumably was thrombotic.

## ANATOMICAL DIAGNOSES

*Malignant mesothelioma of pleura, diffuse, with spread to lungs, mediastinum, pericardium, and peritoneum.*
Pleural hyaline plaques.
Asbestos exposure.

## REFERENCES


1. Jay SJ. Diagnostic procedures for pleural disease. Clin Chest Med 1985; 6:33-48.
2. George RB, Penn RL, Kinasewitz GT. Mycobacterial, fungal, actinomycotic, and nocardial infections of the pleura. Clin Chest Med 1985; 6:63-75.
3. Sahn SA. Malignant pleural effusions. Clin Chest Med 1985; 6:113-25.
4. *Idem.* Immunologic diseases of the pleura. Clin Chest Med 1985; 6: 83-102.
5. Brown SE, Light RW. Pleural effusion associated with pulmonary embolization. Clin Chest Med 1985; 6:77-81.
6. Hillerdal G. Nonmalignant pleural disease related to asbestos exposure. Clin Chest Med 1985; 6:141-52.
7. Epler GR, McLoud TC, Gaensler EA. Prevalence and incidence of benign asbestos pleural effusion in a working population. JAMA 1982; 247:617-22.
8. Mackenzie FA, Harries PG. Changing attitudes to the diagnosis of asbestos disease. J R Nav Med Serv 1970; 56:116-23.
9. Mintzer RA, Cugell DW. The association of asbestos-induced pleural disease and rounded atelectasis. Chest 1982; 81:457-60.
10. Tylén U, Nilsson U. Computed tomography in pulmonary pseudotumors and their relation to asbestos exposure. J Comput Assist Tomogr 1982; 6:229-37.
11. Craighead JE, Mossman BT. The pathogenesis of asbestos-associated diseases. N Engl J Med 1982; 306:1446-55.
12. Newhouse ML, Thompson H. Mesothelioma of the pleura and peritoneum following exposure to asbestos in the London area. Br J Ind Med 1965; 22:261-9.
13. Antman KH, Corson JM. Benign and malignant pleural mesothelioma. Clin Chest Med 1985; 6:127-40.
14. Wagner JC, Sleggs CA, Marchand P. Diffuse pleural mesothelioma and asbestos exposure in the North Western Cape Province. Br J Ind Med 1960; 17:260-71.
15. Newhouse M. Epidemiology of asbestos-related tumors. Semin Oncol 1981; 8:250-7.
16. Doll R. Mortality from lung cancer in asbestos workers. Br J Ind Med 1955; 12:81-6.
17. Knox JF, Holmes S, Doll R, Hill ID. Mortality from lung cancer and other causes among workers in an asbestos textile factory. Br J Ind Med 1968; 25:293-303.
18. Peto J, Doll R, Howard SV, Kinlen LJ, Lewinsohn HC. A mortality study among workers in an English asbestos factory. Br J Ind Med 1977; 34:169-73.
19. Selikoff IJ, Hammond EC, Seidman H. Cancer risk of insulation workers in the United States: biological effects of asbestos. IARC Sci Publ 1973; 8: 209-16.
20. McDonald JC, Becklake MR, Gibbs GW, McDonald AD, Rossiter CE. The health of chrysotile asbestos mine and mill workers of Quebec. Arch Environ Health 1974; 28:61-8.
21. Newhouse ML. A study of the mortality of workers in an asbestos factory. Br J Ind Med 1969; 26:294-301.
22. Stell PM, McGill T. Asbestos and laryngeal carcinoma. Lancet 1973; 2: 416-7.
23. Shettigara PT, Morgan RW. Asbestos, smoking, and laryngeal carcinoma. Arch Environ Health 1975; 30:517-9.
24. Newhouse ML, Berry G. Patterns of mortality in asbestos factory workers in London. Ann NY Acad Sci 1979; 330:53-60.
25. Selikoff IJ. Asbestos disease in the United States: 1918–1975. Rev Fr Mal Respir 1976; 4:Suppl 2:7-24.
26. Kagan E, Jacobson RJ, Yeung K-Y, Haidak DJ, Norchnani GH. Asbestos-associated neoplasms of B cell lineage. Am J Med 1979; 67:325-30.
27. Antman KH. Clinical presentation and natural history of benign and malignant mesothelioma. Semin Oncol 1981; 8:313-20.
28. Selikoff IJ. Cancer risk of asbestos exposure: origins of human cancer. New York: Cold Spring Harbor Laboratory, 1977:1765-84.
29. Chahinian AP, Pajak TF, Holland JF, Norton L, Ambinder RM, Mandel EM. Diffuse malignant mesothelioma: prospective evaluation of 69 patients. Ann Intern Med 1982; 96:746-55.
30. Antman KH, Pomfret EA, Aisner J, MacIntyre J, Osteen RT, Greenberger JS. Peritoneal mesothelioma: natural history and response to chemotherapy. J Clin Oncol 1983; 1:386-91.
31. Trousseau A. Phlegmasia alba dolens: clinique médicale de l'Hôtel-Dieu de Paris. Vol. 3. London: The New Sydenham Society, 1865:94.
32. Sack GH Jr, Levin J, Bell WR. Trousseau's syndrome and other manifestations of chronic disseminated coagulopathy in patients with neoplasms: clinical, pathophysiologic, and therapeutic features. Medicine (Baltimore) 1977; 56:1-37.
33. Smith MJ, Naylor B. A method for extracting ferruginous bodies from sputum and pulmonary tissue. Am J Clin Pathol 1972; 58:250-4.
34. Hasan FM, Nash G, Kazemi H. The significance of asbestos exposure in the diagnosis of mesothelioma: a 28-year experience from a major urban hospital. Am Rev Respir Dis 1977; 115:761-8.
35. Chen W-J, Mottet NK. Malignant mesothelioma with minimal asbestos exposure. Hum Pathol 1978; 9:253-8.
36. Fischbein A, Rohl AN. Pleural mesothelioma and neighborhood asbestos exposure: findings from microchemical analysis of lung tissue. JAMA 1984; 252:86-7.
37. Hillerdale G. Non-malignant asbestos pleural disease. Thorax 1981; 36: 669-75.
38. Klima M, Gyorkey F. Benign pleural lesions and malignant mesothelioma. Virchows Arch [Pathol Anat] 1977; 376:181-93.
39. Ryan CJ, Rodgers RF, Unni KK, Hepper NGG. The outcome of patients with pleural effusion of indeterminate cause at thoracotomy. Mayo Clin Proc 1981; 56:145-9.
40. Hillerdal G, Baris Y. Radiological study of pleural changes in relation to mesothelioma in Turkey. Thorax 1983; 38:443-8.
41. Sheldon CD, Herbert A, Gallagher PJ. Reactive mesothelial proliferation: a necropsy study. Thorax 1981; 36:901-5.



## 35-MILLIMETER LANTERN SLIDES FOR THE CASE RECORDS

Any reader of the *Journal* who uses the Case Records of the Massachusetts General Hospital as a medical teaching exercise or reference material is eligible to receive 35-mm slides, with identifying legends, of the pertinent x-ray films, electrocardiograms, gross specimens, and photomicrographs of each case. The slides are 2 in. by 2 in., for use with a standard 35-mm projector. These slides, which illustrate the current cases in the *Journal*, are mailed weekly from the Department of Pathology and may be retained by the subscriber. Each year approximately 400 slides are sent to each subscriber. The cost of the subscription remains $350 per year. Application forms for the next subscription year, which begins on March 1, 1987, may be obtained from Mrs. Betty U. McNeely, Department of Pathology, Massachusetts General Hospital, Boston, Massachusetts 02114 (telephone [617] 726-8897).