PLAINTIFF'S EXHIBIT
03970.00

CLAIMED
PRIVILEGED
BY OCF

A. M. A.
Archives of Industrial Hygiene and Occupational Medicine

VOLUME 3 JANUARY 1951 NUMBER 1

COPYRIGHT, 1951, BY THE AMERICAN MEDICAL ASSOCIATION

EXPERIMENTAL STUDIES OF ASBESTOSIS

ARTHUR J. VORWALD, Ph.D.(Path.), M.D.
THOMAS M. DURKAN
AND
PHILIP C. PRATT, M.D.
SARANAC LAKE, N. Y.

15-

ASBESTOSIS is a form of pneumonoconiosis resulting from prolonged inhalation of asbestos dust. The name "asbestos," literally "unburnable," is not that of a specific mineral but is a term applied to a number of different minerals whose characteristic feature is a structure composed of long, parallel, flexible fibers. This structure is unique because the fibers are capable of repeated longitudinal subdivision to units of molecular proportions. In length the fibers vary from a few microns to 6 or more inches (15 or more cm.). Some varieties are stiffer than others, but many are sufficiently flexible to be spun into yarn and woven on modified textile machinery.

The asbestos minerals are silicates of variable composition and belong to the serpentine and the amphibole groups. Listed below are the more common varieties.

Amphibole group: actinolite, amosite, amphibole, anthophyllite, crocidolite and tremolite.

Serpentine group: chrysotile.

The bulk of the asbestos of commerce is chrysotile, $3MgO.2SiO_2.2H_2O$, which is mined on this continent principally in the Thetford region of the Province of Quebec, Canada, and in Vermont. Crocidolite and amosite also are used commercially but in much smaller amounts. Chrysotile occurs as veins in serpentine, a mineral of similar chemical composition, which exists in massive form and is made up of microscopic fibers without the parallel orientation characteristic of chrysotile. The massive, bluish black serpentine, which is smooth and soapy to the touch, is traversed by veins of fibrous chrysotile varying in width from a barely perceptible line to 6 (15 cm.) or more inches. The fibers run across the vein and not lengthwise with the formation.

From the Saranac Laboratory of the Edward L. Trudeau Foundation.

This series of studies of asbestosis, initiated at the Saranac Laboratory more than twenty years ago by the late Dr. Leroy U. Gardner, director of the laboratory, was nearly completed at the time of his death in October 1946. Although partial reports and informal reviews of some of the experiments had been given from time to time by Dr. Gardner, this paper presents for the first time a complete survey of the entire experimental investigation.

Produced under Court Order in Hart v. Owens Corning Fiberglas, et al., USDC SD Miss: Confidential information, not to be copied, reproduced or distributed except in accordance with this Court's order.

Bristol 1
5/30/79

PLAINTIFF'S EXHIBIT
WV-000839

08 006 1060

Attention is directed to the mineral brucite, $Mg(OH)_2$, which is often found in the same formations with serpentine and chrysotile and may be fibrous in structure. Except for the manufacture of magnesium, brucite has no commercial value at present because its fibers are not sufficiently flexible to be used in textiles, but they are capable of repeated longitudinal subdivision. Unlike other asbestiform minerals, brucite is not a silicate, and for this reason it has been a valuable tool in an experimental evaluation of the action of fibrous minerals on lung tissue.

CLAIMED
PRIVILEGED
BY OCF

Produced under Court Order in Hart v. Owens Corning Fiberglas, et al., USDC SD Miss. Confidential information, not to be copied, reproduced or distributed except in accordance with this Court's order.

EXPERIMENTAL ASBESTOSIS

For many years studies[1] have been carried on at the Saranac Laboratory in an investigation of the cause, nature and development of asbestosis. The present paper is devoted to experimental asbestosis,



Fig. 1.—Human asbestosis (P-36-144). The photomicrograph reveals a bronchiole (right center) with a smooth muscle bundle at its inferior margin and with an extensive zone of collagen deposition largely obliterating the surrounding alveolar structure. The black foci are macrophages containing incidental pigment. Asbestosis bodies are present but are not apparent at this magnification (× 200).

and in it are described the experiments made on animals with various kinds of asbestos dust. Another report, to be prepared and issued at a future date, will be concerned with human asbestosis and will cover the health aspects of workers who have been exposed to asbestos dust in an industrial environment.

Although in man asbestosis is a chronic disease with diffuse pulmonary fibrosis which requires years to develop, it is possible to reproduce

1. (*a*) Gardner, L. U., and Cummings, D. E.: Studies on Experimental Pneumokoniosis: VI. Inhalation of Asbestos Dust; Its Effect upon Primary Tuberculous Infection, J. Indust. Hyg. 13:65 and 97, 1931. (*b*) Gardner, L. U.: Chrysotile Asbestos as an Indicator of Subtile Differences in Animal Tissues, Am. Rev. Tuberc. 45:762, 1942.

08 006 1061

in one or more species of animal characteristic tissue changes which are similar to the lesions of human asbestosis (fig. 1). Since the life span of the experimental animal is relatively short, it is not possible to produce the characteristic lesions in animals under conditions identical with the usual industrial environment. Consequently, to obtain a complete evaluation of the tissue response to inhaled particulate and fibrous material, it is necessary to accelerate the reaction by employing higher concentrations of dust than would ordinarily be encountered in industry. While conditions of exposure are thus different, the information yielded by animal experiments is invaluable in furnishing a better understanding of the reaction of the human organism to inhaled asbestos dust.

CLAIMED
PRIVILEGED
BY OCF

Experimental Methods

For investigating the tissue reactions of experimental animals to the various asbestos minerals, two types of technic have been employed, namely, the inhalation method and the injection method. In inhalation experiments, groups of animals—up to 100 or more guinea pigs and sometimes smaller numbers of rabbits, cats, dogs, rats or mice—are kept for eight hours a day in a cubical dust room, 8 ft. (2.5 M.) in dimension, in which a cloud of asbestos dust is maintained by a rotating paddle in a dust hopper.[1a] At intervals during the experiment a few animals are killed and the tissues examined to determine the nature and the extent of the dust reaction. Some animals are exposed for periods up to three years. The injection experiments are used to determine in as short a time as possible whether or not a particular dust has a potential capacity to produce inflammatory reaction when in direct contact with tissues of the body. The method involves injecting the dust, either dry or suspended in fluid, into the animal by the intravenous, the intraperitoneal, the intratracheal or another route.

Long term inhalation experiments furnish information on which great reliance is placed when estimating the degree to which a dust might constitute a respiratory hazard to industrial workers. Even though an atmospheric dust may be potentially dangerous, as indicated by injection experiments, only inhalation procedures will reveal whether the dust can be inhaled, pass the natural defense barriers of the body and reach the pulmonary tissue in quantities sufficient to cause damage. Injection methods are useful, however, because they make certain that contact occurs between the dust particles and tissues and because they allow accurate estimation of the dosage and of the potential capacity of that dose to produce reaction. The intratracheal method is particularly valuable when one is dealing with fibrous minerals like asbestos, since it permits observation of the effect of the fibers on pulmonary tissue.

Tissue Susceptibility

Unlike free silica, asbestos does not produce specific effects in all organs of all species of animals. The comparative data presented in table 1 are based on completed observations and therefore differ slightly from a preliminary report.[1b] Fine quartz introduced into various organs

Produced under Court Order in Hart v. Owens Corning Fiberglas, et al., USDC SD Miss: Confidential information, not to be copied, reproduced or distributed except in accordance with this Court's order.

08 006 1062

of contact with the tissue. In cats, rabbits and mice a few of the fibers show an atypical coating after much longer residence in the lungs. In rats the bodies are rarely seen, and in dogs none could be found. Although the evidence is incomplete, it appears that the formation of the asbestosis body prevents the fiber from damaging the tissue. Many of the points mentioned above will be elaborated on in subsequent paragraphs dealing with the actual experiments. For presentation our investigation is divided into two sections, one dealing with inhalation experiments and the other with injection experiments.

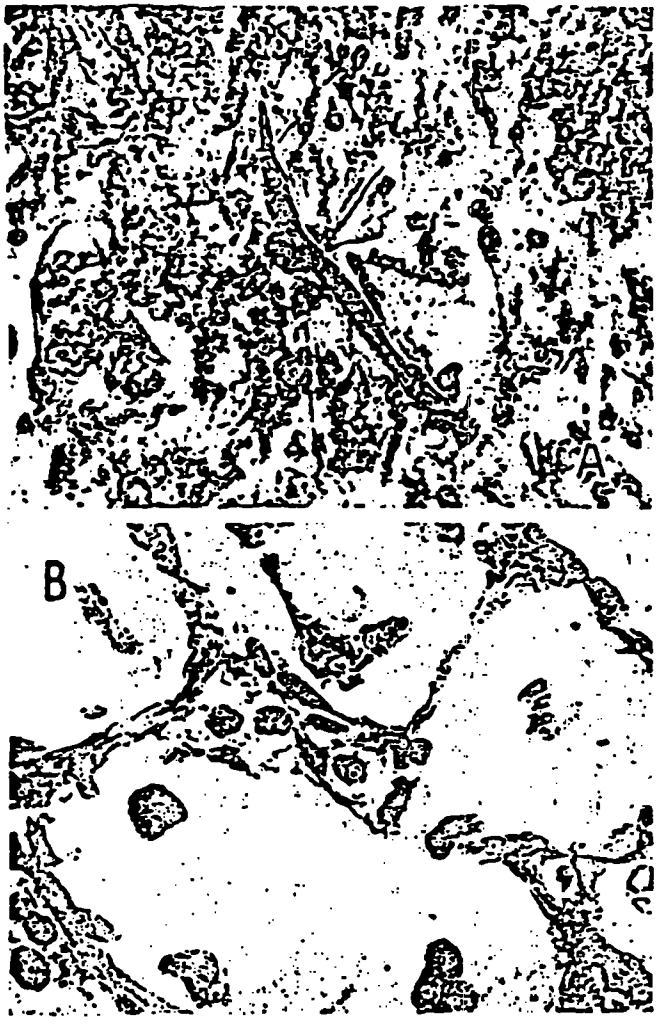

Fig. 2.—*A*, human asbestosis bodies. This collection of asbestosis bodies was found in the lung shown in figure 1. The usual variations of size and configuration are represented (× 400).

B, guinea pig asbestosis body. This one is similar to some of those shown in *A* (× 400).

CLAIMED
PRIVILEGED
BY OCF

Produced under Court Order in Mast v. Owens
Corning Fiberglas, et al., OSDC SD Miss.
Confidential Information, not to be copied,
reproduced or distributed except in accordance
with this Court's order.

08 006 1063

CLAIMED
PRIVILEGED
BY OCF

INHALATION EXPERIMENTS

Four large scale inhalation experiments have been conducted in this laboratory with various forms of asbestos dust. In each of these investigations, more than 160 animals were used, and the experiments were carried on for periods ranging from two to more than five years. The four kinds of asbestos dust employed are designated as King's floats, short fiber, 100 per cent ball-milled, and long fiber asbestos dust.

King's Floats Asbestos Dust

The first inhalation experiment conducted at the Saranac Laboratory with asbestos dust was begun in 1928. Animals inhaled the dust for

TABLE 2.—*Chemical Analysis of Asbestos Dusting Materials*

Type of Asbestos	SiO_2	Fe_2O_3	Al_2O_3	Cr_2O_3	MnO	CaO	MgO	Na_2O	K_2O	CO_2	Ignition Loss	Total
King's floats.....	39.22	8.84		*	*	0.67	35.56	*	*	*	12.74	97.13
Short fiber.....	37.17	9.09	1.40	0.14	0.09	0.85	35.96	0.14	0.29	0.98	14.09	100.11
Long fiber.....	38.40	5.32	0.18	*	0.08	0.31	40.18	0.06	0.06	0.57	14.00	99.76

* Not determined.

TABLE 3.—*Petrographic Analysis of Asbestos Dusting Materials*

King's floats *: The approximate composition, based on particles (except chrysotile) smaller than 10 microns and reported as percentages obtained from particle counts, was chrysotile 14, serpentine 40, magnetite 12, carbonates 19, talc 12, other minerals 4. For chrysotile, fibers up to 200 microns long were included.

Short fiber †: The material, before being ball milled, contained a preponderance of fibrous chrysotile and platy (nonfibrous) serpentine. The approximate composition, by percentage, was chrysotile 17, serpentine 55, magnetite 10, quartz 2, brucite 5, other minerals, including dolomite, actinolite and tremolite, 11.

Long fiber †: The material consisted principally of the fibrous asbestos mineral chrysotile. Shreds of nonseparated fibers 5 to 15 microns in diameter and up to 50 microns in length were present. The approximate composition, by percentage, was chrysotile 75, serpentine 15, magnetite 5, brucite 2, other minerals, among which were calcite and chloritic and micaceous minerals, 3. Only a trace of quartz was observed.

* The analysis of the King's floats asbestos, made by Dr. C. S. Hurlbut Jr., of Harvard University, has been reported elsewhere (Hurlbut, C. S., Jr., and Williams, C. R.: The Mineralogy of Asbestos Dust, J. Indust. Hyg. & Toxicol. 17: 292, 1935).

† For the short fiber asbestos and the long fiber asbestos the petrographic analysis was supplemented with x-ray diffraction examination.

periods up to 33 months. Some guinea pigs with six and nine months' exposure lived for an additional three years after cessation of their exposure. A preliminary report[1a] presented observations after 29 months of exposure. At that time observations covered a period of only 2¼ years and the conclusions as to the ultimate effects of inhaled asbestos dust were provisional. Those conclusions are substantiated by results of the completed study, which is reported as follows.

Composition and Atmospheric Concentration of the Dust.—The dusting material, a commercial variety of asbestos known as King's floats, was composed of short fibers, ranging in length from 1 mm. to 1 micron or less, and of particles which also varied in size. It was obtained from the Thetford, Quebec, plant of the Asbestos Corporation of America, and analyses (tables 2 and 3) reveal that the amount of fibrous chrysotile was only 14 per cent, a rather low value.

Produced under Court Order in Hart v. Owens Corning Fiberglas, et al., USDC SD Miss: Confidential information, not to be copied, reproduced or distributed except in accordance with this Court's order.

08 006 1064

Impinger samples taken soon after the experiment was started indicated that the dust concentration was at first quite low, the average dust count being only 6.0 million particles per cubic foot of air by the standard light field technic and 0.8 million for particles and fibers greater than 10 microns. After the inhalation experiment had been under way for about two years, the speed of the rotating paddle in the dusting machine was increased and for the remaining 10 months of the experiment considerably more dust was dispersed into the atmosphere. The average dust count of impinger samples collected after this change was 53.7 million by the usual light field method and 1.6 million for particles and fibers larger than 10 microns. It is probable, however, that the true values of the dust concentration were higher than the counts given in this paragraph. The impinger samples for the King's floats experiment were collected in water, but later studies[7] have shown that counts of impinger samples of asbestos dust taken in water are not reliable. Ethyl alcohol instead of water was used as the collecting fluid in all subsequent experiments.

CLAIMED PRIVILEGED BY OCF

Produced under court Order in Hart v. Owens Corning Fiberglas, et al., USDC SD Miss: Confidential information, not to be copied, reproduced or distributed except in accordance with this Court's order.

TABLE 4.—*Summary of Inhalation Experiment with King's Floats Asbestos Dust*

Nature of Experiment	Animals	Maximum Dust Exposure, Mo.	Maximum Survival After Dust Exposure, Mo.	Results
Dust exposure continuous throughout life	84 guinea pigs	33	0	Typical peribronchiolar fibrosis after 11 months
	9 rabbits	19	0	Foreign body bronchitis
	18 rats	6	0	Little or no reaction
Dust exposure followed by prolonged residence in normal air	25 guinea pigs	0	25	Nonprogressive fibrosis
	25 guinea pigs	9	27	Nonprogressive fibrosis
	1 rabbit	6	20	Absorption of foreign body reaction
	1 rabbit	19	24	
Tuberculous infection * at start of dust exposure	40 guinea pigs	25	0	Temporary progression of infection, followed by healing with fibrosis
Controls to infection: no dust exposure	23 guinea pigs	0	25 †	Healing by resolution (one exception)
Tuberculous infection * after 25 mo. of dust exposure, then residence in normal air	12 guinea pigs	25	14	No appreciable increase in susceptibility to tuberculous infection; healing with fibrosis
Controls to infection: no dust exposure	12 guinea pigs	0	19 †	Healing by resolution

* The guinea pigs were infected with low virulence Rs strain of tubercle bacillus.
† This means the survival period following infection.

Results of the investigation, briefly summarized in table 4, show that inhalation of King's floats asbestos dust produced a typical peribronchiolar fibrosis in guinea pigs but not in rabbits or rats.

Reaction in Normal Guinea Pigs.—Guinea pigs inhaling this dust for periods up to 33 months had a characteristic fibrosis occurring in conical patches about the respiratory bronchioles. During this exposure the peripheral alveoli were not involved. The particulate elements of the dust were transported through the lymphatic system to the bronchial nodes, causing no significant reaction in either site; the fibrous elements remained fixed at the points of original localization and were seldom detected in the lymph nodes.

After exposure of approximately a year a small amount of cellular reaction had been produced about many respiratory bronchioles (fig. 3*A*). As more dust was inhaled, it continued to accumulate in the same location, and later stages of the disease (fig. 3*B*) consisted of extensions of the original lesions.

Apparently, the inhaled fibers were caught in the pocket-like alveoli that are given off from the lateral walls of the respiratory bronchioles. There they

7. Fulton, W. B.; Houtz, R. L.; Dooley, A., and Mathews, J. L.: Asbestosis: I. The Collection and Counting of Asbestos Dust Encountered in Asbestos Fabricating Plants, Special Bulletin 37, Pennsylvania Department of Labor and Industry, Harrisburg, 1934.

08 006 1065

were phagocytosed, and many of them were carried into the wall by migratory cells. Mononuclear leukocytes attracted to the area caused an appreciable thickening of the bronchiolar wall. After 16 months a delicate fibrosis made its appearance. The process evolved gradually, and the number of fine intercellular collagenous fibers steadily increased. As this fibrous deposit contracted, it partially closed and



Fig. 3.—King's floats inhalation experiment: *A*, lung of a guinea pig with 12 months' exposure. It includes a respiratory bronchiole, at the left, branching and becoming an alveolar duct, at the right. Note the accumulation of cells in the wall of the bronchiole and in adjacent alveoli (× 130). *B*, lung of a guinea pig with 28 months' exposure. The field includes a bronchiole, at the center, with peribronchial fibrosis extending into the walls of adjacent alveoli. Note the cuboidal epithelium lining these alveoli. This is the so-called "adenomatoid" appearance (× 200).

distorted the alveoli, and with this change the alveoli became lined with cuboidal cells. The result was an adenoma-like appearance which frequently accompanies

CLAIMED
PRIVILEGED
BY OCF

Produced under Court Order in Hart v. Owens Corning Fiberglas, et al., USDC SD Miss: Confidential information, not to be copied, reproduced or distributed except in accordance with this Court's order.

08 006 1066

chronic pulmonary inflammation resulting from many causes. Willis[8] described a similar structure in the lungs of guinea pigs inhaling silicon carbide. The longer asbestos exposures resulted only in more thickening of the walls of the air spaces, largely due to an increase in the amount of fibrosis. The fibrous tissue always remained cellular and failed to show the hyalinization characteristic of silicosis.



CLAIMED
PRIVILEGED
BY OCF

Fig. 4.—King's floats inhalation experiment: *A*, lung of a guinea pig with six months' dust exposure followed by 35 months' inhalation of normal air. The reaction is rather slight, but distinct fibrosis is present (× 200). Note that 28 months of continuous exposure (fig. 3 *B*) produces much more extensive reaction.

B, lung of a guinea pig exposed to the asbestos dust for nine months and living thereafter in normal air for 37 months. The reaction shown is more than that in *A* but much less than the reaction in figure 3 *B* (× 200).

8. Willis, H. S., and Brutsaert, P.: Tumor-like Structures in the Lungs of Guinea Pigs Artificially Exposed to Silica Dust, Am. Rev. Tuberc. 17:268. 1928.

Produced under Court Order in Mark Vs. Owens Corning Fiberglas, et al., USDC SD Texas. Confidential information, not to be copied, reproduced or distributed except in accordance with this court's order.

08 006 1067

Asbestosis bodies (fig. 2*B*), first seen in the lungs of the guinea pigs that had inhaled dust for about two months, became more numerous and more distinctly segmented with increasing exposure.

The reaction produced in guinea pigs exposed for six and nine months did not progress significantly during a subsequent period of 35 and 37 months when the animals lived in a normal atmosphere (fig. 4). Between eight and 11 months after exposure ceased, the cellular reaction in the lung had been completely replaced by thin strands of fibrous tissue. At later periods the scar tissue was less in amount, but in the last animal killed, 37 months after discontinuing dust exposure, some fibrosis was still visible.

CLAIMED PRIVILEGED BY OCF

Reaction in Guinea Pigs Infected with Tubercle Bacilli at the Onset of Dust Inhalation.—Of the group of 40 guinea pigs infected with attenuated tubercle bacilli, R_1 strain,[9] at the time that dust exposure was begun, 31 died or were killed before the completion of two years of the exposure and were reported in the paper by Gardner and Cummings.[10] Seventeen of these died from intercurrent pneumonia. Briefly, the results were as follows: Ten revealed some evidence of spread of the tuberculous process (fig. 5*A*); in 6 of these it was confined to the lungs, and in the other 4 the abdominal viscera also were involved. Extension of the infection was first seen after seven months of dust inhalation; during the next 20 months more than half of the animals showed actively spreading tuberculosis, and in 3 of them small cavities had developed. During the last eight months no animals exhibited any evidence of active infection although in half of them the healed fibrous scars of previous spreads were obvious. The scars were more extensive than is characteristic of either tuberculosis or asbestosis alone.

The nine animals which were still alive after two years of dust exposure were killed at intervals during the following year. In four of them the primary foci of infection were healed with fibrosis and even calcification, and there was no evidence of progression (fig. 5*B*). In the remaining five the tuberculous foci showed evidence of having previously spread locally; in four of them, by the time of autopsy, the foci were healed, with excessive fibrosis; in the fifth animal there was a generalized chronic tuberculous pneumonia in one lobe, and in the other lobes there were isolated primary tubercles, which were still active but had not spread.

Reaction in Guinea Pigs Infected with Tubercle Bacilli After Establishment of Asbestosis.—Twelve guinea pigs, after inhaling King's floats asbestos dust for 26 months, were infected with tubercle bacilli and then removed to normal air. Six of these animals died within seven weeks, five from intercurrent nontuberculous infection. The remaining six animals were killed at intervals up to 14 months after infection. The subpleural tubercles were no more numerous in the dusted animals than in the nondusted controls, but a considerable number were found in the depths of the lung about foci of asbestosis. The tuberculous component of the combined reaction showed only slight local extension about lesions in the lungs and tracheobronchial lymph nodes. Caseation was found in tubercles 1½ months old, but by 5½ months it had completely disappeared, leaving only scar tissue. Foci of fibrosis still persisted in the last animal, which was killed 14 months after infection.

Reaction in Rabbits.—Rabbits exposed to the asbestos dust for periods up to 19 months showed a foreign body type of reaction of low grade, but no fibrosis. Although their lungs contained particulate elements of the dust, fibers were not present, indicating that the upper respiratory mechanism of the rabbit is adequate to exclude fibrous foreign bodies. Two rabbits, after inhaling dust for six and 19

9. Steenken, W., Jr., and Gardner, L. U.: R_1 Strain of Tubercle Bacillus: Its Dissociation and Virulence of Variants in Normal and Silicotic Guinea Pigs, Am. Rev. Tuberc. 54:51, 1946.

Produced under Court Order in Hart v. Owens Corning Fiberglas, et al., USDC SD Miss. Confidential information, not to be copied, reproduced or distributed except in accordance with this Court's order.

08 006 1068

months, lived in normal air for more than two years. At autopsy neither animal showed any evidence of cellular reaction or fibrosis in the terminal bronchioles, nor were there any asbestosis bodies.

Reaction in White Rats.—All the rats had acquired an infection, resulting in the formation of pulmonary abscesses, before they came to autopsy. Apparently, so much heavy mucus obstructed their bronchi that very few fibers could have entered

CLAIMED
PRIVILEGED
BY OCF

Produced under Court Order in Hart v. Owens Corning Fiberglas, et al., USDC SD Miss: Confidential information, not to be copied, reproduced or distributed except in accordance with this Court's order.



Fig. 5.—King's float inhalation experiment: *A*, lung of guinea pig infected with R_1 tubercle bacilli and then exposed to dust for 24 months. A bronchiole is shown just above center. Surrounding it is some collagen deposition, together with typical epithelioid cell infiltration of the wall. Note the lack of encapsulation and the peripheral epithelioid cell pneumonia, which illustrate a spreading tuberculous process (× 200).

B, lung of a guinea pig infected with R_1 tubercle bacilli and then exposed to dust for 35 months. Note the subpleural distinctly encapsulated caseous focus, the calcification at the right border of the lesion and the absence of cells in adjacent alveoli, all of which illustrate a healing tuberculous process (× 200).

08 006 1069

their lungs. In a few of the rats, an occasional asbestosis body was discovered, but there was no fibrosis. This phase of the experiment was considered unsuccessful.

Summary and Interpretation of Inhalation Experiment with King's Floats Dust.—The findings in the experiment with King's floats dust can be summarized under two headings:

1. Effect of the inhaled dust on normal animals. The King's floats dust caused a characteristic peribronchiolar fibrosis in guinea pigs but not in rabbits or rats. The fibrosis did not increase significantly in extent after the dust exposure was discontinued.

2. Effect of the inhaled dust on tuberculosis in guinea pigs. In guinea pigs infected with attenuated tubercle bacilli and then placed in the dust room, the results were more variable than is usual in an experiment of this type. A few animals showed no sign of progression of the infection; in most of them there was evidence of temporary progression with subsequent healing; in one animal the tuberculous process remained active to death. In contrast, when guinea pigs after being infected are exposed to quartz dust instead of asbestos dust, the infectious process continues to progress and eventually causes the death of the animals. On the other hand, infected animals exposed to a harmless dust like iron oxide do not show any progression of the infection.[10] Guinea pigs infected with attenuated tubercle bacilli after the termination of two years' asbestos dust exposure did not show progressive disease. The only modification of the infection was in its localization, a few bacilli being retained in the peribronchiolar fibrous tissue, with tubercles forming there in addition to the usual tubercles beneath the pleura.

In view of the variability of the results, the unusual nature of the response and the high proportion of deaths due to intercurrent pneumonia, it is felt that only tentative conclusions as to the influence of asbestos dust on the course of tuberculous infection are justified by this experiment.

Short Fiber Asbestos Dust

Since hazardous dusts like quartz are most effective in producing fibrosis when the particles are 3 microns and less in size, an inhalation experiment was performed to determine whether this condition is true for asbestos dust. It was thought that a short fiber asbestos dust consisting almost entirely of fibers and particles smaller than 3 microns would initiate an accelerated tissue response and produce an advanced reaction in a shorter time than did the King's floats dust, which contained fibers from 1 mm. to 1 micron and less in length as well as much particulate matter.

Composition and Atmospheric Concentration of the Dust.—The dusting material for this experiment was the remains of fibers collected in dust bins of an asbestos-fabricating plant after a carding operation and screened to pass 200 mesh. Since

10. Vorwald, A. J.; Pratt, P. C.; Durkan, T. M.; Delahant, A. B., and Bailey, D. A.: Siderosis: A Benign Pneumoconiosis Due to the Inhalation of Iron Dust, Indust. Med. & Surg. 19:170, 1950.

CLAIMED PRIVILEGED BY OCF

Produced under Court Order in Re: Asbestos Cases, Los Angeles Superior Court Case No. C 000 746 Coordinated Proceedings, Special Title (Rule 1550(b)) All documents produced or distributed pursuant to this Order are to be used solely in connection with the above-captioned litigation, not to be copied, reproduced or distributed except in accordance with this court's order.

08 006 1070

the material as received contained many long fibers, it was ground in a steel ball mill to reduce practically all the particles to 3 microns or less in size. When used alone in the standard dusting machine, this finely ground asbestos tended to pack in the hopper, and it became necessary to mix one volume of the unground material with three volumes of the ground to generate a satisfactory dust cloud. It is pertinent to mention here that the addition of the small quantity of unground asbestos was unfortunate, because it confused the interpretation of results.

The composition of the short fiber asbestos as received is disclosed by the chemical and petrographic analyses given in tables 2 and 3. Samples taken before and after grinding yielded about the same values on analysis, indicating that there was no contamination from the mill or loss of water content.

The dust concentration varied during the experiment, the light field counts for atmospheric samples collected inside the animal cages with the impinger apparatus ranging from 83 million to 182 million. The average of counts was 130 million for the first year of the experiment, 134 million for the second year and 140 million for the third year.

Size-frequency measurements of air-floated dust from inside the cages at a magnification of 1,300 × revealed a great preponderance of fine particles, nearly

TABLE 5.—*Summary of Inhalation Experiment with Short Fiber Asbestos Dust*

Nature of Experiment	Animals	Maximum Dust Exposure, Mo.	Maximum Survival After Dust Exposure, Mo.	Results
Dust exposure continuous throughout life	46 guinea pigs	34	0	Rate of reaction about the same as in experiment with King's floats asbestos but extent of involvement very much less †
	73 rats	22	0	Characteristic patches of peribronchiolar fibrosis; no asbestosis bodies
	18 cats	34 *	0	Subpleural reaction only
	7 rabbits	47 *	0	No fibrosis seen grossly; microscopic evidence of alveolar wall thickening after 16 months' exposure
Dust exposure followed by prolonged residence in normal air	13 guinea pigs	20	14	Progression after removal from dust doubtful—neither clearly established nor definitely excluded
	2 cats	21	24	Same as for continuous exposure
	1 rabbit	42 *	8	Similar to continuous exposure; evidence of slight regression

* After 32 months the animals were exposed to 100 per cent ball-milled asbestos.
† The reaction was probably due to long fibers in the unground material which was mixed with the ground asbestos dust to produce a satisfactory dust cloud.

90 per cent of the particles seen being smaller than 3 microns. It was estimated that approximately 1 per cent of the dust was in the form of fibers greater than 10 microns in length.

Four species of animals—guinea pigs, white rats, cats and rabbits—were used in this experiment. The results of the dust exposure, summarized in table 5, are presented in greater detail below.

Reaction in Guinea Pigs.—Eighty guinea pigs were originally placed in the dust room, but 21 of them were later eliminated from the experiment and killed because of enlargement of the cervical lymph nodes thought to be due to intercurrent infection of the upper respiratory tract. Of the other 59 animals, 46 remained in the dust room until they were killed or died at periods up to 34 months, and 13 animals were transferred to normal air after being exposed to the dust for 20 months.

The type of tissue reaction provoked by the inhaled short fiber asbestos was essentially the same as that already observed in the experiment with King's floats asbestos. The rate of reaction also was approximately the same, but the extent of involvement was very much less. After 16 to 24 months of exposure only a very few small foci of reaction, which generally required microscopic examination for detection, had been produced in the guinea pigs.

CLAIMED PRIVILEGED BY OCE

Produced under court order in Asbestos Litigation, et al., pending in U.S.D.C. Eastern District of Pennsylvania, MDL No. 875. Confidential information may not be copied, reproduced or distributed except in accordance with this court's order.

08 006 1071

CLAIMED
PRIVILEGED
BY OCF

Only after exposures had continued for approximately one year was there an appreciable tendency for dust-containing phagocytes to gather into clumps. By 16 months phagocytes had collected about the walls of a few of the respiratory bronchioles which revealed a little proliferation or infiltration of mononuclear cells. There were also some multinucleated cells, but they were of the inert, foreign body type. At 20 to 24 months the cellular clumps were sometimes quite prominent, and sometimes changes in the epithelium resulted in the adenoma-like or "adenomatoid" appearance (fig. 3 *B*) previously described in the section reviewing the experiment with the King's floats dust. In most of the subsequent members of the series the reaction remained cellular, but a few exhibited pronounced development of fibrous tissue. In these few members of the series the collagen was pale in color and tenuous, with no appearance of being hyalinized. Diffuse chronic pleurisy was present in a few animals without evidence of pulmonary infection. This suggests that pleurisy may be a specific concomitant of asbestosis, but the evidence is not adequate to establish this point. The reaction of the tracheobronchial lymph nodes was more pronounced than in the previous experiment with King's floats asbestos, probably because more fine particles had been transported to the nodes in animals inhaling short fiber asbestos. The nodal reaction was essentially an increase in reticulum, rather than a fibrosis, with the original cells being preserved between the thickened reticular fibers.

TABLE 6.—*Analyses of Lungs of Guinea Pigs After Prolonged Inhalation of Short Fiber Asbestos Dust*

Exposure to Dust, Mo.	Period in Normal Air, Mo.	Amount of Ash, % of Dried Lung	Total SiO_2, % of Dried Lung	Total SiO_2, % of Ash	Tissue Reaction *
Dust Exposure Continuous During Life					
12	0	5.02	0.51	10.23	
		4.58	0.46	10.08	
		5.16	0.54	10.54	±
15	0	5.00	0.49	9.96	
		4.76	0.43	9.00	
		4.95	0.53	10.60	±
20	0	5.86	0.85	14.48	
		6.43	0.90	14.07	2+
24	0	5.42	0.78	14.48	
		5.50	0.78	14.20	3+
30	0	5.35	0.96	17.59	
		6.55	1.27	19.46	4+
34	0	6.06	0.75	12.37	
		6.35	0.96	15.11	4+
Dust Exposure Followed by Prolonged Residence in Normal Air					
20	4	5.16	0.48	9.30	
		5.11	0.36	7.16	2+
20	10	6.11	0.62	10.21	
		3.96	0.34	8.51	3+
20	14	4.77	0.25	5.31	
		5.18	0.26	5.00	
		4.77	0.22	4.60	2+

* The symbols averaging the tissue reaction in each group of guinea pigs represent merely the relative degree of reaction, ranging from ± (questionable) to 4+ (the maximum for this experiment). The relationships apply only within this table and cannot be compared with symbols in other tables.

In the group removed to normal air after 20 months' inhalation of dust, progression of disease was not definitely demonstrated, but neither could it be absolutely disproved, owing to the variability of the response in different animals. The reactions, from mild to severe, occurred sporadically and bore no relationship to the length of time after cessation of exposure. The differences were attributed to variation in individual susceptibility. This view received support from the chemical analyses (table 6), which revealed comparable amounts of ash and silica in lungs with widely different amounts of tissue change. For example, the ash

Produced under Court Order in Hart v. Owens Corning Fiberglas, et al., USDC SD Miss. Confidential information, not to be copied, reproduced or distributed except in accordance with this Court's order.

08 006 1072

and silica values were quite similar for three animals living in dust 20 months and then in normal air for 14 months, yet the tissue reaction was severe in one animal, mild in another and only doubtful in the third.

The formation of asbestosis bodies was at first extremely limited in both groups. After five months' exposure only a very rare short body could be found, usually inside a cell. Some of the finest intracellular particles were surrounded by yellow deposits having the same color as the asbestosis body. One year's exposure had permitted an accumulation of many longer fibers, a number of which were coated and seen as typical asbestosis bodies. Most of these were still short enough to be partially or entirely within phagocytic cells. By the twentieth month and thereafter they

TABLE 7.—*Analyses of Lungs of White Rats That Had Inhaled Short Fiber Asbestos Dust*

Duration of Exposure, Mo.	Amt. of Ash, % of Dried Lung	Total SiO₂, % of Dried Lung	Total SiO₂, % of Ash	Duration of Exposure, Mo.	Amt. of Ash, % of Dried Lung	Total SiO₂, % of Dried Lung	Total SiO₂, % of Ash
0*	3.9	0.00	0.0	6	3.3	0.07	2.1
	4.2	0.00	0.0		3.4	0.03	1.5
	2.9	0.00	0.0		3.7	0.04	1.1
	3.6	0.00	0.0				
	3.3	0.00	0.0				
	3.9	0.00	0.0				
	3.4	0.00	0.0				
				8	3.9	0.08	2.2
					3.6	0.18	5.5
					3.5	0.15	3.4
					4.4	0.17	4.0
					3.7	0.16	4.2
2	3.5	0.08	2.1				
	3.6	0.13	3.5				
	2.9	0.09	3.3				
	3.2	0.05	1.5				
				10	4.9	0.18	3.8
					4.6	0.15	3.3
4	3.3	0.08	2.3		5.3	0.15	2.8
	3.6	0.11	3.0		4.7	0.13	2.8
	3.4	0.07	2.2				

* Normal controls (no dust exposure).

TABLE 8.—*Average Values of Ash and Total Silica for Lungs of White Rats Inhaling Various Dusts for Various Periods (Lungs Only, Without Included Lymph Nodes)*

Duration of Exposure, Mo.	Amt. of Ash, % of Dried Lung				Total SiO₂, % of Dried Lung				Total SiO₂, % of Ash			
	Short Fiber Asbestos	Quartz	Ferruginous Chert	Gypsum-Quartz Mixture	Short Fiber Asbestos	Quartz	Ferruginous Chert	Gypsum-Quartz Mixture	Short Fiber Asbestos	Quartz	Ferruginous Chert	Gypsum-Quartz Mixture
2	3.3	4.3	8.9	2.9	0.09	0.51	0.25	0.06	2.6	11.7	3.9	2.6
4	3.4	4.5	8.9	3.5	0.09	0.51	0.32	0.07	2.5	11.4	3.6	2.0
6	3.5	7.1	9.9	3.4	0.05	2.94	3.45	0.11	1.6	41.5	34.4	3.4
8	3.8	4.6	9.0	3.6	0.15	1.44	2.40	0.22	3.9	29.4	26.5	9.1
10	4.9	7.8	14.1	4.1	0.18	4.40	6.09	0.25	3.2	56.6	42.2	6.7

were relatively numerous although still rare in comparison with the findings in the King's floats experiment.

Reaction in White Rats.—Seventy-three white rats were exposed to atmospheric short fiber asbestos dust for periods up to 32 months. During the first 10 months animals were killed bimonthly and for the remainder of the experiment at less frequent intervals. Up to eight months the dust cells were widely scattered and existed in foci only sporadically. Reaction was limited to occasional slight thickening of the septums about small accumulations of dust cells. At 10 months there was a suggestion of early fibrosis in a few rats, but the change was so slight that it would probably have been overlooked without the clump of dust cells which attracted attention to the area. Only 10 animals were exposed for from 12 to 32 months. In each of them the lungs contained minute foci of well defined fibrosis distributed like that of asbestosis but without asbestosis bodies. The lesions, visible only at a magnification of 150 diameters or more, consisted of patches along

CLAIMED PRIVILEGED BY OCF

Produced under Court Order In Re: W. Owens (USDC SD Miss: Carmichael Distributing Co., et al., Confidential Information. not to be copied, reproduced or distributed except in accordance with this Court's order.

08 006 1073

CLAIMED PRIVILEGED BY OCF

alveolar ducts in which the walls of the associated air spaces were very thick, owing to swollen collagen framework. Connective tissue and Foot-Bielschowsky silver preparations revealed complete loss of capillary bed locally. Outside the collagen was a thin layer of epithelial cells. This did not resemble the "adenomatoid" change characteristic of guinea pig asbestosis. Near the lesions the air spaces were filled with phagocytes containing gray to yellow particulate dust and a rare, long, naked asbestos fiber. Careful search failed to reveal even a suggestion of an asbestosis body. Pleurisy was absent. The tracheobronchial nodes showed compact focal collections of monocytic cells at 12 months and, at 20 months, some diffuse thickening of the reticulum. In a few rats there was definite fibrosis along the margins of the node, extending into the mediastinal areolar tissue.

Results of chemical analyses made on the white rats are given in table 7, and the average values have been recorded in table 8 for comparison with similar values for rats inhaling other dusts. It will be noted that the values for asbestos are lower than those for quartz or chert but approximate those for the gypsum-quartz mixture, in which atmospheric agglutination tended to reduce the amount of dust inhaled. This condition prevailed even though the atmospheric concentration of asbestos dust was essentially the same as that of the quartz, was one-half that of the gypsum-quartz mixture and was one-fifth that of the ferruginous chert. Since the values for asbestos are low, it might be inferred that the total quantity of that dust actually inhaled was small or that it had been eliminated from or dissolved within the lungs. Evaluation of these possibilities is not feasible on the basis of the observations derived from this study.

Reaction in Cats.—Twenty cats were used in this inhalation experiment with the short fiber asbestos. Eighteen were kept in the dust room continuously until put to death, the exposure period ranging from one month to nearly 54 months. The other two were removed to normal air after a dust exposure of 31 months; one of these was killed five months, and the other 24 months, later. In general, the tissue response was confined to microscopic foci of fibrosis, which were in the walls of groups of subpleural alveoli rather than in the peribronchiolar areas. In one animal the change was extensive enough to be visualized on gross inspection of the section. Only in the animal with the longest exposure—54 months—did the roentgenogram reveal definitely abnormal shadows. A roentgenogram made after 30 months revealed no abnormality; after 45 months, a faint mottling could be detected throughout both lungs. At autopsy, nine months later, there was only microscopic fibrosis in the subpleural zone plus heavy lymphocytic infiltration about small bronchioles. Asbestosis bodies were rare. On prolonged search a few yellow atypical bodies, smooth and without haustrations, were found in two animals exposed for more than a year.

Reaction in Rabbits.—Eight rabbits were exposed to dust for periods extending from one to more than five years; the last animal was removed from the dust room and left in normal air six months before being killed. There was never enough pulmonary fibrosis to be detected grossly, and there was no chronic adhesive pleurisy. Microscopic evidence of alveolar wall thickening was first detected in one animal after about three years of exposure and was seen in all five animals examined thereafter, including the one removed to normal air. One animal that died of paralysis after nearly four years of exposure exhibited a reaction visible on gross inspection of tissue sections. The possibility of pulmonary infection in this animal could not be excluded. In another animal dying two years later the focal fibrosis was not nearly as obvious or as advanced. Areas of involvement, which were largely visualized because of phagocytic reaction within the air spaces, tended microscopically to become more fibrous with the passage of time, but there was never much encroachment on the lumen of air spaces and the structure of the lung was preserved. Asbestosis bodies were not detected in rabbits that died early in the experiment but were seen in all animals that had been exposed to the dust for more than three years.

Produced under Court Order in ASB Misc. 3088
Contains Fibrous Material. Not to be copied, reproduced or distributed except in accordance with this Court's order.

08 006 1074

Summary and Interpretation of Inhalation Experiment with Short Fiber Asbestos Dust.—The original purpose of the experiment was to evaluate the role of short asbestos fibers in the genesis of asbestosis. It was felt also that if the tissues reacted more rapidly and more extensively to short fiber asbestos than to King's floats there would be a basis for believing that the action of asbestos is in part, at least, a chemical one as postulated for quartz. This experiment, in which the tissue reaction was slower and less extensive than that in the previous experiment with King's floats dust, indicates that the capacity of inhaled asbestos fibers to produce fibrosis is determined primarily by factors not chemical in nature.

CLAIMED PRIVILEGED BY OCF

Of the four species exposed in this experiment, only the guinea pig and to a lesser extent the white rat responded with characteristic peribronchiolar fibrosis. The cat reacted with atypical subpleural fibrosis and the rabbit with only slight parenchymal fibrosis.

Ball-Milled Asbestos Dust

In the inhalation experiment with short fiber asbestos dust a small quantity of unground short fiber asbestos was mixed with the ball-milled product in order to generate a suitable dust cloud. When that experiment failed to produce an accelerated tissue reaction, in comparison with the response initiated by King's floats, it became apparent that the biologic activity of asbestos is not increased by a reduction of fiber size. Thus the possibility arose that the tissue reaction observed was due solely to the relatively few long fibers of the unground asbestos and that the short fibers of asbestos had no more than a very insignificant role in the production of asbestosis, a concept not in accord with previous experiments concerning pneumonoconiosis. Consequently another inhalation experiment was started in which only ball-milled asbestos was used.

Composition and Atmospheric Concentration of the Dust.—The dusting material was the ball-milled, short fiber asbestos used in the previous inhalation experiment, but unground material was not mixed with it. Owing to the tendency of the material to form small spherules which prevented much of the fibrous portion from floating out of the dusting machine, the dispersal of the dust was not entirely satisfactory. Therefore, after an initial seven months of operation, steel wire brushes were attached to the inside surface of the hopper and to the rotating paddle to disintegrate the spherules and release the fibers. This arrangement gave satisfactory results and was used for the remaining 21 months of the experiment.

The composition of the raw asbestos used is shown in tables 2 and 3. Petrographic and x-ray diffraction examination of atmospheric dust, collected in the dust room with an electrostatic precipitator after the installation of wire brushes, indicated that about 15 per cent of the air-suspended material was chrysotile, and about 60 per cent, serpentine; of the balance, magnetite comprised 10 per cent, brucite 3 per cent, quartz 2 per cent and other minerals 10 per cent. During the seven month period before the wire brushes were used, the chrysotile content of the atmospheric dust was somewhat lower than 15 per cent, but reliable values were not obtained.

The dust concentration during the first seven months of the experiment was about 100 million particles per cubic foot of air. After the wire brushes were

Produced under Court Order in Hart v. Owens Corning Fiberglas, et al., USDC SD Miss: Confidential information, not to be copied, reproduced or distributed except in accordance with this Court's order.

08 006 1075

installed, the dust counts were higher, and the over-all average for the remaining 21 months was about 150 million.

Size-frequency studies of atmospheric dust collected inside the animal cages revealed that nearly 99 per cent of the components suspended in the air could be classified as clumps or particles; only about 1 to 1.5 per cent was fibers. One third to one half of the fibers were longer than 10 microns, indicating a concentration of long fibers of about 0.8 million. This figure is about one-half the estimated value of 1.4 million for the short fiber experiment.

Guinea pigs, rats and mice were used in the inhalation experiment with the 100 per cent ball-milled asbestos dust. The results are summarized in table 9.

Reaction in Guinea Pigs.—The experiment was started with 100 guinea pigs. As the dust exposure proceeded, there were 39 accidental deaths, 32 of these being due to pneumonia in an epidemic. The 61 pigs remaining exposed to the dust were killed at intervals during exposure, except for 16 guinea pigs transferred to normal air after 28 months of dusting. For the first year of exposure practically the only reaction to the dust was the presence of scattered phagocytes and an occasional minute asbestosis body. At 16 and 20 months no gross response was visible on the tissue section, but microscopically peribronchiolar foci of inflammatory cells

TABLE 9.—*Summary of Inhalation Experiment with 100 per Cent Ball-Milled Asbestos Dust*

Nature of Experiment	Animals	Maximum Dust Exposure, Mo.	Maximum Survival After Dust Exposure, Mo.	Results
Dust exposure continuous throughout life	84 guinea pigs	24	0	No appreciable pulmonary reaction
	40 rats	30	0	No suggestion of asbestosis
	24 mice	12	0	No suggestion of asbestosis
Dust exposure followed by prolonged residence in normal air	16 guinea pigs	28	12	Fibrosis typical of asbestosis was present 12 mo. after exposure ceased in an amount sufficient to be visible grossly; smaller foci could be seen microscopically at 2 mo. and 8 mo. after termination of exposure

could be seen. At 24 months (fig. 6 *A*) there was still no change large enough to be seen with a hand lens, although microscopic examination revealed cellular accumulations about terminal bronchioles and many more asbestosis bodies, chiefly within cells. The lungs of animals exposed for the full dusting period of 28 months and afterward living in normal air for two months revealed the changes described above and also very slight peribronchiolar fibrosis. For exposed animals living eight months in normal air the findings were similar, but at 12 months three of four animals showed grossly visible characteristic peribronchiolar fibrosis with adenomatoid change (fig. 6 *B*).

The tracheobronchial nodes were essentially normal until exposure had been continued for more than a year and a half. Animals killed at 12 months and at 16 months revealed a few minute collections of phagocytes containing particles but practically no fibers large enough to be recognized as such. After 20 months of exposure many monocytes filled with yellow granules were present. At 30 months there had been a slight increase in reticulum but no fibrosis. No further changes occurred in the nodes. Asbestosis bodies were not seen in the nodes of any of the guinea pigs.

Minute asbestosis bodies were observed in the lungs as early as three months after exposure began, but they did not become numerous until 16 months had elapsed. The bodies were short and practically all were intracellular, although at 20 months some were long enough to project beyond the cell borders. It is

CLAIMED PRIVILEGED BY OCE

Produced under Court Order [illegible] Dkt. No. [illegible] Containing Material(s) not to be copied, reproduced or distributed except in accordance with this Court's order.

08 006 1076

important to note that in the later months of exposure there was a distinct increase in the number of long fibers, up to 70 microns in length, in the lungs with the formation of characteristic long asbestosis bodies.

Chemical analyses (table 10) of the lungs revealed that considerable dust had been retained in the lungs. After 24 months of continuous exposure the average

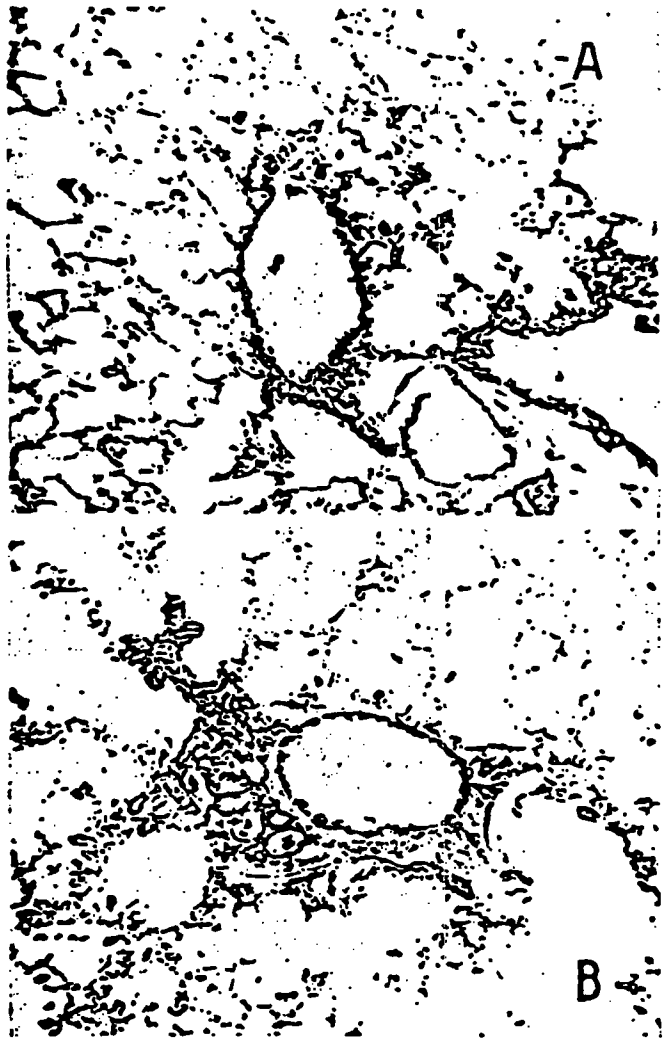

Fig. 6.—Ball-milled asbestos inhalation experiment: *A*, lung of a guinea pig with 24 months' dust exposure. A bronchiole is shown at the center, with a slight accumulation of phagocytic cells but without the formation of collagen (× 200).

B, lung of a guinea pig with 28 months' dust exposure and then 12 months' inhalation of normal air. The reaction is much like that shown in *A*, but there is a slight deposition of collagen, most apparent at the left (× 200).

value for total silica, per cent of ash, was 25.37. This should be contrasted with the average value of 14.34 (table 6) for animals exposed 24 months to the short fiber asbestos dust.

CLAIMED PRIVILEGED BY OCF

Produced under Court Order in Hart v. Owens Corning Fiberglas, et al., USDC SD Miss. Confidential information, not to be copied, reproduced or distributed except in accordance with this court's order.

08 006 1077

In view of the high values for silica obtained with the animals exposed to 100 per cent ball-milled dust, it is important to note that their pulmonary response was much less than that of animals exposed for 24 months to the short fiber asbestos in the previous experiment. This again indicates that the biologic activity of asbestos inhaled into the lung is not increased by a reduction in size of the fibers.

Reaction in White Rats and Mice.—In this experiment 40 rats were exposed for periods up to 20 months and 24 mice for periods up to 12 months. In neither species did even a suggestion of asbestosis develop, and reaction was limited to phagocytosis of inhaled particles by widely scattered dust cells which remained free in air spaces or were transported to the tracheobronchial lymph nodes. No asbestosis bodies were found in the rats, but in the mice there were a very few small, nonhaustrated forms within phagocytes.

TABLE 10.—*Analyses of Lungs of Guinea Pigs Exposed to Dust in Inhalation Experiment with 100 per Cent Ball-Milled Asbestos Dust*

Exposure to Dust, Mo.	Period in Normal Air, Mo.	Amt. of Ash, % of Dried Lung	Total SiO_2, % of Dried Lung	Total SiO_2, % of Ash	Tissue Reaction *
Dust Exposure Continuous During Life					
1	0	4.85	0.21	4.28	
		4.70	0.70	7.05	
		4.33	0.24	5.00	0
2	0	4.05	0.23	6.90	
		4.00	0.24	7.40	
		5.05	0.01	12.01	0
3	0	5.00	0.70	12.47	
		5.07	0.32	6.38	
		5.74	0.36	9.77	0
5	0	5.10	0.38	7.31	
		5.08	0.38	7.47	
		5.02	0.39	7.72	0
8	0	4.38	0.52	11.86	0
12	0	5.05	1.25	22.16	
		6.24	1.43	23.28	0
16	0	5.40	1.02	18.86	
		5.01	1.11	21.96	±
20	0	5.05	1.28	22.00	
		5.20	1.25	24.03	±
24	0	6.30	1.83	29.05	
		5.56	1.21	21.70	±
Dust Exposure Followed by Prolonged Residence in Normal Air					
20	2	7.25	1.57	21.67	
		9.67	2.19	23.24	+
28	8	5.25	0.68	12.90	
		5.90	0.87	14.75	+
28	12	6.38	0.84	13.08	
		5.17	0.64	12.41	2+

* The symbols averaging the tissue reaction in each group represent merely the relative degree of reaction, ranging from 0 to ± (questionable) to 2+ (the maximum observed in this experiment). The relationships apply only within this table and cannot be compared with symbols in other tables.

Summary and Interpretation of Inhalation Experiment with 100 per Cent Ball-Milled Asbestos Dust.—The tissue reaction observed in this experiment was not as intense as that in the previous investigation with short fiber asbestos. The reaction was slower in development and less extensive even though more dust accumulated in the lungs. Since there were fewer fibers longer than 3 microns in the material used in this experiment, the results tend to confirm the interpretation made in the summary of the previous short fiber experiment that the reaction is not primarily chemical in nature, and to support the impression that reduction in size of asbestos fibers does not increase the biologic activity of asbestos inhaled into the lung.

CLAIMED PRIVILEGED BY OCF

Produced under Court Order in Hart v. Owens Corning Fiberglas, et al., USDC SD Miss. Confidential information, not to be copied, reproduced or distributed except in accordance with this Court's order.

08 006 1078

The finding of long asbestosis bodies in animals that had inhaled the ball-milled material is an example of the difficulty of completely eliminating long fibers from a large volume of asbestos as required for an inhalation experiment.

In regard to the progression of the tissue reaction after the animals had been removed from the dust, observed in this experiment but not in the others, the following interpretation is offered: When the reaction is well developed at the termination of exposure, the contraction of the fibrous tissue obscures any progression that may have occurred; in this experiment, however, since the reaction observed was less mature, its subsequent progress was more readily apparent.

CLAIMED PRIVILEGED BY OCF

Long Fiber Asbestos Dust

Since inhalation of short fiber and of 100 per cent ball-milled asbestos dust did not result in acceleration of the tissue reaction in comparison with that produced by King's floats, the hypothesis that short fibers of asbestos were of minor importance in the etiology of asbestosis was given added support, and attention was directed to the view that the long fibers were of primary significance in that etiology. The King's floats asbestos used in the first inhalation experiment had a rather low content of fibrous chrysotile and contained considerable serpentine and other impurities. Therefore, it was decided to conduct a new inhalation experiment with a purer form of chrysotile which would be richer in long fibers.

Composition and Atmospheric Concentration of the Dust.—The dusting material employed in this investigation was obtained from an asbestos fabricating plant. Samples of several varieties of long fiber asbestos dust were first submitted to the Saranac Laboratory for examination, and one of these, which was low in magnetite and chromite and had a fibrous content estimated to be about 75 per cent, was selected as most suitable. Steel wire brushes, fastened to the inside surface of the hopper and to the rotating paddle as in the preceding inhalation experiment, were used to open up the bundles of asbestos and liberate more fibers into the atmosphere.

The composition of the long fiber asbestos used is indicated by the chemical and petrographic analyses given in tables 2 and 3. Analysis of air-suspended material from the dust room disclosed that about 60 per cent of the long fiber dust was chrysotile and about 20 per cent serpentine; as already noted, the composition of a similar air-floated sample of ball-milled, short fiber dust was 15 per cent chrysotile and 60 per cent serpentine.

The dust concentration as revealed by impinger samples taken inside the animal cages was much lower than the concentration for the experiments with short fiber or ball-milled dust. For the first year of the experiment with long fiber asbestos the average of the light field counts was 32 million particles per cubic foot of air; for the second year, 48 million; for the third year, 39 million; and for the fourth year, 43 million.

The size-frequency of atmospheric samples of the long fiber asbestos dust and of the ball-milled dust is shown in table 11. Both samples were collected with the electrostatic precipitator. It will be noted that there was far more fibrous material in the long fiber dust.

Guinea pigs, cats, rats and mice were employed in this inhalation experiment. The results, summarized in table 12, are described in greater detail below.

Produced under Court Order in Hart v. Owens Corning Fiberglass, et al., USDC SD Miss: Confidential information, not to be copied, reproduced or distributed except in accordance with this Court's order.

08 006 1079

Reaction in Guinea Pigs.—The experiment was started with 100 guinea pigs. After exposure had been carried on for a year, a severe epidemic of pneumonia arose in the dust room and about one third of the animals died or were killed. To replace them, 38 more guinea pigs were added to the surviving group. Histological examination revealed lesions in the lungs after eight months of dust exposure, consisting of cellular connective tissue about the terminal bronchioles (fig. 7 *A*). At 12 months there were adenomatoid changes in the adjacent parenchymal areas, and by the sixteenth month (fig. 7 *B*) definite fibrosis was present in these areas as well as around the bronchioles. The fibrous lesion could be seen macroscopically at 20 months. From this time on the reaction increased in extent and in the amount of collagen, and by the thirty-fourth month, it had fanned out

TABLE 11.—*Size-Frequency of Atmospheric Long Fiber and 100 per Cent Ball-Milled Asbestos Dust Collected Inside Cages*

Type of Asbestos	Grains, %			Fibers, %		Clumps, %	Total
	< 3 Microns	3-10 Microns	> 10 Microns	< 10 Microns	> 10 Microns		
Long fiber	65.4	1.1	0.0	25.5	6.7	1.0	100
Ball-milled	90.6	4.8	0.0	0.8	0.6	3.2	100

TABLE 12.—*Summary of Inhalation Experiment with Long Fiber Asbestos Dust*

Nature of Experiment	Animals	Maximum Dust Exposure, Mo.	Maximum Survival After Dust Exposure, Mo.	Results
Dust exposure continuous throughout life	117 guinea pigs	36	0	Definite fibrosis in 16 mo.
	4 cats	42	0	Slowly developing fibrosis first seen at 24 mo.
	20 rats	25	0	Marked peribronchiolar fibrosis first seen at 24 mo.
	20 mice	25	0	Limited reaction; no fibrosis
Dust exposure followed by prolonged residence in normal air	12 guinea pigs	20	14	Clearing of inflammatory reaction and definite contraction of fibrous tissue
	9 guinea pigs	27	9	Clearing of inflammatory reaction and slight contraction of fibrous tissue
	2 cats	18	24	Similar to continuous exposure group; suggestion of progression in one of the two animals

considerably into the parenchyma (fig. 8 *A*). The lesions were rather sharply localized and the extensions from different bronchioles showed no tendency to fuse, even in animals exposed for the maximum period of three years. Although the intrapulmonary reaction sometimes reached the pleura, there was no involvement of that membrane. Emphysema was not detected at any point. Some thickening of the larger bronchi with a chronic inflammatory infiltration was revealed, but it was considered no more than would be produced by a similar period of inhalation of any dust.

In guinea pigs exposed to the dust for 20 months and then removed to normal air, there was a marked tendency for cellular inflammatory reaction to clear. This effect, accompanied by contraction of the fibrous tissue, resulted in a diminishing size of the focal lesions. None of these animals, killed at various periods up to 14 months after exposure, revealed lesions as large as those in the group killed at the end of the 20 month exposure period or those in animals which remained in the dust room for more than 20 months. Fourteen months after dust exposure ceased, the foci in four of the six remaining guinea pigs were so small that they were visible only with a hand lens (fig. 8 *B*).

CLAIMED PRIVILEGED BY OCF

Produced under Court Order in Re: W. R. Grace Corporation Asbestos Litigation, USDC-MD Miss. Confidential Information - Subject to Protective Order - not to be copied, reproduced or distributed except in accordance with this Court's order.

08 006 1080

CLAIMED
PRIVILEGED
BY OCF

In the group exposed for 27 months and then transferred to a normal atmosphere the response was quite similar to that in the 20 month exposure animals mentioned above. Small foci were always visible on gross inspection of sections of all guinea pigs of the 27 month series, but in no instance was there evidence of the reaction.

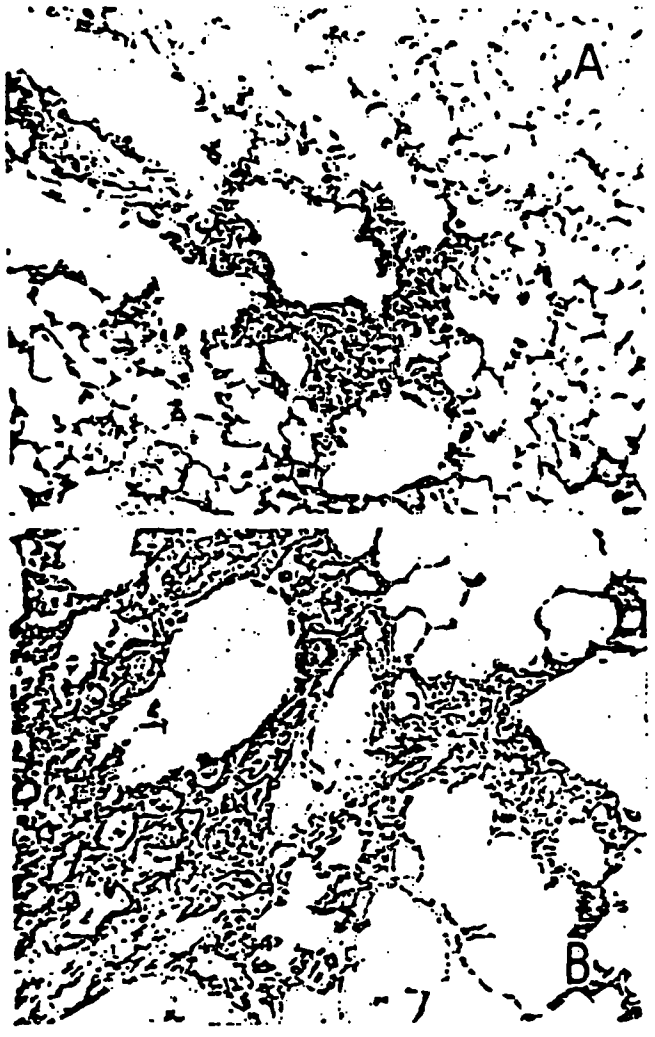

Fig. 7.—Long fiber asbestos inhalation experiment: *A*, lung of a guinea pig with eight months' dust exposure. The bronchiole at the center already shows an accumulation of phagocytic cells, and there is a slight deposition of collagen. Compare with figure 6 *A*, showing the reaction to ball-milled asbestos after 24 months (× 200).

B, lung of a guinea pig with 16 months' dust exposure. Again note a bronchiole with its surrounding reaction, consisting of fibrosis and adenomatoid change. Collagen deposition is now seen in the walls of adjacent alveoli, at the right (× 200).

In the tracheobronchial lymph nodes reaction was first visible at the third month of exposure. By the eighth month patches of cellular connective tissue

Produced under Court Order in Hart v. Owens Corning Fiberglas, et al., USDC SD Miss: Confidential Information, not to be copied, reproduced or distributed except in accordance with this Court's order.

08 006 1081

CLAIMED PRIVILEGED BY OCF

began to appear in the medulla, and by the fourteenth month most of the node had been replaced by cellular connective tissue. This picture, which resembled that in early silicosis, persisted to the end of the experiment. Some animals showed, as a variant, heavy sheets of diffusely distributed monocytes and large active giant cells, but there was never any necrosis or hyaline formation. The spindle-shaped



Fig. 8.—Long fiber asbestos inhalation experiment: *A*, lung of a guinea pig with 34 months' dust exposure. A bronchiole is seen at the lower center; the large area above it represents the involvement of alveolar walls. Compare with figure 7 *B* and note the increased extent of reaction (× 200).

B, lung of a guinea pig with 20 months' dust exposure and then 14 months' living in normal air. The reaction is essentially like that shown in figure 7 *B*: The bronchiole at the right center is surrounded by fibrous tissue with adenomatoid change at the right. There is residual scarring in the walls of adjacent alveoli at the left. It is apparent that no progression has occurred (× 200).

new cells were yellowish from fine pigment granules that stained for iron. No fibers or asbestosis bodies were seen.

Produced under Court Order in Hart v. Owens Corning Fiberglas, et al., USDC SD Miss: Confidential information, not to be copied, reproduced or distributed except in accordance with this Court's order.

08 006 1082

CLAIMED
PRIVILEGED
BY OCF

Although asbestosis bodies were found in the lung as early as one month after exposure began, they were rare and hard to find. At five months more were visible, chiefly coiled inside giant cells, and at eight months many bodies

TABLE 13.—*Analyses of Lungs of Guinea Pigs Exposed to Dust in Inhalation Experiment with Long Fiber Asbestos Dust*

Exposure to Dust, Mo.	Period in Normal Air, Mo.	Amt. of Ash, % of Dried Lung	Total SiO_2, % of Dried Lung	Total SiO_2, % of Ash	Tissue Reaction *
Dust Exposure Continuous During Life					
1	0	4.35	0.04	1.10	
		4.35	0.09	2.11	
		4.37	0.04	0.93	0
2	0	6.65	0.05	1.27	
		6.46	0.05	1.16	
		6.35	0.09	1.46	±
3	0	6.38	0.05	1.20	
		6.38	0.05	1.13	
		6.81	0.05	1.48	±
5	0	6.77	0.05	1.75	
		6.63	0.13	2.07	
		8.09	0.09	1.77	±
8	0	6.72	0.10	2.21	
		6.92	0.09	1.50	
		6.34	0.07	1.54	+
12	0	6.87	0.25	5.20	
		5.05	0.20	4.09	
		5.16	0.31	5.99	+
16	0	2.96	0.38	12.70	
		2.81	0.35	12.25	
		3.16	0.34	10.91	2+
20	0	3.34	0.43	12.88	
		3.09	0.42	13.63	
		3.35	0.52	14.50	2+
24	0	3.42	0.35	10.18	
		3.52	0.29	8.29	3+
27	0	3.40	0.39	11.51	
		3.74	0.49	13.15	3+
30	0	3.53	0.37	10.55	
		3.93	0.34	11.53	
		3.64	0.24	6.10	4+
34	0	3.85	0.50	8.69	
		6.70	0.84	12.47	4+
36	0	4.10	0.37	9.11	
		2.71	0.35	12.60	4+
Dust Exposure Followed by Prolonged Residence in Normal Air					
20	0	3.34	0.43	12.88	
		3.09	0.42	13.63	
		3.35	0.52	14.50	2+
20	4	3.92	0.31	7.85	
		2.81	0.27	9.50	2+
20	10	4.19	0.24	5.75	
		4.30	0.22	5.07	2+
20	14	5.01	0.21	4.19	
		5.04	0.18	3.56	+
27	0	3.40	0.39	11.51	
		3.74	0.49	13.15	3+
27	3	3.56	0.31	8.59	
		2.84	0.19	6.94	2+
27	7	3.19	0.25	7.90	
		3.18	0.28	8.72	2+
27	9	3.21	0.29	8.95	
		2.76	0.23	8.31	2+

* The symbols averaging the tissue reaction in each group represent merely the relative degree of reaction, ranging from 0 to ± (questionable) to 4+ (the maximum for this experiment). The relationships apply only within this table and cannot be compared with symbols in other tables.

were free in connective tissue. They became fairly abundant as exposure continued, although in some later animals the asbestosis bodies were only moderately numerous.

It is important to note from analyses of the lungs (table 13) that even though the tissue response at any given period of time was much greater in the guinea

Produced under Court Order in Hart v. Owens Corning Fiberglas, et al., USDC SD Miss: Confidential information, not to be copied, reproduced or distributed except in accordance with this Court's order.

08 006 1083

CLAIMED
PRIVILEGED
BY OCF

Reaction in Mice.—Out of 20 white mice used in this experiment, 11 lived a year or more in dust and died or were killed without showing an appreciable degree of pulmonary infection. The reaction to the inhaled dust was limited to phagocytosis by mononuclear cells. Usually these were widely scattered through the air spaces; a limited number were grouped about the terminal bronchioles, producing some thickening of their walls. There was no suggestion of fibrosis.

Numerous asbestosis bodies were observed in animals killed late in the experiment. Thus these animals exhibited asbestosis bodies without fibrosis.

Summary and Interpretation of Inhalation Experiment with Long Fiber Asbestos Dust.—The purpose of this experiment was to evaluate the importance of long fibers in the tissue response to inhaled asbestos. The results, in comparison with those of previous investigations, indicate strongly that long fibers are chiefly responsible for asbestosis. Thus, the reaction in guinea pigs developed earlier and became more extensive in this experiment than in previous experiments in spite of a smaller concentration of atmospheric dust and a lower mineral content of the lungs. Furthermore, typical peribronchiolar fibrosis was produced in cats, although in a previous experiment with short fiber dust peribronchiolar fibrosis did not develop in this species.

The cause of the cellular fibrosis in the lymph nodes of the guinea pigs is not clear. It did not occur in other inhalation experiments with asbestos.

INJECTION EXPERIMENTS

Since the inhalation experiments reported above strongly suggested that long fibers of asbestos are the significant factor in the causation of asbestosis, a series of injection experiments was inaugurated wherein the dosage and the length of the fibers could be controlled more precisely. Also, by the use of controlled dosages, the relative capacities of various asbestos minerals to produce reaction could be compared. In these injection experiments, guinea pigs, rabbits, rats and dogs were used, and the mineral dust was injected by the intratracheal, the intraperitoneal and the intravenous technic, but not all the technics were used for each species. For the purpose of simplification the findings in each series of tests, except for dogs, have been condensed and reported in tables, to which reference will be made later. In the case of dogs, only one test was made, and since the findings were negative, no detailed report is included.

EXPERIMENTS USING INTRATRACHEAL TECHNIC

As the asbestos minerals do not cause typical advanced fibrosis in extrapulmonary tissue, the intratracheal technic is the preferred way of introducing fibrous dust into the experimental animal. In this method the dust suspension is injected by means of a special needle or catheter deep into the trachea, from which it flows into the lungs.

Comparison of Fibrous and Nonfibrous Dusts.—To demonstrate that the ability of asbestos to produce fibrosis resides in its fibrous character, the series of injection experiments reported in table 14 were performed.

Produced under Court Order in Basic Dockets (DDC ID Nos. [illegible]) Contains Privileged Material et al. Information. Not to be copied, reproduced or distributed except in accordance with this Court's order.

08 006 1084

CLAIMED PRIVILEGED BY OCF

TABLE 14.—*Comparison of Reactions to Chrysotile and Serpentine Injected Intratracheally*

Dosage: Each animal was given an intratracheal injection of 0.5 cc. of a 5 per cent suspension of the dust. Two weeks later another similar injection was given. Total amount of dust injected was 50 mg.

Animals used: Six groups of 9 guinea pigs each (one group for each type of dust).

Periods at which animals were killed: One or two animals in each group at 1, 2, 6, 8½ and 12 months after last injection.

Preparation of dust: Chrysotile (ball milled) unheated: Ball milled for 1,176 hr., dried and reground in agate mortar.
Chrysotile (ball milled) ignited: Ball milled chrysotile heated for 2 hr. at about 700 C., then ground in agate mortar 2 or 3 min.
Chrysotile (fibrous) unheated: Ground in agate mortar to pass 200 mesh.
Chrysotile (fibrous) ignited: 200-mesh material heated for 2 hr. at about 700 C. No further grinding.
Serpentine (ball milled) unheated: Ball milled for 1,456 hr., dried and reground in agate mortar.
Serpentine (ball milled) ignited: Ball milled serpentine heated for 2 hr. at about 700 C., then ground in agate mortar 2 or 3 min.

Mineral	Size of Dust Particles	Results
Chrysotile (ball milled) unheated	3 microns and less	Grinding destroyed capacity to cause fibrosis. At 1 mo. considerable inflammatory edema and cellular proliferation and localization of dust particles about bronchioles; at 2 mo., only a very slight proliferative reaction; at 6, 8½ and 12 mo., widely scattered small mononuclear phagocytes. At 12 mo., a few microscopic patches of thin alveolar wall thickening with some adenomatoid change in portion of air spaces abutting on thickened bronchi. No asbestosis bodies seen.
Chrysotile (ball milled) ignited	3 microns and less	Reaction limited to large foreign body giant cells without production of fibrous tissue.
Chrysotile (fibrous) unheated	20-30 microns approx.	A distinct fibrosis. Reaction localized to connective tissue about terminal bronchioles; little within those tubes. Contraction caused adenomatoid appearance of air spaces given off directly from terminal bronchioles. Reaction area became smaller with progress of time; no new regions involved. No chronic pleurisy even at points abutting intrapulmonary change. At 1 mo. considerable inflammatory edema and foci of cellular proliferation; at 2 mo. well marked cellular proliferation and fibrosis occurring focally about respiratory bronchioles. This reaction developed before asbestosis bodies had formed and was as advanced as that produced by 2 yr. inhalation of asbestos dust. At 6 mo., reaction less extensive than at 2 mo., apparently due to contraction of fibrous tissue; asbestosis bodies were abundant. At 8½ mo., reaction still less extensive, confined to the immediate vicinity of the small terminal bronchioles, where the scar tissue was quite dense and was becoming hyaline in character. Sometimes it even obliterated the bronchiole. Asbestosis bodies had become scarce. At 12 mo., the well developed peribronchial and intrabronchial adenomatoid areas of fibrosis had produced considerable distortion. More peripherally were patches of pneumonitis with eosinophilic infiltration, some of which was being transformed into fibrous tissue. These seemed to be precursors of the localized, diffuse patches of thin alveolar wall fibrosis seen elsewhere.
Chrysotile (fibrous) ignited	20-30 microns approx.	Reaction limited to large foreign body giant cells without proliferation. Heating the fibers, which made them brittle, destroyed their capacity to produce significant reaction.
Serpentine (ball milled) unheated	3 microns and less	Dust relatively inactive. At 1 and 2 mo., simple phagocytosis without proliferation; at 6 mo., no change except possibly lymphoid cell infiltration; at 8½ mo., a slight chronic pneumonitis; at 12 mo., only a little pneumonitis without suggestion of fibrosis.
Serpentine (ball milled) ignited	3 microns and less	Dust relatively inactive. Reaction essentially the same as for unheated serpentine. With ignited serpentine, less tendency for dust to be carried to bronchial nodes.

Produced under Court Order in Matt F. Ommen (UNITED Minerals Corporation et al. Confidential Information, not to be copied, reproduced or distributed except in accordance with this Court's order.

08 006 1085

CLAIMED
PRIVILEGED
BY OCF



Fig. 10.—Comparison of reactions provoked by injected long fiber and ball-milled asbestos dusts: *A*, lung of a guinea pig which four months before had received an intratracheal injection of long fiber asbestos dust. Note the peribronchiolar accumulation of cells with collagen deposition. The bronchiole chiefly involved is in the midst of the reaction (× 200).

B, lung of a guinea pig which four months before had received an intratracheal injection of ball-milled asbestos dust. A bronchiole is shown at the right. In contrast with *A*, note that only a few cells have accumulated about the bronchiole and that collagen deposition is absent (× 200).

Produced under Court Order in Hart v. Owens Corning Fiberglas, et al., USDC SD Miss: Confidential Information, not to be copied, reproduced or distributed except in accordance with this Court's order.

08 006 1086

CLAIMED
PRIVILEGED
BY OCF

The tests were made with long fiber chrysotile, unheated, and with chrysotile that had been ignited to destroy its flexible structure or ball milled to reduce the length of fiber to 3 microns and less. At the same time control tests were made with serpentine, which has the same chemical composition as chrysotile but is nonfibrous. A review of the findings reveals that only the unheated, long fiber chrysotile produced typical peribronchiolar fibrosis and that ball-milled material containing only fibers less than 3 microns in length failed to cause fibrosis (figs. 10 and 11). Fibers subjected to ignition also had lost their capacity to cause serious tissue damage. Ignition produced important changes in the chrysotile fibers, among them being loss of water, an alteration from a flexible to a brittle structure and possibly other changes. Experi-

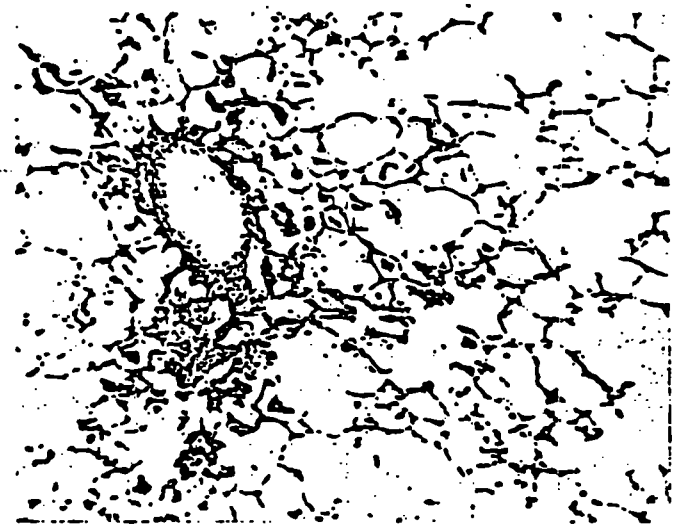

Fig. 11.—Serpentine injection experiment: Lung of a Guinea pig that had received an intratracheal injection of this dust four months before. A bronchiole is shown at the left center. The phagocytic cells exhibit little predilection for the bronchiole and collagen deposition is absent (× 200).

mental studies concerning this observation will be reported in a separate publication.

Comparison of Various Long Fiber Dusts.—Some very interesting findings are disclosed by the results of the experiments recorded in table 15. First, all the long fiber asbestos minerals tested, with the exception of anthophyllite, produced typical fibrosis. The characteristic peribronchiolar reaction caused by three representative long fiber asbestos minerals—chrysotile, amosite and crocidolite—is shown in figures 10 *A* and 12. Why anthophyllite behaved differently from the other asbestos minerals is not entirely clear.

Second, with the mineral brucite, which is not a silicate but is a fibrous form of magnesium hydroxide, a characteristic fibrosis like

Produced under Court Order in Hart v. Owens Corning Fiberglass, et al., USDC ED Miss: Confidential information, not to be copied, reproduced or distributed except in accordance with this Court's order.

08 006 1087

Intratracheally

CLAIMED PRIVILEGED BY OCE

Dosage: Two injections of 0.5 cc. of a 5 per cent suspension given two weeks apart. Total dose was 50 mg.

Animals used: From 6 to 9 guinea pigs for each dust.

Periods at which animals were killed: Usually at 1, 4, 8 and 12 months after last injection.

Size of dust particles: Separated so that most fibers were from 20 to 30 microns long.

Mineral	Results
Chrysotile (Thetford)	Distinct fibrosis. Additional information given opposite chrysotile (fibrous) untreated, in table 14.
Chrysotile (Arizona; low iron content; 0.2% Fe_2O_3)	Reaction virtually identical with that to Thetford chrysotile. Both fibrous and asbestosis bodies produced with an asbestos containing very little iron. Fibrosis occurred as plugs within terminal bronchioles and as dust deposits at periphery. Fibrosis developed before asbestosis bodies were seen and was in cellular state well formed at one month. With age, fibrous tissue contracted and occupied smaller area but was more dense. Adenomatoid changes similar to those with Thetford chrysotile. Pleurisy limited to immediate vicinity of early reaction about areas of massive localization. Asbestosis bodies formed but were few. At 1 mo. after injection, minute foci of mononuclear proliferation about bronchioles and in areas of atelectasis; at 1½ mo., heavy peribronchiolar patches of fibrosis often with papillary projections partially closing lumen of bronchiole; adenomatoid appearance marked; connective tissue reaction showed heavy collagen but no hyalinization; at 2 mo., minute foci of well matured fibrosis about bronchioles; at 6 mo., mature asbestosis *fibrosis with evidence of contraction; considerable* chronic pneumonitis with infiltration of lymphocytes and eosinophils. At 9 mo., small intrabronchiolar fibrous plugs with foci of more delicate fibrosis at periphery.
Amosite	Typical fibrous endobronchiolitis and peribronchiolitis with formation of atypical asbestosis bodies. Haustration of bodies begun before 4th mo. *after injection, well developed by* 8th mo. *Bodies* persist after 12th mo. Reaction at 1 mo. heavy endobronchiolitis and peribronchiolitis already showing fibrous changes; atelectasis and fibrosis with some necrosis at site of massive localization of dust. At 4 mo., heavy, widely scattered endobronchiolitis and peribronchiolitis, now fibrous, with marked deformity of bronchioles and with an adenomatoid appearance. *At 8 and 10½* mo., reaction in lung essentially the same as at 4 mo. At 12 mo., foci of fibrous endobronchiolitis and peribronchiolitis still large, with more dense scar tissue and more deformity of bronchial tubes but no extension into, or atelectasis of, peripheral parenchyma.
Crocidolite (Bolivia)	Advanced fibrous endobronchiolitis and *peribronchiolitis*. Beaded asbestosis bodies noted at 8 mo. At 1 mo., early fibrous endobronchiolitis and peribronchiolitis; many giant cells and some lymphocytic reaction. At 4 mo., small areas of endobronchiolitis scattered throughout the lung; cellular fibrosis. At 8 and 12 mo., areas of bronchiolitis smaller because of contraction of dense scar tissue; at 12 mo., marked lymphocytic infiltration and adenomatoid appearance.
Crocidolite (S. Africa)	Typical advanced fibrous endobronchiolitis and peribronchiolitis produced by 0.5% suspension (1 cc. total dose); most animals would not tolerate usual 5% suspension. Fibrosis well developed before asbestosis bodies seen. At 4 mo., well developed fibrous bronchiolitis with lymphocytes and *giant cells and adenomatoid change*. At 8 mo., typical bronchiolitis not quite as extensive or as heavily fibrous as with a 5% suspension, otherwise the same. Many deeply stained fibers with a good proportion of haustrated asbestosis bodies. At 12 mo., heavy fibrous bronchiolitis, more peribronchiolitis and endobronchiolitis, with lymphocytes and giant cells; very marked adenomatoid appearance.
Anthophyllite	Lymphocytic infiltration and giant cells but no fibrosis. A very few atypical asbestosis bodies. At 1 mo., many scattered foci of intrabronchiolar dust without massive localization; lymphocytic infiltration of walls and a few giant cells. At 8 and 12 mo., little evidence of dust; a few bronchioles and bronchi with giant cells in *adjacent alveoli and with lymphocytic* infiltration of walls.
Tremolite	Fibrosis about bronchioles. At 1 mo., areas of dust localization with collapse of alveoli and infiltration with acute inflammatory cells, macrophages and giant cells. Within the area were a few foci of fibrous tissue *and numerous areas of hypertrophy of alveolar epithelium*. Many bronchioles packed with fibers. At 4 mo., general appearance of lesion unchanged; pleura slightly thickened over heavy localizations of dust. An occasional segmented asbestosis body seen. At 8 mo., many foci of fibers in bronchioles and alveolar ducts with cellular reaction as before; also, some foci showed distinct collagen deposition. At 12 and 18 *mo.*, reaction as before with fibrosis about bronchioles more apparent because of contraction and decrease of inflammation. Giant cells prominent. Pleura markedly involved.
Brucite	Typical fibrous endobronchiolitis and peribronchiolitic like reaction to asbestos minerals. At 1 mo., extensive *endobronchiolitis and peribron*chiolitis with giant cells; dense fibrous loops within bronchioles and cellular fibrosis about them; adenomatoid change present. At 2 mo., heavy intrabronchiolar and peribronchiolar fibrosis producing marked deformity with distortion of tubes and obliteration of surrounding air spaces; fibrosis pale without hyalinization but with few nuclei; no necrosis. Typical asbestosis bodies seen. At 4 and 8 mo., little change; fibrous tissue contracting. At 10½ mo., dense fibrous bronchiolitis with asbestosis bodies. No pleurisy. No extension to surrounding lung.
Glass wool	No fibrosis within a year. At 1 mo., no reaction inside bronchioles; in peripheral air spaces clumps of giant cells packed with fine spicules of glass with lymphocytic infiltration of adjacent walls; no asbestosis bodies. At 2 mo., reaction less intense than at 1 mo.; fair-sized clumps of elongated giant phagocytes containing spicules and particles of glass; no endobronchiolitis. At 4 and 8 mo., reaction still diminishing. At 12 mo., focal areas of pneumonitis with no fibrosis or endobronchiolitis; moderate number of smooth iron-staining fibers.

Produced under Court Order in Part v. Owens Corning Fiberglas, et al., USDC SD Miss. Confidential Information, not to be copied, reproduced or distributed except in accordance with this Court's order.

08 006 1088

CLAIMED
PRIVILEGED
BY OCF

that produced by the asbestos minerals was obtained (fig. 13 *A*). Since the brucite used contained only 0.90 per cent silica as an impurity, it is obvious that a siliceous component is not an essential factor in the development of asbestosis.



Fig. 12.—Amosite and crocidolite injection experiments: *A*, lung of a guinea pig four months after an intratracheal injection of amosite. The inflammatory reaction exhibits pronounced accumulation of cells and collagen deposition (× 200). *B*, lung of a guinea pig four months after an intratracheal injection of crocidolite. As in *A*, peribronchiolar accumulation of cells and deposition of collagen are shown (× 200).

Third, no fibrosis resulted from the injection of glass wool fibers (fig. 13 *B*), even though glass wool resembles asbestos However, there are fundamental differences. A glass woo

Produced under Court Order in Hart v. Owens Corning Fiberglas, et al., USDC SD Miss. Confidential information, not to be copied, reproduced or distributed except in accordance with this Court's order.

08 006 1089

in diameter is a solid rod which in short lengths is fairly rigid, while an asbestos fiber of the same diameter is a bundle of extremely fine filaments which impart to the fiber a high degree of flexibility. It would seem that this structure and the associated flexibility are important factors governing the capacity of a mineral to produce peribronchiolar



CLAIMED
PRIVILEGED
BY OCF

Fig. 13.—Brucite and glass wool injection experiments: *A*, lung of a guinea pig which four months before had received an intratracheal injection of brucite. Even with this nonsiliceous fibrous mineral there is peribronchiolar accumulation of cells and deposition of collagen similar to that shown in *A* and *B* of figure 12 (× 200).

B, lung of a guinea pig which four months before had received an intratracheal injection of glass wool. Two bronchioles are shown, one in cross section and the other in longitudinal section. Below the latter is a thick-walled blood vessel. The bronchioles are without reaction and can be considered normal for comparison with other figures. Glass wool fibers are present in this field but cannot be seen at this magnification (× 200).

Produced under Court Order in Hart v. Owens Corning Fiberglas, et al., USDC SD Miss. Confidential information, not to be copied, reproduced or distributed except in accordance with this Court's order.

08 006 1090

fibrosis. Experimental studies concerning this observation will be reported in a separate publication.

TABLE 16.—*Comparison of Reactions Produced by Long Fiber and Short Fiber Dusts Injected Intratracheally*

Dosage: Two injections of 0.5 cc. of a 5 per cent suspension given two weeks apart. Total dose was 50 mg.

Animals used: Six groups of guinea pigs.

Periods at which animals were killed: 1, 2, 6, 8½ and 12 months after injection.

Mineral	Size of Dust Particles	Results
Chrysotile (Thetford)	Long fiber, 20-50 microns	A distinct fibrosis. Refer to chrysotile (fibrous) unheated in table 14.
	Short fiber, 3 microns and less	No fibrosis. Refer to chrysotile (ball milled) unheated in table 14.
Amosite	Long fiber, 20-50 microns	Typical fibrous endobronchiolitis and peribronchiolitis. Refer to table 15.
	Short fiber, 20 microns and less	Reaction limited to phagocytosis with lymphocytic infiltration of adjacent walls. Short fibers packed inside swollen phagocytes; longer ones free; some coated to form typical asbestosis bodies. At 1 mo. after injection, alveoli contained good-sized giant cells; most phagocytes were within air spaces and had not migrated to walls. At 4 mo., free extracellular fibers had worked themselves into interstitial tissue, where there was extensive proliferation of lymphoid cells and monocytes but no fibrosis. At 8 mo. foreign body reaction with some pneumonitis, no bronchiolitis. Typical asbestosis bodies present.
Crocidolite (Bolivia)	Long fiber, 20-50 microns	Advanced fibrous endobronchiolitis and peribronchiolitis. Refer to table 15.
	Short fiber, 20 microns and less	No fibrosis. At 1 mo., air spaces compressed and largely filled with giant cells packed with dust needles. Walls heavily infiltrated with monocytes and lymphoid cells. At 4 mo., a moderate degree of cellular infiltration of walls; small giant cells packed with dust spicules. At 6 and 8½ mo., masses of giant cells, containing mineral particles, in small bronchi but not in respiratory bronchioles; smaller ones widely scattered in terminal air spaces. Numerous asbestosis bodies. No reaction in connective tissue. No endobronchial proliferation. At 12 mo., many scattered small monocytes packed with dust. No endobronchitis. No peripheral fibrosis. In lymph node, slight reticulosis; no fibrosis.
Anthophyllite	Long fiber, 20-50 microns	Lymphocytic infiltration and giant cells but no definite fibrosis. Refer to table 15.
	Short fiber, 3 microns and less	No fibrosis and practically no asbestosis bodies. At 1 mo., focal collections of dust-filled monocytes and a few giant cells; at 4 mo., some adenomatoid epithelial reaction; at 8 mo., simple pneumonitis with phagocytosis of short fibers; at 12 mo., isolated and sharply localized collections of dust cells inside air spaces about terminal arterioles. Reaction in walls limited to lymphoid cell infiltration. No fibrosis. In lymph node, reaction limited to slight prominence of reticulum.
Tremolite	Long fiber, 20-50 microns	Fibrosis about bronchioles. Refer to table 15.
	Short fiber, 20 microns and less	Simple foreign body reaction. No acute inflammation. No accumulation of dust in or about terminal bronchioles. No endobronchitis. At 1 mo., scattered small giant cells and considerable infiltration of adjacent walls with monocytes and lymphoid cells. At 4 mo., little change except more cellular infiltration of connective tissue. At 8 mo., lymphoid infiltration and thickening of walls about some but not all terminal bronchioles.
Brucite	Long fiber, 20-50 microns	Typical fibrous endobronchiolitis and peribronchiolitis like reaction to asbestos minerals. Refer to table 15.
	Short fiber (made by crushing long fibers with rubber policeman)	Inert type of reaction. At 1 mo. after injection, small monocytes widely scattered through air spaces; focus of atelectasis with lymphoid infiltration of compressed air-space walls. No endobronchial reaction as with chrysotile. At 2 mo., reaction similar to that at 1 mo.; typical asbestosis bodies seen. At 12 mo., small clumps of inactive dust-filled phagocytes; no fibrosis. No reaction in lymph nodes.

Comparison of Long Fiber and Short Fiber Dusts.—With quartz dust it has been demonstrated that the smaller the particles the more

CLAIMED PRIVILEGED BY OCF

Produced under Court Order in Hart v. Owens Corning Fiberglas, et al., USDC SD Miss. Confidential information, not to be copied, reproduced or distributed except in accordance with this Court's order.

08 006 1091

CLAIMED PRIVILEGED BY OCF

intense is the tissue reaction and that particles larger than 3 microns in diameter cause little reaction. In the case of asbestos, however, the reverse is true and apparently only long fibers have any specific effect, as was suggested by the inhalation experiments. This is confirmed by the data of table 16, in which a series of tests with fibrous minerals is reported. When the injected dust consisted of fibers 20 to 50 microns long, all the fibrous minerals tested except anthophyllite, as noted in the preceding section, produced fibrosis; when the material was prepared by first grinding the fibrous dust until the length of fibers was reduced to 20 microns and less or, in some cases, to 3 microns and less, none of the injected dusts caused fibrosis.

These results differ from those of King, Clegg and Rae,[11] who reported the production of reticulosis comparable to the experimental silicotic nodule in rabbits receiving monthly intratracheal injections of 100 mg. of Rhodesian asbestos fibers, 15 microns long, and the production of diffuse interstitial fibrosis in rabbits receiving similar injections of short fibers, 2.5 microns in length. We believe this dose, especially in the long term rabbits, is highly excessive. In our experiments the dosage was kept low in order to minimize untoward reactions which might obscure the peribronchiolar type of fibrosis which characterizes early human asbestosis.

Experiments Using Intravenous Technic

The experiments summarized in table 17, in which the intravenous method of injection was employed, show that the asbestos minerals are far different from quartz in their action on tissue. It has been repeatedly demonstrated that intravenous injection of quartz particles 3 microns and less in diameter will cause a typical tissue reaction with the development of hyalinized fibrotic lesions in extrapulmonary sites, such as the liver and the spleen. Asbestos minerals, however, on intravenous injection generally produce only an inert type of reaction, as is revealed by the results given in the table. The reason for the early deaths in the experiment with chrysotile particles is not clear.

Experiments Using Intraperitoneal Technic

The results of injection experiments with the intraperitoneal technic are given in table 18. It will be noted that the long fiber dusts produced a fibrous reaction while dusts composed of particles 3 microns and less in size caused only an inert type of response. These experiments indicate also that the fibrosis initiated by the irritation of asbestos fibers is not restricted to the lungs, as was formerly assumed, but can be produced in the peritoneum as well.

OTHER EXPERIMENTS WITH ASBESTOS MINERALS

A number of additional experiments were conducted to throw more light on specific phases of the asbestosis problem.

11. King, E. J.; Clegg, J. W., and Rae, V. M.: Effect of Asbestos, and of Asbestos and Aluminum, on Lungs of Rabbits, Thorax 1:188, 1946; abstracted, Indust. Hyg. Digest, 1947, vol. 11 (Feb.), no. 234.

Produced under Court Order in Hart v. Owens Corning Fiberglas, et al., USDC SD Miss. Confidential information, not to be copied, reproduced or distributed except in accordance with this Court's order.

08 006 1092

TABLE 17.—*Summary of Injection Experiments by Intravenous Technic*

Dosage: Total amount of dust was 1.0 Gm., divided into 20 equal doses (each dose was 5 cc. of a 1 per cent suspension) which were given twice a week for 10 weeks.

Mineral	Size of Dust Particles	Rabbits Used	Maximum Survival After Last Injection, Mo.	Results
Chrysotile (Thetford)	3 microns and less (ball milled 192 hr.)	6	..	The rabbits did not tolerate intravenous injections of finely ground chrysotile and 5 of the 6 died after 1 to 5 injections of even diluted suspensions; the other animal died after 25 injections of one-quarter strength suspension (69 days after first injection). Reaction limited to few large giant phagocytes of inactive type in liver, spleen and lungs. No thrombi of dust cells seen in pulmonary capillaries. No definite explanation for fatalities discovered, but material may have been retained in heart, causing focal thrombi.
Amosite	3 microns and less (ground in agate mortar)	5	17	Advanced pulmonary infection killed 3 animals at 9, 11 and 17 mo. after last injection, shortening intended duration of experiment and complicating picture. However, rabbits killed earlier (1 and 6 mo.) showed only inert phagocytosis with no progression in the 6 mo. animal. The last two (11 and 17 mo.) were probably the same although focal necrosis of the liver and amyloid of the spleen made interpretation difficult.
Crocidolite	3 microns and less (ground in agate mortar)	6	12	Reaction was that to an inert substance with no change in 12 mo. (Other observations at 3, 4 and 6 mo.) Simple phagocytosis of particles. No tendency to agglomerate and no change in adjacent tissues. Grinding the dust to sizes of 3 microns and under destroyed the fibrous structure of this mineral, and the injected material resembled plates rather than fibers.
Anthophyllite	3 microns and less (ball milled 1,400 hr.)	4	21	Reaction essentially that of an inert mineral. Observations made at 3, 6, 12 and 24 mo. Only suggestion of irritating properties manifested in spleen and lymph nodes, but not liver, of the 21 mo. rabbit. In this animal there had been proliferation of mononuclear and giant cells that was not present in either spleen or lymph node of 12 mo. animal. The absence of associated fibroblastic reaction in these organs and of any change in the liver condition justifies the classification of anthophyllite as an inert silicate. No fibers were retained in lung to demonstrate whether asbestosis bodies would develop.
Tremolite (soda-iron)	3 microns and less (ball milled 140 hr.)	4	18	Reaction essentially that of an inert mineral. Last animal killed showed a little proliferation and lymphocytic infiltration in liver, not seen earlier (at 3, 6 and 12 mo.). No evidence of any activity in lesions in other organs.
Tremolite (soda)	3 microns and less (ball milled 48 hr.)	4	21	An inert foreign body reaction with no change in 21 mo. Observations made at 3, 6, 12 and 24 mo.

CLAIMED
ILLEGED
OGF

08 006 1093

Produced under Court Order in Hart v. Owens Corning Fiberglas, et al., USDC SD Miss: Confidential information, not to be copied, reproduced or distributed except in accordance with this Court's order.

TABLE 18.—*Summary of Injection Experiments by Intraperitoneal Technic*

Dosage: Each animal * received a single intraperitoneal injection of 2 cc. of a 10 per cent dust suspension. Total amount of dust injected was 0.2 Gm.

Mineral	Size of Dust Particles	Guinea Pigs Used	Maximum Survival After Injection, Mo.	Results
Chrysotile (Thetford)	3 microns and less (ball milled 250 hr.)	15	36	No fibrosis or asbestosis bodies. Dust particles ingested by phagocytes, chiefly multinucleated variety. Six mo. after injection fibrous elements of dust appear to have dissolved leaving only the insoluble magnetite, a contaminant. No reaction in surrounding fat or areolar tissue. No transporting of dust to regional lymph nodes. Observations made at intervals from 1 to 36 mo. after injection.
Chrysotile (Thetford)	*Long fiber* (through 100 mesh)	4	2	Definite fibrous reaction produced, delicate and nonhyaline. Atypical asbestosis bodies developed, but all were unusually small. No evidence of extra long fibers seen. Observations only at 2 mo.
Amosite	3 microns and less (ground in agate mortar)	9	12	Infection interfered with interpretation. Dust reaction appeared to be of inert type and limited to phagocytosis with a moderate tendency to lymphocytic infiltration. Observations at 1, 4, 8 and 12 mo.
Crocidolite	3 microns and less; also some long spicules (ground in agate mortar)	7	12	Dust foci consisted only of large mononuclear and giant phagocytes surrounded by a minimum amount of cellular connective tissue. The injected dust contained not only fine material that *in grinding had been* mashed into *irregular plates but also many long spicules* 10 microns or *more* in length. No asbestosis bodies seen, although the longer spicules appeared slightly swollen and greenish. Observations at 1, 4, 8 and 12 mo.
Anthophyllite	3 microns and less (ball milled 1,400 hr.)	6	25	Essentially inert foreign body reaction. In early animals (1, 4 and 8 mo.) foci of monocytes and small giant cells and a little central necrosis. In the 4 mo. animal there was also slight peripheral fibrosis. At 12 and 25 mo., nonprogressive mass of monocytes and giant cells; no fibrosis.
Anthophyllite (originally labeled talc)	Mostly 3 microns and less; some fibers 30 microns or more long (ground in agate mortar)	5	12	Reaction, which consisted of very large giant cells surrounded by a variable number of lymphocytes, was much heavier to these unintentionally long fibers than to the fine dust in the experiment above. There was more or less proliferation of fibroblasts producing cellular connective tissue visible in areas where the quantity of foreign particles was not so great that it obscured the reaction. Observations at 1, 4, 8 and 12 mo.
Tremolite (soda-iron)	3 microns and less (ball milled 15 hr.)	5	12	Inert type of response never progressing beyond the stage of very slight lymphocytic reaction about masses of dust-filled phagocytes. No fibrosis. Observations at 1, 4, 8 and 12 mo.
Tremolite (soda)	3 microns and less (ball milled 45 hr.)	5	18	Inert nonprogressive foreign body type of reaction. No fibrosis. Observations at 1, 4, 8, 12 and 18 mo.
Anthophyllite	100 microns and less	6	12	Distinct early fibrosis produced by anthophyllite and fibrous pyrophyllite with subsequent regression; crystalline pyrophyllite inert throughout. At 1 mo., giant cells about long thick splinters; at 4 mo., definite fibrosis replacing giant cells of anthophyllite and fibrous pyrophyllite reaction; at 8 mo., fibrosis which started at 4 mo. had decreased, especially with fibrous pyrophyllite. At 12 mo., reaction to all three dusts consisted of foreign body giant cells with lymphocytes but without necrosis or fibrosis. No asbestosis bodies.
Pyrophyllite (fibrous)	100 microns and less	5	12	
Pyrophyllite (crystalline)	100 microns and less	5	12	

* Each animal receiving long fiber chrysotile was given an injection of 2 cc. of a 0.5 per cent dust suspension.

08 006 1094

CLAIMED PRIVILEGED BY OCE

Produced under Court Order in Hart v. Owens Corning Fiberglas, et al., USDC SD Miss: Confidential information, not to be copied, reproduced or distributed except in accordance with this Court's order.

CLAIMED PRIVILEGED BY OCF

Protective Action of Aluminum Compounds

When colloidal aluminum hydroxide had been added to a suspension of long fiber chrysotile prior to injecting this suspension intratracheally into rats, the aluminum compound did not prevent the irritation of tissue due to chrysotile. If anything, the acute inflammatory response evoked by the injected fibrous mineral was accelerated. One month after the last injection of the dust suspension the bronchiolitis was becoming fibrous. King and his associates also found that aluminum failed to protect pulmonary tissue from the irritation caused by asbestos fibers[11]; in their experiments metallic aluminum was used instead of the hydroxide.

Formation of Asbestosis Bodies

The iron in the coating of the asbestosis body appears to be derived from blood or tissue elements and not, as has been suggested, from the mineral fiber. After two kinds of chrysotile were injected subcutaneously into the groin of a guinea pig—one kind containing 2 per cent and the other 0.2 per cent ferric oxide—the asbestosis bodies were equally numerous at both sites of injection and showed no difference in their reaction to prussian blue, the reagent which stains iron. This finding is in agreement with that of Giroux.[12]

Tissue Reaction to Asbestosis Bodies

Asbestosis bodies recovered from human lung tissue and injected intratracheally into guinea pigs failed to produce a fibrous reaction. The material for injection was obtained by digesting with sodium hypochlorite solution the lung tissue removed at autopsy from an asbestos worker. The asbestosis bodies could be seen in the guinea pigs for at least a year after injection. This experiment shows that the asbestosis body has a rather resistant coating which is not destroyed by moderate hypochlorite treatment, which may be maintained in vivo for a year or longer and which renders the fiber incapable of producing fibrosis. It thus appears that the coating is a protective mechanism. This thought was expressed by Beintker as early as 1934.[13]

THEORY OF IRRITANT ACTION

Two hypotheses have been proposed to explain the tissue irritation and reaction caused by asbestos fibers: the chemical and the mechanical. In the chemical theory, which is based on experience with quartz, it is assumed that the asbestos minerals dissolve in the body fluids and that in this process their bases are leached away to leave silica in a form capable of irritating tissues. According to this hypothesis asbestosis is merely an indirect silicosis. Several facts make the chemical theory untenable: Intratracheal injection of brucite fibers, which had a silica

12. Giroux, M.: Amiantose expérimentale: valeur pathognomonique du "corps d'amiante," Laval méd. 8:239, 1943.

13. Beintker, E.: Über die Asbestosiskörperchen: Bemerkungen zu der Arbeit von Beger, Virchows Arch. f. path. Anat. 293:527, 1934.

08 006 1095

CLAIMED
PRIVILEGED
BY OCF

content of only 0.90 per cent, caused typical fibrosis like that produced by the asbestos minerals; free silica particles increase in potency as the particle size becomes less, but asbestos fibers shorter than about 10 to 20 microns are relatively innocuous; aluminum hydroxide neutralizes the irritating effect of quartz but not of asbestos; serpentine has the same chemical composition as long fiber chrysotile, but it produced only an inert type of tissue reaction; there is a wide range in the chemical composition of the minerals which do cause asbestosis (table 19). In view of this evidence it seems more likely that asbestosis is caused by an unusual mechanical irritation due to long asbestos fibers, this irritation being related to the peculiar filamented structure of the fiber and the associated flexibility, which are possessed by no other foreign body studied. Thus, ignition of chrysotile fibers changed their structure and made them inert, although the same fibers, before being heated, would have produced fibrosis (table 14). Further support for the theory of mechanical irritation is that asbestosis occurs in an organ of high mobility —the lung—and that a fibrous reaction can be produced by injecting

TABLE 19.—*Analyses of Fibrous Minerals*

Fibrous Minerals	SiO_2 %	Fe_2O_3 %	FeO %	Al_2O_3 %	CaO %	MgO %	Na_2O %	K_2O %	Ignition < 105 C. %	Loss > 105 C. %	Total %
Amosite	46.23	4.06	33.63	1.09	2.01	6.28	0.33	0.20	0.66	5.28	99.97
Amphibole	55.04	3.06	.....	1.09	12.22	23.29	0.42	0.12	0.32	3.60	99.77
Anthophyllite	59.80	0.57	.....	0.32	0.44	33.37	0.52	0.15	0.27	4.08	99.52
Brucite	0.90	6.78	9.38	0.46	0.04	53.90	0.91	0.16	0.53	26.86	99.79
Chrysotile	38.56	2.35	.....	0.34	0.03	38.95	0.29	0.06	4.30	14.99	99.89
Crocidolite	54.99	16.27	4.29	1.01	0.80	12.25	6.92	0.57	0.02	2.56	99.64
Tremolite	56.20	7.21	.....	0.56	4.44	20.52	6.78	0.90	0.34	2.78	99.52

asbestos fibers into the peritoneum, where there is also a degree of mobility, but not by injecting them into other extrapulmonary organs such as the liver, the spleen and subcutaneous tissue.

COMPLICATIONS

The experimental investigations with asbestos minerals were concerned primarily with the effect of the dust on normal tissue, but some attention was given to other phases, such as susceptibility to infection. The only experiment in which the effect of asbestos dust on a pulmonary infection was studied was the first inhalation experiment, carried on with King's floats dust. It is unfortunate that, owing to the lack of adequate facilities at that time, infection studies could not be made in the other inhalation experiments also.

SUSCEPTIBILITY TO TUBERCULOUS INFECTION

The development of a tuberculous process initiated at the beginning of exposure to dust, and also of a tuberculous infection superimposed on an established asbestosis, was described in preceding sections of this paper. It may be stated that asbestos when classified according to the effect of a dust on tuberculous infection would be placed below an active

Produced under Court Order in Hart v. Owens Corning Fiberglas, et al., USDC SD Miss: Confidential information, not to be copied, reproduced or distributed except in accordance with this Court's order.

08 006 1096

CLAIMED PRIVILEGED BY OCF

dust like quartz but above an inert dust such as iron oxide. In animals infected with attenuated tubercle bacilli, quartz causes the infectious process to progress until the animal dies of tuberculosis. Inert dusts have no effect on the infection, and the lesions usually heal and the disease disappears. Asbestos dust is in a different category. In the experimental investigation, when the fibrous dust was being inhaled during the evolution of the infection, there was spreading of the tuberculous process for a time, but usually the stimulus for continued proliferation of the tubercle bacilli was not sustained, the progression was arrested and healing followed. In guinea pigs infected with attenuated tubercle bacilli after being exposed to asbestos dust for slightly more than two years, progressive disease did not develop. The only modification of the infection was one of localization, a few bacilli being retained in the fibrous terminal bronchioles and forming tubercles there, in addition to the usual foci beneath the pleura. Such tubercles healed in a few months.

Susceptibility to Nontuberculous Infection

There was no specific experiment concerning the effect of inhaled asbestos dust on nontuberculous infection. Intercurrent pneumonia was rather common among animals exposed to asbestos dust, the frequency in guinea pigs exposed in the four inhalation experiments ranging from 16 to 39 per cent. This incidental evidence suggests the possibility of an effect of asbestos dust on nontuberculous infection. Nevertheless, since such epidemics are not uncommon in inhalation experiments with other dusts and even in the colony of normal animals, it is felt that the inhalation of asbestos dust does not exert a significant effect on the susceptibility to nontuberculous pulmonary infection.

COMMENT AND SUMMARY

Owing to the vast amount of data included in this investigation, it seems most convenient to summarize and to state as concisely as possible the various observations which emerged from the experiments and to follow each with a brief résumé of the evidence.

A. Various species of animals, including the guinea pig, the rat and the rabbit, but not the mouse and the dog, develop peribronchiolar fibrosis of the lung similar to human asbestosis after being exposed by inhalation or intratracheal injection to long chrysotile asbestos fibers.

Both inhalation and injection experiments provide ample support for this statement. Figure 8*A* reveals the cellular fibrosis that occurs in guinea pigs following inhalation of long fiber asbestos; figure 9 shows the fibrosis caused in the cat by inhalation of long fiber asbestos dust. Similar but less extensive fibrosis occurred also in rats and rabbits (table 1). Mice and dogs failed to respond. This variation in response of different species to identical dust exposures is still to be accounted for.

B. Long asbestos fibers are essential in the production of the peribronchiolar fibrosis; short fibers are incapable of producing this reaction.

Produced under Court Order in Box ... Docket ... Case ... Plaintiff's Exhibit ... Confidential Information. Not to be copied, reproduced or distributed except in accordance with this Court's order.

08 006 1097

CLAIMED
PRIVILEGED
BY OCF

Inhalation experiments with asbestos dust suggest, and intratracheal injection experiments confirm, that peribronchiolar fibrosis is produced by asbestos fibers between 20 and 50 microns in length but not by particles shorter than 20 microns (tables 16 and 18). This indicates that the minimum length of fiber possessing the capacity to produce the typical peribronchiolar fibrosis in animals is somewhere between 20 and 50 microns. Pointed studies have not been carried out to determine the upper limit of effective fiber length. It appears, however, that that limit will be determined by the inhalability of the fiber.

C. The mode of action of the long asbestos fiber in the production of asbestosis is primarily mechanical rather than chemical in nature.

The evidence for this conclusion has been reviewed in a preceding section, page 39. The flexible filamented structure of asbestos fibers plays an essential part in the irritating action, since the solid, inflexible fibers of glass wool do not produce fibrosis (fig. 13 *B*).

D. Typical experimental asbestosis was produced by the inhalation of an atmospheric suspension containing an average of 138 million asbestos particles per cubic foot of air by light field count, of which less than 1 per cent consisted of fibers longer than 10 microns.

In the inhalation experiment with 100 per cent ball-milled asbestos dust containing 0.6 per cent of fibers longer than 10 microns (table 11) typical fibrosis was obtained (table 9). The evidence presented shows at least that an atmospheric concentration of asbestos dust containing less than 1 million (0.6 per cent × 138 million) fibers longer than 10 microns per cubic foot of air is capable of producing experimental asbestosis in guinea pigs. The actual lower limit of concentration of long fibers necessary to produce asbestosis in animals cannot be established from these studies.

E. The duration of exposure required to develop the pulmonary reaction to inhaled asbestos dust is inversely proportional to the concentration of long fibers in the atmosphere; as the concentration is increased, the reaction develops in shorter time.

The basis for this statement appears in the data of the inhalation experiment with long fiber asbestos. For that experiment the average concentration of the atmospheric dust was about 40 million particles per cubic foot of air, and size-frequency determinations disclosed that 6.7 per cent of the air-suspended material consisted of fibers longer than 10 microns (table 11). Thus, by calculation, it is estimated that the concentration of the longer fibers was 2.7 million (6.7 per cent × 40 million). The lungs of animals exposed to the long fiber asbestos dust revealed that the pulmonary reaction developed in approximately one-half the exposure time required for its development in animals inhaling the ball-milled product, for which the concentration of the longer fibers was only 0.8 million (0.6 per cent × 138 million).

F. Established experimental asbestosis ceases to progress on discontinuance of dust exposure.

The experimental investigation shows, in fact, that on discontinuance of exposure there was an appreciable clearing of the mature pulmonary

Produced under Court Order in Hart v. Owens Corning Fiberglass, et al., USDC SD Miss. Confidential information, not to be copied, reproduced or distributed except in accordance with this Court's order.

08 006 1098

FORWALD ET AL.—STUDIES OF ASBESTOSIS 43

CLAIMED
PRIVILEGED
BY OCF

lesions, due to contraction of the fibrous tissue. In contrast, an immature tissue response, evidenced primarily by cells with little or no fibrosis, continued to progress. It is assumed that, following attainment of fibrotic maturity, the same process of contraction would ensue as was noted for the mature lesion.

G. The formation of asbestosis bodies represents a coating of the fibers by blood and tissue elements, which results in loss of ability of the fiber to produce fibrosis.

Intratracheal injection of asbestosis bodies failed to produce the typical asbestotic tissue reaction in experimental animals. The cessation of progressive reaction observed soon after exposure terminates may be due to the formation of asbestosis bodies.

H. Aluminum hydroxide failed to neutralize the fibrosing action of the long fiber asbestos.

Aluminum hydroxide added to the suspension of chrysotile asbestos prior to intratracheal injection did not retard or prevent the development of asbestosis in rats.

I. Inhalation of asbestos dust did not alter significantly the final outcome of experimental tuberculosis in two series of guinea pigs exposed to the dust.

The apparently mild influence of asbestos dust is in distinct contrast to the stimulating effect exerted by inhaled quartz on a tuberculous process in the lung. The interpretation must remain tentative, however, since it is based on an investigation limited to two series of guinea pigs exposed to only one kind of asbestos, namely, King's floats: Table 4 shows that when the infection was coincidental with the onset of dust exposure, there was temporary progression of the infectious process, with subsequent healing; when infection was initiated after 26 months of dust exposure, the course of the tuberculosis was not appreciably altered. The latter finding is quite different from our usual experience with quartz dust or with mixed dusts containing quartz, wherein the adverse influence of quartz on a tuberculous infection is manifested most strikingly when infection is initiated after a period of dust exposure, viz., superimposed on a background of established silicosis. As indicated above, this more sensitive test, when applied to asbestos dust, failed to demonstrate that the latter had an adverse influence on a tuberculous infection. The inability of asbestos dust in that experiment to affect unfavorably the tuberculous process furnishes strong support for the interpretation that inhaled asbestos dust has no more than a mildly unfavorable effect on pulmonary tuberculosis.

This investigation was made possible by the generous financial support of a group of companies of the asbestos industry.

Produced under Court Order in Hart v. Owens Corning Fiberglass, et al., USDC SD Miss: Confidential information, not to be copied, reproduced or distributed except in accordance with this Court's order.

08 006 1099

*** USE THIS COPY FOR REFERENCE ONLY***
USE THE EXHIBIT THAT IS LOOSE IN THE FOLDER
TO MAKE YOUR COPY

PLAINTIFF'S EXHIBIT 3970.0
PENGAD-Bayonne, N. J.

A
Archives of Industrial Hygiene and Occupational Medicine
VOLUME 3 JANUARY 1951 NUMBER 1

COPYRIGHT, 1951, BY THE AMERICAN MEDICAL ASSOCIATION

EXPERIMENTAL STUDIES OF ASBESTOSIS

ARTHUR J. VORWALD, Ph.D.(Path.), M.D.
THOMAS M. DURKAN
AND
PHILIP C. PRATT, M.D.
SARANAC LAKE, N. Y.

ASBESTOSIS is a form of pneumonoconiosis resulting from prolonged inhalation of asbestos dust. The name "asbestos," literally "unburnable," is not that of a specific mineral but is a term applied to a number of different minerals whose characteristic feature is a structure composed of long, parallel, flexible fibers. This structure is unique because the fibers are capable of repeated longitudinal subdivision to units of molecular proportions. In length the fibers vary from a few microns to 6 or more inches (15 or more cm.). Some varieties are stiffer than others, but many are sufficiently flexible to be spun into yarn and woven on modified textile machinery.

The asbestos minerals are silicates of variable composition and belong to the serpentine and the amphibole groups. Listed below are the more common varieties.

Amphibole group: actinolite, amosite, amphibole, anthophyilite, crocidolite and tremolite.

Serpentine group: chrysotile.

The bulk of the asbestos of commerce is chrysotile, $3MgO.2SiO_2.2H_2O$, which is mined on this continent principally in the Thetford region of the Province of Quebec, Canada, and in Vermont. Crocidolite and amosite also are used commercially but in much smaller amounts. Chrysotile occurs as veins in serpentine, a mineral of similar chemical composition, which exists in massive form and is made up of microscopic fibers without the parallel orientation characteristic of chrysotile. The massive, bluish black serpentine, which is smooth and soapy to the touch, is traversed by veins of fibrous chrysotile varying in width from a barely perceptible line to 6 (15 cm.) or more inches. The fibers run across the vein and not lengthwise with the formation.

From the Saranac Laboratory of the Edward L. Trudeau Foundation.

This series of studies of asbestosis, initiated at the Saranac Laboratory more than twenty years ago by the late Dr. Leroy U. Gardner, director of the laboratory, was nearly completed at the time of his death in October 1946. Although partial reports and informal reviews of some of the experiments had been given from time to time by Dr. Gardner, this paper presents for the first time a complete survey of the entire experimental investigation.

Attention is directed to the mineral brucite, $MgO.H_2O$, which is often found in the same formations with serpentine and chrysotile and may be fibrous in structure. Except for the manufacture of magnesium, brucite has no commercial value at present because its fibers are not sufficiently flexible to be used in textiles, but they are capable of repeated longitudinal subdivision. Unlike other asbestiform minerals, brucite is not a silicate, and for this reason it has been a valuable tool in an experimental evaluation of the action of fibrous minerals on lung tissue.

EXPERIMENTAL ASBESTOSIS

For many years studies[1] have been carried on at the Saranac Laboratory in an investigation of the cause, nature and development of asbestosis. The present paper is devoted to experimental asbestosis,



Fig. 1.—Human asbestosis (P-36-144). The photomicrograph reveals a bronchiole (right center) with a smooth muscle bundle at its inferior margin and with an extensive zone of collagen deposition largely obliterating the surrounding alveolar structure. The black foci are macrophages containing incidental pigment. Asbestosis bodies are present but are not apparent at this magnification (× 200).

and in it are described the experiments made on animals with various kinds of asbestos dust. Another report, to be prepared and issued at a future date, will be concerned with human asbestosis and will cover the health aspects of workers who have been exposed to asbestos dust in an industrial environment.

Although in man asbestosis is a chronic disease with diffuse pulmonary fibrosis which requires years to develop, it is possible to reproduce

1. (*a*) Gardner, L. U., and Cummings, D. E.: Studies on Experimental Pneumokoniosis: VI. Inhalation of Asbestos Dust; Its Effect upon Primary Tuberculous Infection, J. Indust. Hyg. **13**:65 and 97, 1931. (*b*) Gardner, L. U.: Chrysotile Asbestos as an Indicator of Subtile Differences in Animal Tissues, Am. Rev. Tubere. **45**:762, 1942.

in one or more species of animal characteristic tissue changes which are similar to the lesions of human asbestosis (fig. 1). Since the life span of the experimental animal is relatively short, it is not possible to produce the characteristic lesions in animals under conditions identical with the usual industrial environment. Consequently, to obtain a complete evaluation of the tissue response to inhaled particulate and fibrous material, it is necessary to accelerate the reaction by employing higher concentrations of dust than would ordinarily be encountered in industry. While conditions of exposure are thus different, the information yielded by animal experiments is invaluable in furnishing a better understanding of the reaction of the human organism to inhaled asbestos dust.

Experimental Methods

For investigating the tissue reactions of experimental animals to the various asbestos minerals, two types of technic have been employed, namely, the inhalation method and the injection method. In inhalation experiments, groups of animals—up to 100 or more guinea pigs and sometimes smaller numbers of rabbits, cats, dogs, rats or mice—are kept for eight hours a day in a cubical dust room, 8 ft. (2.5 M.) in dimension, in which a cloud of asbestos dust is maintained by a rotating paddle in a dust hopper.[4a] At intervals during the experiment a few animals are killed and the tissues examined to determine the nature and the extent of the dust reaction. Some animals are exposed for periods up to three years. The injection experiments are used to determine in as short a time as possible whether or not a particular dust has a potential capacity to produce inflammatory reaction when in direct contact with tissues of the body. The method involves injecting the dust, either dry or suspended in fluid, into the animal by the intravenous, the intraperitoneal, the intratracheal or another route.

Long term inhalation experiments furnish information on which great reliance is placed when estimating the degree to which a dust might constitute a respiratory hazard to industrial workers. Even though an atmospheric dust may be potentially dangerous, as indicated by injection experiments, only inhalation procedures will reveal whether the dust can be inhaled, pass the natural defense barriers of the body and reach the pulmonary tissue in quantities sufficient to cause damage. Injection methods are useful, however, because they make certain that contact occurs between the dust particles and tissues and because they allow accurate estimation of the dosage and of the potential capacity of that dose to produce reaction. The intratracheal method is particularly valuable when one is dealing with fibrous minerals like asbestos, since it permits observation of the effect of the fibers on pulmonary tissue.

Tissue Susceptibility

Unlike free silica, asbestos does not produce specific effects in all organs of all species of animals. The comparative data presented in table 1 are based on completed observations and therefore differ slightly from a preliminary report.[4b] Fine quartz introduced into various organs

of various animals (guinea pig, rabbit, rat, mouse, cat, dog, chicken and even tadpole) eventually will produce silicotic nodules but at different rates. Similar introduction of long fiber asbestos has resulted in a fibrous reaction in the lung and, to a lesser extent, in the peritoneum but not in other organs of the guinea pig, the rabbit, the cat and the white rat. In our experience the lungs of the dog and the white mouse failed to respond with fibrosis, although Schuster [2] has reported such changes in a dog that lived in an asbestos-fabricating plant. This variation in species and in organ susceptibility is yet to be accounted for [3]; it is presumed that in the susceptible animals the greater reaction of the lung to asbestos, far exceeding the reaction of other organ tissues, is due principally to the greater mobility of the lung.

Peculiar Characteristics of Asbestos

Experience has demonstrated that most of the nonfibrous dust particles inhaled into the lungs of man and animal are 10 microns or less

Table 1.—*Reaction to Long Fiber Chrysotile in Lungs of Man and Other Species of Animal*

Species	Mode of Exposure	Fibrosis *	Asbestosis Bodies
Man	Inhalation	4+	Numerous
Guinea pig	Inhalation and injection	2+	Moderately numerous
Rabbit	Inhalation and injection	+	Rare and atypical
Cat	Inhalation and injection	+	Rare and atypical
White rat	Inhalation and injection	−	Very rare
White mouse	Inhalation	0	Rare and atypical
Dog	Injection	0	None

* The symbols 0 to 4+ refer to the degree of tissue reaction.

in maximum dimension. Larger particles apparently do not gain access to the lungs, because, first, large particles settle in air so rapidly that few remain suspended in the atmosphere breathed and, second, large particles are more effectively removed by the protective mechanisms of the upper respiratory tract. In the case of fibrous materials these factors have less influence and fibers 100 and even 200 microns in length have been found in the terminal air spaces of human lungs. In small laboratory animals exposed to asbestos dust the maximum length of fiber found in the lung rarely exceeds 60 microns.

A large proportion of nonfibrous particulate dust inhaled into the lung is found in the terminal air spaces (alveolar ducts, atriums, alveoli) in all parts of the organ; in contrast, inhaled asbestos fibers are first discovered in the respiratory bronchioles. These small passages are immediately distal to bronchioles lined by ciliated epithelium.[4] Their

2. Schuster, N. H.: Pulmonary Asbestosis in a Dog, J. Path. & Bact. 34 (pt. 2):751, 1931.

3. Vorwald, A. J.: Variations in Individual Susceptibility to Industrial Dusts Inhaled into the Lungs, Am. Rev. Tuberc. 62: (IB) 13, 1950.

4. Miller, W. S.: The Lung, Springfield, Ill., Charles C Thomas, Publisher, 1937.

own essential lining is a low cuboidal type of epithelium but, as their name implies, they actually function in respiration through lateral alveoli distributed along their walls. Either these alveoli or the abrupt change in the character of the lining epithelium, or the small diameter of the respiratory bronchiole, or the combination of all three factors is responsible for retention of the fiber at this site. Only after asbestosis is well established are appreciable numbers of fibers seen in the more peripheral air spaces. Further explanation is required to clarify this observation.

Rate of Tissue Reaction to Asbestos Fibers

The affected tissues react much more rapidly to asbestos than to quartz dust. For example, in rats receiving asbestos fibers by intratracheal injection fibrosis of a characteristic type is visible as early as one month after injection; for quartz dust the latent period is two months or more. Thus, the development of nodular fibrosis due to inhaled silica lags behind the deposition of dust to a greater extent than does the evolution of the diffuse reaction to asbestos. This results in a difference in the degree of progression which follows termination of exposure to dust. For example, on discontinuance of exposure the nodules of silicosis become larger, to a limited extent, for a considerable period of time, whereas the fibrosis of asbestosis increases for only a short time. Subsequently, the asbestotic fibrous tissue contracts; this process often distorts the adjacent pulmonary tissue and may, as a result, progressively interfere with cardiorespiratory function.

Asbestosis Bodies

The peculiar structure known as the asbestosis body or "curious body" is a specific concomitant of asbestosis.[5] The typical body is a golden yellow, beaded or haustrated rod, which may be either straight or curved (fig. 2). Often one or both ends are bulbous like a dumbbell. The bodies vary considerably in length, and dimensions up to 250 microns have been recorded.

It is believed that asbestosis bodies are inhaled fibers on which protein and iron pigment of tissue origin have been deposited.[6] Gloyne [5b] observed reproduction of these bodies in guinea pigs nine months after subcutaneous injection of fibers rendered free of iron. The bodies are abundant in man and in the guinea pig (table 1) but are much larger in the former, probably because the larger-sized air passages admit fibers of greater dimension. In guinea pigs they form after about 70 days

5. Gloyne, S. R.: (*a*) The Formation of the Asbestosis Body in the Lung, Tubercle **12**:393, 1931; (*b*) The Asbestosis Body, Lancet **1**:1351, 1932. (*c*) Gardner and Cummings.[1a]

6. Lynch, K. M., and Smith, W. A.: Asbestosis Bodies in Sputum and Lung, J. A. M. A. **95**:659 (Aug. 30) 1930. Simson, F. W., and Strachan, A. S.: Asbestosis Bodies in the Sputum: A Study of Specimens from 50 Workers in an Asbestos Mill, J. Path. & Bact. **34**:1, 1931. Gardner and Cummings.[1a] Gardner.[1b] Gloyne.[5a, b]

of contact with the tissue. In cats, rabbits and mice a few of the fibers show an atypical coating after much longer residence in the lungs. In rats the bodies are rarely seen, and in dogs none could be found. Although the evidence is incomplete, it appears that the formation of the asbestosis body prevents the fiber from damaging the tissue. Many of the points mentioned above will be elaborated on in subsequent para-



Fig. 2.—*A*, human asbestosis bodies. This collection of asbestosis bodies was found in the lung shown in figure 1. The usual variations of size and configuration are represented (× 400).

B, guinea pig asbestosis body. This one is similar to some of those shown in *A* (× 400).

graphs dealing with the actual experiments. For presentation our investigation is divided into two sections, one dealing with inhalation experiments and the other with injection experiments.

INHALATION EXPERIMENTS

Four large scale inhalation experiments have been conducted in this laboratory with various forms of asbestos dust. In each of these investigations, more than 100 animals were used, and the experiments were carried on for periods ranging from two to more than five years. The four kinds of asbestos dust employed are designated as King's floats, short fiber, 100 per cent ball-milled, and long fiber asbestos dust.

King's Floats Asbestos Dust

The first inhalation experiment conducted at the Saranac Laboratory with asbestos dust was begun in 1928. Animals inhaled the dust for

TABLE 2.—*Chemical Analysis of Asbestos Dusting Materials*

Type of Asbestos	SiO_2	Fe_2O_3	Al_2O_3	Cr_2O_3	MnO	CaO	MgO	Na_2O	K_2O	CO_2	Ignition Loss	Total
King's floats.....	39.32	8.84		*	*	0.67	35.5-	*	*	*	12.74	97.13
Short fiber.....	37.17	9.09	1.40	0.14	0.09	0.85	35.96	0.14	0.20	0.09	14.09	100.11
Long fiber.....	38.40	5.22	0.76	*	0.06	0.21	40.15	0.06	0.06	0.57	14.00	99.76

* Not determined.

TABLE 3.—*Petrographic Analysis of Asbestos Dusting Materials*

King's floats *: The approximate composition, based on particles (except chrysotile) smaller than 10 microns and reported as percentages obtained from particle counts, was chrysotile 14, serpentine 40, magnetite 12, carbonates 15, talc 12, other minerals 4. For chrysotile, fibers up to 200 microns long were included.

Short fiber †: The material, before being ball milled, contained a preponderance of fibrous chrysotile and platy (nonfibrous) serpentine. The approximate composition, by percentage, was chrysotile 17, serpentine 55, magnetite 10, quartz 2, brucite 5, other minerals, including dolomite, actinolite and tremolite, 11.

Long fiber †: The material consisted principally of the fibrous asbestos mineral chrysotile. Shreds of nonseparated fibers 5 to 15 microns in diameter and up to 50 microns in length were present. The approximate composition, by percentage, was chrysotile 75, serpentine 15, magnetite 5, brucite 2, other minerals, among which were calcite and chloritic and micaceous minerals, 3. Only a trace of quartz was observed.

* The analysis of the King's floats asbestos, made by Dr. C. S. Hurlbut Jr., of Harvard University, has been reported elsewhere (Hurlbut, C. S., Jr., and Williams, C. R.: The Mineralogy of Asbestos Dust, J. Indust. Hyg. & Toxicol. 17: 292, 1935).

† For the short fiber asbestos and the long fiber asbestos the petrographic analysis was supplemented with x-ray diffraction examination.

periods up to 33 months. Some guinea pigs with six and nine months' exposure lived for an additional three years after cessation of their exposure. A preliminary report [18] presented observations after 29 months of exposure. At that time observations covered a period of only 2¼ years and the conclusions as to the ultimate effects of inhaled asbestos dust were provisional. Those conclusions are substantiated by results of the completed study, which is reported as follows.

Composition and Atmospheric Concentration of the Dust.—The dusting material, a commercial variety of asbestos known as King's floats, was composed of short fibers, ranging in length from 1 mm. to 1 micron or less, and of particles which also varied in size. It was obtained from the Thetford, Quebec, plant of the Asbestos Corporation of America, and analyses (tables 2 and 3) reveal that the amount of fibrous chrysotile was only 14 per cent, a rather low value.

Impinger samples taken soon after the experiment was started indicated that the dust concentration was at first quite low, the average dust count being only 6.0 million particles per cubic foot of air by the standard light field technic and 0.8 million for particles and fibers greater than 10 microns. After the inhalation experiment had been under way for about two years, the speed of the rotating paddle in the dusting machine was increased and for the remaining 10 months of the experiment considerably more dust was dispersed into the atmosphere. The average dust count of impinger samples collected after this change was 53.7 million by the usual light field method and 1.6 million for particles and fibers larger than 10 microns. It is probable, however, that the true values of the dust concentration were higher than the counts given in this paragraph. The impinger samples for the King's floats experiment were collected in water, but later studies[7] have shown that counts of impinger samples of asbestos dust taken in water are not reliable. Ethyl alcohol instead of water was used as the collecting fluid in all subsequent experiments.

TABLE 4.—*Summary of Inhalation Experiment with King's Floats Asbestos Dust*

Nature of Experiment	Animals	Maximum Dust Exposure, Mo.	Maximum Survival After Dust Exposure, Mo.	Results
Dust exposure continuous throughout life	54 guinea pigs	33	0	Typical peribronchiolar fibrosis after 18 months
	9 rabbits	19	0	Foreign body bronchitis
	18 rats	6	0	Little or no reaction
Dust exposure followed by prolonged residence in normal air	25 guinea pigs	6	55	Nonprogressive fibrosis
	25 guinea pigs	9	37	Nonprogressive fibrosis
	1 rabbit	6	30	Absorption of foreign body reaction
	1 rabbit	19	34	
"Tuberculous" infection * at start of dust exposure	60 guinea pigs	26	0	Temporary progression of infection, followed by healing with fibrosis
Controls to infection: no dust exposure	22 guinea pigs	0	33 †	Healing by resolution (one exception)
Tuberculous infection * after 25 mo. of dust exposure, then residence in normal air	12 guinea pigs	25	14	No appreciable increase in severity of tuberculous infection, healing with fibrosis
Controls to infection: no dust exposure	12 guinea pigs	0	19 †	Healing by resolution

* The guinea pigs were infected with low virulence R1 strain of tubercle bacillus.
† This means the survival period following infection.

Results of the investigation, briefly summarized in table 4, show that inhalation of King's floats asbestos dust produced a typical peribronchiolar fibrosis in guinea pigs but not in rabbits or rats.

Reaction in Normal Guinea Pigs.—Guinea pigs inhaling this dust for periods up to 33 months had a characteristic fibrosis occurring in conical patches about the respiratory bronchioles. During this exposure the peripheral alveoli were not involved. The particulate elements of the dust were transported through the lymphatic system to the bronchial nodes, causing no significant reaction in either site; the fibrous elements remained fixed at the points of original localization and were seldom detected in the lymph nodes.

After exposure of approximately a year a small amount of cellular reaction had been produced about many respiratory bronchioles (fig. 3*A*). As more dust was inhaled, it continued to accumulate in the same location, and later stages of the disease (fig. 3*B*) consisted of extensions of the original lesions.

Apparently, the inhaled fibers were caught in the pocket-like alveoli that are given off from the lateral walls of the respiratory bronchioles. There they

7. Fulton, W. B.; Houtz, R. L.; Dooley, A., and Mathews, J. L.: Asbestosis: I. The Collection and Counting of Asbestos Dust Encountered in Asbestos Fabricating Plants, Special Bulletin 37, Pennsylvania Department of Labor and Industry, Harrisburg, 1934.

were phagocytosed, and many of them were carried into the wall by migratory cells. Mononuclear leukocytes attracted to the area caused an appreciable thickening of the bronchiolar wall. After 16 months a delicate fibrosis made its appearance. The process evolved gradually, and the number of fine intercellular collagenous fibers steadily increased. As this fibrous deposit contracted, it partially closed and



Fig. 3.—King's Boats inhalation experiment: *A*, lung of a guinea pig with 12 months' exposure. It includes a respiratory bronchiole, at the left, branching and becoming an alveolar duct, at the right. Note the accumulation of cells in the wall of the bronchiole and in adjacent alveoli (× 130). *B*, lung of a guinea pig with 28 months' exposure. The field includes a bronchiole, at the center, with peribronchial fibrosis extending into the walls of adjacent alveoli. Note the cuboidal epithelium lining these alveoli. This is the so-called "adenomatoid" appearance (× 200).

distorted the alveoli, and with this change the alveoli became lined with cuboidal cells. The result was an adenoma-like appearance which frequently accompanies

Asbestosis bodies (fig. 2*B*), first seen in the lungs of the guinea pigs that had inhaled dust for about two months, became more numerous and more distinctly segmented with increasing exposure.

The reaction produced in guinea pigs exposed for six and nine months did not progress significantly during a subsequent period of 35 and 37 months when the animals lived in a normal atmosphere (fig. 4). Between eight and 11 months after exposure ceased, the cellular reaction in the lung had been completely replaced by thin strands of fibrous tissue. At later periods the scar tissue was less in amount, but in the last animal killed, 37 months after discontinuing dust exposure, some fibrosis was still visible.

Reaction in Guinea Pigs Infected with Tubercle Bacilli at the Onset of Dust Inhalation.—Of the group of 40 guinea pigs infected with attenuated tubercle bacilli, R_1 strain,[9] at the time that dust exposure was begun, 31 died or were killed before the completion of two years of the exposure and were reported in the paper by Gardner and Cummings.[1a] Seventeen of these died from intercurrent pneumonia. Briefly, the results were as follows: Ten revealed some evidence of spread of the tuberculous process (fig. 5*A*); in 6 of these it was confined to the lungs, and in the other 4 the abdominal viscera also were involved. Extension of the infection was first seen after seven months of dust inhalation; during the next 20 months more than half of the animals showed actively spreading tuberculosis, and in 3 of them small cavities had developed. During the last eight months no animals exhibited any evidence of active infection although in half of them the healed fibrous scars of previous spreads were obvious. The scars were more extensive than is characteristic of either tuberculosis or asbestosis alone.

The nine animals which were still alive after two years of dust exposure were killed at intervals during the following year. In four of them the primary foci of infection were healed with fibrosis and even calcification, and there was no evidence of progression (fig. 5*B*). In the remaining five the tuberculous foci showed evidence of having previously spread locally; in four of them, by the time of autopsy, the foci were healed, with excessive fibrosis; in the fifth animal there was a generalized chronic tuberculous pneumonia in one lobe, and in the other lobes there were isolated primary tubercles, which were still active but had not spread.

Reaction in Guinea Pigs Infected with Tubercle Bacilli After Establishment of Asbestosis.—Twelve guinea pigs, after inhaling King's floats asbestos dust for 26 months, were infected with tubercle bacilli and then removed to normal air. Six of these animals died within seven weeks, five from intercurrent nontuberculous infection. The remaining six animals were killed at intervals up to 14 months after infection. The subpleural tubercles were no more numerous in the dusted animals than in the nondusted controls, but a considerable number were found in the depths of the lung about foci of asbestosis. The tuberculous component of the combined reaction showed only slight local extension about lesions in the lungs and tracheobronchial lymph nodes. Caseation was found in tubercles 1½ months old, but by 5½ months it had completely disappeared, leaving only scar tissue. Foci of fibrosis still persisted in the last animal, which was killed 14 months after infection.

Reaction in Rabbits.—Rabbits exposed to the asbestos dust for periods up to 19 months showed a foreign body type of reaction of low grade, but no fibrosis. Although their lungs contained particulate elements of the dust, fibers were not present, indicating that the upper respiratory mechanism of the rabbit is adequate to exclude fibrous foreign bodies. Two rabbits, after inhaling dust for six and 19

9. Steenken, W., Jr., and Gardner, L. U.: R_1 Strain of Tubercle Bacillus: Its Dissociation and Virulence of Variants in Normal and Silicotic Guinea Pigs, Am. Rev. Tuberc. 54:51, 1946.

months, lived in normal air for more than two years. At autopsy neither animal showed any evidence of cellular reaction or fibrosis in the terminal bronchioles, nor were there any asbestosis bodies.

Reaction in White Rats.—All the rats had acquired an infection, resulting in the formation of pulmonary abscesses, before they came to autopsy. Apparently, so much heavy mucus obstructed their bronchi that very few fibers could have entered



Fig. 5.—King's float inhalation experiment: *A*, lung of guinea pig infected with R_1 tubercle bacilli and then exposed to dust for 24 months. A bronchiole is shown just above center. Surrounding it is some collagen deposition, together with typical epithelioid cell infiltration of the wall. Note the lack of encapsulation and the peripheral epithelioid cell pneumonia, which illustrate a spreading tuberculous process (× 200).

B, lung of a guinea pig infected with R_1 tubercle bacilli and then exposed to dust for 33 months. Note the subpleural distinctly encapsulated caseous focus, the calcification at the right border of the lesion and the absence of cells in adjacent alveoli, all of which illustrate a healing tuberculous process (× 200).

their lungs. In a few of the rats, an occasional asbestosis body was discovered, but there was no fibrosis. This phase of the experiment was considered unsuccessful.

Summary and Interpretation of Inhalation Experiment with King's Floats Dust.—The findings in the experiment with King's floats dust can be summarized under two headings:

1. Effect of the inhaled dust on normal animals. The King's floats dust caused a characteristic peribronchiolar fibrosis in guinea pigs but not in rabbits or rats. The fibrosis did not increase significantly in extent after the dust exposure was discontinued.

2. Effect of the inhaled dust on tuberculosis in guinea pigs. In guinea pigs infected with attenuated tubercle bacilli and then placed in the dust room, the results were more variable than is usual in an experiment of this type. A few animals showed no sign of progression of the infection; in most of them there was evidence of temporary progression with subsequent healing; in one animal the tuberculous process remained active to death. In contrast, when guinea pigs after being infected are exposed to quartz dust instead of asbestos dust, the infectious process continues to progress and eventually causes the death of the animals. On the other hand, infected animals exposed to a harmless dust like iron oxide do not show any progression of the infection.[10] Guinea pigs infected with attenuated tubercle bacilli after the termination of two years' asbestos dust exposure did not show progressive disease. The only modification of the infection was in its localization, a few bacilli being retained in the peribronchiolar fibrous tissue, with tubercles forming there in addition to the usual tubercles beneath the pleura.

In view of the variability of the results, the unusual nature of the response and the high proportion of deaths due to intercurrent pneumonia, it is felt that only tentative conclusions as to the influence of asbestos dust on the course of tuberculous infection are justified by this experiment.

Short Fiber Asbestos Dust

Since hazardous dusts like quartz are most effective in producing fibrosis when the particles are 3 microns and less in size, an inhalation experiment was performed to determine whether this condition is true for asbestos dust. It was thought that a short fiber asbestos dust consisting almost entirely of fibers and particles smaller than 3 microns would initiate an accelerated tissue response and produce an advanced reaction in a shorter time than did the King's floats dust, which contained fibers from 1 mm. to 1 micron and less in length as well as much particulate matter.

Composition and Atmospheric Concentration of the Dust.—The dusting material for this experiment was the remains of fibers collected in dust bins of an asbestos-fabricating plant after a carding operation and screened to pass 200 mesh. Since

10. Vorwald, A. J.; Pratt, P. C.; Durkan, T. M.; Delahant, A. B., and Bailey, D. A.: Siderosis: A Benign Pneumoconiosis Due to the Inhalation of Iron Dust, Indust. Med. & Surg. **19**:170, 1950.

the material as received contained many long fibers, it was ground in a steel ball mill to reduce practically all the particles to 3 microns or less in size. When used alone in the standard dusting machine, this finely ground asbestos tended to pack in the hopper, and it became necessary to mix one volume of the unground material with three volumes of the ground to generate a satisfactory dust cloud. It is pertinent to mention here that the addition of the small quantity of unground asbestos was unfortunate, because it confused the interpretation of results.

The composition of the short fiber asbestos as received is disclosed by the chemical and petrographic analyses given in tables 2 and 3. Samples taken before and after grinding yielded about the same values on analysis, indicating that there was no contamination from the mill or loss of water content.

The dust concentration varied during the experiment, the light field counts for atmospheric samples collected inside the animal cages with the impinger apparatus ranging from 83 million to 182 million. The average of counts was 130 million for the first year of the experiment, 134 million for the second year and 140 million for the third year.

Size-frequency measurements of air-floated dust from inside the cages at a magnification of 1,300 × revealed a great preponderance of fine particles, nearly

TABLE 5.—*Summary of Inhalation Experiment with Short Fiber Asbestos Dust*

Nature of Experiment	Animals	Maximum Dust Exposure, Mo.	Maximum Survival After Dust Exposure, Mo.	Results
Dust exposure continuous throughout life	46 guinea pigs	34	0	Rate of reaction about the same as in experiment with King's floats asbestos but extent of involvement very much less †
	73 rats	32	0	Characteristic patches of peribronchiolar fibrosis; no asbestosis bodies
	18 cats	54 *	0	Subpleural reaction only
	7 rabbits	47 *	0	No fibrosis seen grossly; microscopic evidence of alveolar wall thickening after [illegible] months' exposure
Dust exposure followed by prolonged residence in normal air	13 guinea pigs	20	14	Progression after removal from dust doubtful—neither clearly established nor definitely excluded
	2 cats	31	24	Same as for continuous exposure
	1 rabbit	62 *	6	Similar to continuous exposure; evidence of slight regression

* After 32 months the animals were exposed to 100 per cent ball-milled asbestos.
† The reaction was probably due to long fibers in the unground material which was mixed with the ground asbestos dust to produce a satisfactory dust cloud.

90 per cent of the particles seen being smaller than 3 microns. It was estimated that approximately 1 per cent of the dust was in the form of fibers greater than 10 microns in length.

Four species of animals—guinea pigs, white rats, cats and rabbits—were used in this experiment. The results of the dust exposure, summarized in table 5, are presented in greater detail below.

Reaction in Guinea Pigs.—Eighty guinea pigs were originally placed in the dust room, but 21 of them were later eliminated from the experiment and killed because of enlargement of the cervical lymph nodes thought to be due to intercurrent infection of the upper respiratory tract. Of the other 59 animals, 46 remained in the dust room until they were killed or died at periods up to 34 months, and 13 animals were transferred to normal air after being exposed to the dust for 20 months.

The type of tissue reaction provoked by the inhaled short fiber asbestos was essentially the same as that already observed in the experiment with King's floats asbestos. The rate of reaction also was approximately the same, but the extent of involvement was very much less. After 16 to 24 months of exposure only a very few small foci of reaction, which generally required microscopic examination for detection, had been produced in the guinea pigs.

Only after exposures had continued for approximately one year was there an appreciable tendency for dust-containing phagocytes to gather into clumps. By 16 months phagocytes had collected about the walls of a few of the respiratory bronchioles which revealed a little proliferation or infiltration of mononuclear cells. There were also some multinucleated cells, but they were of the inert, foreign body type. At 20 to 24 months the cellular clumps were sometimes quite prominent, and sometimes changes in the epithelium resulted in the adenoma-like or "adenomatoid" appearance (fig. 3 *B*) previously described in the section reviewing the experiment with the King's floats dust. In most of the subsequent members of the series the reaction remained cellular, but a few exhibited pronounced development of fibrous tissue. In these few members of the series the collagen was pale in color and tenuous, with no appearance of being hyalinized. Diffuse chronic pleurisy was present in a few animals without evidence of pul-

TABLE 6.—*Analyses of Lungs of Guinea Pigs After Prolonged Inhalation of Short Fiber Asbestos Dust*

Exposure to Dust, Mo.	Period in Normal Air, Mo.	Amount of Ash, % of Dried Lung	Total SiO_2, % of Dried Lung	Total SiO_2, % of Ash	Tissue Reaction *
Dust Exposure Continuous During Life					
12	0	5.02	0.51	10.21	
		4.58	0.46	10.08	
		5.16	0.54	10.54	±
15	0	5.00	0.49	9.90	
		4.79	0.43	9.00	
		4.95	0.53	10.80	±
20	0	5.95	0.85	14.46	
		6.45	0.90	14.07	2+
24	0	5.42	0.78	14.46	
		5.50	0.78	14.20	3+
30	0	5.22	0.96	17.99	
		6.53	1.27	19.48	4+
34	0	6.66	0.75	12.37	
		6.85	0.96	15.11	4+
Dust Exposure Followed by Prolonged Residence in Normal Air					
20	4	5.16	0.48	9.30	
		5.11	0.36	7.10	2+
20	10	6.11	0.62	10.21	
		6.26	0.34	5.51	3+
20	14	4.77	0.25	5.21	
		5.15	0.25	5.00	
		4.77	0.22	4.60	2+

* The symbols averaging the tissue reaction in each group of guinea pigs represent merely the relative degree of reaction, ranging from ± (questionable) to 4+ (the maximum for this experiment). The relationships apply only within this table and cannot be compared with symbols in other tables.

monary infection. This suggests that pleurisy may be a specific concomitant of asbestosis, but the evidence is not adequate to establish this point. The reaction of the tracheobronchial lymph nodes was more pronounced than in the previous experiment with King's floats asbestos, probably because more fine particles had been transported to the nodes in animals inhaling short fiber asbestos. The nodal reaction was essentially an increase in reticulum, rather than a fibrosis, with the *original cells being preserved between the thickened reticular fibers.*

In the group removed to normal air after 20 months' inhalation of dust, progression of disease was not definitely demonstrated, but neither could it be absolutely disproved, owing to the variability of the response in different animals. The reactions, from mild to severe, occurred sporadically and bore no relationship to the length of time after cessation of exposure. The differences were attributed to variation in individual susceptibility. This view received support from the chemical analyses (table 6), which revealed comparable amounts of ash and silica in lungs with widely different amounts of tissue change. For example, the ash

and silica values were quite similar for three animals living in dust 20 months and then in normal air for 14 months, yet the tissue reaction was severe in one animal, mild in another and only doubtful in the third.

The formation of asbestosis bodies was at first extremely limited in both groups. After five months' exposure only a very rare short body could be found, usually inside a cell. Some of the finest intracellular particles were surrounded by yellow deposits having the same color as the asbestosis body. One year's exposure had permitted an accumulation of many longer fibers, a number of which were coated and seen as typical asbestosis bodies. Most of these were still short enough to be partially or entirely within phagocytic cells. By the twentieth month and thereafter they

TABLE 7.—*Analyses of Lungs of White Rats That Had Inhaled Short Fiber Asbestos Dust*

Duration of Exposure, Mo.	Amt. of Ash, % of Dried Lung	Total SiO_2, % of Dried Lung	Total SiO_2, % of Ash	Duration of Exposure, Mo.	Amt. of Ash, % of Dried Lung	Total SiO_2, % of Dried Lung	Total SiO_2, % of Ash
0*	3.9	0.00	0.0	6	3.3	0.07	2.1
	4.3	0.00	0.0		3.4	0.05	1.5
	2.9	0.00	0.0		3.7	0.04	1.1
	3.6	0.00	0.0				
	3.3	0.00	0.0				
	3.9	0.00	0.0		3.9	0.06	2.2
	3.4	0.00	0.0		3.6	0.19	5.5
2	3.5	0.08	2.1	8	3.5	0.15	3.4
	3.6	0.13	3.5		4.4	0.17	4.9
	2.9	0.09	3.2		3.7	0.16	4.2
	3.2	0.06	1.5				
4	3.3	0.08	2.3	10	4.0	0.15	3.8
	3.6	0.11	3.0		4.6	0.15	3.3
	3.4	0.07	2.2		5.3	0.15	2.8
					4.7	0.13	2.9

* Normal controls (no dust exposure).

TABLE 8.—*Average Values of Ash and Total Silica for Lungs of White Rats Inhaling Various Dusts for Various Periods (Lungs Only, Without Included Lymph Nodes)*

Duration of Exposure, Mo.	Amt. of Ash, % of Dried Lung				Total SiO_2, % of Dried Lung				Total SiO_2, % of Ash			
	Short Fiber Asbestos	Quartz	Ferruginous Chert	Gypsum-Quartz Mixture	Short Fiber Asbestos	Quartz	Ferruginous Chert	Gypsum-Quartz Mixture	Short Fiber Asbestos	Quartz	Ferruginous Chert	Gypsum-Quartz Mixture
2	3.3	4.3	5.9	2.9	0.09	0.51	0.25	0.09	2.6	11.7	3.9	2.6
4	3.4	4.5	5.9	3.3	0.09	0.51	0.22	0.07	2.5	11.4	3.6	2.9
6	3.5	7.1	9.9	3.4	0.06	2.94	3.45	0.11	1.6	41.5	34.4	3.4
8	3.3	4.6	9.0	3.6	0.15	1.44	2.49	0.32	3.9	29.4	28.5	9.1
10	4.9	7.3	14.1	4.1	0.15	4.49	6.09	0.25	3.2	56.9	43.2	6.7

were relatively numerous although still rare in comparison with the findings in the King's floats experiment.

Reaction in White Rats.—Seventy-three white rats were exposed to atmospheric short fiber asbestos dust for periods up to 32 months. During the first 10 months animals were killed bimonthly and for the remainder of the experiment at less frequent intervals. Up to eight months the dust cells were widely scattered and existed in foci only sporadically. Reaction was limited to occasional slight thickening of the septums about small accumulations of dust cells. At 10 months there was a suggestion of early fibrosis in a few rats, but the change was so slight that it would probably have been overlooked without the clump of dust cells which attracted attention to the area. Only 10 animals were exposed for from 12 to 32 months. In each of them the lungs contained minute foci of well defined fibrosis distributed like that of asbestosis but without asbestosis bodies. The lesions, visible only at a magnification of 150 diameters or more, consisted of patches along

alveolar ducts in which the walls of the associated air spaces were very thick, owing to swollen collagen framework. Connective tissue and Foot-Bielschowsky silver preparations revealed complete loss of capillary bed locally. Outside the collagen was a thin layer of epithelial cells. This did not resemble the "adenomatoid" change characteristic of guinea pig asbestosis. Near the lesions the air spaces were filled with phagocytes containing gray to yellow particulate dust and a rare, long, naked asbestos fiber. Careful search failed to reveal even a suggestion of an asbestosis body. Pleurisy was absent. The tracheobronchial nodes showed compact focal collections of monocytic cells at 12 months and, at 20 months, some diffuse thickening of the reticulum. In a few rats there was definite fibrosis along the margins of the node, extending into the mediastinal areolar tissue.

Results of chemical analyses made on the white rats are given in table 7, and the average values have been recorded in table 8 for comparison with similar values for rats inhaling other dusts. It will be noted that the values for asbestos are lower than those for quartz or chert but approximate those for the gypsum-quartz mixture, in which atmospheric agglutination tended to reduce the amount of dust inhaled. This condition prevailed even though the atmospheric concentration of asbestos dust was essentially the same as that of the quartz, was one-half that of the gypsum-quartz mixture and was one-fifth that of the ferruginous chert. Since the values for asbestos are low, it might be inferred that the total quantity of that dust actually inhaled was small or that it had been eliminated from or dissolved within the lungs. Evaluation of these possibilities is not feasible on the basis of the observations derived from this study.

Reaction in Cats.—Twenty cats were used in this inhalation experiment with the short fiber asbestos. Eighteen were kept in the dust room continuously until put to death, the exposure period ranging from one month to nearly 54 months. The other two were removed to normal air after a dust exposure of 31 months; one of these was killed five months, and the other 24 months, later. In general, the tissue response was confined to microscopic foci of fibrosis, which were in the walls of groups of subpleural alveoli rather than in the peribronchiolar areas. In one animal the change was extensive enough to be visualized on gross inspection of the section. Only in the animal with the longest exposure—54 months—did the roentgenogram reveal definitely abnormal shadows. A roentgenogram made after 30 months revealed no abnormality; after 45 months, a faint mottling could be detected throughout both lungs. At autopsy, nine months later, there was only microscopic fibrosis in the subpleural zone plus heavy lymphocytic infiltration about small bronchioles. Asbestosis bodies were rare. On prolonged search a few yellow atypical bodies, smooth and without haustrations, were found in two animals exposed for more than a year.

Reaction in Rabbits.—Eight rabbits were exposed to dust for periods extending from one to more than five years; the last animal was removed from the dust room and left in normal air six months before being killed. There was never enough pulmonary fibrosis to be detected grossly, and there was no chronic adhesive pleurisy. Microscopic evidence of alveolar wall thickening was first detected in one animal after about three years of exposure and was seen in all five animals examined thereafter, including the one removed to normal air. One animal that died of paralysis after nearly four years of exposure exhibited a reaction visible on gross inspection of tissue sections. The possibility of pulmonary infection in this animal could not be excluded. In another animal dying two years later the focal fibrosis was not nearly as obvious or as advanced. Areas of involvement, which were largely visualized because of phagocytic reaction within the air spaces, tended microscopically to become more fibrous with the passage of time, but there was never much encroachment on the lumen of air spaces and the structure of the lung was preserved. Asbestosis bodies were not detected in rabbits that died early in the experiment but were seen in all animals that had been exposed to the dust for more than three years.

Summary and Interpretation of Inhalation Experiment with Short Fiber Asbestos Dust.—The original purpose of the experiment was to evaluate the role of short asbestos fibers in the genesis of asbestosis. It was felt also that if the tissues reacted more rapidly and more extensively to short fiber asbestos than to King's floats there would be a basis for believing that the action of asbestos is in part, at least, a chemical one as postulated for quartz. This experiment, in which the tissue reaction was slower and less extensive than that in the previous experiment with King's floats dust, indicates that the capacity of inhaled asbestos fibers to produce fibrosis is determined primarily by factors not chemical in nature.

Of the four species exposed in this experiment, only the guinea pig and to a lesser extent the white rat responded with characteristic peribronchiolar fibrosis. The cat reacted with atypical subpleural fibrosis and the rabbit with only slight parenchymal fibrosis.

Ball-Milled Asbestos Dust

In the inhalation experiment with short fiber asbestos dust a small quantity of unground short fiber asbestos was mixed with the ball-milled product in order to generate a suitable dust cloud. When that experiment failed to produce an accelerated tissue reaction, in comparison with the response initiated by King's floats, it became apparent that the biologic activity of asbestos is not increased by a reduction of fiber size. Thus the possibility arose that the tissue reaction observed was due solely to the relatively few long fibers of the unground asbestos and that the short fibers of asbestos had no more than a very insignificant role in the production of asbestosis, a concept not in accord with previous experiments concerning pneumonoconiosis. Consequently another inhalation experiment was started in which only ball-milled asbestos was used.

Composition and Atmospheric Concentration of the Dust.—The dusting material was the ball-milled, short fiber asbestos used in the previous inhalation experiment, but unground material was not mixed with it. Owing to the tendency of the material to form small spherules which prevented much of the fibrous portion from floating out of the dusting machine, the dispersal of the dust was not entirely satisfactory. Therefore, after an initial seven months of operation, steel wire brushes were attached to the inside surface of the hopper and to the rotating paddle to disintegrate the spherules and release the fibers. This arrangement gave satisfactory results and was used for the remaining 21 months of the experiment.

The composition of the raw asbestos used is shown in tables 2 and 3. Petrographic and x-ray diffraction examination of atmospheric dust, collected in the dust room with an electrostatic precipitator after the installation of wire brushes, indicated that about 15 per cent of the air-suspended material was chrysotile, and about 60 per cent, serpentine; of the balance, magnetite comprised 10 per cent, brucite 3 per cent, quartz 2 per cent and other minerals 10 per cent. During the seven month period before the wire brushes were used, the chrysotile content of the atmospheric dust was somewhat lower than 15 per cent, but reliable values were not obtained.

The dust concentration during the first seven months of the experiment was about 100 million particles per cubic foot of air. After the wire brushes were

installed, the dust counts were higher, and the over-all average for the remaining 21 months was about 150 million.

Size-frequency studies of atmospheric dust collected inside the animal cages revealed that nearly 99 per cent of the components suspended in the air could be classified as clumps or particles; only about 1 to 1.5 per cent was fibers. One third to one half of the fibers were longer than 10 microns, indicating a concentration of long fibers of about 0.8 million. This figure is about one-half the estimated value of 1.4 million for the short fiber experiment.

Guinea pigs, rats and mice were used in the inhalation experiment with the 100 per cent ball-milled asbestos dust. The results are summarized in table 9.

Reaction in Guinea Pigs.—The experiment was started with 101 guinea pigs. As the dust exposure proceeded, there were 39 accidental deaths, 32 of these being due to pneumonia in an epidemic. The 61 pigs remaining exposed to the dust were killed at intervals during exposure, except for 16 guinea pigs transferred to normal air after 28 months of dusting. For the first year of exposure practically the only reaction to the dust was the presence of scattered phagocytes and an occasional minute asbestosis body. At 16 and 20 months no gross response was visible on the tissue section, but microscopically peribronchiolar foci of inflammatory cells

TABLE 9.—*Summary of Inhalation Experiment with 100 per Cent Ball-Milled Asbestos Dust*

Nature of Experiment	Animals	Maximum Dust Exposure, Mo.	Maximum Survival After Dust Exposure, Mo.	Results
Dust exposure continuous throughout life	84 guinea pigs	24	0	No appreciable pulmonary reaction
	40 rats	30	0	No suggestion of asbestosis
	24 mice	12	0	No suggestion of asbestosis
Dust exposure followed by prolonged residence in normal air	16 guinea pigs	28	12	Fibrosis typical of asbestosis was present 12 mo. after exposure ceased in an amount sufficient to be visible grossly; smaller foci could be seen microscopically at 2 mo. and 8 mo. after termination of exposure

could be seen. At 24 months (fig. 6*A*) there was still no change large enough to be seen with a hand lens, although microscopic examination revealed cellular accumulations about terminal bronchioles and many more asbestosis bodies, chiefly within cells. The lungs of animals exposed for the full dusting period of 28 months and afterward living in normal air for two months revealed the changes described above and also very slight peribronchiolar fibrosis. For exposed animals living eight months in normal air the findings were similar, but at 12 months three of four animals showed grossly visible characteristic peribronchiolar fibrosis with adenomatoid change (fig. 6*B*).

The tracheobronchial nodes were essentially normal until exposure had been continued for more than a year and a half. Animals killed at 12 months and at 16 months revealed a few minute collections of phagocytes containing particles but practically no fibers large enough to be recognized as such. After 20 months of exposure many monocytes filled with yellow granules were present. At 30 months there had been a slight increase in reticulum but no fibrosis. No further changes occurred in the nodes. Asbestosis bodies were not seen in the nodes of any of the guinea pigs.

Minute asbestosis bodies were observed in the lungs as early as three months after exposure began, but they did not become numerous until 16 months had elapsed. The bodies were short and practically all were intracellular, although at 20 months some were long enough to project beyond the cell borders. It is

important to note that in the later months of exposure there was a distinct increase in the number of long fibers, up to 70 microns in length, in the lungs with the formation of characteristic long asbestosis bodies.

Chemical analyses (table 10) of the lungs revealed that considerable dust had been retained in the lungs. After 24 months of continuous exposure the average



Fig. 6.—Ball-milled asbestos inhalation experiment: *A*, lung of a guinea pig with 24 months' dust exposure. A bronchiole is shown at the center, with a slight accumulation of phagocytic cells but without the formation of collagen (× 200).

B, lung of a guinea pig with 28 months' dust exposure and then 12 months' inhalation of normal air. The reaction is much like that shown in *A*, but there is a slight deposition of collagen, most apparent at the left (× 200).

value for total silica, per cent of ash, was 25.37. This should be contrasted with the average value of 14.34 (table 6) for animals exposed 24 months to the short fiber asbestos dust.

In view of the high values for silica obtained with the animals exposed to 100 per cent ball-milled dust, it is important to note that their pulmonary response was much less than that of animals exposed for 24 months to the short fiber asbestos in the previous experiment. This again indicates that the biologic activity of asbestos inhaled into the lung is not increased by a reduction in size of the fibers.

Reaction in White Rats and Mice.—In this experiment 40 rats were exposed for periods up to 20 months and 24 mice for periods up to 12 months. In neither species did even a suggestion of asbestosis develop, and reaction was limited to phagocytosis of inhaled particles by widely scattered dust cells which remained free in air spaces or were transported to the tracheobronchial lymph nodes. No asbestosis bodies were found in the rats, but in the mice there were a very few small, nonhaustrated forms within phagocytes.

TABLE 10.—*Analyses of Lungs of Guinea Pigs Exposed to Dust in Inhalation Experiment with 100 per Cent Ball-Milled Asbestos Dust*

Exposure to Dust, Mo.	Period in Normal Air, Mo.	Amt. of Ash, % of Dried Lung	Total SiO_2, % of Dried Lung	Total SiO_2, % of Ash	Tissue Reaction *
Dust Exposure Continuous During Life					
1	0	4.55	0.21	4.29	
		4.30	0.30	7.05	
		4.35	0.24	5.60	0
2	0	4.66	0.23	4.90	
		4.60	0.34	7.40	
		5.05	0.61	12.01	0
3	0	5.60	0.70	12.47	
		5.07	0.32	6.38	
		5.74	0.56	9.77	0
5	0	5.10	0.38	7.51	
		5.06	0.35	7.47	
		5.02	0.39	7.72	0
8	0	4.25	0.52	11.96	0
12	0	5.65	1.25	22.16	
		6.24	1.45	23.23	0
16	0	5.40	1.02	18.98	
		5.01	1.11	21.95	±
20	0	5.05	1.08	21.40	
		5.20	1.28	24.61	±
24	0	6.30	1.55	24.06	
		5.56	1.21	21.70	±
Dust Exposure Followed by Prolonged Residence in Normal Air					
23	2	7.25	1.57	21.63	
		8.67	2.19	25.24	+
23	8	5.25	0.68	12.99	
		5.96	0.87	14.55	+
25	12	6.29	0.84	13.08	
		6.17	0.64	12.41	2+

* The symbols averaging the tissue reaction in each group represent merely the relative degree of reaction, ranging from 0 to ± (questionable) to 2+ (the maximum observed in this experiment). The relationships apply only within this table and cannot be compared with symbols in other tables.

Summary and Interpretation of Inhalation Experiment with 100 per Cent Ball-Milled Asbestos Dust.—The tissue reaction observed in this experiment was not as intense as that in the previous investigation with short fiber asbestos. The reaction was slower in development and less extensive even though more dust accumulated in the lungs. Since there were fewer fibers longer than 3 microns in the material used in this experiment, the results tend to confirm the interpretation made in the summary of the previous short fiber experiment that the reaction is not primarily chemical in nature, and to support the impression that reduction in size of asbestos fibers does not increase the biologic activity of asbestos inhaled into the lung.

The finding of long asbestosis bodies in animals that had inhaled the ball-milled material is an example of the difficulty of completely eliminating long fibers from a large volume of asbestos as required for an inhalation experiment.

In regard to the progression of the tissue reaction after the animals had been removed from the dust, observed in this experiment but not in the others, the following interpretation is offered: When the reaction is well developed at the termination of exposure, the contraction of the fibrous tissue obscures any progression that may have occurred; in this experiment, however, since the reaction observed was less mature, its subsequent progress was more readily apparent.

Long Fiber Asbestos Dust

Since inhalation of short fiber and of 100 per cent ball-milled asbestos dust did not result in acceleration of the tissue reaction in comparison with that produced by King's floats, the hypothesis that short fibers of asbestos were of minor importance in the etiology of asbestosis was given added support, and attention was directed to the view that the long fibers were of primary significance in that etiology. The King's floats asbestos used in the first inhalation experiment had a rather low content of fibrous chrysotile and contained considerable serpentine and other impurities. Therefore, it was decided to conduct a new inhalation experiment with a purer form of chrysotile which would be richer in long fibers.

Composition and Atmospheric Concentration of the Dust.—The dusting material employed in this investigation was obtained from an asbestos fabricating plant. Samples of several varieties of long fiber asbestos dust were first submitted to the Saranac Laboratory for examination, and one of these, which was low in magnetite and chromite and had a fibrous content estimated to be about 75 per cent, was selected as most suitable. Steel wire brushes, fastened to the inside surface of the hopper and to the rotating paddle as in the preceding inhalation experiment, were used to open up the bundles of asbestos and liberate more fibers into the atmosphere.

The composition of the long fiber asbestos used is indicated by the chemical and petrographic analyses given in tables 2 and 3. Analysis of air-suspended material from the dust room disclosed that about 60 per cent of the long fiber dust was chrysotile and about 20 per cent serpentine; as already noted, the composition of a similar air-floated sample of ball-milled, short fiber dust was 15 per cent chrysotile and 60 per cent serpentine.

The dust concentration as revealed by impinger samples taken inside the animal cages was much lower than the concentration for the experiments with short fiber or ball-milled dust. For the first year of the experiment with long fiber asbestos the average of the light field counts was 32 million particles per cubic foot of air; for the second year, 48 million; for the third year, 39 million, and for the fourth year, 43 million.

The size-frequency of atmospheric samples of the long fiber asbestos dust and of the ball-milled dust is shown in table 11. Both samples were collected with the electrostatic precipitator. It will be noted that there was far more fibrous material in the long fiber dust.

Guinea pigs, cats, rats and mice were employed in this inhalation experiment. The results, summarized in table 12, are described in greater detail below.

Reaction in Guinea Pigs.—The experiment was started with 100 guinea pigs. After exposure had been carried on for a year, a severe epidemic of pneumonia arose in the dust room and about one third of the animals died or were killed. To replace them, 38 more guinea pigs were added to the surviving group. Histological examination revealed lesions in the lungs after eight months of dust exposure, consisting of cellular connective tissue about the terminal bronchioles (fig. 7 *A*). At 12 months there were adenomatoid changes in the adjacent parenchymal areas, and by the sixteenth month (fig. 7 *B*) definite fibrosis was present in these areas as well as around the bronchioles. The fibrous lesion could be seen macroscopically at 20 months. From this time on the reaction increased in extent and in the amount of collagen, and by the thirty-fourth month, it had fanned out

TABLE 11.—*Size-Frequency of Atmospheric Long Fiber and 100 per Cent Ball-Milled Asbestos Dust Collected Inside Cages*

	Grains, %			Fibers, %			
Type of Asbestos	< 3 Microns	3-10 Microns	> 10 Microns	< 10 Microns	> 10 Microns	Clumps, %	Total
Long fiber.....	65.4	1.1	0.0	25.5	6.7	1.9	100
Ball-milled	90.6	4.8	0.0	0.5	0.6	3.2	100

TABLE 12.—*Summary of Inhalation Experiment with Long Fiber Asbestos Dust*

Nature of Experiment	Animals	Maximum Dust Exposure, Mo.	Maximum Survival After Dust Exposure, Mo.	Results
Dust exposure continuous throughout life	117 guinea pigs	34	0	Definite fibrosis in 20 mo.
	4 cats	42	0	Slowly developing fibrosis first seen at 21 mo.
	20 rats	25	0	Marked peribronchiolar fibrosis first seen at 21 mo.
	20 mice	25	0	Limited reaction; no fibrosis
Dust exposure followed by prolonged residence in normal air	12 guinea pigs	20	14	Clearing of inflammatory reaction and definite contraction of fibrous tissue
	9 guinea pigs	27	9	Clearing of inflammatory reaction and slight contraction of fibrous tissue
	2 cats	18	24	Similar to continuous exposure group; suggestion of progression in one of the two animals

considerably into the parenchyma (fig. 8 *A*). The lesions were rather sharply localized and the extensions from different bronchioles showed no tendency to fuse, even in animals exposed for the maximum period of three years. Although the intrapulmonary reaction sometimes reached the pleura, there was no involvement of that membrane. Emphysema was not detected at any point. Some thickening of the larger bronchi with a chronic inflammatory infiltration was revealed, but it was considered no more than would be produced by a similar period of inhalation of any dust.

In guinea pigs exposed to the dust for 20 months and then removed to normal air, there was a marked tendency for cellular inflammatory reaction to clear. This effect, accompanied by contraction of the fibrous tissue, resulted in a diminishing size of the focal lesions. None of these animals, killed at various periods up to 14 months after exposure, revealed lesions as large as those in the group killed at the end of the 20 month exposure period or those in animals which remained in the dust room for more than 20 months. Fourteen months after dust exposure ceased, the foci in four of the six remaining guinea pigs were so small that they were visible only with a hand lens (fig. 8 *B*).

In the group exposed for 27 months and then transferred to a normal atmosphere the response was quite similar to that in the 20 month exposure animals mentioned above. Small foci were always visible on gross inspection of sections of all guinea pigs of the 27 month series, but in no instance was there evidence of the reaction.



Fig. 7.—Lung fiber asbestos inhalation experiment: *A*, lung of a guinea pig with eight months' dust exposure. The bronchiole at the center already shows an accumulation of phagocytic cells, and there is a slight deposition of collagen. Compare with figure 6 *A*, showing the reaction to bail-milled asbestos after 24 months (× 250).

B, lung of a guinea pig with 16 months' dust exposure. Again note a bronchiole with its surrounding reaction, consisting of fibrosis and adenomatoid change. Collagen deposition is now seen in the walls of adjacent alveoli, at the right (× 250).

In the tracheobronchial lymph nodes reaction was first visible at the third month of exposure. By the eighth month patches of cellular connective tissue

began to appear in the medulla, and by the fourteenth month most of the node had been replaced by cellular connective tissue. This picture, which resembled that in early silicosis, persisted to the end of the experiment. Some animals showed, as a variant, heavy sheets of diffusely distributed monocytes and large active giant cells, but there was never any necrosis or hyaline formation. The spindle-shaped



Fig. 8.—Long fiber asbestos inhalation experiment: *A*, lung of a guinea pig with 34 months' dust exposure. A bronchiole is seen at the lower center; the large area above it represents the involvement of alveolar walls. Compare with figure 7 *B* and note the increased extent of reaction (× 200).

B, lung of a guinea pig with 20 months' dust exposure and then 14 months' living in normal air. The reaction is essentially like that shown in figure 7 *B*: The bronchiole at the right center is surrounded by fibrous tissue with adenomatoid change at the right. There is residual scarring in the walls of adjacent alveoli at the left. It is apparent that no progression has occurred (× 200).

new cells were yellowish from fine pigment granules that stained for iron. No fibers or asbestosis bodies were seen.

Although asbestosis bodies were found in the lung as early as one month after exposure began, they were rare and hard to find. At five months more were visible, chiefly coiled inside giant cells, and at eight months many bodies

TABLE 13.—*Analyses of Lungs of Guinea Pigs Exposed to Dust in Inhalation Experiment with Long Fiber Asbestos Dust*

Exposure to Dust, Mo.	Period in Normal Air, Mo.	Amt of Ash, % of Dried Lung	Total SiO_2, % of Dried Lung	Total SiO_2, % of Ash	Tissue Reaction *
		Dust Exposure Continuous During Life			
1	0	4.35	0.04	1.10	
		4.33	0.09	2.11	
		4.37	0.04	0.93	0
2	0	4.45	0.05	1.23	
		4.43	0.05	1.18	
		4.35	0.06	1.46	±
3	0	4.38	0.06	1.20	
		4.38	0.05	1.13	
		4.51	0.06	1.48	±
5	0	4.77	0.08	1.75	
		[illegible]	0.12	2.67	
		5.06	0.09	1.77	±
8	0	4.72	0.10	2.21	
		4.92	0.09	[illegible]	
		4.34	0.07	1.58	+
12	0	4.87	0.25	5.20	
		5.02	0.20	4.09	
		5.15	0.31	5.99	+
16	0	2.93	0.38	12.70	
		2.83	0.35	12.25	
		3.16	0.34	10.91	2+
20	0	3.54	0.43	12.22	
		3.60	0.49	13.63	
		3.58	0.52	14.59	2+
24	0	3.42	0.35	10.19	
		3.52	0.29	8.29	3+
27	0	3.40	0.39	11.51	
		3.74	0.49	13.15	3+
30	0	[illegible]	0.37	10.55	
		[illegible]	0.34	[illegible]	
		3.88	0.24	6.10	4+
34	0	5.85	0.50	8.60	
		6.70	0.84	12.47	4+
36	0	4.10	0.37	9.11	
		2.74	0.35	12.80	4+
		Dust Exposure Followed by Prolonged Residence in Normal Air			
20	0	3.54	0.43	12.22	
		3.60	0.49	13.63	
		3.58	0.52	14.59	2+
20	4	2.92	0.21	7.23	
		2.81	0.27	9.59	2+
20	10	4.15	0.24	5.75	
		4.30	0.22	5.07	2+
20	14	5.01	0.21	4.19	
		5.04	0.18	3.58	+
27	0	3.40	0.39	11.51	
		3.74	0.49	13.15	3+
27	3	3.56	0.31	8.59	
		2.54	0.18	6.94	2+
27	7	3.19	0.25	7.99	
		3.15	0.23	8.72	2+
27	9	2.21	0.29	8.96	
		2.75	0.23	8.31	2+

* The symbols averaging the tissue reaction in each group represent merely the relative degree of reaction, ranging from 0 to ± (questionable) to 4+ (the maximum for this experiment). The relationships apply only within this table and cannot be compared with symbols in other tables.

were free in connective tissue. They became fairly abundant as exposure continued, although in some later animals the asbestosis bodies were only moderately numerous.

It is important to note from analyses of the lungs (table 13) that even though the tissue response at any given period of time was much greater in the guinea

pigs of this experiment than in those exposed to either short fiber or ball-milled asbestos, the amount of mineral matter in the lung ash was much less.

Reaction in Cats.—Four cats inhaled the long fiber asbestos dust for periods of 14, 25, 33 and 42 months, respectively, and were immediately killed. Two other cats, after being exposed to dust for 18 months, lived in a normal atmosphere for an additional 24 months. Fourteen months' exposure was sufficient to produce cellular accumulations of phagocytes around terminal bronchioles and peripheral arterioles together with compact collections of similar cells in the tracheobronchial lymph nodes. At that time there were no typical asbestosis bodies, but smooth, pointed, yellow fibers were seen very rarely. With continued exposure, up to 42 months, reaction in the locations noted progressed to the formation of cellular connective tissue which made well defined sheaths about the respiratory bronchioles and arterioles, marked lymphoid hyperplasia and lymphoid infiltration of bronchiolar walls (fig. 9). Typical asbestosis bodies were not formed, although there was



Fig. 9.—Long fiber asbestos inhalation experiment: Lung of a cat with 42 months' dust exposure. Two bronchioles are shown with adjacent cellular reaction and collagen deposition (× 200).

an occasional fiber, smooth, yellow and pointed. Pleurisy was not present. The reaction was similar in location to that in the guinea pigs, but fibrosis was much slower in development. Roentgenograms of cats made after exposure periods of 25, 33 and 42 months, respectively, failed to demonstrate evidence of pulmonary lesions.

Reaction in Rats.—Although 20 rats were placed in the dust room, many died from pneumonia and were not suitable for study. Five animals, of which one was exposed for 19 months and four for 25 months, were free from pulmonary infection and offered a basis for tentative conclusions. In the 19 month animal, the reaction was just beginning. All four animals killed at 25 months showed a well marked peribronchiolar fibrosis. After a long search, only two small, smooth asbestosis bodies were found in the 19 month animal and none was found in the 25 month animal. Thus these animals exhibited fibrosis without asbestosis bodies or fibrosis accompanied by only a very infrequent asbestosis body.

Reaction in Mice.—Out of 20 white mice used in this experiment, 11 lived a year or more in dust and died or were killed without showing an appreciable degree of pulmonary infection. The reaction to the inhaled dust was limited to phagocytosis by mononuclear cells. Usually these were widely scattered through the air spaces; a limited number were grouped about the terminal bronchioles, producing some thickening of their walls. There was no suggestion of fibrosis.

Numerous asbestosis bodies were observed in animals killed late in the experiment. Thus these animals exhibited asbestosis bodies without fibrosis.

Summary and Interpretation of Inhalation Experiment with Long Fiber Asbestos Dust.—The purpose of this experiment was to evaluate the importance of long fibers in the tissue response to inhaled asbestos. The results, in comparison with those of previous investigations, indicate strongly that long fibers are chiefly responsible for asbestosis. Thus, the reaction in guinea pigs developed earlier and became more extensive in this experiment than in previous experiments in spite of a smaller concentration of atmospheric dust and a lower mineral content of the lungs. Furthermore, typical peribronchiolar fibrosis was produced in cats, although in a previous experiment with short fiber dust peribronchiolar fibrosis did not develop in this species.

The cause of the cellular fibrosis in the lymph nodes of the guinea pigs is not clear. It did not occur in other inhalation experiments with asbestos.

INJECTION EXPERIMENTS

Since the inhalation experiments reported above strongly suggested that long fibers of asbestos are the significant factor in the causation of asbestosis, a series of injection experiments was inaugurated wherein the dosage and the length of the fibers could be controlled more precisely. Also, by the use of controlled dosages, the relative capacities of various asbestos minerals to produce reaction could be compared. In these injection experiments, guinea pigs, rabbits, rats and dogs were used, and the mineral dust was injected by the intratracheal, the intraperitoneal and the intravenous technic, but not all the technics were used for each species. For the purpose of simplification the findings in each series of tests, except for dogs, have been condensed and reported in tables, to which reference will be made later. In the case of dogs, only one test was made, and since the findings were negative, no detailed report is included.

Experiments Using Intratracheal Technic

As the asbestos minerals do not cause typical advanced fibrosis in extrapulmonary tissue, the intratracheal technic is the preferred way of introducing fibrous dust into the experimental animal. In this method the dust suspension is injected by means of a special needle or catheter deep into the trachea, from which it flows into the lungs.

Comparison of Fibrous and Nonfibrous Dusts.—To demonstrate that the ability of asbestos to produce fibrosis resides in its fibrous character, the series of injection experiments reported in table 14 were performed.

TABLE 14.—*Comparison of Reactions to Chrysotile and Serpentine Injected Intratracheally*

Dosage: Each animal was given an intratracheal injection of 0.5 cc. of a 5 per cent suspension of the dust. Two weeks later another similar injection was given. Total amount of dust injected was 50 mg.

Animals used: Six groups of 6 guinea pigs each (one group for each type of dust).

Periods at which animals were killed: One or two animals in each group at 1, 2, 6, 9½ and 12 months after last injection.

Preparation of dust: Chrysotile (ball milled) unheated: Ball milled for 1,176 hr., dried and reground in agate mortar.

Chrysotile (ball milled) ignited: Ball milled chrysotile heated for 2 hr. at about 700 C., then ground in agate mortar 2 or 3 min.

Chrysotile (fibrous) unheated: Ground in agate mortar to pass 200 mesh.

Chrysotile (fibrous) ignited: 200-mesh material heated for 2 hr. at about 700 C. No further grinding.

Serpentine (ball milled) unheated: Ball milled for 1,176 hr., dried and reground in agate mortar.

Serpentine (ball milled) ignited: Ball milled serpentine heated for 2 hr. at about 700 C., then ground in agate mortar 2 or 3 min.

Mineral	Size of Dust Particles	Results
Chrysotile (ball milled) unheated	3 microns and less	Grinding destroyed capacity to cause fibrosis. At 1 mo. considerable inflammatory edema and cellular proliferation and localization of dust particles about bronchioles; at 2 mo., only a very slight proliferative reaction; at 6, 9½ and 12 mo., widely scattered small mononuclear phagocytes. At 12 mo., a few microscopic patches of thin alveolar wall thickening with some adenomatoid change in portion of air spaces abutting on thickened bronchi. No asbestosis bodies seen.
Chrysotile (ball milled) ignited	3 microns and less	Reaction limited to large foreign body giant cells without production of fibrous tissue.
Chrysotile (fibrous) unheated	20-50 microns approx.	A distinct fibrosis. Reaction localized to connective tissue about terminal bronchioles; little within those tubes. Contraction caused adenomatoid appearance of air spaces given off directly from terminal bronchioles. Reaction area became smaller with progress of time; no new regions involved. No chronic pleurisy even at points abutting intrapulmonary change. At 1 mo. considerable inflammatory edema and foci of cellular proliferation; at 2 mo. well marked cellular proliferation and fibrosis occurring locally about respiratory bronchioles. This reaction developed before asbestosis bodies had formed and was as advanced as that produced by 2 yr. inhalation of asbestos dust. At 6 mo., reaction less extensive than at 2 mo., apparently due to contraction of fibrous tissue; asbestosis bodies were abundant. At 9½ mo., reaction still less extensive, confined to the immediate vicinity of the small terminal bronchioles, where the scar tissue was quite dense and was becoming hyaline in character. Sometimes it even obliterated the bronchiole. Asbestosis bodies had become scarce. At 12 mo., the well developed peribronchial and intrabronchial adenomatoid areas of fibrosis had produced considerable distortion. More peripherally were patches of pneumonitis with eosinophilic infiltration, some of which was being transformed into fibrous tissue. These seemed to be precursors of the localized, diffuse patches of thin alveolar wall fibrosis seen elsewhere.
Chrysotile (fibrous) ignited	20-50 microns approx.	Reaction limited to large foreign body giant cells without proliferation. Heating the fibers, which made them brittle, destroyed their capacity to produce significant reaction.
Serpentine (ball milled) unheated	3 microns and less	Dust relatively inactive. At 1 and 2 mo., simple phagocytosis without proliferation; at 6 mo., no change except possibly lymphoid cell infiltration; at 9½ mo., a slight chronic pneumonitis; at 12 mo., only a little pneumonitis without suggestion of fibrosis.
Serpentine (ball milled) ignited	3 microns and less	Dust relatively inactive. Reaction essentially the same as for unheated serpentine. With ignited serpentine, less tendency for dust to be carried to bronchial nodes.



Fig. 10.—Comparison of reactions provoked by injected long fiber and ball-milled asbestos dusts: *A*, lung of a guinea pig which four months before had received an intratracheal injection of long fiber asbestos dust. Note the peribronchiolar accumulation of cells with collagen deposition. The bronchiole chiefly involved is in the midst of the reaction (× 200).

B, lung of a guinea pig which four months before had received an intratracheal injection of ball-milled asbestos dust. A bronchiole is shown at the right. In contrast with *A*, note that only a few cells have accumulated about the bronchiole and that collagen deposition is absent (× 200).

The tests were made with long fiber chrysotile, unheated, and with chrysotile that had been ignited to destroy its flexible structure or ball milled to reduce the length of fiber to 3 microns and less. At the same time control tests were made with serpentine, which has the same chemical composition as chrysotile but is nonfibrous. A review of the findings reveals that only the unheated, long fiber chrysotile produced typical peribronchiolar fibrosis and that ball-milled material containing only fibers less than 3 microns in length failed to cause fibrosis (figs. 10 and 11). Fibers subjected to ignition also had lost their capacity to cause serious tissue damage. Ignition produced important changes in the chrysotile fibers, among them being loss of water, an alteration from a flexible to a brittle structure and possibly other changes. Experi-



Fig. 11.—Serpentine injection experiment: Lung of a Guinea pig that had received an intratracheal injection of this dust four months before. A bronchiole is shown at the left center. The phagocytic cells exhibit little predilection for the bronchiole and collagen deposition is absent (× 200).

mental studies concerning this observation will be reported in a separate publication.

Comparison of Various Long Fiber Dusts.—Some very interesting findings are disclosed by the results of the experiments recorded in table 15. First, all the long fiber asbestos minerals tested, with the exception of anthophyllite, produced typical fibrosis. The characteristic peribronchiolar reaction caused by three representative long fiber asbestos minerals—chrysotile, amosite and crocidolite—is shown in figures 10*A* and 12. Why anthophyllite behaved differently from the other asbestos minerals is not entirely clear.

Second, with the mineral brucite, which is not a silicate but is a fibrous form of magnesium hydroxide, a characteristic fibrosis like

TABLE 15.—*Comparison of Reactions to Various Long Fiber Dusts Injected Intratracheally*

Dosage: Two injections of 0.5 cc. of a 6 per cent suspension given two weeks apart. Total dose was 30 mg.

Animals used: From 6 to 9 guinea pigs for each dust.

Periods at which animals were killed: Usually at 1, 4, 8 and 12 months after last injection.

Size of dust particles: Separated so that most fibers were from 20 to 30 microns long.

Mineral	Results
Chrysotile (Thetford)	Distinct fibrosis. *Additional information given opposite chrysotile (fibrous) untested, in table 14.*
Chrysotile (*Arizona; low iron content; 0.2% Fe₂O₃*)	*Reaction virtually identical with that to Thetford chrysotile. Both fibrosis and asbestosis bodies produced with an asbestos containing very little iron. Fibrosis occurred as plugs within terminal bronchioles and as dust deposits at periphery. Fibrosis developed before asbestosis bodies were seen and was in cellular state well formed at one month. With age, fibrous tissue contracted and occupied smaller area but was more dense. Adenomatoid changes similar to those with Thetford chrysotile. Pleurisy limited to immediate vicinity of entry section about areas of massive localization. Asbestosis bodies formed but were few. At 1 mo. after injection, minute foci of mononuclear proliferation about bronchioles and in areas of atelectasis; at 1½ mo., heavy peribronchiolar patches of fibrosis often with papillary projections partially closing lumen of bronchiole; adenomatoid appearance marked; connective tissue reaction showed heavy collagen but no hyalinization; at 2 mo., minute foci of well matured fibrosis about bronchioles; at 6 mo., mature asbestosis fibrosis with evidence of contraction; considerable chronic pneumonitis with infiltration of lymphocytes and eosinophils. At 9 mo., small interbronchial fibrous plugs with foci of more delicate fibrous at periphery.*
Amosite	*Typical fibrous endobronchiolitis and peribronchiolitis with formation of atypical asbestosis bodies [illegible]; beginning at 1 mo. after injection, well developed by 4th mo. Bodies persist after 12th mo. Reaction at 1 mo. heavy endobronchiolitis and peribronchiolitis already showing fibrous changes; atelectasis and fibrosis with some pneumonia at site of massive localization of dust. At 4 mo., heavy, widely scattered endobronchiolitis and peribronchiolitis, now fibrotic, with marked deformity of bronchioles and [illegible] adenomatoid appearance. At 8 mo. [illegible], no reaction in lungs essentially like that at 4 mo. At 12 mo., foci of fibrous endobronchiolitis and peribronchiolitis still large, with considerable scar tissue and moderate deformity of bronchial tubes but no extension into, or atelectasis of, peripheral parenchyma.*
Crocidolite (Bolivia)	*Advanced fibrous endobronchiolitis and peribronchiolitis. Heavier asbestosis bodies noted at 8 mo. At 1 mo., early fibrous endobronchiolitis and peribronchiolitis; many giant cells and some lymphocytic reaction. At 4 mo., small areas of endobronchiolitis scattered throughout the lungs, cellular fibrosis. At 8 and 12 mo., areas of bronchiolitis smaller because of contraction of dense scar tissue; at 12 mo., marked lymphocytic infiltration and adenomatoid appearance.*
Crocidolite (S. Africa)	*Typical advanced fibrous endobronchiolitis and peribronchiolitis produced by 0.5% suspension of the [illegible] dust; animals were killed at the usual 2% suspension. [illegible] At 4 mo., [illegible] At 8 mo., [illegible] giant cells and scar tissue. At 8 mo., typical bronchiolitis not quite as extensive or as nearly fibrous as with a 2% suspension, otherwise the same. Many dusty stained fibers with a small proportion of haustrated asbestosis bodies. At 12 mo., heavy fibrous bronchiolitis, more peribronchiolitis and endobronchiolitis, with lymphocytes and giant cells; very marked adenomatoid appearance.*
Anthophyllite	*Lymphocytic infiltration and giant cells but no fibrosis. A very few atypical asbestosis bodies. At 1 mo., many scattered foci of intrabronchiolar dust without massive localization; lymphocytic infiltration of walls and a few giant cells. At 8 and 12 mo., little evidence of dust; a few bronchioles and bronchi with giant cells in adjacent alveoli and with lymphocytic infiltration of walls.*
Tremolite	*Fibrosis about bronchioles. At 1 mo., areas of dust localization with collapse of alveoli and infiltration with acute inflammatory cells, macrophages and giant cells. Within the area were a few foci of fibrous tissue and numerous areas of hypertrophy of alveolar epithelium. Many bronchioles packed with fibers. At 4 mo., general appearance of lesion unchanged; pleura slightly thickened over heavy localizations of dust. An occasional segmented asbestosis body seen. At 8 mo., many foci of fibers in bronchioles and alveolar ducts with cellular reaction as before; also, some foci showed dust but no collagen deposition. At 12 and 15 mo., reaction as before with fibrosis about bronchioles more apparent because of contraction and decrease of inflammation, giant cells prominent. Pleura markedly involved.*
Brucite	*Typical fibrous endobronchiolitis and peribronchiolitis. Like reaction to asbestos minerals. At 1 to 2 mo., extensive endobronchiolitis and peribronchiolitis with giant cells; dense fibrous loops within bronchioles and cellular fibrosis about them; adenomatoid change present. At 2 mo., heavy intrabronchiolar and [illegible] fibrosis producing marked deformity with distortion of tubes and obliteration of surrounding air spaces; fibrosis pale without hyalinization but with few nuclei; no necrosis. Typical asbestosis bodies seen. At 4 and 8 mo., little change; fibrous tissue contracting. At 10½ mo., dense fibrous bronchiolitis with asbestosis bodies. No pleurisy. No extension to surrounding lung.*
Glass wool	*No fibrosis within a year. At 1 mo., no reaction inside bronchioles; in peripheral air spaces clumps of giant cells packed with fine spicules of glass with lymphocytic infiltration of adjacent walls; no asbestosis bodies. At 2 mo., reaction less intense than at 1 mo.; fair-sized clumps of elongated giant phagocytes containing spicules and particles of glass; no endobronchiolitis. At 4 and 8 mo., reaction still diminishing. At 12 mo., focal areas of pneumonitis with no fibrosis or endobronchiolitis; moderate number of smooth iron staining fibers.*

that produced by the asbestos minerals was obtained (fig. 13 *A*). Since the brucite used contained only 0.90 per cent silica as an impurity, it is obvious that a siliceous component is not an essential factor in the development of asbestosis.



Fig. 12.—Amosite and crocidolite injection experiments: *A*, lung of a guinea pig four months after an intratracheal injection of amosite. The inflammatory reaction exhibits pronounced accumulation of cells and collagen deposition (× 200). *B*, lung of a guinea pig four months after an intratracheal injection of crocidolite. As in *A*, peribronchiolar accumulation of cells and deposition of collagen are shown (× 200).

Third, no fibrosis resulted from the injection of glass wool fibers (fig. 13 *B*), even though glass wool resembles asbestos in many ways. However, there are fundamental differences. A glass wool fiber 3 microns

in diameter is a solid rod which in short lengths is fairly rigid, while an asbestos fiber of the same diameter is a bundle of extremely fine filaments which impart to the fiber a high degree of flexibility. It would seem that this structure and the associated flexibility are important factors governing the capacity of a mineral to produce peribronchiolar



Fig. 13.—Brucite and glass wool injection experiments: *A*, lung of a guinea pig which four months before had received an intratracheal injection of brucite. Even with this nonsiliceous fibrous mineral there is peribronchiolar accumulation of cells and deposition of collagen similar to that shown in *A* and *B* of figure 12 (× 200).

B, lung of a guinea pig which four months before had received an intratracheal injection of glass wool. Two bronchioles are shown, one in cross section and the other in longitudinal section. Below the latter is a thick-walled blood vessel. The bronchioles are without reaction and can be considered normal for comparison with other figures. Glass wool fibers are present in this field but cannot be seen at this magnification (× 200).

fibrosis. Experimental studies concerning this observation will be reported in a separate publication.

TABLE 16.—*Comparison of Reactions Produced by Long Fiber and Short Fiber Dusts Injected Intratracheally*

Dosage: Two injections of 0.5 cc. of a 5 per cent suspension given two weeks apart. Total dose was 50 mg.

Animals used: Six groups of guinea pigs.

Periods at which animals were killed: 1, 2, 6, 8½ and 12 months after injection.

Mineral	Size of Dust Particles	Results
Chrysotile (Thetford)	Long fiber, 20-50 microns	A distinct fibrosis. Refer to chrysotile (fibrous) unbeaten in table 14.
	Short fiber, 5 microns and less	No fibrosis. Refer to chrysotile (ball milled) unbeaten in table 14.
Amosite	Long fiber, 20-50 microns	Typical fibrous endobronchiolitis and peribronchiolitis. Refer to table 15.
	Short fiber, 20 microns and less	Reaction limited to phagocytosis with lymphocytic infiltration of adjacent walls. Short fibers packed inside swollen phagocytes; longer ones free; some coated to form typical asbestosis bodies. At 1 mo. after injection, alveoli contained occasional giant cells; most phagocytes were within air spaces and had not migrated to walls. At 4 mo., free extracellular fibers had worked themselves into interstitial tissue, where there was extensive proliferation of lymphoid cells and monocytes but no fibrosis. At 8 mo. focal cellular reaction with some pneumonitis, no bronchiolitis. Typical asbestosis bodies present.
Crocidolite (Bolivia)	Long fiber, 20-50 microns	Advanced fibrous endobronchiolitis and peribronchiolitis. Refer to table 15.
	Short fiber, 20 microns and less	No fibrosis. At 1 mo., air spaces compressed and largely filled with giant cells packed with dust particles. Walls heavily infiltrated with monocytes and lymphoid cells. At 4 mo., a moderate degree of cellular infiltration of walls; small giant cells packed with dust spicules. At 6 and 8½ mo., masses of giant cells, containing mineral particles in small bronchioles, not in respiratory bronchioles; smaller ones widely scattered in terminal air spaces. Numerous asbestosis bodies. No reaction in connective tissue. No evidence of peribronchitis. At 12 mo., many scattered small monocytes packed with dust. No endobronchitis. No peribronchial fibrosis. In lymph node, slight reticulosis; no fibrosis.
Anthophyllite	Long fiber, 20-50 microns	Lymphocytic infiltration and giant cells but no definite fibrosis. Refer to table 15.
	Short fiber, 5 microns and less	No fibrosis and practically no asbestosis bodies. At 1 mo., focal collections of distended monocytes and a few giant cells; at 4 mo., some adenomatoid epithelial reaction; at 8 mo., simple pneumonitis with phagocytosis of short fibers; at 12 mo. isolated and sharply localized collections of dust cells inside air spaces about terminal arterioles. Reaction in walls limited to lymphoid cell infiltration. No fibrosis. In lymph node, reaction limited to slight prominence of reticulum.
Tremolite	Long fiber, 20-50 microns	Fibrosis about bronchioles. Refer to table 15.
	Short fiber, 20 microns and less	Simple foreign body reaction. No acute inflammation. No accumulation of dust in or about terminal bronchioles. No endobronchitis. At 1 mo., scattered small giant cells and considerable infiltration of adjacent walls with monocytes and lymphoid cells. At 4 mo., little change except more cellular infiltration of connective tissue. At 8 mo., lymphoid infiltration and thickening of walls about some but not all terminal bronchioles.
Brucite	Long fiber, 20-50 microns	Typical fibrous endobronchiolitis and peribronchiolitis like reaction to asbestos mineral. Refer to table 15.
	Short fiber (made by crushing long fibers with rubber policeman)	Inert type of reaction. At 1 mo. after injection, small masses were scattered through air spaces; foci of atelectasis with lymphoid infiltration of compressed alveolar walls. No endobronchial reaction as with chrysotile. At 2 mo., reaction similar to that at 1 mo.; typical asbestosis bodies seen. At 12 mo., small clumps of inactive dust-filled phagocytes; no fibrosis. No reaction in lymph nodes.

Comparison of Long Fiber and Short Fiber Dusts.—With quartz dust it has been demonstrated that the smaller the particles the more

intense is the tissue reaction and that particles larger than 3 microns in diameter cause little reaction. In the case of asbestos, however, the reverse is true and apparently only long fibers have any specific effect, as was suggested by the inhalation experiments. This is confirmed by the data of table 16, in which a series of tests with fibrous minerals is reported. When the injected dust consisted of fibers 20 to 50 microns long, all the fibrous minerals tested except anthophyllite, as noted in the preceding section, produced fibrosis; when the material was prepared by first grinding the fibrous dust until the length of fibers was reduced to 20 microns and less or, in some cases, to 3 microns and less, none of the injected dusts caused fibrosis.

These results differ from those of King, Clegg and Rae,[11] who reported the production of reticulosis comparable to the experimental silicotic nodule in rabbits receiving monthly intratracheal injections of 100 mg. of Rhodesian asbestos fibers, 15 microns long, and the production of diffuse interstitial fibrosis in rabbits receiving similar injections of short fibers, 2.5 microns in length. We believe this dose, especially in the long term rabbits, is highly excessive. In our experiments the dosage was kept low in order to minimize untoward reactions which might obscure the peribronchiolar type of fibrosis which characterizes early human asbestosis.

Experiments Using Intravenous Technic

The experiments summarized in table 17, in which the intravenous method of injection was employed, show that the asbestos minerals are far different from quartz in their action on tissue. It has been repeatedly demonstrated that intravenous injection of quartz particles 3 microns and less in diameter will cause a typical tissue reaction with the development of hyalinized fibrotic lesions in extrapulmonary sites, such as the liver and the spleen. Asbestos minerals, however, on intravenous injection generally produce only an inert type of reaction, as is revealed by the results given in the table. The reason for the early deaths in the experiment with chrysotile particles is not clear.

Experiments Using Intraperitoneal Technic

The results of injection experiments with the intraperitoneal technic are given in table 18. It will be noted that the long fiber dusts produced a fibrous reaction while dusts composed of particles 3 microns and less in size caused only an inert type of response. These experiments indicate also that the fibrosis initiated by the irritation of asbestos fibers is not restricted to the lungs, as was formerly assumed, but can be produced in the peritoneum as well.

OTHER EXPERIMENTS WITH ASBESTOS MINERALS

A number of additional experiments were conducted to throw more light on specific phases of the asbestosis problem.

11. King, E. J.; Clegg, J. W., and Rae, V. M.: Effect of Asbestos, and of Asbestos and Aluminium, on Lungs of Rabbits, Thorax **1**:188, 1946; abstracted, Indust. Hyg. Digest, 1947, vol. 11 (Feb.), no. 234.

Table 17.—*Summary of Injection Experiments by Intravenous Technic*

TABLE 17.—*Summary of Injection Experiments by Intravenous Technic*

Dosage: Total amount of dust was 1.0 Gm., divided into 20 equal doses (each dose was 5 cc. of a 1 per cent suspension) which were given twice a week for 10 weeks.

Mineral	Size of Dust Particles	Rabbits Used	Maximum Survival After Last Injection, Mo.	Results
Chrysotile (Thetford)	3 microns and less (ball milled 192 hr.)	6	..	The rabbits did not tolerate intravenous injections of finely ground chrysotile and 5 of the 6 died after 1 to 5 injections of even diluted suspensions; the other animal died after 21 injections of one-quarter strength suspension (69 days after first injection). Reaction limited to few large giant phagocytes of inactive type in liver, spleen and bones. No thrombi of dust cells seen in pulmonary capillaries. No definite explanation for fatalities discovered, but material may have been retained in heart, causing local thrombi.
Amosite	3 microns and less (ground in agate mortar)	5	17	Advanced pulmonary infection killed 3 animals at 9, 11 and 17 mo. after last injection, shortening intended duration of experiment and complicating picture. However, rabbits killed earlier (3 and 6 mo.) showed only inert phagocytosis with no progression in the 6 mo. animal. The last two (11 and 17 mo.) were probably the same although focal necrosis of the liver and amyloid of the spleen made interpretation difficult.
Crocidolite	3 microns and less (ground in agate mortar)	4	12	Reaction was that to an inert substance with no change in 12 mo. (Other observations at 3, 6 and 9 mo.) Simple phagocytosis of particles. No tendency to agglomerate and no change in adjacent tissue. Grinding the dust to size of 3 microns and under destroyed the fibrous structure of this mineral, and the injected material resembled plates rather than fibers.
Anthophyllite	3 microns and less (ball milled 1,00 hr.)	4	24	Reaction essentially that of an inert mineral. Observations made at 3, 6, 12 and 24 mo. Only suggestion of irritating properties manifested in spleen and lymph nodes, but not liver, of the 24 mo. rabbit. In this animal there had been proliferation of mononuclear and giant cells that was not present in either spleen or lymph node of 12 mo. animal. The absence of associated fibroblastic reaction in these organs and of any change in the liver condition justifies the classification of anthophyllite as an inert silicate. No fibers were retained in lung to demonstrate whether asbestosis bodies would develop.
Tremolite (soda iron)	3 microns and less (ball milled 168 hr.)	4	19	Reaction essentially that of an inert mineral. Last animal killed showed a little proliferation and lymphocytic infiltration in liver, not seen earlier (at 3, 6 and 12 mo.). No evidence of any activity in lesions in other organs.
Tremolite (soda)	3 microns and less (ball milled 48 hr.)	4	24	An inert foreign body reaction with no change in 24 mo. Observations made at 3, 6, 12 and 24 mo.

TABLE 18.—*Summary of Injection Experiments by Intraperitoneal Technic*

Dosage: Each animal* received a single intraperitoneal injection of 2 cc. of a 10 per cent dust suspension. Total amount of dust injected was 0.2 Gm.

Mineral	Size of Dust Particles	Guinea Pigs Used	Maximum Survival After Injection, Mo.	Results
Chrysotile (Thetford)	3 microns and less (ball milled 210 hr.)	15	36	No fibrosis or asbestosis bodies. Dust particles ingested by phagocytes, chiefly multinucleated variety. Six mo. after injection fibrous elements of dust appear to have dissolved leaving only the insoluble magnetite, a contaminant. No reaction in surrounding fat or areolar tissue. No transporting of dust to regional lymph nodes. Observations made at intervals from 1 to 36 mo. after injection.
Chrysotile (Thetford)	Long fiber (through 100 mesh)	4	2	Definite fibrous reaction produced, delicate and monotypaline. Atypical asbestosis bodies developed, but all were unusually small. No evidence of extra long fibers seen. Observations only at 2 mo.
Amosite	3 microns and less (ground in agate mortar)	9	12	Infection interfered with interpretation. Dust reaction appeared to be of inert type and limited to phagocytosis with a moderate tendency to lymphocytic infiltration. Observations at 1, 4, 8 and 12 mo.
Crocidolite	3 microns and less; also some long splendes (ground in agate mortar)	7	12	Dust fed consisted only of large mononuclear and giant phagocytes surrounded by a minimum amount of cellular connective tissue. The injected dust contained not only fine material that in granules had been crushed into irregular plates but also many long splendes 10 microns or more in length. No asbestosis bodies seen, although the longer splendes appeared slightly swollen and granular. Observations at 1, 4, 8 and 12 mo.
Anthophyllite	3 microns and less (ball milled 1,165 hr.)	5	25	Essentially inert foreign body reaction. In early animals (1, 4 and 8 mo.) focus of monocytes and small giant cells and a little central necrosis. In the 4 mo. animal there was also slight perifocal fibrosis. At 12 and 25 mo., nonprogressive mass of monocytes and giant cells; no fibrosis.
Anthophyllite (originally bicked talc)	Mostly 3 microns and less, some fibers 20 microns or more long (ground in agate mortar)	5	12	Reaction, which consisted of very large giant cells surrounded by a variable number of lymphocytes, was much heavier to these unintentionally long fibers than to the fine dust in the experiment above. There was more or less proliferation of fibroblasts producing cellular connective tissue visible in areas where the quantity of foreign particles was not so great that it obscured the reaction. Observations at 1, 4, 8 and 12 mo.
Tremolite (sodic-iron)	3 microns and less (ball milled 15 hr.)	5	12	Inert type of response never progressing beyond the stage of very slight lymphocytic reaction about masses of dust filled phagocytes. No fibrosis. Observations at 1, 4, 8 and 12 mo.
Tremolite (soda)	3 microns and less (ball milled 45 hr.)	5	18	Inert nonprogressive foreign body type of reaction. No fibrosis. Observations at 1, 4, 8, 12 and 18 mo.
Anthophyllite	100 microns and less	5	12	Distinct early fibrosis produced by anthophyllite and fibrous pyrophyllite with subsequent regression; slight crystalline pyrophyllite inert throughout. At 1 mo., giant cells about long thick splinters; at 4 mo., definite fibrosis replacing giant cells of anthophyllite and fibrous pyrophyllite reaction; at 8 mo., fibrosis which started at 4 mo. had decreased, especially with fibrous pyrophyllite. At 12 mo., reaction to all three dusts consisted of foreign body giant cells with lymphocytes but without foci of necrosis or fibrosis. No asbestosis bodies.
Pyrophyllite (*fibrous*)	100 microns and less	5	12	
Pyrophyllite (crystalline)	100 microns and less	5	12	

* Each animal receiving long fiber chrysotile was given an injection of 2 cc. of a 0.6 per cent dust suspension.

Protective Action of Aluminum Compounds

When colloidal aluminum hydroxide had been added to a suspension of long fiber chrysotile prior to injecting this suspension intratracheally into rats, the aluminum compound did not prevent the irritation of tissue due to chrysotile. If anything, the acute inflammatory response evoked by the injected fibrous mineral was accelerated. One month after the last injection of the dust suspension the bronchiolitis was becoming fibrous. King and his associates also found that aluminum failed to protect pulmonary tissue from the irritation caused by asbestos fibers [11]; in their experiments metallic aluminum was used instead of the hydroxide.

Formation of Asbestosis Bodies

The iron in the coating of the asbestosis body appears to be derived from blood or tissue elements and not, as has been suggested, from the mineral fiber. After two kinds of chrysotile were injected subcutaneously into the groin of a guinea pig—one kind containing 2 per cent and the other 0.2 per cent ferric oxide—the asbestosis bodies were equally numerous at both sites of injection and showed no difference in their reaction to prussian blue, the reagent which stains iron. This finding is in agreement with that of Giroux.[12]

Tissue Reaction to Asbestosis Bodies

Asbestosis bodies recovered from human lung tissue and injected intratracheally into guinea pigs failed to produce a fibrous reaction. The material for injection was obtained by digesting with sodium hypochlorite solution the lung tissue removed at autopsy from an asbestos worker. The asbestosis bodies could be seen in the guinea pigs for at least a year after injection. This experiment shows that the asbestosis body has a rather resistant coating which is not destroyed by moderate hypochlorite treatment, which may be maintained in vivo for a year or longer and which renders the fiber incapable of producing fibrosis. It thus appears that the coating is a protective mechanism. This thought was expressed by Beintker as early as 1934.[13]

Theory of Irritant Action

Two hypotheses have been proposed to explain the tissue irritation and reaction caused by asbestos fibers: the chemical and the mechanical. In the chemical theory, which is based on experience with quartz, it is assumed that the asbestos minerals dissolve in the body fluids and that in this process their bases are leached away to leave silica in a form capable of irritating tissues. According to this hypothesis asbestosis is merely an indirect silicosis. Several facts make the chemical theory untenable: Intratracheal injection of brucite fibers, which had a silica

12. Giroux, M.: Amiantose expérimentale: valeur pathognomonique du "corps d'amiante," Laval méd. 8:239, 1943.

13. Beintker, E.: Über die Asbestosiskörperchen: Bemerkungen zu der Arbeit von Beger, Virchows Arch. f. path. Anat. 293:527, 1934.

content of only 0.90 per cent, caused typical fibrosis like that produced by the asbestos minerals; free silica particles increase in potency as the particle size becomes less, but asbestos fibers shorter than about 10 to 20 microns are relatively innocuous; aluminum hydroxide neutralizes the irritating effect of quartz but not of asbestos; serpentine has the same chemical composition as long fiber chrysotile, but it produced only an inert type of tissue reaction; there is a wide range in the chemical composition of the minerals which do cause asbestosis (table 19). In view of this evidence it seems more likely that asbestosis is caused by an unusual mechanical irritation due to long asbestos fibers, this irritation being related to the peculiar filamented structure of the fiber and the associated flexibility, which are possessed by no other foreign body studied. Thus, ignition of chrysotile fibers changed their structure and made them inert, although the same fibers, before being heated, would have produced fibrosis (table 14). Further support for the theory of mechanical irritation is that asbestosis occurs in an organ of high mobility —the lung—and that a fibrous reaction can be produced by injecting

TABLE 19.—*Analyses of Fibrous Minerals*

Fibrous Minerals	SiO_2 %	Fe_2O_3 %	FeO %	Al_2O_3 %	CaO %	MgO %	Na_2O %	K_2O %	Ignition < 105 C. %	Loss > 105 C. %	Total %
Amosite	46.23	4.06	33.83	1.09	2.01	6.28	0.33	0.20	0.66	5.28	99.[illegible]
Amphibole	55.04	3.06	.....	1.69	12.22	23.29	0.43	0.12	0.22	3.60	99.[illegible]
Anthophyllite	[illegible]	0.57	.....	0.32	0.44	33.37	0.52	0.15	0.27	4.08	99.[illegible]
Brucite	0.[illegible]	6.75	9.26	0.46	0.04	53.99	0.91	0.16	0.53	26.66	99.[illegible]
Chrysotile	38.[illegible]	2.35	.....	0.34	0.03	36.[illegible]	0.2[illegible]	0.0[illegible]	4.30	14.99	99.[illegible]
Crocidolite	54.[illegible]	16.27	4.29	1.01	0.90	12.25	6.92	0.57	0.02	2.56	99.[illegible]
Tremolite	[illegible]	7.21	.....	0.56	4.44	20.52	6.7[illegible]	0.[illegible]	0.34	2.7[illegible]	[illegible]

asbestos fibers into the peritoneum, where there is also a degree of mobility, but not by injecting them into other extrapulmonary organs such as the liver, the spleen and subcutaneous tissue.

COMPLICATIONS

The experimental investigations with asbestos minerals were concerned primarily with the effect of the dust on normal tissue, but some attention was given to other phases, such as susceptibility to infection. The only experiment in which the effect of asbestos dust on a pulmonary infection was studied was the first inhalation experiment, carried on with King's floats dust. It is unfortunate that, owing to the lack of adequate facilities at that time, infection studies could not be made in the other inhalation experiments also.

SUSCEPTIBILITY TO TUBERCULOUS INFECTION

The development of a tuberculous process initiated at the beginning of exposure to dust, and also of a tuberculous infection superimposed on an established asbestosis, was described in preceding sections of this paper. It may be stated that asbestos when classified according to the effect of a dust on tuberculous infection would be placed below an active

dust like quartz but above an inert dust such as iron oxide. In animals infected with attenuated tubercle bacilli, quartz causes the infectious process to progress until the animal dies of tuberculosis. Inert dusts have no effect on the infection, and the lesions usually heal and the disease disappears. Asbestos dust is in a different category. In the experimental investigation, when the fibrous dust was being inhaled during the evolution of the infection, there was spreading of the tuberculous process for a time, but usually the stimulus for continued proliferation of the tubercle bacilli was not sustained, the progression was arrested and healing followed. In guinea pigs infected with attenuated tubercle bacilli after being exposed to asbestos dust for slightly more than two years, progressive disease did not develop. The only modification of the infection was one of localization, a few bacilli being retained in the fibrous terminal bronchioles and forming tubercles there, in addition to the usual foci beneath the pleura. Such tubercles healed in a few months.

Susceptibility to Nontuberculous Infection

There was no specific experiment concerning the effect of inhaled asbestos dust on nontuberculous infection. Intercurrent pneumonia was rather common among animals exposed to asbestos dust, the frequency in guinea pigs exposed in the four inhalation experiments ranging from 16 to 39 per cent. This incidental evidence suggests the possibility of an effect of asbestos dust on nontuberculous infection. Nevertheless, since such epidemics are not uncommon in inhalation experiments with other dusts and even in the colony of normal animals, it is felt that the inhalation of asbestos dust does not exert a significant effect on the susceptibility to nontuberculous pulmonary infection.

COMMENT AND SUMMARY

Owing to the vast amount of data included in this investigation, it seems most convenient to summarize and to state as concisely as possible the various observations which emerged from the experiments and to follow each with a brief résumé of the evidence.

A. Various species of animals, including the guinea pig, the rat and the rabbit, but not the mouse and the dog, develop peribronchiolar fibrosis of the lung similar to human asbestosis after being exposed by inhalation or intratracheal injection to long chrysotile asbestos fibers.

Both inhalation and injection experiments provide ample support for this statement. Figure 8*A* reveals the cellular fibrosis that occurs in guinea pigs following inhalation of long fiber asbestos; figure 9 shows the fibrosis caused in the cat by inhalation of long fiber asbestos dust. Similar but less extensive fibrosis occurred also in rats and rabbits (table 1). Mice and dogs failed to respond. This variation in response of different species to identical dust exposures is still to be accounted for.

B. Long asbestos fibers are essential in the production of the peribronchiolar fibrosis; short fibers are incapable of producing this reaction.

Inhalation experiments with asbestos dust suggest, and intratracheal injection experiments confirm, that peribronchiolar fibrosis is produced by asbestos fibers between 20 and 50 microns in length but not by particles shorter than 20 microns (tables 16 and 18). This indicates that the minimum length of fiber possessing the capacity to produce the typical peribronchiolar fibrosis in animals is somewhere between 20 and 50 microns. Pointed studies have not been carried out to determine the upper limit of effective fiber length. It appears, however, that that limit will be determined by the inhalability of the fiber.

C. The mode of action of the long asbestos fiber in the production of asbestosis is primarily mechanical rather than chemical in nature.

The evidence for this conclusion has been reviewed in a preceding section, page 39. The flexible filamented structure of asbestos fibers plays an essential part in the irritating action, since the solid, inflexible fibers of glass wool do not produce fibrosis (fig. 13*B*).

D. Typical experimental asbestosis was produced by the inhalation of an atmospheric suspension containing an average of 138 million asbestos particles per cubic foot of air by light field count, of which less than 1 per cent consisted of fibers longer than 10 microns.

In the inhalation experiment with 100 per cent ball-milled asbestos dust containing 0.6 per cent of fibers longer than 10 microns (table 11) typical fibrosis was obtained (table 9). The evidence presented shows at least that an atmospheric concentration of asbestos dust containing less than 1 million (0.6 per cent × 138 million) fibers longer than 10 microns per cubic foot of air is capable of producing experimental asbestosis in guinea pigs. The actual lower limit of concentration of long fibers necessary to produce asbestosis in animals cannot be established from these studies.

E. The duration of exposure required to develop the pulmonary reaction to inhaled asbestos dust is inversely proportional to the concentration of long fibers in the atmosphere; as the concentration is increased, the reaction develops in shorter time.

The basis for this statement appears in the data of the inhalation experiment with long fiber asbestos. For that experiment the average concentration of the atmospheric dust was about 40 million particles per cubic foot of air, and size-frequency determinations disclosed that 6.7 per cent of the air-suspended material consisted of fibers longer than 10 microns (table 11). Thus, by calculation, it is estimated that the concentration of the longer fibers was 2.7 million (6.7 per cent × 40 million). The lungs of animals exposed to the long fiber asbestos dust revealed that the pulmonary reaction developed in approximately one-half the exposure time required for its development in animals inhaling the ball-milled product, for which the concentration of the longer fibers was only 0.8 million (0.6 per cent × 138 million).

F. Established experimental asbestosis ceases to progress on discontinuance of dust exposure.

The experimental investigation shows, in fact, that on discontinuance of exposure there was an appreciable clearing of the mature pulmonary

lesions, due to contraction of the fibrous tissue. In contrast, an immature tissue response, evidenced primarily by cells with little or no fibrosis, continued to progress. It is assumed that, following attainment of fibrotic maturity, the same process of contraction would ensue as was noted for the mature lesion.

G. The formation of asbestosis bodies represents a coating of the fibers by blood and tissue elements, which results in loss of ability of the fiber to produce fibrosis.

Intratracheal injection of asbestosis bodies failed to produce the typical asbestotic tissue reaction in experimental animals. The cessation of progressive reaction observed soon after exposure terminates may be due to the formation of asbestosis bodies.

H. Aluminum hydroxide failed to neutralize the fibrosing action of the long fiber asbestos.

Aluminum hydroxide added to the suspension of chrysotile asbestos prior to intratracheal injection did not retard or prevent the development of asbestosis in rats.

I. Inhalation of asbestos dust did not alter significantly the final outcome of experimental tuberculosis in two series of guinea pigs exposed to the dust.

The apparently mild influence of asbestos dust is in distinct contrast to the stimulating effect exerted by inhaled quartz on a tuberculous process in the lung. The interpretation must remain tentative, however, since it is based on an investigation limited to two series of guinea pigs exposed to only one kind of asbestos, namely, King's floats: Table 4 shows that when the infection was coincidental with the onset of dust exposure, there was temporary progression of the infectious process, with subsequent healing; when infection was initiated after 26 months of dust exposure, the course of the tuberculosis was not appreciably altered. The latter finding is quite different from our usual experience with quartz dust or with mixed dusts containing quartz, wherein the adverse influence of quartz on a tuberculous infection is manifested most strikingly when infection is initiated after a period of dust exposure, viz., superimposed on a background of established silicosis. As indicated above, this more sensitive test, when applied to asbestos dust, failed to demonstrate that the latter had an adverse influence on a tuberculous infection. The inability of asbestos dust in that experiment to affect unfavorably the tuberculous process furnishes strong support for the interpretation that inhaled asbestos dust has no more than a mildly unfavorable effect on pulmonary tuberculosis.

This investigation was made possible by the generous financial support of a group of companies of the asbestos industry.