Denver Clinic Medical Centers, P.C.

Celebrating 30 years...1956-1986

Corporate Offices • 701 East Colfax Avenue
Denver, Colorado 80203 • (303) 831-7171

March 3, 1987

Thomas W. Henderson, Esquire
Henderson & Goldberg, P.C.
1030 Fifth Avenue
Pittsburgh, PA 15219



Dear Mr. Henderson:

Thank you for referring Junior Caves to me for evaluation.

At your request I interviewed and examined him on February 26, 1987. Based upon this examination I find that Mr. Caves had a significant exposure to polychlorinated biphenyls as a salvager.

As a result of Mr. Caves exposure to polychlorinated biphenyls he has developed persistent skin abnormalities, including chloracne with residual comedones and scarring. In addition, he has actinic keratoses of the forehead, and has had at least one skin cancer removed.

Mr. Caves also has evidence of peripheral neurological abnormalities, and he has evidence of mild central nervous system abnormalities which have been documented by the appropriate examinations. This cluster of peripheral neurological changes, and central nervous system disorders is characteristic of type 2 B psychoorganic syndrome.

Mr. Caves has evidence of a myofascial syndrome characterized by acute tenderness of the muscles of the back, shoulders, and chest. He also has evidence of an action dystonia. These findings are associated with PCB induced myopathy.

Mr. Caves has chronic obstructive pulmonary disease which is significant. It is likely that his PCB exposure aggravated his underlying lung disease.

His laboratory examinations show mild elevations of coproporphyrins which may well be related to his PCB exposure.

Based upon this examination, it is my opinion that Mr. Caves has skin disease, central nervous system disease, peripheral nervous system disease, neurosthenic syndrome, and muscle disease caused by PCB's.

If you have any questions, please do not hesitate to call me.

Sincerely,

Daniel T. Teitelbaum, M.D

/ls

Central: 701 E. Colfax, Denver 80203 • 831-7171
East: 9450 E. Mississippi, Denver 80231 • 751-1241
North: 84th & Zuni, Suite 225, Denver 80221 • 429-1529
West: Denver West Office Park, Bldg. 52, Golden 80401 • 279-7525
Aurora: 15101 E. Iliff, Suite 140, Aurora 80014 • 696-7525
Littleton: 1900 W. Littleton Blvd., Littleton 80120 • 797-6700
Tiffany Plaza: 7400 East Hampden, Denver 80231 • 770-3200

See reverse for professional staff listing

WATER_PCB-SD0000032528

MEDICAL DICTATION

RE: Junior Caves

BY: Dr. Daniel Teitelbaum

DATE: March 3, 1987

Chief complaint:

The patient stated that in September 3, 1984, he left his job as a public housing employee because he just could not work anymore. He had pain in his knees, and pain in his hips. He was extremely tired, and he was bruising very easily.

Present illness:

The patient stated that he had pain in his hip and knees for approximately 3 to 4 years prior to the time that he left work. He also had complaints of very poor sexual performance with impotence. He felt very weak and tired. He had multiple complaints about his skin including the development of pimples, boils, and other eruptions.

The patient indicated that he had worked as a salvager, as an independent contractor. He collected and junked capacitors which he would chop open or cut open, dump the oil and remove the copper for sale. Approximately one and a half pounds and a half a gallon PCB oil was found in each capacitor. He believes that he salvaged 3 to 5 thousand capacitors in his salvage work. He dumped the oil from this capacitor on his property. He frequently had PCB oil all over his arms, chest, and body. His clothing was often soaked with this material. He stated that it looked like number 5 weight machine oil. It never occurred to him that there was any danger or any problem from this oil. There were no labels on the capacitors warning about the oil. The only identification on the capacitor was a Westinghouse label with a serial number on it.

The patient stated that he smoked 2 and a half to 3 packages of cigarettes per day for 40 years. He has recently taken little no alcohol. The last time he became intoxicated, he stated, was in 1946. He occasionally does have a single drink but this has never been more than a minimal quantity of alcohol. He states that at the present moment is the heaviness in his legs. He has numbness from his hips to his toes. He had no feeling in the top of his thighs. His feet cramp continuously at night. He has taken various medications, the precise names of which he could not state at the time of this interview. There has been no improvement from the medication. He also has problems with his hands with tingling and cramps. He states that when he grips the steering wheel in his car, his hands go into spasm. After he has been driving for an hour to an and a half hour he cannot let

WATER_PCB-SD0000032529

go of the wheel. Mr. Caves also indicates that that he frequently becomes short tempered and cannot control his temper. He becomes hyperactive and he also notes that he has both recent and long term memory loss.

Family history:

His father died at age 78 of a stroke; his mother died at 68 of natural causes. He had 6 siblings, 4 boys and 2 girls; 1 brother has died of a heart attack; 1 brother died in an accident; his youngest brother recently died of a heart attack; 1 brother and 1 sister are still alive.

Medications:

His current medication use includes arthritis medication, bone medication of some sort, [he is not sure of the exact nature], Tagamet and an antacid.

Review of systems:

He has complaints concerning rash which has been present since the late 1960's. This is particularly troublesome on his hands, but he has also had problems on his feet and legs as well. Occasionally he has an outbreak of the rash on his thighs. His head and neck; there are no specific complaints. Chest: Mr. Caves complains of shortness of breath, with one to 2 blocks of walking on the flat. He is unable to climb more than one flight of stairs. He has a very productive cough with thick yellow to brown mucus. His abdomen and appetite are normal. He believes that he has gained a great deal of weight and that his protuberant abdomen is a relatively recent finding. His GU: see present illness. Extremities: see present illness. Neurological: the patient has complained that headaches have been present almost continually for approximately 10 years. There is a severe, frontal pounding headache which radiates to the back of the neck. There is no nausea, vomiting, or migraine type aura noted. Headaches last from 2 hours to an entire day. Tylenol has been some help. He has taken considerable amounts of this medication. The patient has also complained of loss of memory, tingling, and various other abnormalities as detailed in the present illness. Coordination has been a problem. He believes that he is considerably less steady than he was previously, and that he has a tendency to fall. Bones and joints: see present illness.

Physical Examination:

The patient was a pleasant, well developed, moderately obese, white male in no acute distress. Blood pressure was 120/86; pulse 80; respirations 19; and the temperature 97.7. The skin showed much actinic damage on the head and neck. There were comedones on the face, neck and back. There was a

WATER_PCB-SD0000032530

moderate raised small red rash in a number of areas in the lower extremities. Examination of the head, ears, eyes, nose and throat was unremarkable except for the largely edentulous mouth. The chest was moderately hyperexpanded, air entry was very poor, the chest was very quiet. There were rales and ronchi in all lung fields. The ronchi cleared on coughing but the rales were fixed and persistent. There was a faint rub in the right lower lung field. Examination of the heart revealed a regular sinus rhythm. There were no thrills, rubs or murmurs noted. The abdomen was protuberant, but was soft, and non-tender. The liver, spleen, and kidneys did not appear to be enlarged. Examination of the GU system revealed a normal male. Examination of the extremities revealed that the joints at the knees, elbows, and wrists were quite painful on motion. Muscles of both upper and lower extremities were extremely tender to touch. The muscles of the back in the upper spinal group, and along the spine were also very tender. Neurological examination revealed the patient to be alert and oriented. The cranial nerves appeared to be intact. The sensory examination revealed decreased pin prick throughout the lower extremities. Sharp was interpreted as dull, and the pinwheel sensation was stated to be highly variable. Motor examination appeared to be normal except for painful muscle contraction. Reflexes were 2+ and equal throughout. The cerbellar examination revealed some tendency to fall when tandem walking was done. The tendency to fall was not consistently to either side. The lymph nodes were not enlarged.

The physical examination revealed an elderly, white male with obvious skin damage of a chronic nature, due to sun and PCB exposure. In addition, there is evidence of marked muscle tenderness, and neurological abnormality. The patient has significant chronic obstructive pulmonary disease which is very likely related to his long term exposure to cigarette smoke.

Diagnoses:

1) Toxic syndrome 2° to PCB with:
   a) Chloracne
   b) Skin cancer
   c) Peripheral neuropathy
   d) cognitive defect
   e) Type 2 B psycho-organic syndrome
   f) Myofascial syndrome
   g) Mild coporporphyrinuria
   h) COPD
   i) Neurasthenic syndrome
   j) Action dystonia
2) Actinic skin damage
3) Peptic ulcer disease by history

WATER_PCB-SD0000032531

Name: JUNIOR CAVES Date of birth: 05/29/26

I have reviewed and considered the clinical note of Dr. Daniel T. Teitelbaum. In addition, I have noted the following history from Mr. Caves.

This 60 year-old man worked as a laborer for many years. Between 1967 and 1978 he salvaged canisters containing oils containing PCB's. He now has problems with shortness of breath, headaches, joint pains, numbness of his thighs, problems with coordination and memory loss, and impotence. He had acne as a teenager but this cleared. During the time he was in contact with oils he had frequent whiteheads and pimples on his face and upper body. He also has had a skin cancer excised from his nose and a bone cyst removed from the left foot. There is no family history of skin disease.

whiteheads are not PCB

Examination reveals mottling and wrinkling of the skin of the face, neck, and arms. He has a few scattered comedones on the posterior neck and a few small depressed scars on the right cheek. There is a scaly macule on the right side of the forehead. The skin of his arms and legs is dry and scaly and he has scaly patches on both elbows. There are multiple small white scars on the forearms. He has a linear white streak with thinning of the nail plate involving the nail of the left third finger. There is scaling and slight redness of the soles and toe webs of both feet. All of the toenails on the right side and the nails of the left first, third, fourth, and fifth toe are thickened and whitish discoloration and subungual debris. There is a 1 x 1 cm flesh colored soft nodule on the right buttocks.

I have examined and evaluated Mr. Caves with reference to his possible dermatologic problems. I have likewise reviewed various hospital, medical, and related records of Mr. Caves. Also, I have performed a potassium hydroxide preparation of scale taken from the right third toe web.

where are these hosp. records

Based upon my examination, the test indicated, and various portions of the records, it is my opinion that Mr. Caves suffers from:

1. Chloracne with residual comedones and scarring
2. Actinic keratosis, right forehead
3. Skin cancer, by history
4. Ichthyosis, possibly acquired, involving arms and legs
5. Scarring, arms secondary to trauma incurred at work
6. Heller's median canaliform dystrophy, left third fingernail
7. Solar elastosis, face and arms
8. Nevus, probably intradermal, right buttocks
9. Dermatophytosis of feet and toenails

00096

WATER_PCB-SD0000032532

I also have considered the relevant medical and scientific literature regarding exposure to PCBs, dibenzofurans, and dibenzodioxins and certain adverse health effects associated with exposure to those chemicals. It is my further opinion that the following diagnoses are related to, ie.e. caused or contibuted, Mr. Cave's previous exposure to PCBs and/or their contaminants:

1. Chloracne with residual comedones and scarring.
2. Actinic keratosis, right forehead
3. Skin cancer, by history
4. Ichthyosis, possibly acquired, involving arms and legs
5. Scarring, arms secondary to trauma incurred at work
6. Dermatophytosis of feet and toenails

where is just fear

These opinions are within a reasonable degree of medical probability.

Edgar B. Smith

Edgar B. Smith, M.D.
Professor and Chairman
Department of Dermatology
University of Texas
Medical Center
Galveston, Texas 77550

WATER_PCB-SD0000032533

THE UNIVERSITY OF ROCHESTER
MEDICAL CENTER
300 CRITTENDEN BOULEVARD
ROCHESTER, NEW YORK 14642
AREA CODE 716
SCHOOL OF MEDICINE AND DENTISTRY · SCHOOL OF NURSING
STRONG MEMORIAL HOSPITAL

Eric D. Caine, M.D.
Associate Professor of Psychiatry and Neurology
Director, Ambulatory Services
Director, Neuropsychiatry Program
(716) 275-3571

NEUROPSYCHIATRIC EVALUATION

NAME: Junior F. Caves
DOB: 9 May 1926

Thank you for the opportunity to evaluate Junior F. Caves, who I assessed on 27 February 1987. In addition to examining Mr. Caves, I reviewed and considered the clinical note of Dr. Daniel T. Teitelbaum. I have also reviewed various hospital, medical, and other related records of Mr. Caves.

Mr. Caves underwent a comprehensive neuropsychiatric evaluation. This evaluation included administration of the Neuropsychological Symptom Checklist (NSC), the 28-item version of the General Health Questionnaire (GHQ), the abbreviated version of the Beck Depression Inventory (BDI), the revised 90-item version of the Hopkins Symptom Checklist (SCL-90-R), and a semi-structured interview using the Schedule for Affective Disorders and Schizophrenia - Lifetime Version (SADS-L), with the Global Assessment Scale (GAS).

The NSC is a general, qualitative (non-quantitative) symptom inventory useful for preliminarily assessing patients with possible neurological, emotional, or intellectual dysfunction. The GHQ is used typically in medical, non-psychiatric settings to establish the presence of clinically prominent emotional distress. The BDI is used to establish the overall severity of depressive mental symptoms, which can be grouped as mild, moderate, or severe. The SCL-90-R is used in a variety of clinical settings, most often for defining problems in patients having behavioral or emotional symptoms. From data gathered using the SADS-L interview, it is possible to develop a standardized, rigorous lifetime psychiatric diagnosis, where applicable. The GAS is useful for establishing the overall level of current disease severity and functional impairment due to psychopathology.

Mr. Caves was also evaluated with an array of standardized neuropsychological tests to assess his intellectual functioning. These tests included assessments of orientation, attention/concentration, verbal and nonverbal memory, visuospatial abilities, language/reasoning, and motor/"executive" functions.

Based upon my examination, including the tests that I have indicated, as well as Mr. Caves's records and Dr. Teitelbaum's evaluation, it is my opinion that Mr. Caves suffers from a neurasthenic syndrome, associated with neuropsychological impairments indicative of mild central nervous system

Where is this shown

00099

WATER_PCB-SD0000032534

RUSH-PRESBYTERIAN-ST. LUKE'S MEDICAL CENTER 1653 WEST CONGRESS PARKWAY, CHICAGO, ILLINOIS 60612

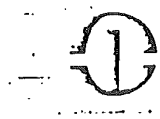

DEPARTMENT OF NEUROLOGICAL SCIENCES

19 March 1987

Thomas W. Henderson, Esquire
Henderson & Goldberg, P.C.
1030 Fifth Avenue
Pittsburgh, PA 15219

RE: Junior Caves

Dear Mr. Henderson:

I have reviewed and considered the clinical report of Dr. Daniel T. Teitelbaum.

I have examined and evaluated Mr. Caves with reference to his possible neurologic problems. I have likewise reviewed various hospital, medical and related records supplied by your office. I also obtained a history at the time of the neurologic examination which I performed.

Based upon my history and examination and supported by various portions of the records, it is my opinion that Mr. Caves suffers from:

1. Postural tremor and terminal intention tremor (action tremor);
2. Action dystonia;
3. Peripheral neuropathy;
4. Cerebellar ataxia and;
5. Psychoorganic syndrome, including neurasthenic syndrome.

Come he share there.

I also have consdered the relevant medical and scientific literature regarding exposure to PCBs, dibenzofurans, and dibenzodioxins and certain adverse health effects associated with exposure to those chemicals. It is my further opinion that Mr. Caves's previous exposure to PCBs and/or their contaminants caused or contributed to all of the above diagnoses.

These opinions are with a reasonable degree of medical probability.

Sincerely,

Harold L. Klawans, M.D.
Professor, Neurology & Pharmacology

/gl

1725 W. Harrison, Suite 915, Chicago, Illinois 60612, (312) 942-5936

00100

WATER_PCB-SD0000032535

HARRIS BUSCH, M.D., PH.D.
PROFESSOR AND CHAIRMAN
DEPARTMENT OF PHARMACOLOGY
BAYLOR COLLEGE OF MEDICINE
TEL. (713) 790-4457
1200 MOURSUND AVENUE
HOUSTON, TEXAS 77030

EXAMINATION
Dr. Harris Busch
Dr. Frank Smith

CAVES, Junior
March 23, 1987

Mr. Caves is 63 years of age with major complaints of rather difficult to describe abdominal discomfort, impotence, and chronic shortness of breath associated with chronic cough and usually clear sputum production. He has no hemoptysis, chest pain, or other pulmonary symptoms. He has been a heavy smoker of 1-1/2 to 2 packs of cigarettes per day for 50 years. Multiple other medical complaints have been listed by Mr. Caves including some discomfort in the knees and ankles as well as the elbows.

He indicates he has pains in his knees, elbows, ankles, and accordingly, x-rays are being made of these regions. No external evidence was found of arthritic lesions or other aberrations. He has dry skin, especially on the legs, and brittle toenails. He also has cramps in his legs as well as numbness. His numbness occurs when his legs are crossed and this is relieved by standing and shaking. He also takes Tylenol. Although he has bowel trouble, Metamucil is helpful to him. He continues to smoke approximately 2-3 packs per day.

On physical examination, Mr. Caves was found to have a blood pressure of 140/90 and weighs 215 pounds. His respiratory rate is 10 per minute and his pulse rate 90 per minute and regular. He is somewhat plethoric and moderately obese on physical examination. There is no adenopathy in the neck. There is some increase in AP diameter of the chest but the lung fields are clear. There are no murmurs, rubs, or gallops on cardiac examination. The liver is 11 cm. in overall dimension and there is no splenomegaly. The abdomen is somewhat protuberant but there is no ascites. He has rather dry skin and venous stasis in both legs. His CBC and SMA-13 are all normal.

X-ray examination of the knees and elbows revealed no significant degenerative changes. No bone or joint abnormality was noted.

Preliminary Diagnosis

1. Chronic bronchitis
2. Venous stasis

WATER_PCB-SD0000032536

Caves, Junior F.
WM 60
3-24-87

CC & HPI:

This divorced 60 year old white male salvage worker states that he was essentially well in every aspect until he "come down sick in 1983" with multiple illnesses which he attributes to PCBs. Current complaints include the following:

Numbness and pains in his feet and legs bilaterally, cramps in his legs, with chronic weakness. "They play out." He "couldn't walk a city block." He reports that his thighs go numb when he walks, and that they hurt constantly.

A skin rash, on both feet and legs and both forearms. His skin stays rough. The skin on his hands "tears like paper."

Nausea and vomiting, for no particular reason. Sometimes even hot water will cause him to become nauseated and to vomit. This complaint is intermittent, not associated with food intake or any other physical activity or cause of he which he is aware.

Most importantly, his sex life has decreased steadily since 1983, until his present status, of total impotence. "I haven't had sex in the past 4 years."

Pt reports that when he cuts himself healing is extremely slow.

His fingers cramp. His joints ache constantly.

He reports decreasing memory, especially over the past 4 years; he forgets where he puts things, and may be totally unable to find his belongings when he needs them. At times he buys groceries and other items that he already has and wouldn't need to buy at all. A lesser complaint is that he cannot remember names, places and dates with any facility at all.

There is serious sleep disturbance. Pt goes to bed at 10:30 p.m., is usually able to go to sleep without difficulty but awakens between 1 and 2 a.m. and again between 4 and 5 a.m. and tosses and turns until he finally gets up at 6 a.m. Occasionally he naps during the day, but limits it to 45-60 minutes so he will have a better chance of sleeping well at night.

WATER_PCB-SD0000032537

The pt denies specifically any feelings of depression, present or past tendency to weep, despair or any present feelings of hopelessness or helplessness. In fact his attitude is just the opposite. He maintains that he has a significant zest for living and looks forward to a long life yet, worrying only that inflation will eat up his meager, fixed income ($360.00 monthly). He is still very interested in his hobbies of fishing and hunting, although weakness will not allow him to hunt any more.

There has been no loss of appetite, and no weight loss.

Pt's medications are limited to Tylenol, only, because his straitened financial condition requires him to get his medicines through the VAH, and they will dispense no other medication.

Pt remembers having seeing a psychiatrist 7 years ago, but remembers no details. He states that he "probably" went to the VAH, but can't remember anything else, except that he "probably" received no medications.

Past Med. Hx:

Pt has been hospitalized 4 times:

1. 1965 for hemorrhaging ulcer, tx at VAH, with no recurrence.
2. 1983 and again 1984, tx at VAH for abdominal pain and the associated, aforementioned nausea and vomiting. Reports that the doctors couldn't find anything wrong and consequently prescribed no tx.
3. 1985 VAH for open wrist reduction.

ROS:

In addition to the complaints listed under the HPI, the pt complains of the following:

1. Headaches: All over, without lateralization or distinguishing features or pattern. Treated with Tylenol.
2. Mouth: Excessive dryness
3. Eyes: Vision going downhill steadily; needs new glasses.
4. Sense of smell: Reported to be absent, accompanied by a poor taste.
5. Respiratory: Complains of SOB for the past 1 and 1/2 years duration. Sleeps on one pillow. Rather constant, unchanging.
6. Cardiovascular: NSA
7. GI: No complaints following his 1965 operation for bleeding ulcer. States that his appetite is slightly diminished, but there is no weight loss. He stays bloated, however; "everything bloats me."

WATER_PCB-SD0000032538

8. GU: Impotence as above. Also complains of urgency. Has nocturia x2 and oftentimes may dribble on the way to the bathroom, uncontrollably.

Habits: Tobacco: 30 cigarettes per day x 40 years.
Alcohol: none. Has consumed very little alcohol during his lifetime because of lack of money. "I was raised poor, and I'm still poor. It takes money to drink."
Drugs: none

Significant Social HX:

Pt was born and grew up in a rural area in southern Indiana, near Salem. Family consisted of father, mother and 6 siblings. They were very poor, and all worked very hard on the farm. Because of their poverty he was allowed to attend school only through the 2nd grade. After that time he worked on the farm, raising tomatoes, and tobacco, and as he got older splitting rails and hewing crossties. He describes his childhood as "hard." At age 17 he "just got fed up and left."

After working for the ICRR in Chicago, doing track labor for a while, the pt was drafted into the army. He served 4 months, in 1944, during which time he worked on a railroad. He was discharged because of his poor education, with the rank of private. Honorable discharge.

After World War II the pt worked in a shipyard for the navy for a time, then got married and shortly thereafter opened his own salvage business in Bloomington, Indiana, which he operated steadily until he went on disability in April, 1985.

The pt has been married 3 times: #1, at age 20, married his first wife, 28 years of age. They were married for 28 years, had 6 children, all living and well, and then the marriage "fell apart and I got a divorce."

Marriage # 2, 1974. Divorced herin 1978, for infidelity. She is stated to be 10 years younger than the patient.

Married wife #3 in 1980. He was 54, she 28. He states that she left him after 5 days, but returned off and on for 30 days at the time for several "repeats." They are no longer married but she continues to visit him from time to time.

The pt was put on social security disability in April, 1985 because his physical disabilities rendered him unable to work. He reports that he salvaged copper cannisters which contained PCB in the early 1980s, which was his introduction to the PCBs.

WATER_PCB-SD0000032539

Arrests/legal Encounters:
Pt was arrested and served 1 year at Pendleton Reformatory, Indiana, for nonsupport of his wife and three children, in the 1950s. States that he thought he was sending the money through his landlady, but she was in fact keeping it.

Served 55 days on the Indiana State Farm (dates unknown) for possession of stolen junk. States that it was really his brother-in-law's fault, that he was ignorant of the events and therefore innocent.

MS Exam:

Pt is a well-developed slightly obese white male appearing of stated age who is appropriately dressed. He entered into the interview situation with some anxiety but nonetheless cooperatively and as it progressed became relaxed. His demeanor showed no abnormalities. Speech was normal, without hesitation. He gave his history in a logical, coherent fashion. Mood was neither elevated nor depressed; affect was congruent to mood. Thought processes showed no blocking, tangentiality, circumstantiality, paranoid ideation or other aberrant or disruptive process and no secondary manifestations such as hallucinations or delusions. He is not ruminative. He states that his greatest worry is about the future, adding "off the record" that his income is so small that he worries about what he is going to do in the future, considering the number of persons who need disability at the present time, and the current rate of inflation.

There is no sign of organically-based brain dysfunction in this pt, although admittedly his fund of information is low, which seems largely to be on the basis of his educational and social deprivation. He was able to name the presidents from the present back through FDR. He missed the name "Nixon" but identified him as "the one who got pitched out." When one talked about the army, about the salvage business, or matters similarly within his purview, he seemed adequately informed, as did he when discussing radio programs of the 1930's and current TV programs.

Attention span was not impaired. On arithmetic calculations he was unable to carry our serial 7s but was able to describe tonnage, convert pints into quarts and do simple calculations with which he had been associated in his work.

There was no overt sign of concreteness, although it was difficult to evaluate his interpretation of proverbs because of his low educational status.

Judgment and insight appeared normal. He gave reasonable answers to questions of fire in the theatre, a leaking ferry.

WATER_PCB-SD0000032540

In Summation:

Pt gives the bodily complaints innumerated under HPI and the ROS. There is no sign of significant anxiety or of depression, although he is admittedly worried about his physical status, particularly the impotence, and about his uncertain financial future. There is no disturbance of thought process and no abnormality of thought content. Cognitive functioning is within normal limits for his age and status.

Impression:

No psychiatric diagnosis

WATER_PCB-SD0000032541

HARRIS,BU [illegible] PH D
HARRIS,BU [illegible] PH D HA
HARRIS,BU

(0000)1091939-7-7082
SEX M AGE 60 YRS
PRINTED: 25MAR87 06:39

SPECIMEN DATE	23MAR87
WEEKDAY/DAY OF STAY	MON 1
TIME	1635HRS

CHEMISTRY

REFERENCE RANGE		TEST	
-- ELECTROLYTE/PROFILE CHEMISTRIES --			
8-	24 MG/DL	BUN	16
0.5-	1.5 MG/DL	CREATININE	1.4
65-	110 MG/DL	GLUCOSE	95
4.0-	9.0 MG/DL	URIC ACID	4.9
8.7-	10.7 MG/DL	CALCIUM	9.4
2.5-	4.5 MG/DL	PHOSPHORUS	3.0
6.0-	8.4 G/DL	TOTAL PROTEIN	6.5
3.5-	5.1 MG/DL	ALBUMIN	4.0
0.2-	1.2 MG/DL	TOTAL BILIRUBIN	0.2
30-	115 U/L	ALK PHOS	77
5-	40 U/L	ALT (SGPT)	25
5-	35 U/L	AST (SGOT)	11
75-	200 U/L	LD	125

* = VALUE OUTSIDE REFERENCE RANGE
# = RESULT CORRECTION

WATER_PCB-SD0000032542

HARRIS,BUSCH,M D ,PH.D.
HARRIS,BUSCH,M D.,PH.D. HA
HARRIS,BU

(0000)1091939-7-7082
SEX M AGE 60 YRS
PRINTED: 25MAR87 06:39

SPECIMEN DATE	23MAR87
WEEKDAY/DAY OF STAY	MON 1
TIME	1635HRS

HEMATOLOGY

REFERENCE RANGE		TEST	
-------- BLOOD CELL PROFILE --------			
4.5-	11.0 K/UL	WBC	8.1
4.40-	6.00 M/UL	RBC	4.98
14.0-	18.0 G/DL	HGB	15.9
41.0-	51.0 %	HCT	45.4
82.0-	100.0 FL	MCV	91.2
27.0-	34.0 PG	MCH	31.9
32.0-	36.0 %	MCHC	35.0
----- BLOOD SMEAR PERCENT DIFF -----			
35-	65 %	SEGS	50
0-	11 %	BANDS	11
25-	45 %	LYMPHS	31
0-	10 %	MONO	7
0-	5 %	EOS	1
------ BLOOD SMEAR MORPHOLOGY ------			
		PLT ESTIMATE	ADEQUATE
		ATYPICAL LYMPHS	FEW

* = VALUE OUTSIDE REFERENCE RANGE
@ = RESULT CORRECTION

The Methodist Hospital
Department of Pathology
Houston, Texas 77030

Cumulative Pathology Report

00108

WATER_PCB-SD0000032543

PH D
PH D
HARRIS,BU

(0000)1091939-7-7082
SEX M AGE 60 YRS
PRINTED: 24MAR87 06:37

SPECIMEN DATE	23MAR87
WEEKDAY/DAY OF STAY	MON 1
TIME	1635HRS

HEMATOLOGY

REFERENCE RANGE		TEST	
-------- BLOOD CELL PROFILE --------			
4.5-	11.0 K/UL	WBC	8.1
4.40-	6.00 M/UL	RBC	4.98
14.0-	18.0 G/DL	HGB	15.9
41.0-	51.0 %	HCT	45.4
82.0-	100.0 FL	MCV	91.2
27.0-	34.0 PG	MCH	31.9
32.0-	36.0 %	MCHC	35.0
----- BLOOD SMEAR PERCENT DIFF -----			
35-	65 %	SEGS	50
0-	11 %	BANDS	11
25-	45 %	LYMPHS	31
0-	10 %	MONO	7
0-	5 %	EOS	1
------ BLOOD SMEAR MORPHOLOGY ------			
		PLT ESTIMATE	ADEQUATE
		ATYPICAL LYMPHS	FEW

* = VALUE OUTSIDE REFERENCE RANGE
# = RESULT CORRECTION

Methodist

The Methodist Hospital
Department of Pathology
Houston, Texas 77030

Cumulative Pathology Report

00109

Cumulative Report

WATER_PCB-SD0000032544

Barry L. Horowitz, M.D.
James E. Harrell, M.D.
Chief of Radiology Services
M.E. Sandlin, M.D.
Pliny C. Smith, M.D.
Morris Weiner, M.D.

FINAL CONSULTATION REPORT
03-24-87

NAME: LAVES, JUNIOR
ID #: 10019397
ORDERING MD: BUSCH, HARRIS MD
PAY ADDRESS:

SEX: M
DOB: 05-09-1926
ROOM #: S/T OP
EXAM DATE: 03-23-87

EXAM: HIP JOINT (4 VIEWS)
BOTH HIPS

ORDER #: 410721

Also includes #410722, Right Knee, 3/23/87
#410726, Left Knee, 3/23/87
#410727, Right Elbow, 3/23/87
#410728, Left Elbow, 3/23/87

IMPRESSION:

No significant degenerative changes are present. No bone or joint abnormality is noted.

ORDER #: 410720 Exam: CHEST (2 VIEWS)
PA & LATERAL

IMPRESSION:

The lungs are slightly hyperinflated. The heart and pulmonary vessels are normal in appearance without evidence of infiltrate. Granuloma and calcified right hilar nodes are noted compatible with old granulomatous disease, without evidence of present activity. Bullous disease is present in both lung apices.

kls 03-24-87

SAX, STEVEN L., M.D.

Methodist

The Methodist Hospital

Department of Radiology
6565 Fannin
Houston, Texas 77030

00110