

EXHIBIT 188

EXPERIMENTAL STUDIES OF ASBESTOSIS*

by

Arthur J. Vorwald
Thomas M. Durkan
Philip C. Pratt

from

The Saranac Laboratory

of

The Edward L. Trudeau Foundation

June 1, 1950

*This series of studies of asbestosis, initiated at the Saranac Laboratory more than twenty years ago by the late Dr. Leroy U. Gardner, director of the Laboratory, was nearly completed at the time of his death in October 1948. Although partial reports and informal reviews of some of the experiments had been given from time to time by Doctor Gardner, this paper presents for the first time a complete survey of the entire experimental investigation.

I N T R O D U C T I O N

Asbestosis is a form of pneumoconiosis resulting from prolonged inhalation of asbestos dust. The name asbestos, literally "unburnable," is not that of a specific mineral but is a term applied to a number of different minerals whose characteristic feature is a structure composed of long, parallel, flexible fibers. This structure is unique because the fibers are capable of repeated longitudinal subdivision to units of molecular proportions. In length the fibers vary from a few microns to six or more inches. Some varieties are stiffer than others but many are sufficiently flexible to be spun into yarn and woven on modified textile machinery.

The asbestos minerals are silicates of variable composition and belong to the serpentine and the amphibole groups. Listed below are the more common varieties.

Amphibole Group

Actinolite	Anthophyllite
Amosite	Crocidolite
Amphibole	Tremolite

Serpentine Group

Chrysotile

The bulk of the asbestos of commerce is chrysotile, $3MgO.2SiO_2.2H_2O$, which is mined on this continent principally in the Thetford region of the Province of Quebec and in Vermont. Crocidolite and amosite also are

used commercially but in much smaller amounts. Chrysotile occurs as veins in serpentine, a mineral of similar chemical composition, which exists in massive form and is made up of microscopic fibers without the parallel orientation characteristic of chrysotile. The massive bluish-black serpentine, which is smooth and soapy to the touch, is traversed by veins of fibrous chrysotile varying in width from a barely perceptible line to six or more inches. The fibers run across the vein and not lengthwise with the formation.

Attention is directed to the mineral brucite, $MgO \cdot H_2O$, which is often found in the same formations with serpentine and chrysotile and may be fibrous in structure. Except for the manufacture of magnesium, brucite has no commercial value at present because its fibers are not sufficiently flexible to be used in textiles, but they are capable of repeated longitudinal subdivision. Unlike other asbestiform minerals, brucite is not a silicate and for this reason it has been a valuable tool in an experimental evaluation of the action of fibrous minerals upon lung tissue.

E X P E R I M E N T A L A S B E S T O S I S

For many years studies[1,2] have been carried on at the Saranac Laboratory in an investigation of the cause, nature and development of asbestosis. The present paper is devoted to experimental asbestosis and in it

---

1. Gardner, L.U. and Cummings, C.U.: Studies on Experimental Pneumoconiosis. VI. Inhalation of Asbestos Dust. J. Indust. Hyg. 13: 65, 97, 1931.

2. Gardner, L.U.: Chrysotile Asbestos as an Indicator of Subtle Differences in Animal Tissues. Am. Rev. Tuberc. 46: 702, 1942.

are described the animal experiments with various kinds of asbestos dust. Another report, to be prepared and issued at a future date, will be concerned with human asbestosis and will cover the health aspects of workers who have been exposed to asbestos dust in an industrial environment.

Although asbestosis in man is a chronic disease with diffuse pulmonary fibrosis which requires years to develop, it is possible to reproduce in one or more species of animal characteristic tissue changes which are similar to the lesions of human asbestosis, (fig. 1). Since the life-span of the experimental animal is relatively short, it is not possible to develop the characteristic lesions in animals under conditions identical with the usual industrial environment. Consequently, to obtain a complete evaluation of the tissue response to inhaled particulate and fibrous material, it is necessary to accelerate the reaction by employing higher concentrations of dust than would ordinarily be encountered in industry. While conditions of exposure are thus different, the information yielded by experiments with animals is invaluable in furnishing a better understanding of the reaction of the human organism to inhaled asbestos dust.

Experimental Methods. For investigating the tissue reaction of the experimental animal to the various asbestos minerals, two types of technique have been employed, namely, the inhalation method and the injection method. In inhalation experiments, groups of animals - up to 100 or more guinea pigs and sometimes smaller numbers of rabbits, cats, dogs, rats or mice - are kept for ~~eight~~ 7 hours a day in a cubical dust room, ~~eight~~ 8 feet in dimension, in which a cloud of asbestos dust is maintained by a rotating

paddle in a dust hopper[1]. At intervals during the experiment, a few animals are sacrificed and the tissue examined to determine the nature and extent of the dust reaction. Some animals are exposed for periods up to three years. The injection experiments are used to determine in as short a time as possible whether or not a particular dust has a potential capacity to produce inflammatory reaction when in direct contact with tissues of the body. The method involves injection of the dust, either dry or suspended in fluid, into the animal by the intravenous, the intraperitoneal, intratracheal, or other routes.

Long-term inhalation experiments furnish information upon which great reliance is placed when estimating the degree to which a dust might constitute a respiratory hazard to industrial workers. Even though an atmospheric dust may be potentially dangerous, as indicated by injection experiments, only inhalation procedures will reveal whether the dust can be inhaled, pass the natural defense barriers of the body and reach the pulmonary tissue in quantities sufficient to cause damage. Injecti methods are useful, however, because they make certain that contact occurs between the dust particles and tissues and because they allow accurate estimation of the dosage and of the potential capacity of that dose to produce reaction. The intratracheal method is particularly valuable when dealing with fibrous minerals like asbestos, since it permits observation of the effect of the fibers on pulmonary tissue.

Tissue susceptibility. Unlike free silica, asbestos does not produce specific effect in all organs of all species of animal. Comparative

data, presented in table 1, is based upon completed observations and therefore differs slightly from a preliminary report[2]. Introduction of fine quartz into various organs of the guinea pig, rabbit, rat, mouse, cat, dog, chicken and even tadpole eventually will produce silicotic nodules but at a different rate of development. Similar introduction of ~~long-fiber~~ asbestos has resulted in a fibrous reaction in the lung and, to a lesser extent, in the peritoneum but not in other organs of the guinea pig, rabbit, cat and white rat. In our experience the lungs of the dog and white mouse failed to respond with fibrosis although Schuster[3] has reported such changes in a dog that lived in an asbestos fabricating plant. This variation in species and in organ susceptibility is yet to be accounted for[4]; it is presumed that in the susceptible animals the greater reaction of the lung to asbestos, far exceeding the reaction of other organ tissues, is due principally to the greater mobility of the lung.

Peculiar Characteristics of Asbestos. Experience has demonstrated that most of the non-fibrous particulate dust inhaled into the lungs of man and animal is 10 microns or less in maximum dimension. Larger particles apparently do not gain access to the lungs because of two reasons: first, large particles settle in air so rapidly that few remain suspended

---

3. Schuster, N.H.: Pulmonary Asbestosis in a Dog. J. Path. and Bact. 31: Part 2, 751, 1931.

4. Vorwald, A.J.: Variations in Individual Susceptibility to Industrial Dusts Inhaled into the Lungs. Am. Rev. Tubere. 62: 13, 13, 1950.

in the atmosphere breathed; second, large particles are more effectively removed by the protective mechanisms of the upper respiratory tract. In the case of fibrous materials these factors have less influence and fibers 100 and even 200 microns in length have been found in the terminal air spaces of human lungs. In small laboratory animals exposed to asbestos dust the maximum length of fiber found in the lung rarely exceeds 50 microns.

A large proportion of non-fibrous particulate dust inhaled into the lung is found in the terminal air spaces (alveolar duct, atrium, alveoli) in all parts of the organ; in contrast, inhaled asbestos fibers are first discovered in the respiratory bronchioles. These small passages are immediately distal to bronchioles lined by ciliated epithelium[6]. Their own essential lining is a low cuboidal type of epithelium but, as their name implies, they actually function in respiration through lateral alveoli distributed along their walls. Either these alveoli or the abrupt change in the character of the lining epithelium or the small diameter of the respiratory bronchiole or the combination of all three factors is responsible for retention of the fiber at this site. Only after asbestosis is well established are appreciable numbers of fibers seen in the more peripheral air spaces. Further explanation is required to clarify this observation.

Rate of Tissue Reaction to Asbestos Fibers. The tissue reaction to asbestos develops much more rapidly than does the reaction to quartz dust.

S. Miller, William S.: The Lung. Charles C. Thomas, Publishers, 1937.

For example, in rats receiving asbestos fibers by intratracheal injection fibrosis of characteristic type is visible as early as one month after injection; for quartz dust the latent period is two months or more. Thus, the development of nodular fibrosis due to inhaled silica lags behind the deposition of dust to a greater extent than does the evolution of the diffuse reaction to asbestos. This results in a difference in the degree of progression which follows termination of exposure to dust. For example, on discontinuing exposure, the nodules of silicosis become larger, to a limited extent, for a considerable period of time, whereas the fibrosis of asbestosis increases for only a short time. Subsequently, the asbestotic fibrosis contracts; this process often distorts the adjacent pulmonary tissue and may result in a progressive interference with cardiorespiratory function.

Asbestosis Bodies. The peculiar structure known as the asbestosis body or "curious body" is a specific concomitant of asbestosis[1,6,7]. The typical body is a golden-yellow, beaded or haustrated rod which may be either straight or curved (Figs. 2 and 3). Often one or both ends are bulbous like a dumb-bell. The bodies vary considerably in length, and dimensions up to 260 microns have been recorded.

It is believed that asbestosis bodies are due to a deposit of protein and iron pigment of tissue origin upon the surface of inhaled fibers

---

6. Gloyne, S.R.: The Formation of the Asbestosis Body in the Lung. Tubercle 12: 398, 1931.

7. Gloyne, S.R.: The Asbestosis Body. Lancet, 1351, June 25, 1932.

(1,2,6,7,8,9). Gloyne[8] reproduced bodies 9 months after subcutaneous injection in guinea pigs of fibers rendered free of iron. The bodies are abundant in man and in the guinea pig (table 1) but are much larger in the former, probably because the larger-sized air passages admit fibers of greater dimension. In guinea pigs they form after about 70 days of contact with the tissue. In cats, rabbits and mice there is an atypical coating of a few of the fibers after much longer retention in the lungs. In rats, bodies are rarely seen and in dogs none could be found. Although the evidence is incomplete, it appears that the formation of the asbestosis body prevents damage to the tissue by the fiber. Many of the points mentioned above will be elaborated upon in subsequent paragraphs dealing with the actual experiments. For presentation our investigation is divided into two sections, one dealing with inhalation experiments and the other with injection experiments.

I N H A L A T I O N E X P E R I M E N T S

Four large-scale inhalation experiments have been conducted in this laboratory with various forms of asbestos dust. In each of these investigations more than 100 animals were used and the experiments were carried on for periods ranging from 2 to more than 5 years. The four kinds of asbestos dust employed are designated as Ring's float, short-fiber, 100 per cent ball-milled, and long-fiber asbestos dust.

---

8. Lynch, K.M. and Smith, W.A.: Asbestosis Bodies in Sputum and Lung. J.A.M.A. 91: 627, 1928.

9. Simson, F.T. and Strachan, A.F.: Asbestosis Bodies in the Sputum: A Study of Specimens from Fifty Workers in an Asbestos Mill. J. Path. and Bact. 33: 1, 1931.

KING'S FLOATS ASBESTOS DUST

The first inhalation experiment conducted at the Saranac Laboratory with asbestos dust was begun in 1928. Animals inhaled the dust for periods up to 33 months. Some guinea pigs with 3 and 9 months' exposure lived for an additional three years after cessation of their exposure. A preliminary report[1] presented observations after 29 months of exposure. At that time observations covered a period of only 2-1/4 years and the conclusions as to the ultimate effects of inhaled asbestos dust were provisional. Those conclusions are substantiated by results of the completed study, which is reported as follows.

Composition and Atmospheric Concentration of the Dust. The dusting material, a commercial variety of asbestos known as King's floats, was composed of short fibers, ranging in length from 1 millimeter to 1 micron or less, and of particles which also varied in size. It was obtained from the Thetford, Quebec plant of the Asbestos Corporation of America and analyses (tables 2 and 3) reveal that the amount of fibrous chrysotile was only 14 per cent, a rather low value. Impinger samples taken soon after the experiment was started indicated that the dust concentration was at first quite low, the average dust count being only 6.0 million particles per cubic foot of air by the standard light-field technique and 0.8 million for particles and fibers greater than 10 microns. After the inhalation experiment had been under way for about two years, the speed of the rotating paddle in the dusting machine was increased and for the remaining 10 months of the experiment considerably more dust was dispersed into the atmosphere. The average dust count of impinger samples collected after this change was 68.7 million by the usual light-field method and 1.6 million for particles and fibers larger than 10 microns. It is probable, however, that the true values of the dust concentration were higher than the counts given in this paragraph. The impinger samples for the King's floats experiment were

collected in water but later studies[10] have shown that counts of impinger samples of asbestos dust taken in water are not reliable. Ethyl alcohol instead of water was used as the collecting fluid in all subsequent experiments.

Results of the investigation, briefly summarized in table 4, show that inhalation of King's floats asbestos dust produced a typical peribronchiolar fibrosis in guinea pigs but not in rabbits or rats.

Reaction in Normal Guinea Pigs. Guinea pigs inhaling this dust for periods up to 33 months developed a characteristic fibrosis occurring in conical patches about the respiratory bronchioles. During this exposure the peripheral alveoli were not involved. The particulate elements in the dust were transported through the lymphatic system to the bronchial nodes, causing no significant reaction in either site; the fibrous elements remained fixed at the points of original localization and were seldom detected in the lymph nodes.

After exposure of approximately a year, a small amount of cellular reaction had been produced about many respiratory bronchioles (fig. 4). As more dust was inhaled, it continued to accumulate in the same location and later stages of the disease (fig. 5) consisted of extensions of the original lesions.

Apparently, the inhaled fibers were caught in the pocket-like alveoli that are given off from the lateral walls of the respiratory bronchioles. There they were phagocytized and many of them were carried into the wall by migratory cells. Mononuclear leucocytes attracted to the area caused an appreciable thickening of the bronchiolar wall. After

---

10. Fulton, W.B., Houtz, R.L., Dooley, A. and Mathews, J.L.: Asbestosis, Part I. The Collection and Counting of Asbestos Dust. Spec. Bull. 37, Penn. Dept. of Labor and Industry, 1934.

16 months a delicate fibrosis made its appearance. The process evolved gradually and the number of fine intercellular collagenous fibers steadily increased. As this fibrosis contracted, it partially closed and distorted the alveoli, and with this change the alveoli became lined with cuboidal cells. The result was an adenoma-like appearance which frequently accompanies chronic pulmonary inflammation resulting from many causes. Willis[10] described a similar structure in the lungs of guinea pigs inhaling silicon carbide. The longer exposures to asbestos resulted only in more thickening of the walls of the air spaces, largely due to an increase in the amount of fibrous. The fibrous tissue always remained cellular and failed to show the hyalinization characteristic of silicosis. Asbestosis bodies (fig. 5), first seen in the lungs of the guinea pigs that had inhaled dust for about 2 months, became more numerous and more distinctly segmented with increasing exposure.

The reaction produced in guinea pigs exposed for 6 and 9 months did not progress significantly during a subsequent period of 35 and 37 months when the animals lived in a normal atmosphere (figs. 6 and 7). Between 8 and 11 months after exposure ceased, the cellular reaction in the lung had been completely replaced by thin strands of fibrous tissue. At later periods, the scar tissue was less in amount but in the last animal sacrificed, 37 months after discontinuing dust exposure, some fibrosis was still visible.

---

10. Willis, H.S. and Brutsaert, P.: Tumor-like Structures in the Lungs of Guinea Pigs Artificially Exposed to Silica Dust. Am. Rev. Tuberc. 17: 209, 1928.

Reaction in Guinea Pigs Infected with Tubercle Bacilli at the Onset of Dust Inhalation. Of the group of 40 guinea pigs infected with attenuated tubercle bacilli, R_1 strain[12 11], at the time that exposure to dust was begun, 31 died or were sacrificed before the completion of two years of dust exposure and were reported in the paper by Gardner and Cummings[1]. Seventeen of these died from intercurrent pneumonia. Briefly, the results were as follows: 10 revealed some evidence of spread of the tuberculous process (fig. 8); in 6 of these it was confined to the lungs and in the other 4 the abdominal viscera also were involved. Extension of the infection was first seen after 7 months of dust inhalation; during the next 20 months more than half of the animals showed an actively spreading tuberculosis and in 3 of them small cavities had developed. During the last 3 months no animals exhibited any evidence of active infection although in half of them the healed fibrous scars of previous spreads were obvious. The scars were more extensive than is characteristic of either tuberculosis or asbestosis alone.

The 9 animals which were still alive after two years of dust exposure were sacrificed at intervals during the following year. In 4 of them the primary foci of infection were healed with fibrosis and even calcification and there was no evidence of progression (fig. 9). In the other 5 the tuberculous foci showed evidence of having previously spread locally; in 4 of them, by the time of autopsy, the foci were healed, with excessive fibrosis; in the remaining animal there was a generalized chronic tuberculous pneumonia in one lobe and in the other lobes there were isolated primary tubercles, which were still active but had not spread.

---

[1] 4. Steenken, W., Jr. and Gardner, L.U.: R_1 Strain of Tubercle Bacillus. Am. Rev. Tubere. 54: 51, 1946.

Reaction in Guinea Pigs Infected with Tubercle Bacilli after Establishment of Asbestosis. Twelve guinea pigs, after inhaling King's floats asbestos dust for 26 months, were infected with tubercle bacilli and then removed to normal air. Six of these animals died within seven weeks, five from intercurrent non-tuberculous infection. The remaining six animals were sacrificed at intervals up to 14 months after infection. The subpleural tubercles in the dusted animals were no more numerous than in non-dusted controls but a considerable number were found in the depths of the lung about foci of asbestosis. The tuberculous component of the combined reaction showed only slight local extension about lesions in the lungs and tracheobronchial lymph nodes. Caseation was found in tubercles 1-1/2 months old, but by 6-1/2 months it had completely disappeared, leaving only scar tissue. Foci of fibrosis still persisted in the last animal, which was killed 14 months after infection.

Reaction in Rabbits. Rabbits exposed to the asbestos dust for periods up to 19 months developed a low-grade foreign-body type of reaction but no fibrosis. Although their lungs contained particulate elements of the dust, fibers were not present, indicating that the upper respiratory mechanism of the rabbit is adequate to exclude fibrous foreign bodies. Two rabbits, after inhaling dust for 8 and 19 months, lived in normal air for more than two years. At autopsy neither animal showed any evidence of cellular reaction or fibrosis in the terminal bronchioles nor were there any asbestosis bodies.

Reactions in White Rats. All the rats had acquired an infection, re-

sulting in the formation of pulmonary abscesses, before they came to autopsy. Apparently, so much heavy mucus obstructed their bronchi that very few fibers could have entered their lungs. In a few of the rats, an occasional asbestosis body was discovered but there was no fibrosis. This phase of the experiment was considered unsuccessful.

Summary and Interpretation of Inhalation Experiment with King's Floats Dust. The findings in the experiment with King's floats dust can be summarized under two headings.

A. Effect of the inhaled dust on normal animals. The King's floats dust caused a characteristic peribronchicler fibrosis in guinea pigs but not in rabbits or rats. The fibrosis did not increase significantly in extent after the dust exposure was discontinued.

B. Effect of the inhaled dust on tuberculosis in guinea pigs. In guinea pigs infected with attenuated tubercle bacilli and then placed in the dust room, the results were more variable than is usual in an experiment of this type. A few animals showed no sign of progression of the infection; in most of them there was evidence of temporary progression with subsequent healing; in one animal the tuberculous process remained active to death. In contrast, when guinea pigs, after being infected, are exposed to quartz dust instead of asbestos dust, the infectious process continues to progress and eventually causes the death of the animals. On the other hand, exposure of infected animals to a harmless dust like iron oxide does not lead to any progression of the infection(12). Guinea

12. Vorwald, A.J., Pratt, P.C., Durkan, T.M., Dalgaard, A.B. and Bailey, D.A.: Siderosis. A benign pneumoconiosis due to the inhalation of Iron Dust. Industr. Med. and Surg. 19: 170, 1950

pigs infected with attenuated tubercle bacilli following the termination of two years' exposure to asbestos dust did not develop progressive disease. The only modification of the infection was in its localization, a few bacilli being retained in the peribronchiolar fibrous tissue with the formation of tubercles there in addition to the usual tubercles beneath the pleura.

In view of the variability in results, the unusual nature of the response and the high proportion of deaths from intercurrent pneumonia, it is felt that only tentative conclusions as to the influence of asbestos dust on the course of tuberculous infection are justified by this experiment.

SHORT-FIBER AND STONE DUST

Since hazardous dusts like quartz are most effective in producing fibrosis when the particles are 5 microns and less in size, an inhalation experiment was performed to determine whether this condition is true for asbestos dust. It was thought that a short-fiber asbestos dust consisting almost entirely of fibers and particles smaller than 5 microns would initiate an accelerated tissue response and produce an advanced reaction in a shorter time than did the King's Floats dust, which contained fibers from 1 millimeter to 1 micron and less in length as well as much particulate matter.

Commercial and Atmospheric Concentration of the Dust. The dusting material for this experiment was the remains of fibers collected in dust bins of an asbestos fabricating plant after a carding operation and

screened to pass 200 mesh. Since the material as received contained many long fibers, it was ground in a steel ball mill to reduce practically all the particles to 3 microns or less in size. When used alone in the standard dusting machine, this finely-ground asbestos tended to pack in the hopper and it became necessary to mix one volume of the unground material with three volumes of the ground to generate a satisfactory dust cloud. It is pertinent to mention here that the addition of the small quantity of unground asbestos was unfortunate because it confused the interpretation of results.

The composition of the short-fiber asbestos as received is disclosed by the chemical and petrographic analyses given in tables 2 and 3. Samples taken before and after grinding yielded about the same values on analysis, indicating that there was no contamination from the mill or loss of water content. The dust concentration varied during the experiment, the light-field counts for atmospheric samples collected inside the animal cages with the impinger apparatus ranging from 33 million to 100 million. The average of counts was 130 million for the first year of the experiment, 134 million for the second year and 140 million for the third year. Size-frequency measurements of air-floated dust from inside the cages at a magnification of 1300X revealed a great preponderance of fine particles, nearly 90 per cent of the particles seen being smaller than 3 microns. It was estimated that approximately 1 per cent of the dust was in the form of fibers greater than 10 microns in length.

Four species of animals - guinea pigs, white rats, cats and rabbits - were used in this experiment. The results of the dust exposure, summarized in table 5, are presented in greater detail below.

Reaction in Guinea Pigs. Eighty guinea pigs were originally placed in the dust room, but 21 of them were later eliminated from the experiment and killed because of enlarged cervical lymph nodes thought to be due to intercurrent upper respiratory infection. Of the other 59 animals, 46 remained in the dust room until they were sacrificed or died at periods up to 31 months and 13 animals were transferred to normal air after being exposed to the dust for 20 months.

The type of tissue reaction to the inhaled short-fiber asbestos was essentially the same as that already observed in the experiment with King's floats asbestos. The rate of reaction also was approximately the same, but the extent of involvement with the short-fiber dust was very much less. After 18 to 24 months of exposure only a very few small foci of reaction, which generally required microscopic examination for detection, were produced in the guinea pigs.

Only after exposures had continued for approximately one year was there an appreciable tendency for dust-containing phagocytes to gather into clumps. By 16 months phagocytes had collected about the walls of a few of the respiratory bronchioles with a little proliferation or infiltration of mononuclear cells in those walls. There were also some multinucleated cells but they were of the inert foreign-body type. At 20 and 24 months the cellular clumps were sometimes quite marked and sometimes changes in the epithelium resulted in the adenoma-like or "adenomatoid" appearance (fig. 5) previously described in the section reviewing the experiment with the King's floats dust. In most of the subsequent members of the series, the reaction remained cellular, but a few exhibited pro-

nounced development of fibrous tissue. In these few, the collagen was pale in color and tenuous with no heavy swollen hyalinization. Diffuse chronic pleurisy without evidence of pulmonary infection was present in a few animals. This suggests that pleurisy may be a specific concomitant of asbestosis, but the evidence is not adequate to establish this point. The reaction in the tracheobronchial lymph nodes was more pronounced than in the previous experiment with Fiag's floats asbestos, probably because of the transportation of more fine particles to the nodes in animals inhaling short-fiber asbestos. The nodal reaction was essentially an increase in reticulum, rather than a fibrosis, with preservation of the original cells between the thickened reticular fibers.

In the other group removed to normal air following 20 months' exposure to dust, progression of disease was not definitely demonstrated but neither could it be absolutely disproved, owing to the variability of the response in different animals. The reactions from mild to severe occurred sporadically and bore no relationship to the length of time after cessation of exposure. The differences were attributed to variation in individual susceptibility. This view received support from the chemical analyses (table 8), which revealed comparable amounts of ash and silica in lungs with widely different amounts of tissue change. For example, the ash and silica values were quite similar for three animals in dust 20 months and then in normal air for 14 months, yet the tissue reaction for one animal was severe; for another, mild; and for the third, only doubtful.

The formation of asbestosis bodies within both groups was at first extremely limited. After 5 months' exposure only a very rare short body

could be found, usually inside cells. Some of the finest intracellular particles were surrounded by yellow deposits having the same color as the asbestosis body. Exposure of one year had permitted an accumulation of many longer fibers, a number of which were coated and seen as typical asbestosis bodies. Most of these were still short enough to be partially or entirely within phagocytic cells. By the 20th month and thereafter they were relatively numerous although still rare in comparison with the findings in the King's floats experiment.

Reaction in White Rats. Seventy-three White rats were exposed to atmospheric short-fiber asbestos dust for periods up to 32 months. Sacrificings during the first 12 months were made bimonthly and for the remainder of the experiment at less frequent intervals. Up to 8 months the dust cells were widely scattered and existed in foci only sporadically. Reaction was limited to occasional slight thickenings of the septa about small accumulations of dust cells. In a few rats at 12 months, there was a suggestion of early fibrosis but the change was so slight that it would probably have been overlooked without the clump of dust cells which attracted attention to the area. Only 10 animals were exposed from 12 to 32 months. In each of them the lungs showed minute foci of well-defined fibrosis distributed like that of asbestosis but without asbestosis bodies. The lesions, visible only at a magnification of 150 diameters or more, consisted of patches of alveolar ducts in which the walls of the dilated air spaces were very thick, due to swollen collagen fibers. Connective tissue and Foot-Bielschowsky silver preparations revealed complete loss of capillary bed locally. Outside the collagen was a thin

layer of epithelial cells. This did not resemble the "adenomatoid" change characteristic of guinea pig asbestosis. Near the lesions the air spaces were filled with phagocytes containing gray to yellow particulate dust and a rare, long, naked asbestos fiber. Careful search failed to reveal even a suggestion of an asbestosis body. Pleurisy was absent. The tracheobronchial nodes showed compact focal collections of monocytic cells at 12 months and, at 20 months, some diffuse thickening of the reticulum. In a few rats there was definite fibrosis along the margins of the node and extending into the mediastinal areolar tissue.

Results of chemical analyses made on the white rats are given in table 7 and the average values have been tabulated in table 8 for comparison with similar values for rats inhaling other dusts. It will be noted that the values for asbestos are lower than those for quartz or chert but approximate those for the gypsum-quartz mixture, in which atmospheric agglutination tended to reduce the amount of dust inhaled. This condition prevailed even though the atmospheric concentration of asbestos dust was essentially the same as that for the quartz, was one-half that for the gypsum-quartz mixture, and was one-fifth that for the ferruginous chert. Since the values for asbestos are low, it might be inferred that the total quantity of that dust actually inhaled was small or that it had been eliminated from or dissolved within the lungs. Evaluation of those possibilities is not feasible on the basis of the observations derived from this study.

Reaction in Cats. Twenty cats were used in this inhalation experiment with the short-fiber asbestos. Eighteen were kept in the dust room

continuously, until sacrificed, the exposure period ranging from one month to nearly 54 months. The other two were removed to normal air after a dust exposure of 31 months; one of these was sacrificed 6 months, and the other 14 months, later. In general, the tissue response was confined to microscopic foci of fibrosis in the walls of groups of subpleural alveoli, rather than in the peribronchiolar areas. In one animal the change was extensive enough to be visualized on gross inspection of the section. Only in the animal with the longest exposure—54 months—did the X-ray reveal definitely abnormal shadows. After 30 months the picture was negative; after 45 months, a faint mottling could be detected throughout both lungs. At autopsy, 9 months later, there was only microscopic fibrosis in the subpleural zone plus heavy lymphocytic infiltration about small bronchioles. Asbestosis bodies were rare. On prolonged search a few yellow atypical bodies, smooth and without haustrations, were found in two animals exposed for more than a year.

Reaction in Rabbits. Eight rabbits were exposed to dust for periods extending from one to more than five years; the last animal was removed from the dust room and left in normal air 6 months before being sacrificed. There was never enough pulmonary fibrosis to be detected grossly and there was no chronic adhesive pleurisy. Microscopic evidence of alveolar wall thickening was first detected in one animal after about 3 years of exposure and was seen in all five animals examined thereafter, including one removed to normal air. One animal, that died of paralysis after nearly four years of exposure, exhibited a reaction visible on gross inspection of tissue sections. The possibility of pulmonary infection in this

animal could not be excluded. In another animal dying two years later the focal fibrosis was not nearly as obvious or as advanced. Areas of involvement, which were largely visualized because of phagocytic reaction within the air spaces, tended microscopically to become more fibrous with the passage of time but there was never much encroachment upon the lumen of air spaces and the architecture of the lung was preserved. Asbestosis bodies were not detected in rabbits that died early in the experiment, but were seen in all animals that had been exposed to the dust for more than three years.

Summary and Interpretation of Inhalation Experiment with Short-Fiber Asbestos Dust. The original purpose of the experiment was to evaluate the role of short asbestos fibers in the pathogenesis of asbestosis. It was felt also that if the tissue reaction to short-fiber asbestos were more rapid and more extensive than to King's floats there would then be basis for believing that the action of asbestos is in part, at least, a chemical one as postulated for quartz. This experiment, in which the tissue reaction was slower and less extensive than that in the previous experiment with King's floats dust, indicates that the capacity of inhaled asbestos fibers to produce fibrosis is determined primarily by factors not chemical in nature.

Of the four species exposed in this experiment only the guinea pig and to a lesser extent the white rat responded with characteristic peribronchiolar fibrosis. The cat reacted with atypical subpleural fibrosis and the rabbit with only slight parenchymal fibrosis.

BALL-MILLED ASBESTOS DUST

In the inhalation experiment with short-fiber asbestos dust a small quantity of unground short-fiber asbestos was mixed with the ball-milled product in order to generate a suitable dust cloud. When that experiment failed to produce an accelerated tissue reaction, in comparison with the response initiated by King's floats, it became apparent that the biological activity of asbestos is not increased by reduction in size of the fibers. Thus the possibility arose that the tissue reaction observed was due solely to the relatively few long fibers in the unground asbestos and that the short fibers of asbestos had no more than a very insignificant role in the production of asbestosis, a concept not in accord with previous experiments concerning pneumoconiosis. Consequently another inhalation experiment was started in which only ball-milled asbestos was used.

Composition and Atmospheric Concentration of the Dust. The dusting material was the ball-milled short-fiber asbestos used in the previous inhalation experiment but unground material was not mixed with it. Owing to the tendency of the material to form small spherules which prevented much of the fibrous portion from floating out of the dusting machine, the dispersal of the dust was not entirely satisfactory. Therefore, after an initial 7 months of operation, steel wire brushes were attached to the inside surface of the hopper and to the rotating paddle to disintegrate the spherules and release the fibers. This arrangement gave satisfactory results and was used for the remaining 21 months of the experiment. The

composition of the raw asbestos used is shown in tables 2 and 3. Petrographic and X-ray diffraction examination of atmospheric dust, collected in the dust room with an electrostatic precipitator after the installation of wire brushes, indicated that about 15 per cent of the air-suspended material was chrysotile and about 60 per cent, serpentine; of the balance magnetite comprised 10 per cent, brucite 5 per cent, quartz 2 per cent and other minerals 10 per cent. During the 7-month period before the wire brushes were used the chrysotile content of the atmospheric dust was somewhat lower than 15 per cent but reliable values were not obtained. The dust concentration for the first 7 months of the experiment was about 100 million particles per cubic foot of air. After the wire brushes were installed, the dust counts were higher and the overall average for the remaining 21 months was about 150 million. Size-frequency studies of atmospheric dust collected inside the animal cages revealed that nearly 99 per cent of the components suspended in the air could be classified as clumps or particles; only about 1 to 1.5 per cent was fibers. One-third to one-half of the fibers were longer than 10 microns, indicating a concentration of long fibers of about 0.3 million. This figure is about one-half the estimated value of 1.4 million for the short-fiber experiment.

Guinea pigs, rats and mice were used in the inhalation experiment with the 100 per cent ball-milled asbestos dust. The results are summarized in table 9.

Reaction in Guinea Pigs. The experiment was started with 100 guinea pigs. As the dust exposure proceeded, there were 20 accidental deaths,

32 of these being due to pneumonia in an epidemic. The 61 pigs remaining exposed to the dust were sacrificed at intervals during exposure, except for 15 guinea pigs transferred to normal air after 28 months of dusting. For the first year of exposure practically the only reaction to the dust was the presence of scattered phagocytes and an occasional minute asbestosis body. At 16 and 20 months no gross response was visible on the tissue section but microscopically peribronchiolar foci of inflammatory cells could be seen. At 24 months (fig. 10) there was still no change large enough to be seen with a hand lens although microscopic examination revealed cellular accumulations about terminal bronchioles and many more asbestosis bodies, chiefly within cells. The lungs of animals exposed for the full dusting period of 28 months and afterwards living in normal air for 2 months revealed the changes described above and also very slight peribronchiolar fibrosis. For exposed animals living 9 months in normal air the findings were similar but at 12 months 3 of 4 animals showed grossly-visible characteristic peribronchiolar fibrosis with adenomatoid change (fig. 11).

The tracheobronchial nodes were essentially negative until exposure had been continued for more than a year and a half. Animals sacrificed at 12 months and at 16 months revealed a few minute collections of phagocytes containing particles but practically no fibers large enough to be recognized as such. After 20 months of exposure many monocytes filled with yellow granules were present. At 30 months there had been a slight increase in reticulum but no fibrosis. No further changes occurred in the nodes. Asbestosis bodies were not seen in the nodes of any of the guinea pigs.

Minute asbestosis bodies were observed in the lungs as early as 3 months after exposure began but they did not become numerous until 16 months had elapsed. The bodies were short and practically all were intracellular although at 20 months some were long enough to project beyond the cell borders. It is important to note that in the later months of exposure there was a distinct increase in the number of long fibers, up to 70 microns in length, in the lungs with the formation of characteristic long asbestosis bodies.

Chemical analyses (table 10) of the lungs reveal that considerable dust had been retained in the lungs. After 24 months of continuous exposure the average value for total silica, per cent of ash, was 25.37. This should be contrasted with the average value of 14.34 (table 6) for animals exposed 24 months to the short-fiber asbestos dust.

In view of the high values for silica obtained for the animals with exposure to the 100 per cent ball-milled dust, it is important to note that their pulmonary response was much less than that in animals exposed for 24 months to the short-fiber asbestos. This again indicates that the biological activity of asbestos inhaled into the lung is not increased by a reduction in size of the fibers.

Reaction in White Rats and Mice. In this experiment 40 rats were exposed for periods up to 20 months and 24 mice for periods up to 12 months. Neither species developed even a suggestion of asbestosis and reaction was limited to phagocytosis of inhaled particles by widely-scattered dust cells which remained free in air spaces or were transported

to the tracheobronchial lymph nodes. No asbestosis bodies were found in the rats but in the mice there were a very few small non-haustrated forms within phagocytes.

Summary and Interpretation of Inhalation Experiment with 100 Per Cent Ball-Milled Asbestos Dust. The tissue reaction observed in this experiment was not as intense as that in the previous investigation with short-fiber asbestos. The reaction was slower in development and less extensive even though more dust accumulated in the lungs. Since there were fewer fibers longer than 3 microns in the material used in this experiment, the results tend to confirm the interpretation made in the summary of the short-fiber experiment that the reaction is not primarily chemical in nature, and to support the impression that reduction in size of asbestos fibers does not increase the biological activity of asbestos inhaled into the lung.

The finding of long asbestosis bodies in animals that had inhaled the ball-milled material is an example of the difficulty of completely eliminating long fibers from a large volume of asbestos as required for an inhalation experiment.

In regard to progression of the tissue reaction after removal of the animals from dust, which was observed in this experiment but not in the others, the following interpretation is offered: When the reaction is well-developed at the termination of exposure, the contraction of the fibrous tissue obscures any progression that may have occurred; in this experiment, however, since the reaction observed was less mature, its subsequent progress was more readily apparent.

Since inhalation of short-fiber and of 100 per cent ball-milled asbestos dust did not result in acceleration of the tissue reaction in comparison with that produced by King's floats, the hypothesis that short fibers of asbestos were of minor importance in the etiology of asbestosis was given added support and attention was directed to the view that the long fibers were of primary significance in that etiology. The King's floats asbestos used in the first inhalation experiment had a rather low content of fibrous chrysotile and contained considerable serpentine and other impurities. Therefore, it was decided to conduct a new inhalation experiment with a purer form of chrysotile which would be richer in long fibers.

Composition and Atmospheric Concentration of the Dust. The asbestos material employed in this investigation was obtained from an asbestos fabricating plant. Samples of several varieties of long-fiber asbestos dust were first submitted to the Saranac Laboratory for examination and one of these, which was low in magnetite and chromite and had a fibrous content estimated to be about 75 per cent, was selected as most suitable. Steel wire brushes, fastened to the inside surface of the hopper and to the rotating paddle, as in the preceding inhalation experiment, were used to open up the bundles of asbestos and liberate more fibers into the atmosphere.

The composition of the long-fiber asbestos used is indicated by the chemical and petrographic analyses given in tables 2 and 3. Analysis of

air-suspended material in the dust room disclosed that about 50 per cent of the long-fiber dust was chrysotile and about 20 per cent, serpentine; as already noted, the composition of a similar air-floated sample of ball-milled short-fiber dust was 15 per cent chrysotile and 60 per cent serpentine. The dust concentration as revealed by impinger samples taken inside the animal cages was much lower than the concentration for the experiments with short-fiber or ball-milled dust. For the first year of the experiment with long-fiber asbestos the average of the light-field counts was 32 million particles per cubic foot of air; for the second year, 40 million; for the third year, 39 million; and for the fourth year, 43 million. The size-frequency of atmospheric samples of the long-fiber asbestos dust and of the ball-milled dust is shown in table 11. Both samples were collected with the electrostatic precipitator. It will be noted that there was far more fibrous material in the long-fiber dust.

Guinea pigs, cats, rats and mice were employed in this inhalation experiment. The results, summarized in table 12, are described in greater detail below.

Reaction in Guinea Pigs. The experiment was started with 100 guinea pigs. After exposure had been carried on for a year, a severe epidemic of pneumonia broke in the dust room and about one-third of the animals died or were killed. To replace them, 38 more guinea pigs were added to the surviving group. Histological examination revealed lesions in the lungs after 3 months of exposure to dust, consisting of cellular connective tissue about the terminal bronchioles (fig. 12). At 12 months there were adenomatoid changes in the adjacent parenchymal areas and by the

16th month (fig. 13) a diffuse fibrosis was present in these areas as well as around the bronchioles. The fibrous lesion could be seen macroscopically at 20 months. From this time on the reaction increased in extent and in the amount of collagen and by the 24th month, it had fanned out considerably into the parenchyma (fig. 14). The lesions were rather sharply localized and the extensions from different bronchioles showed no tendency to fuse, even in animals exposed for the maximum period of 3 years. Although the intrapulmonary reaction sometimes reached the pleura, there was no involvement of that membrane. Emphysema was not detected at any point. Some thickening of the larger bronchi with chronic inflammatory infiltration was revealed, but it was considered no more than would be produced by a similar exposure to any dust.

In guinea pigs exposed to the dust for 20 months and then removed to normal air, there was a marked tendency for cellular inflammatory reaction to clear. This effect, accompanied by contraction of the fibrous tissue, resulted in a diminishing size of the focal lesions. Most of these animals, killed at various periods up to 14 months after exposure, revealed lesions as large as those in the group sacrificed at the end of the 20-month exposure period or those in animals which remained in the dust room for more than 20 months. Fourteen months after dust exposure ceased, the foci in 4 of the 6 remaining guinea pigs were so small that they were visible only with a hand lens (fig. 15).

Reaction in the group exposed for 27 months and then transferred to a normal atmosphere was quite similar to the response in the 20-month exposure animals mentioned above. Small foci were always visible on gross inspection of sections of all guinea pigs of the 27-month series, but in

no instance was there evidence of the reaction.

Reaction in the tracheobronchial lymph nodes was first visible the third month of exposure. By the 8th month, patches of cellular connective tissue began to appear in the medulla and by the 14th month most of the node had been replaced by cellular connective tissue. This picture, which resembled that in early silicosis, persisted to the end of the experiment. Some animals, as a variant, showed heavy sheets of diffuse monocytes and large active giant cells but there was never any necrosis or hyaline formation. The spindle-shaped new cells were yellowish in color from fine pigment granules that stained for iron. No fibers or asbestosis bodies were seen.

Although asbestosis bodies were found in the lung as early as one month after exposure began, they were rare and hard to find. At 5 months more were visible, chiefly coiled inside giant cells, and at 8 months many bodies were free in connective tissue. They became fairly abundant as exposure continued although in some later animals the asbestosis bodies were only moderately numerous.

It is important to note from analyses of the lungs (table 13) that even though the tissue response at any given period of time was much greater in the guinea pigs of this experiment than in those exposed to either short-fiber or ball-milled asbestos, the amount of mineral matter in the lung ash was much less.

Reaction in Cats. Four cats inhaled the long-fiber asbestos dust for periods of 14, 25, 33 and 42 months, respectively, and were immediately sacrificed. Two other cats, after being exposed to dust for 18 months,

lived in a normal atmosphere for an additional 21 months. Exposure for 14 months was sufficient to produce cellular accumulations of phagocytes around terminal bronchioles and peripheral arterioles together with compact collections of similar cells in the tracheobronchial lymph nodes. At that time there were no typical asbestosis bodies, but smooth, pointed, yellow fibers were seen very rarely. With continued exposure, up to 42 months, reaction in the locations noted progressed to the formation of cellular connective tissue which made well-defined sheaths about the respiratory bronchioles and arterioles, marked lymphoid hyperplasia and lymphoid infiltration of bronchiolar walls (fig. 18). Typical asbestosis bodies were not formed although there was an occasional fiber, smooth, yellow and pointed. Pleurisy was not present. The reaction was similar in location to that in the guinea pigs, but fibrosis was much slower in development. Roentgenograms of cats made after exposure periods of 13, 33 and 42 months, respectively, failed to demonstrate evidence of pulmonary pathology.

Reaction in Rats. Although 20 rats were placed in the dust room, many died from pneumonia and were not suitable for study. Five animals, of which one was exposed for 19 months and four for 25 months, were free from pulmonary infection and offer a basis for tentative conclusions. In the 19-months animal, the reaction was just beginning. All four animals sacrificed at 25 months showed a well-marked peribronchiolar fibrosis. After a long search only two small smooth asbestosis bodies were found in the 19-months animal and none was found in the 25-months animal. Thus, these animals exhibited fibrosis without asbestosis bodies or fibrosis accompanied by only a very infrequent asbestosis body.

Reaction in Mice. Out of 20 white mice used in this experiment, 11 lived a year or more in dust and died or were sacrificed without showing an appreciable degree of pulmonary infection. The reaction to the inhaled dust was limited to phagocytosis by mononuclear cells. Usually these were widely scattered through the air spaces; a limited number were grouped about the terminal bronchioles producing some thickening of their walls. There was no suggestion of fibrosis.

Numerous asbestosis bodies were observed in animals killed late in the experiment. Thus, these animals exhibited asbestosis bodies without fibrosis.

Summary and Interpretation of Inhalation Experiment with Long-fiber Asbestos Dust. The purpose of this experiment was to evaluate the importance of long fibers in the tissue response to inhaled asbestos. The results, in comparison with previous investigations, indicate strongly that long fibers are chiefly responsible for asbestosis. Thus, the reaction in guinea pigs developed earlier and became more extensive in this experiment than in previous experiments in spite of a smaller concentration of asbestiform dust and a lower mineral content of the lungs. Furthermore, a typical peribronchiolar fibrosis was produced in cats although in a previous experiment with short-fiber dust peribronchiolar fibrosis did not develop in this species.

The cause of the cellular fibrosis in the lymph nodes of the guinea pigs is not clear. It did not occur in other inhalation experiments with asbestos.

INJECTION EXPERIMENTS

Since the inhalation experiments reported above strongly suggested that long fibers of asbestos are the significant factor in the etiology of asbestosis, a series of injection experiments was inaugurated wherein the dosage and length of the fibers could be controlled more precisely. Also, by using controlled dosages, the relative capacity of various asbestos minerals to produce reaction could be compared. In these injection experiments guinea pigs, rabbits, rats and dogs were used and the mineral dust was injected by the intratracheal, intraperitoneal and intravenous techniques, but not all the techniques were used for each species. For the purpose of simplification the findings in each series of tests, except for dogs, have been condensed and reported in tables, to which reference will be made later. In the case of dogs, only one test was made and since the findings were negative no detailed report is included.

EXPERIMENTS USING INTRATRACHEAL TECHNIQUE

As the asbestos minerals do not cause a typical advanced fibrosis in extra-pulmonary tissue, the intratracheal technique is the preferred way of introducing fibrous dust into the experimental animal. In this method the dust suspension is injected by means of a special needle or catheter deep into the trachea, from which it flows into the lungs.

Second, with the mineral brucite, which is not a silicate but is a fibrous form of magnesium hydroxide, a characteristic fibrosis like that produced by the asbestos minerals was obtained (fig. 22). Since the brucite used contained only 0.30 per cent silica, as an impurity, it is obvious that a siliceous component is not an essential factor in the development of asbestosis.

Third, no fibrosis resulted from the injection of glass wool fibers (fig. 23), even though glass wool resembles asbestos in many ways. However, there are fundamental differences. A glass wool fiber 3 microns in diameter is a solid rod and, in short lengths, is fairly rigid, while an asbestos fiber of the same diameter is a bundle of extremely fine filaments which impart to the fiber a high degree of flexibility. It would seem that this structure and the associated flexibility are important factors governing the capacity of a mineral to produce peribronchiolar fibrosis. Experimental studies concerning this observation will be reported in a separate publication.

Comparison of Long-Fiber and Short-Fiber Dusts. With quartz dust it has been demonstrated that the smaller the particles, the more intense is the tissue reaction, and that there is little reaction to particles larger than 3 microns in diameter. In the case of asbestos, however, the reverse is true and apparently only long fibers have any specific effect, as was suggested by the inhalation experiments. This is confirmed by the data of table 15, in which a series of tests with fibrous minerals is reported. When the injected dust consisted of fibers 20 to 80 microns long, all the fibrous minerals tested, except anthophyllite, as noted in

the preceding section, produced a fibrosis; when the material was prepared by first grinding the fibrous dust until the length of fibers was reduced to 20 microns and less or, in some cases, to 3 microns and less, none of the injected dusts caused fibrosis.

These results differ from those of King, et al,[13] who report the production of nodulosis comparable with the experimental silicotic nodule in rabbits receiving monthly intratracheal injections of 100 mg. of Rhodesian asbestos fibers, 15 microns long, and the production of diffuse interstitial fibrosis in rabbits similarly injected with short fibers, 2.5 microns in length. We believe this dose, especially in the long-term rabbits, is highly excessive. In our experiments the dosage was kept low in order to minimize untoward reactions which might obscure the peribronchiolar type of fibrosis which characterizes early human asbestosis.

EXPERIMENTS USING INTRAVENOUS TECHNIQUE

The experiments, summarized in table 17, in which the intravenous method of injection was employed, show that the asbestos minerals are far different from quartz in their action on tissue. It has been repeatedly demonstrated that intravenous injection of quartz particles 3 microns and less in diameter will cause a typical tissue reaction with the development of hyalinized fibrotic lesions in extra-pulmonary sites, such as the liver and the spleen. Asbestos minerals, however, on intravenous injection generally produce only an inert type of reaction, as is revealed by

---

13. King, E.J., Clegg, J.W. and Fua, Y.M.: Effect of Asbestos, and of Asbestos and Aluminum, on Lungs of Rabbits. Thorax 1: 188 (Sept.) 1946. Abstr. in Indust. Hyg. Digest 11: No. 234 (Feb.) 1947.

the results given in the table. The reason for the early deaths in the experiment with chrysotile particles is not clear.

EXPERIMENTS USING INTRAPERITONEAL TECHNIQUE

The results of injection experiments with the intraperitoneal technique are given in table 13. It will be noted that the long-fiber dusts produced a fibrous reaction while dusts composed of particles 3 microns and less in size caused only an inert type of response. These experiments indicate also that the fibrosis initiated by the irritation of asbestos fibers is not restricted to the lungs, as was formerly assumed, but can be produced in the peritoneum as well.

OTHER EXPERIMENTS WITH ASBESTOS MINERALS

A number of additional experiments were conducted to throw more light on specific phases of the asbestosis problem.

PROTECTIVE ACTION OF ALUMINUM COMPOUNDS

Intratracheal injection into a series of rats of a suspension of long-fiber chrysotile to which colloidal aluminum hydroxide had been added revealed that the addition of the aluminum compound did not prevent the tissue irritation produced by chrysotile. If anything, the acute inflammatory response to the injected fibrous mineral was accelerated. One month after the last injection of the dust suspension the bronchiolitis was becoming fibrous. King and his associates also found that aluminum

failed to protect pulmonary tissue from the irritation caused by asbestos fibers[14]; in their experiments metallic aluminum instead of the hydroxide was used.

FORMATION OF ASBESTOSIS BODIES

The iron in the coating of the asbestosis body appears to be derived from blood or tissue elements and not, as has been suggested, from the mineral fiber. Following subcutaneous injection of two kinds of chrysotile into the groin of guinea pigs - one kind containing 2 per cent and the other 0.2 per cent Fe_2O_3 - the asbestosis bodies were equally numerous at both sites of injection and showed no difference in their reaction to Prussian blue, the reagent which stains iron. This finding is in agreement with that of Giroux[15].

TISSUE REACTION TO ASBESTOSIS BODIES

Intratracheal injection into guinea pigs of asbestosis bodies recovered from human lung tissue failed to produce a fibrous reaction. The material for injection was obtained by digesting with sodium hypochlorite solution the lung tissue removed at autopsy from an asbestos worker. The asbestosis bodies could be seen in the guinea pigs for at least a year after injection. This experiment shows that the asbestosis body has a rather resistant coating which is not destroyed by moderate hypochlorite treatment, which may be maintained in vivo for a year or longer and which

---

15 14. Giroux, M.: Amiantose experimentale: Valeur Pathognomonique du "corps D'Amiante". Laval Medical 3: 235, 1943.



Fig. 23 - Glass wool injection experiment. Guinea pig injected intratracheally; 4 months after injection. Two bronchioles are shown, one in cross section and the other in longitudinal section. Below the latter is a thick-walled blood vessel. The bronchioles are without reaction and can be considered normal for comparison with other figures. Glass wool fibers are present in this field but cannot be seen at this magnification. (200 X)

renders the fiber incapable of producing fibrosis. It thus appears that the coating is a protective mechanism. This thought was expressed by Beintker as early as 1934[15].

THEORY OF IRRITANT ACTION

Two hypotheses have been proposed to explain the tissue irritation and reaction caused by asbestos fibers: the chemical and the mechanical. In the chemical theory, which is based upon experience with quartz, it is assumed that the asbestos minerals dissolve in the body fluids and that in this process their bases are leached away to leave silica in a form capable of irritating tissues. According to this hypothesis asbestosis would be merely an indirect silicosis. Several facts make the chemical theory untenable: intratracheal injections of brucite fibers, which had a silica content of only 0.30 per cent, caused a typical fibrosis like that produced by the asbestos minerals; free-silica particles increase in potency as the particle size becomes less, but asbestos fibers shorter than about 10 to 20 microns are relatively innocuous; aluminum hydroxide neutralizes the irritating effect of quartz but not of asbestos; serpentine has the same chemical composition as long-fiber chrysotile but it produced only an inert type of tissue reaction; there is a wide range in the chemical composition of the minerals which do cause asbestosis (table 10). In view of this evidence it seems more likely that asbestosis is caused by an unusual mechanical irritation from long asbestos fibers, this

15. Beintker, M.: Über die Asbestosiskörperchen. Bemerkungen zu der Arbeit von Boger. Virchows Arch. f. path. Anat. 293: 527, 1934.

irritation being related to the peculiar filamented structure of the fiber and the associated flexibility, which are possessed by no other foreign body studied. Thus, ignition of chrysotile fibers changed their structure and made them inert although the same fibers, before being heated, produced fibrosis (table 14). Further support for the theory of mechanical irritation is that asbestosis occurs in an organ of high mobility - the lung - and that a fibrous reaction can be produced by injection of asbestos fibers into the peritoneum, where there is also a degree of mobility, but not in other extra-pulmonary organs such as the liver, spleen and subcutaneous tissue.

C O M P L I C A T I O N S

The experimental investigations with asbestos minerals were concerned primarily with the effect of the dust on normal tissue but some attention was given to other phases, such as susceptibility to infection. The only experiment in which the effect of asbestos dust on a pulmonary infection was studied was the first inhalation experiment, carried on with King's floats dust. It is unfortunate that, owing to the lack of adequate facilities at that time, infection studies could not be made in the other inhalation experiments also.

Susceptibility to Tuberculous Infection. The development of a tuberculous process initiated at the beginning of exposure to dust, and also of a tuberculous infection superimposed upon an established asbestosis, was described in preceding sections of this paper. It may be stated that

asbestos, when classified according to the effect of a dust on tuberculous infection, would be placed below an active dust like quartz but above an inert dust, such as iron oxide. In animals infected with attenuated tubercle bacilli, quartz causes the infectious process to progress until the animal dies of tuberculosis. Inert dusts have no effect on the infection and the lesions usually heal and the disease disappears. Asbestos dust is in a different category. In the experimental investigation, when the fibrous dust was being inhaled during the evolution of the infection, there was a spreading of the tuberculous process for a time but usually the stimulus for continued proliferation of the tubercle bacilli was not sustained, the progression was arrested and healing followed. In guinea pigs infected with attenuated tubercle bacilli after completion of slightly more than two years of exposure to asbestos dust, progressive disease did not develop. The only modification of the infection was one of localization, a few bacilli being retained in the fibrous terminal bronchioles and forming tubercles there in addition to the usual foci beneath the pleura. Such tubercles healed in a few months.

Susceptibility to Non-tuberculous Infection. There was no specific experiment concerning the effect of inhaled asbestos dust on non-tuberculous infection. Intercurrent pneumonia among animals exposed to asbestos dust was rather common, the frequency in guinea pigs exposed in the four inhalation experiments ranging from 16 to 33 per cent. This incidental evidence suggests the possibility of an effect of asbestos dust on non-tuberculous infection. Nevertheless, since such epidemics are not uncommon

in inhalation experiments with other dusts and even in the colony of normal animals, it is felt that the inhalation of asbestos dust does not exert a significant effect on the susceptibility to non-tuberculous pulmonary infection.

D I S C U S S I O N A N D S U M M A R Y

Owing to the vast amount of data included in this investigation, it seems most convenient to summarize and to state as concisely as possible the various observations which emerged from the experiments and to follow each with a brief resume' of the evidence.

A. Various species of animals, including the guinea pig, the rat and the rabbit, but not the mouse, and the dog, develop peribronchiolar fibrosis of the lung similar to human asbestosis, following the inhalation or the intratracheal injection of long chrysotile asbestos fibers.

Both inhalation and injection experiments provide ample support for this statement. Figure 14 reveals the cellular fibrosis that follows inhalation of long-fiber asbestos by guinea pigs; fig. 16 shows the fibrosis in the cat caused by inhalation of long-fiber asbestos dust. Similar but less extensive fibrosis occurred also in rats and rabbits (table 1). Mice and dogs failed to respond. This variation in response of different species to identical dust exposures is still to be accounted for.

B. Long asbestos fibers are essential in the production of the peribronchial fibrosis; short fibers are incapable of producing this reaction.

Inhalation experiments with asbestos dust suggest and intra-

tracheal injection experiments confirm that peribronchiolar fibrosis is produced by asbestos fibers between 20 and 50 microns in length, but not by particles shorter than 20 microns (tables 16 and 18). This indicates that the minimum length of fiber possessing the capacity to produce the typical peribronchiolar fibrosis in animals is somewhere between 20 and 50 microns. Pointed studies have not been carried out to determine the upper limit of effective fiber length. It appears, however, that that limit will be determined by the inhalability of the fiber.

C. The mode of action of the long asbestos fiber in the production of asbestosis is primarily mechanical rather than chemical in nature.

The evidence for this conclusion has been reviewed in a preceding section, page 40. The flexible filamented structure of asbestos fibers plays an essential part in the irritating action, since the solid inflexible fibers of glass wool do not produce fibrosis (fig. 22).

D. Typical experimental asbestosis was produced by the inhalation of an atmospheric suspension containing an average of 138 million asbestos particles per cubic foot of air by light-field count, of which less than 1 per cent consisted of fibers longer than 10 microns.

In the inhalation experiment with 100 per cent ball-milled asbestos dust containing 0.5 per cent of fibers longer than 10 microns (table 11), a typical fibrosis was obtained (table 9). The evidence presented shows at least that an atmospheric concentration of asbestos dust containing less than 1 million (0.5% x 138 million) fibers, longer than 10 microns, per cubic foot of air is capable of producing

experimental asbestosis in guinea pigs. The actual lower limit of concentration of long fibers necessary to produce asbestosis in animals cannot be established from these studies.

E. The duration of exposure required to develop the pulmonary reaction to inhaled asbestos dust is inversely proportional to the concentration of long fibers in the atmosphere, viz., as the concentration is increased, the reaction develops in shorter time.

The basis for this statement appears in the data of the inhalation experiment with long-fiber asbestos. For that experiment the average concentration of the atmospheric dust was about 40 million particles per cubic foot of air and size-frequency determinations disclosed that 5.7 per cent of the air-suspended material consisted of fibers longer than 10 microns (table 11). Thus, by calculation it is estimated that the concentration of the longer fibers was 2.7 million (6.7% x 40 million). The lungs of animals exposed to the long-fiber asbestos dust revealed that the pulmonary reaction developed in approximately one-half the exposure time required for its development in animals inhaling the ball-milled product, for which the concentration of the longer fibers was only 0.3 million (0.6% x 136 million).

F. Established experimental asbestosis ceases to progress on discontinuing exposure to dust.

The experimental investigation shows, in fact, that on discontinuing exposure there was an appreciable clearing of the mature pulmonary lesions, due to contraction of the fibrotic reaction. In contrast, an immature tissue response consisting primarily of cells

with little or no fibrosis continued to progress. It is assumed that following attainment of fibrotic maturity, the same process of contraction would ensue as was noted for the mature lesion.

G. The formation of asbestosis bodies represents a coating of the fibers by blood and tissue elements, which results in loss of ability of the fiber to produce fibrosis.

Intratracheal injection of asbestosis bodies failed to produce the typical asbestotic tissue reaction in experimental animals. The cessation of progressive reaction to inhaled asbestos dust soon after exposure terminates may be due to the formation of asbestosis bodies.

H. Aluminum hydroxide failed to neutralize the fibrosing action of the long-fiber asbestos.

Intratracheal injection of aluminum hydroxide with chrysotil asbestos did not retard or prevent the development of asbestosis in rats.

I. Inhalation of asbestos dust did not alter significantly the final outcome of experimental tuberculosis in two series of guinea pigs exposed to the dust.

The apparently mild influence of asbestos dust is in distinct contrast to the stimulating effect of inhaled quartz upon a tuberculous process in the lung. The interpretation must remain tentative, however, since it is based upon an investigation limited to two series of guinea pigs exposed to only one kind of asbestos, namely, King's Floats. Reference to table 4 shows that when the infection was coincidental with the onset of dust exposure, there

TABLE 1

REACTION TO LONG-FIBER CHRYSOTILE

IN LUNGS OF MAN AND OTHER SPECIES OF ANIMAL

Species	Mode of Exposure	Fibrosis	Asbestosis Bodies
Man	Inhalation	4+	Numerous
Guinea Pig	Inhalation and injection	2+	Mod. numerous
Rabbit	" " "	+	Rare and atypical
Cat	" " "	+	" " "
White Rat	" " "	+	Very rare
White Mouse	Inhalation	0	Rare and atypical
Dog	Injection	0	None

The symbols 0 to 4+ refer to the degree of tissue reaction.

was temporary progression of the infectious process with subsequent healing; when infection was initiated after 26 months of dust exposure the course of the tuberculosis was not appreciably altered. This latter finding is quite different from our usual experience with quartz dust or with mixed dusts containing quartz, wherein the adverse influence of quartz upon a tuberculous infection is manifested most strikingly when infection is initiated after a period of dust exposure, viz., superimposed upon a background of established silicosis. As indicated above, application of this more sensitive test to asbestos dust failed to demonstrate that asbestos had an adverse influence upon a tuberculous infection. The inability of asbestos dust in that experiment to affect unfavorably the tuberculous process furnishes strong support for the interpretation that inhaled asbestos dust has no more than a mildly unfavorable effect on pulmonary tuberculosis.

Acknowledgment

Acknowledgment is gratefully made to the group of companies of the asbestos industry whose generous financial support made this investigation possible.

TABLE 2

CHEMICAL ANALYSIS OF ASBESTOS DUSTING MATERIAL

	King's floats	Short-fiber	Long-fiber
	per cent	per cent	per cent
SiO_2	39.32	37.17	38.40
Fe_2O_3)	) 8.84	9.09	5.32
Al_2O_3)	)	1.40	0.78
Cr_2O_3	*	0.14	*
MnO	*	0.09	0.08
CaO	0.67	0.85	0.31
MgO	35.56	35.96	40.18
Na_2O	*	0.14	0.06
K_2O	*	0.20	0.06
CO_2	*	0.93	0.57
Ignition loss	12.74	14.09	14.00
	97.13	100.11	99.76

* Not determined

TABLE 3

PETROGRAPHIC ANALYSIS OF ASBESTOS DUSTING MATERIAL

King's floats

The approximate composition, based on particles (except chrysotile) smaller than 10 microns and reported as percentages obtained from particle counts, was: chrysotile 14, serpentine 40, magnetite 12, carbonates 18, talc 12, other minerals 4. For chrysotile, fibers up to 200 microns long were included.

Short-fiber

The material as received contained a preponderance of fibrous chrysotile and platy (non-fibrous) serpentine. Accessory minerals present were dolomite, chromite, magnetite and a little tremolite and actinolite. The size-distribution was nonuniform. There were more fibers in this material than in the King's floats.

Long-fiber

The material contained about 75 per cent of fibrous asbestos mineral, probably chrysotile, with some serpentine and small amounts of calcite, magnetite and chloritic or micaceous minerals. A trace of quartz was seen. There were shreds of non-separated fibers 10 to 50 microns long and 5 to 15 microns in diameter.

TABLE 4

SUMMARY OF INHALATION EXPERIMENT WITH FINCH'S FLOATS ASBESTOS DUST

Future of Experiment	Number of Animals	Maximum Dust Exposure	Maximum Survival After Dust Exposure	Results
		months	months	
Dust exposure continuous throughout life.	54 g. pigs	53	0	Typical peribronchiolar fibrosis after 16 months.
	9 rabbits	19	0	Foreign body bronchitis.
	18 rats	6	0	Little or no reaction.
Dust exposure followed by a prolonged residence in normal air.	25 g. pigs	6	35	Nonprogressive fibrosis.
	25 g. pigs	9	37	Nonprogressive fibrosis.
	1 rabbit	6	30	Absorption of foreign body reaction.
	1 rabbit	19	34	
Tuberculous infection* at start of dust exposure.	40 g. pigs	35	0	Temporary progression of infection followed by healing with fibrosis.
Controls to infection; no dust exposure.	23 g. pigs	0	36**	Healing by resolution (one exception).
Tuberculous infection* after 26 months of dust exposure, then residence in normal air.	12 g. pigs	26	14	No appreciable increase in susceptibility to tuberculous infection. Healing with fibrosis.
Controls to infection; no dust exposure.	12 g. pigs	0	19**	Healing by resolution.

* With low-virulent F_1 strain of tubercle bacillus.

** After infection.

TABLE 5

SUMMARY OF INHALATION EXPERIMENT WITH SHORT-FIBER ASBESTOS [illegible] DUST

Nature of Experiment	Number of Animals	Maximum Dust Exposure months	Maximum Survival After Dust Exposure months	Results
Dust exposure continuous throughout life	45 g. pigs	34	0	Rate of reaction about the same as in experiment with King's floats asbestos but extent of involvement very much less. See note below.**
	73 rats	32	0	Characteristic patches of peribronchioler fibrosi no asbestosis bodies.
	16 cats	54*	0	Subpleural reaction only.
	7 rabbits	47*	0	No fibrosis seen grossly; microscopic evidence of alveolar wall thickening after 40 months exposure
Dust exposure followed by a prolonged residence in normal air.	13 g. pigs	20	14	Progression after removal from dust doubtful; neither clearly established nor definitely exclude
	2 cats	31	24	Same as for continuous exposure.
	1 rabbit	62*	6	Similar to continuous exposure; evidence of slig regression.

* Exposure after 33 months was to 100 per cent ball-milled asbestos.

** Reaction probably due to long fibers in the unground material which was mixed with the ground asbestos dust to produce a satisfactory dust cloud.

TABLE 6

ANALYSIS OF LUNG[illegible] OF GUINEA PIGS AFTER PROLONGED INHALATION OF SHORT-FIBER ASBESTOS [illegible] DUST

		Time from beginning of dust exposure					
		months 12	months 18	months 20	months 24	months 30	months 34
	Exposure to dust	12	18	20	24	30	34
	Period in normal air	0	0	0	0	0	0
Dust Exposure Continuous During Life		per cent	per cent	per cent	per cent	per cent	per cent
	Amount of ash (% of dried lung)	6.02 4.58 5.18	5.00 4.76 4.96	5.86 6.43	5.42 5.50	6.35 6.55	6.06 6.35
	Total SiO_2 (% of dried lung)	0.51 0.46 0.54	0.49 0.43 0.53	0.85 0.90	0.78 0.78	0.96 1.27	0.75 0.96
	Total SiO_2 (% of ash)	10.23 10.08 10.54	9.96 9.00 10.69	14.46 14.07	14.48 14.20	17.89 19.43	12.37 15.11
	Tissue Reaction*	±	±	2+	3+	4+	4+
		months	months	months	months	months	months
	Exposure to dust	-	-	-	20	20	20
	Period in normal air	-	-	-	4	10	14
Dust Exposure Followed by Prolonged Residence in Normal Air		per cent	per cent	per cent	per cent	per cent	per cent
	Amount of ash (% of dried lung)	-	-	-	5.16 5.11	6.11 5.58	4.77 6.18 4.77
	Total SiO_2 (% of dried lung)	-	-	-	0.48 0.36	0.52 0.34	0.25 0.28 0.22
	Total SiO_2 (% of ash)	-	-	-	9.30 7.16	10.21 8.51	5.31 5.00 4.60
	Tissue Reaction*	-	-	-	2+	3+	2+

*The symbols averaging the tissue reaction in each group represent merely the relative degree of reaction, ranging from ± (questionable) to 4+ (the maximum for this experiment). The relationships apply only within this table and cannot be compared with symbols in other tables.

TABLE 7

ANALYSES OF LUNGS OF WHITE RATS THAT HAD INHALED SHORT-FIBER ASBESTOS (CHRYSOTILE) DUST

	Duration of Exposure					
	0 months*	2 months	4 months	6 months	8 months	10 months
	per cent	per cent	per cent	per cent	per cent	per cent
Amount of ash (% of dried lung)	3.9 4.3 2.9 3.6 3.3 3.9 3.4	3.5 3.6 2.9 3.2	3.3 3.6 3.4	3.3 3.4 3.7	3.9 3.8 3.5 4.4 3.7	4.9 4.6 5.3 4.7
Total SiO_2 (% of dried lung)	0.00 0.00 0.00 0.00 0.00 0.00 0.00	0.08 0.13 0.09 0.05	0.08 0.11 0.07	0.07 0.05 0.04	0.08 0.18 0.15 0.17 0.16	0.18 0.1[illegible] 0.1[illegible] 0.13
Total SiO_2 (% of ash)	0.0 0.0 0.0 0.0 0.0 0.0 0.0	2.1 3.5 3.2 1.6	2.3 3.0 2.2	2.1 1.5 1.1	2.2 5.5 3.4 4.0 4.2	3.8 3.3 2.8 2.8

* Normal controls (no dust exposure)

TABLE 8

COMPARISON OF AVERAGE VALUES FOR ASH AND TOTAL SILICA

FOR LUNGS OF WHITE RATS INHALING VARIOUS DUSTS

(Lungs only without included lymph nodes)

		Duration of Exposure				
		2 months	4 months	6 months	8 months	10 months
		per cent	per cent	per cent	per cent	per cent
Amount of Ash (% of dried lung)	Short-fiber asbestos	3.3	3.4	3.5	3.8	3.9
	Quartz	4.3	4.5	7.1	4.6	7.3
	Ferruginous chert	5.9	8.9	9.9	9.0	14.1
	Gypsum-quartz mixture	2.9	3.8	3.4	3.6	4.1
Total SiO_2 (% of dried lung)	Short-fiber asbestos	0.09	0.09	0.08	0.15	0.15
	Quartz	0.51	0.51	2.04	1.44	4.40
	Ferruginous chert	0.25	0.32	3.45	2.40	6.00
	Gypsum-quartz mixture	0.08	0.07	0.11	0.32	0.28
Total SiO_2 (% of ash)	Short-fiber asbestos	2.6	2.5	1.6	3.9	3.2
	Quartz	11.7	11.4	41.5	29.4	56.6
	Ferruginous chert	3.9	3.6	34.4	26.6	43.2
	Gypsum-quartz mixture	2.6	2.0	3.4	9.1	8.7

TABLE 9

SUMMARY OF INHALATION EXPERIMENT

WITH 100 PER CENT BALL-MILLED ASBESTOS DUST

Nature of Experiment	Number of Animals	Maximum Dust Exposure	Maximum Survival After Dust Exposure	Results
		months	months	
Dust exposure continuous throughout life	84 g. pigs	24	0	No appreciable pulmonary reaction.
	40 rats	20	0	No suggestion of asbestosis.
	24 mice	12	0	No suggestion of asbestosis.
Dust exposure followed by a prolonged residence in normal air	16 g. pigs	23	12	Fibrosis typical of asbestosis was present 12 months after exposure ceased in an amount sufficient to be visible grossly; smaller foci could be seen microscopically at 2 months and 3 months after termination of exposure.

ANALYSES OF LUNGS OF GUINEA PIGS EXPOSED TO DUST IN INHALATION EXPERIMENT WITH 100 PER CENT BALL-MILLED ASBESTOS DUST

	Time from beginning of dust exposure								
	months 1	months 2	months 3	months 5	months 8	months 12	months 16	months 20	months 24
Exposure to dust	1	2	3	5	8	12	16	20	24
Period in normal air	0	0	0	0	0	0	0	0	0
	per cent	per cent	per cent	per cent	per cent	per cent	per cent	per cent	per cent
Amount of ash (% of dried lung)	4.85 5.30 4.35	4.66 4.60 5.05	5.60 5.07 5.74	5.10 5.08 5.02	4.35	5.65 6.24	5.40 5.01	5.65 5.20	6.30 5.56
Total SiO_2 (% of dried lung)	0.21 0.50 0.24	0.23 0.34 0.61	0.70 0.32 0.66	0.58 0.38 0.30	0.52	1.25 1.45	1.02 1.11	1.28 1.28	1.65 1.21
Total SiO_2 (% of ash)	4.28 7.05 5.60	4.90 7.40 12.01	12.47 8.38 9.77	7.51 7.47 7.72	11.96	22.18 23.28	18.96 21.95	22.60 24.61	28.05 21.70
Tissue Reaction*	0	0	0	0	0	0	±	±	±

	Time from beginning of dust exposure		
	months 30	months 36	months 40
Exposure to dust	28	28	28
Period in normal air	2	8	12
	per cent	per cent	per cent
Amount of ash (% of dried lung)	7.25 8.67	5.25 5.98	6.39 6.17
Total SiO_2 (% of dried lung)	1.67 2.19	0.88 0.67	0.84 0.64
Total SiO_2 (% of ash)	21.83 26.24	12.99 10.56	13.08 10.41
Tissue Reaction*	+	+	2+

The symbols averaging the tissue reaction in each group represent merely the relative degree of reaction, ranging from 0 to ± (questionable) to 2+ (the maximum observed in this experiment). The relationships apply only within this table and cannot be compared with symbols in other tables.

TABLE 11

COMPARISON OF SIZE-FREQUENCY OF ATMOSPHERIC LONG-FIBER AND 100 PER CENT BALL-MILLED ASBESTOS DUST COLLECTED INSIDE CAGES

		Long-Fiber	Ball-Milled
		per cent	per cent
Grains	< 3 microns	65.4	90.6
	3-10	1.1	4.8
	> 10	0.0	0.0
Fibers	< 10	25.8	0.8
	> 10	6.7	0.6
Clumps		1.0	3.2
		100.0	100.0

TABLE 12

SUMMARY OF INHALATION EXPERIMENT

WITH LONG-FIBER ASBESTOS DUST

Nature of Experiment	Number of Animals	Maximum Dust Exposure	Maximum Survival After Dust Exposure	Results
		months	months	
Dust exposure continuous throughout life	117 g. pigs	36	0	Definite fibrosis in 16 months.
	4 cats	42	0	Slowly developing fibrosis first seen at 24 months.
	20 rats	25	0	Marked peribronchiolar fibrosis first seen at 24 months.
	20 mice	25	0	Limited reaction; no fibrosis.
Dust exposure followed by a prolonged residence in normal air	12 g. pigs	20	14	Clearing of inflammatory reaction and definite contraction of fibrosis.
	9 g. pigs	27	9	Clearing of inflammatory reaction and slight contraction of fibrosis.
	2 cats	18	24	Similar to continuous exposure group; suggestion of progression in one of the two animals.



Fig. 6 - King's floats inhalation experiment. Guinea pig with 6 months' dust exposure and then in normal air 35 months. The reaction is rather slight, but distinct fibrosis is present. Note that 28 months of continuous exposure (fig. 6) produces much more extensive reaction. (200 X)

ANALYSSS OF LONGS OF GUINEA PIGS EXPOSED TO DUST IN INHALATION EXPERIMENT WITH LONG-FIBER ASBESTOS DUST

		Time from beginning of dust exposure												
		months 1	months 2	months 3	months 5	months 8	months 12	months 16	months 20	months 24	months 27	months 30	months 34	months 36
	Exposure to dust	1	2	3	5	8	12	16	20	24	27	30	34	36
	Period in normal air	0	0	0	0	0	0	0	0	0	0	0	0	0
		%	%	%	%	%	%	%	%	%	%	%	%	%
	Amount of ash	4.55	4.46	4.39	4.77	4.72	4.87	2.98	3.54	3.42	3.40	3.53	5.65	4.10
	(% of dried lung)	4.35	4.48	4.38	4.63	4.52	5.02	3.33	3.60	3.52	3.74	3.93	5.70	3.74
		4.57	4.35	4.51	5.06	4.34	5.18	3.16	3.58			3.83		
Past														
Exposure	Total SiO_2	0.04	0.05	0.05	0.08	0.10	0.25	0.38	0.43	0.35	0.39	0.37	0.50	0.5.
Continuous	(% of dried lung)	0.03	0.05	0.05	0.12	0.09	0.20	0.35	0.49	0.29	0.49	0.34	0.5.	0.35
during		0.04	0.06	0.05	0.09	0.07	0.31	0.34	0.62			0.24		
Life														
	Total SiO_2	1.10	1.23	1.20	1.76	2.21	5.20	12.70	12.22	10.18	11.51	10.55	8.60	9.11
	(% of ash)	2.11	1.18	1.15	2.67	1.90	4.09	12.25	13.83	8.29	13.15	11.22	12.47	12.60
		0.95	1.46	1.49	1.77	1.58	5.99	10.91	14.69			6.10		
	Tissue Reaction*	0	±	±	±	+	+	2+	2+	3+	3+	4+	4+	4+

		Time from beginning of dust exposure							
		months 20	months 20	months 20	months 20	months 27	months 27	months 27	months 27
	Exposure to dust	20	20	20	20	27	27	27	27
	Period in normal air	0	4	10	14	0	3	7	9
		%	%	%	%	%	%	%	%
	Amount of ash	3.64	2.92	4.18	5.01	3.40	3.66	3.19	3.21
	(% of dried lung)	3.60	2.81	4.30	5.04	3.74	2.64	3.18	2.75
		3.58							
ust									
xposure									
ollowed by	Total SiO_2	0.43	0.21	0.24	0.21	0.39	0.31	0.26	0.29
o longed	(% of dried lung)	0.49	0.27	0.22	0.18	0.49	0.16	0.28	0.23
esidence		0.52							
Normal									
ir	Total SiO_2	12.22	7.23	5.76	4.00	11.61	8.59	8.99	8.96
	(% of ash)	15.63	9.60	5.07	3.58	13.15	6.94	8.72	8.31
		14.59							
	Tissue Reaction*	2+	2+	2+	+	3+	2+	2+	2+

*The symbols averaging the tissue reaction in each group represent merely the relative degree of reaction, ranging from 0 to ± (questionable) to 4+ (the maximum for this experiment). The relationships apply only within this table and cannot be com-

	Long fiber 20-50 microns	Lymphocytic infiltration [illegible] giant cells but no definite fibrosis. Refer to table 15.
	Short-fiber 3 microns and less	No fibrosis and practically no asbestosis bodies. At 1 month, focal collections of dust-filled monocytes and a giant cells; at 4 months, some adenomatoid epithelial reaction; at 8 months, simple pneumonitis with phagocytosis of short-fibers; at 12 months, isolated and sharply localized collections of dust cells inside air spaces about terminal arterioles. Reaction in walls limited to lymphoid cell infiltration. No fibrosis. In lymph node, reaction limited to slight prominence of reticulum.
Rabbits	Long-fiber 20-50 microns	Fibrosis about bronchioles. Refer to table 15.
	Short-fiber 20 microns and less	Simple foreign-body reaction. No acute inflammation. No accumulation of dust in or about terminal bronchioles. No endobronchitis. At 1 month, scattered small giant cells and considerable infiltration of adjacent ~~small giant cel and considerable infiltration of~~ adjacent walls with monocytes and lymphoid cells. At 4 months, little change except more cellular infiltration of connective tissue. At months, lymphoid infiltration and thickening of walls abo some but not all terminal bronchioles.
Ferrets	Long-fiber 20-50 microns	Typical fibrous endo- and peribronchiolitis like reaction to asbestos minerals. Refer to table 15.
	Short-fiber (made by crushing long fibers with rubber policeman)	Inert type of reaction. At 1 month after injection, small monocytes widely scattered through air spaces; focus of atelectasis with lymphoid infiltration of compressed air-space walls. No endobronchial reaction as with chrysotile At 2 months, reaction similar to that at 1 month; typical asbestosis bodies seen. At 12 months, small clumps of inactive dust-filled phagocytes; no fibrosis. No reaction in lymph nodes.



BY INTRAVENOUS TECHNIQUE

of a 1per cent suspension) which were given twice a week for 10 weeks.

Results
intravenous injections of finely-ground chrysotile and 5 of the 6 died after 1 to 5 injections; the other animal died after 27 injections of one-quarter strength suspension). Reaction limited to few large giant phagocytes of inactive type in liver, of dust cells seen in pulmonary capillaries. No definite explanation for fatalities was been retained in heart and caused local thrombi.
killed 3 animals at 9, 11 and 17 months after last injection, shortening intended complicating picture. However, rabbits sacrificed earlier (3 and 6 months) showed no progression in the 6 months animal. The last two (11 and 17 months) were probably sis of the liver and amyloid of the spleen made interpretation difficult.
substance with no change in 12 months. (Other observations at 3, 4 and 6 months). ion. No tendency to agglomerate and no change in adjacent tissues. Grinding the powder destroyed the fibrous structure of this mineral and injected material re- ory.
an inert mineral. Observations made at 3, 6, 12 and 24 months. Only suggestion of ted in spleen and lymph nodes, but not the liver, of the 24-month rabbit. In this mi- ion of mononuclear and giant cells that was not present in either spleen or lymph nodes ce of associated fibroblastic reaction in these organs and of any change in the liver ification of anthophyllite as an inert silicate. No fibers were retained in lung to n bodies would develop.
an inert mineral. Last animal sacrificed showed a little proliferation and lymphocytic n earlier (at 3, 6 and 12 months). No evidence of any activity in lesions in other
with no change in 24 months. Observations made at 3, 6, 12 and 24 months.

dust suspension. Total amount of dust injected = 0.2 gram.

	Results
	bodies. Dust particles ingested by phagocytes, chiefly multinucleated variety. Six rous elements of dust appear to have dissolved leaving only the insoluble magnetite, a surrounding fat or areolar tissue. No transporting of dust to regional lymph nodes. ls from 1 to 36 months after injection.
	rchical, delicate and non-hyaline. Atypical asbestosis bodies developed but all were e of extra-long fibers seen. Observations only at 2 months.
	nterpretation. Dust reaction appeared to be of inert type and limited to phagocyto- y to lymphocytic infiltration. Observations at 1, 4, 8 and 12 months.
	large mononuclear and giant phagocytes surrounded by a minimum amount of cellular jected dust contained not only fine material that in grinding had been mashed into y long spicules 10 microns or more in length. No asbestosis bodies seen although d slightly swollen and greenish. Observations at 1, 4, 8 and 12 months.
	y reaction. In early animals (1, 4 and 8 months) focus of monocytes and small giant crosis. In the 4-month animal there was also slight peripheral fibrosis. At 12 and mass of monocytes and giant cells; no fibrosis.
	f very large giant cells surrounded by a variable number of lymphocytes, more much ally long fibers than to the fine dust in the experiment above. There was more or bblasts producing cellular connective tissue visible in areas where the quantity of great that it obscured the reaction. Observations at 1, 4, 8 and 12 months.
	progressing beyond the stage of very slight lymphocytic reaction about masses of fibrosis. Observations at 1, 4, 8 and 12 months.
	n-body type of reaction. No fibrosis. Observations at 1, 4, 8, and 12 and 18 months.
	ced by anthophyllite and fibrous pyrophyllite with subsequent regression; crystal- ut. At 1 month, giant cells about long thick splinters; at 4 months, definite of anthophyllite and fibrous pyrophyllite reaction; at 8 months, fibrosis which ased, especially with fibrous pyrophyllite. At 12 months, reaction to all three y giant cells with lymphocytes but without necrosis or fibrosis. No asbestosis
	t suspension.

TABLE 14

COMPARISON OF REACTION TO CHRYSOTILE AND SERPENTINE

I[illegible]ED INTRATRACHEALLY

Dosage
Each animal was injected intratracheally with 0.5 cc of a 5 per cent suspension of the dust. Two weeks later another similar injection was given. Total amount of dust injected = 50 mg.

Animals Used
Six groups of 9 guinea pigs each (one group for each type of dust).

Sacrificing Periods
One or two animals in each group at 1, 2, 6, 8-1/2 and 12 months after last injection.

Preparation of Dust

Chrysotile (ball-milled) unheated: Ball-milled for 1176 hours, dried and reground in agate mortar.

Chrysotile (ball-milled) ignited: Ball-milled chrysotile heated for 2 hours at about 700°C., then ground in agate mortar 2 or 3 minutes.

Chrysotile (fibrous) unheated: Ground in agate mortar to pass 200-mesh.

Chrysotile (fibrous) ignited: 200-mesh material heated for 2 hours at about 700°C. No further grinding.

Serpentine (ball-milled) unheated: Ball-milled for 1488 hours, dried and reground in agate mortar.

Serpentine (ball-milled) ignited: Ball-milled serpentine heated for 2 hours at about 700°C., then ground in agate mortar 2 or 3 minutes.

Mineral	Size of Dust Particles	Results
Chrysotile (ball-milled) unheated	3 microns and less	Grinding destroyed capacity to cause fibrosis. At 1 month, considerable inflammatory edema and cellular proliferation and localization of dust particles about bronchioles; at 2 months, only a very slight proliferative reaction; at 6, 8-1/2 and 12 months, widely-scattered small mononuclear phagocytes. At 12 months, a few microscopic patches of thin alveolar wall thickening with some adenomatoid change in portion of air spaces abutting on thickened bronchi. No asbestosis bodies seen.
Chrysotile (ball-milled) ignited	3 microns and less	Reaction limited to large foreign-body giant cells without production of fibrous tissue.
Chrysotile (fibrous) unheated	20-50 microns approx.	A distinct fibrosis. Reaction localized to connective tissue about terminal bronchioles; little within these tubes. Contraction caused adenomatoid appearance of air spaces given off directly from terminal bronchioles. Reaction area became smaller with progress of time; no new regions involved. No chronic pleurisy even at points abutting intrapulmonary cysts. At 1 month considerable inflammatory edema and foci of cellular proliferation; at 2 months well-marked cellular proliferation and fibrosis occurring focally about respiratory bronchioles. This reaction developed before asbestosis bodies had formed and was as advanced as that [illegible]

		ffned to the immediate vicinity of the small terminal [illegible] ohioles, where the scar tissue was quite dense and was [illegible] ing hyaline in character. Sometimes it even obliterate[illegible] bronchiole. Asbestosis bodies had become scarce. At 1[illegible] months, the well-developed peri- and intra-bronchial ad[illegible] matoid areas of fibrosis had produced considerable dis[illegible] More peripherally were patches of pneumonitis with cor[illegible] lic infiltration, some of which was being transferred i[illegible] fibrous tissue. These seemed to be precursors of the l[illegible] ized, diffuse patches of thin alveolar wall fibrosis se[illegible] elsewhere.
Chrysotile (fibrous) ignited	20-50 microns approx.	Reaction limited to large foreign-body giant cells wit[illegible] proliferation. Heating the fibers, which made them bri[illegible] destroyed their capacity to produce significant reacti[illegible]
Serpentine (ball-milled) unheated	3 microns and less	Dust relatively inactive. At 1 and 2 months, simple p[illegible] cytosis without proliferation; at 6 months, no change [illegible] possibly lymphoid cell infiltration; at 8-1/2 months, [illegible] chronic pneumonitis; at 12 months, only a little pneum[illegible] without suggestion of fibrosis.
Serpentine (ball-milled) ignited	3 microns and less	Dust relatively inactive. Reaction essentially the s[illegible] for unheated serpentine. With ignited serpentine, le[illegible] dency for dust to be carried to bronchial nodes.



TABLE 15

COMPARISON OF REACTION TO VARIOUS LONG-FIBER DUSTS INJECTED INTRATRACHEALLY

Dosage

Two injections of 0.5 cc of a 5 per cent suspension given two weeks apart. Total dose = 50 mg.

Animals Used

From 6 to 9 guinea pigs for each dust.

Sacrificing Periods

Usually at 1, 4, 8 and 12 months after last injection.

Size of Dust Particles

Separated so that most fibers are from 20 to 50 microns long.

Mineral	Results
Chrysotile (Thetford)	A distinct fibrosis. Additional information given opposite chrysotile (fibrous) unheated, in table 14.
Chrysotile (Arizona; low iron content; 0.2% Fe_2O_3)	Reaction virtually identical with that to Thetford chrysotile. Both fibrosis and asbestosis bodies produced with an asbestos containing very little iron. Fibrosis occurred as plugs within terminal bronchioles and as finer deposits at periphery. Fibrosis developed before asbestosis bodies were seen and was in cellular state well-formed at one month. With age, fibrous tissue contracted and occupied smaller area but was more dense. Adenomatoid changes similar to those with Thetford chrysotile. Pleurisy limited to immediate vicinity of early reaction about areas of massive localization. Asbestosis bodies formed but were few in number. At 1 month after injection, minute foci of mononuclear proliferation about bronchioles and in areas of atelectasis; at 1-1/2 months, heavy peribronchiolar patches of fibrosis often with papillary projections partially closing lumen of bronchiole; adenomatoid appearance marked; connective tissue reaction showed heavy collagen but no hyalinization; at 2 months, minute foci of well-matured fibrosis about bronchioles; at 8 months, mature asbestosis fibrosis with evidence of contraction; considerable chronic pneumonitis with infiltration of lymphocytes and eosinophiles. At 9 months, small intrabronchiolar fibrous plugs with foci of more delicate fibrosis at periphery.
Crocidolite (Bolivia)	Typical fibrous endo- and peribronchiolitis with formation of atypical asbestosis bodies. Maximum formation of bodies began before 4th month after injection, well-developed by 8th month. Bodies persist after 12th month. Reaction at 1 month heavy endo- and peribronchiolitis already showing fibrous changes; atelectasis and fibrosis with some necrosis at site of massive localization of dust. At 4 months, heavy, widely-scattered endo- and peribronchiolitis, now fibrous, with marked deformity of bronchioles and with an adenomatoid appearance. At 8 and 10-1/2 months, reaction in lung essentially the same as at 4 months. At 12 months, foci of fibrous endo- and peribronchiolitis still large with more dense scar tissue and more deformity of bronchial tubes but no extension into, or atelectasis of, peripheral parenchyma.
Amosite	Advanced fibrous endo- and peribronchiolitis. Beaded asbestosis bodies noted at 8 months. At 1 month, early fibrous endo- and peribronchiolitis; many giant cells and some lymphocytic reaction. At 4 months, small areas of endobronchiolitis scattered throughout the lung; cellular fibrosis. At 8 and 12 months [illegible]

	...sum; at 12 months ...rked lymphocytic infiltratio... and ...toid appearance.
...(Anthophyllite ...ican)	Typical advanced fibrous endo- and peribronchiolitis produced by 0.5% suspension (1 cc total dose); most animals would not tolerate usual 5 % suspension. Fibrosis well-developed before asbestosis bodies seen. At 4 months, well-developed fibrous bronchiolitis with lymphocytes and giant cells and adenomatoid change. At 8 months, typical bronchiolitis not quite as extensive or as heavily fibrous as with a 5% suspension, otherwise the same. Many deeply-stained fibers with a good proportion of beaded asbestosis bodies. At 12 months, heavy fibrous bronchiolitis, more peri- than endobronchiolitis, with lymphocytes and giant cells; very marked adenomatoid appearance.
	Lymphocytic infiltration and giant cells but no fibrosis. A very few atypical asbestosis bodies. At 1 month, many scattered foci of intrabronchiolar dust without massive localization; lymphocytic infiltration of walls and a few giant cells. At 8 and 12 months, little evidence of dust a few bronchioles and bronchi with giant cells in adjacent alveoli and with lymphocytic infiltration of walls.
Tremolite	Fibrosis about bronchioles. At 1 month, areas of dust localization with collapse of alveoli and infiltration with acute inflammatory cells, macrophages and giant cells. Within the area were a few foci of fibrous tissue and numerous areas of hypertrophy of alveolar epithelium. Many bronchioles packed with fibers. At 4 months, general appearance of lesion unchanged; pleura slightly thickened over heavy localizations of dust. An occasional segmented asbestosis body seen. At 8 months, many foci of fibers in bronchioles and alveolar ducts with cellular reaction as before; also, some foci showed distinct collagen deposition. At 12 and 18 months reaction as before with fibrosis about bronchioles more apparent because of contraction and decrease of inflammation. Giant cells prominent. Pleura markedly involved.
Brucite	Typical fibrous endo- and peribronchiolitis like reaction to asbestos minerals. At 1 month, extensive endo- and peribronchiolitis with giant cells; dense fibrous loops within bronchioles and cellular fibrosis about them; adenomatoid change present. At 2 months, heavy intrabronchiolar and peribronchiolar fibrosis producing marked deformity with distortion of tubes and obliteration of surrounding air spaces; fibrosis pale without hyalinization but with few nuclei; no necrosis. Typical asbestosis bodies seen. At 4 and 8 months, little change; fibrous tissue contracting. At 10-1/2 months, dense fibrous bronchiolitis with asbestosis bodies. No pleurisy. No extension to surrounding lung.
Glass Wool	No fibrosis within a year. At 1 month, no reaction inside bronchioles; in peripheral air spaces clumps of giant cells packed with fine spicules of glass with lymphocytic infiltration of adjacent walls; no asbestosis bodies. At 2 months, reaction less intense than at 1 month; fair-sized clumps of elongated giant phagocytes containing spicules and particles of glass; no endobronchitis. At 4 and 8 months, reaction still diminishing. At 12 months, focal areas of pneumonitis with no fibrosis or endobronchitis; moderate number of smooth iron-staining fibers.

TABLE 16

COMPARISON OF REACTION PRODUCED BY LONG-FIBER AND SHORT-FIBER DUSTS

INJECTED INTRATRACHEALLY

Dosage

Two injections each of 0.5 cc of a 5 per cent suspension given two weeks apart. Total dose = 50 mg.

Animals Used

Six groups of guinea pigs.

Sacrificing Periods

1, 2, 6, 8 and 12 months after injection.

Mineral	Size of Dust Particles	Results
Chrysotile (Textford)	Long-fiber 20-60 microns	A distinct fibrosis. Refer to chrysotile (fibrous) unheated in table 14.
	Short-fiber 3 microns and less	No fibrosis. Refer to chrysotile (ball-milled) unheated in table 14.
Amosite	Long-fiber 20-60 microns	Typical endo- and peribronchiolitis. Refer to table 15. fibrous
	Short-fiber 20 microns and less	Reaction limited to phagocytosis with lymphocytic infiltration of adjacent walls. Short fibers packed inside mononuclear phagocytes; longer ones free, some coated to form typical asbestosis bodies. At 1 month after injection, alveoli contained good-sized giant cells; most phagocytes were within air spaces and had not migrated to walls. At 4 months, extracellular fibers had worked themselves into interstitial tissue where there was extensive proliferation of lymphoid cells and monocytes but no fibrosis. At 8 months foreign body reaction with some pneumonitis, no bronchiolitis. Typical asbestosis bodies present.
Crocidolite (Bolivia)	Long-fiber 20-60 microns	Advanced fibrous endo- and peribronchiolitis. Refer to table 15.
	Short-fiber 20 microns and less	No fibrosis. At 1 month, air spaces compressed and large filled with giant cells packed with dust needles. Walls heavily infiltrated with monocytes and lymphoid cells. At 4 months, a moderate degree of cellular infiltration of walls; small giant cells packed with dust spicules. At and 8-1/2 months, masses of giant cells, containing miner particles, in small bronchi but not in respiratory bronch smaller ones widely scattered in terminal air spaces. N erous asbestosis bodies. No reaction in connective tissu No endobronchial proliferation. At 12 months, many scattered small monocytes packed with dust. No endobronchiti No peribronchial fibrosis. In lymph node, a slight reticul no fibrosis.
[illegible]	Long-fiber 20-60 mi[illegible] s	Lymphocytic infiltration and giant cells but no definit fibrosis. Refer to table [illegible]

TABLE

SUMMARY OF INJECTION [illegible]

Dosage

Total amount of dust = 1.0 gram, divided into 20 equal doses (each dose [illegible] 5 [illegible]

Mineral	Size of Dust Particles	Animals Used	Maximum Survival After Last Injection months	
Chrysotile (Thetford)	3 microns and less (ball-milled 192 hours)	8 rabbits	-	The rabbits did not tolerate injections of even diluted [illegible] pension (69 days after first [illegible] spleen and lungs. No throm[illegible] discovered but material [illegible]
Amosite	3 microns and less (ground in agate mortar)	5 rabbits	17	Advanced pulmonary infection [illegible] duration of experiment and [illegible] only inert phagocytosis with the same although fecal [illegible]
Crocidolite	3 microns and less (ground in agate mortar)	4 rabbits	12	Reaction was that to an inert [illegible] Simple phagocytosis of part[illegible] dust to sizes of 3 microns [illegible] sembled plates rather than [illegible]
Anthophyllite	3 microns and less (ball-milled 1400 hours)	4 rabbits	24	Reaction essentially that of irritating properties [illegible] mal there had been proliferation of 12-month animal. The [illegible] condition justifies the [illegible] demonstrate whether asbestos [illegible]
Tremolite (soda-iron)	3 microns and less (ball-milled 140 hours)	6 rabbits	19	Reaction essentially that of infiltration in liver, not [illegible] organs.
Tremolite (soda)	3 microns and less (ball-milled 48 hours)	4 rabbits	24	An inert foreign-body reaction

022

TABLE 1

SUMMARY OF INJECTION EXPERIMENTS

Dosage: Each animals received a single injection intraperitoneally of 2 cc of a 5 per c

Mineral	Size of Dust Particles	Animals Used	Maximum Survival After Injection	
			months	
Chrysotile (Thetford)	3 microns and less (ball-milled 216 hours)	15 g. pigs	56	No fibrosis nor neoplastic months after injection contaminant. No reactio Observations made at int
Chrysotile (Thetford)	Long-fiber (through 100 mesh)	4 g. pigs	2	Definite fibrous reactio unusually small. No evi
Amosite	3 microns and less (ground in agate mortar)	9 g. pigs	12	Infection interfered wi sis with a moderate ten
Crocidolite	3 microns and less; also some long spicules (ground in agate mortar)	7 g. pigs	12	Dust foci consisted only connective tissue. The irregular plates but als the longer spicules app
Anthophyllite	3 microns and less (ball-milled 1400 hours).	6 g. pigs	25	Essentially inert foreig cells and a little contr 25 months, non-progress
Anthophyllite (originally labeled talc)	Mostly 3 microns and less; some fibers 30 microns or more long (ground in agate mortar)	6 g. pigs	12	Reaction, which consist heavier to those with loss proliferation of f foreign particles was ne
Tremolite (soda-iron)	3 microns and less (ball-milled 16 hours)	6 g. pigs	12	Inert type of response w dust-filled phagocytes.
Tremolite (soda)	3 microns and less (ball-milled 48 hours)	5 g. pigs	18	Inert non-progressive fo
Anthophyllite	100 microns and less	6 g. pigs	12	Distinct early fibrosis like pyrophyllite inert fibrosis replacing giant started at 4 months had dusts consisted of foreign bodies.
Pyrophyllite (fibrous)	100 microns and less	6 g. pigs	12	
Pyrophyllite (crystalline)	100 microns and less	6 g. pigs	12	

* Each animal receiving long-fiber chrysotile was injected with 2 cc of a 0.5 per ce

TABLE 19

ANALYSES OF FIBROUS MINERALS

	Amosite	Amphibole	Antho-phyllite	Brucite	Chrysotile	Croci-dolite	Tremolite
	per cent	per cent	per cent	per cent	per cent	per cent	per cent
SiO_2	46.23	55.04	59.80	0.90	38.56	54.99	56.20
Fe_2O_3	4.06	3.06	0.57	6.78	2.35	16.27	7.21
FeO	33.83	-	-	9.36	-	4.29	-
Al_2O_3	1.09	1.69	0.32	0.46	0.34	1.61	0.56
CaO	2.01	12.22	0.44	0.04	0.03	0.80	4.44
MgO	6.28	23.29	33.37	53.09	38.96	12.25	20.52
Na_2O	0.33	0.48	0.52	0.91	0.29	8.92	6.78
K_2O	0.20	0.12	0.15	0.18	0.08	0.57	0.09
Ignition (<105°C.	0.66	0.32	0.27	0.53	4.30	0.02	0.34
Loss (>105°C.	5.28	3.60	4.08	26.86	14.99	2.93	2.73
	99.97	99.77	99.82	99.79	99.89	99.68	99.82



Fig. 1 - Human asbestosis (P-36-144). The photomicrograph reveals a bronchiole (right center) with a smooth muscle bundle at its inferior margin and with an extensive zone of collagen deposition largely obliterating the surrounding alveolar structure. The black foci are macrophages containing incidental pigment. Asbestosis bodies are present but are not apparent at this magnification. (200 X)



Fig. 2 - Human asbestosis bodies. This collection of asbestosis bodies was found in the lung shown in fig. 1. The usual variations in size and configuration are represented. (400 X)



Fig. 3 - Guinea pig asbestosis body. This body is similar to some of those shown in fig. 2 (400 X)



Fig. 4 - King's floats inhalation experiment. Guinea pig with 12 months' exposure. The figure includes a respiratory bronchiole, at left, branching and becoming an alveolar duct, at right. Note the accumulation of cells in the wall of the bronchiole and in adjacent alveoli. (130 X)



Fig. 6 - Ring's floats inhalation experiment. Guinea pig with 23 months' exposure. The field includes a bronchiole, at center, with peribronchial fibrosis extending into the walls of adjacent alveoli. Note the cuboidal epithelium lining these alveoli. This is the so-called "adenomatoid" appearance. (200 X)



Fig. 7 - King's floats inhalation experiment. Guinea pig with 9 months' dust exposure and then in normal air 37 months. The reaction shown is more than that in fig. 6 but much less than the reaction in fig. 5. (200 X)



Fig. 8 - King's fleats inhalation experiment. Guinea pig infected with R_1 tubercle bacilli and then exposed to dust for 24 months. A bronchiole is shown just above center. It is surrounded by some collagen deposition together with typical epithelioid cell infiltration of the wall. Note the lack of encapsulation and the peripheral epithelioid cell pneumonia, which illustrate a spreading tuberculous process. (200 X)



Fig. 9 - King's floats inhalation experiment. Guinea pig infected with R_1 tubercle bacilli and then exposed to dust for 35 months. Note the subpleural distinctly-encapsulated caseous focus, the calcification at the right border of the lesion and the absence of cells in adjacent alveoli, all of which illustrate a healing tuberculous process. (200 X)



Fig. 10 - Ball-milled asbestos inhalation experiment. Guinea pig with 24 months' dust exposure. A bronchiole is shown at the center, with only a slight accumulation of phagocytic cells but without the formation of collagen. (200 X)



Fig. 11 - Ball-milled asbestos inhalation experiment. Guinea pig with 23 months' dust exposure and then in normal air 12 months. The reaction is much like that shown in fig. 10, but there is a slight deposition of collagen, most apparent at the left. (200 X)



Fig. 12 - Long-fiber asbestos inhalation experiment. Guinea pig with 8 months' dust exposure. The bronchiole, at center, already shows an accumulation of phagocytic cells, with slight collagen deposition. Compare with fig. 10, showing the reaction to ball-milled asbestos after 24 months. (200 X)



Fig. 13 - Long-fiber asbestos inhalation experiment. Guinea pig with 16 months' dust exposure. Again note a bronchiole with its surrounding reaction consisting of fibrosis and adenomatoid change. Collagen deposition is now seen in the walls of adjacent alveoli, at right. (200 X)

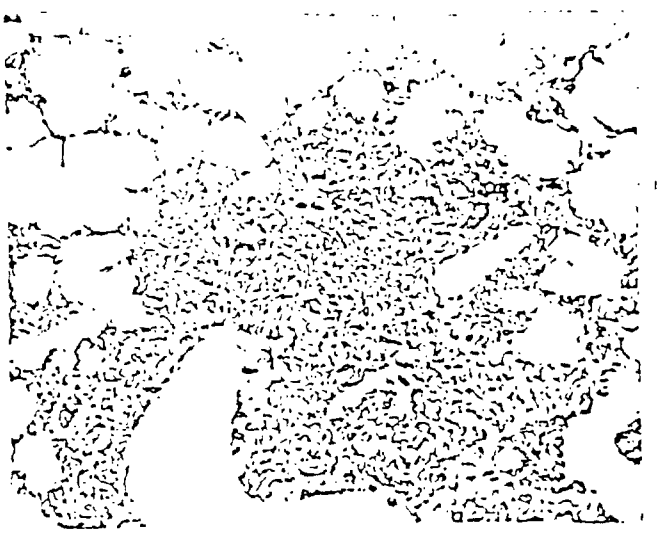

Fig. 14 - Long-fiber asbestos inhalation experiment. Guinea pig with 34 months' dust exposure. A bronchiole is at lower center; the large area above it represents the involvement of alveolar walls. Compare with fig. 13 and note the increased extent of reaction. (200 X)

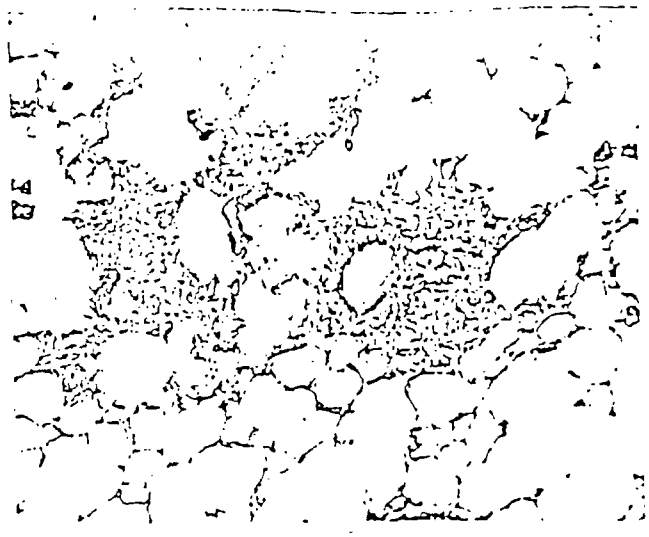

Fig. 15 - Long-fiber asbestos inhalation experiment. Guinea pig with 20 months' dust exposure and then 14 months in normal air. The reaction is essentially like that shown in fig. 13: the bronchiole at right center is surrounded by fibrosis with adenomatoid change at the right. There is residual scarring in the walls of adjacent alveoli at the left. It is apparent that no progression has occurred. (200 X)



Fig. 16 - Long-fiber asbestos inhalation experiment. Cut with 42 months' dust exposure. Two bronchioles are shown with adjacent cellular reaction and collagen deposition. (200 X)

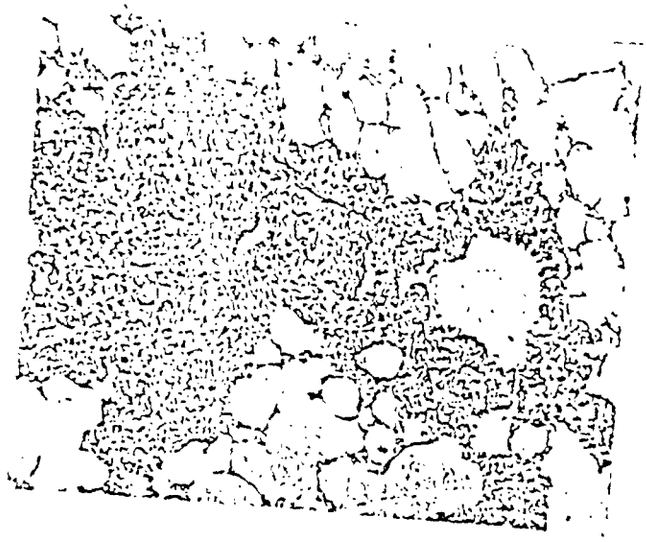

Fig. 17 - Long-fiber asbestos injection experiment. Guinea pig injected intratracheally; 4 months after injection. Note the peribronchiolar accumulation of cells with collagen deposition. The bronchiole chiefly involved is in the midst of the reaction. (300 X)



Fig. 18 - Ball-milled asbestos injection experiment. Guinea pig injected intratracheally; 4 months after injection. A bronchiole is shown at the right. In contrast with fig. 17, note that only a few cells have accumulated about the bronchiole and that collagen deposition is absent. (200 X)



Fig. 19 - Serpentine injection experiment. Guinea pig injected intratracheally; 4 months after injection. A bronchiole is shown at left center. The phagocytic cells exhibit little predilection for the bronchiole and collagen deposition is absent. (200 X)



Fig. 20 - Amosite injection experiment. Guinea pig injected intratracheally; 4 months after injection. The inflammatory reaction exhibits pronounced accumulation of cells and collagen deposition. (200 X)



Fig. 21 - Crocidolite injection experiment. Guinea pig injected intratracheally; 4 months after injection. As in fig. 20, peribronchiolar accumulation of cells and deposition of collagen are shown. (200 X)



Fig. 22 - Brucite injection experiment. Guinea pig injected intratracheally; 4 months after injection. Even with this non-siliceous fibrous mineral there is peri-bronchiolar accumulation of cells and deposition of collagen similar to that shown in figs. 20 and 21. (200 X)