Histopathologic Studies on Liver Tumorigenesis Induced in Mice by Technical Polychlorinated Biphenyls and Its Promoting Effect on Liver Tumors Induced by Benzene Hexachloride[1, 2]

Nobuyuki Ito, *M.D.*,[3] Hiroshi Nagasaki, *M.D.*,[4] Masayuki Arai, *M.D.*,[3] Sachio Makiura, *M.D.*,[3] Seiichi Sugihara, *M.D.*,[3] *and* Kazuya Hirao, *M.D.*[3]

SUMMARY—The effects of technical polychlorinated biphenyls (PCBs) on mouse liver were examined histologically and ultrastructurally. Pathologic studies were also made on the effects of PCBs on tumorigenesis induced by benzene hexachloride (BHC) in mouse liver. Neoplastic changes were observed in livers of mice fed a basal diet containing 500 parts per million (ppm) of the PCBs, Kanechlor 500, for 32 weeks. Amyloid degeneration in the liver of mice was observed in groups fed a diet containing lower concentrations of PCBs. Histologically and ultrastructurally, the neoplastic areas of mouse liver induced by PCBs appeared to be typical nodular hyperplasias and well-differentiated hepatocellular carcinomas. The effects of PCBs on neoplastic changes induced by isomers of BHC in the livers of mice fed a diet containing BHC with or without PCBs for 24 weeks were studied. Among groups fed BHC alone, only the group receiving 250 ppm of the α-isomer developed nodular hyperplasia and hepatocellular carcinoma. However, among the groups fed BHC plus PCBs, only those receiving 100 or 50 ppm of α-BHC or 250 or 100 ppm of β-BHC developed nodular hyperplasia and hepatocellular carcinoma. Groups fed γ-BHC with or without PCBs did not show neoplastic changes of the liver. Thus PCBs themselves induced hepatic neoplasms in mice and also promoted the induction of tumors by α-BHC and β-BHC.—J Natl Cancer Inst 51: 1637–1646, 1973.**

TECHNICAL POLYCHLORINATED BIPHENYLS (PCBs) are used in industry as plasticizers, in the manufacture of electrical incubators and heat transfer media, and in many other ways. PCBs have been found in the environment and in living things including fish (*1–8*). Recently, PCBs produced in the United States, West Germany, Japan, and other countries have received attention from ecologists, toxicologists, and pathologists. Many investigators (*9–12*) have reported the chronic toxicity and carcinogenicity of PCBs in various animals. The biologic interaction and synergistic effects of PCBs on DDT in insects were demonstrated by Fuhremann and Lichtenstein (*13*).

This paper reports histopathologic and ultrastructural observations on tumorigenesis induced in mouse liver by PCBs. We recently reported on the induction of liver tumors in mice treated with benzene hexachloride (BHC) (*14–16*), which included an analysis of the effects from PCBs on hepatocarcinogenesis in these mice.

MATERIALS AND METHODS

Mice:—Strain dd males (Awazu Animal Farm, Osaka), 8 weeks old and weighing about 19.0 g, received a commercial stock diet (Oriental NMF, Tokyo).

Chemicals:—PCBs samples, obtained from the Kanegafuchi Chemical Co., Osaka, were: Kanechlor-300 (PCBs-3)—average content, 59.8% trichlorobiphenyl, 23.0% tetrachlorobiphenyl, 16.6% dichlorobiphenyl, and 0.6% pentachlorobiphenyl (lot 348); Kanechlor-400 (PCBs-4)—average content, 43.8% tetrachlorobiphenyl, 32.8% trichlorobiphenyl, 15.8% pentachlorobiphenyl, 4.6% hexachlorobiphenyl, and 3.0% dichlorobiphenyl (lot 471); and Kanechlor-500 (PCBs-5)—average content, 55.0% pentachlorobiphenyl, 26.5% tetrachlorobiphenyl, 12.8% hexachlorobiphenyl, and 5.0% trichlorobiphenyl (lot 360). The isomers of BHC, α-BHC, β-BHC, and γ-BHC were purchased from Tokyo Kasei Chemical Co., Tokyo. Each isomer appeared to be over 99.0% pure by gas chromatography. Mixed diets were made once a week and kept in a cold room.

Experimental series I.—A total of 114 dd males were given basal diet with the following additions: group 1—500 parts per million (ppm) PCBs-5; group 2—250 ppm PCBs-5; group 3—100 ppm PCBs-5; group 4—500 ppm PCBs-4; group 5—250 ppm PCBs-4; group 6—100 ppm PCBs-4; group 7—500 ppm PCBs-3; group 8—250 ppm PCBs-3; group 9—100 ppm PCBs-3; group 10—no addition. The effective number of animals is shown in tables 1 and 2.

Experimental series II.—A total of 560 dd males were given basal diet with the following additions: group 1—250 ppm α-BHC; group 2—250 ppm α-BHC plus 250 ppm PCBs-5; group 3—100 ppm α-BHC; group 4—100 ppm α-BHC plus 250 ppm PCBs-5; group 5—50 ppm α-BHC; group 6—50 ppm α-BHC plus 250 ppm PCBs-5; group 7—250 ppm β-BHC; group 8—250 ppm β-BHC plus 250 ppm PCBs-5; group 9—100 ppm β-BHC; group 10—100 ppm β-BHC

[1] Received May 21, 1973; accepted July 30, 1973.
[2] Supported in part by grants for scientific research from the Ministry of Health of Japan (1972–73), the Ministry of Education of Japan (No. 801587, 1973), and the Experimental Pathological Research Association (1972–73).
[3] Cancer Center Institute, Nara Medical University, Kashihara, Nara 634, Japan.
[4] Department of Hygiene, Nara Medical University, Kashihara, Nara 634, Japan.

DSW 030121

STLCOPCB4014083

plus 250 ppm PCBs-5; group 11—50 ppm β-BHC; group 12—50 ppm β-BHC plus 250 ppm PCBs-5; group 13—250 ppm γ-BHC; group 14—250 ppm γ-BHC plus 250 ppm PCBs-5; group 15—100 ppm γ-BHC; group 16—100 ppm γ-BHC plus 250 ppm PCBs-5; group 17—50 ppm γ-BHC; group 18—50 ppm γ-BHC plus 250 ppm PCBs-5; group 19—250 ppm PCBs-5; group 20—no addition.

The effective number of mice in each group is shown in tables 3 and 4. Animals in series I and II were housed individually in aluminum cages, with bedding under natural lighting conditions in an air-conditioned room kept at 24° C. They received the experimental diets and tap water ad libitum, and were weighed weekly. After 32 weeks in series I and 24 weeks in series II, animals were fasted for 18 hours, killed with ether and examined macroscopically for tumors. The liver of each animal was weighed, and pieces were taken for histologic or ultrastructural studies. Mice dying during the experiment were excluded from the final effective number of animals.

For histology, tissues were fixed in 10% buffered formalin solution. All tissues were stained with hematoxylin and eosin; selected tissues received special stainings for amyloid material. For ultrastructural observations, samples of neoplastic or non-neoplastic areas from animals fed 500 ppm PCBs-5 were fixed with glutaraldehyde and osmic acid solutions. The fixed specimens were embedded in Epon resin by a routine method for electron microscopy. Ultrathin sections were stained with saturated uranyl acetate and then lead citrate and were examined in a Hitachi, Model HU-12, electron microscope. Sections for light microscopy were stained with 0.1% toluidine blue in Veronal buffer, pH 5.0.

RESULTS

Experimental Series I

Liver changes: The changes in liver weight in each group are summarized in table 1. In general, the liver weight increased, in groups on diet supplemented with PCBs-5, -4, or -3, the greatest increase occurring in the group that received 500 ppm PCBs-5. Gross examination showed that 7 of the 12 mice in the latter group developed liver neoplasias. In these animals the liver had an irregular surface with many large, dark-yellowish, or brown nodules of up to 1.5 cm in diameter (fig. 1). None of the mice in the other groups developed liver nodules. No cirrhotic changes of the liver were seen.

No metastatic changes or neoplasms in other organs were seen in mice with or without liver nodules.

Histopathologic findings: Groups fed PCBs-5 or PCBs-4 showed focal hypertrophy of the centrolobular liver cells in non-neoplastic areas. Nuclear enlargement in cells in hypertrophic areas was occasional, but mitotic figures, fatty changes, and necrotic signs in the cells were rare (fig. 2). Oval cells and bile-duct proliferation were also rare. In all groups receiving PCBs-5, -4, or -3, except those given 500 ppm PCBs-5 or PCBs-4, marked amyloid degeneration of the liver occurred in the space between the sinus endothelium and the liver parenchymal cells (fig. 3). The hyaline-like amyloid material in the livers of these animals stained with iodine, periodic acid-Schiff reaction, and Congo red. Deposition of amyloid material in the liver was seen more clearly in groups receiving a low concentration of PCBs than in those given a high concentration (table 2).

Liver nodules in the group fed the diet containing 500 ppm PCBs-5 were classified histologically, as described in (*16*), as hyperplastic nodules and well-differentiated hepatocellular carcinomas. The areas of hyperplastic nodules were relatively clearly demarcated from non-nodular areas. In these areas, cells were hypertrophic with acidophilic cytoplasm. Their nuclei were relatively small and mitotic findings were rare (fig. 4). In areas of hepatocellular carcino-

TABLE 1.—*Changes in body and liver weights of male dd mice treated with technical polychlorinated biphenyls (PCBs) for 32 weeks**

PCBs† in diet (ppm)		Effective number of mice‡	Body weight (g)		Liver weight	
			Initial	Final	Grams	Percent of body weight
PCBs-5	(500)	12	19.7±0.5	39.0±2.8	5.1±1.5	12.9±3.4
	(250)	12	19.8±0.4	40.6±2.7	3.2±0.5	7.8±1.1
	(100)	12	19.7±0.5	39.6±2.5	2.7±0.8	6.9±1.0
PCBs-4	(500)	12	19.7±0.5	39.0±5.3	3.0±0.5	7.8±1.8
	(250)	12	19.7±0.5	39.0±2.8	2.6±0.6	7.4±1.7
	(100)	12	19.7±0.5	38.8±4.2	2.8±1.0	7.6±0.3
PCBs-3	(500)	12	19.7±0.5	37.0±1.7	2.7±0.3	5.8±0.6
	(250)	12	19.8±0.4	37.5±3.1	2.1±0.3	5.7±0.9
	(100)	12	19.8±0.4	37.8±3.2	2.9±0.9	6.2±0.9
Controls		6	20.0±0.0	36.8±3.1	1.5±0.3	3.9±0.6

*Mean±SD.
†PCBs-5, Kanechlor 500; PCBs-4, Kanechlor 400; PCBs-3, Kanechlor 300.
‡Mice dying during the experiment were not included.

DSW 030122

STLCOPCB4014084

TABLE 2.—*Histopathologic findings in the livers of male dd mice treated with technical polychlorinated biphenyls (PCBs) for 52 weeks*

PCBs* in diet (ppm)	Histopathology of liver				Liver nodules (percent)	
	Oval cells	Bile-duct proliferation	Cellular hypertrophy	Amyloid degeneration (percent)	Nodular hyperplasia	Hepatocellular carcinoma
PCBs-5 (500)	+	+	++	0/12 —	7/12 (58.3)	5/12 (41.7)
(250)	±	±	+	2/12 (16.7)	0/12 —	0/12 —
(100)	−	−	±	3/12 (25.0)	0/12 —	0/12 —
PCBs-4 (500)	+	+	++	0/12 —	0/12 —	0/12 —
(250)	±	±	+	3/12 (25.0)	0/12 —	0/12 —
(100)	−	−	±	10/12 (83.3)	0/12 —	0/12 —
PCBs-3 (500)	−	−	±	1/12 (8.3)	0/12 —	0/12 —
(250)	−	−	±	4/12 (33.3)	0/12 —	0/12 —
(100)	−	−	−	10/12 (83.3)	0/12 —	0/12 —
Controls	−	−	−	0/6 —	0/6 —	0/6 —

*PCBs-5, Kanechlor 500; PCBs-4, Kanechlor 400; PCBs-3, Kanechlor 300.

mas, dilated sinusoidal spaces were separated by narrow cords of cells. Carcinoma cells were irregularly shaped and pyknotic and occasionally had mitotic nuclei. Trabecular structures with distended sinusoidal spaces with hemorrhagic reactions were usually seen (fig. 5). Cells surrounding areas of well-differentiated carcinoma were pyknotic with nuclear irregularities and there was an increased number of nuclei in cell cords.

Histopathologic findings in the liver of mice in series I are summarized in table 2.

Ultrastructural findings: In carcinomatous areas, the cytoplasm of hepatocellular carcinoma cells had elongated, irregular-shaped mitochondria and a greatly increased amount of smooth endoplasmic reticulum. The number of free ribosomes was also increased. The cytoplasmic areas occasionally contained concentrated lamellar bodies of various sizes. The nuclei were irregular in shape, inclusions were frequently seen, and the nucleoplasm contained loose chromatin material and had low electron opacity. The nucleoli were enlarged and the nucleolonemas were deformed (figs. 7–9). In non-neoplastic areas, the liver cells also contained a slightly increased amount of smooth endoplasmic reticulum, but mitochondrial changes were relatively rare. Nuclear and nucleolar abnormalities of the cells also were rare (fig. 10).

Experimental Series II

Liver changes: The changes in the liver weight in each group are summarized in table 3. In general, groups on diets supplemented with BHC plus PCBs showed a greater increase in liver weight than the group receiving BHC only. But the groups on diets containing only BHC or PCBs showed a greater increase in liver weight than did the control group.

Table 4 gives the hepatic-neoplasm incidence for each group. Gross examination showed that livers with neoplasms had irregular surfaces with many large, dark-yellowish nodules of up to 2.0 cm in diameter. No cirrhotic changes of the liver or metastatic changes in other organs were noted.

Histopathologic findings: The histologic changes and incidence of nodular hyperplasias and hepatocellular carcinomas in the livers of animals in the various groups are given in table 4.

Oval cell infiltration and bile-duct proliferations were rare in all groups. But hypertrophic changes of liver parenchymal cells in centrolobular areas were clear in groups that received α-BHC or β-BHC plus PCBs or α-BHC alone. Among the 30 mice in the group given 250 ppm α-BHC, nodular hyperplasia was found in 23 (76.7%) and hepatocellular carcinoma in 8 mice (26.7%). No hyperplastic nodules or hepatocellular carcinomas were seen in any other group fed α-BHC or β-BHC only. However, some mice in the groups that received 100 or 50 ppm α-BHC or 250 or 100 ppm β-BHC with PCBs developed nodular hyperplasias and well-differentiated hepatocellular carcinomas (fig. 6). The incidence of hepatocellular carcinoma in mice given 250 ppm α-BHC increased when the diet was supplemented with 250 ppm PCBs-5. No neoplastic changes were seen in groups fed α-BHC. The histologic patterns of nodular hyperplasias and hepatocellular carcinomas induced in mice by α-BHC or β-BHC were not affected by supplementation of the diet with PCBs. The histopathology of neoplasms induced by α-BHC or β-BHC was essentially the same as of that induced by PCBs in series I.

However, amyloidosis observed in the groups given PCBs only, in series I, was not seen in series II in the groups fed PCBs and BHC.

DISCUSSION

The results of series I show that hepatocellular carcinomas are induced in mice by PCBs (Kanechlor 500), which contains a large number of the chlorine compounds, but not by 2 other kinds of PCBs, Kanechlor 400 and Kanechlor 300.

DSW 030123

STLCOPCB4014085

TABLE 3.—*Changes in the body and liver weight of male dd mice treated with isomers of benzene hexachloride (BHC) and technical polychlorinated biphenyls (PCBs) for 24 weeks**

BHC or PCBs† in diet (ppm)	Effective number of mice‡	Body weight (g)		Liver weight	
		Initial	Final	Grams	Percent of body weight
α-BHC(250)	30	19.6±0.5	38.8±3.2	3.3±0.8	8.3±1.9
α-BHC(250)+PCBs-5(250)	26	19.7±0.5	36.0±2.8	7.1±2.4	18.8±5.2
α-BHC(100)	26	19.6±0.5	36.1±2.5	1.9±0.5	5.2±0.5
α-BHC(100)+PCBs-5(250)	25	19.6±0.5	37.3±3.4	4.1±0.9	10.6±2.0
α-BHC (50)	28	19.6±0.5	38.7±2.4	1.8±0.2	4.9±0.6
α-BHC (50)+PCBs-5(250)	30	20.0±0.0	41.5±3.3	3.2±0.4	7.8±1.2
β-BHC(250)	26	19.6±0.5	38.2±2.4	1.9±0.3	5.1±0.8
β-BHC(250)+PCBs-5(250)	29	20.6±0.9	40.0±2.5	4.1±0.9	10.4±2.3
β-BHC(100)	26	19.6±0.5	38.1±2.7	1.8±0.3	4.6±0.3
β-BHC(100)+PCBs-5(250)	30	20.0±0.0	41.1+2.6	3.9±0.6	9.6±1.5
β-BHC (50)	28	19.6±0.5	39.5±2.2	1.5±0.3	4.6±0.3
β-BHC (50)+PCBs-5(250)	29	20.7±1.0	38.7±2.8	3.1±0.4	9.6±1.5
γ-BHC(250)	26	19.5±0.5	37.6±2.1	1.5±0.2	4.0±0.3
γ-BHC(250)+PCBs-5(250)	28	21.4±1.9	36.8±2.2	2.9±0.3	9.6±1.5
γ-BHC(100)	28	19.6±0.5	38.6±2.4	1.6±0.2	4.0±0.8
γ-BHC(100)+PCBs-5(250)	30	21.3±1.9	38.0±3.5	3.6±0.9	7.8±1.2
γ-BHC (50)	28	19.5±0.5	37.8±4.2	1.7±0.3	4.5±1.2
γ-BHC (50)+PCBs-5(250)	27	20.7±0.9	38.0±2.7	2.8±0.5	7.3±1.2
PCBs-5(250)	20	19.8±0.5	40.6±2.6	3.2±0.5	7.5±1.1
Controls	20	19.6±0.5	37.6±2.4	1.5±0.1	4.0±0.2

*Mean±SD.
†PCBs-5, Kanechlor 500.
‡Mice dying during the experiment were not included.

Histologically, the neoplasms induced in mouse liver by PCBs were nodular hyperplasia and well-differentiated hepatocellular carcinomas. They were similar to those described previously, produced on administration of the α-isomer of BHC (*14–16*), and to those induced by other chemical carcinogens (*17–25*).

The chemical structures of PCBs, BHC, and DDT are similar in that they are all annelated chlorine compounds (*9, 13, 14, 26*). Nagasaki et al. reported that rats were more resistant than mice to the hepatocarcinogenic action of BHC (*27*). Recently, neoplastic changes in the liver of rats induced by PCBs were observed by Kimura and Baba (*11*). On histologic examination they found nodular hyperplasias but no hepatic cell carcinomas. This may reflect a greater resistance of rat liver than of mouse liver to PCBs.

In our work, in experimental series I, amyloid degeneration of the liver was seen in the groups that received PCBs-5, -4, and -3. Amyloid degeneration induced in mice by the chemical carcinogen, methylcholanthrene, was reported by Hirao et al. (*28*). The mechanism of amyloid degeneration of the liver induced by PCBs and the relation between the grade and the dose require further studies.

The results of series II show the synergistic effect of PCBs and BHC on hepatic tumorigenesis. Previously, we found that the hepatocarcinogenic action of BHC in mice was due to the α-isomer not the β-, γ-, or δ-isomer (*15, 16*). The histologic changes in mouse liver induced by δ-BHC were much less than those induced by other isomers. Accordingly, in the present study, the effect of δ-BHC plus PCBs was not examined. We did confirm that hepatic neoplasms were induced in mice fed diets containing 500 or 250 ppm α-BHC alone for 24 weeks. But hepatocellular carcinomas developed only in groups on diets containing β-BHC when the diet was supplemented with PCBs. Furthermore, in the groups on diets containing 100 and 50 ppm α-BHC, hepatocellular carcinomas and nodular hyperplasias were induced only when the diet was supplemented with PCBs.

As reported, certain hepatocarcinogens have synergistic or promoting actions in rats (*29, 30*). The present results show that the hepatocarcinogenic actions of α-BHC or β-BHC are promoted by PCBs in mice. The retention of PCBs in the body has been studied by several investigators (*3, 4*). Now the promoting effects of PCBs and BHC on liver carcinogenesis must be followed up at environmental and social levels.

DSW 030124

STLCOPCB4014086

TABLE 4.—*Histopathologic findings in the liver of male dd mice treated with isomers of benzene hexachloride (BHC) and technical polychlorinated biphenyls (PCBs) for 24 weeks*

BHC or PCBs* in diet (ppm)	Effective number of mice†	Histopathology of liver			Liver nodules (percent)	
		Oval cells	Bile-duct proliferation	Cellular hypertrophy	Nodular hyperplasia	Hepatocellular carcinoma
α-BHC(250)	30	±	±	+++	23 (76.7)	8 (26.7)
α-BHC(250)+PCBs-5(250)	26	+	+	+++	21 (80.8)	15 (57.6)
α-BHC(100)	26	—	—	+	0 —	0 —
α-BHC(100)+PCBs-5(250)	25	±	±	++	8 (32.0)	1 (4.0)
α-BHC (50)	28	—	—	—	0 —	0 —
α-BHC (50)+PCBs-5(250)	30	—	—	++	9 (30.0)	2 (6.7)
β-BHC(250)	26	—	—	+	0 —	0 —
β-BHC(250)+PCBs-5(250)	29	±	±	+++	16 (55.2)	6 (20.7)
β-BHC(100)	26	—	—	—	0 —	0 —
β-BHC(100)+PCBs-5(250)	30	—	—	++	5 (16.7)	1 (3.3)
β-BHC (50)	28	—	—	—	0 —	0 —
β-BHC (50)+PCBs-5(250)	29	—	—	+	0 —	0 —
γ-BHC(250)	26	—	—	±	0 —	0 —
γ-BHC(250)+PCBs-5(250)	28	—	—	+	0 —	0 —
γ-BHC(100)	28	—	—	—	0 —	0 —
γ-BHC(100)+PCBs-5(250)	30	—	—	+	0 —	0 —
γ-BHC (50)	28	—	—	—	0 —	0 —
γ-BHC (50)+PCBs-5(250)	27	—	—	+	0 —	0 —
PCBs-5(250)	20	±	±	+	0 —	0 —
Controls	20	—	—	—	0 —	0 —

*PCBs-5, Kanechlor 500.
†Mice dying during the experiment were not included.

Histologically, the liver nodules induced by PCBs-5 were nodular hyperplasias and well-differentiated hepatocellular carcinomas. Ultrastructurally, the carcinomatous and non-neoplastic areas appeared similar to those induced by α-BHC or DDT (*31*, *32*). The ultrastructure of the cells of hepatocellular carcinomas induced by PCBs or BHC was different from that of hyperplastic nodules developing spontaneously in C3H mouse liver (*16*, *33*, *34*). Histologic findings in the liver, especially in areas of nodular hyperplasia and hepatocellular carcinoma in mice treated with BHC, were not influenced by treatment with PCBs. However, development of amyloid degeneration of mouse liver induced by PCBs was clearly prevented by administration of BHC.

In analysis of the mechanism of the carcinogenic action of PCBs, further studies are also required on the promoting effects of PCBs on BHC-hepatocarcinogenesis.

REFERENCES

(*1*) HOLES DC, SIMMONS JH, TATTON JOG: Chlorinated hydrocarbons in British wildlife. Nature (Lond) 216:227–229, 1967

(*2*) KOEMAN JH, THE NOEVER DE BRAUW MC, DE VOS RH: Chlorinated biphenyls in fish, mussels and birds from the river Rhine and the Netherlands coastal area. Nature (Lond) 221:1126–1128, 1969

(*3*) REYNOLDS LM: Polychlorobiphenyls (PCBs) and their interference with pesticide residue analysis. Bull Environ Contam Toxicol 4:128–143, 1969

(*4*) PRESTT I, JEFFERIES DJ, MOORE NW: Polychlorinated biphenyls in wild birds in Britain and their avian toxicity. Environ Pollution 1:3–26, 1970

(*5*) DUKE TW, LOWE JI, WILSON AJ: A polychlorinated biphenyl (Aroclor 1254) in the water, sediment, and biota of Escambia Bay, Florida. Fla Bull Environ Contam Toxicol 5:171–180, 1970

(*6*) PEAKALL DB, LINGER JL: Polychlorinated biphenyls, another long life widespread chemical in the environment. Bioscience 20:958–964, 1970

(*7*) RISEBROUGH RW, RIECHE P, PEAKALL DB, et al: Polychlorinated biphenyls in the global ecosystem. Nature (Lond) 220:1098–1102, 1968

(*8*) TSAO CH, SULLIVAN WN, NORNSTEIN I: A comparison of evaporation rates and toxicity to house flies of lindane and lindane-chlorinated polyphenyl desposits. J Econ Entomol 46:882–884, 1953

(*9*) VOS JG, BEEMS RB: Dermal toxicity studies of technical polychlorinated biphenyls and fractions there of in rabbits. Toxicol Appl Pharmacol 19:617–633, 1971

(*10*) NAGASAKI H, TOMII S, MEGA T, et al: Hepatocarcinogenicity of polychlorinated biphenyls in mice. Gann 63:805, 1972

(*11*) KIMURA N, BABA T: Neoplastic changes in the rat liver induced by polychlorinated biphenyl. Gann 64:105–108, 1973

(*12*) KOLLER LD, ZINKL JG: Pathology of polychlorinated biphenyls in rabbits. Am J Pathol 70:363–378, 1973

DSW 030125

STLCOPCB4014087

(13) FUHREMANN TW, LICHTENSTEIN EP: Increase in the toxicity of organophosphorus insecticides to house flies due to polychlorinated biphenyl compounds. Toxicol Appl Pharmacol 22:628–640, 1972

(14) NAGASAKI H, TOMII S, MEGA T, et al: Carcinogenicity of benzene hexachloride (BHC). *In* Topics in Chemical Carcinogenesis, Proc 2d Int Symp of The Princess Takamatsu Cancer Research Fund. Tokyo, Univ Tokyo Press, 1972, pp 343–353

(15) NAGASAKI H, TOMII S, MEGA T, et al: Hepatocarcinogenic effect of α-, β-, γ- and δ-isomers of benzene hexachloride in mice. Gann 63:393, 1972

(16) ITO N, NAGASAKI H, ARAI M, et al: Histologic and ultrastructural studies on hepatocarcinogenicity of benzene hexachloride in mice. J Natl Cancer Inst 51:817–826, 1973

(17) COOK JW, HEWETT CL, KENNAWAY EL, et al: Effects produced in livers of mice by azo-naphthalenes and related compounds. Am J Cancer 40:62–77, 1940

(18) ARMSTRONG RC, BONSER GM: The carcinogenic action of 2-acetylaminofluorene on various strains of mice. J Pathol 59:19–27, 1947

(19) HESTON WE, VLAHAKIS G, DERINGER MK: High incidence of spontaneous hepatoma and the increase of this incidence with urethan in C3H, C3Hf, and C3He male mice. J Natl Cancer Inst 24:425–435, 1960

(20) KELLY MG, O'GARA RW: Induction of tumors in newborn mice with dibenz[*a,h*]anthracene and 3-methylcholanthrene. J Natl Cancer Inst 26:651–679, 1961

(21) KLEIN M: Susceptibility of strain B6AF$_1$/J hybrid infant mice to tumorigenesis with 1,2-benzanthracene, deoxycholic acid and 3-methylcholanthrene. Cancer Res 23:1701–1707, 1963

(22) NISHIZUKA Y, ITO K, NAKAKUKI K: Liver tumor induction by a single injection of o-aminoazotoluene to newborn mice. Gann 56:135–142, 1965

(23) TAKAYAMA S, OOTA K: Induction of malignant tumors in various strains of mice by oral administration of N-nitrosodimethylamine and N-nitrosodiethylamine. Gann 56:189–199, 1965

(24) ROE FJ, WARWICK GP, CARTER RL, et al: Liver and lung tumors in mice exposed at birth to 4-dimethylaminoazobenzene or its 2-methyl or 3′-methyl derivatives. J Natl Cancer Inst 47:593–601, 1971

(25) TOMATIS L, TURUSOV V, DAY N, et al: The effect of long-term exposure to DDT on CF-1 mice. Int J Cancer 10:489–506, 1972

(26) DAVIS KJ, FITZHUGH OG: Tumorigenic potential of aldrin and dieldrin for mice. Toxicol Appl Pharmacol 4:187–189, 1962

(27) NAGASAKI H, TOMII S, MEGA T, et al: Development of liver tumors in mice and rats treated with BHC-isomers (α-, β-, γ- and δ). Proc Jap Cancer Assoc, 31st Annual Meet, 33, 1972

(28) HIRAO F, FUJISAWA T, TSUBURA E, et al: Experimental amyloidosis induced by 20-methylcholanthrene in rabbits. Acta Pathol Jap 17:23–35, 1967

(29) MACDONALD JC, MILLER EC, MILLER JA, et al: The synergistic action of mixtures of certain hepatic carcinogens. Cancer Res 12:50–54, 1952

(30) ITO N, HIASA Y, KONISHI Y, et al: The development of carcinoma in liver of rats treated with m-toluylenediamine and the synergistic and antagonistic effects with other chemicals. Cancer Res 29:1137–1145, 1969

(31) ORTEGA P: Light and electron microscopy of dichlorodiphenyltrichloroethane (DDT) poisoning in the rat liver. Lab Invest 15:657–679, 1966

(32) ARAI M, SUGIHARA S, HIASA Y, et al: On ultrastructural findings of liver tumors in mice treated with benzene hexachloride (BHC). Proc Jap Cancer Assoc, 31st Annual Meet, 107, 1972

(33) ESSNER E: Ultrastructure of spontaneous hyperplastic nodules in mouse liver. Cancer Res 27:2137–2152, 1967

(34) HRUBAN Z, KIRSTEN WH, SLESERS A: Fine structure of spontaneous hepatic tumors of male C3H/fGs mice. Lab Invest 15:576–588, 1966

DSW 030126

STLCOPCB4014088



FIGURE 1.—Numerous yellowish nodules in the liver of male mouse treated with 500 ppm PCBs-5 for 32 weeks.

FIGURE 2.—Focal cell hypertrophy in the liver of male mouse treated with 500 ppm PCBs-4 for 32 weeks. × 100

FIGURE 3.—Extensive amyloid deposits in periportal areas of lobules. Round, ovoid, or doughnut-shaped amyloid deposits and abnormally narrow liver cell cords are visible. × 100

FIGURE 4.—Typical hyperplastic nodules compressing surrounding parenchyma in male mouse treated with 500 ppm PCBs-5 for 32 weeks. × 100

DSW 030127

STLCOPCB4014089



FIGURE 5.—Hepatocellular carcinoma in male mouse treated with 500 ppm of PCBs-5 for 32 weeks. Dilation of sinusoidal spaces and increased number of nuclei in cell cords are visible. Mitotic figures and nuclear irregularities also shown. × 100

FIGURE 6.—Well-differentiated hepatocellular carcinoma in male mouse treated with 250 ppm β-BHC plus 250 ppm PCBs-5 for 24 weeks. Cells irregular and there is increased number of nuclei in cell cords. Sinusoidal spaces are visible. × 100

DSW 030128

STLCOPCB4014090

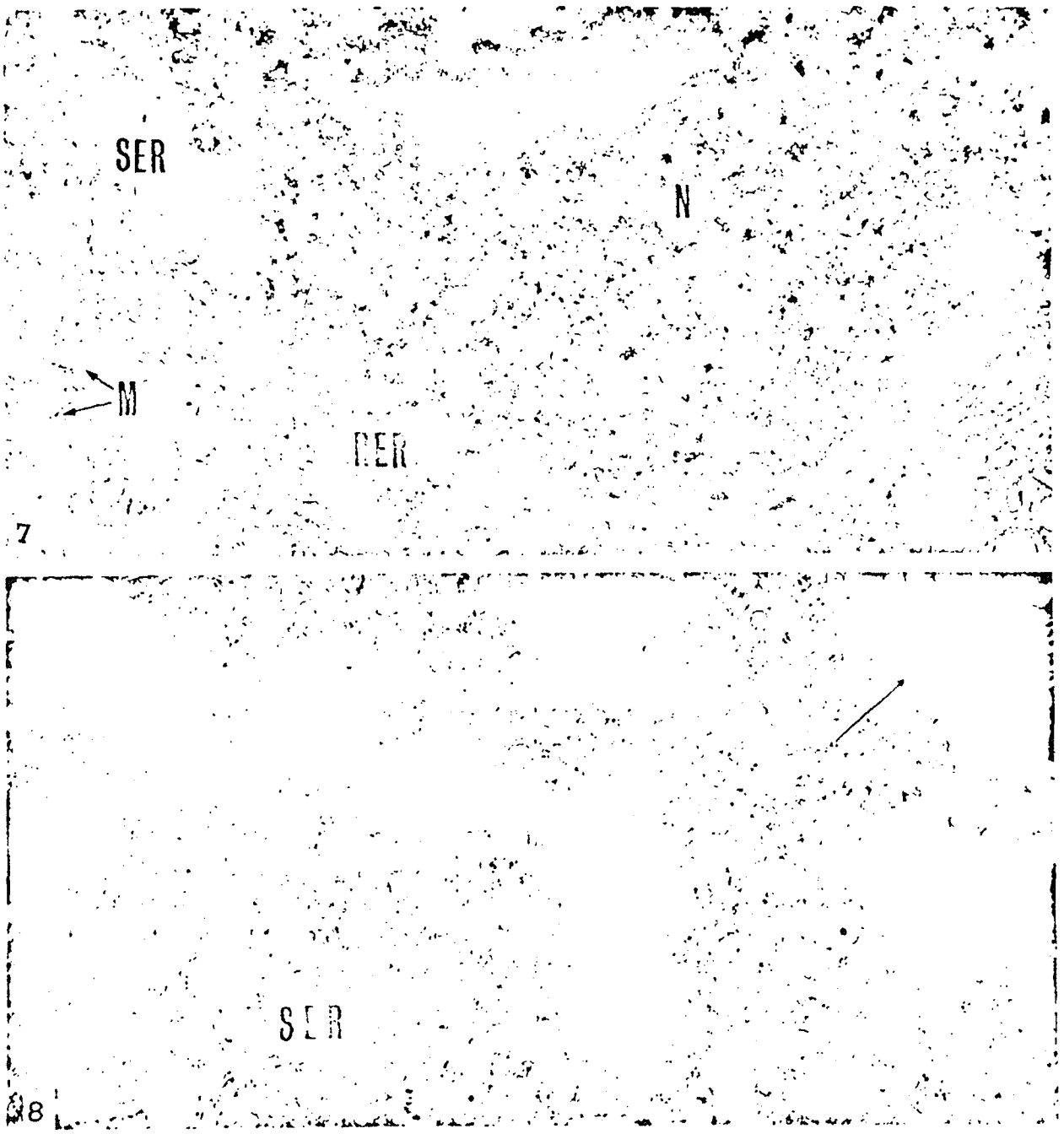

FIGURE 7.—Hepatocellular carcinoma cells induced in liver of mouse by 500 ppm PCBs-5 for 32 weeks. Nucleus (N) is irregular; diffuse masses of smooth endoplasmic reticulum (SER), and decreased rough endoplasmic reticulum (RER). Mitochondrial changes (M, *arrows*) are remarkable. × 12,000

FIGURE 8.—Hepatocellular carcinoma cell induced by 500 ppm PCBs-5 in the liver of mouse for 32 weeks. Mitochondrial changes (M) and increased SER are visible. Concentrated lamellar body (*arrow*). × 30,000

DSW 030129

STLCOPCB4014091



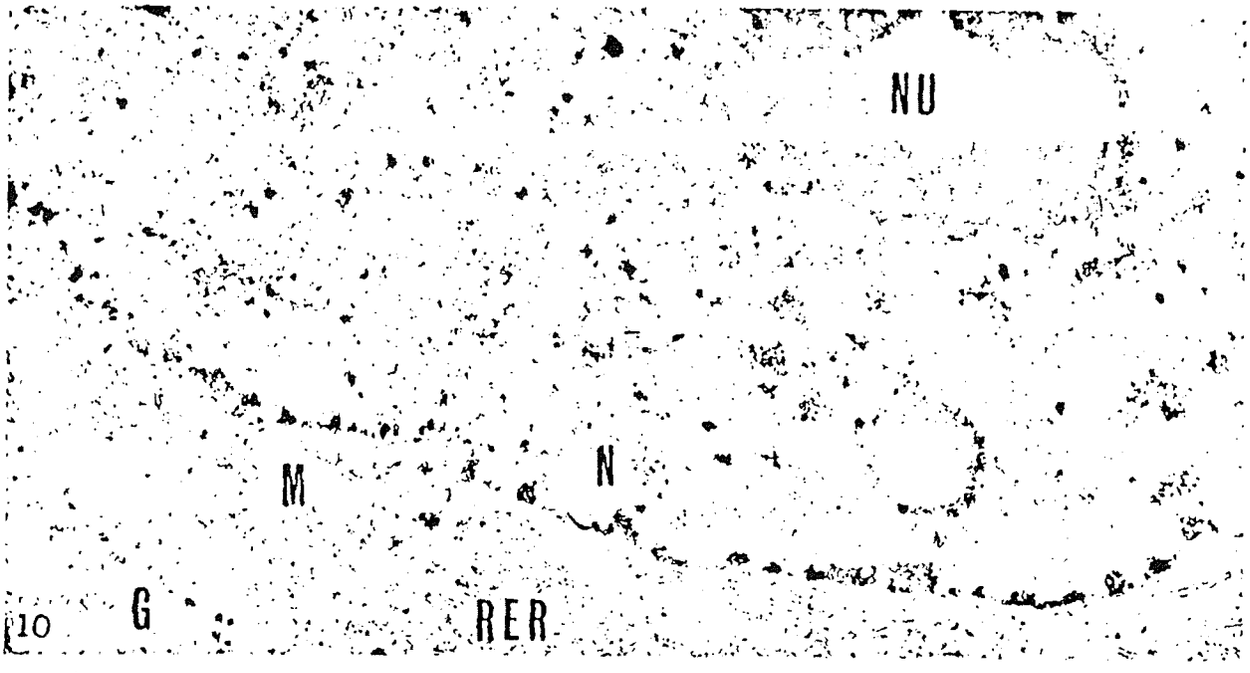

FIGURE 9.—Hepatocellular carcinoma cell induced by 500 ppm PCBs-5 for 32 weeks in a mouse. Nucleus (N) has irregular contour. Nucleoli (NU, *arrows*) and nuclear inclusion (1B). × 16,000

FIGURE 10.—Non-neoplastic cell induced by 500 ppm PCBs-5 for 32 weeks in liver of mouse. No remarkable changes are seen in the nucleus (N), nucleolus (NU), and glycogen granules (G), but there is decrease in the RER. × 12,000

DSW 030130

STLCOPCB4014092