Induction of Liver Tumors in Sherman Strain Female Rats by Polychlorinated Biphenyl Aroclor 1260[1,2]

Renate D. Kimbrough,[3] Robert A. Squire,[4] Ralph E. Linder,[5] John D. Strandberg,[6] Richard J. Montali,[6] *and* Virlyn W. Burse[5,7]

SUMMARY—Sherman strain female rats (200) were fed 100 ppm of a polychlorinated biphenyl (Aroclor 1260) for approximately 21 months, and 200 female rats were kept as controls. The rats were killed when 23 months old. Twenty-six of 184 experimental animals and 1 of 173 controls had hepatocellular carcinomas. None of the controls but 146 of 184 experimental rats had neoplastic nodules in their livers, and areas of hepatocellular alteration were noted in 28 of 173 controls and 182 of 184 experimental animals. Thus the polychlorinated biphenyl Aroclor 1260, when fed in the diet, had a hepatocarcinogenic effect in these rats. The incidence of tumors in other organs did not differ appreciably between the experimental and control groups.—J Natl Cancer Inst 55: 1453–1459, 1975.

Polychlorinated biphenyls (PCB's) have been used over the past 44 years as transformer, capacitor, and cooling fluids in various systems (*1*). Since they are excellent dielectrics and flame retardants, many new industrial uses have been found for them, particularly in the past two decades. These compounds are persistent as environmental contaminants and were first established as pollutants in 1966 (*2*). The toxicity of these and related compounds has recently been reviewed (*3*).

In a preliminary feeding study in which the toxicities of two PCB mixtures (Aroclor 1254 and Aroclor 1260) were compared (*4*), a bladder tumor was found in 1 of 10 female rats fed 100 ppm Aroclor 1260 in their diet. This bladder tumor was tentatively classified at the time as a poorly differentiated epidermoid carcinoma. Severe autolysis hampered the microscopic examination (Kimbrough RD: Unpublished observation). To establish whether this tumor had developed spontaneously or was induced by the PCB, 200 female rats were fed 100 ppm Aroclor 1260. Another group of 200 females were the controls. This paper reports the results of this study.

MATERIALS AND METHODS

Four hundred weanling Sherman strain COBS[8] female rats 21–26 days old and weighing 48–97 g were distributed into two groups of 200 animals each according to a table of random numbers. Ten animals were housed per cage in conventional humidity, light, and temperature-controlled surroundings. Two hundred rats were fed plain ground Purina Laboratory Chow and 200 were fed the same diet containing 100 ppm Aroclor 1260 (lot No. AK-3; Monsanto Industrial Chemical Co., St. Louis, Mo.). For incorporation of Aroclor 1260 into the diet, 5.2 g was dissolved in ethyl ether; this was added to 100 g cornstarch, and the ether was allowed to evaporate. The PCB cornstarch mixture was blended with increasing amounts of ground chow. The diets were prepared fresh every 10–14 days. Random samples from the final mixes and samples of control chow were taken at regular intervals to determine PCB levels, at first biweekly and later bimonthly.

For determination of the PCB levels, the samples were extracted for 2 hours on an automatic shaker with a 3:1 mixture of hexane and isopropanol (*5*). After filtration of the extract through glass wool, the extracts were washed with a 2% sodium chloride solution and dried with sodium sulfate. Samples were eluted through Florisil (*6*). The 6% fraction was collected and eluted through the silicic acid–celite column of Armour and Burke (*7*). Samples were analyzed by electron-capture, gas–liquid chromatography, and/or Coulson Conductometric gas–liquid chromatography.

During the first year of the study, three batches of food, both when first received and after having been in the food cups for a week, were analyzed for aflatoxins (*8*).

The combined body weight of rats in each cage was recorded weekly until the rats were 6 months old, biweekly until 12 months, and monthly thereafter. Individual weights were recorded only at the onset of the experiment and at death or when the animals were killed. The rats were observed briefly each day, and those exhibiting debilitating signs or large tumors were removed from the group cage and housed individually. At each weighing the animals were examined individually and abnormalities were noted. Food consumption was measured on all rats during the first 2 weeks of the experiment, and then during weeks 5, 8, 11, and 20, and every 12 weeks thereafter. The dietary exposure of the experimental group to Aroclor 1260 was discontinued 6 weeks before they were killed. Autopsies were performed on all that died. When the animals were 23 months old, they were anesthetized and their venae cavae were severed. Tissues were fixed in 10% buffered formalin and stained with hematoxylin and eosin. Selected tissue sections were stained with periodic acid-Schiff, Wilder's reticulum, azure eosin, and Masson's trichrome. In addition to tissue masses, the following organs were studied microscopically: brain, pituitary, thyroid, parathyroid, tra-

[1] Received May 20, 1975; accepted July 24, 1975.

[2] Supported in part by Public Health Service contrac's N01 CP43300 and N01 CP43288 from the Division of Cancer Cause and Prevention, National Cancer Institute.

[3] Toxicology Branch, Center for Disease Control, Public Health Service, U.S. Department of Health, Education, and Welfare, Atlanta, Ga. 30333.

[4] National Cancer Institute, National Institutes of Health, Public Health Service, U.S. Department of Health, Education, and Welfare, Bethesda, Md. 20014.

[5] Environmental Protection Agency (EPA), Research Triangle Park, N. C. 27711.

[6] The Johns Hopkins University, School of Medicine, Baltimore, Md., 21205.

[7] We thank Mr. Martin Goldstein, Federal Drug Administration (FDA), New Orleans District, for the feed analysis for aflatoxins and Mr. Sol Cohen, FDA, Atlanta District, for helpful suggestions. Mr. Richard Moore (EPA) assisted with animal care and autopsies.

[8] The Sherman rats are descendants of the Sherman strain developed at Columbia University from the Osborne Mendel strain. They have been randomly bred in our colony at the Center for Disease Control since 1950. They were cesarean obtained and barrier sustained (COBS) in 1966. In conventional rats, the incidence of murine pneumonia was high. Since they have been COBS, this is no longer a problem.

DSW 025860

STLCOPCB4009815

chea, esophagus, lung, stomach, kidney, heart, liver, spleen, adrenal, ovary, uterus, and urinary bladder. Student's *t*-test was used for comparison of mean body weights and mean weight gain.

RESULTS

The PCB concentrations in the experimental diet ranged usually from 70 to 107 ppm. Occasionally, lower values were found at the beginning of the study. The occurrence of low PCB concentrations in the experimental diet was later resolved by improvement of the extraction method. PCB's in the control diets were less than 0.1 ppm and usually below the limit of detection. Aflatoxins were not detected in either diet. The sensitivity levels were 2.5 ppb aflatoxins B_1 and G_1 and 0.1 ppb aflatoxins B_2 and G_2. A study in which aflatoxin B_1 was added to a portion of the feed showed 94% recovery.

No definite dose-related signs of toxicity were observed in the test animals. Comparative curves of body-weight gain and food consumption on the basis of body weight, as well as PCB intake of the test group, are given in text-figures 1 and 2. A slight decline in the rate of weight gain in the test group compared to that in the control group began about 3 months after onset of the experiment. Mean final body weights were 420 g (SD = 72 g, SE = 5.4 g) for the control group and 392 g (SD = 62 g, SE = 4.6 g) in the test group; the difference was statistically significant ($P < 0.001$). Food consumption (text-fig. 2) was comparable in both groups. Mean weight gain was 350 g (SD = 70 g, SE = 5.3 g) and 323 g (SD = 60 g, SE = 4.5 g) for the control and test groups, respectively; the difference in weight gain was also statistically significant ($P < 0.001$). PCB intake declined from 11.6 mg/kg/day during the first week of exposure to 6.1 mg/kg/day at 3 months of exposure and to 4.3 mg/kg/day at 20 months (text-fig. 2).

Pathologic Findings

Control rats (173) and experimental animals (184) were examined grossly and microscopically. The experimental group included 5 rats that were killed 1–2 months before the final kill. The remaining animals were not included because of improper tissue fixation or because they died early in the experiment.

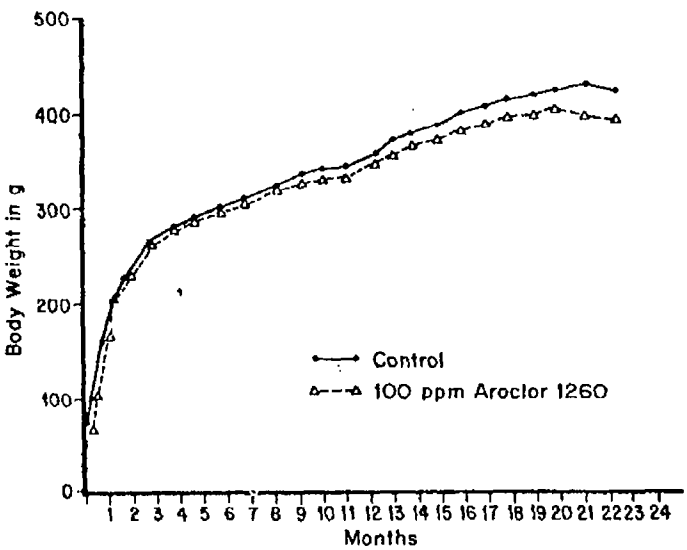

TEXT-FIGURE 1.—Average body weight of control rats and those consuming Aroclor 1260.

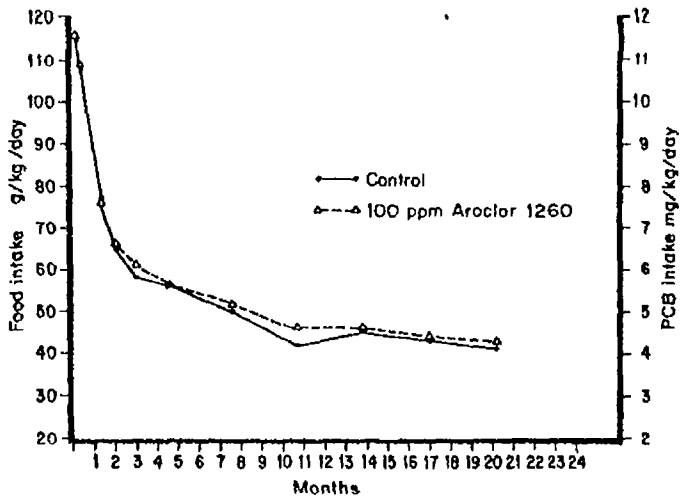

TEXT-FIGURE 2.—Food intake of control and experimental rats and consumption of Aroclor 1260 by experimental rats.

A consistent difference in the appearance of the livers was observed between the experimental and control groups. Almost all (170/184) livers of the experimental animals had from a few to multiple elevated tan nodules on the surfaces; additional nodules were usually seen on sectioning. These nodules varied from 0.1 to several cm in diameter, and in some rats replaced almost the entire liver. In contrast, the liver of only one control showed gross abnormalities and was markedly enlarged, nodular, tan, and firm. In addition, a variety of tumors of other organs was observed in both the experimental and the control groups. The incidence and type of tumors are given in table 1.

Histologic examination showed that 26 experimental animals and 1 control with enlarged, nodular livers had hepatocellular carcinomas. The additional 144 experimental rats with gross liver nodularity had hepatocellular nodules characteristic of neoplastic nodules [synonym, "hyperplastic nodules" (*9*)]. A recent workshop sponsored by The National Cancer Institute[9] recommended the term "neoplastic nodules" for these lesions as a more accurate indication of their biologic significance. No nodules were in control animals.

The hepatocellular carcinomas were well-differentiated trabecular types (figs. 1–3), except for three in the experimental animals which had a glandular, papillary pattern (fig. 4). The trabecular tumors showed severe disruption of normal liver architecture and were usually easily recognized at low magnification. Liver plates, two or more cells thick in some areas, were arranged in haphazard linear, branching, or pseudoglandular patterns. Different patterns were usually present in the same tumor. Blunt-ended plates, sinusoidal ectasia, and congestion were frequent. The hepatocytes varied from a normal appearance to enlarged, acidophilic, or diffusely basophilic cells with large, hyperchromatic nuclei and prominent nucleoli. The cytoplasm often contained eosinophilic inclusions within vacuoles. Mitotic figures were sometimes present. Foci of coagulative necrosis were occasionally observed in cancerous areas, but there

[9] Rat Liver Tumor Workshop at Silver Spring, Md., Dec. 11–13, 1974; sponsored by Carcinogenesis, Division of Cancer Cause and Prevention, National Cancer Institute.

DSW 025861

STLCOPCB4009816

TABLE 1.—*Incidence and type of liver lesions and tumors of other organs examined histologically*

Organ or tissue	Type of lesion	Incidence	
		Controls	Experimental
Liver	Hepatocellular carcinoma	1/173	26/184
	Neoplastic nodules	0/173	144/184
	Foci or areas of cytoplasmic alteration	28/173	182/184
Thyroid gland	Parafollicular cell tumor	37/160	18/166
Adrenal gland	Pheochromocytoma	1/173	1/167
Pituitary gland	Chromophobe adenoma	41/153	28/139
	Carcinoma	0/153	1/139
Uterus	Endometrial polyp	18/149	25/163
	Adenocarcinoma	0/149	2/163
	Sarcoma of endometrial stroma	3/149	7/163
Urinary bladder	Transitional cell papilloma	1/167	0/169
Mammary gland	Fibroadenoma	17/173[a]	13/184[a]
	Adenocarcinoma	5/173[a]	1/184[a]
Salivary gland	Fibrosarcoma	1/173[a]	0/184[a]
Lung	Adenoma	2/173	2/184
Adipose tissue	Lipoma	0/173[a]	2/184[a]
Brain	Glioma	0/173	2/184
Ovary	Granulosa theca cell tumor	5/149	0/163
	Papillary adenoma	1/149	2/163
Hematopoietic system	Granulocytic leukemia	1/173	0/184
	Lymphoma	0/173	2/184
Kidney	Hemangioma	0/173	1/184
Thymus	Thymoma	1/173[a]	0/184[a]
Parathyroid gland	Adenoma	0/173	2/184
Skin	Fibroma	0/173[a]	1/184[a]

[a] Incidence based on gross detection with microscopic confirmation.

was no fibrosis or other evidence of chronic degenerative changes. Periodic acid-Schiff (PAS) without diastase stained carcinomas less intensely than uninvolved liver, which suggested a decrease in glycogen. Most carcinomas were more basophilic than the normal liver with azure eosin stain. No definite intravascular invasion or metastases were found.

Neoplastic nodules were generally spherical and well demarcated, and occupied areas equal to those of several liver lobules (fig. 5). The cells in these nodules were generally enlarged, and the cytoplasm was either ground-glass-appearing, diffusely basophilic, or clear. Enlarged hyperchromatic nuclei, double nuclei, and mitotic figures were often present. The cytoplasm frequently contained inclusions similar to those in the carcinomas, except they were larger and appeared as whorled, concentric lamellae. In previous studies (*3*) these formations were shown by electron microscopy to represent aggregates of smooth endoplasmic reticulum. The normal liver architecture was absent within nodules, and cells were in sheets or irregular plates. Portal areas and central veins were absent and sinusoids were dilated in some areas. At the periphery of the nodules, the surrounding liver plates were tangentially arranged and narrowed, due to compression (figs. 6, 7). Nodules varied in PAS positivity, but always differed from surrounding liver. Most nodules were more eosinophilic, and a few were more basophilic than the normal liver with azure eosin stain.

In 182 treated and 28 control animals, there were also foci or areas of hepatocytes with altered cytoplasm (figs. 8–10). In controls, these were mostly collections of cells with water-clear cytoplasm. In treated animals, most affected cells were enlarged and had eosinophilic, ground-glass-appearing cytoplasm or were diffusely basophilic and smaller than normal cells. In basophilic areas, sinusoids were dilated and liver plates somewhat tortuous. In general, the cells in these areas were like those in neoplastic nodules, but there were no architectural alterations, and plates of involved liver cells merged with the surrounding liver.

No unusual features were noted in tumors of other organs, and there were no apparent differences in incidence between experimental and control animals. Parafollicular thyroid tumors varied from small circumscribed nodules of pale, oval-to-spindle cells to masses that obliterated the gland and invaded the capsule. They were similar to those described by Boorman et al. (*10*). Other frequent tumors included pituitary chromophobe adenomas, mammary fibroadenomas, and endometrial polyps. Endometrial stromal sarcomas were also present in 10 animals.

The only bladder tumor observed was in a control animal. Therefore, the occurrence of the bladder tumor in the previous experiment was apparently unrelated to the ingestion of Aroclor 1260.

A few rats in the experimental group also showed areas of adenofibrosis (synonym, "cholangiofibrosis") of the liver, a lesion described previously following the administration of Aroclor 1260 (*4*).

DISCUSSION

The livers of treated animals showed neoplastic lesions in 170 of the 184 examined, and in only 1 of 173 controls. Although only 26 of the lesions in treated rats were clearly carcinomas according to traditional histologic criteria, neoplastic nodules are part of the spectrum of response to hepatocarcinogens and must be included in the evaluation of tumorigenesis.

In the past, these liver lesions have been interpreted in various ways, and different names have been used to report them: nodular hyperplasia, hyperplastic nodules (*11*), hepatomas (*12, 13*), and hepatic nodules (*14*). Similar ambiguity exists in the classification of human liver lesions of this type (*15*).

Several studies with known carcinogens have demonstrated the development of liver nodules, indistinguishable from the neoplastic nodules in this study, before the appearance of carcinoma (*11, 16–18*). In a recent review (*9*), the biology and significance of nodules and their relationship to hepatocellular carcinoma were thoroughly discussed. In our study, Aroclor 1260 induced a spectrum of nodules and cancers in treated animals as outlined by the Rat Liver Tumor Workshop.[9]

A few Japanese polychlorinated biphenyls and the American product, Aroclor 1254, have been shown to induce neoplastic liver lesions in rodents. In a study with male BALB/cJ mice, nodules were observed in the liver after 11 months' exposure to Aroclor 1254 (*19*). The Japanese PCB's Kanechlor 400 and 500 have reportedly produced liver tumors in female Donryu rats and male dd mice, respectively (*20, 21*). PCB's have a promoting effect on liver tumor induction by benzene hexachloride (*21*), whereas they protected male Sprague-Dawley rats from the tumor-inducing effect of three hepatocarcinogens: 3′-methyl-4-dimethylaminoazobenzene, *N*-2-fluorenylacetamide, and diethylnitrosamine (*22*). The authors suggested that this protective effect may be due to the induction of microsomal enzymes by PCB's. The animals treated only for 20 weeks probably did not receive

DSW 025862

STLCOPCB4009817

the material long enough for the PCB's to induce tumors.

It is not known whether mixtures of polychlorinated biphenyls that are primarily composed of isomers with four or less chlorines on the ring would also induce liver tumors, or whether only those mixtures containing an appreciable proportion of pentachlorobiphenyl, hexachlorobiphenyl, and heptachlorobiphenyl have this effect. Kanechlor 400 contains 3% dichlorobiphenyl, 32.8% trichlorobiphenyl, 43.8% tetrachlorobiphenyl, 15.8% pentachlorobiphenyl, and 4.6% hexachlorobiphenyl. Kanechlor 500 contains 5% trichlorobiphenyl, 26% tetrachlorobiphenyl, 55% pentachlorobiphenyl, and 13% hexachlorobiphenyl (*21*). Chlorinated dibenzofuran was found in one Kanechlor 400 sample (*23*). The composition of the Aroclor 1260 studied by us is not known. Sissons and Welti (*24*) analyzed Aroclor 1260 manufactured by Monsanto Chemicals Ltd. and concluded that hexachlorobiphenyl and heptachlorobiphenyl were major constituents.

REFERENCES

(*1*) Broadhurst MG: Use and replaceability of polychlorinated biphenyls. Environ Health Perspect 1:81–102, 1972

(*2*) Jensen S: A new chemical hazard. New Sci 32:612, 1966

(*3*) Kimbrough RD: The toxicity of polychlorinated polycyclic compounds and related chemicals. CRC Crit Rev Toxicol 2:445–498, 1974

(*4*) Kimbrough RD, Linder RE, Gaines TB: Morphological changes in livers of rats fed polychlorinated biphenyls. Arch Environ Health 25:354–364, 1972

(*5*) Dawsey LH, Barthel WF, Schutzmann RL, et al: Southhaven Region Manual. U.S. Department of Agriculture, Agriculture Research Service, Plant Pesticide Control Division, June 1965, pp 56–59

(*6*) Mills PA: Detection and semiquantitative estimation of chlorinated organic pesticide residues in foods by paper chromatography. J Assoc Off Agri Chem 42:734–740, 1959

(*7*) Armour J, Burke J: Method for separating polychlorinated biphenyls for DDT and its analogs. J Assoc Off Anal Chem 53:761, 1970

(*8*) Pons WA Jr, Cucullu AF, Lee LS: Determination of aflatoxins in mixed feeds. *In* Third International Congress of Food, Science and Technology (S.O.S./70). Washington, D.C., 1970, pp 705–711

(*9*) Farber E: Hyperplastic liver nodules. *In* Methods in Cancer Research, vol 7, chapt VIII. New York and London, Academic Press, 1973, pp 345–375

(*10*) Boorman GA, Van Boord M, Hollander CF: Naturally occurring medullary thyroid carcinoma in the rat. Arch Pathol 94:35–41, 1972

(*11*) Epstein S, Ito N, Merkow L, et al: Cellular analysis of liver carcinogenesis: The induction of large hyperplastic nodules in the liver with 2-fluorenylacetamide or ethionine and some aspects of their morphology and glycogen metabolism. Cancer Res 27:1702–1711, 1967

(*12*) Vesselinovitch SD, Mihailovich N: The induction of benign and malignant liver tumors by urethan in newborn rats. Cancer Res 28:881–887, 1968

(*13*) Edwards JE, White J: Pathologic changes, with special reference to pigmentation and classification of hepatic tumors in rats fed *p*-dimethylaminoazobenzene (butter yellow). J Natl Cancer Inst 2:157–183, 1941

(*14*) Popper H, Sternberg SS, Oser BL, et al: The carcinogenic effect of aramite in rats. Cancer 13:1035–1046, 1960

(*15*) Mays ET, Christopherson WM, Barrows GH: Focal nodular hyperplasia of the liver. Am J Clin Pathol 61:735–746, 1974

(*16*) Klavins JV, Kenney TD, Kaufman N: Hepatic nodules resembling tumors in rats after administration and withdrawal of ethionine. Proc Soc Exp Biol Med 89:540–543, 1965

(*17*) Popper H, de la Huerga J, Yesinick C: Tumors due to prolonged ethionine feeding. Science 118:80–82, 1953

(*18*) Wachstein M, Meisel E: Enzymatic histochemistry of ethionine induced liver cirrhosis and hepatoma. J Histochem Cytochem 7:189–201, 1959

(*19*) Kimbrough RD, Linder RE: Induction of adenofibrosis and hepatomas of the liver in BALB/cJ mice by polychlorinated biphenyls (Aroclor 1254). J Natl Cancer Inst 53:547–552, 1974

(*20*) Kimura NT, Baba T: Neoplastic changes in the rat liver induced by polychlorinated biphenyl. Gann 64:105–108, 1973

(*21*) Ito N, Nagasaki H, Aria M, et al: Histopathologic studies on liver tumorigenesis induced in mice by technical polychlorinated biphenyls and its promoting effect on liver tumors induced by benzene hexachloride. J Natl Cancer Inst 51:1637–1646, 1973

(*22*) Makiura S, Aoe H, Sugihara S, et al: Inhibitory effect of polychlorinated biphenyls on liver tumorigenesis in rats treated with 3′-methyl-4-dimethylaminoazobenzene, *N*-2-fluorenylacetamide, and diethylnitrosamine. J Natl Cancer Inst 53:1253–1257, 1974

(*23*) Roach JA, Pomerantz JH: The findings of chlorinated dibenzofurans in a Japanese polychlorinated biphenyl sample. Bull Environ Contam Toxicol 12:338–341, 1974

(*24*) Sissons D, Welti D: Structural identification of polychlorinated biphenyls in commercial mixtures by gas-liquid chromatography, nuclear magnetic resonance and mass spectrometry. J Chromatogr 60:15–32, 1971

DSW 025863

STLCOPCB4009818

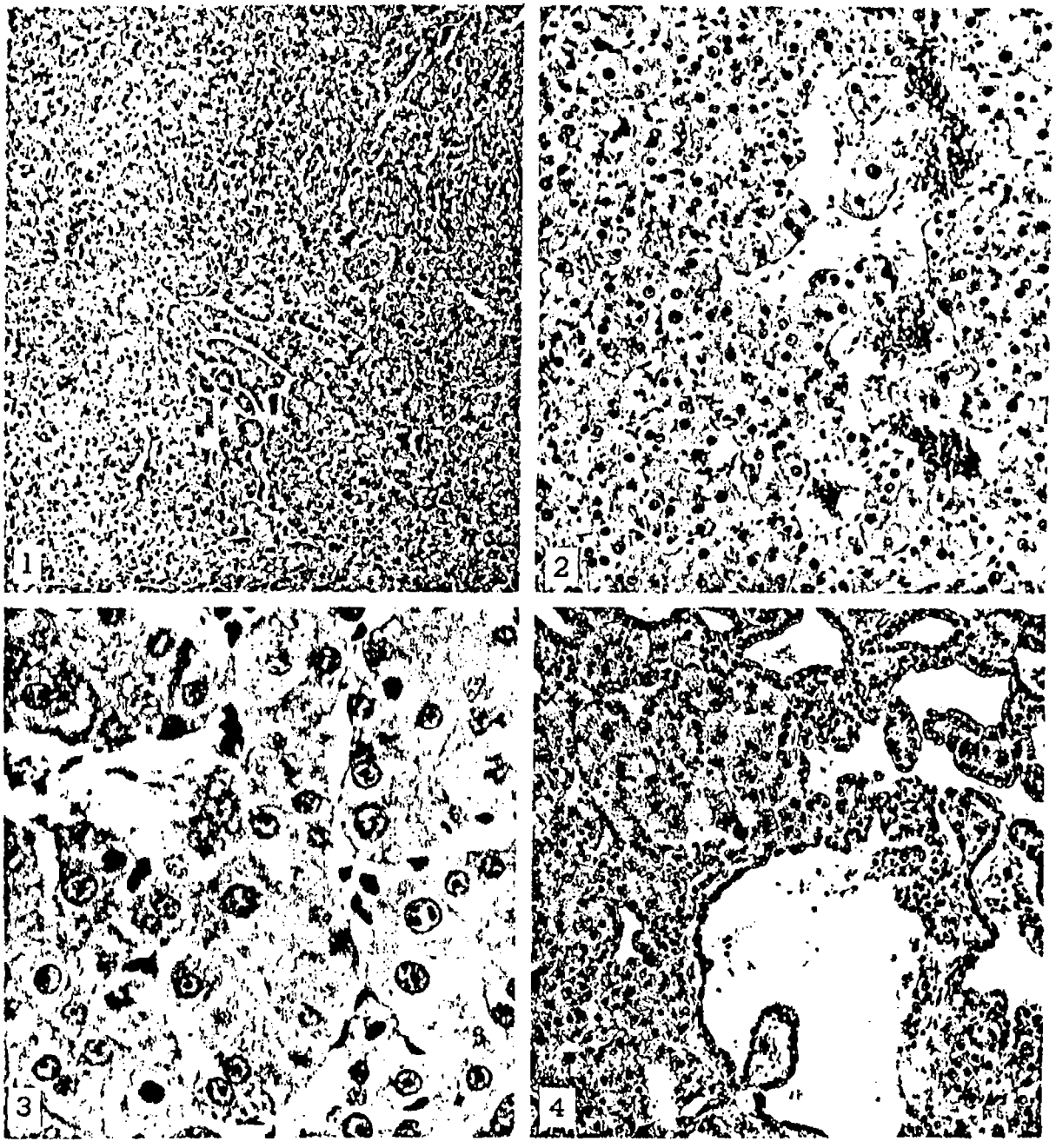

FIGURE 1.—Focus of hepatocellular carcinoma in rat fed Aroclor 1260. Tumor cells are in sheets, irregular nests, and cords. Hematoxylin and eosin (H & E). × 45

FIGURE 2.—Focus of hepatocellular carcinoma in rat fed Aroclor 1260. *Note* plates and nests of cells, two or more cells in thickness, enveloped by lining cells. H & E. × 115

FIGURE 3.—Focus of hepatocellular carcinoma in rat fed Aroclor 1260 showing nests of cells in pseudoacinar patterns. H & E. × 360

FIGURE 4.—Focus of hepatocellular carcinoma with glandular pattern in rat fed Aroclor 1260. H & E. × 105

DSW 025864

STLCOPCB4009819

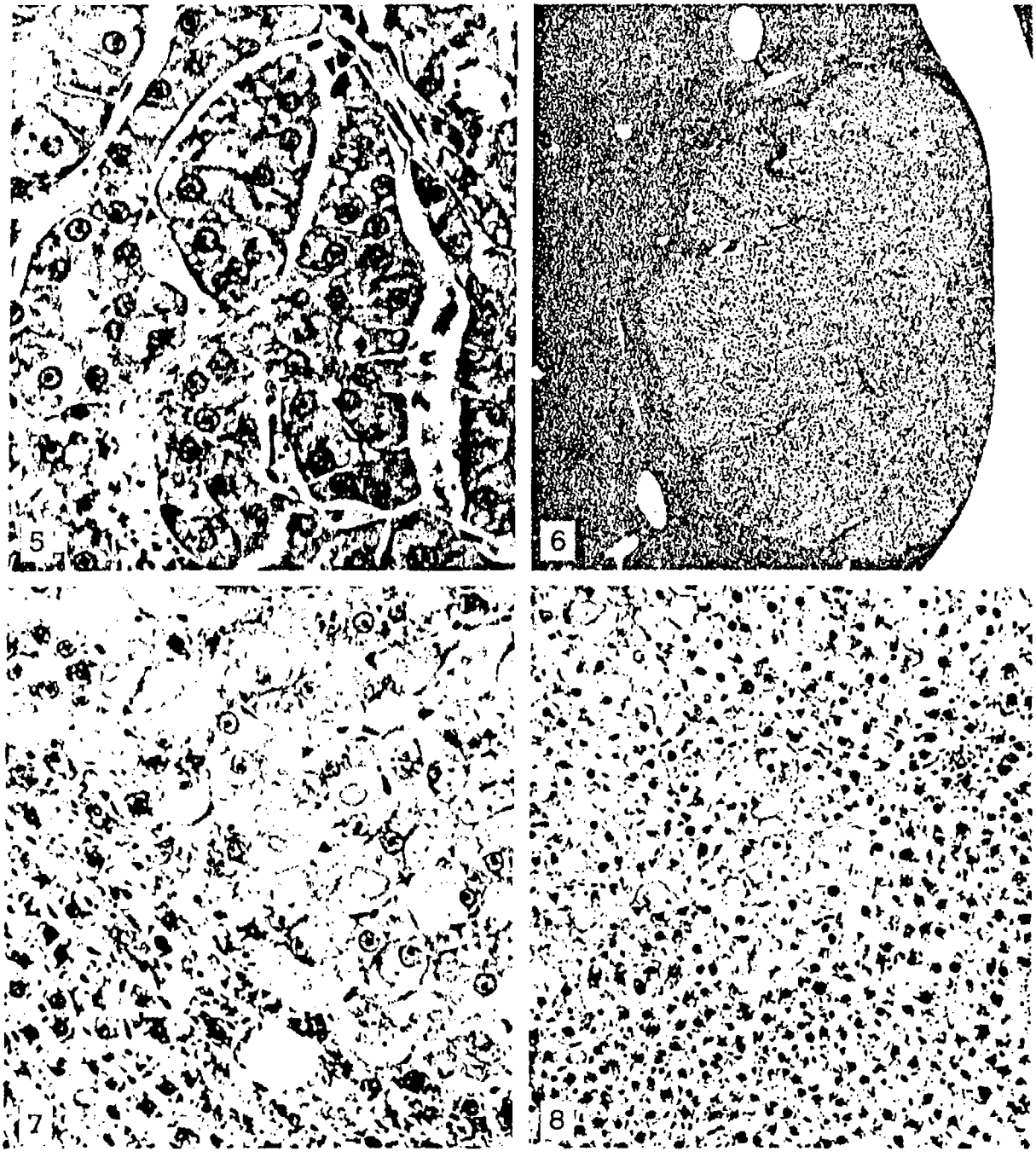

FIGURE 5.—Focus of hepatocellular carcinoma in rat fed Aroclor 1260. *Note* thick cell plates, hyperchromatic nuclei, and prominent nucleoli. H & E. × 360

FIGURE 6.—Neoplastic nodule in rat fed Aroclor 1260. Periphery is sharply demarcated from surrounding parenchyma. H & E. × 1

FIGURE 7.—Edge of neoplastic nodule in figure 6. Surrounding liver plates are compressed and tangentially arranged around nodule. *Note* eosinophilic, lamellar bodies in cytoplasm of nodule cells. H & E. × 330

FIGURE 8.—Area of clear-cell cytoplasmic alteration. H & E. × 185

DSW 025865

STLCOPCB4009820

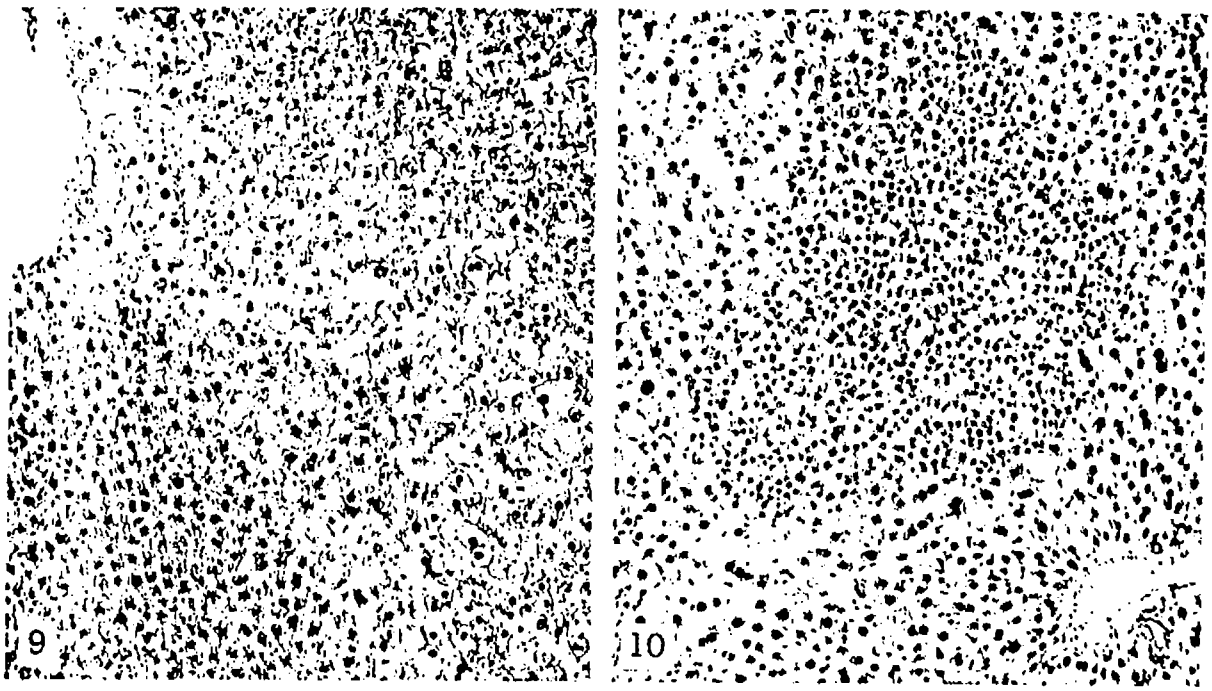

FIGURE 9.—Area of eosinophilic cytoplasmic alteration having the appearance of ground glass. H & E. × 185

FIGURE 10.—Area of basophilic cytoplasmic alteration. H & E. × 105

DSW 025866

STLCOPCB4009821