PLAINTIFF'S EXHIBIT

MET-583

The Biological Action of Inhaled Beryllium Sulfate

A Preliminary Chronic Toxicity Study on Rats

GERRIT W. H. SCHEPERS, M.D., D.Sc.; THOMAS M. DURKAN, M.E.; ANTHONY B. DELAHANT, and FRANCIS T. CREEDON, Saranac Lake, N. Y.

One of the first steps in the extraction of beryllium metal from beryl is treatment of the ground ore with sulfuric acid in order to form beryllium sulfate. In subsequent steps the sulfate is purified and converted to the oxide by calcination. During these operations, in certain circumstances, plant personnel can inhale beryllium sulfate in a particulate state (Williams[1]). For this reason an experimental investigation of the biological action of inhaled beryllium sulfate has practical significance.

From the point of view of biology, a study of beryllium sulfate presents the advantage that the compound is readily soluble. In investigations of the chronic biological effects of beryllium products, the over-all results of inhalation experiments conducted with beryllium metal fume and with the poorly soluble compounds of beryllium have been comparatively unrewarding. Thus, it has proved particularly difficult to reproduce in experimental animals the type of granulomata characteristic of the human chronic pulmonary disease (Schepers[2]).

The present paper records the results obtained from a series of studies on the long-range effects on the rat of inhaled beryllium sulfate. Acute and subacute toxicity studies on inhaled beryllium sulfate have previously been conducted with six species of animals by Sprague, LaBelle, Pettengill, and Stokinger.[3] A total of 56 animals were studied for periods not exceeding 40 days. Of these animals only 10 were rats. While a wide range of biochemical, hematological, and pathological criteria was explored, only the pulmonary reactions are relevant to the present inquiry. The animals showed pulmonary edema to a variable degree. It was most marked in hamsters, rats, and rabbits and least evident in guinea pigs. While inflammatory exudate in the terminal bronchi and focal atelectasis characterized the lesions in rabbits, hemorrhages into the alveolar sacs occurred in the hamsters, and the rats showed a moderate degree of infiltration of the pulmonary tissues by neutrophiles and monocytes. These results are significant in that they indicate that beryllium sulfate is capable of provoking considerable pulmonary damage when inhaled. It should be noted, however, that the above studies were conducted with an aerosol concentration of 90 mg. of $BeSO_4 \cdot 4H_2O$ per cubic meter—a very high dosage.

Systematic investigations into the long-range biological action of beryllium and its various compounds were initiated in the Saranac Laboratory in 1943 by the late Dr. Leroy U. Gardner. These studies have continued without interruption until the present time. Three of us (T. M. D., A. B. D., and F. T. C.) have been associated with all these experiments from their onset. One of the projects undertaken was an inhalation study with beryllium sulfate. The lack of a toxic effect of a mist of beryllium sulfate inhaled by guinea pigs for three hours daily for periods lasting from two and a half to four and a quarter months has been reported by Vorwald.[4] The only reaction was the sparse production of large mononuclear alveolar phagocytes.

Following the experiments in which beryllium sulfate mist failed to produce signifi-

Received for publication Oct. 8, 1956.

Director Saranac Laboratory and Trudeau Foundation (Dr. Schepers) and Associate Director Saranac Laboratory (Mr. Durkan)

Division of L... Management

Notice: This m... the copyright law. (Title 17, U. S. Code)

cant pulmonary changes in exposed guinea pigs, similar inhalation studies were carried on with rats. Material derived from those studies has not been at our disposal, and the results to be recorded in the present paper are based on work subsequently conducted by means of grants-in-aid awarded to the senior investigator (G. W. H. S.).

Materials and Methods

For the experimental investigation several pounds of beryllium sulfate were obtained in 1949 from the Clifton Products, Inc., through the cooperation of the Atomic Energy Commission. This original shipment has been the source material for all the experimental studies with beryllium sulfate subsequently carried on at the Saranac Laboratory. The material is a white, coarsely granular product soluble in water and on x-ray diffraction examination yields a pattern like that reported for $BeSO_4{\cdot}4H_2O$.[8]

The essential experimental principle comprised exposure of rats to an aerosol of beryllium sulfate in specially constructed octagonal chambers (Urban[9]). All the chambers employed were identical in every respect. These chambers were segregated in a special sealed-off section of an outbuilding both to provide greater safety for personnel and to minimize the risk of accidental exposure of other animals. The volume of the chamber was about 80 cu. ft., and fresh air was drawn in at the rate of about 8 to 10 cu. ft. per minute. Whenever animals were residing within the chamber, a constant supply of fresh air was maintained for 24 hours a day. This air was passed through a Fiberglas filter, the main purpose of which was to guard against any contamination of the atmosphere in the event that, through an accident, the chamber air should happen to be discharged back through the inlet.

To produce the aerosol, the beryllium sulfate was dissolved in distilled water to make a 1% solution, and the solution was atomized into a fine mist, which was introduced into the fresh air stream to the chamber at the point of inlet, located at the top center. The amount of compressed air used for atomization of the beryllium sulfate solution was negligible in comparison with the total volume of air passed through the chamber. Smoke studies of the pattern of air flow revealed that the aerosol was uniformly diffused throughout each chamber. The outgoing filtered air from all the chambers was led into a single duct and passed through a final ultrafilter before being discharged into the atmosphere.

At regular intervals the atmospheric concentration of beryllium sulfate in each chamber was determined by chemical analysis. In collecting samples for analysis, air was withdrawn from the interior of the chamber at a point just above the breathing level of the exposed animals and was passed through three fritted-disk gas washing bottles connected in series. Distilled water was used as the collecting fluid in the bottles. Most of the beryllium sulfate trapped by the sampling apparatus was recovered in the first bottle, but a small amount was carried over to the second and even to the third bottle. Routinely, the contents of the flasks, after the sample had been taken, were acidified slightly and filtered, and the sulfate was precipitated with barium chloride by the standard gravimetric method. In a few cases, as a check, samples were divided into two parts, one part being used for the sulfate determination and the other part for a beryllium determination by the fluorometric method of Klemperer and Martin.[7]

Some difficulty was experienced during the earlier part of the experiments in maintaining the concentration of the aerosol at a uniform level, and on several occasions wide fluctuations in the beryllium sulfate content of atmospheric samples were observed. Usually, however, the concentration of beryllium sulfate in each chamber was near the level sought. For the whole period of each exposure phase the atmospheric concentration was, on the average, about 12γ of $BeSO_4$ (1γ of Be) per cubic foot of air.

The number of animals used, their distribution according to strain, source, and sex, and other pertinent data are recorded in Table 1. As is evident, a total of 136 albino rats were exposed to the beryllium sulfate aerosol for periods up to six months, and a further 139 rats were kept as controls in a normal atmosphere in another building. Special precautions were taken to ensure that the control animals would not be exposed accidentally to any beryllium.

The Sherman rats used in the experiments were obtained from two separate commercial supply houses (Manor Farms and Sprague Dawley). The Wistar rats represented animals from the Saranac Laboratory colony which had been bred at the Laboratory during the past 10 years. For practical purposes the female animals predominated in the experiment, but a sufficient number of males was included to be sure that the effect of sex would not be overlooked in evaluating our results. At the start of the experiments the rats of the Sherman strain ranged in weight between 80 and 110 gm., and the rats of the Wistar strain between 140 and 210 gm.

Two basic experiments were conducted: In one (Study A) the period of exposure to the beryllium sulfate aerosol ranged from 1 day to 30 days, while in the other (Study B) the period was 180 days. As part of the experiments special attention was given to the control animals (Studies C and

TABLE 1.—*Tabulation of Rats in Experiment on the Biological Action of Beryllium Sulfate Aerosol*

Experimental Group: Exposed to Beryllium Sulfate Aerosol for Different Lengths of Time and Thereafter Allowed to Reside in Normal Air

Controls: Never Exposed to Beryllium Sulfate Aerosol

Animal Series	Experimental Group: Animals Exposed to $BeSO_4$		Controls: Animals Never Exposed to $BeSO_4$	
Group	A	B	C	D
No. of animals	21	115	70	69
Strain: Sherman	21	88	70	--
Strain: Wistar	--	27	--	69
Source: Sprague Dawley	21	3	59	--
Source: Manor Farms	--	60	11	--
Source: Saranac Laboratory	--	52	--	69
Sex: female	21	69	59	50
Sex: male	--	43	11	19
Duration of exposure, days	1-30	180	0	0
Average concentration of $BeSO_4$, γ cu. ft.	12	12	0	0
Period in normal air, mo.	3	18	20	22
Intercurrent deaths				
Under exposure	0	46	--	--
In normal air	2	12	5	5

D). In the first study (Study A) three groups, each composed of seven rats, were exposed in the same chamber to the aerosol for, respectively, one day, one week, and one month. In the case of the one-day exposure the beryllium sulfate mist was disseminated for 8 hours, but the rats remained in the exposure chamber for a further 16 hours. On removal, four were immediately killed, while three were allowed to live in normal air for a period of three months. A similar procedure was followed for the rats exposed for a week and for a month. It should be noted, however, that a week in this case represents an exposure to the beryllium sulfate aerosol of eight hours a day on five days, four hours on Saturday, and no exposure on Sunday. These nine animals that were allowed to survive in normal air are not reported on in this study but will form the basis of a subsequent communication dealing with the delayed effect of transient exposures to beryllium compounds.

For the 115 rats which inhaled the beryllium sulfate aerosol for 180 days (Study B), a schedule similar to that of Study A was followed, but, owing to limitations of space, the animals were exposed in three separate chambers, and the experiment was conducted in two phases. During the period while the animals were being exposed to the beryllium sulfate aerosol, 46 of the 136 rats died, and a further 29 were killed. Of the latter group 15 were sampled on completion of the full period of 180 days of exposure, and the other 14 were killed prior to the end of the third month of exposure. In addition, there were the nine rats mentioned in the preceding paragraph. This left a balance of 52 rats which were transferred to normal air and observed for periods up to 18 months. During this time 12 animals died, and the remainder were killed in the order shown in Table 2.

Of the 139 control animals 70 were of the Sherman strain (Study C) and 69 of the Wistar strain (Study D). These animals were killed in sets of three or four at intervals of two months. Only five of the Sherman group and five of the Wistar group died of natural causes. The changes which developed in these two strains of laboratory rats could thus be followed over periods of 20 and 22 months, respectively, and could be contrasted with the lesions provoked in the lungs of the rats which had been exposed to beryllium sulfate aerosol.

Intercurrent Deaths

Since Sprague, LaBelle, Pettengill, and Stokinger [3] had previously demonstrated that animals which inhaled beryllium sulfate aerosol in relatively high concentrations developed an acute form of chemical pneumonitis, the prevalence of spontaneous deaths in our series of animals requires some comment. As is shown in Table 2, the majority of those deaths occurred during the first three months. The fact that no animals from the control group died during this period tended to incriminate the beryllium sulfate as a factor in the cause of the deaths. The majority of these animals died from a subacute to chronic type of pleuropericarditis with a tendency to chronic macrophage pneumonitis and multiple abscess formation. No pathogenic bacteria could be isolated from these lesions. Nevertheless, in spite of these indications that the beryllium sulfate may have been the cause,

TABLE 2.—*Effect of Inhaled Beryllium Sulfate Aerosol on the Lungs of Rats: Gross Observations*

Period of Experiment, Mo.	No. of Animals	Mode of Death	Gross Observations: Miscellaneous Lesions: Perforations	Miscellaneous Lesions: Pleurisy	Miscellaneous Lesions: Pneumonitis	Miscellaneous Lesions: Abscess	Miscellaneous Lesions: Atelectasis	Reactive Foci: Discrete	Reactive Foci: Coalescent	Pulmonary Tumors: Large	Pulmonary Tumors: Medium	Pulmonary Tumors: Small	Lymphatic System Tumor
Exposure to Beryllium Sulfate Aerosol													
Up to 1	31	18 died 13 killed	8	4	5	6	..	..	..	..	..	..	..
2 and 3	24	23 died 1 killed	6	6	7	7	1	..	..	..	..	..	..
4 and 5	5	5 died	2	2	2	3	..	2	..	..	..	..	..
6	15	15 killed	..	..	..	..	..	12	7	..	..	..	..
Residence in Normal Air After Six months. Exposure to Beryllium Sulfate Aerosol													
1	6	4 died 2 killed	..	..	3	4	..	3	2	..	..	..	1
3	4	4 killed	..	..	..	..	..	4	1	..	..	..	1
4	1	1 died	..	..	..	1	..	1	1	..	..	..	1
6	5	1 died 4 killed	..	..	1	..	..	5	3	..	..	4	..
7	2	2 died	..	..	..	..	..	2	2	..	..	..	1
9	4	4 killed	..	..	..	..	..	4	4	1	2	..	..
10	15	15 killed	..	..	..	..	3	15	15	11	3	29	..
12	1	1 killed	..	..	..	..	..	1	1	1	2	1	..
14	2	1 died 1 killed	..	..	..	..	..	2	1	..	1	3	..
16	1	1 died	..	..	..	..	..	1	1	..	..	4	..
17	4	1 died 3 killed	..	..	..	1	2	4	..	..	2	3	1
18	7	1 died 6 killed	..	..	..	..	..	7	..	6	6	5	..

Figures in Columns 1 to 7, under Gross Observations, refer to the number of animals in which the lesion was found; in Columns 8 to 11, to the number of tumors found.

we are satisfied, for the following reasons, that the deaths represented an intercurrent epizootic. First, deaths ceased rather promptly after sulfathiazole and sodium bicarbonate were added to the drinking water furnished to the animals. This therapy was continued for a period of several weeks, until there were no more deaths. Second, the deaths were limited to animals in the first two chambers in which beryllium sulfate exposures were maintained. In the third chamber, in which exposures were commenced several months after the exposures in the first two chambers were terminated, no deaths occurred during the full six-month period, nor were there any deaths in the animals exposed for a month in Study A. In more recent experiments additional sets of 10, 110, and 30 rats have been exposed to a beryllium sulfate aerosol, which had about the same concentration as before, for periods of nine, six, and three months, respectively, without losing a single animal. This suggests rather conclusively that at a concentration of approximately 12γ per cubic foot of air beryllium sulfate by itself does not induce either an acute or a subacute pulmonary inflammatory reaction. The possibility that the inhaled beryllium may have facilitated a latent virus-caused pneumonitis has not, however, been wholly excluded. In this connection it may be mentioned that the rats bred at the Saranac Laboratory have been relatively disease-free for a considerable time.

Pulmonary Responses During Exposure

Prior to the third month of exposure there were no pulmonary reactions other than those associated with the intercurrent infections. In those animals that died during the fourth and fifth months of exposure, isolated gross foci of reaction could be identified, but they were not clearly linked to the inflammatory process which killed the animals. Histopathological changes were sparse and inconclusive. Mild bronchitis and pulmonary hyperemia sometimes occurred in animals which did not die from pulmonary

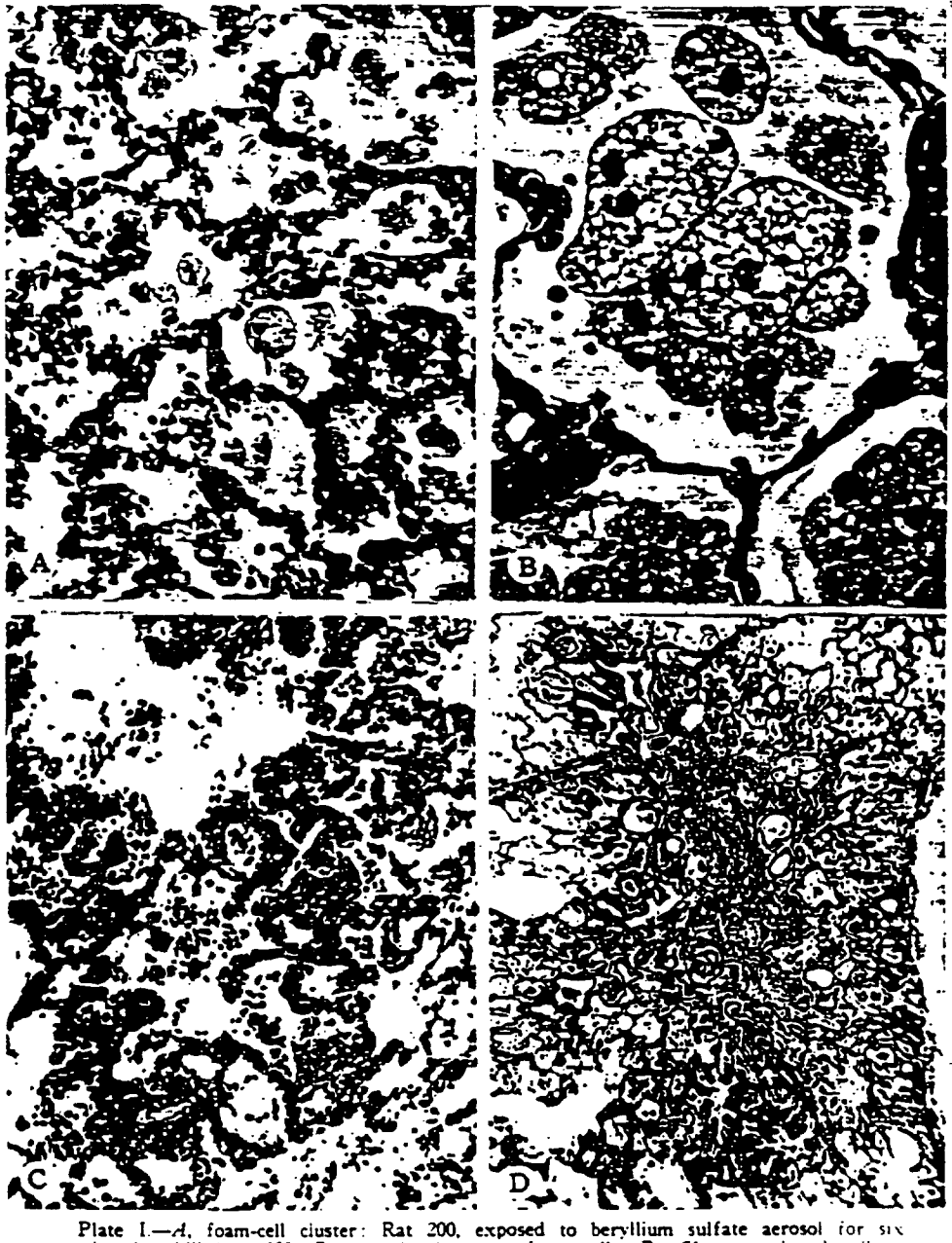

Plate I.—*A*, foam-cell cluster: Rat 200, exposed to beryllium sulfate aerosol for six months, then killed; × 350. *B*, intra-alveolar giant foam cells: Rat 21, exposed to beryllium sulfate aerosol for 6 months, then in normal air 10 months; × 800. *C*, focal mural cellular infiltration: Rat 198, exposed to beryllium sulfate aerosol for six months, then killed; × 175. *D*, focus of interstitial cellular infiltration and partial fibrosis, surrounded by epithelialized distorted alveoli: Rat 26, exposed to beryllium sulfate aerosol for six months, then in normal air six months; × 65.

disease. Also, in the other organs surveyed (liver, spleen, kidney, pancreas, thyroid, suprarenal, pulmonary and hepatic lymph nodes) no abnormalities could be demonstrated. In these organs the beryllium sulfate either proved to be inert as a direct chemical pathogen or did not become deposited in concentrations sufficient to provoke even the least cytological deviations commonly associated with mild metallic toxicity.

In the majority of the animals killed at the end of six months of exposure to the beryllium sulfate aerosol, there were macroscopically detectable multiple small grayish-white subpleural foci of reaction in variable numbers (Table 2). In most instances the lungs were moderately well seeded with such discrete lesions, and in about half the cases there was some tendency toward marginal coalescence of individual foci. On histological examination the macroscopically detectable grayish-white foci resolved themselves into zones of reaction of variable composition.

Foam-Cell Clusters.—Collections of foamy macrophages in several adjacent subpleural lobules were the chief explanation for the macroscopically detectable lesions (Plate I, *A*, *B*). Each of the animals killed at the end of six months possessed such foam-cell clusters (Table 3), and an average of about three cluster units could be counted in single whole-lung sections passing through the midcoronal plane. There was considerable variation in the prevalence of these areas, some rats showing as many as eight while others had only one or two. There was variation also in the number of alveolar spaces involved in each unit, but in most instances it was clearly apparent that the foam cells had congregated within discrete pulmonary lobules. Marginal confluence was achieved through involvement of contiguous lobules rather than through spillage of the reaction beyond the anatomical limits of individual lobules. At this early stage the majority of the affected areas lay immediately beneath the pleura. In those instances where foam-cell clusters were demonstrable more centrally, they were generally confined to lung parenchyma abutting on ramifications of larger blood vessels or bronchi.

The foam-cell units possessed further characteristics worth recording. The component foam cells varied from small mononucleated to large multinucleated macrophages. The nuclear chromatin stained intensely, and there were large karyosomes. The cytoplasm was relatively excessive and somewhat granular, and the vacuoles which usually impart to such cells their foamy character were as yet relatively small. The foam cells were not yet crowded together excessively, but in most cases each alveolar space within these unit areas possessed two or more cells per plane of section. The cell boundaries were exceptionally sharply defined.

The presence of such foam-cell-filled lobules, though arresting in appearance, does not yet constitute a specific type of pulmonary reaction, as similar cell clusters have been described by other authors (Innes, McAdams, and Yevich[9]). We have observed this phenomenon in inhalation experiments with amorphous silica dust, though the foam cells do not usually occur in quite such abundance as was seen in the present instance. In the normal control animals (Table 4) isolated foam-cell clusters occurred only rarely.

Focal Mural Infiltration.—At numerous points within the lungs the alveolar walls were thickened either by proliferation of the cells lining the alveoli or due to infiltration by macrophages. The occurrence of such foci of mural infiltration was sometimes related to areas where foam-cell clustering was also present. However, foam-cell clustering occurred in some instances without any associated mural thickening. On the other hand, thickening of the walls unaccompanied by foam-cell clusters was also observed. In enumerating the foci of mural infiltration for the purpose of constructing Table 3, only those foci were recorded in which no

TABLE 3--*Effect of Inhaled Beryllium Sulfate Aerosol on the Lungs of Rats: Histological Features*

Period of Experiment, Mo.	No. of Animals	Mode of Death	Miscellaneous Features: Bronchi: Bronchitis	Bronchi: Metaplasia	Alveoli: Hyperemia	Alveoli: Emphysema	Alveoli: Crystals	Alveoli: Foam-Cell Clusters	Alveoli: Mural Infiltration (Focal)	Alveoli: Peribronchial Epithelialization	Alveoli: Septal-Cell Proliferation	Alveoli: Focal Metaplasia	Alveoli: Granulomata	Alveoli: Adenomata	Neoplasia: Mucigenous Tumor	Neoplasia: Carcinomata: Squamous	Carcinomata: Acinous Adeno-	Carcinomata: Papillary Adeno-	Carcinomata: Alveolar Cell	Carcinomata: Endo(meso)-thelioma	Reticuroma
Exposure to Beryllium Sulfate Aerosol																					
Up to 1	31	18 died 13 killed	1	..	10	..	..	..	..	..	..	..	..	..	..	..	..	..	..	..	..
2 and 3	24	23 died 1 killed	1	..	11	..	..	..	..	..	..	..	..	..	..	..	..	..	..	..	..
4 and 5	5	5 died	..	..	5	..	..	2	..	2	3										
6	15	15 killed	5	..	1	..	..	42	19	21	15	3	3	1	..	..	1	..	..	..	..
Residence in Normal Air After Six Months' Exposure to Beryllium Sulfate Aerosol																					
1	6	4 died 2 killed	2	..	..	..	..	13	6	9	5	..	..	..	..	..	1	..	..	..	..
3	4	4 killed	2	..	..	1	..	25	19	8	10	..	4	..	..	..	..	..	..	..	..
4	1	1 died	..	..	..	..	..	5	4	2	1	..	1	..	..	..	..	..	..	..	..
5	5	1 died 4 killed	2	..	..	2	3	58	40	51	12	2	21	3	..	1	3	3	..	..	..
7	2	2 died	2	..	..	1	2	25	13	23	7	1	13	2	..	..	1	..	..	..	1
9	4	4 killed	2	3	..	3	1	29	22	40	8	2	50	1	..	1	2	..	..	..	..
10	15	15 killed	1	5	..	6	12	115	133	103	67	12	260	7	7	1	10	5	6	..	..
12	1	1 killed	..	3	..	..	1	15	14	7	4	1	20	..			1	..	1	1	
14	2	1 died 1 killed	1	1	..	1	..	8	6	5	4	2	2	2							
16	1	1 died	1	2	..	2	..	18	18	5	9	1	15	1			1	3	..	..	..
17	4	1 died 3 killed	3	2	..	4	3	19	19	3	6	1	20	1			1	..	..	..	1
18	7	1 died 6 killed	1	2	..	5	3	9	16	3	7	2	15	..	..	2	3	..	..	..	1

Figures in Columns 1 to 5, under Miscellaneous Features, refer to the number of animals in which the lesion was found; in Columns 6 to 11, to the number of features seen; in Columns 12 to 19, under Neoplasia, to the number of tumors found. Each number in Columns 6 to 19 was obtained by adding together, for each killing period, the total number of features observed (or of tumors revealed) in a single midcoronal section of each animal studied at that period

TABLE 4.—*Rate of Occurrence of Pulmonary Lesions in Rats Resting in Normal Air Only*

Source	No. Male	No. Female	Age, Mo.	Dominant Lesion*	Pulmonary Lesions*: Foam Cell Clusters	Mural Infiltrations (Focal)	Epithelialization of Peribronchial Alveoli	Tubular Proliferations of Septal Cells	Focal Metaplasia (Alveoli)	Granulomata	Neoplasmata
Sherman strain											
S. D.	..	6	2-6	....	..	1	..	..	..	..	..
S. D.	..	12	7-12	A-1 B-5 E-1 P-6	2	1	..	..	..	..	..
S. D.	..	7	13-18	B-1 P-3	1	1	..	..	..	..	..
M. F.	11	..	19-24	P-2	..	3	..	..	..	3	..
Wistar strain											
S. L.	1	12	2-6	A-1 P-2	..	2	..	..	..	..	..
S. L.	12	12	7-12	B-1 E-1 P-1	5	2	..	..	..	4	..
S. L.	6	13	13-18	B-1 P-5	3	5	..	..	..	2	..
S. L.	..	4	19-22	P-1 Pl-2	..	..	..	..	..	..	..

Explanations of Abbreviations:
A = Abscess
B = Bronchiectasis
E = Exudation into alveoli
P = Pneumonitis (interstitial)
Pl = Pleurisy
S. D. = Sprague Dawley
M. F. = Manor Farms
S. L. = Savannah Laboratory

*The figures in the column under Dominant Lesion refer to the number of animals exhibiting each dominant lesion, and the figures in the columns under Pulmonary Lesions refer to the total number of lesions seen in all animals killed.

foam-cell clusters were present. Such isolated zones of mural infiltration occurred oftenest in peribronchial or periductal alveoli (Plate IC). No stromal elements could be identified, the mural thickening being due to cellular elements. Generally, too, the infiltration produced no gross distortion of the peribronchiolar alveolar spaces, but occasionally some atelectasis with resultant focal consolidation supervened (Plate ID). As may be inferred from Table 3, this phenomenon was as yet infrequently observed in the animals killed at the end of the six months' period of exposure. In the control rats of approximately equal age comparable foci of mural cellular infiltration were rarely seen.

Epithelialization of Peribronchial Alveoli.—Next in extent, but probably no less significant in importance, was the multifocal epithelialization of peribronchial alveolar spaces. In most instances this epithelial reaction commenced unilaterally in relation to an alveolar duct (Plate IIA), but in other areas it surrounded the bronchioles (Plate IIB). The epithelium covering the surfaces of these alveoli tended to assume a low cuboidal character. The nuclei were closely crowded and tended to be relatively pyknotic. Sometimes the affected alveoli appeared to be somewhat atelectatic; at other times they seemed to be distended. Foam cells and macrophages were often seen within such alveolar spaces, but in other instances the alveoli were empty. There was no tendency at this stage for these alveolar epithelial cells to be shed. An indisputable connection between the alveolar ductal epithelium and

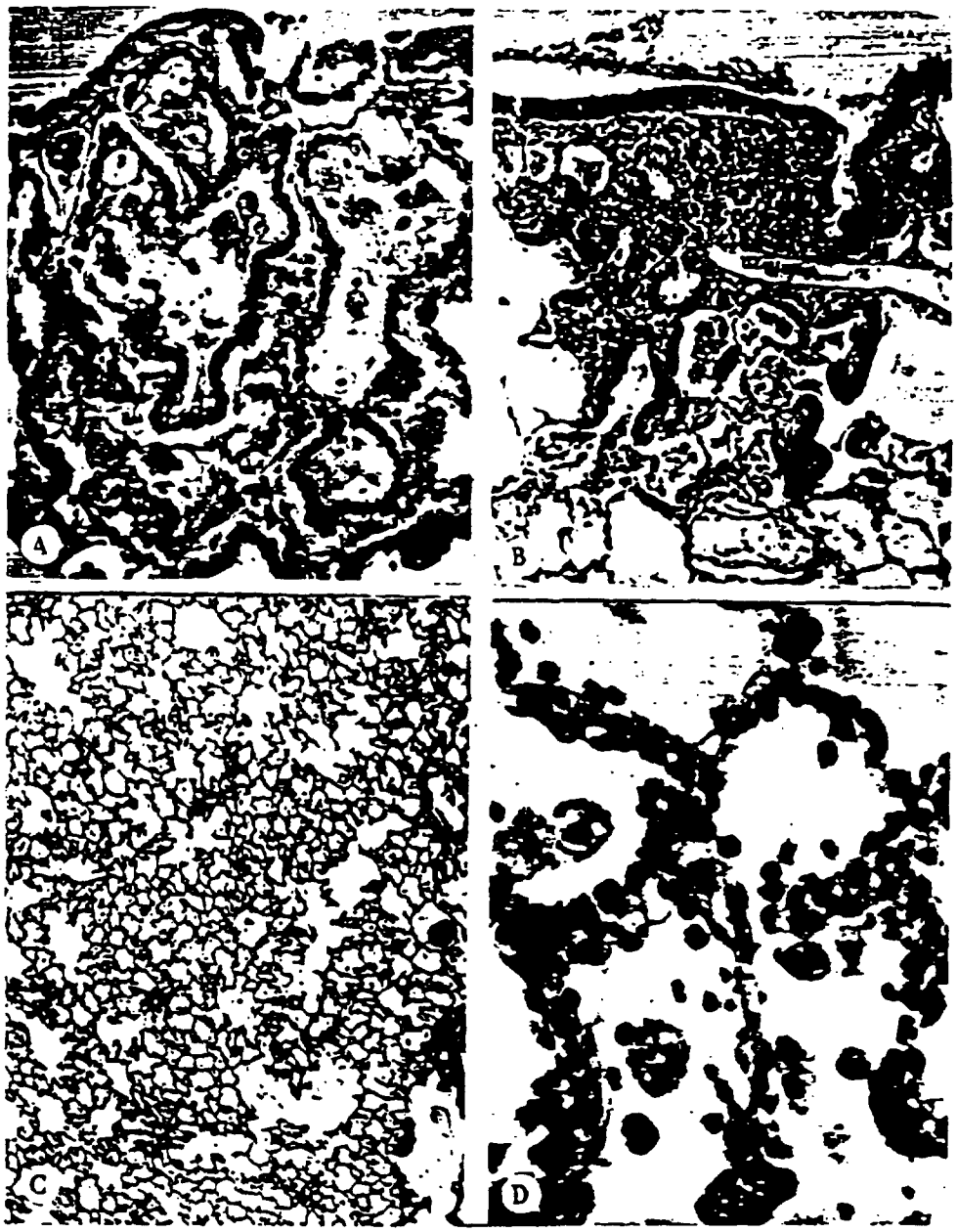

Plate II.—*A*, alveolar spaces lined by highly cellular cuboidal epithelium undergoing distortion and distention (note foamy macrophages): Rat 42, exposed to beryllium sulfate aerosol for six months, then in normal air six months, then killed; × 350. *B*, parabronchial evagination of bronchial epithelium: Rat 198, exposed to beryllium sulfate aerosol for six months, then killed; × 175. *C*, lobular proliferation of alveolar wall septal cells: Rat 144 exposed to beryllium sulfate aerosol for six months, then killed; × 65. *D*, cytological detail of part *C*: Rat 143, exposed to beryllium sulfate aerosol for six months, then killed; × 800

the new epithelium could be demonstrated in some areas; in other instances the two systems did not appear to be continuous with each other, although serial sectioning will have to be resorted to before such a connection can be ruled out. Where the epithelialization ended, it generally did so abruptly, so that an alveolus could sometimes be seen to be partly lined with cuboidal cells and partly devoid of any epithelium. One to three such foci could be demonstrated per midcoronal whole-lung section in each of the rats killed at the end of six months of exposure to the beryllium sulfate aerosol.

No epithelializations of alveolar walls could be demonstrated in rats of comparable age from the control series. It should be noted that in man and other animals epithelium sometimes forms in lung areas which have been isolated by a process of fibrosis. Typical examples of this type of epithelialization have also been observed in animals exposed at the Saranac Laboratory to oil smoke. In the present series of animals there was no indication that the epithelialization of the alveolar walls was due to isolation of the affected areas.

Lobular Proliferations of Septal Cells.—A fourth distinctive type of lesion was discovered at the end of the six months' period of exposure to beryllium sulfate. It manifested itself as discrete lobular proliferations of alveolar wall surface cells. Under low power these foci were readily discernible by virtue of the relative prominence of the chromatin and the close crowding of the multiplying cells lining the alveolar walls (Plate IIC). At the edge of each focus of proliferation there was an abrupt zone of transition to the normal pulmonary parenchyma. It was noted that the alveolar spaces were not significantly occupied by cells, though an occasional macrophage occurred here, and some of the proliferating cells could be seen in the process of being shed into the lumen (Plate IID). In some cases several of these centers of proliferation could be demonstrated per midcoronal whole-lung section, while almost every rat possessed at least one such area.

In the control series no comparable lesions could be demonstrated.

Focal Metaplasia of Alveolar Walls.—In one of the rats killed at the end of six months of exposure to the beryllium sulfate aerosol, three areas were found in a whole-lung section taken through the midcoronal plane in which alveolar walls had become the seat of focal metaplasia. The cells were of an unusual type, and nothing comparable was seen in the control series.

Granulomata.—Three small granulomata were found in one of the animals killed at the end of six months of exposure to the aerosol. They were near the pleura and were composed of macrophages and plasma cells with interposed crystal clefts. Such granulomata were observed in an occasional control animal but never in rats less than 18 months of age (Table 4).

Neoplasia.—At least one indisputable adenoma and several other probable adenomata were demonstrated in the rats killed after six months of exposure to the beryllium sulfate aerosol. In one instance focal epithelial proliferation had exceeded a benign cytological condition to such an extent that the lesion simulated an early papillary adenocarcinoma. The cells covering the distorted alveolar spaces showed many mitotic figures, and those surface cells which were observed within the spaces resembled neither macrophages nor foam cells, and probably represented desquamating neoplastic elements. The tumor tissue invaded the surrounding parenchyma, there being no capsule. No neoplasia was observed in the control series of rats.

Postexposure Sequelae

Contrary to expectation, the pulmonary reaction, which had developed toward the end of the six-month period of exposure to the beryllium sulfate, did not subside when this nocuous stimulus was withdrawn. Not only was there a progressive increase in the frequency of the changes observed in animals killed when the exposure phase was terminated, but additional features made their appearance.

It is of interest to note that significant signs of pulmonary infection disappeared soon after the animals were placed in normal air (Table 2).

The macroscopically detectable foci of reaction were observed in increasing numbers and later were seen in all animals. Each focus tended to become somewhat larger, and confluence of distinct units came to be a universal feature until about 14 months after the animals had been transferred to normal air. Thereafter individual foci became smaller and were inclined to be discrete.

The most outstanding development concerns the appearance of visible and palpable tumors of increasing size. During the first four months of the postexposure period isolated tumors were detected in the hilar lymph nodes. Thereafter, and until the end of the 18-month period of survival in normal air, pulmonary tumors were found in increasing numbers in the animals which were serially autopsied. Not all the rats developed macroscopically detectable tumors. Some, on the other hand, showed several discrete growths of different size in one or more lobes of the lungs. Though it remained for histological examination to prove the neoplastic nature of these nodular lesions, the majority had the gross features of new growths.

On histological examination of the lungs of these animals (Table 3) the further development of the lesions which were present at the end of the six months of exposure to the beryllium sulfate could be followed.

Hyperemia had disappeared. At later stages there was even a tendency to relative ischemia. Emphysema of the atrophic vesicular variety made its appearance in increasing numbers of animals but did not affect all the rats. Bronchitis was found sporadically throughout the period, and foci of metaplasia of the bronchial epithelium were found in a few of the rats after the ninth month of residence in normal air. At various points, but particularly in alveolar spaces immediately beneath the pleura, spindle-shaped crystals were detected. The nature of these crystals could not be determined, but their optical properties suggested that they were composed of cholesterol. In some instances these crystals were embedded in alveolar walls, and at other times they were found within some of the granulomata. Similar crystals have occasionally been observed in rats never previously exposed to beryllium sulfate.

Foam-Cell Clusters.—Increasing numbers of pulmonary lobules became occupied by foam cells, the incidence per rat lung of these units reaching a peak toward the seventh month in normal air. At this stage a distinct change set in, and in animals killed in subsequent months progressively fewer foam-cell clusters were discovered (Fig. 1), and each unit became smaller.

During the phase of increasing prevalence of the foam-cell areas the individual cells grew in size and increased in number until each alveolar space became virtually choked with these cells. At the same time the cytoplasmic vacuoles expanded. These units were found in greater number also in relation to bronchioles and alveolar ducts, although the tendency to form subpleural foci persisted. It is in the latter locations particularly that confluence of cells and infiltration of alveolar walls first became a conspicuous associated phenomenon. With the breakdown of the cell boundaries, nuclear and cytoplasmic debris collected within the alveolar spaces, and sharp crystals could be seen with fair regularity.

The greater prevalence of mural infiltration at these sites suggests a causal relationship or a common etiology. It is possible that products of degeneration of these foam cells became incorporated into the alveolar walls. Soon crystals also appeared in the walls, and cellular granulomata formed in relation to them. The latter phenomena were most marked during the phase of decreasing prevalence of the foam-cell units. It is likely that the clusters ultimately disappeared, both because no new lesions were created and also on account of the progressive breakdown of the foam cells and the resorption of the resultant detritus.

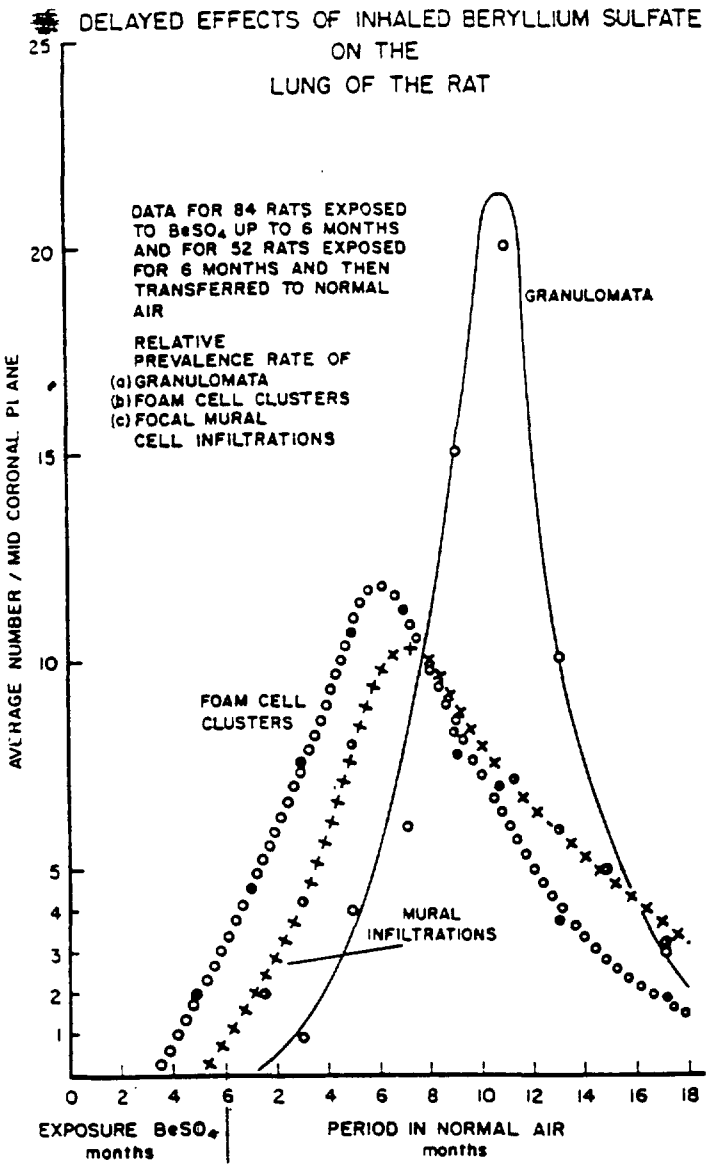

Fig. 1.—Graph showing the evolution and subsequent regression of foam-cell clusters, focal mural infiltration, and granulomata in rats exposed continually to a beryllium sulfate aerosol for 6 months and thereafter residing in normal air for periods up to 18 months. The curves are based on the comparative prevalences of the lesions in a single midcoronal histological section of the lung.

A total of 11 small foam-cell clusters were found in the lungs of the 139 rats of the control series. It is of interest to note, too, that these cells were most prevalent between the 7th and the 18th month of the life of the normal rats.

Focal Mural Infiltrations.—Focal mural infiltrations increased and later decreased in numbers in a manner roughly parallel to the course followed by the foam cells. As shown in Figure 1, mural infiltration continued to lag behind foam-cell production as a temporal phenomenon. This relationship may have an etiological significance insofar that foam cells became progressively associated with these regions of mural infiltration. As the infiltrated areas mostly occurred periductally, they lay on the route along which foam cells may have been evacuated from the lung parenchyma. The

slight degree of ductal stenosis associated with the focal mural infiltrations may have retarded the egress of the large foam cells so that they accumulated temporarily in the pulmonary lobules.

Focal interstitial cellular infiltration also occurred without undue participation of foam cells. In some instances a small amount of collagen could be demonstrated among the infiltrating cells, but generally the alveolar walls remained cellular. This fact largely accounts for the subsequent disappearance of lesions.

There is, of course, no proof that in the animals killed after, say, the 10th month in normal air there had previously been greater numbers of foam-cell units and mural infiltrations than were found at later stages. Such a point can be settled completely only by means of serial biopsies in the same animals, obviously a technically difficult procedure. The curves of incrementation and regression at least suggest that we are dealing here with evanescent lesions which reflect retarded pulmonary responses to the preceding six months of irritation by the beryllium sulfate aerosol or which may represent a rebound histopathological change caused by the withdrawal of the pathogenic agent.

Peribronchial Epithelialization of Alveoli.—The fate of the epithelializations of the periductal alveoli and the sequelae of the lobular alveolar wall septal-cell proliferations may now be traced. As is shown in Figure 2, the epithelialized type of lesion rapidly became more prevalent with the passage of time and reached a peak production toward the end of eight months after the rats were removed from the beryllium sulfate environment. Thereafter epithelialization diminished as a histological sign with the same rapidity, so that ultimately it was but rarely encountered. Likewise, the extent of the lesion first increased and thereafter decreased. At the stage of maximum productivity the epithelialized alveolar spaces frequently surrounded the bronchioles almost completely. Two types of reaction appeared in some rats. In the one type of epithelium the nuclei were pyknotic, and the cytoplasm scanty. In the other type the epithelial cells possessed a more abundant acidophilic cytoplasm. It is possible that infection may have been a factor in bringing about these differences, as neutrophile polymorphonuclear leucocytes were commoner in the lesions of the latter type of reaction.

What happened to the epithelialized areas after the phase of their peak production deserves some inquiry. At earlier stages the epithelium often appeared to be fully differentiated, even possessing cilia (Plate III*A*). These cilia were not observed at later stages. It is quite possible that at least some of the epithelial cells were later desquamated. In many animals such areas of denudation could be found between zones of epithelialization, and it is conceivable that with the passage of time all such newly formed epithelium was discharged into the respiratory passages. At several sites it would seem as if individual epithelial cells budded off to become freely roaming spherical alveolar cells. In yet other instances such epithelial cells may have participated in the formation of giant cells after the relevant alveoli had become completely atelectatic. In yet further instances the epithelial cells became incorporated within areas of interstitial fibrocellular reaction and, through resorption of trapped air spaces, became reduced to multiple circular foci of dark-staining cells within a dominantly stromal area (Plate III*B*). These are the regressive changes. In a small proportion of cases epithelial proliferation appeared to have proceeded virtually autonomously with the formation of papillary processes and secondary acinar recesses (Plate III*C*). The borderline between neoplasia and simple hyperplasia could be drawn only with difficulty in many such instances and not at all in others.

Epithelialization of the foregoing type did not develop in the rats of the control series during the full period in which they were under observation.

Septal-Cell Proliferation.—The lobular foci in which alveolar septal cells under-

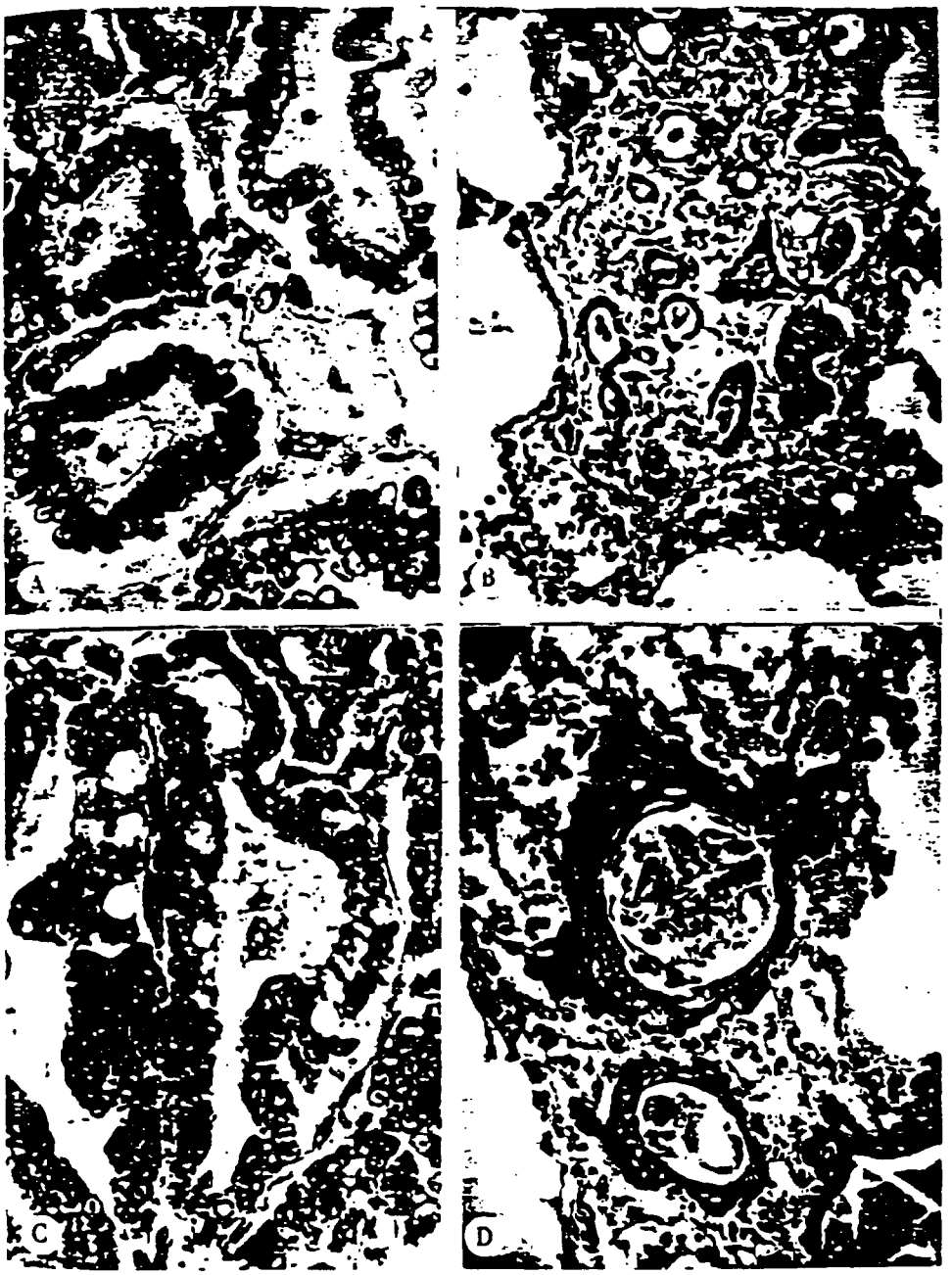

Plate III.—*A*, ciliated cuboidal epithelium lining atrophic peribronchial alveoli: Rat 42, exposed to beryllium sulfate aerosol for six months, then in normal air six months, then killed; × 800. *B*, remnants of epithelialized alveoli trapped within a fibrocellular focus; metaplasia to solid cords: Rat 20, exposed to beryllium sulfate aerosol for six months, then in normal air 10 months, then killed; × 300. *C*, metaplasia in foci of epithelialization of alveolar spaces; transition from cuboidal to pseudostratified epithelium, incipient papilloma formation, and stromal invasion: Rat 20, exposed to beryllium sulfate aerosol for 6 months, then in normal air 10 months, then killed; × 350. *D*, circular foci of squamous metaplasia and possibly incipient carcinomatosis originating around macrophages and foam cells: Rat 27, exposed to beryllium sulfate aerosol for 6 months, then in normal air 18 months, then killed; × 350.

went proliferation did not change their character much as time passed. These lesions increased but slowly in over-all prevalence and reached a climax only after about 15 months from the time of cessation of the beryllium sulfate exposure. In at least some cases they were the source of pleomorphic types of alveolar cells. Not much stroma appeared to have developed in relation to them. It is suspected that in at least some instances these focal proliferations were the source of certain of the tumors which developed in these animals.

No comparable lesions were observed in the control series.

Focal Metaplasia.—At isolated foci in the lungs of the animals autopsied six months and longer after the exposure to the beryllium sulfate had been discontinued, foci of metaplasia of the alveolar lining cells could be demonstrated. In some instances there was squamous metaplasia (Plate III*D*). At other sites ciliated columnar or pseudostratified epithelium predominated. Though these lesions were not numerous, their significance as precursors to neoplasia must be recognized. This metaplasia was entirely different from that often found in rats with chronic bronchiectasis and suppuration (Passey, Leese, and Knox[9]). Comparable metaplasia was not observed in the control series.

Granulomata.—There can be no doubt that the present study yielded a particularly bountiful crop of granulomata in the exposed animals. Viewed as an objective of the study, this result was a very desirable one, because for the past 12 years it has been an endeavor of the Saranac Laboratory to reproduce experimentally in animals the pulmonary granulomata characteristic of a chronic disease exhibited by some industrial workers exposed to beryllium compounds. The evolution of the granulomata produced in the rats by the beryllium sulfate exposure is outlined in summary form in Table 3 and Figure 1. Attention should be drawn to the fact that, with the exception of the three instances found in animals at the end of the six-month period of exposure to the aerosol of beryllium sulfate, the granulomata made their appearance only after this exposure had been discontinued. In their time of onset they thus lagged behind the phenomena of both foam-cell production and mural infiltration. However, there is seemingly close biostatistical correlation among these three phenomena, which may signify a common mechanism of pathogenesis. In fact, it would appear that most of the granulomata had evolved within alveolar walls when products of the degeneration of foam cells became concentrated among the infiltrated macrophages. At least some granulomata appeared also to have arisen in relation to de-aerated alveolar spaces within foam-cell units.

In essence, each granuloma consisted of a central core of large macrophages and a superficial thin zone of plasma cells. In most instances, too, a layer of cuboidal or flat cells covered the surfaces of granulomata which faced alveolar spaces. Although crystals were not universally present, they could be found within individual granulomata even at the end of 18 months from the time of cessation of the beryllium sulfate exposure (Plate IV*A*). A marked tendency was noted in this series of rats for granulomata to become confluent as their numbers increased. Toward the 10th month of survival in normal air the majority of the granulomata were relatively large composite structures (Plate IV*B*).

Giant cells of the polymorphonuclear type sometimes were present in these small unit lesions but were more usually observed in relation to composite granulomata. Crystals were often interposed between the macrophages within the medulla of the granuloma and sometimes crowded the latter to such a degree that each cell was reduced to a flat disk-like structure. At other times the crystals had apparently formed within giant cells; alternatively, preformed crystals had been phagocytosed by giant cells. It is also possible that in some cases the giant cells engulfing these crystals represented macro-

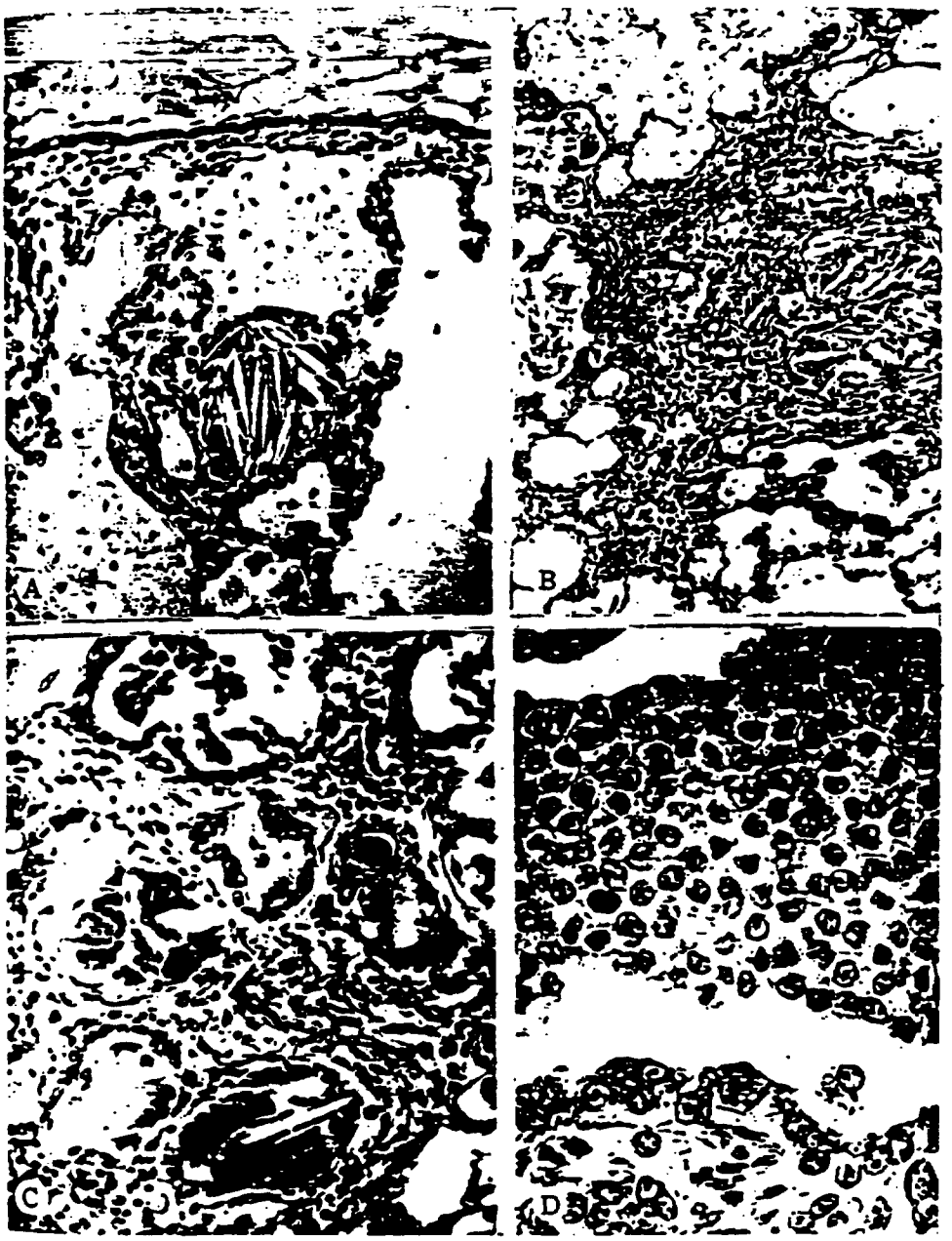

Plate IV.—*A*, granuloma with crystals and macrophages: Rat 35, exposed to beryllium sulfate aerosol for 6 months, then in normal air 18 months; × 350. *B*, composite granuloma (note fringe of plasma cells): Rat 19, exposed to beryllium sulfate aerosol for 6 months, then in normal air 10 months; × 175. *C*, giant-cell formation through confluence of epithelial cells of atrophic alveoli: Rat 36, exposed to beryllium sulfate aerosol for 6 months, then in normal air 10 months; × 350. *D*, epithelialized alveolar space filled with spheroidal cells: Rat 15, exposed to beryllium sulfate aerosol for 6 months, then in normal air 18 months, then killed; × 800.

TABLE 5.—*Prevalence of Various Pulmonary Lesions in Rats Exposed to Beryllium Sulfate Aerosol and in Rats Never Exposed to Any Dust*

	Experimental Group (136): BeSO₄ up to 6 Mo. then Normal Air up to 18 Mo.		Control Group (139): Normal Air Only up to 22 Mo.	
Pulmonary Lesions	No.	L/100	No.	L/100
Foam-cell clusters	383	282	11	8
Mural infiltrations	328	242	15	11
Epithelialization of peribronchial alveoli	372	273	0	0
Lobular proliferations of septal cells	158	116	0	0
Focal metaplasia (Alveoli)	27	20	0	0
Granulomata	424	310	9	7
Neoplasmata	76	55	0	0

L/100 refers to number of lesions per 100 animals.

phages which had fused together to form the multinucleated giants (Plate IVC). No conchoidal bodies could be demonstrated.

In the series of 139 control rats only nine granulomata were found and these were confined to only 3 animals. Virtually all the rats that had been exposed to the beryllium sulfate aerosol developed granulomata.

It may be pertinent at this stage to review the relative prevalence of the more important pulmonary lesions observed in the exposed and in the control series of rats. The total numbers of lesions found have been assembled in Table 5. No refined biostatistical analysis need be invoked to emphasize the fact that the seven criteria listed predominated absolutely in the group of experimental animals which had been caused to inhale the beryllium sulfate aerosol as compared with a control series which was not knowingly exposed to any beryllium compound. The seven types of lesion perhaps constitute a syndrome specific for beryllium sulfate. It should be further noted that the majority of the lesions manifested themselves only in those 52 animals which were allowed to survive in normal air after their exposure to the beryllium was terminated.

Pulmonary Neoplasia.—The lesions which are probably of the greatest importance because of the gravity of their significance are the new growths. Some discrepancy may be noted between the number of tumors detected macroscopically and the number identified on microscopy as neoplastic in nature. A total of 89 tumors were seen or palpated at the time of the autopsy on the animals previously exposed to beryllium sulfate (Table 2), while only 76 tumors are listed in Table 3 as histologically neoplastic. The explanation is simply that in constructing Table 3 only the new growths identified in single midcoronal sections of both lungs were recorded. While it may be apparent that many growths which could not have been identified on naked-eye examination are included in the histologically neoplastic group, it should be obvious, too, that many others were not enumerated, because they were not located in the midcoronal plane. The important discovery of this study is that there were such extremely large numbers of neoplasmata.

The various types of growth identified have been summarized in Table 6. It is highly probable that all three retesarcomata represented metastases from tumors which probably originated within the abdominal lymphatic nodes. While neither lymphatic system tumors nor primary pulmonary new growths were present in the control series, retesarcomata have occurred from time to time in rats used in other studies. Their presence in the present series of beryllium-

TABLE 6.—*Neoplasia in Fifty-Two Rats Exposed to Beryllium Sulfate Aerosol for Six Months and Then Living in Normal Air for Periods up to Eighteen Months*

Neoplasm	No.	Metastases
Adenoma	18	-
Squamous carcinoma	5	1
Acinous adenocarcinoma	24	2
Papillary adenocarcinoma	11	1
Alveolar-cell adenocarcinoma	2	-
Mucinous tumor	2	-
Endothelioma	1	-
Reticulosarcoma	3	3
Total	76	7

exposed animals, therefore, is not of too great significance.

The criteria employed in deciding that a neoplasm was malignant rather than benign were primarily cytological and histological. In most instances the malignant tumors were markedly cellular with epithelium-derived tissue predominating or even exclusively present. Mitosis was a prominent feature, and generally at least one mitotic figure could be seen per oil-immersion field. No capsules could be demonstrated, the tumors infiltrating and permeating the surrounding tissue. The individual cells generally were larger than the tissue cells of the normal rat, the nuclei being particularly large with prominent nucleoli. Often the nuclei varied greatly in size and chromatin content, with pallid and pyknotic nuclei sometimes lying adjacent to one another. In most of these tumors this pleomorphism and anaplasia were associated with functional suppression. However, in one series keratin was produced, and in another series there was mucoid secretion. No necrosis, ulceration, or hemorrhages occurred in these earlier stages. The tumors remained relatively avascular. Attention should be drawn also

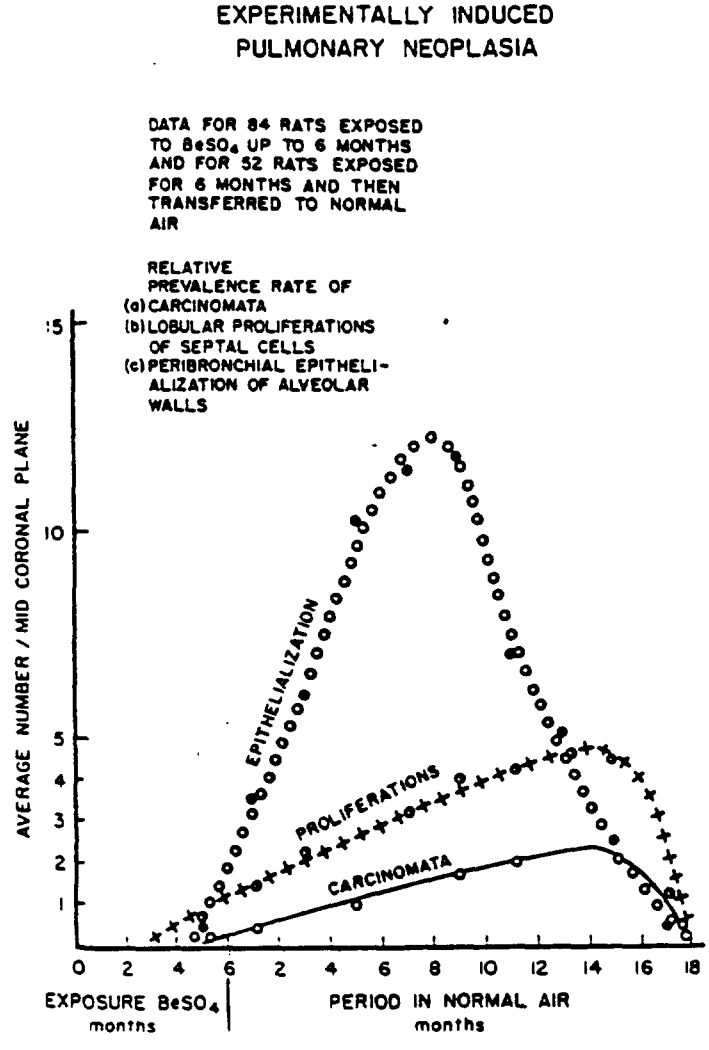

Fig. 2.—Graph showing the evolution of peribronchial alveolar wall epithelialization, lobular septal-cell proliferations, and pulmonary carcinomatosis in rats exposed continually to a beryllium sulfate aerosol for 6 months and thereafter residing in normal air for periods up to 18 months. Only lesions detected in a single midcoronal plane are recorded.

to the multifocal origin of many of these tumors in several animals. In some only one lesion could be found; in others there were numerous separate foci of neoplasia. Other features supporting the malignant character of these tumors were the tendency to metastasize and the successful transplantation of the growths into the subcutaneous tissues of new host rats. Some of these secondary and tertiary growths produced metastases.

The first unmistakably malignant growth was found in one of the animals killed at the end of six months of exposure to the beryllium sulfate aerosol. A second was detected in one of three animals sampled at the end of a week after the cessation of the exposure. Thereafter tumors became progressively more frequent until the 15th month of residence in normal air had been reached, whereafter the prevalence rate declined rapidly (Fig. 2).

The main varieties of tumor found have been classified in Table 6. Not included in these series are a number of focal lesions in which epithelium-lined lacunae were found filled with spheroidal cells (Plate IV*D*). These cell masses may represent the product of continued multiplication of the epithelial layer and thus be equivalent to an alveolar granuloma. On the other hand, these cell formations may be examples of carcinoma in situ.

Squamous carcinomata occurred both with and without keratin production. The keratin-forming squamous carcinomata appeared to be slow growing. In several instances typical epithelial pearls could be found. The stratified epithelium characterizing these tumors was remarkable chiefly for the excessive size of its nuclei, the acidophilia of the cytoplasm, and the marked propensity for forming flat cornified superficial laminae (Plate V*A*). The variety without keratin presented multiple trabeculae covered with stratified epithelium on both surfaces and exhibiting a variable amount of stroma (Plate V*B*). These epithelioid tumors tended to be relatively expansile, and cell multiplication took place at the free surface. One of these epitheliomatous growths was associated with a metastatic deposit in the hepatic lymph node. The tumors appear to have arisen from alveolar wall epithelium which had undergone metaplasia. Several such foci of stratification could be seen in relation to foam-cell clusters and at the edges of granulomata. At least one of these cancers originated around a partly degenerated granuloma.

The adenocarcinomata were the most numerous. They occurred in several varieties, and it seems highly probable that these tumors are the malignant analogues of the epithelial hyperplasias already described.

The acinous type of adenocarcinoma was most prevalent (Plate V*C*). Sometimes the tumor consisted simply, on cross section, of numerous circular groupings of proliferating cuboidal cells, and it had expanded marginally by the multiplication of these hollow acini. The intervening stroma generally remained scanty, but rarely some collagen was produced. At the tumor edge there frequently was an abrupt line of transition from anaplastic to normal tissue. The acini varied from relatively small rings of cells, with scarcely a lumen, to relatively dilated spaces. Both appeared to be equally malignant, and sometimes histological lesions of both types were found in the same tumor.

The papillary adenocarcinomata probably were simply variants of the foregoing type, in which epithelial hyperplasia had proceeded at such a disproportionate rate that sessile or villous projections of epithelium, either with or without any stroma, protruded into the acini (Plate V*D*). In some instances the acini became virtually occluded by the papillae. At their margins these tumors sometimes sent out solid cellular projections into surrounding noncarcinomatous lung tissue. At other times the acinar processes invaded adjacent areas first.

The designation of the alveolar cell carcinomata as such is based on the observation that these tumors were almost solid masses of malignant cells at the center, their mar-

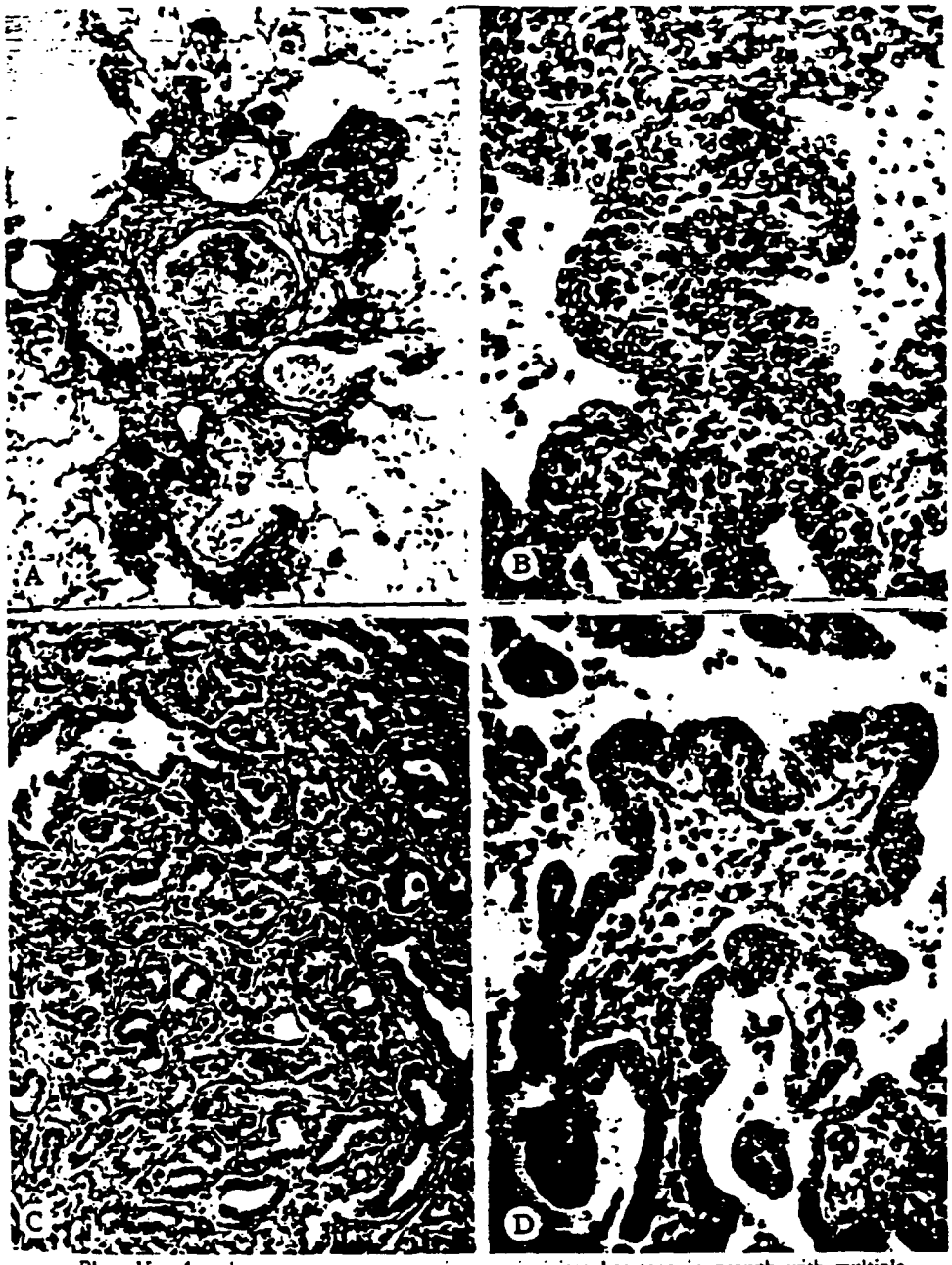

Plate V.—*A*, pulmonary squamous carcinoma; incipient keratogenic growth with multiple pearls and proliferating basal layers: Rat 1, exposed to beryllium sulfate aerosol for six months, then in normal air six months, then killed; × 175. *B*, pulmonary squamous carcinoma; epithelioid growth showing stratified bilaminated trabeculae which do not produce keratin: Rat 19, exposed to beryllium sulfate aerosol for 10 months, then in normal air 10 months, then killed; × 250. *C*, pulmonary acinous adenocarcinoma; acinous adenocarcinoma with small lacunae and delicate collagen bundles: Rat 15, exposed to beryllium sulfate aerosol for 6 months, then in normal air for 18 months, then killed; × 175. *D*, pulmonary papillary adenocarcinoma; stroma-containing pedunculated papilla in a papillary adenocarcinoma: Rat 36, exposed to beryllium sulfate aerosol for 6 months, then in normal air 10 months, then killed; × 750.

THE LIBRARY OF THE
AMERICAN MEDICAL ASSOCIATION
535 NORTH DEARBORN STREET
CHICAGO 10, ILLINOIS

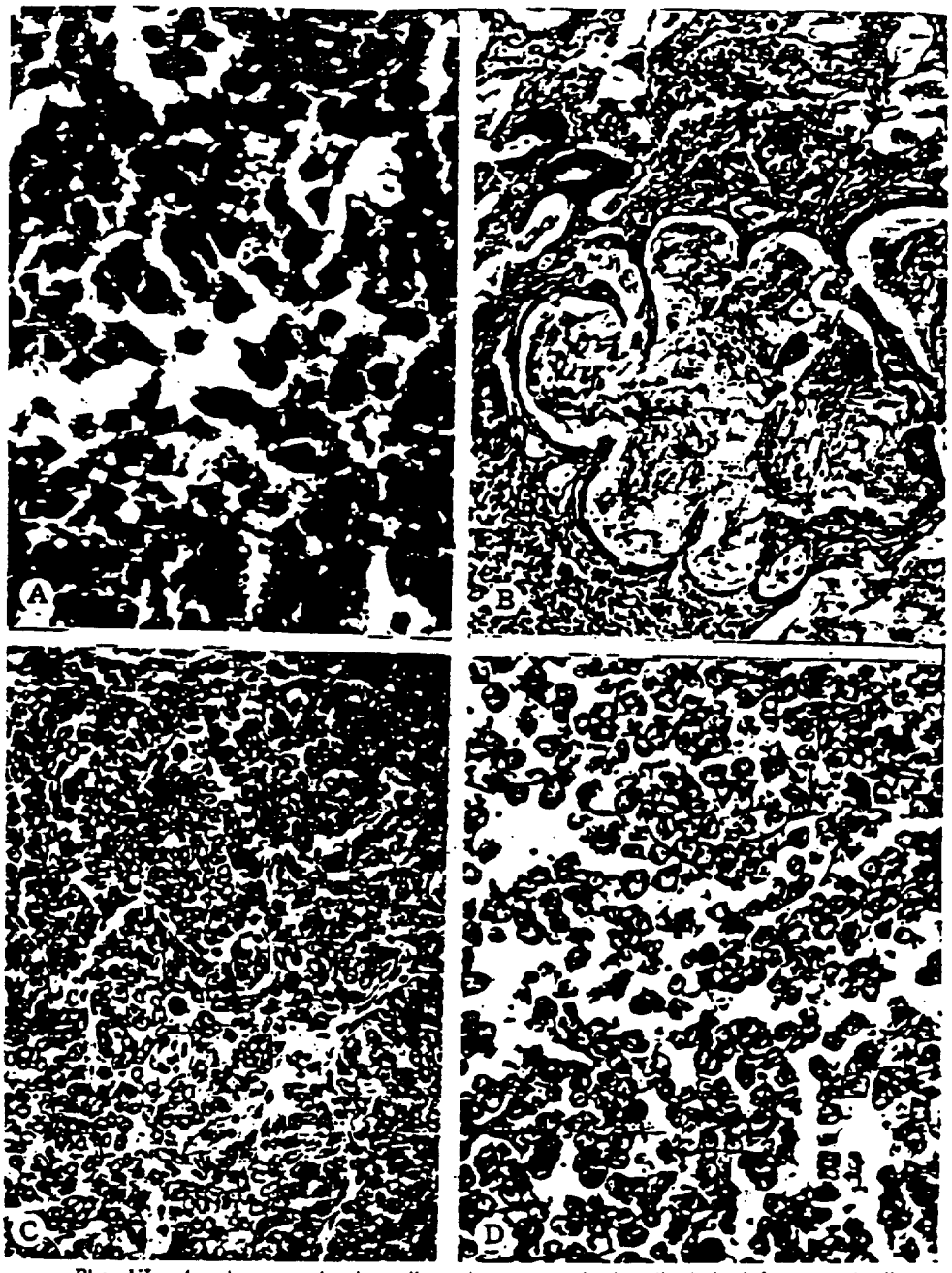

Plate VI.—*A*, pulmonary alveolar cell carcinoma; neoplastic cells derived from septal-cell elements beginning to fill an alveolar space: Rat 6, exposed to beryllium sulfate aerosol for 6 months, then in normal air 10 months, then killed; × 800. *B*, pulmonary mucigenous tumor: confluent mucus-containing epithelium-lined loculi (note advancing columns and peripheral round-cell reaction): Rat 30, exposed to beryllium sulfate aerosol for 6 months, then in normal air 10 months, then killed; × 10. *C*, endothelioma of the pleura: Rat 18, exposed to beryllium sulfate aerosol for 6 months, then in normal air 12 months; × 350. *D*, argentophilic reticulum supporting cells of retesarcoma: Rat 35, exposed to beryllium sulfate aerosol for 6 months, then in normal air 10 months; × 350.

gins showing that the component cytological elements were derived by universal anaplastic proliferation of alveolar lining cells into the pulmonary alveoli (Plate VIA). Slightly more centrally from the tumor edge, the cells from opposite sides of the alveoli could sometimes be seen to meet and thus to obliterate the air spaces. At yet other points neoplastic cells were shed into the alveolar lumen. Fundamentally, therefore, these were also alveolar-cell carcinomata.

No attempt was made by the alveolar-cell tumors to evolve either new acini or to become truly papillomatous. In some of the less vigorously developing tumors, the original alveolar architectonic pattern was preserved, but the air sacs were filled with neoplastic cells which contrasted sharply with the intervening nonmalignant stromal cells. In quite a few instances the asymmetrically proliferating alveolar cells tended to form central bodies of polyhedral cells attached to the alveolar wall along one edge but unattached elsewhere. The provisional indications appear to be that these tumors arose out of the lobular alveolar septal-cell proliferations already described.

A number of mucigenous carcinomata were discovered. Their malignant nature was held in doubt, and they were at first classified as mucigenous adenomata until at least one indisputable instance of metastasis could be traced to one of these tumors. The disproportionate amount of mucoid contents of their distended acini belied their dangerous nature. The mucoid contents of these tumors were clearly derived from secretory cells among those forming the lining of epithelial membranes. Some of these cells resembled goblet cells. In typical fashion many of the epithelial cells became separated from the stromal base and became inbedded in the mucoid substance, leaving sectors of the original acinus denuded (Plate VIB). This change was generally furthest advanced toward the centers of the tumors, thus creating an illusion of acellularity here. There was also a tendency for interruption of alveolar walls in the deeper reaches of the tumor with sequential confluence of mucoid masses. Thus, a multiloculated character was imparted to some of these tumors. Along the expanding edges of the tumor the cytological elements were better preserved, and it could be seen that the growth invaded surrounding lung parenchyma by means of solid cords of cells which subsequently acquired a lumen in which secretions collected. Such advancing trabeculae sometimes insinuated themselves around obstructing major blood vessels. There was also a fairly distinct tendency to lymphocytic and plasma-cell reaction to the presence of these invading columns, a feature not observed in connection with other tumors of this series.

The source of these mucoid tumors was not readily apparent. There is a strong suspicion that they arose from the epithelialized alveoli which surrounded certain bronchi (Plate IIB).

The single example of an endothelioma or mesothelioma encountered in these animals was located on the pleural surface of the apex of a basal lobe. It showed no tendency to invade the subjacent lung but had spread laterally and into the pleural fissure. In structure it consisted of solid cords of pleomorphic proliferating cells with some superficial palisading. Delicate vascular or lymphatic channels were interposed between the cell masses (Plate VIC). The existence of independent pleural mesotheliomata has been repeatedly challenged, and because of this skepticism it is well to record that in the rat in which the endothelioma occurred there were in other parts of the lungs one incipient squamous carcinoma, one papillary adenocarcinoma, and one alveolar-cell carcinoma. This case, therefore, illustrates well the multipotential character of the neoplastic process in this series of animals. While it is possible that the endothelioma of the present instance could represent a pleural metastasis from any of the foregoing three parenchymal tumors, its cytological and histological features did not closely resemble any of these three lung tumors. While it must be granted that this observation does not com-

pletely exclude the metastatic origin of the lesion, it does at least lend support to the possibility that the endothelioma was a fourth independent tumor.

For the sake of completeness, and perhaps because their existence in this series of animals may be more than coincidental, reference has been made to the pulmonary metastatic retesarcomata. These tumors did not differ materially from those which have been seen from time to time in our own rat colony and in animals obtained from other sources. They were characterized by the exceedingly cellular nature of the tumor and the large size of the polyhedral pleomorphic cells and of the cell nuclei. A delicate argentophilic reticulum supported most of these cells (Plate VID). Of more particular interest in the present series of rats is the fact that the pulmonary metastases showed a predilection for localization in relation to areas of foam-cell clustering and granulomatosis. This observation helps to illustrate the point that the lymphatic pathways to and from the foam-cell clusters and granulomata were not obstructed by the pulmonary reaction to the inhaled beryllium sulfate.

Comment

The success with which the features of human chronic beryllium disease have been duplicated in this series of rats deserves comment. For a considerable time the main diagnostic criterion of human chronic berylliosis has been the granuloma. Skepticism has gradually come to surround the validity of the human lesion as a pathognomonic diagnostic criterion because of failure to reproduce this lesion in animals and because of the occurrence of somewhat similar granulomata in Boeck's sarcoidosis. Since granulomata can be reproduced abundantly in the lungs of at least one animal species by exposures to beryllium sulfate, a feat accomplished in the present experiment, the discovery of similar lesions in personnel of beryllium-utilizing industries becomes the more convincingly significant.

The tissue changes which accompanied and preceded its emergence seem, however, to be even more important than the phenomenon of granulomatosis. Similar histological alterations have previously been found in lungs of persons who had been exposed to beryllium compounds (Scheepers[2]). It is evident from the present study that the granuloma phenomenon is but a subordinate feature of the whole syndromic response of the rat lung to the inhaled beryllium sulfate. By analogy with this observation diagnosis of the human disease may be facilitated by taking greater cognizance of the histopathological accompaniments of the granulomata. As the latter feature is not the only component of the tissue response, it may well be timely to review human cases previously rejected because of paucity of the granulomata. Phenomena such as foam-cell clustering, periductal and peribronchial alveolar wall epithelialization, diffuse and focal interstitial or mural infiltration, and lobular septal-cell proliferation may furnish a clue that the pulmonary disease may be due to inhaled beryllium.

The exceedingly minute quantities of beryllium sulfate which effectively induced pulmonary changes in these rats should be noted. It is estimated that at most each rat could have inspired about 150γ of beryllium sulfate during the exposure phase. On biochemical analysis beryllium was recovered from the lung tissue, as shown in Figure 3. Although beryllium sulfate is a soluble compound, it is calculated that about 0.2% of the inhaled beryllium evidently was at first tenaciously retained by the pulmonary protoplasm, and appreciable excretion of the element occurred only after three to five months' residence in normal air. However, the initial pulmonary tissue response does not appear to have been a function of the higher pulmonary concentration of beryllium. Emergence of the biological reaction coincided better with the phase of reduced pulmonary retention of the beryllium. It is possible, therefore, that we are dealing here with either a delayed response to the previous phase of maximal concentration or a rebound phenomenon brought about by with-