chronic pulmonary inflammation resulting from many causes. Willis [8] described a similar structure in the lungs of guinea pigs inhaling silicon carbide. The longer asbestos exposures resulted only in more thickening of the walls of the air spaces, largely due to an increase in the amount of fibrosis. The fibrous tissue always remained cellular and failed to show the hyalinization characteristic of silicosis.

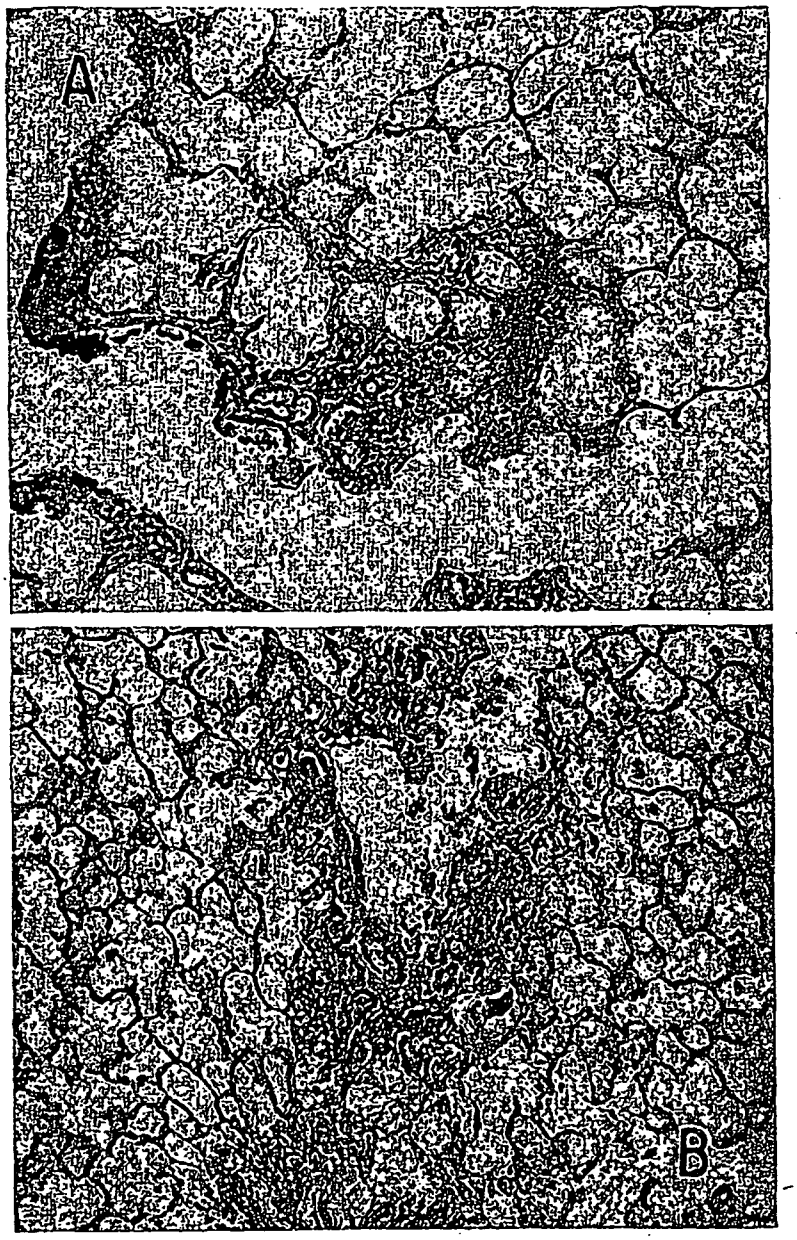

Fig. 4.—King's floats inhalation experiment: *A*, lung of a guinea pig with six months' dust exposure followed by 35 months' inhalation of normal air. The reaction is rather slight, but distinct fibrosis is present (× 200). Note that 28 months of continuous exposure (fig. 3 *B*) produces much more extensive reaction. *B*, lung of a guinea pig exposed to the asbestos dust for nine months and living thereafter in normal air for 37 months. The reaction shown is more than that in *A* but much less than the reaction in figure 3 *B* (× 200).

8. Willis, H. S., and Brutsaert, P.: Tumor-like Structures in the Lungs of Guinea Pigs Artificially Exposed to Silica Dust, Am. Rev. Tuberc. **17**:268, 1928.