Asbestos

MEDICAL INTELLIGENCE



CURRENT CONCEPTS

Asbestos or Ferruginous Bodies*

EDWARD A. GAENSLER, M.D., AND
WHITNEY W. ADDINGTON, M.D.

THE health hazards of asbestos have been recognized for 40 years. Nevertheless, the problems of asbestos pneumoconiosis (asbestosis) and asbestos-related neoplasms have increased alarmingly despite much improved dust control.[1] This is because of a rapidly rising use of asbestos and because of an ever larger variety of asbestos-containing products, which are often used without awareness of their composition and under poor supervision.[2] In our laboratory in New England some 35 different occupations ranging from cigarette-filter manufacturing to wire braiding have been incriminated. Community "asbestos air pollution" is being recognized only now, and its importance is uncertain. Increasingly, practicing physicians are being confronted by these problems and then, almost invariably, the consequences of "asbestos bodies" are discussed. A review of current concepts concerning these structures is timely.

MORPHOLOGY

In 1906 Marchand[3] first noted "peculiar pigment crystals" in lungs. His description of what came to be known as "asbestos bodies" is still apt: within the alveoli were masses of peculiar, rod-shaped structures with clubbed ends. They were light yellow to reddish brown, 30 to 200 μ long and 1 to 6 μ thick. Striking was the segmentation of the bodies into disk-shaped structures that remained interconnected by colorless threads (Fig. 1). Because they turned black near areas of putrefaction, Marchand suspected that the yellow pigment contained iron; this he confirmed by intense blue coloring with potassium ferrocyanate. In proximity to the "crystals" he noted masses of "epithelial cells," which contained yellow granular material and which looked like heart-failure cells. Because neither of his two autopsied patients gave other evidence of chronic passive congestion, and because some granules looked like segments of the "crystals," he deduced that this material was debris and not hemosiderin. Finally, the appearance of the unusual bodies led him to inquire about the occupation of the patients, but asbestos was not then incriminated.



FIGURE 1. *Lung Biopsy of a 42-Year-Old Rubber Shredder with Diffuse Pulmonary Infiltration*[4] *(Perle's Blue Stain, Original Magnification X1500).*

Talc crystals were identified throughout the specimen as well as in the atmosphere at his place of work. Here shown is a "pseudoasbestos body" undoubtedly due to asbestos amphiboles present in commercial talc.

TERMINOLOGY

Cooke,[5] unaware of Marchand's paper, 20 years later described "curious bodies" throughout the lungs of an asbestos worker and thought that these were of vegetable origin. Stewart[6] first recognized such "brown bodies" as the result of inhaled asbestos, concluded that they were diagnostic of asbestosis and introduced the term "asbestosis bodies." Soon thereafter, such bodies were found in the lungs of asbestos workers without associated fibrosis, and therefore the name was shortened to "asbestos body." Subsequently, morphologically indistinguishable structures were noted in talc workers[7] and designated "pseudoasbestos bodies" (Fig. 1). During the last years a number of other

*From the Thoracic Services, departments of Medicine and Surgery, Boston University School of Medicine (address reprint requests to Dr. Gaensler at Boston University School of Medicine, 80 E. Concord St., Boston, Mass. 02118).

Supported in part by a research grant (HE-05953), a research career award (5-K6-HE-1173) and a training grant (1TS:5562) from the National Heart Institute, National Institutes of Health, United States Public Health Service, and by a grant from the Massachusetts Tuberculosis and Health League, Incorporated.

PLAINTIFF'S
EXHIBIT
AL-1242

substances have been shown to cause asbestos-body-like structures, and therefore Gough[8] suggested the name "mineral fiber bodies." Perhaps the most suitable term, "ferruginous bodies," was coined by Gross[9] to describe structures that have a coating containing iron demonstrable by the Prussian blue reaction, that look like asbestos bodies and that may or may not have asbestos fibers as their core.

Ultrastructure

The original descriptions have now been made more precise by electron microscopy. The core of the bodies is variable. Chrysotile consists of hollow tubes 150 to 400 Å in diameter that may be filled with crystal fragments.[10] The amphibole group, which includes crocidolite, amosite and tremolite, has solid fibers that are much larger, the smallest being 800 Å in diameter. Davis[11] has shown that the coating consists of ferritin granules approximately 60 Å in diameter, and of amorphous material, probably protein. This coating may be very thin or as thick as 5 μ. Several fine needles of asbestos, 0.05 to 0.5 μ in length, may be scattered throughout the body with their axes parallel to the surface. Ferritin may accumulate around very small dust particles and produce "asbestos bodies" of a size below the resolution of the light microscope. Although the deposition of the protein-iron complex was thought to be an extracellular process, electron microscopy now has shown that the formation is intracellular, probably within giant cells or macrophages.

Chemistry

The principal component of the asbestos body is organic, mainly protein with iron; usually there is less than 5 per cent asbestos. Early workers believed that the bodies were formed free within the alveoli and that the coating was derived from hemoglobin released from vessels injured mechanically by the fibers. Another theory was that the coating is deposited by phagocytes.[12] The finding of hydroxyproline led some to suggest that it contains collagen deposited by fibroblasts.[13] Amino acid residues in the protein of asbestos bodies have been examined in the hope of differentiating collagen from other proteins. The analytical values for proline, hydroxyproline, leucine and glycine were all too low for collagen to be the main part of the protein envelope.[14] The protein resembles that of general lung proteins and is also similar to that of serum gamma globulin, globins and hemoglobins. This chemical evidence supports the finding, on electron microscopy, that the coating is formed by the cytoplasm of alveolar macrophages or giant cells. The iron may be derived from disintegrating erythrocytes also ingested by these cells.

Prevalence

In recent years a search has been made for "asbestos bodies" in random post-mortem material. At first, they were found in 26 per cent of autopsies in Capetown near mining operations, but later, surprisingly enough, a similar percentage was demonstrated in Miami, Florida.[15] Since then a still greater prevalence has been reported from other cities.[16] Animals apparently are subject to the same air pollution because asbestos bodies can be found in donkeys, field rats and baboons near mines.[17] The method of sampling is important: on routine histologic examination ferruginous bodies were found in only 2 per cent of lungs without fibrosis; this prevalence increased to 21 per cent if squeezed lung juice was used, and it rose to 48 per cent with scraping of the cut surface.[18] The sampling site was also important, right basilar segments giving the highest yield. A distillation process has revealed a few asbestos bodies in 97 per cent of lungs.[19] In none of these autopsy surveys was there a relation between the prevalence of asbestos bodies and pulmonary fibrosis or cancer. The source of asbestos or other mineral fibers in the city atmosphere has been the subject of much speculation. Dust from automobile brake linings and clutch faces was soon suspected.[15]



FIGURE 2. *Section of the Lung of a 56-Year-Old Shipyard Pipe Coverer Who Died of Squamous-Cell Bronchogenic Carcinoma with Brain Metastases (Hematoxylin and Eosin Stain; Original Magnification X32).*

He was at our laboratories nine years earlier because of asbestosis. The section shows at the top diffuse interstitial fibrosis with honeycombing. In the left lower field the carcinoma is surrounded by masses of asbestos bodies.

409677 0494



FIGURE 3. *Section of Pleura of a 61-Year-Old Man Who Had Been an Asbestos-Sheet Stacker for 22 Years (Hematoxylin and Eosin Stain, Original Magnification X600).*

Seven years earlier asbestosis was recognized at our laboratory. He died three months after the onset of dyspnea, weight loss, chest pain and recurrent serosanguineous pleural effusion.[22] At the bottom there is a nest of asbestos bodies within a mesothelioma. In the upper right area there are several smaller bodies and fine crystals with early beading.

The chrysotile imbedded by heat in the plastic of these linings becomes anhydrous forsterite. Animal experiments have now shown that forsterite indeed can produce ferruginous bodies but that, unlike asbestos, it is nonfibrogenic.[20]

Sputum of asbestos workers frequently contains asbestos bodies, the frequency increasing with time of exposure (22 per cent under one year and 38 per cent over five years) and increasing with higher dust concentration.[21] However, asbestos bodies in sputum are not necessarily indicative of asbestosis. They have also been found in feces, presumably from swallowed sputum, and in the spleen, tonsils and lymph nodes of exposed persons. Neoplasms, particularly bronchogenic carcinoma and pleural and peritoneal mesothelioma, may contain asbestos bodies within and around them (Fig. 2 and 3).

EXPERIMENTAL PRODUCTION

Asbestos bodies can be produced in animals without necessarily causing fibrosis or tumor. Indeed, they have been found after only seven days of exposure.[23] Some animals produce them readily; most notably guinea pigs. They respond by granuloma formation that may provide the ideal environment for coating. Rats do not form bodies, perhaps because asbestos dust causes early fibrosis.[24] Only a tiny fraction, probably less than 1 per cent of all the fibers in the lung, become coated (Fig. 4). Whether a special environment is required for the coating is being investigated by means of pleural injection. Preliminary results suggest that acid mucopolysaccharides and colloidal iron both must be present.[20,24] In tissue cultures, even the smallest dust particles are taken up by macrophages and fibroblasts, but no typical asbestos bodies develop.[25]

NONASBESTOS FERRUGINOUS BODIES

Today, respirable fibers are legion. Diatomaceous earth, graphite and carborundum already have been identified as the core of typical "asbestos bodies" in man.[26] Substances believed to be biologically inert, including fibrous aluminum silicate (Fig. 5), fibrous glass (Fig. 6), silicon carbide and forsterite have caused ferruginous bodies in hamsters and guinea pigs.[9,20] Even fragments of the lung's own elastic tissue may produce "elastosis bodies" that look sim-

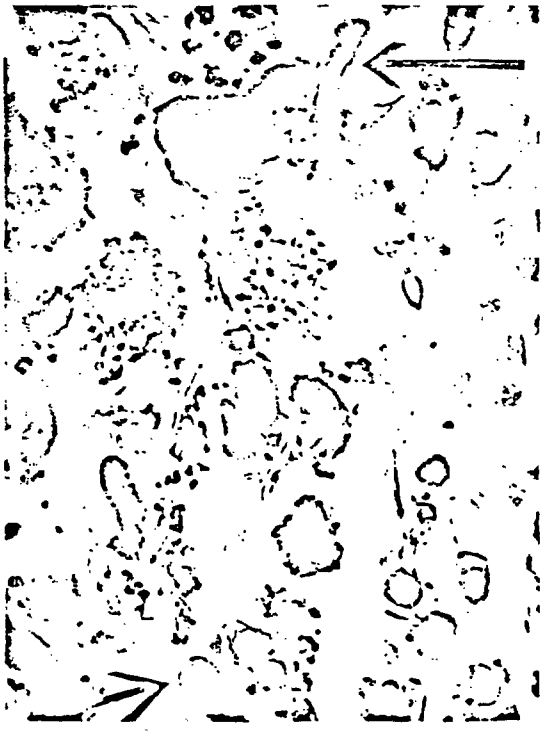

FIGURE 4. *Section of the Lung of a 55-Year-Old Man Who Had Been an Asbestos Sheet Planer for Nine Years (Partially Polarized, Hematoxylin and Eosin Stain, Original Magnification X800).*

A left upper lobectomy was performed because of a large nodule, which proved to be an asbestoma. There are numerous free asbestos fibers throughout the section. Many macrophages are filled with yellow granular debris. There is one well preserved segmented asbestos body at the top (upper arrow) and several broken-off, round heads of bodies at the bottom (lower arrow).

409677 0495



FIGURE 5. *Smear of Sediment of Saline Washing of Hamster Lung Nine Months after Endotracheal Injection with Ceramic Aluminum Silicate (Perle's Blue and Eosin Stain X800).*

A ferruginous body has macrophages attached at each end. (This material was kindly supplied by Dr. Paul Gross, director of the Industrial Hygiene Foundation Laboratories, Pittsburgh, Pa.)

ilar.[8] Technics are now available for analysis of the core fibers. They include electron beam and x-ray diffraction, laser microprobes, ultrasonic disintegration and mass spectroscopy. The electron-beam diffraction patterns of ferruginous bodies from 22 lungs of "unexposed" persons did not coincide with that of chrysotile. Since 95 per cent of asbestos used in the United States is of this type, it was concluded that the vast majority of ferruginous bodies found at random autopsies are not from asbestos.[20]



FIGURE 6. *Section of Hamster Lung 16 Months after Endotracheal Injection with Fibrous Glass Dust (Hematoxylin and Eosin Stain, Original Magnification X600).*

Well developed ferruginous bodies are seen in the upper left and lower right fields. (Material from Dr. Paul Gross.)

Biologic Importance

Obviously, the diagnosis of asbestosis, based on the finding of ferruginous bodies in an apparently unexposed person, must be made with caution. However, one must be equally cautious in making a diagnosis of "nonspecific interstitial pneumonitis" in a person with known exposure because there is no relation between the number of bodies and the severity of asbestos pneumoconiosis. On the contrary, we and others have noted an inverse relation.[8,27] In persons with prolonged but distant exposure, often retired because of respiratory impairment, the lungs frequently show severe fibrosis with only rare asbestos bodies whereas in patients with more recent exposure, lung biopsy reveals alveoli filled with bodies and debris-laden macrophages but little or no fibrosis.

This paradox can be explained in a number of ways. The small number of asbestos bodies in workers with fibrosis who were exposed long ago may be the result of clearing of the intra-alveolar material. This clearing occurs most rapidly in areas of supple alveolar walls whereas it is delayed in the more noncompliant regions near the thickened pleura and around larger vessels and bronchi. Therefore, the distribution of asbestos bodies is uneven, and their number in any section need not be representative.[20,24] The relation between the number of visible asbestos bodies and the degree of fibrosis is also poor because only a very small and variable fraction of fibers become coated (Fig. 4). Probably the tiniest, uncoated particles, which are invisible by light microscopy, are most fibrogenic because they have the largest aggregate surface area. This is important because at some stage a chemical reaction must initiate the process of fibrosis. The visible asbestos bodies, therefore, are best considered as markers, rather than as important causative agents.

Conclusions

In 1929 Cooke said that "curious bodies have been found in every necropsy in pulmonary asbestosis, and the problems we have to decide are, first, what the bodies are, and second, whether they are diagnostic of asbestosis." Although at first answers seemed deceptively simple, new information increasingly has raised new questions. That asbestos bodies may contain asbestos is clear. It is equally clear that structures apparently indistinguishable from asbestos bodies may have as their core other materials. Unfortunately, the methods of identification are exceedingly complex, and, even in the best hands, results remain tentative. Nevertheless, recent animal exposure and analytical work suggests that, until asbestos has been identified as

409677 0496

the core of an "asbestos body," it is best to use the more general term "ferruginous body."

REFERENCES

1. Selikoff, I. J., Bader, R. A., Bader, M. E., Churg, J., and Hammond, E. C. Asbestosis and neoplasia. *Am. J. Med.* 42:487-496, 1967.
2. Brodeur, P. Magic mineral. *The New Yorker* (October 12), 1968. Pp. 117-165.
3. Marchand, F. Über eigentümliche Pigmentkristalle in den Lungen. *Verhandl. d. deutsch. path. Gesellsch.* 10:223-228, 1906.
4. Graham, W. G. B., and Gaensler, E. A. Talco-silicosis in rubber worker. *Med. thorac.* 22:590-604, 1965.
5. Cooke, W. E. Fibrosis of lungs due to inhalation of asbestos dust. *Brit. M. J.* 2:147, 1924.
6. Stewart, M. J. Immediate diagnosis of pulmonary asbestosis at necropsy. *Brit. M. J.* 2:509, 1928.
7. Schepers, G. W. H., and Durkan, T. M. Experimental study of effects of talc dust on animal tissue. *Arch. Indust. Health* 12:317-328, 1955.
8. Gough, J. Differential diagnosis in pathology of asbestosis. *Ann. New York Acad. Sc.* 132:368-372, 1965.
9. Gross, P., deTreville, R. T. P., Cralley, L. J., and Davis, J. M. G. Pulmonary ferruginous bodies: development in response to filamentous dusts and method of isolation and concentration. *Arch. Path.* 85:539-546, 1968.
10. Gaze, R. Physical and molecular structure of asbestos. *Ann. New York Acad. Sc.* 132:23-30, 1965.
11. Davis, J. M. G. Electron-microscope studies of asbestosis in man and animals. *Ann. New York Acad. Sc.* 132:98-111, 1965.
12. Simson, F. W. Pulmonary asbestosis in South Africa. *Brit. M. J.* 1:885-887, 1928.
13. Beattie, J. Asbestos body. In British Occupational Hygiene Society. *Inhaled Particles and Vapours: Proceedings of an international symposium organized by the Society, Oxford, 29 Mar.-1 Apr., 1960.* Edited by C. N. Davies. Oxford: Pergamon, 1961. Pp. 434-441.
14. Blount, M., Holt, P. F., and Leach, A. A. Protein coating of asbestos bodies. *Biochem. J.* 101:204-207, 1966.
15. Thomson, J. G. Asbestos and urban dweller. *Ann. New York Acad. Sc.* 132:196-214, 1965.
16. Cooper, W. C. Asbestos as hazard to health: fact and speculation. *Arch. Environ. Health* 15:285-290, 1967.
17. Webster, I. Asbestosis in non-experimental animals in South Africa. *Nature* (London) 197:506, 1963.
18. Anjilvel, L., and Thurlbeck, W. M. Incidence of asbestos bodies in lungs at random necropsies in Montreal. *Canad. M. A. J.* 95: 1179-1182, 1966.
19. Utidjian, M. D., Gross, P., and deTreville, R. T. P. Ferruginous bodies in human lungs: prevalence at random autopsies. *Arch. Environ. Health* 17:327-333, 1968.
20. Gross, P. Studies of pathogenicity of synthetic and natural asbestos and brake drum dust. Presented at Fibrous Dust Seminar, Mellon Institute, Pittsburgh, Pennsylvania, November 22, 1968.
21. Dreessen, W. C., Dallavalle, J. M., Edwards, T. I., Miller, J. W., and Sayers, R. R. Study of asbestosis in asbestos textile industry. *Pub. Health Bull.* 241:1-126, 1938.
22. Belleau, R., and Gaensler, E. A. Case report from Thoracic Services, Boston University. Mesothelioma and asbestosis. *Respiration* 25:67-79, 1968.
23. Holt, P. F., Mills, J., and Young, D. K. Experimental asbestosis with four types of fibers: importance of small particles. *Ann. New York Acad. Sc.* 132:87-97, 1965.
24. Davis, J. M. G. Pathologic studies of ferruginous bodies. Presented at Fibrous Dust Seminar, Mellon Institute, Pittsburgh, Pennsylvania, November 22, 1968.
25. Pernis, B., Vigliani, E. C., Marchisio, M. A., and Zanardi, S. Observations on effect of asbestos on cells *in vitro*. *Med. d. lavoro* 57:721-729, 1966.
26. Meurman, L. Asbestos bodies and pleural plaques in Finnish series of autopsy cases. *Acta path. et microbiol. Scandinav.* Supp. 181:7-107, 1966.
27. Nagelschmidt, G. Some observations of dust content and composition in lungs with asbestosis, made during work on coal miners pneumoconiosis. *Ann. New York Acad. Sc.* 132:64-76, 1965.

BY THE LONDON POST

Rewards of Teaching and Research

JOHN LISTER, M.D.

THE recurring economic problems of Britain have had an intensely depressing effect upon the whole nation, and one of the principles that has become generally accepted as a means of stabilizing the economy is the need for everyone to accept some discipline in the matter of income. It is not surprising, however, that the principle is readily acceptable in general but hard to accept in particular. No section of the community is likely to be content to receive what it considers to be an adverse or unfair decision of the Prices and Income Board, to which the majority of pay claims are now referred. A major dispute has recently arisen from the report of the Board[1] on the pay of university teaching staff.

The Association of University Teachers had asked for a 15 per cent salary rise, based on a comparison with salaries in industry and the civil service, but the Board proposed only an average rise of 4.9 per cent and emphasized the fact that the endless chain of increases made because similar groups had received increases must be broken. To recruit teachers of quality the largest rises were recommended for assistant lecturers, who would receive increases in salary ranging from 10 to 17 per cent, with much smaller increases for senior lecturers and professors. More controversial, however, than the reduction in the total claim was the comment in the report that the present salaries and career structures of university teachers are biased toward research rather than teaching and promotion tends to depend on the number of publications a teacher has made. To correct this bias the Board proposed that bonuses amounting to 4 per cent of a university's total salary bill should be given up to half the teaching staff below the grade of professor so long as they had passed a four-year or five-year period of probation. This system should be designed to reward a teacher's hours of teaching, the quality of his teaching and sometimes his load of administrative work. Apart from obvious statistics of teaching work load it was suggested that a teacher's merit should be assessed by students through a carefully drafted questionnaire or by the examination performance of his students. Similar awards would be made to professors who had shown outstanding merit, particularly in the setting up and administration of teaching departments.

Justifying his proposal to use student opinion in assessing the merit of their teachers Mr. Aubrey Jones, the chairman of the Prices and Income

409677 0497