Response of the nonhuman primate to polychlorinated biphenyl exposure[1]

J. R. ALLEN

Regional Primate Research Center, University of Wisconsin Medical School, and Food Research Institute, University of Wisconsin, Madison, Wisconsin 53706

The polychlorinated biphenyls (PCBs) have been used extensively for industrial purposes during the past 40 years. These compounds are extremely stable, not hydrolyzed by water, acid or alkali, and are able to withstand temperatures up to 650 C without disintegrating. These properties make them ideal for use in adhesives, paints, varnishes, printing inks, and as general fillers. Since they do not conduct electricity, they have found widespread use in electrical equipment such as transformers. However, it was only during the past decade that the health significance of these compounds in man and lower animals has been brought to public attention. Prior to this time only workers exposed to the PCBs during the production process (15) or workers who were in direct contact with manufactured products containing PCBs (10) occasionally developed a skin rash on exposed portions of the body. It was not until 1966 that Jensen (14) reported the presence of PCBs in the tissues of wildlife suffering from what was thought to be DDT intoxication. As a result of these findings other investigators began to evaluate the magnitude of environmental contamination of this newly discovered pollutant.

The public health significance of the PCBs was brought to the forefront when over 1,000 Japanese consumed rice oil that had been contaminated with a PCB mixture. In this outbreak the exposed persons developed chloracne and subcutaneous edema. Infants born to exposed mothers were small, exhibited discolored skin and had an abnormal eye discharge. Many of the symptoms and lesions that developed in those persons exposed to the PCBs have persisted (17).

The properties that make the PCBs ideal for commercial usage also enhance their resistance to degradation in the environment. The magnitude of PCB contamination is exemplified by their presence in coho salmon, milk-fat, poultry, eggs and fish (16). Detectable levels of PCBs are also present in over 30% of randomly sampled inhabitants of the United States (22).

In the following presentation a detailed description of the biological responses of nonhuman primates to various levels of PCBs will be presented, thus establishing this animal species as an ideal model for evaluating PCB intoxication in man. Data are also presented which show that levels of PCBs presently permitted in some foods destined for human consumption will produce ill effects in nonhuman primates within a relatively short period.

Effects on nonhuman primates of high level exposure to PCBs

When adult *Macaca mulatta* monkeys were given diets containing 100 and 300 ppm of a polychlorinated biphenyl (Aroclor 1248, Monsanto, St. Louis, Mo.) for periods ranging from 2 to 3 months, they experienced extreme morbidity within 1 month and mortality approaching 100% within 3 months. Although the signs and lesions that developed in these animals became apparent equally as soon in those receiving the lower dosage of PCBs, the total intake varied from 0.8 to 1.0 g for the 100 ppm group to 3.6 to 5.4 g for the 300 ppm group (5). There was a gradual weight loss experienced by all of the PCB-fed animals, with the 300 ppm group having a 25% decrease in body weight during the 3-month period of exposure. Within 3 weeks to 1 month the animals had lost a majority of their hair from the face, head, and neck, and the mouth and eyelids were edematous (6). In addition, there was a loss of eyelashes, excessive lacrimation, and conjunctival congestion. Small comedones were particularly obvious around the mouth and on the cheeks and neck (Fig. 1).

These animals also showed a gradual decrease in hemoglobin and hematocrit. Although the total white cell count was not altered appreciably, there was a decrease in the number of circulating lymphocytes and a concomitant increase in neutrophils. Decreases in the serum proteins were related to a reduction in the level of albumin. Reduced total serum lipids, cholesterol, and triglycerides accompanied the altered serum protein (1).

The major microscopic changes in the skin of the affected animals were the development of large intrafollicular keratin cysts and epithelial hyperplasia of the hair follicles particularly of the face with the eyelids being most severely affected (Fig. 2). In addition, in many instances the tissue surrounding these affected hair follicles was edematous and contained acute inflammatory cells (1, 6). There were also major modifications in the morphological features of the stomach, particularly in the fundic and pyloric regions (Fig. 3). The markedly thickened gastric mucosa contained numerous large cysts filled with mucin and lined by epithelium. Penetration of the muscularis mucosa into the underlying submucosa by the glandular epithelium was a common feature of these affected stomachs. Cystic areas similar to those present in the mucosa were larger and more abundant in the submucosa. In addition, ulcerations of the gastric mucosa developed in areas of eroded epithelium and where large mucinous cysts had ruptured (6). This hyperplastic gastritis has persisted in mon-

[1] Supported in part by Public Health grants RR-00167, ES-00472 and CA-13288 from the National Institutes of Health, and the University of Wisconsin Sea Grant Program. Primate Center Publication no. 142-026.

Abbreviations: PCB, polychlorinated biphenyl; TCB, 2,5,2',5'-tetrachlorobiphenyl.

MONS 083885



Figure 1. Facial edema is depicted in a monkey given 100 ppm Aroclor 1248 for 1 month. Swollen lips and eyelids and absence of eyelashes are common features of these animals. Small comedones are discernible on the upper lip, nose and forehead.

keys for over 1 year following the discontinuation of PCB exposure (5).

Ingestion of the PCBs by monkeys caused a decided hypertrophy of the liver which in many instances amounted to over a twofold increase in size. Electron microscopically, the hepatocytes of these livers showed a decided increase in smooth endoplasmic reticulum (Fig. 4). In addition, there were segments of endoplasmic reticulum that formed elaborate concentric membrane arrays. Terminally, the livers of these animals continued to have enlarged hepatocytes. However, there was a rearrangement of the proliferated smooth endoplasmic reticulum in these cells. Instead of being distributed throughout the cytoplasm it was arranged in well circumscribed packets of closely associated membranes (Fig. 5) (1).

Liver biopsies taken from these animals during the course of the experiments showed a decided proliferation of the smooth endoplasmic reticulum of the hepatic cells. Biochemically, the liver homogenates contained a decreased level of DNA (mg/g liver) and RNA (mg/mg DNA) and increased activity of microsomal mixed function oxidases. Terminally, as the morphological features of the proliferated endoplasmic reticulum were modified there was a decided decrease in the activity of the mixed function oxidases (1). Such changes in the endoplasmic reticulum have been designated by Hutterer *et al.* (13) as hyperplastic, hypoactive endoplasmic reticulum.

At necropsy, tissues from these animals were analyzed by gas liquid chromatography for their PCB content. The major storage site for the PCBs was in the adipose tissue and to a lesser extent in the liver, adrenals, and pancreas. Regardless of the site of deposition the higher chlorine isomers predominated in the tissues (Fig. 6).

Low level PCB exposure

Adult female rhesus monkeys have been fed diets containing 2.5, 5.0 and 25.0 ppm of Aroclor 1248 over periods ranging from 2 months for the higher PCB level to 1 year for the two lower doses (4, 8). Animals on the 25 ppm dose developed facial edema, alopecia and acne within 1 month, and 1 of 6 animals had expired as a result of PCB intoxication 2 months after having been removed from the experiment diet. The total intake of PCBs during the experiment ranged from 250 to 400 mg per animal. As was the case with the higher doses, these animals de-

Figure 2. Large keratin cysts (C) in the hair follicles are common on the face of monkeys exposed to PCBs. Tissue from animal given 100 ppm Aroclor 1248 for 3 months. Hematoxylin and eosin stain; ×60.

Figure 3. *a)* The morphological features of the normal gastric mucosa (M) of the monkey are depicted. The muscularis mucosa is intact and glandular elements in the submucosa (S) are absent. Hematoxylin and eosin stain; ×28. *b)* Hypertrophy and hyperplasia involving primarily the mucous secreting cells of the gastric mucosa (M) developed in monkeys fed diets containing Aroclor 1248 ranging from 25 to 300 ppm for 2 to 3 months. Penetration of the muscularis mucosa by the glandular epithelial elements and disruption of the underlying submucosa is a common feature of these affected stomachs.

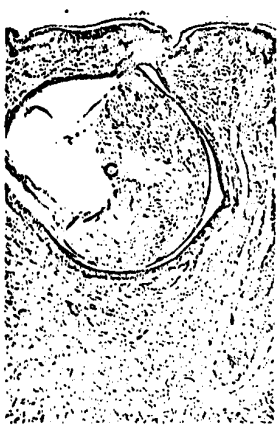



MONS 083886



Figure 4. Hepatocyte of a monkey that had received 100 ppm Aroclor 1248 in the diet for 1 month. Abundant smooth endoplasmic reticulum (ER) and concentric membrane arrays (CMAs) develop in the cytoplasm of these cells. Large lysosomes (L) (acid phosphatase positive) containing numerous large lucent vacuoles are dispersed throughout the cytoplasm. Uranyl acetate stain; ×2970.

veloped anemia, hypoproteinemia, bone marrow hypoplasia and severe hypertrophic hyperplastic gastritis. PCB concentrations in samples of subcutaneous adipose tissue obtained from the animals averaged 127 μg/g fat at the time the experimental diet was discontinued. Eight months later the PCB content of the adipose tissue had decreased to 34 μg/g fat. However, the surviving animals continued to show clinical signs and lesions of PCB intoxication 2 years following PCB exposure. Infants born to these PCB-fed females were small and contained detectable levels of PCB in their tissues (Table 1).

When adult rhesus monkeys were fed diets containing PCB equal to and one-half that permitted in some foods destined for human consumption (2.5 and 5.0 ppm) for 1 year, the females of the group developed periorbital edema, alopecia, erythema and acneform lesions that involved the face and neck within 1 to 2 months. Even though the males consumed more PCB, they exhibited only moderate periorbital edema and erythema. During the course of the experiment the females on the higher PCB dose consumed 364 mg while those on the lower dose ingested 182 mg. The males which received only the higher dosage consumed 383 mg of PCB. After having established a relatively steady tissue level of PCB at 6 months, the females were bred to control males. Following 3 matings 12.5% of the 5 ppm group and 37.5% of the 2.5 ppm group was pregnant as compared to 90% in the control group. However, the conception rate of females bred to PCB-fed males was equally as great as that in females bred to control males. Throughout the course of the experiment the females that consumed the PCBs had higher levels of urinary ketosteroids and a decided increase in the length of menses and amount of menstrual bleeding (8).

Absorption, metabolism, tissue deposition and excretion of PCB

When adult rhesus monkeys were given a single oral dose of Aroclor 1248 and the urine and feces evaluated chromatographically for 14 days, over 90% of the compound was absorbed from the gastrointestinal tract. Ten percent of the original dose was detected in the excreta within 14 days with the greatest percentage occurring between the second and eighth day (7). When a tritiated PCB isomer (2,5,2',5'-tetrachlorobiphenyl) (TCB) was given to monkeys, less than 5% of the tritium had been eliminated in the excreta within 72 hours (12). Analysis of the excreta indicated that direct hydroxylation was not a major metabolic pathway for TCB in the monkey as is the case in the rat (20). Instead, hydroxylation occurred through the arene oxide intermediate (12). The TCB which remained in the body of these animals was primarily associated with the tissue protein and nucleic acids and serum albumin of the blood. In addition, the analysis of hexane extracts of liver and skin homogenates revealed that over 95% of the TCB present was in an unmetabolized form (12). When phenobarbital and SKF-525A were given to adult monkeys to increase and decrease their hepatic microsomal enzyme activities respectively, the response of these animals to TCB was decidedly different. The animals pretreated with SKF 525A died within 48 hours on a dose of TCB that produced no obvious ill effects in animals that had been pretreated with phenobarbital (8).

COMMENTS

In experiments that have been conducted to determine the effects of polychlorinated biphenyls on nonhuman primates it has been established that the signs and lesions that appear in these animals are similar to those that occur in man exposed to similar levels of PCBs. Acne, subcutaneous edema, particularly about the face, and conjunctivitis along with excessive secretion of the meibomian glands were constantly present in PCB exposed man and lower primates (6, 17). The more severely affected animals have a decrease in erythrocytes, reduced hemoglobin and a leukocytosis. The most debilitating lesions in the monkeys were the severe gastric mucosal hyperplasia and ulceration. Whether simi-

MONS 083887

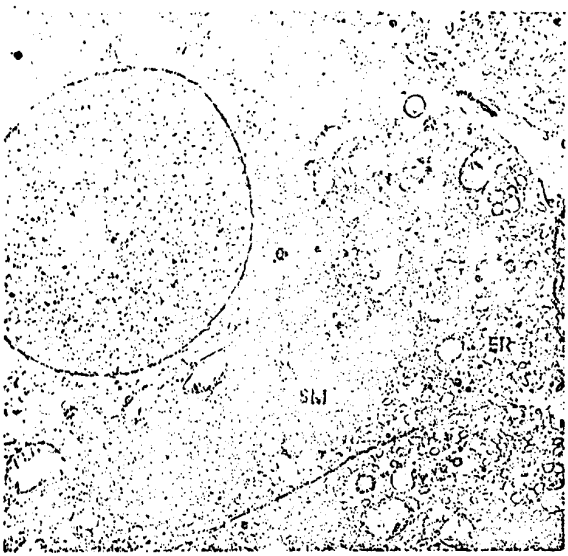

Figure 5. A very fine network of smooth surfaced membranes (SM) is present in the cytoplasm of hepatocytes from monkeys fed Aroclor 1248 in the diet for 3 months. Note the vesicular appearance of the remaining portions of the endoplasmic reticulum (ER). Contrast these membranes with those of Fig. 4. Uranyl acetate stain; ×5950.

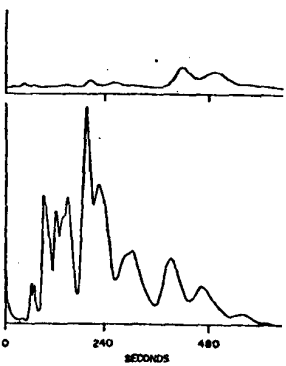

Figure 6. GLC-EC tracing of Aroclor 1248 (lower); the residue in the fat of a monkey given a diet containing 25 ppm Aroclor 1248 for 2 months (upper).

lar changes occur in the stomach of man exposed to PCBs has not been established. However, the nausea and anorexia they experienced was suggestive of gastritis. Liver hypertrophy, proliferation of the hepatic endoplasmic reticulum and increased microsomal enzyme activity were consistent hepatic changes in both species (1, 11). Altered ketosteroid levels, dysmenorrhea, reduced birth weights of infants born to exposed mothers and transplacental movement of PCBs have also been recorded. Of major significance is the persistence of lesions in both species for years following exposure to PCBs which may be related in part to the continued presence of detectable levels of PCB in the tissues of those exposed (4, 19).

The previously presented data indicate that the PCBs are toxic to primates over a wide dose range. It is particularly significant that monkeys develop signs of PCB intoxication within 1 to 2 months at doses as low as 2.5 and 5.0 ppm in the diet. Although the possibility of man consuming a diet containing these concentrations of PCB on a continuous basis is remote, these data do point out the fact that only small amounts of these compounds are required to produce toxicity and that a safe level has not yet been established. Since PCBs are known to accumulate in the tissues of exposed animals, continuous exposure to even minute quantities may be sufficient to eventually cause toxic effects.

Indications are that the toxicity of PCB is directly related to the ability of the animal to metabolize and excrete it (8, and Allen and Van Miller, ms in preparation). This has been demonstrated in rats and monkeys by the use of drugs that inhibit and increase the activity of hepatic microsomal enzymes. Animals that had been pretreated with phenobarbital prior to PCB administration suffered no ill effects from doses of PCB that under control conditions would have been very toxic. However, when the animals were given SKF 525A during the initial 24 hours of exposure to PCB, they succumbed rapidly. Such data suggest that the PCBs and not their metabolites are responsible for the acute toxic effects of the PCBs.

It has recently been shown that rats were able to survive for a period of one year on doses of PCB (100

TABLE 1. PCB content of tissues obtained from mother and infant monkey following consumption of Aroclor 1248[a] by mother prior to pregnancy[b]

Organ	Weight, gm	PCB content, μg/gm tissue
Mother		
Liver		56.3
Fat		50.0
Placenta		0.9
Infant		
Fat		27.70
Adrenals	0.2	24.40
Muscle		0.98
Stomach		0.55
Small intestine		0.52
Skin		0.31
Brain	52.9	0.29
Lung	6.1	0.21
Kidney	2.8	0.10
Large intestine		0.08
Liver	11.9	0.01

[a] Monsanto Co., Inc., St. Louis, Mo. [b] Adult on diet containing 25 ppm PCB for 2 months and subsequently placed on a control diet for 2.5 months before breeding.

MONS 083888

ppm in the diet) that were lethal to monkeys within 2 to 3 months (2, 6). An explanation for the variation in species response is associated with the rate at which they metabolize PCB. In the rat the half-life of the PCB isomer 2,5,2',5'-tetrachlorobiphenyl was less than 24 hours (21) due to its rapid metabolism and excretion. However, the half-life of 2,5,2',5'-tetrachlorobiphenyl in the monkey is much longer (Allen and Van Miller, ms in preparation), primarily due to its slow metabolism. This difference in the rate of metabolism of 2,5,2',5'-tetrachlorobiphenyl in the rat and monkey may be related to the difference in metabolic pathways. There are data which indicate that most of the PCBs undergo direct hydroxylation in the rat (21) while an arene oxide intermediate is formed prior to hydroxylation in the monkey (12).

The presence of arene oxide as an intermediate metabolite of PCB in the primate broadens the scope of possible injurious effects that may be experienced following PCB exposure. The arene oxides have been shown to be strong alkylating agents capable of producing sufficient changes in the proteins and nucleic acids to cause death or neoplastic transformations in affected cells (18). These cell modifications may be rather subtle and require years to be manifested. Therefore, continuous low level exposure to PCBs may be insufficient to produce obvious signs of PCB intoxication yet the dose may be adequate to cause macromolecular alterations.

Many of the lesions that develop in PCB intoxicated primates are directly related to the deposition of the compound in the affected tissue while other changes may be secondary. The loss of weight, decrease in serum protein and moderate anemia were likely related to the reduced food intake that occurred in the animals with hyperplastic gastritis, the latter having developed due to the irritating effect that the PCB had on the gastric mucosa. The hypertrophic hyperactive livers that developed in PCB exposed animals were a result of the stimulatory effect they had on the hepatic endoplasmic reticulum and their enzymes. However, when the exposure to PCB is sufficiently great, degenerative changes develop particularly in the organelle containing the highest level of PCB, the endoplasmic reticulum (1). The skin lesions may also be directly related to the presence of high levels of PCB. It has been shown that following exposure a considerable amount of PCB accumulates in the skin and underlying tissue and persists in this area for an indefinite period (4).

Many of the injurious effects of PCB intoxication may result secondarily from the rapid metabolism of endogenous substances by the hyperactive endoplasmic reticulum. Following PCB exposure there is an increased metabolism of steroids and steroid-like compounds. These altered steroid hormone levels may be responsible for the inability of PCB-fed primates to conceive (8). Decreased levels of vitamin A as have been reported to occur in quail, rats (9) and monkeys (D. A. Barsotti, M. H. Zile and Allen, unpublished observations) could also be at least in part responsible for the follicular dermatitis that occurs in these animals.

A majority of the data presented in this paper were obtained through the efforts of my colleagues in the Experimental Pathology Laboratory: L. J. Abrahamson, D. A. Barsotti, L. A. Carstens, I. C. Hsu, R. J. Marlar, D. H. Norback, J. P. Van Miller.

REFERENCES

1. ALLEN, J. R., L. J. ABRAHAMSON AND D. H. NORBACK. Biological effects of polychlorinated biphenyls and triphenyls on the subhuman primate. *Environ. Res.* 6: 344, 1975.
2. ALLEN, J. R., L. A. CARSTENS AND L. J. ABRAHAMSON. Responses of rats exposed to polychlorinated biphenyls for fifty-two weeks. I. Comparison of tissue levels of PCB and biological changes. *Arch. Environ. Contam. Toxicol.* In press.
3. ALLEN, J. R., L. A. CARSTENS, L. J. ABRAHAMSON AND R. J. MARLAR. Response of rats and nonhuman primates to 2,5,2',5'-tetrachlorobiphenyl. *Environ. Res.* In press.
4. ALLEN, J. R., L. A. CARSTENS AND D. A. BARSOTTI. Residual effects of short-term, low level exposure of nonhuman primates to polychlorinated biphenyls. *Toxicol. Appl. Pharmacol.* 30: 440, 1974.
5. ALLEN, J. R., L. A. CARSTENS AND D. H. NORBACK. Biological effects of the polychlorinated biphenyls in non-human primates. *Proceedings of the International Symposium on Recent Advances in the Assessment of the Health Effects of Environmental Pollution*, World Health Organization. In press.
6. ALLEN, J. R., AND D. A. NORBACK. Polychlorinated biphenyl and triphenyl induced mucosal hyperplasia in primates. *Science* 179: 498, 1973.
7. ALLEN, J. R., D. H. NORBACK AND I. C. HSU. Tissue modifications in monkeys as related to absorption, distribution and excretion of polychlorinated biphenyls. *Arch. Environ. Contam. Toxicol.* 2: 86, 1974.
8. BARSOTTI, D. A., AND J. R. ALLEN. Effects of polychlorinated biphenyls on reproduction in the primate. *Federation Proc.* 34: 338, 1975.
9. BITMAN, J., H. S. CECIL AND S. J. HARRIS. Biological effects of polychlorinated biphenyls in rats and quail. *Environ. Health Persp.* 1: 145, 1972.
10. GOOD, C. K., AND N. PENSKY. Halowax acne; cutaneous eruptions in marine electricians due to certain chlorinated naphthalenes and diphenyls. *Arch. Dermatol. Syphilol.* 48: 215, 1943.
11. HIRAYAMA, C., T. IRISA AND T. YAMAMOTO. Fine structural changes of the liver in patients with chlorobiphenyl intoxication. *Fukuoka Igaku Zasshi* 60: 455, 1969.
12. HSU, I. C., J. P. VAN MILLER AND J. R. ALLEN. Metabolic fate of ^{3}H 2,5,2',5'-tetrachlorobiphenyl in nonhuman primates. *Bull. Environ. Contam. Toxicol.*, submitted.
13. HUTTERER, F., F. SCHAFFNER, F. M. KLION AND H. POPPER. Hypertrophic, hyposactive smooth endoplasmic reticulum: A sensitive indicator of hepatotoxicity exemplified by dieldrin. *Science* 161: 1017, 1968.
14. JENSEN, S. Report on a new chemical hazard. *New Sci.* 32: 612, 1966.
15. JONES, J. W., AND H. S. ALDEN. An acneform dermatergosis. *Arch. Dermatol. Syphilol.* 33: 1022, 1936.
16. KOLBYE, A. C. Food exposure to polychlorinated biphenyls. *Environ. Health Persp.* 1: 85, 1972.
17. KURATSUNE, M. An epidemiologic study of "Yusho" or chlorobiphenyl poisoning. *Fukuoka Igaku Zasshi* 60: 515, 1969.
18. KURATSUNE, M., T. YOSHIMURA, J. MATSUZAKA AND A. YAMAGUCHI. Epidemiologic study on Yusho, a poisoning caused by ingestion of rice oil contaminated with a commercial brand of polychlorinated biphenyls. *Environ. Health. Persp.* 1: 119, 1972.
19. MILLER, J. A. Carcinogenesis by chemicals. *Cancer Res.* 30: 559, 1970.
20. OKIMURA, M., C. HIRAYAMA AND M. UZAWA. Study of Yusho (chlorobiphenyl poisoning) in clinical examination. *Fukuoka Igaku Zasshi* 62: 123, 1971.
21. VAN MILLER, J. P., I. C. HSU AND J. R. ALLEN. Distribution and metabolism of ^{3}H 2,5,2',5'-tetrachlorobiphenyl in rats. *Proc. Soc. Expl. Biol. Med.* 148: 682, 1975.
22. YOSS, A. R. Food exposure to polychlorinated biphenyls. *Environ. Health Persp.* 1: 79, 1972.

MONS 083889