suggested that it may be associated with necrotising arteritis.

I thank Dr. W. M. Capper for permission to publish the details of the first patient; Mr. Geoffrey Dake, who performed the first operation on this patient; and Mr. Charles Bartlett, who came to my assistance at the time of the second operation.

REFERENCES

Baker, H. (1956) *Brit. med. J.* ii, 1429.
Baker, T. J., Capper, W. M. (1951) *ibid.* i, 1177.
Capper, W. M., Baker, T. J. (1951) *ibid.* ii, 265.
Watson, P. C. (1956) *ibid.* i, 1334.

ASBESTOSIS AND ABDOMINAL NEOPLASMS

E. E. KEAL
M.R.C.P., D.C.H.
SENIOR REGISTRAR IN CHEST MEDICINE, LEEDS CHEST CLINIC, AND KILLINGBECK HOSPITAL, LEEDS, 14 *

IN 1953, an impression was formed at The London Hospital that women suffering from pulmonary asbestosis had ovarian neoplasms more often than other women. The occurrence of further cases led to the present investigation, which is based on a search of the records of the hospital since 1948. In that period 23 women have been inpatients with a diagnosis of asbestosis. 15 are known to have died, 4 with lung cancers and 9 with intra-abdominal neoplasms. Of these 9, 1 had an ovarian carcinoma, and 4 had peritoneal growths, possibly of ovarian origin. In the other 4, the diagnosis was carcinomatosis peritonei and, though 2 underwent laparotomy and 1 came to necropsy, no primary lesion was found. During the same period, 19 men were admitted with asbestosis. 15 of them are known to have died, including 10 with lung cancer and 1 thought to have a malignant mesothelioma of peritoneum, though there were some features suggestive of a primary bronchial neoplasm. Detailed case-histories will be given only for the 9 women with ovarian or peritoneal growths, and for the one man thought to have a peritoneal mesothelioma. Relevant details of the other cases are summarised in tables I and II, and will be briefly discussed. Many other patients with asbestosis attend the hospital, but only as outpatients, and so do not appear in the diagnostic index. Their total numbers are therefore not known.

* This work was done while the author was medical registrar at The London Hospital, London, E.1.

Case-records

Occupational histories are omitted for brevity, but will be found in tables I and II.

Case 1.—A spinster, aged 42, was admitted in May, 1951, with papilloedemic hypertension and left ventricular failure. A diagnosis of asbestosis had been accepted by the pneumoconiosis panel five years earlier and a full pension granted. While in hospital she had retention of urine, and pelvic examination revealed a swelling in the pouch of Douglas. A week later she suddenly became unconscious, with signs of a left hemiplegia, and she died shortly afterwards.

Necropsy.—Death was due to an embolus in the right carotid artery. There was no pleural effusion, but there was a narrow band of fibrous adhesions over the anteromedial surface of the

TABLE I—CASES OF ASBESTOSIS (WOMEN)

Case	London Hospital number	Present age or age at death	Years since first exposure	Duration of exposure (years)	Type of exposure	Associated disease
1	22415/50	Died 43	21	21	Asbestos grinding ✓	Carcinoma of ovary
2	22152/49	Died 45	28	7	Asbestos spinning	Peritoneal carcinoma, probably from ovary
3	51430/49	Died 64	45	4	Asbestos spinning	" " ? ovary; ? mesothelioma
4	14638/52	Died 49	30	4½	Carding room	" " "
5	4269/53	Died 52	30	3	Mattress department	Carcinomatosis peritonei
6	35421/55	Died 58	33	2	Asbestos spinning	Peritoneal carcinoma, probably from ovary
7	41550/37	Died 39	23	4	Slab-making department	Carcinomatosis peritonei
8	37250/55	Died 59	31	1	Slab-making department	" "
9	50265	Died 35	..	..	Not known	" "
10	37252/55	Died 56	35	1 month	Warping machine	Carcinoma of bronchus (squamous cell)
11	29339/52	Died 59	35	7	Asbestos grinding ✓	" " " (*poly. gonal cell*)
12	23267/53	Died 45	27	4	Asbestos weaving	" " " "atypical" cells in sputum
13	21144/47	Died 50	20	20	Mattress department	" " " (type not stated)
14	49720/49	43 (1951)	20	3	Asbestos spinning	Last seen 1951
15	16224/50	51 (1950)	25	3	Unspecified	Well, 1950
16	53324/50	57	18	13	Unspecified	Well
17	10355/53	53	21	1½	Unspecified	Well
18	22913/56	51	26	6	Asbestos weaver	Congestive heart-failure
19	23622/54	72	39	5	Sweeper in asbestos factory	Cholecystitis
20	24930/55	Died 52	33	3	Spinning department	Pulmonary hypertension; right heart-failure; carcinoma of breast
21	14793	Died 63	30	3	Mattress filler	Carcinoma of stomach
22	25563	53	19	37	Tape lapper ✓	Carcinoma of breast
23	41545/51	59	32	4	Unspecified	Congestive heart-failure

TABLE II—CASES OF ASBESTOSIS (MEN)

Case	London Hospital number	Present age or age at death	Years since first exposure	Duration of exposure (years)	Type of exposure	Associated disease
24	22265/55	Died 59	26	23	Cleaning ventilators ✓	Malignant mesothelioma of peritoneum
25	22852/51	Died 63	45	45	Asbestos lagger ✓	Carcinoma of lung (anaplastic, spheroidal cell)
26	15178/53	Died 53	5	5	Asbestos grinder ✓	" " " (polygonal cell)
27	31502/52	Died 47	22	2	Sorter in asbestos factory	" " " (anaplastic, spheroidal cell)
28	24472/55	Died 55	7	7	Tipping asbestos	" " " (not stated)
29	34815/56	Died 63	6	6	Asbestos carter	" " " (squamous cell)
30	29223/57	Died 54	39	15	" Asbestos factory "	" " " (squamous cell)
31	16355	Died 76	31	17	" Asbestos factory "	" " " (squamous cell)
32	24128	Died 56	40	40	Boiler coverer ✓	" " " (squamous cell)
33	29413/56	Died 53	31	18	Unloading and sawing asbestos	" " " (anaplastic, spheroidal cell)
34	45921	Died 37	15	18	Boiler coverer ✓	" " " (polygonal cell)
35	27148/55	Died 65	35	4½ mos	Asbestos grinder ✓	Suppurative pneumonia, cerebral abscess
36	41535/52	59	42	42	Boiler coverer ✓	Emphysema, congestive heart-failure
37	24612/52	Died 42	19	19	Asbestos packer	Bronchopneumonia, pulmonary infarction
38	25509/51	Died 62	40	3	Asbestos packer	Upper respiratory tract acute gastric erosion
39	53013/52	Died 60	24	4	Asbestos factory labourer	Carcinoma of sigmoid
40	17139/55	44	31	6 mos	Pressing up asbestos	Bronchitis
41	13552	55	36	5	" Asbestos factory "	..
42	23376/43	63 (1955)	22	25	Loading and burning asbestos	..



Fig. 1—Case 1. Papillary, columnar, and cuboidal-cell carcinoma, with occasional aggregates of larger, pale-staining polygonal cells suggestive of the whorling seen in squamous-cell carcinoma. (×110.)

right upper lobe. All lobes of lung showed a firm shotty induration with almost confluent nodules of greyish-black fibrosis against a paler reddish-brown background. The fibrosis was more diffuse in the anterior parts of the right upper lobe and in the right lower lobe, showing a blue-grey interlacing network of fibrous strands. The left ovary was enlarged (*11 cm. diameter*) by a nodular necrotic cystic carcinoma, unaccompanied by peritoneal or any other secondary deposits.

Histology.—The tumour was a papillary, columnar, and cuboidal-cell carcinoma, with occasional aggregates of larger pale-staining polygonal cells suggestive of the whorling seen in squamous-cell carcinoma (fig. 1). The lungs showed peribronchiolar and peribronchial interstitial fibrosis with some slight bronchiolar epithelial hyperplasia. Numerous asbestos bodies were found, often entirely or partially ingested by giant-cells of the foreign-body type. A few asbestos bodies were found in a partially fibrotic hilar lymph-node.

Case 2.—Asbestosis had been diagnosed at the age of 40. She was admitted when she was 45, with a history of lower abdominal bearing-down pains for one year, followed by anorexia, diarrhœa and weight-loss. A large hard irregular mass was felt in the lower abdomen, arising from the pelvis. At laparotomy, the whole of the posterior sheath of the rectus appeared *infiltrated by growth and no further* examination was made. A biopsy was taken and histological examination showed a carcinoma composed of papillary, tubular, and cuboidal cells, suggesting an ovarian primary (fig. 2). She died in hospital after nine months.



Fig. 3—Case 3. Moderately scirrhous solid trabecular small polygonal-cell carcinoma, with grouping of the cells suggestive of rosettes. (×120.)



Fig. 2—Case 2. Papillary, tubular, and solid masses of cuboidal-cell carcinoma, suggesting an ovarian primary. (×114.)

Necropsy (Dr. B. E. Heard at St. Mary's Hospital).—There were many fibrous adhesions in both pleural sacs with numerous, evenly scattered, dark nodules throughout both lungs. Scrapings showed asbestos bodies. A great amount of growth filled the peritoneum and invaded the walls of the intestines and the greater omentum. There was one nodule in the liver. The ovaries were not identified in the mass of growth filling the pelvis. The cause of death was given as carcinoma of peritoneum, probably from ovary.

Case 3.—She was found to have asbestosis in 1953, and was admitted one year later at the age of 61, with a five-week history of abdominal distension, anorexia, constipation, and progressive weight-loss. She was cachectic. There was ascites, and a large hard irregular mass could be felt rising from the pelvis. She required repeated paracentesis, and died after twelve weeks in hospital.

Necropsy.—Fibrous adhesions were found at the apex of the left lung. There was conspicuous diffuse emphysema. Asbestos *bodies were seen in* smears from the cut surface of the lung. Fine fibrosis was present throughout both lungs with discrete areas of anthracosis, maximal in the lower lobes. There were nodules of growth throughout the peritoneum, with plaques of growth surrounding the liver and spleen. A mass of growth filled the pelvis and the ovaries were not identified. On histological examination, the lungs showed variable pleural fibrosis. Numerous asbestos bodies were seen, with patchy fibrosis in the lung-substance. Sections of the tumour showed a moderately scirrhous solid trabecular small-cell carcinoma, with grouping of the cells suggestive of rosettes (fig. 3).



Fig. 4—Case 4. Small cuboidal and flat-celled tubular secondary carcinomata in omentum. Ovary is probable primary site; peritoneal endothelium is at bottom. (×114.)

Case 4.—Admitted in October, 1952, with a three-month history of abdominal swelling, weakness, and weight loss. She was ill and wasted. The fingers were clubbed. Coarse crepitations were heard at bases of both lungs. Chest X-ray showed diffuse reticulation in both lower zones with bilateral pleural thickening. The sputum contained asbestos bodies. There was ascites, and a mass was felt on vaginal examination. At laparotomy, a mass of growth filled the pelvis, and there were nodules in the omentum and over the anterior abdominal wall. A biopsy was taken, and histological examination showed a secondary carcinoma composed of small, cuboidal, tubular, and flat cells in omentum (fig. 4). The ovary was thought to be a probable primary site, though a peritoneal endothelioma could not be excluded. She was admitted on two further occasions for paracentesis, but died at home and necropsy was not performed.

Case 5.—Admitted in February, 1953, at the age of 52, with a six-week history of bearing-down pains in the lower abdomen radiating to the vagina and thighs. The pain was worse on defecation and micturition, but there had been no change in bowel habits and no blood in stools or urine. She worked in the mattress department of an asbestos company for three years from the age of 16, and had been breathless on exertion for some years but denied having had a cough. She was ill and wasted. The fingers were not clubbed. There were bilateral basal crepitations, and X-ray examination showed pleural thickening at the right base, and fine reticulation throughout the



Fig. 5—Case 6. Tubular, and occasionally papillary, cuboidal-cell carcinoma suggestive of ovarian origin. (×114.)

lung-fields. The sputum contained asbestos bodies, but no tubercle bacilli or neoplastic cells. The liver was enlarged, hard, and irregular; and pelvic examination revealed a craggy mass in the pouch of Douglas. The stools contained no occult blood and a catheter specimen of urine was normal. She was thought to have peritoneal carcinomatosis and further investigations were unjustifiable. She died at home some weeks later, and no postmortem examination was made.

Case 6.—Admitted at the age of 53, when she gave a history of exertional dyspnœa for several years, severe unproductive cough for seven months and pleurisy four months earlier. Her main symptom was lower abdominal pain, associated with anorexia and weight-loss. The chest was emphysematous but there were no added sounds, and the fingers were not clubbed. Chest X-ray showed no definite abnormality, but the sputum contained numerous asbestos bodies. There was suprapubic tenderness, and on pelvic examination the uterus was felt to be enlarged, irregular, and fixed. At laparotomy, free fluid was present and the pelvis was filled by a mass of growth of undetermined origin. There were nodules of growth throughout the peritoneum. A biopsy specimen was taken and histological examination showed a carcinoma made up of papillary, tubular, and cuboidal cells, suggestive of an ovarian primary (fig. 5). She died four months later and postmortem examination was not made.



Fig. 6—Case 7. Nodule of secondary carcinoma from peritoneum, composed of solid trabeculæ of polygonal cells. (×120.)

Case 7.—Thought to have asbestosis when she was admitted at the age of 38, complaining of abdominal swelling for six weeks. She was obese and dyspnœic with impaired percussion note at both bases and bilateral basal crepitations. Chest X-ray showed diffuse mottling throughout both lungs with pleural thickening at the left base. No asbestos bodies were found in the one specimen of sputum examined. Free fluid was present in the abdomen, and a mobile mass was felt in the hypogastrium. At laparotomy, the omentum and peritoneum were studded with miliary nodules. The ovaries were cystic and studded with growth, but were not apparently the primary site. The histological appearance was that of secondary carcinoma in omentum, composed of solid trabeculæ of polygonal cells (fig. 6). She died at home six months later, and no postmortem examination was made.

Case 8.—Admitted at the age of 59. She had worked in the slab-making department of an asbestos factory for one year when she was 21. There had been no subsequent chest symptoms and the chest X-ray showed no abnormality, but her sputum contained numerous asbestos bodies. She complained of malaise for one year and of increasing girth for five months. There was gross ascites, with an irregular mass in the left hypochondrium and another in the pelvis. A barium enema showed some narrowing in the region of the splenic flexure, thought to be due to extrinsic pressure, but no intrinsic lesion of the colon. At laparotomy, the mass in the upper abdomen was found to be rolled up omentum, invaded by growth, and there were nodules of growth throughout the peritoneum. The ovaries were atrophic and also studded with growth. No abnormality was found in the stomach or intestine. The appendix and a piece of omentum were removed for histological examination, which



Fig. 7—Case 8. Dense subserous fibrosis and lymphocytic infiltration with ill-defined tubules of polygonal and cuboidal cells that show no cytological evidence of malignancy. (×144.)

showed very dense subserous fibrosis and lymphocytic infiltration, with ill-defined tubular inclusions lined by polygonal cells that showed no cytological evidence of malignancy (fig. 7). The patient was seen once more in outpatients two months later, when the abdomen was said to be solid with growth. She died at home shortly afterwards and necropsy was not performed.

Case 9.—A 35-year-old woman was admitted to a gynæcological ward with a three-month history of gradual enlargement of the abdomen. No history of exposure to asbestos was recorded in the notes, but her sister was noted to have died from lung cancer secondary to asbestosis. There was dullness to percussion at both lung bases, with diminished breath sounds and coarse crepitations. The abdomen was greatly distended with fluid. Chest X-rays showed loss of translucency over both sides of the diaphragm, and the sputum contained asbestos bodies. At laparotomy, hard nodular swellings were found along the mesenteric border of the small intestine and studded over the omentum. The ovaries, liver, kidneys, appendix, and uterus were normal. The patient died seven weeks after operation.

Necropsy.—A layer of soft white growth covered the visceral peritoneum over the intestines, stomach, and pelvic viscera. There was similar growth over the under surface of the left lobe

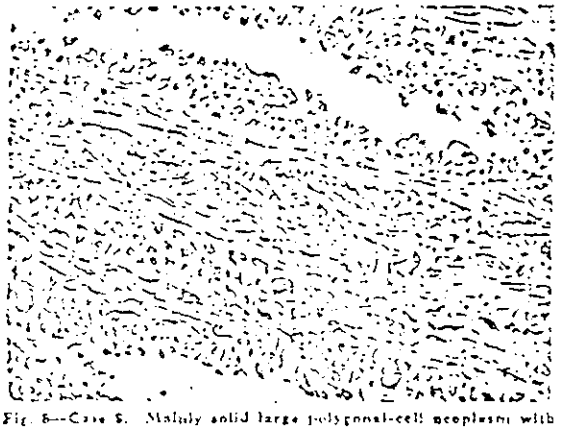

Fig. 8—Case 8. Mainly solid large polygonal-cell neoplasm with some papillary and some small-cell areas with cleft formation. A few areas show a transitional pattern. (×110.)

of the diaphragm and over the posterior abdominal wall. The ovaries were normal, but their surfaces were covered with growth. In the chest, there were tough fibrous adhesions between the right dome of the diaphragm and the lung, and two plaques of hyaline fibrosis in the pleura over the left dome of the diaphragm. No growth was found in the hilar lymph-nodes. There was diffuse fibrosis throughout the lower lobes of both lungs, with areas of confluent slaty-black anthracosis. No primary growth was found anywhere. Histological examination showed a neoplasm composed of solid, large polygonal cells with some papillary-cell and small-cell areas, associated with cleft formation. Occasional areas showed a transitional-cell pattern (fig. 8).

Case 24.—Admitted at the age of 50. Three years earlier, a diagnosis of asbestosis had been made. One year before admission, he attended outpatients with an eight-month history of epigastric discomfort, unrelated to meals but worse at night. There were no abnormal signs and a barium-meal examination showed no abnormality. He had some relief from alkalis; but vague abdominal discomfort persisted, and for two months before admission there had been loss of appetite with increasing girth. He was ill and wasted. The percussion note was impaired at both lung bases and there were bilateral basal crepitations. The abdomen was tense with fluid, but, after paracentesis, a large epigastric mass was felt. Chest X-rays showed diffuse reticulation, maximal in the lower zones. The sputum contained asbestos bodies. He died after three months in hospital.

Necropsy.—Firm fibrous thickening of the parietal pleura was present over the posterior chest wall, particularly on the right. There was slight diffuse fibrosis of the visceral pleura throughout, with underlying anthracotic flecking. The lungs showed slight diffuse induration, with scattered areas of anthracosis. No macroscopic carcinoma was found in the bronchi, or hilar lymph-nodes. In the mesentery of the ilium, a nodular firm fibrous mass was found which separated easily from the posterior abdominal wall. There were numerous nodules of growth in the lesser omentum, and around the pylorus of an otherwise normal stomach. Further nodules and plaques of growth were found throughout the peritoneum, in many places indenting the mucosa of the large and small bowel, but nowhere infiltrating the mucosa. On histological examination, the tumour shown was composed of small cuboidal cells with papillary, cleft-like, and tubular formation. There were a few areas of larger, less well-differentiated cells, and also some areas of myxomatous degeneration. This neoplasm was present in the serosa of ileum, spleen, and the peritoneal surface of the diaphragm, with one solid trabecula of cells extending through the diaphragm into the hyaline, fibrotic pleural surface. There were small clumps of cells in a carinal lymph-node, which also contained asbestos bodies. In the lungs, there was moderate peribronchiolar and pleural fibrosis with numerous asbestos bodies. A little bronchiolar epithelial hyperplasia was seen in the right lower lobe.

Discussion

Asbestosis

The first recorded case of pulmonary asbestosis was that of a patient who died in Charing Cross Hospital, London, in 1900. Details were given to the Departmental Committee on Compensation for Industrial Diseases (1907), by Dr. Montague Murray. It was not until 1930, when a further inquiry was held (Merewether 1930a and b, Merewether and Price 1930), that asbestosis was recognised as an industrial disease in this country and measures were taken to prevent it. By the nature of the work involved, these measures were unlikely to be wholly successful, and it is of interest that of the 42 cases in this series, ten (8 men and 2 women) were first exposed after 1930.

Asbestosis and Lung Cancer

Lynch and Smith (1935) reported the first case of lung cancer associated with asbestosis. In 1952, Hueper (1952) was able to collect 61 published examples. Of 99 detailed by Hueper (1955), 82 originated in England. The first statistical review was that of Merewether (1947), who reported the finding of lung cancer in 13·2% of 235 necropsies on patients with asbestosis. This was compared with an incidence of 1·32% among 6884 cases of silicosis. Wyers (1950) reported an incidence of 14·8% among 115 necropsies, and Gloyne (1951) found lung cancer in 14·1% of deaths associated with asbestosis. Doll (1955) provided further confirmation of a causal relationship with his investigation of necropsy reports on 105 persons who had been employed at one asbestos works. Lung cancer was found in 15 of 75 cases with asbestosis, and in 3 of the 30 cases without asbestosis. He concluded that the risk of lung cancer among men employed for twenty years or more was ten times that of the general population.

Such a direct association is not universally accepted. Jacob and Bohlig (1955), in Dresden, studied 243 cases of asbestosis and found only 4 cases of lung cancer, but 15 of associated active tuberculosis. [illegible] during the past twenty years, the average number of asbestos workers throughout Germany has [illegible] 3000 and 4000 but that only 17 cases of [illegible] reported among them. [illegible] based on necropsy findings [illegible] the popu-

lation at risk. In an epidemiological study of over 6000 workers in the asbestos mines of Quebec, they found only 9 proved lung cancers—an incidence of 25·3 : 100,000 of the population studied. Comparing this incidence with that of 22·5 per 100,000 for the rest of the province of Quebec, they conclude that the absestos workers do not have a significantly higher death-rate from lung cancer than do comparable sections of the general population.

The present series is too small for statistical analysis, but it will be seen that the incidence of lung cancer at necropsy is very much higher than any previously reported —particularly among the men, where it is 67%. This is largely explained by selection, since 6 of the 10 men were referred directly to the medical and surgical thoracic units from other hospitals with the diagnosis, either provisional or established, of lung cancer. The same explanation does not hold for the females, who all attended at general medical outpatients, thus giving a lung cancer incidence of 26% of all deaths associated with asbestosis. It will be seen from table III that the average duration of exposure

TABLE III—PERIOD SINCE FIRST EXPOSURE AND DURATION OF EXPOSURE OF 35 CASES OF ASBESTOSIS, ASBESTOSIS WITH LUNG CANCER, AND ASBESTOSIS WITH PERITONEAL CANCER

—	Number of cases		Years since first exposure		Duration of exposure (years)	
	M	F	M	F	M	F
Asbestosis and peritoneal cancer ..	1	8	26	30·7* 21–38†	23	5·8* 1–21†
Asbestosis and lung cancer	10	4	21·6* 5–43†	24* 15–34†	14·3* 2–45†	9·7* 1½–20†
Asbestosis alone	4	9	30·0* 18–42†	21·5* 13–33†	19·3* ½–42†	7·2* 3–17†

* Average. † Range.

of the 4 women with lung cancer was only about nine and three-quarters years whereas the average period from first exposure to death was twenty-five years, suggesting that time of exposure is not the most important factor in the development of lung cancer. Merewether (1947) also noted that the average age of death with asbestosis and carcinoma of lung was about fifty-two years against about forty-four years for those with asbestosis alone, though there was little difference in the duration of exposure. Hueper (1951) draws the conclusion that many of these patients die from asbestosis before their lung cancers have time to develop.

As in other reported series, there is no great preponderance of any one cell type. Of 15 lung cancers, 5 were squamous, 8 anaplastic, and in 2 others the type was not stated. It is worth noting that the 4 women with lung cancer were all nonsmokers.

Asbestosis and Peritoneal Cancer

Leicher (1954) reported the case of a 53-year-old asbestos worker who had suffered from asbestosis complicated by pulmonary tuberculosis for several years, and who died in 1952 from tuberculous meningitis. At necropsy, the peritoneum was found to be studded with nodules of growth and there were plaques of growth over the peritoneal aspect of the diaphragm. This was thought to be a "primary cornical cell tumour of the peritoneum". No typical asbestos bodies or fibres were seen in the tissues of the tumour, but asbestos was demonstrated [illegible] Bonser et al. (1955) appear to have had in the [illegible] reference to a high [illegible] of abdominal [illegible] associated with [illegible] Of their series of 35 cases, 9 (3 men and [illegible] lung cancers [illegible] and 2 women, 2 [illegible] Bonser [illegible]

TABLE IV—CAUSES OF DEATH OF 15 MEN AND 15 WOMEN WITH ASBESTOSIS

—	Men	Women
Ovarian or peritoneal cancer ..	1	9 (60%)
Carcinoma of lung	10 (67%)	4 (26%)
Pneumonia	2	..
Other causes	2	2

In the present series, 9 of 15 deaths in women were associated with ovarian or peritoneal cancer, an incidence of 60%. In one case (no. 5) the diagnosis was only clinical, and there was nothing in the history or examination to incriminate any particular organ as the site of the primary lesion. In the remaining 8 cases, either laparotomy or postmortem examination was performed. Only 1 (case 1) had a definite ovarian neoplasm without peritoneal involvement. In every other case there was diffuse peritoneal growth with ascites. In 4, the pelvis contained a mass of growth and the ovaries were not identified. In 2 other cases, the ovaries were said to be studded with growth but were not, apparently, the site of the primary lesion; in 1 case the ovaries were cystic but not involved by growth.

Case 24 was the only man to show a similar picture of diffuse peritoneal cancer. An intensive examination revealed no macroscopic evidence of a primary growth, but subsequent microscopy showed bronchial epithelial hyperplasia in the right lower lobe, and tumour-cells in a hilar lymph-node. In addition, there was a solid trabecula of growth extending through the diaphragm, which may have arisen on either the pleural or the peritoneal aspects. In this case, and in case 9 where plaques of growth were also found on both aspects of the diaphragm, the possibility of a missed bronchial primary is more difficult to refute.

It is possible that these cases do not represent a new pathological entity but are all cases of secondary carcinoma from bronchial primaries. The occurrence of secondary deposits from bronchial carcinoma, many months before there is clinical or radiological evidence of the primary lesion, is familiar to all. Even at necropsy, a small primary growth in the wall of a peripheral bronchus is easily missed unless specifically sought. The absence of clinical or radiological evidence of lung cancer in the 10 cases of peritoneal cancer described does not eliminate this possibility, nor will the negative record of such a primary entirely convince the sceptical. Yet the findings differ from those usually associated with carcinomatosis from lung cancer in which it is common to find deposits in liver, adrenals, and kidneys, but most unusual to see diffuse peritoneal involvement without such deposits. However, Bonser et al. (1955) and Bonser (1959) attach importance to the plaques of hyaloserositis tethering the base of the lung to the upper surface of the diaphragm in many cases of asbestosis, as in case 9 and case 24 of this series. They consider that the consequent alteration of lymphatic drainage of the region offers a means of spread to the abdomen of cancer arising in sequestrated bronchial epithelium. On the other hand, this explanation is difficult to relate to the predominance of women in the present series, since lung cancer is commoner among the men.

2 of Bonser's 3 patients with asbestosis and peritoneal cancer were thought to have primary ovarian growths. Case 1 of this series was [illegible] at [illegible], and in 4 others, the ovaries were [illegible] a mass of growth filling the pelvis and [illegible] the site of the primary lesion. In all [illegible] histological [illegible] was possible [illegible] and this has been

the diagnosis in most cases. In spite of this, and of the fact that all but one of the cases in this series have been women, some doubt must be cast on this diagnosis. In 3 cases in which the ovaries were identified they appeared not to be the primary site, and, though ovarian carcinoma is the commonest cause of undifferentiated peritoneal cancer in women, it is possible that these organs have become a dumping-ground for other cases of "carcinomatosis peritonei" in which no definite primary can be demonstrated.

Wyss (1953) reported the findings of asbestos fibres in the urine of patients with asbestosis. Stovin (1959) found asbestos bodies in the thyroid of case 38, at necropsy, and Bonser (1959) states that asbestos fibres were found in the spleen of one of Stewart's cases of asbestosis. These were chance findings and it is possible that more diligent search, such as that of Leicher (1954), might produce further evidence of a hæmatogenous spread of asbestos fibres and their eventual deposition in extrapulmonary tissues. It is beyond the scope of this article to review the evidence for "chemical" versus "mechanical" carcinogenesis in asbestosis, but there is much support for the former concept. If this be accepted, it is conceivable that peripherally deposited asbestos may provoke local neoplastic change. McLaughlin (1959) has described a carcinoma on a doctor's finger at the site of penetration by asbestos fibres.

It remains to be explained why the peritoneum should be so frequently involved without any reported increase in other extrapulmonary neoplasms. Primary mesothelial tumours are rare, and even the concept of "pleural mesothelioma" has now been largely abandoned in favour of lymphatic spread from an underlying bronchial neoplasm or primary growth elsewhere (Smart and Hinson 1957, Hinson 1958). Hugh-Jones (1960), however, suggests that this type of tumour is more common in patients with asbestosis. Vorwald et al. (1951) suggested a mechanical factor, related to length of fibre, in the production of asbestosis; and in the course of their experiments on rats were able, by injecting asbestos fibres, to produce a fibrotic reaction in the peritoneum, but not in liver, spleen, or subcutaneous tissues. They attributed this to movement taking place between peritoneal surfaces. It has been suggested that such fibrosis may play a part in the development of neoplastic changes, and this is supported by the recent work of Menkin (1960), who produced evidence of a growth-promoting factor in inflammatory exudates and suggested that this may act as a cocarcinogen. Such a factor, together with the "chemical" factor in asbestos, may determine selection of the peritoneum as the site of tumour-formation following the transdiaphragmatic or hæmatogenous spread of asbestos fibres. To support this theory it would be necessary to demonstrate the earlier stage of peritoneal inflammation in patients with uncomplicated asbestosis. The further difficulty of the great predominance of women with peritoneal cancer in this series might be explained by the greater disposition of men to lung cancer, whether this be related to sex, associated bronchitis, smoking habits, or air pollution. It will be seen that the average period after first exposure for the 14 patients with lung cancer was under twenty-five years compared with thirty years for the group with peritoneal cancer.

It is clear that no single satisfactory explanation for these cases can be drawn from the available material, though they appear to form a clinical entity of statistical significance.

2 cases in this series require further comment. In case 6 there was a clear history of exposure to absestos dust, and her sputum contained asbestos bodies thirty-three years after exposure ceased. In spite of this, she had no chest symptoms; X-rays of her chest showed no definite abnormality, and she could not be said to have asbestosis. From the clinical course and operative findings there can be little doubt that she had peritoneal cancer. In a similar way case 27 developed lung cancer with asbestos bodies in his sputum twenty years after removal from exposure to asbestos dust, without any intervening symptoms or radiological changes to establish a diagnosis of asbestosis. Clearly the question of chemical carcinogenesis, whether it be due to the asbestos itself or to some product of its reaction with the tissues, is of medicolegal interest in these cases. In the past, Hueper (1951) has commented on "the apparent dependence of cancerous changes in the lungs of asbestos workers upon the presence of asbestosis".

Summary

23 female and 19 male cases of asbestosis are summarised with details of type and duration of exposure, period since first exposure, and associated disease.

Of 30 deaths (15 men, 15 women), there were 14 who died with lung cancer—10 in men and 4 in women. This high incidence among the men is partly explained by selection, but this does not apply to the women, who were all non-smokers.

9 women and 1 man died with ovarian or peritoneal cancer. This appears to be more than a chance association, and spread from undiagnosed lung cancer seems unlikely. At least four of the tumours were not of ovarian origin. Some evidence of hæmatogenous spread of asbestos fibres is adduced, and it is suggested that a combination of mechanical and chemical factors may determine the peritoneum as the site of inflammatory and subsequent neoplastic change.

Attention is drawn to the occurrence of bronchial carcinoma in one patient and of peritoneal cancer in a second. The sputum of both patients contained asbestos bodies many years after removal from exposure, but there was no other evidence of asbestosis.

I am indebted to Dr. K. M. A. Perry, Dr. A. I. G. McLaughlin, Prof. D. S. Russell, and Dr. G. M. Bonser for much advice and criticism in the preparation of this article. Dr. P. G. Stovin of the Bernhard Baron Institute of Pathology at the London Hospital kindly provided the photomicrographs, and was responsible for many of the pathology reports.

REFERENCES

Braun, D. C., Truan, T. D. (1958) *A.M.A. Arch. indust. Hlth*, 17, 634.
Bonser, G. M. (1959) Personal communication.
— Faulds, J. S., Stewart, M. J. (1955) *Amer. J. clin. Path.* 25, 126.
Departmental Committee on Compensation for Industrial Diseases. Minutes of Evidence, Appendices and Index, 1907. Cmd 3496; p. 127; Report Cmd 3495; p. 14. H.M. Stationery Office.
Doll, R. (1955) *Brit. J. indust. Med.* 12, 81.
Gloyne, S. R. (1951) *Lancet*, i, 810.
Hinson, K. F. W. (1958) Carcinoma of Lung; p. 130. London.
Hugh-Jones, P. (1960) *Brit. med. J.* i, 1351.
Hueper, W. C. (1951) *Industr. Med.* 20, 49.
— (1952) Occupational and Environmental Pulmonary Cancer with Special Reference to Pneumoconiosis. Proc. of the Seventh Saranac Symposium on Pneumoconiosis.
— (1955) Public Health Monograph no. 36. U.S. Public Health Service.
Jacob, G., Bohlig, H. (1955) *Arch. Gewerbepath. Gewerbehyg.* 14, 10.
Leicher, F. (1954) *ibid.* 13, 382.
Lynch, K. M., Smith, W. A. (1935) *Amer. J. Cancer* 24, 56.
McLaughlin, A. I. G. (1959) Personal communication.
Meissner, V. (1960) *Brit. med. J.* i, 1585.
Merewether, E. R. A. (1930a) *J. Industr. Hyg.* 12, 198.
— (1930b) *ibid.* 12, 205.
— (1947) Annual Report of the Chief Inspector of Factories. H.M. Stationery Office.
— Price, C. W. (1930) Report on the Effects of Asbestos Dust on the Lungs and Dust Suppression in the Asbestos Industry. H.M. Stationery Office.
Stewart, J., Hinson, K. F. W. (1957) *Brit. J. Radiol.* 30, 315.
Stovin, P. G. (1959) Personal communication.
Vorwald, A. J., Durkan, T. M., Pratt, P. C. (1951) *Arch. indust. Hyg.* 3, 1.
Wyss, O. (1951) *ibid.* 3, 610.
Wyss, V. (1953) *Acta Anat.* 20, 51.

van een zodanige grootte waren, dat ze [illegible] bronchusboom konden passeren, zodat het pa[illegible] werking pas in de perifere longdelen plaats [illegible] men zich voorstellen, dat de pleura-afwijkingen [illegible] beheersten.

Patient *C* (Dr. SCHORNAGEL) was een isoleerder van 57 jaar van wie niet bekend is, hoelang hij in de isolatie-industrie had gewerkt. Zijn ziektegeschiedenis is korter en toont ook weinig overeenkomst met beide vorige gevallen. Een half jaar vóór zijn overlijden klaagde patiënt over hevige pijn rechts-boven in de buik, waarbij er aanvankelijk geen organische afwijkingen werden aangetroffen. Er waren geen klachten over de luchtwegen. Gedurende het verblijf in het ziekenhuis ontstond er echter een demping in het onderveld van de rechter long en werd er onder de rechter ribbenboog een tumor palpabel. Uit de rechter pleuraholte werd een weinig vocht gepunteerd, waarin maligne cellen werden aangetoond van niet nader aan te duiden herkomst. De patiënt overleed na enkele maanden onder het beeld van cachexie.

Bij de obductie werd een fibrosarcoom gevonden, dat de onder- en middenkwab van de rechter long omgaf, en het diafragma doorwoekerde tot diep in de lever. Er was slechts een matig aantal asbestlichaampjes in de longen.

Een lange reeks van casuistische mededelingen over het samengaan van asbestosis en bronchuscarcinoom leidde tenslotte tot een algemene aanvaarding van de zienswijze, dat asbest als een bevorderende factor moest worden beschouwd voor het ontstaan van longkanker. Asbest, dat uit magnesiumsilicaat bestaat, bevat geen kankerverwekkende stoffen, zodat de carcinogene werking van de ingeademde asbestvezeltjes aan chronische mechanische irritatie wordt toegeschreven. In overeenstemming hiermede is dan ook, dat het carcinoom zich ontwikkelt in de longdelen waarin de asbestlichaampjes het meest geconcentreerd zijn; in het algemeen dus in de onderkwabben; bovendien in de omgeving van het diafragma en de overige perifere longgedeelten, waarop de asbestvezels de sterkste prikkeling uitoefenen, omdat daar de sterkste ventilatie plaatsheeft.

Uit het feit, dat bij asbestosis pulmonum zelden een sterke *pleuraverdikking, tot zwoerdvorming toe,* ontbreekt, mag men aannemen, dat de mechanische irritatie door de asbestvezels op zijn minst genomen bijdraagt tot de verdikking van de pleurabladen.

In de bovenbeschreven gevallen werden in geen van de talrijke coupes asbestvezeltjes aangetroffen in het lumen van bronchi of bronchioli. Ook ontbraken er metaplastische afwijkingen aan het bronchusepitheel, zoals dat door HAMPE in 1952 bij een lijder aan asbestosis pulmonum met longcarcinoom zo duidelijk werd gedemonstreerd. Neemt men nu aan, dat de afmetingen van de geïnhaleerde asbestvezeltjes

Deze overwegingen leidden ertoe, de [illegible] tussen asbestosis en longcarcinoom door te [illegible] pleuragezwellen. Hierin werden wij gesterkt door het onderzoek van DOLL, gepubliceerd in 1955, waarin hij [illegible] tische gronden bewijst, dat de gemiddelde kans [illegible] kanker bij asbestarbeiders, die hun beroep gedurende of meer jaren hebben uitgeoefend, tien maal zo groot [illegible] de bevolking in het algemeen. Zijn tabel, die [illegible] histologische diagnosen vermeldt, bevat één geval [illegible] ra-endothelioom, en hij noemt dus deze pleurata[illegible] één adem met de longgezwellen.

Blijkens de gegevens van de centrale dienst der [illegible] inspectie komt asbestose verreweg het meest voor [illegible] westen van ons land, waar de asbestverwerkende [illegible] industrie is gevestigd. Hierin zijn honderden a[illegible] werkzaam. Nauwkeurige gegevens omtrent het voo[illegible] van asbestose zijn thans nog niet beschikbaar, maar [illegible] nomen mag worden, dat ongeveer 20 pct van de arb[illegible] min of meerdere mate aan asbestose lijden. Het tegenw[illegible] de verspreiding van het asbeststof schijnt een [illegible] technisch probleem te zijn.

Discussie:

Dr. VAN DER ZALM vestigt de aandacht op een [illegible] thelioom van de pleurakoepel, dat werd waargenomen [illegible] silicose met pseudotumorvorming. Zijn in de literatuur [illegible] van dergelijke gevallen bekend?

VAN DER SCHOOT antwoordt: In de door mij [illegible] pleegde literatuur heb ik geen publikaties kunnen [illegible] die verband legden tussen pleuragezwellen en een [illegible] van pneumoconiose. De betrekking tussen silicose [illegible] cinoom is beslist minder duidelijk dan tussen a[illegible] en carcinoom.

Dr. SCHORNAGEL: Kortelings obduceerde ik [illegible] overleden patiënt met asbestose, die echter een [illegible] lioom van het peritoneum had. Zoudt U een verband [illegible] leggen tussen deze asbestose van de long en het peri[illegible] gezwel? Patiënt was isoleerder en heeft tijdelijk in A[illegible] in een atoomfabriek gewerkt.

VAN DER SCHOOT antwoordt: Indien er is vastgest[illegible] er in de thorax geen gezwelweefsel voorkwam, en het [illegible] het diafragma niet heeft doorgroeid, lijkt mij het v[illegible] tussen beide ziekteprocessen moeilijk te leggen.

I. S. LEVY en Dr. A. SCHABERG, *Correlaties t[illegible] peptische afwijkingen aan maag en duodenum en andere z[illegible]*

Bij het Rotterdamse obductiemateriaal werd een on[illegible] verricht naar mogelijke correlaties tussen peptis[illegible] wijkingen en andere ziekten. Het obductiemateriaa[illegible] verzameld tussen mei 1940 en januari 1956. Het [illegible] 4354 mannen en 3340 vrouwen bij wie geen ulcus pe[illegible] als doodsoorzaak werd gevonden. Bij 1030 van deze [illegible] ties kwamen chronische peptische afwijkingen vo[illegible] 398 acute peptische afwijkingen. Voor elke ulcuspatiën[illegible] uit het obductiemateriaal een controlepatiënt zonde[illegible] tische afwijking genomen, die van gelijk geslacht en[illegible] leeftijd was, en die in hetzelfde jaar was overled[illegible] waren dus 4 groepen, te weten 1030 patiënten met chr[illegible] peptische afwijkingen met 1030 controles, en 398 pa[illegible] met acute peptische afwijkingen met 398 contro[illegible] deze 4 groepen werden allen bij de obductie gevonden [illegible] genoteerd.