Hydropericardium and Ascites in Chicks Fed a Chlorinated Hydrocarbon*

E. L. McCune, J. E. Savage and B. L. O'Dell
Departments of Veterinary Bacteriology, Poultry Husbandry and Agricultural Chemistry, University of Missouri, Columbia, Missouri

(Received for publication May 3, 1961)

An epoxy-resin paint† has been used in our laboratory to coat galvanized batteries employed for trace mineral studies. This paint was supplied as two separate fractions which were mixed just prior to use. One portion contained the epoxy monomer and the other the amine hardener which catalyzed polymerization. On one occasion the paint did not harden before chicks were placed in the battery and within 3 weeks the chicks showed symptoms closely resembling those of the "chick edema" or "toxic fat" syndrome described by Schmittle *et al.* (1958) and Sanger *et al.* (1958). Because of the interest in the chemical nature of the toxic factor (Brew *et al.*, 1959; Friedman *et al.*, 1959; Wooton and Alexander, 1959; Harman *et al.*, 1960) that has been observed in feed-grade fats and the lipid origin of certain components of the paint, it seemed worthwhile to investigate further the causative agent in the epoxy-resin paint.

EXPERIMENTAL

Groups of ten, straight-run, Vantress-White Rock, cross-bred chicks were placed in electrically heated batteries at hatching and allowed to consume the experimental rations *ad libitum* for a four-week period. They were weighed weekly and examined daily for gross symptoms. All chicks were autopsied at death and at least two individuals per group were selected during the third and fourth weeks for histological examination of liver, kidney, heart, lung and spleen. The tissues were processed in the routine manner for histological examination and were stained with hematoxylin and eosin.

The basal ration was a practical-type broiler ration composed of soybean oil meal 36%, yellow corn 59.5%, $CaHPO_4$ 2%, limestone 1.3%, iodized salt 0.5%, methionine 0.1%, a trace mineral mixture and a vitamin supplement. The various paint fractions were dissolved in isopropyl alcohol and added to the mixed ration. Since some of the components were slightly volatile, the feeds were stored in closed containers and kept under refrigeration. Small portions were placed in the feeders daily.

RESULTS

In a preliminary trial the two fractions of the paint, the amine hardener and the epoxy monomer, were tested at a level of 0.1%. One-half of the chicks that received the amine hardener died whereas the other group lived and grew at a normal rate. From this test it was clear that the toxic substance was associated with the amine hardener. According to the manufacturer this fraction contained isopropyl alcohol, polyamid (made from diethylenetriamine and dimerized fatty acids), tri-dimethyl-

* Contribution from the Missouri Agricultural Experiment Station, Journal Series No. 2295.

† The paint (Epo Floor Top) was obtained from the Steelcote Manufacturing Co., St. Louis, Missouri. We gratefully acknowledge the assistance of Mr. A. G. Sternberg of this company who kindly supplied the various fractions tested.

DSW 312418

STLCOPCB4072404

Table 1.—*Toxicity of various components of the amine hardener*

Substance fed		3 weeks		4 weeks	Gross pathology
Name	Level	Weight	Mortality	Mortality	
	%	g.	%	%	
Isopropyl Alcohol	2.0	290	0	0	None
Amine Hardener	0.1	219	20	60	Hydropericardium; lungs hemorrhagic and edematous; kidneys and liver swollen
Chlorinated Biphenyl	0.1	106	90	90	Similar to amine hardener
Diethylenetriamine	0.1	288	0	0	Slight enteritis; kidneys slightly swollen
Tri-dimethylamino-methylphenol	0.1	234	0	0	Liver and kidneys enlarged. No edema
Dimerized Fatty Acids	0.1	336	0	0	None
Polyamid	0.1	318	0	0	None

aminomethylphenol, and a chlorinated biphenyl (Aroclor 1242) which contains about 42% chlorine. The chlorinated biphenyl was added as a plasticizer and is not an essential component of the paint.

These fractions were tested and the results are summarized in Table 1. It is clear from these results that the major toxic agent was the chlorinated biphenyl. Diethylenetriamine, which is considered to be highly toxic to man, had relatively little effect on the chick although it did cause slight liver and kidney damage. Feed consumption was not measured but it may be assumed that these chicks which had an average weight of 440 grams at 4 weeks consumed about 800 grams of feed and 0.8 grams of diethylenetriamine. Tri-dimethylaminomethylphenol caused some liver and kidney damage and depressed the rate of gain, but was not severely toxic. The dimerized fatty acids and the product (polyamid) that results from dimerized fatty acids and diethylenetriamine showed no gross evidence of toxicity.

In order to determine the degree of toxicity of the chlorinated biphenyl it was fed at graded levels. It was also fed with polyamid to determine whether or not there was a potentiating effect from this component. The results are summarized in Table 2. When chlorinated biphenyl was fed at 0.01% there was only slight evidence of toxicity. At the 0.02% level typical symptoms of the "toxic fat" syn-

Table 2.—*Toxicity of chlorinated biphenyl (Aroclor 1242)*

Substance fed		3 weeks		4 weeks	Gross pathology
Name	Level	Weight	Mortality	Mortality	
	%	g.	%	%	
Chlorinated Biphenyl	0.01	306	0	0	Slight
Chlorinated Biphenyl	0.02	317	0	0	Hydropericardium
Chlorinated Biphenyl	0.04	237	10	50	Hydropericardium; hemorrhage of internal organs; liver enlarged and mottled; enteritis
Chlorinated Biphenyl	0.08	160	50	90	Hydropericardium; hydroperitoneum; enlarged heart; enteritis; kidney and liver damage
Polyamid	0.10	340	0	0	No pathology
Polyamid + Chlorinated Biphenyl	0.10 + 0.04	259	40	70	Hydropericardium

DSW 312419

STLCOPCB4072405

drome such as distended abdomen and labored respiration were evident, but there was no mortality during the four-week test period. At necropsy hydropericardium was evident. The 0.04% level produced symptoms resembling those observed among chicks fed 0.1% level of the amine hardener fraction. Feeding the polyamid along with chlorinated biphenyl did not change the results appreciably.

Gross Pathology. The gross pathology produced by chlorinated biphenyl closely resembled that observed in the "chick edema" syndrome. Losses usually started during the third week and reached major proportions during the fourth week. Before death the chicks exhibited symptoms of labored respiration with rales and in some cases the abdominal cavity was distended with fluid. At necropsy the most striking pathology was hydropericardium as illustrated in Figure 1. The crop of several birds contained bloody fluid. The kidneys were swollen and pale in most chicks but in the advanced stages many were hemorrhagic. The liver was sometimes enlarged and mottled in appearance. The lungs were commonly hydropic and hemorrhagic. A yellow, jelly-like fluid was frequently found under the skin and within body cavities. A large amount of fibrin was often present in this fluid.



FIG. 1. Hydropericardium observed in a chick fed 0.02% of chlorinated biphenyl for 4 weeks.



FIG. 2. Tubular dilatation in kidney of a chick fed 0.1% of chlorinated biphenyl. H and E stain (100×).

Histopathology. Chlorinated biphenyl at the 0.1% level caused severe renal tubular dilatation with numerous casts especially near the surface of the kidneys. Figure 2 illustrates the typical kidney damage and Figure 3 is a photomicrograph from a control kidney. The majority of the casts were basophilic, but appeared to be made up of strands resembling fibrin. Many of these basophilic bodies contained smaller homogenous eosinophilic bodies suggestive of amyloid. The damage was concentrated largely in the smaller collecting tubules.

The liver had a few areas of lymphocyt-

DSW 312420

STLCOPCB4072406

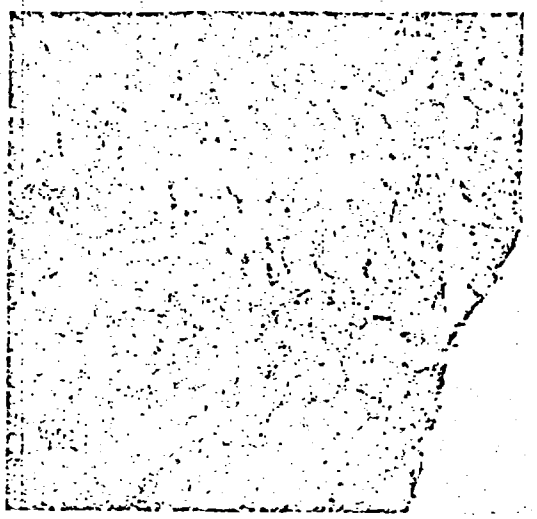

Fig. 3. Kidney from control chick. H and E stain (100 X).

ic infiltration which was observed chiefly around the smaller blood vessels. The severity of the liver lesions varied with individual birds, but tended to be directly related to the level of chlorinated biphenyl. The damage to liver and kidney observed in chicks fed the 0.01% level was of only questionable significance.

The heart showed chiefly mechanical dilatation. A few areas of infiltration of lymphocytes and heterophils had occurred between the muscle fibers.

The microscopic lesions produced by 0.1% of the amine hardener were similar to those produced by chlorinated biphenyl but additional lesions were observed. These included cellular casts in the renal convoluted tubules, glomerular atrophy, and mild tubular necrobiosis. Some kidneys showed glomerular congestion, glomerular vacuolization and hyaline infiltration, and small areas of interstitial nephritis.

The livers of chicks fed the amine hardener showed general toxic degeneration. The most frequent lesion was bile duct proliferation with an increased number of reticular cells and heterophils. The parenchymal cells showed generalized fatty degeneration. Cord cell atrophy, reduced amounts of lymphoid tissue, and irregular accumulations of lymphocytes and heterophils were present in some chicks. The results suggest that the amine hardener was somewhat more toxic than the chlorinated biphenyl alone. The product of dimerized fatty acids and diethylenetriamine (Polyamid) produced microscopic lesions similar to those caused by a low level of the amine hardener. These consisted of hepatic cord cell vacuolization and a few dilated renal tubules containing faintly eosinophilic casts. There was a slight increase in the groups of large basophilic cells commonly found in the kidney.

DISCUSSION

The symptoms and gross pathology observed in birds fed chlorinated biphenyl can not be distinguished from those described for the "toxic fat" syndrome (Schmittle *et al.*, 1958). The microscopic lesions were similar to those described by Sanger *et al.* (1958), but there were differences, at least in degree. In the case of chlorinated biphenyl the renal tubules and bile ducts were more severely damaged and less hepatic necrosis had occurred. The lesions observed in this study bear a strong resemblance to those produced by coal-tar creosote (Bullis and Van Roekel, 1944).

The fact that it is not possible to distinguish between the syndromes produced by "toxic fat" and chlorinated biphenyl suggests that the toxic compounds are similar in nature. On the other hand, it is recognized that many different toxic compounds produce similar symptoms in the chick. The chlorinated biphenyl fed in this investigation was far less toxic than the crystalline compound isolated by

DSW 312421

STLCOPCB4072407

Harman *et al.* (1960). It is possible that the toxic component of the chlorinated biphenyl product used here is a contaminant rather than the major component.

Although the toxicity of some chlorinated hydrocarbons has been studied in poultry, the pathology involved has received little attention. Pudelkiewicz *et al.* (1958) observed that a mixture of penta- and hexa-chloronaphthalenes caused high mortality in poults but there was no accumulation of fluid in body cavities.

Hydropericardium and ascites in chicks can be caused by a variety of compounds, the most common cause under practical conditions being excessive amounts of sodium chloride. Gordon *et al.* (1959) observed that a fat-soluble substance in blood meal caused a syndrome resembling the "toxic fat" syndrome. Excess salt increased the incidence of the disease in the presence but not in the absence of the fat-soluble factor. Accumulation of fluid results when the kidney fails to maintain normal water balance either because of excess electrolytes or because of kidney damage. Chlorinated biphenyl causes estensive kidney damage and ascites is probably a secondary result.

SUMMARY

Chicks fed fractions of an epoxy-resin paint developed hydropericardium and ascites. These symptoms were similar to those observed in the "toxic-fat" syndrome. The toxicity was found to be caused by a chlorinated biphenyl product used as a plasticizer in the paint.

Chlorinated biphenyl was moderately toxic when fed at a level of 0.02% and caused high mortality and extensive pathology within 4 weeks at a dietary level of 0.04%. Gross pathology included hydropericardium, hydroperitoneum, enlarged heart, liver and kidneys, and hemorrhage of internal organs. Microscopically the kidneys showed marked tubular dilatation and numerous casts.

REFERENCES

Brew, W. B., J. B. Dore, J. H. Benedict, G. C. Potter and E. Sipos, 1959. Characterization of a type of unidentified compound producing edema in chicks. J. Assoc. Offic. Agr. Chemists, 42: 120–128.

Bullis, K. L., and H. Van Roekel, 1944. Uncommon pathological conditions in chickens and turkeys. Cornell Vet. 34: 313–319.

Friedman, L., D. Firestone, W. Horwitz, D. Banes, M. Anstead and G. Shue, 1959. Studies of the chick edema disease factor. J. Assoc. Offic. Agr. Chemists, 42: 129–140.

Gordon, R. S., R. A. Mulholland, L. J. Machlin and K. H. Maddy, 1959. Hydropericardium and ascites caused by excess salt and a factor in blood meal. Poultry Sci. 38: 1209.

Harman, R. E., G. E. Davis, W. H. Ott, N. G. Brink and F. A. Kuehl, 1960. The isolation and characterization of the chick edema factor. J. Am. Chem. Soc. 82: 2078.

Pudelkiewicz, W. J., R. V. Boucher, E. W. Callenbach and R. C. Miller, 1958. Some physiological responses of Broad Breasted Bronze poults to chlorinated napthalene. Poultry Sci. 37: 185–187.

Sanger, V. L., L. Scott, A. Hamdy, C. Gale and W. D. Pounden, 1958. Alimentary toxemia in chickens. J. Am. Vet. Med. Assoc. 133: 172–176.

Schmittle, S. C., H. M. Edwards and D. Morris, 1958. A disorder of chickens probably due to a toxic feed-preliminary report. J. Am. Vet. Med. Assoc. 132: 216–219.

Wooton, J. C., and J. C. Alexander, 1959. Some chemical characteristics of the chick edema disease factor. J. Assoc. Offic. Agr. Chemists, 42: 141–148.

AUGUST 10–18. TWELFTH WORLD'S POULTRY CONGRESS SYDNEY, AUSTRALIA

SEPTEMBER 18–21. FIRST INTERNATIONAL CONGRESS OF FOOD SCIENCE AND TECHNOLOGY, IMPERIAL COLLEGE OF SCIENCE AND TECHNOLOGY, LONDON, ENGLAND

DSW 312422

STLCOPCB4072408