Toxicity of Chlorinated Hydrocarbons and Related Compounds

A Review Including Chlorinated Dibenzodioxins and Chlorinated Dibenzofurans

Renate D. Kimbrough, M.D., Chamblee, Ga

Various chlorinated technical compounds, namely, 2,4,5-trichlorophenol, 2,4,5-trichlorophenoxyacetic acid (2,4,5-T), and European chlorinated biphenyls (Phenoclor DP6 and Clophen A60), have been found to be contaminated with trace amounts of chlorinated dibenzofurans or chlorinated dibenzodioxins. Toxic fat which produces hydropericardium in chickens also contains chlorinated dibenzodioxins. These and other technical chlorinated compounds such as the technical pentachlorophenol have been implicated in causing chloracne, liver disease, teratogenicity, x-disease in cattle, and chick edema. The literature on the toxicity of the chlorinated technical compounds is reviewed. It is mentioned that 2,4,5-T and the chlorinated biphenyls also induce porphyria. Whether the various disease entities are caused by the contaminents, combinations of the chemical and its contaminants or by the chemicals themselves needs further evaluation.

RECENTLY several chlorinated compounds, such as the polychlorinated biphenyl and 2,4,5-trichlorophenoxyacetic acid (2,4,5-T), have received a great deal of attention. Polychlorinated biphenyls (PCB) are increasingly found in our environment and 2,4,5,-T has been used extensively as an herbicide. Occasionally these and other chlorinated technical compounds have caused diseases that bear similarity to each other.

Some of these chemicals have been found to be contaminated with chlorinated dibenzofurans or chlorinated dibenzodioxins. The various diseases produced by one or more of the different technical compounds are discussed in this paper. Attention is focused on the various contaminants and their possible relationship to different diseases in a variety of species. The need for further well-coordinated epidemiological and experimental animal studies is pointed out.

Submitted for publication Oct 8, 1971; accepted March 3, 1972.

From the Chamblee Toxicology Laboratory, Environmental Protection Agency, Chamblee, Ga.

Reprint requests to Chamblee Toxicology Laboratory, Environmental Protection Agency, 4770 Buford Hwy, Chamblee, Ga 30341 (Dr. Kimbrough).

Chloracne

This disease is described by the formation of comedones with or without cysts and pustules. The follicular orifices are filled with sebaceous and keratinous material. Melanosis and a secondary inflammatory reaction may exist. Chloracne was described for the first time by Herxheimer[1] in 1899 who thought it was produced by free chlorine. Wauer[2] in 1918 and Teleky[3] in 1927 suggested the term "pernakrankheit." They felt that this skin disease was produced by certain chlorinated hydrocarbons. Jones and Alden[4] were among the first to report a case of chloracne in a 26-year-old male Negro who worked for three years distilling chlorinated biphenyls. This patient also complained of lassitude, loss of appetite, and loss of libido.

Chloracne is one of the most frequent forms of occupational dermatitis, and many cases have been reported in the United States as well as in Europe, particularly Germany and England.

Teleky[5] reported in 1949 that he personally had seen at least "150 to 280 workers" in four different factories with chloracne. He stated that liver disease occurs independently from chloracne, and usually manifests itself after an exposure time of four to six months, but may occur in as short a time as seven weeks. Occasionally loss of appetite, nausea, and edema of the face and hands are the first symptoms. Abdominal pain and vomiting follow, and then jaundice develops. At autopsy, acute yellow atrophy of the liver is found. He cites Flinn and Jarvik[6] who reported cases of acute yellow atrophy with fatal outcome following exposure to Halowaxes. Halowaxes, which are chlorinated naphthalenes, as well as the PCB (Aroclors) were increasingly used after 1930 to insulate cables. Teleky[5] cites many other case reports (Drinker et al,[7] Jones,[8] Greenburg et al,[9] Cotter,[10] McLechtchie and Robertson,[11] and Collier[12]). Von Oettin-

MONS 084678

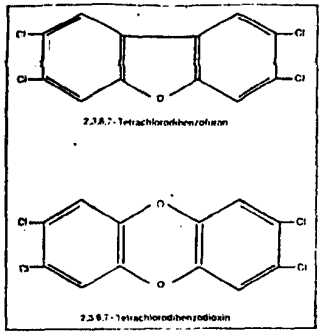

Chemical structure of a chlorinated dibenzodioxin and a chlorinated dibenzofuran.

gen[13(pp308-318)] describes the occurrence of chloracne in workers exposed to these chemicals. He cites several references which indicate that dermatitis is the result of the local effect or direct contact with the chemical, while the toxic hepatitis results from absorption.

Chloracne has been reported in workers exposed to chloronaphthalenes, chlorobiphenyls, chlorodiphenyloxides, certain petroleum products, and solid chlorophenols.[14] More recently Meigs et al[15] and Hofman and Meneghini[16] reported 14 and 13 cases of chloracne, respectively. Exposure to chlorinated biphenyls was established in most of these cases. Birmingham[17] observed chloracne in 15 employees who had painted flat sections of glass with enamel and then baked it. The enamel had Aroclor (a PCB) incorporated in it. Plewig[18] produced chloracne experimentally on the upper back of eight male adults by applying Halowax 1014, pentachloronaphthalene, and hexachloronaphthalene.

Bauer et al[19] reported chloracne in workers that handled technical 2,4,5-trichlorophenol. In some of these workers neuromuscular weakness, psychopathological changes, blepharoconjunctivitis, and liver involvement also occurred. Kimmig and Schulz[20] found that pure 2,4,5-trichlorophenol did not produce hyperkeratosis when applied to the rabbit ear. (The rabbit ear test is used as a screening test to determine whether a compound is likely to produce chloracne. The chemical, dissolved in propylene glycol, is painted on the rabbit ear. If the test is positive, erythema occurs within two days and in a few weeks hyperkeratosis develops.) The rabbit skin offers us an experimental method that will indicate the ability of substances to produce acneiform dermatitis in man.[21] Pure 2,4,5-trichlorophenol did not affect the rabbit ear, and neither did 1,2,4,5-tetrachlorobenzene, the starting material in the manufacture of 2,4,5-trichlorophenol. However, technical 2,4,5-trichlorophenol which was used in the production of 2,4,5-T did produce hyperkeratosis of the rabbit ear. It was concluded that by-products which had resulted during alkaline hydrolysis of 1,2,4,5-tetrachlorobenzene were the causative agents.

Kimmig and Schulz[20] isolated several contaminants and found that some of them, namely tetrachlorodibenzofuran (Figure) at a concentration of 0.05% as well as tetrachlorodibenzodioxin (Figure) at a concentration of 0.005%, produced hyperkeratosis in the rabbit ear. A hepatotoxic effect was also observed with these compounds. They also found that pure pentachlorophenol did not produce hyperkeratosis of the rabbit ear. Chloracne was observed in workers of a West German plant who produced technical pentachlorophenol from hexachlorobenzene.[22] The technical material also induced hyperkeratosis in the rabbit ear. It is possible that technical pentachlorophenol contains toxic impurities, particularly since pentachlorophenol is produced by alkaline hydrolysis from hexachlorobenzene. Dibenzodioxin and dibenzofuran themselves do not cause liver necrosis or hyperkeratosis when applied to the rabbit ear; however, they become highly toxic when they contain three or more chlorine atoms.[20] Some of the workers with chloracne also develop eye irritation, hepatotoxicity, intolerance to alcohol, neuromuscular symptoms, porphyria cutanea tarda, and psychologic alterations.[23] According to Braun,[24] chloracne seems to result from direct contact with the chemicals producing it. Crow,[20] on the other hand, points out that chloracne can also be produced by systemic absorption.

MONS 084679

X-disease

This disease in cattle was described by Olafson[26] in 1947. A few years later evidence was published showing that highly chlorinated naphthalenes caused the disease.[27] Cattle with x-disease show a rapid decline in vitamin A plasma levels. Symptoms of poisoning include excessive lacrimation, diarrhea, polyuria, marked salivation, and discharge from the nostrils. A chronic cough, poor appetite, and numerous red maculae in the buccal mucosa develop, and hyperkeratosis of the skin follows. Microscopic examination of autopsy material shows central lobular degeneration of liver cells with bile duct proliferation and dilation of the glands in the wall of the gallbladder. Cystic dilation of the collecting tubules of the renal cortex, with a moderate degree of fibrosis and degenerated cells in the pancreas, was also observed.[28] In sheep, necrosis and cirrhosis of the liver, damage to the nephrons, and squamous metaplasia of the endometrium were the principle findings after ingestion of feed containing highly chlorinated naphthalenes.[29] Huber and Link[30] fed hexachloronaphthalenes to young swine and produced degenerative lesions of the liver and kidneys and hyperplasia of the vaginal epithelium with keratin formation. A depression of the vitamin A plasma level was also observed.

Drinker and co-workers[7] found that the liver of rats was affected when the animals were fed high doses of tetrachloronaphthalene, pentachloronaphthalene, and hexachloronaphthalene or chlorinated biphenyls. When Schoettle et al[31] fed hexachloronaphthalene to rats, they observed mild to moderate fatty degeneration of the liver with centrilobular vacuolation of hepatic cells. Degenerative changes were observed in the kidneys and the skin showed hyperkeratosis.

It can be concluded from these reports that highly chlorinated naphthalenes produce liver changes in several species. In cows, x-disease of the skin, together with a drop in the vitamin A plasma level, is one of the leading manifestations of the disease. It is possible that the vitamin A deficiency represents a manifestation of concomitant liver disease.

Sikes et al[12] found that x-disease could be produced in cattle with highly chlorinated naphthalenes, but also with petroleum products such as crank case oil. The toxic products were excreted in the milk and produced x-disease in the calves drinking the milk. They cited other authors who were able to produce the disease with a complex wood preservative and a lubricant.

Bell[33] tested the ability of various compounds of the chlorinated naphthalene group to produce x-disease. He discovered that dichlorinated and trichlorinated naphthalenes did not produce the disease while tetrachloronaphthalene had an effect, and the higher chlorinated naphthalene, pentachloronaphthalene, hexachloronaphthalene, heptachloronaphthalene, and octachloronaphthalene, caused severe disease. Octachloronaphthalene was less toxic than hexachloronaphthalene and heptachloronaphthalene.

Chick Edema

In 1957,[34,35] a disease occurred in a large number of chickens which, at first glance, seemed to represent an epidemic. It was soon discovered that the residues of certain distilled animal fats produced the condition when they were added to the chicken diet.[36,37] The disease was called chick edema because it manifests itself with hydropericardium and ascites in chickens. Ducks and turkeys experience a reduction in growth.

Allen and Lalich[38] produced hydropericardium and ascites in chickens when enough toxic fat was given to kill most of the birds in five weeks. ("Toxic fat" is a term used for fat found in chicken feed that induces chick edema.) When the concentration of toxic fat was reduced and fed to the chickens for 150 days, hydropercardium and ascites developed less frequently, but testicular hypoplasia became apparent. Simpson et al[39] described proliferation and hypertrophy of the vascular endothelium and possible necrosis of hepatic and bile duct tissue in chickens and turkeys. When monkeys (*Macaca mulatta*) were fed toxic fat, alopecia, subcutaneous edema, decreased total serum protein (with a reversal in the albumin-globulin ratio), and reduced hematopoiesis and spermatogenesis developed. Gastric ulcers occurred in 66% of the animals. Focal areas of necrosis and degeneration were observed in the liver; and the bile duct epithelium was found to be affected when it was examined under the electron microscope. Dilata-

MONS 084680

Table 1.—Disease Resulting From Exposure to Technical Compound

Chlorosne	Pathological Findings of the Liver	Birth Defects and Lethal Factor	X-Disease in Cattle	Chick Edema
Certain petroleum products	Chlorinated naphthalenes	Certain technical 2,4,5-T	Highly chlorinated naphthalenes	Toxic fat*
Chloronaphthalenes (mainly penta, hexa, and hepta)	Chlorinated biphenyls	Purified material from toxic fat*	Petroleum products	Chlorinated biphenyl
Chlorobiphenyls	Technical 2,4,5-T and other chlorophenols	Polychlorinated biphenyls		Mixture of pentachl naphthalene and hexachloro-naphthalene
Chlorodiphenyloxides				
Chlorophenols (technical 2,4,5-trichlorophenol, pentachlorophenol)				
Technical 2,4,5-T				

* "Toxic fat" is a term used for fat found in chicken feed that induces chick edema.

tion of the heart and hypertrophy of the cardiac muscle were also present.[40]

Toxic fat is not the only product capable of producing the chick edema syndrome. Chlorinated biphenyl products, used as a plasticizer in a paint, have caused hydropericardium and ascites in chickens,[41] and two of seven Bengalese finches fed PCB developed hydropericardium.[42] The seven finches of a total of 56 birds died during the course of the experiment. A mixture of pentachloronaphthalene and hexachloronaphthalene, when fed to chickens, resulted in chick edema.[43] The toxic fat which contained the chick edema factor was studied intensively. Flick et al[44] separated a purified crystalline concentrate which produced chick edema and decreased the hatchability of injected eggs. Embryonic deformities were also produced. Flick et al[45] were not able to produce testicular hypoplasia in cockerels when they fed low doses of toxic fat (0.6% and 1.0%) to the cockerels for 12 weeks, as had been reported by Allen and Lalich.[36]

In 1967, Cantrell et al[46] reported that 1,2,3,7,8,9-hexachlorodibenzo-*p*-dioxin was one of the toxic compounds producing chick edema. Tomita et al[47] had shown earlier that the heating of pentachlorophenol produced octachlorodibenzo-*p*-dioxin. Higginbotham et al[48] showed that the chick edema factor represented chlorinated dibenzo-*p*-dioxins. The two principal compounds isolated were 2,3,7-trichlorodibenzo-*p*-dioxin and 2,3,7,8,-tetrachlorodibenzo-*p*-dioxin. The authors suggested, as a possible source of contamination, fats and fatty acids containing commercial chlorophenols. When crude fats and tallows are heated to produce fatty acids chlorophenol residues might be converted to a chick edema factor.

It was mentioned earlier in this article that the Aroclors can produce chick edema. The Aroclors (PCB) are used primarily as dielectric fluids for capacitors and transformers, as industrial fluids for hydraulic, for gas turbine and for vacuum pumps, and as heat transfer fluids. They are also used as plasticizers and are widely distributed in the environment.[49] Aroclor is a trade name under which these compounds are marketed in the United States. They can be found in synthetic resins, synthetic and natural rubbers, cellulose resins, paint varnish, wax, asphalt, and in allyl starch. They have been employed for dust prevention, moisture proofing, sealing, impregnation, and vapor suppression to prolong the residual life of insecticides. They increase the toxicity of dieldrin and DDT in insects.[50] Depending on the amount of chlorine they contain they are assigned certain numbers. Aroclor 1260 for instance, contains 60% chlorine, while Aroclor 1242 has an approximate chlorine content of 42%. Miller,[51] in 1944, tested a commercial chlorinated biphenyl with 42% chlorine and observed liver damage in rabbits, guinea pigs and rats. Skin changes were observed in the animals who received subcutaneous injections and application of the material to the skin. The skin lesions produced by subcutaneous injection were histologically similar to those of chloracne in man. Direct application to the skin produced inconsistent lesions compatible with low-grade irritation. Von Oettingen[13(pp306-307)] discusses some of the earlier work on the toxicity of the Aroclors in his book *The Halogenated Hydrocarbons, Toxicity and Potential Dangers*. Nishizumi[52] observed changes in the livers of mice and monkeys after feeding them chlorinated biphenyls. The author undertook this work because of an outbreak of poisoning that involved at least 600 people ingested rice bran inated with ch PCB (Kanechlor leaked into the holes in a pipe us manufacturing p mentation and brown pigment (born and newbo Stillbirths were of the mother. A orexia, fatigue, e like discharge fr and dark-brown

Vos and Koen several polychlo ens, quail and r the toxicity of polychlorinated and Clophen A which was prod The European toxicity and pro crosis. Chick ed with European Aroclor 1260. duced porphyric three compour benzofuran, pe hexachloronaph the European s from the Unite cardium occurr Aroclor 1260, t indicative of sn tor in this prep

Recently, Bi Bethesda, Md

MONS 084681

to Technical Compounds	
	Chick Edema
Toxic fat*	
Chlorinated biphenyls	
Mixture of pentachloronaphthalene and hexachloronaphthalene	

Table 2.—Toxic Contaminants Found in Some Technical Compounds*

2,4,5-trichlorophenol	Tetrachlorodibenzofuran Tetrachlorodibenzodioxin
2,4,5-T	Tetrachlorodibenzofuran Tetrachlorodibenzodioxin
Toxic fat	1,2,3,7,8,9 hexachlorodibenzo-p-dioxin 2,3,7 trichlorodibenzo-p-dioxin 2,3,7,8 tetrachlorodibenzo-p-dioxin
European chlorinated biphenyls (Phenoclor DP6 and Clophen A 60)	Tetrachlorodibenzofuran Pentachlorodibenzofuran Hexachloronaphthalene

* Listed in Table 1.

least 600 people in Western Japan who had ingested rice bran oil that had been contaminated with chlorobiphenyls, a Japanese PCB (Kanechlor 400). The chlorobiphenyls leaked into the rice bran oil through pinholes in a pipe used for heat exchange in the manufacturing process. An increase in pigmentation and abnormal grayish dark-brown pigment deposits in the skin of stillborn and newborn infants was observed.[53] Stillbirths were unrelated to PCB poisoning of the mother. Adults showed chloracne, anorexia, fatigue, edema of the eyelids, cheese-like discharge from the meibomian glands, and dark-brownish pigmented nails.[54]

Vos and Koeman[55] studied the toxicity of several polychlorinated biphenyls in chickens, quail and rats. The authors compared the toxicity of two European commercial polychlorinated biphenyls (Phenoclor DP6 and Clophen A60) and one (Aroclor 1260) which was produced in the United States. The European compounds showed higher toxicity and produced centrilobular liver necrosis. Chick edema was a common finding with European compounds and rare with Aroclor 1260. All three compounds produced porphyria. Chemical analysis of these three compounds revealed tetrachlorodibenzofuran, pentachlorodibenzofuran, and hexachloronaphthalene as a contaminant in the European samples but not in the sample from the United States.[56] Since hydropericardium occurred occasionally in chicks fed Aroclor 1260, the authors felt that this was indicative of small quantities of a toxic factor in this preparation.

Teratogenesis

Recently, Bionetics Research Laboratory, Bethesda, Md (unpublished data), as cited by Emerson et al[57] found a teratogenic effect of technical 2,4,5-T in rats. Apparently, the technical 2,4,5-T was contaminated with 27 ppm of 2,3,7,8-tetrachlorodibenzo-*p*-dioxin. In the study published by Courtney et al,[58] it was stated that the technical 2,4,5-T which was found to be teratogenic in two strains of mice and one strain of rats was contaminated with 30 ppm 2,3,7,8-tetrachlorodibenzodioxin. Emerson et al[57] tested 2,4,5-T that only contained 1 ppm 2,3,7,8-tetrachlorodibenzo-*p*-dioxin at comparable dosage levels and did not elicit a teratogenic effect. This finding was substantiated by Sparschu et al[59] who studied teratogenic effect of 2,3,7,8-tetrachlorodibenzo-*p*-dioxin in the rat. A slight effect was observed at a dose of 0.125μg/kg/day when the material was given by gavage from day 6 through day 15 of gestation. At the level of 0.5μg/kg/day, the effect was quite pronounced. Courtney and Moore[60] were able to produce cleft palates and kidney malformations in three strains of mice with high doses (100 mg/kg subcutaneously daily from day 6 to 15 of pregnancy) of analytical grade 2,4,5-T that contained less than 0.05 ppm 2,3,7,8-tetrachlorodibenzo-*p*-dioxin.

Keplinger et al[61] reported a decreased survival of pups in rat reproduction studies when fed 100 ppm of Aroclor 1242 and 1254, and poor hatchability of eggs from chickens fed 10 or 100 ppm of Aroclor 1242 or 100 ppm of Arochlor 1254. It has been said[43] that a purified crystalline concentrate from toxic fat led to the development of embryonic deformities in chickens.

Comment

In some instances, the same chemical compounds are responsible for the occurrence of

MONS 084682

chloracne in people, liver disease in several species, x-disease in cattle, chick edema, and teratologic or other effects on the fetus. Not all of the disease entities have thus far been produced by all of the compounds (Table 1). Some of the compounds in question have been shown to be contaminated with chlorinated dibenzo-*p*-dioxins or chlorinated dibenzofurans (Table 2). The degree of contamination seems to vary with different compounds. Some companies manufacturing these compounds have instituted clean-up procedures which remove the greatest part of the contaminants. Improved hygiene among the workers and improved ventilation of the working area have, in many instances, reduced the incidence of chloracne. Whether all disease entities described are caused by the chlorinated dibenzodioxins or the chlorinated dibenzofurans is not yet known. Some of these chemicals are highly toxic, as illustrated by the fact that two applications of 10μg of 2,3,6,7,-tetrachlorodibenzo-*p*-dioxin applied to human skin[62] produced chloracne-like symptoms. Single oral doses of 20μg to 50μg/kg/body weight resulted in fatal liver necrosis in rabbits.[62] There is no readily available information on the metabolism of these compounds in animals and their breakdown in the environment.[63] It is probable that they are stable. Crosby et al[64] found that 2,3,7,8-tetrachlorodibenzo-*p*-dioxin and its homologues decomposed rapidly in alcohol solution under artificial light and natural light. However, photodecomposition was negligible in aqueous suspensions and on wet or dry soil. It is unknown whether the disease entities discussed are the result of one or several contaminants or the combined effect of the chemical compound and its contaminant.

Another unsolved problem is the observation that some of these compounds such as technical 2,4,5-T induce porphyria.[23] The chlorinated biphenyls also cause porphyria.[65] Whether porphyria is the result of the chemicals themselves or of the contaminants, or both, is not known. Crow[63] suggests that the porphyria produced by technical 2,4,5-T may have been caused by contamination of the chemical with crude chlorobenzenes, which were used to produce the chlorophenols from which the 2,4,5-T was made. Better awareness of the possible contamination of the technical chemicals with various highly toxic substances, well coordinated epidemiological studies, and additional experimental studies in animals are needed to clarify these problems.

Chloracne has been produced experimentally in men by Shelley and Kligman (*Arch Derm* 75:689, 1957). The authors cite additional references on experimental dermal exposure of animals and men to chlorinated naphthalenes.

References

1. Hersheimer K: Uber Cloraskne. *Münch Med Wschr* 46:278, 1899.
2. Wauer H: Gewerbliche Erkrankungen durch gechlorte Kohlenwasserstoffe. *Zbl Gew Hyg* 6:100, 1918.
3. Teleky L: Die Pernakrankheit (Chlorakne). *Klin Wschr* 6:845-848; 897-901, 1927.
4. Jones JW, Alden HW: An acneiform dermatergosis. *Arch Derm Syph* 33:1022-1034, 1936.
5. Teleky L: Uber Neurere Forschungsmethoden und Forschungen auf dem Gebiet der Gewerbekrankheiten. *Klin Wschr* 27:249-257, 1949.
6. Flinn FB, Jarvik NE: Actions of certain chlorinated naphthalenes of the liver. *Proc Soc Exp Biol Med* 35:118-120, 1936.
7. Drinker CK, Warren MF, Bennett GA: The problem of possible systemic effects from certain chlorinated hydrocarbons. *J Industr Hyg Toxic* 19:282-311, 1937.
8. Jones AT: The etiology of acne with special reference to acne of occupational origin. *J Industr Hyg Toxic* 23:200-212, 1941.
9. Greenburg L, Mayers MR, Ross-Smith A: The systemic effect resulting from exposure to certain chlorinated hydrocarbons. *J Industr Hyg Toxic* 21:29-38, 1938
10. Cotter LH: Pentachlorinated naphthalenes in industry. *JAMA* 125:273-274, 1944.
11. McLechtchie NGB, Robertson D: Chlorinated naphthalene poisoning. *Brit Med J* 1:691-692, 1942.
12. Collier E: Poisoning by chlorinated naphthalenes. *Lancet* 244:72-74, 1943.
13. Von Oettingen WF: *The Halogenated Hydrocarbons, Toxicity and Potential Danger*, publication 414. Public Health Service, 1955.
14. Schwartz L, Tulipan L, Birmingham DJ: *Occupational Diseases of the Skin*, ed 3. Philadelphia, Lea and Febiger Publishers, 1957, pp 336-345.
15. Meigs WJ, Albom JJ, Kartin BL: Chloracne from and unusual exposure to aroclor. *JAMA* 154:1417-1418, 1954.
16. Hofmann MF, Meneghini CL: A proposito delle folliculosi da idrocarburi clorosostituiti (Acne clorica). *G Ital Derm* 103:427-450, 1962.
17. Birmingham DJ: Occupational dermatology: Current problems. *Skin* 3:38-42, 1942.
18. Plewig G: Zur Kinetik der Comedonenbildung bei Chloracne (Halowaxacne). *Arch Klin Exp Derm* 238:228-241, 1970.
19. Bauer H, Schulz KH, Spiegelberg U: Berufliche Vergiftungen bei der Herstellung von Chlorphenol-Verbindungen. *Arch Gerwerbepath Gewerbehyg* 18:538-555,1961.
20. Kimmig J, Schulz KH: Berufliche Akne (Sog

MONS 084683

Chloralkne) durch chlorierte aromatische zyklische Äther. *Dermatologica* 115:540-546, 1957.

21. Adams EM, Irish DD, Spencer HC, et al: The response of rabbit skin to compounds reported to have caused acneform dermatitis. *Industr Med Surg* 2:1-4, 1941.

22. Bauder EW, Bauer HJ: Industrial intoxication due to pentachlorophenol. *Ind Med Surg* 20:286-290, 1951.

23. Poland AP, Smith D, Metter G, et al: A health survey of workers in a 2,4-D plant and 2,4,5-T plant. *Arch Environ Health* 22:316-327, 1971.

24. Braun W: Klinische Beobachtungen zur Entstehung der Chlor. cne. *Hautarzt* 10:126-129, 1959.

25. Crow KD: Cornene. *Brit J Derm* 83:599-600, 1970.

26. Olafson P: Pyperkeratosis (x-disease) of cattle. *Cornell Vet* 37:279-291, 1947.

27. Hansel W, Olafson P, McEntee K: The isolation and identification of the causative agent of bovine hyperkeratosis (x-disease) from a processed wheat concentrate. *Cornell Vet* 45:94-101, 1955.

28. Sikes D, Bridges ME: Experimental production of hyperkeratosis (x-disease) of cattle with a chlorinated naphthalene. *Science* 116:506-507, 1952.

29. Brock WE, Jones EW, MacVicar R, et al: Chlorinated naphthalene intoxication in sheep. *Amer J Vet Res* 18:625-630, 1957.

30. Huber WG, Link RP: Toxic effects of hexachloronaphthalene on swine. *Toxic Appl Pharmacol* 4:257-262, 1962.

31. Schoettle CE, Reber EF, Morrill CC, et al: Experimental production of hyperkeratosis in rats and hamsters. *Amer J Vet Res* 16:187-188, 1955.

32. Sikes D, Wise JC, Bridges ME: The experimental production of x-disease (hyperkeratosis) in cattle with chlorinated naphthalenes and petroleum products. *J Amer Vet Med Assoc* 121:337-344, 1952.

33. Bell WB: Relative toxicity of the chlorinated naphthalenes in experimentally produced bovine hyperkeratosis (x-disease). *Vet Med* 48:135-140, 1953.

34. Sanger VL, Scott L, Hanidy A, et al: Alimentary toxemia in chickens. *J Amer Vet Med Assoc* 133:172-176, 1958.

35. Anonymous: The chickedema factor. *Nutrition Rev* 26:28-30, 1968.

36. Schmittle SC, Edwards HM, Morris DA: A disorder of chickens probably due to a toxic feed-preliminary report. *J Amer Vet Med Assoc* 132:216-219, 1958.

37. Edgar SA, Bond DS, Melius P, et al: The effect of a toxic substance in fat on poultry. *Poult Sci* 37:1200-1201, 1958.

38. Allen JR, Lalich JJ: Response of chickens to prolonged feeding of crude toxic fat. *Proc Soc Exp Biol Med* 100:48-51, 1962.

39. Simpson CF, Pritchard WR, Harms RH: An endothelionia in chickens and turkeys caused by an unidentified dietary factor. *J Amer Vet Med Assoc* 134:410-416, 1959.

40. Allen JR, Carstens LA: Light and electron microscopic observations in *Macacca mulatta* monkeys fed toxic fat. *Amer J Vet Res* 28:1513-1526, 1967.

41. McCune EL, Savage JE, O'Dell BL: Hydropericardium and ascites in chicks fed a chlorinated hydrocarbon. *Poult Sci* 41:295-299, 1962.

42. Prestt I, Jefferies DJ, Moore NW: Polychlorinated biphenyls in wild birds in Britain and their avian toxicity. *Environ Pollut* 1:3-26, 1970.

43. Pudelkiewicz WJ, Boucher RV, Callenbach EW, et al: Some physiological responses of New Hampshire chickens to a mixture of pentac- and hexachloronaphthalenes. *Poult Sci* 38:424-430, 1959.

44. Flick DF, Firestone D, Marliac JP: Studies of the chick edema disease: II. Preparation and biological effects of a crystalline chick edema factor concentrate. *Poult Sci* 44:1214-1222, 1965.

45. Flick DF, O'Dell BG, Ross VC: Studies of the chick edema disease: Long-term, low-level feeding of chick edema factor. *Poult Sci* 46:196-201, 1967.

46. Cantrell JS, Webb NC, Mabis AJ: Search for chick edema factor. *Chem Eng News* 45:30, 1967.

47. Tomita M, Ueda S, Narisada M: Dibenzo-*p*-dioxin derivatives: XXVII. Synthesis of polybromodibenzo-*p*-dioxins. *Yakugaku Zasshi* 79:186-192, 1959.

48. Higginbotham GR, Huang A, Firestone D, et al: Chemical and toxicological evaluations of isolated and synthetic chloro derivatives of dibenzo-*p*-dioxin. *Nature* 220:702-703, 1968.

49. Risebrough RW, Rieche P, Peakall DB, et al: Polychlorinated biphenyls in the global ecosystem. *Nature* 220:1098-1102, 1968.

50. Lichenstein EP, Schulz KR, Fuhremann TW, et al: Biological interaction between plasticizers and insecticides. *J Econ Entom* 62:761-765, 1969.

51. Miller JW: Pathological changes in animals exposed to a commercial chlorinated biphenyl. *Public Health Rep* 59:1085-1093, 1944.

52. Nishizumi M: Light and electron microscope study of chlorobiphenyl poisoning. *Arch Environ Health* 21:620-632, 1970.

53. Taki I, Hisanaga S, Amagase Y: Reports of the study of "Yusho." *Fukuoka Acta Medica* 60:471-474, 1969.

54. Okumura M, Katsuki S: Clinical observation on "Yusho." *Fukuoka Acta Medica* 60:440-446, 1969.

55. Vos JG, Koeman JH: Comparative toxicologic study with polychlorinated biphenyls in chickens with special reference to porphyrin, edema formation, liver necrosis and tissue residues. *Toxic Appl Pharmacol* 17:656-668, 1970.

56. Vos JG, Koeman JH, Van Der Maas HL, et al: Identification and toxicological evaluation of chlorinated dibenzofuran and chlorinated naphthalene in two commercial polychlorinated biphenyls. *Food Cosmet Toxic* 8:625-633, 1970.

57. Emerson JL, Thompson DJ, Strebing RJ, et al: Teratogenic studies of 2,4,5-trichlorophenoxyacetic acid in the rat and rabbit. *Food Cosmet Toxic* 9:395-404, 1971.

58. Courtney KD, Gaylor DW, Hogan MD, et al: Teratogenic evaluation of 2,4,5-T. *Science* 168:864-866, 1970.

59. Sparschu GL, Dunn FL, Rowe VK: Study of teratogenicity of 2,3,7,8-tetrachlorodibenzo-*p*-dioxin. *Food Cosmet Toxic* 9:405-412, 1971.

60. Courtney KD, Moore JA: Teratology studies with 2,4,5-trichlorophenoxyacetic acid and 2,3,7,8-tetrachlorodibenzo-*p*-dioxin. *Toxic Appl Pharmacol* 20: 396-403, 1971.

61. Keplinger ML, Fancher OE, Calandra JC: Toxicologic studies with polychlorinated biphenyls. Read before the tenth annual meeting of the Society of Toxicology, Washington, DC, 1971.

62. Schulz KH: Klinische und experimentelle Untersuchungen zur Ätiologie der Chlorakne. *Arch Klin Exp Derm* 206:589-596, 1957.

63. Abelson PH: Pollution by organic chemicals. *Science* 170:495, 1970.

64. Crosby DG, Wong AS, Plimmer JR, et al: Photodecomposition of chlorinated dibenzo-*p*-dioxins. *Science* 173:748-749, 1971.

65. Crow KD: Chloracne. *Trans St John Hosp Derm Soc* 56:79-99, 1970.

MONS 084684