ew or widespread, osed in irregular r zones. Seen end- e periphery, along ent to the media- ill also very often on, involving the irectly behind the as encountered in Hurwitz[37, 38]).

o evidence of pre- was found. These d unilateral pleural kening or effusion. the beginning, but itary mass in the pleural neoplasm, nsive nodular or g. 5). This pattern



n clearly on the

ly significant find- , but of course, a secondary malig- ten a large pleural only after removal that the pleura is the parietal and ed pneumothorax, rather character- ularity along the the collapsed lung.



Fig. 6. Induced pneumothorax revealing gross malignant involvement of pleura. A considerable quantity of fluid is still present in the right pleural cavity.

In the later stages, a considerable part of the pleural cavity may be obliterated and a comparatively small space may remain. Here fluid may collect under tension and the lung may be further compressed, in spite of being encased by a thick tough covering of malignant tissue. As the mediastinal pleura thickens, and the regional lymph glands become infiltrated, widening of the mediastinum is seen radiologically. Eventually the pericardium is involved by direct extension, and the resultant pericardial effusion causes progressive enlargement of the cardiac silhouette and a change in its configuration. Extrapleural extension can also occur; then radiological evidence of rib involvement may be present.

Stout and Murray[5] remark upon the right-sided preponderance of the disease. In the series of 24 cases reported by Choptal *et al.*,[16] 19 were right-sided. Our cases present an identical distribution, since 27 of the 34 cases had right-sided lesions. In no case was the mesotheliomatous process initially bilateral, although the X-rays of 10 of the patients showed bilateral changes due to asbestosis.

Thoracoscopy and Thoracotomy

The information obtained from thoracoscopy was disappointing. The view is always limited in cases of mesothelioma because the cannula cannot be freely manipulated. When blood has extravasated into the effusion, the walls of the cavity are covered with fibrinous deposits and no architectural details are visible. The chief objection to the technique, as a diagnostic measure, is that the choice of area for biopsy is restricted, and it is impossible to obtain a representative specimen. Thoracoscopy was the usual diagnostic procedure in the early stages and, although sufficient material for microscopic examination was usually obtained, we feel that a great deal of information was missed.

With early cases, where the pleura is thin and the effusion clear, it is often possible to visualize the discrete pleural nodules overlying the still elastic lung. The nodules are then usually cherry-coloured and either smoothly-rounded or warty in appearance. Later the discrete nodules coalesce and the underlying lung is obscured. The growth is then usually seen as a grey opaque membrane, with localized excrescences of variable size and similar appearance projecting into the pleural space. At this stage the outstanding feature is the thickness and density of the pleural growth and the complete immobility of the incarcerated lung beneath.

As far as possible, it is now our policy to obtain a specimen of lung by open operation. With 4 early cases, attempts were made to decorticate lungs which were completely encased by thick, apparently fibrous, coverings. In 3 cases the findings were similar. The parietal pleura was 1 - 2 cm. thick and very hard. The lungs were collapsed and bound down by thickened visceral pleura, identical in appearance with the parietal pleura. The pleural spaces were occupied by straw-coloured or blood-stained fluid. Attempts to strip the 'peel' off the chest wall could only be made through the extrapleural plane, but even then the intercostal spaces were constantly entered and no vestige of normal parietal pleura could be found. Calcified plaques within the diseased tissue were frequently encountered, particularly over the diaphragm and inter-

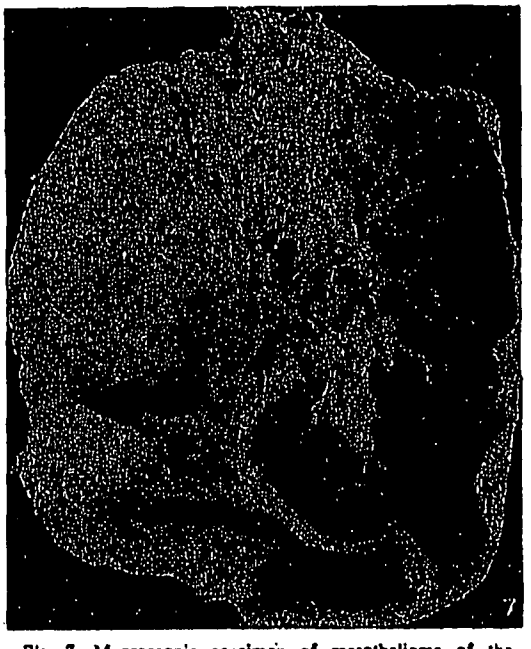

Fig. 7. Macroscopic specimen of mesothelioma of the pleura.