NOTICE: This material may be protected by copyright.

CHAPTER 5

Acute and chronic toxicity, carcinogenesis, reproduction, teratogenesis and mutagenesis in animals

ERNEST E. McCONNELL
National Institute of Environmental Health Sciences, Research Triangle Park, NC 27709, U.S.A.

5.1. Introduction

The halogenated dibenzo-*p*-dioxins, dibenzofurans, polychlorinated and polybrominated biphenyls, chlorinated naphthalenes and terphenyls comprise a group of structurally related compounds of considerable environmental interest because of their ubiquitousness, stability, potential for biomagnification and highly toxic nature of selected isomers. These chemicals may be industrially useful (biphenyls, terphenyls and naphthalenes) or unwanted contaminants (dioxins and furans) of other useful chemicals. The toxicological properties of some of the compounds (dioxins and biphenyls) have been studied in some depth, others (naphthalenes and furans) less so, while little is known about the terphenyls. Additionally, many of the compounds are composed of mixtures of various isomers (each with its own independent toxic potential) and may also contain contaminants of some of the other classes of chemicals. Because of the complex nature of these chemicals, the toxic signs and lesions produced by them often appear confusing to both the research scientist and diagnostician.

The purpose of this chapter is an attempt to delineate specific aspects of toxicity and arrive at a commonality of signs and lesions that are (1) useful in defining the toxic syndrome in various species of animals; (2) useful for the diagnosis of unknown intoxications which mimic these pathological changes; and (3) useful in predicting the acute and long-term effects from accidental exposures.

5.2. Toxicity

According to *Dorland's Medical Dictionary* the definition of toxicity is "the quality of being poisonous" (Friel, 1974). To discuss the 'toxicity' of the subject com-

NIOSH 225368

pounds with a definition this broad would be impossible and would overlap to some degree every chapter in this text. Therefore, for the purposes of this review, toxicity will cover the more 'classic' aspects of the subject such as clinical signs, hematology, blood chemistry and lesions caused by these chemicals in nonhuman mammals and birds. Numerical dose–response relationships are not dealt with in detail in this chapter for the reasons stated below. Additional information on LD_{50} values, toxic dose levels and no effect levels are available to the reader in reviews noted at the end of this section.

5.2.1. Clinical signs

The clinical signs of toxicity vary with the dose, length of exposure (acute or chronic) and with the species of animal exposed. However, in general, the compounds reviewed here may cause the same types of toxic reactions on a qualitative basis in a given species of animal, but the effects in different species may vary considerably (McConnell and Moore, 1979). Quantitatively, vast differences exist in the amount required to produce such an effect (see Chapter 7). The concept of a commonality of toxic responses to these compounds is often difficult to appreciate in reviewing the literature because in comparing the effects of these compounds various experimental designs are encountered. The same design and dose may be used for the different classes of compounds (or various isomers of the same class of compound) but still result in somewhat different clinical signs due to differing degrees of toxicity of different isomers (McKinney et al., 1976; Vos and Koeman, 1970; Schwetz et al., 1973). The apparent disparity in signs and lesions is particularly difficult to reconcile when one studies some of the relatively nontoxic isomers where it may be almost impossible to produce severe toxicity (Norback et al., 1975). However, if one uses lethality as an end point or gives the same dose relative to the LD_{100} or LD_{50}, then these differences disappear for the most part (McConnell et al., 1978b).

While comparative isomeric studies have not been conducted on all of these classes of compounds, those with polychlorinated biphenyls (PCBs) (Biocca et al., 1976; Lillie et al., 1974), chlorinated dibenzodioxins (CDDs) (McConnell et al., 1978b), chlorinated dibenzofurans (CDFs) (Moore et al., 1979) and chlorinated naphthalenes (CN) (Brinkman and Reymer, 1976) clearly demonstrate that the degree of toxicity is dependent upon both the number and location of the halogen atoms (McKinney et al., 1980). A major problem in the toxicological assessment of these compounds is that the commercial preparations occur as mixtures of several isomers and often contain impurities which could have their own toxic properties (Polin et al., 1979). For example, it is well known that most PCBs contain significant levels of CDFs which may be more toxic than the parent compound (Bowes et al., 1975; Vos and Koeman, 1970).

Another interesting feature of intoxication is the relationship of dose vs. time. It appears that a lesser amount of these compounds is needed to produce a given level of intoxication if exposure is extended over a longer period of time (Nelson et al.,

MONS 225369

1972). For example the single oral LD_{50} of 2,3,7,8-tetrachlorodibenzo-*p*-dioxin (TCDD) in monkeys is reported to be approximately 50 μg/kg (McConnell et al., 1978a), while when the same species were exposed to extremely low levels (500 ppt) in the diet over a 6 month period, the total accumulated lethal dose was only about 2 μg/kg (Allen et al., 1977). Another study which demonstrated this phenomenon in a slightly different way involved a commercial mixture of polybrominated biphenyls (PBBs) (Gupta and Moore, 1979). Male rats were exposed to the PBBs daily, 5 days/week for one month, and were then observed for an additional 60 days. At the end of the 30 day exposure period the LD_{50} of the rats was calculated to be 4.4 g/kg, but 30 days later this had decreased to 3.7 g/kg and after 30 more days the LD_{50} was 3.3 g/kg. The explanation for this phenomenon probably lies in the long half-life, variable absorption rates, and tissue distribution of these compounds, all of which are discussed in Chapter 4. Therefore, it is difficult and probably not valid to state which class of compounds is the most toxic. However, in general, if a given animal species is exposed to the most toxic isomer of each class of compound (Table 5.1), the relative toxicity is dioxin > furan ≫ PCB ≫ naphthalene (McConnell and McKinney, 1978). While definitive work in this regard has not been done on terphenyls, it appears that they may be relatively less toxic chemicals (Adamson and Weeks, 1973). Interestingly, 2,3,6,7-tetrabrominated naphthalene is much more toxic than the identically chlorinated naphthalene (Table 5.1). It remains to be proven whether the other brominated classes of compounds are more toxic than the chlorinated ones.

5.2.1.1. Acute signs. In acute (relatively high single dose) studies the initial sign of toxicity is weight loss or reduced weight gain. Interestingly, this is only partially related to a decrease in food or water consumption (Harris et al., 1973). In a smaller laboratory animal species and birds this effect is observed as early as 3 days following a single dose. It may not be observed as quickly in larger animals such as dogs, cows, horses or nonhuman primates. However, in these latter species it will still be the first effect recognized. In acute but sublethal studies in rodents, this loss of

TABLE 5.1

Relative toxicity of the most toxic isomer of related halogenated hydrocarbons in guinea pig.

	LD_{50-30}[a]	Relative potency[b]
2,3,7,8-TCDD	0.006	1883
2,3,7,8-TCDF	0.023	507
3,3',4,4',5,5'-HCB	1.39	8
2,3,6,7-TCN	>11.3	1
2,3,6,7-TBN	0.547	21

a. Amount (μmol/Kg) required to kill 50% of the animals by 30 days post exposure.

b. Relative potency normalized to molar LD_{50-30} of the least toxic chemical (TCN) (the higher the number, the greater the potency).

MONS 225370

TABLE 5.2

Summary of pathologic findings due to the toxicity of polybrominated biphenyl (PBB), polychlorinated biphenyl (PCB), tetrachlorodibenzo p-dioxin (TCDD) and tetrachlorodibenzofuran (TCDF) in laboratory animals and humans (Courtesy of Dr. Bhola N. Gupta, NIEHS).

Chemical	Species	Decrease body wt.	Acne/ alopecia	Edema	Lymphoid atrophy		Hepatomegaly	Hepatomegalocytosis	Multinucleated giant cell	Necrosis, degeneration	Fat	Bile duct hyper	Porphyria	Urinary bladder hyper	Gastropathy	Tumor induction
					Thymus	Spleen										
PBB	rat	+	(−)	(−)	+	+	+	+	+	+	+	+	+	(−)	+	+
	mouse	+	(−)	?	+	+	+	+	(−)	+	+	(−)	+	(−)	(−)	+
	guinea pig	+	(−)	(−)	+	+	+	(−)	(−)	+	+	(−)	(−)	+	(−)	(−)
	chicken	+	(−)	+	+	+	+	(−)	(−)	+	+	(−)	+	(−)	?	(−)
	monkey	+	+	?	+	+	+	+	(−)	+	+	(−)	(−)	(−)	+	(−)
	human	n.r.[a]	n.r.	n.r.	n.r.	n.r.	n.r.	n.r.	n.r.	n.r.	n.r.	n.r.	n.r.	n.r.	n.r.	n.r.
PCB	rat	+	(−)	(−)	+	+	+	+	+	+	+	+	+	(−)	(−)	+
	mouse	+	(−)	+	+	+	+	+	(−)	+	+	(−)	+	(−)	(−)	+
	guinea pig	+	(−)	(−)	+	+	+	(−)	(−)	+	+	(−)	(−)	+	(−)	(−)
	chicken	+	(−)	+	+	+	+	(−)	(−)	+	+	(−)	+	(−)	+	(−)
	monkey	+	+	+	+	+	+	+	(−)	+	+	(−)	(−)	(−)	+	(−)
	human	+	+	+	n.r.	n.r.	+	+	(−)	+	+	(−)	+	(−)	(−)	(−)
TCDD	rat	+	(−)	(−)	+	+	+	+	+	+	+	+	+	(−)	(−)	+
	mouse	+	(−)	+	+	+	+	+	(−)	+	+	(−)	+	(−)	(−)	?
	guinea pig	+	(−)	(−)	+	+	+	(−)	(−)	+	+	(−)	(−)	+	(−)	(−)
	chicken	+	(−)	+	+	+	+	(−)	(−)	+	+	(−)	+	(−)	?	(−)
	monkey	+	+	+	+	+	+	+	(−)	+	+	(−)	(−)	+	+	(−)
	human	n.r.	+	+	n.r.	n.r.	+	n.r.	(−)	+	+	(−)	+	(−)	n.r	(−)
TCDF	rat	+	(−)	(−)	+	+	+	+	+	+	+	+	+	(−)	n.r.	n.r.
	mouse	+	(−)	+	+	+	+	+	(−)	+	+	(−)	+	(−)	(−)	n.r.
	guinea pig	+	(−)	(−)	+	+	+	(−)	(−)	+	+	(−)	(−)	+	(−)	(−)
	chicken	+	(−)	+	+	+	+	(−)	(−)	+	+	(−)	+	(−)	n.r.	(−)
	monkey	+	+	+	+	+	+	+	(−)	+	+	(−)	(−)	(−)	+	(−)
	human	n.r.	+	+	n.r.	n.r.	n.r.	n.r.	(−)	n.r.	n.r.	n.r.	(−)	n.r.	n.r	(−)

a. n.r. = not reported in the literature as yet.

MONS 225371

weight gain can be recovered with few if any other signs being observed.

Different species of animals vary widely in their susceptibility to intoxication of these compounds (Table 5.2). In general, female animals are more sensitive than males (Harris et al., 1973) and young animals are more sensitive than adults (Linder et al., 1974). Poultry, guinea pigs, mink and nonhuman primates are the most susceptible animals to the toxic effects of these classes of compounds, while frogs (Beatty et al., 1976) appear to be quite resistant.

In lethal studies, weight loss becomes progressive until death ensues. Even here weight loss cannot be attributed entirely to a lack of food or water intake (Harris et al., 1973). In the rat, guinea pig and the mouse, to a lesser extent, weight loss with general debilitation may be the only signs observed prior to death (McConnell et al., 1978b). In contrast, birds, particularly chickens, may actually show an increase in body weight just prior to death as a result of an extracellular accumulation of body fluids (subcutaneous edema, ascites, hydrothorax and hydropericardium). In fact, the resulting 'bloated' appearance in the chicken (Fig. 5.1) is of diagnostic importance and the toxic syndrome has been referred to as 'chick edema disease'.

Outbreaks of 'chick edema' were first recognized in the southeastern United States in 1957 with serious economic loss to the poultry industry (Sanger et al., 1958;



Fig. 5.1. Chick edema disease. Chick on left shows large amounts of subcutaneous edema in the neck and between the legs. The abdomen is distended due to ascites. Chick on right has been opened to demonstrate massive hydropericardium. Pericardial sac is outlined by arrows: H = heart. Photographs courtesy of Dr. David Firestone, Food and Drug Administration, Department of Health and Human Services, Washington, D.C.

MONS 225372

Simpson et al., 1959). Affected birds also showed dyspnea, stunting and paleness, and often died suddenly. The disease was caused by the incorporation of 'toxic fat' obtained from the degreasing of animal hides into poultry rations (Firestone, 1973). This 'toxic fat' was contaminated with high levels of CDDs, particularly hexa-CDD (Cantrell et al., 1969), probably during the curing, brining, soaking and pickling operations prior to the rendering process. In one outbreak in North Carolina over one million chickens died or had to be killed before the chick edema disease was controlled (Firestone, 1973). Recently, PCBs from a leaking transformer in a feed mill have been incriminated in a similar syndrome in the Pacific northwestern U.S., and experimentally PCBs (Platonow et al., 1973) and PBBs (Ringer and Polin, 1977) have produced classic 'chick edema disease'. Millions of chickens in Japan were also affected in the 'Yusho Disease' incident described in Chapter 9B1 (Shoya, 1974). Subcutaneous edema and ascites are also observed occasionally in mice exposed lethally to these compounds.

Terminally some rodents and especially birds may show hemorrhage in the gastrointestinal tract (Gupta et al., 1973) and under the skin (McConnell et al., 1978b).

One of the interesting aspects of acute poisoning with these compounds is the median time to death which is 2 to 3 weeks after a single exposure for most small laboratory animal species and is even longer for larger domestic animals, dogs and nonhuman primates (McConnell and Moore, 1979). Even doses several fold greater than the LD_{50} do not markedly reduce this figure (Buu-Hoi et al., 1972b).

5.2.1.2. Chronic signs. The clinical signs observed in chronic exposures are initially only those observed in acute studies. In mice, rats and guinea pigs, these may still be the only signs observed. However, in some other species cutaneous manifestations are distinctive to the point of being of diagnostic value.

In 1947 Olafsen described a hyperkeratotic disease of cattle in the United States which he referred to as 'X-disease'. These animals showed hard thickened skin, especially on the upper part of the face (around the eyes), dorsal neck and over the shoulders (Fig. 5.2). Associated symptomatology included severe lacrimation, diarrhea, polyuria, marked salivation and nasal discharge. The exact cause (chlorinated naphthalenes) of the disease syndrome was not established for some period of time (Hansel et al., 1955) although experimentally, highly chlorinated naphthalenes and used crankcase oils could produce an identical disease in cattle (Bell, 1953) and were also toxic to sheep (Brock et al., 1957) and swine (Huber and Link, 1962). However, skin lesions were not observed in the latter two species. 'X-disease' is still observed occasionally in cattle today, often attributed to contamination of feed with lubricants and the use of discarded petroleum products as vehicles for insecticides in the treatment of ectoparasites. Cattle have become similarly intoxicated by licking axle grease from farm implements. A similar disease of cattle was observed in Germany between 1946 and 1948 which was related to exposure to a wood preservative (Wagener, 1951). While cattle experimentally housed in barns painted with the compound exhibited the disease, the exact toxic chemical was never identified. Recently,

MONS 225373



Fig. 5.2. X-disease (hyperkeratosis) in a bull exposed to chlorinated naphthalene. Notice the thickened and wrinkled skin on neck and shoulders. Photograph courtesy of Dr. Peter Olafson, Cornell University, Ithaca, N.Y.

it has been suggested that cattle housed in barns constructed with pentachlorophenol treated lumber show a syndrome similar to 'X-disease' (Conklin and Fox, 1978). If such a problem occurs it has been clearly established that the cause is not pentachlorophenol *per se*, but rather the contaminants (probably CDDs and CDFs) found in the pentachlorophenol (McConnell et al., 1980).

Another toxic condition of domestic animals of disastrous proportions that mimicked 'X-disease' of cattle to some degree occurred in Michigan in 1973–1974 (Jackson and Halbert, 1974). This incident was caused by the inadvertent introduction of PBBs into animal feed (Kay, 1977). Exposure of animals became so widespread that 18,000 cattle, 3,500 pigs, 1,200 sheep and 1.5 million chickens eventually had to be killed (Dunckel, 1975; Mercer et al., 1976). In addition vast amounts of animal products such as milk, cheese and eggs had to be destroyed.

Another animal species which shows skin changes from exposure to these chemicals is the Old World monkey. Monkeys are particularly sensitive to these classes of compounds and the ensuing skin lesions are highly diagnostic and in many ways mimic those changes observed in man, i.e., chloracne (Allen and Carstens, 1967). While a single exposure will produce the cutaneous syndrome in 30 to 60 days (McConnell et al., 1978a), it is more conspicuous after chronic exposure (Allen et al., 1977). The lesion consists of edema, alopecia and folliculitis, primarily

MONS 225374



Fig. 5.3. TCDD toxicity in a rhesus monkey. Top: monkey prior to exposure; bottom: closer view of this same monkey 42 days after a single oral dose of 70 μg/kg body weight. Note swollen eyelids, loss of eyelashes, facial alopecia and acneform eruptions on the bridge of the nose.

MONS 225375

on the face (Fig. 5.3) and later on the chest. Concomitantly the skin becomes dry and scaly. The finger and toenails slough due to rapid growth of the subjacent keratin bed. If one everts the eyelids of affected monkeys a highly characteristic sign of intoxication is observed. The Meibomian (tarsal) glands are markedly thickened and tortuous (Fig. 5.4). Clinically these monkeys show photophobia but in reality the probable cause of this sign is lack of the normal Meibomian glands secretion resulting in irritation of the cornea. The ear canals of these monkeys contain an exuberant amount of granular debris due to a similar lesion in the ceruminous glands.

Chloracne-like lesions are not usually observed in rodents although they were reported in one study of rats exposed to PCDFs (Oishi et al., 1978).

Spontaneous disease in monkeys from exposure to these chemicals has been observed in several primate facilities in the United States (McNulty and Griffin, 1976; Altman et al., 1979) and Europe (Van Putten et al., 1970). In the U.S. the syndrome has been related to the presence of PCBs in cement floor sealers and possibly coatings on the wire fencing. In The Netherlands it has been associated with the use of wood shavings obtained from treated wood. However, considering that PCBs, dioxins and naphthalenes are so widespread in the environment (Rappe, 1979) and the extreme susceptibility of monkeys to intoxication from these compounds, it is not surprising that primate disease outbreaks occur.

The ear of the rabbit will also react to contact exposure to these compounds, first with hyperkeratosis and later with grossly visible folliculitis (Hass et al., 1978; Vos and Beems, 1971). In fact, the inner surface of the rabbit ear is such a sensitive tissue to the effects of these compounds it can serve as a useful tool to test for the presence of and relative toxic potential of complicated mixtures containing these materials (Jones and Krisek, 1962). One merely applies the test material to a small (1 cm^2) area of the inner surface of the ear daily for 3 to 5 days. Signs should occur within 1 week and progress during the following 2 to 3 weeks. The contra-lateral ear can serve as a vehicle or nontreated control surface. It should be noted that cutaneous absorption of these compounds in rabbits is so efficient that generalized toxemia may develop before the cutaneous lesions have developed fully (Kimmig and Schultz, 1957).



Fig. 5.4. Inner surface of the eyelids from a control (left) monkey and one exposed to a single oral dose of 1000 μg/kg TCDF (right). Several of the meibomian glands on right are thickened and tortuous compared to the control monkey.

MONS 225376

Hairless mice have also been shown to exhibit hyperkeratosis after ingestion of PCBs and in this respect also may be of diagnostic value in the testing of these chemicals (Inagami and Koga, 1969).

Skin lesions of a slightly different character (alopecia and ulceration) have also been observed in horses inadvertently exposed to dioxins and PCBs. This incident took place in Missouri in 1971–72 when waste oil containing 2,4,5-trichlorophenol, TCDD and PCBs was used to control dust in several riding arenas (Carter et al., 1975; Case, 1971; Case and Coffman, 1973). Further details of this incident are described in Chapter 9B2.

5.2.2. Hematology

The study of changes in the cellular components of blood caused by these chemicals is somewhat confusing and definitely not clear at this time. The reasons for this are (1) different animal species vary in their hematological response to these chemicals; (2) acute vs chronic studies can show marked differences in their effect on the blood due to variable life spans of the cellular components; and (3) doses approaching lethality will cause markedly different hematological changes. However, again if one exposes the same species of animal to an equivalent toxic dose of any of these classes of compounds, the results will usually be similar.

In acute studies (less than 30 days) very little change may be found in the cellular components of blood. Vos et al. (1974) found little hematological change in mice exposed to an approximate LD_{50} of TCDD. In contrast Buu-Hoi et al. (1972b) found a moderate anemia and leukocytosis in rats exposed to a dose of TCDD equivalent to 100 times the LD_{50}. Interestingly, Greig et al. (1973) and Zinkl et al. (1973 found the opposite effect (hemoconcentration) with TCDD in different strains of rats. The dose in both the latter studies was roughly equivalent but only 1/50 that of the previous study, which may explain the disparity. Anemia was not observed in mice and guinea pigs which received an approximately equivalent toxic dose of TCDD (Zinkl et al., 1973). Thrombocytopenia and clotting abnormalities have been observed in rats exposed acutely to lethal levels of TCDD (Weissberg and Zinkl, 1973).

These confusing and often conflicting studies of acute hematological sequella to dioxin intoxication are also observed in experiments in laboratory rodents exposed to CDFs, PCBs and PBBs. Hematological studies with terphenyls are so meager that conclusions cannot be drawn.

The red blood cell picture becomes a little clearer in long-term studies of these compounds. In all species studied using doses that are toxic, one observes a mild to moderate anemia. This effect is clearly dose and time dependent. For example female rats exposed to 0.1 μg/kg/day TCDD showed no evidence of anemia after 13 weeks of treatment (Kociba et al., 1976) but at the end of 2 years (Kociba et al., 1978) mild anemia was observed. Also at a dose of 1.0 μg/kg mild anemia was found after 36 days of exposure. A moderate thrombocytopenia and mild leukocytosis was found at the 1.0 μg/kg dose in the earlier (13 week) phase of the study but both were

MONS 225377

in the normal range at the end of 2 years at the lower dose. This suggests that erythrocytic precursors are more sensitive to the toxic effects of TCDD than the white cell components of blood. Monkeys spontaneously exposed to PCBs (McConnell et al., 1979) and experimentally exposed to PCBs (Allen et al., 1974), PBBs (Allen et al., 1978), dioxins (McConnell et al., 1978a) and furans (Moore et al., 1979) also show a dose–time related anemia which has been postulated to be due to the toxic effects on erythropoiesis.

The white blood cell picture is confusing in long-term exposures: some studies show leukocytosis, some normal total white cell and differential counts and some leukopenia, due primarily to a decrease in circulating lymphocytes. The white blood cell picture is particularly confusing in primates where pre-existing subclinical bacterial, viral or parasitic diseases may become manifested during the toxic syndrome. Depending upon the etiology of these secondary infections, an increase, decrease and/or shifts in the leukocyte differential may occur. Pancytopenia has been observed in rats exposed chronically to TCDD (Kociba et al., 1978).

5.2.3. Clinical chemistry

Changes in blood serum chemistries after exposure to these classes of compounds should be viewed very critically if one intends to determine primary from secondary effects. As with the hematological aspects of toxicity, serum chemistry dyscrasias are frequently observed which may appear incongruous when trying to compare various studies. It is important to know the relative toxicity (how close to an LD_{50}) of the dose, the period of time during and after exposure, and most importantly, the state of health of the host at the time the blood sample was obtained. Many parameters, especially serum enzymes, will vary markedly in animals given the same dose of one of these compounds depending on these factors.

Since these compounds are stored and to some degree metabolized, detoxified, and excreted by the liver (Rose et al., 1976), one would expect liver related enzymes to be altered in blood serum and this is the case in those species of animals where liver damage has occurred (McConnell and Moore, 1979). This includes rodents, rabbits and chickens. However, in those animal species where hepatotoxicity is not as apparent such as monkeys, guinea pigs and cows, liver function tests and serum enzymes related to the liver are near to normal values.

Liver function tests such as the clearance of bromsulphalein (BSP) and indocyanine green (ICG) from the blood have only been conducted occasionally in studies with these chemicals. In general, they are not adversely affected (Hwang, 1973), and clearance may be enhanced (Cagen and Gibson, 1978) even in animal species which show moderate liver damage. Similarly, bilirubin levels are rarely increased, although icterus was described in a chronic study of TCDD in rats (Kociba et al., 1976). On the other hand, some of the more sensitive indicators of liver toxicity such as liver-related serum enzymes may be increased. In general, increases in these enzymes are usually directly related to the severity of the liver lesion as seen histopathologically. In those species with little histopathological change in the liver

MONS 225378

such as monkeys, guinea pigs and cows, the only enzymes that are consistently increased are γ-glutamyl transpeptidase and sorbital dehydrogenase. Other enzymes such as alkaline phosphatase, transaminases and lactic acid dehydrogenase (LDH) are usually increased in those species of animals which show severe hepatotoxicity (Buu-Hoi et al., 1972a; McConnell et al., 1978a). Unfortunately, these enzymes may also be elevated in blood serum from animals killed in a moribund condition due to breakdown of tissues other than the liver. Therefore, the value of these enzymes for determining hepatotoxicity may be more useful if determined on the blood of animals before they become moribund. Another useful method would be the determination of isoenzyme profiles (such as LDH) that are more directly referable to liver toxicity.

Another clinical chemistry determination that is affected after exposure to toxic levels of these chemicals is serum protein values. There is species variation in this parameter, but when altered the trend is usually toward lower serum protein values, usually due to a reduction in the albumin fraction (McConnell and Moore, 1979). This results in a decrease in the albumin/globulin ratio. The decrease in albumin is probably related to hepatotoxicity (Davidson and Henry, 1969) and is less evident or non-existent in those animals which show little damage to the liver. An important consideration in the study of serum proteins is a knowledge of the state of health of the host. For example, the serum protein levels of blood obtained from a moribund animal will be quite different (higher) than the same animal if obtained a few days prior to this time. This is because terminally ill animals become so weak they cannot eat or drink resulting in hemoconcentration.

Globulin levels may also be decreased (Vos et al., 1974). This is usually due to a reduction in a specific fraction, particularly the alpha-globulins. This again varies among animal species. In long-term studies involving monkeys, increases in gamma-globulins have been reported. Changes in globulin levels are reviewed in more detail in Chapter 9.

Renal function is not adversely affected by these chemicals as evidenced by normal blood urea nitrogen (BUN) and creatinine levels, even in severely intoxicated animals. Also, the examination of urine using standard procedures does not reveal changes attributed directly to intoxication related to these chemicals. However, the urinary excretion of coproporphyrins and uroporphyrins may be increased in those species of animals with increased porphyrin levels in the liver (see Chapter 8).

Abnormalities in the levels of serum lipids may also be observed. In general, triglycerides and free fatty acids are increased, while total cholesterol is decreased (Lambrecht et al., 1978; McConnell et al., 1978a). These changes have been related to liver dysfunction and a debilitated condition in the host. Again, there are marked species differences in regard to these parameters.

Abnormalities in the hormone levels of the blood have been reported. Bastomsky (1977) reported that TCDD enhances the elimination of thyroxine (T_4) in the bile in rats which results in reduced blood levels of this hormone. Similar reductions in blood levels of T_4 have been found in cattle, exposed chronically to pen-

NONS 225379

tachlorophenol contaminated with dioxins and furans. However, since a reduction in T_4 was also observed in cattle exposed to pure pentachlorophenol (McConnell et al., 1980), dioxins in this animal species may or may not reduce the levels of this hormone. PCBs have also been shown to cause this effect in rats (Collins et al., 1977).

While some investigators have demonstrated changes in circulating corticoids after exposure to these chemicals (Neal et al., 1979), Van Logten et al. (1980) have shown that the lethality of TCDD is not mediated by a process involving the adrenal. A decrease in serum estradiol and progesterone has been reported in rhesus monkeys exhibiting reproductive dysfunction as a result of TCDD (Barsotti et al., 1979) and PBB (Lambrecht et al., 1978).

Blood electrolyte, PO_2 and PCO_2 levels are usually within normal range until late in the toxic syndrome where changes may be observed which reflect the moribund condition of the host.

In summary the use of clinical chemistry analyses, while of value in establishing the severity of intoxication and prognosis, are not particularly valuable for diagnostic purposes.

5.2.4. Lesions

The lesions (Tables 5.3 and 5.4) produced by these classes of compounds vary with the species of animal exposed, duration and dose of exposure, and to some degree the age of the animal exposed. However, as noted before if the parameters of exposure are the same, including the same relative toxic dose of the chemicals, the lesions are usually comparable within the same species of animal for all these classes of compounds (McConnell and Moore, 1979; Nishizumi, 1978).

In the experimental setting involving acute exposures the spectrum of lesions may be meager (quantitatively and qualitatively). Loss of body fat and change in organ weight (Table 5.3) may be the most striking features (Harris et al., 1973). In all experiments involving immature animals, the size and weight of the thymus will be

TABLE 5.3

Organ weight changes produced by related halogenated compounds.

Brain	—	
Heart	↑	Relative to body weight only
Lung	—	
Liver	↑	At lethal and sublethal doses
Spleen	↓	At high doses
	↑	At low doses
Thymus	↓↓	
Kidney	↑	Absolute weight only
Adrenal	↑	Relative to body weight and in lethal studies only
Testicle	↓	Varies with animal species; at lethal doses only

Key: — No change. ↑ Mild to ↑↑ moderate increase. ↓ Mild to ↓↓ marked decrease.

MONS 225380

TABLE 3.4
Lesions produced by related halogenated compounds.

	Acute	Chronic	Comments
1. Thymus (involution)	severe	severe	applicable in young animals only
2. Spleen (atrophy)	mild	minimal	not observed in sublethal exposures
3. Bone marrow (atrophy)	severe	moderate	less apparent in sublethal exposures
4. Liver			
necrosis	minimal to marked	minimal to moderate	species related
intrahepatic bile duct hyperplasia	none	minimal to moderate	species related
5. Gall bladder (hyperplasia)	acute	minimal to severe	species related
6. G.I. tract (hyperplasia – stomach and colon)	none to minimal	none to severe	species related
7. Urinary tract (hyperplasia)	none to moderate	none to severe	species related
8. Skin and sebaceous glands (hyper- and metaplasia)	none	none to severe	species related; present in rabbits with dermal exposure
9. Testicle (atrophy)	minimal to severe	minimal to severe	less apparent in sublethal exposures
10. Neoplasms		liver, and to a lesser extent oral cavity, nasal turbinates and lung	

MONS 225381

markedly less than the controls (Fig. 5.5). If death occurs the thymus may be only 1/4 to 1/5 normal size (Gupta et al., 1973; McConnell and Moore, 1979; Ringer and Polin, 1977). Microscopically, the reduction in size is reflected almost entirely as a loss in the cortical lymphocytes (Fig. 5.6). This lesion has been referred to as thymic atrophy or involution, but time-course studies have shown that the pathogenesis of the lesion actually involves necrosis of lymphocytes and may be seen very early in the toxic syndrome. Thymic effects are even more dramatic in the offspring of dams exposed to these compounds during gestation and lactation (Faith and Moore, 1977). The clinical ramifications of this lesion are expressed by changes in the immune system (see Chapter 9).

Other lymphoid tissues are less affected. The weight of the spleen and size of the gut associated lymphoid tissue (Peyer's patch) are often reduced in animals that are exposed to lethal levels of these chemicals. Microscopically, the reduction in the size of the spleen is due to a reduction in the size of the germinal centers, primarily due to a reduction in the periarterial lymphoid sheath (PALS) portion (Vos and Moore, 1974). In contrast, at lower doses the spleen may actually be increased in size due to an increase in the amount of white pulp.

Hypoplastic changes have also been observed in the bone marrow (Allen and Carstens, 1967), and diffuse loss of bone marrow of a severe magnitude has been reported in animals which die from exposure to these chemicals (McConnell et al., 1978b). In chronic low level exposures the hypoplastic changes are not as apparent but the persistent anemia and an increase in the myeloid/erythroid (M/E) ratio suggest that a definite effect on bone marrow is present (McConnell et al., 1978a). The increased M/E ratio has been attributed to a selective effect on the erythroid stem cells or erythroid maturation process but this has not been definitively studied. In fact, information on bone marrow toxicity by these compounds is a relative void which needs to be pursued in the context of altered host defense (Thigpen et al., 1975) and immunological manifestations which are discussed in Chapter 9.

An increase in the weight of the liver may be an even more sensitive and useful indicator of toxicity from these chemicals than the thymus. Enlargement of the liver is found in all ages and species of animals studied (Kimbrough et al., 1978a) and may be observed at doses below those where significant weight effects are found in the thymus (Kociba et al., 1976). Interestingly, an increase in liver weight is observed in all animals, even in those species where liver lesions are minimal such as the guinea pig, cow, and monkey (McConnell et al., 1978a, 1978b). The morphologic explanation for hepatomegaly is hepatocellular hypertrophy and possibly hyperplasia (Young et al., 1978). Some hepatocytes are 5 times normal size due primarily to an increase in cytoplasm (Fig. 5.7). In rats multinucleated (4–30 nuclei) hepatocytes have been reported as a result of exposure to TCDD (Greig et al., 1973; Gupta et al., 1973; Jones and Butler, 1974) and PBBs (Gupta and Moore, 1979). The multinucleated cells are felt to be a degenerative change whereby several cells coalesced with fusion of cytoplasmic membranes (Jones and Butler, 1974). The ultrastructural basis for hepatocyte enlargement is due to a large extent to proliferation of en-

MONS 225382

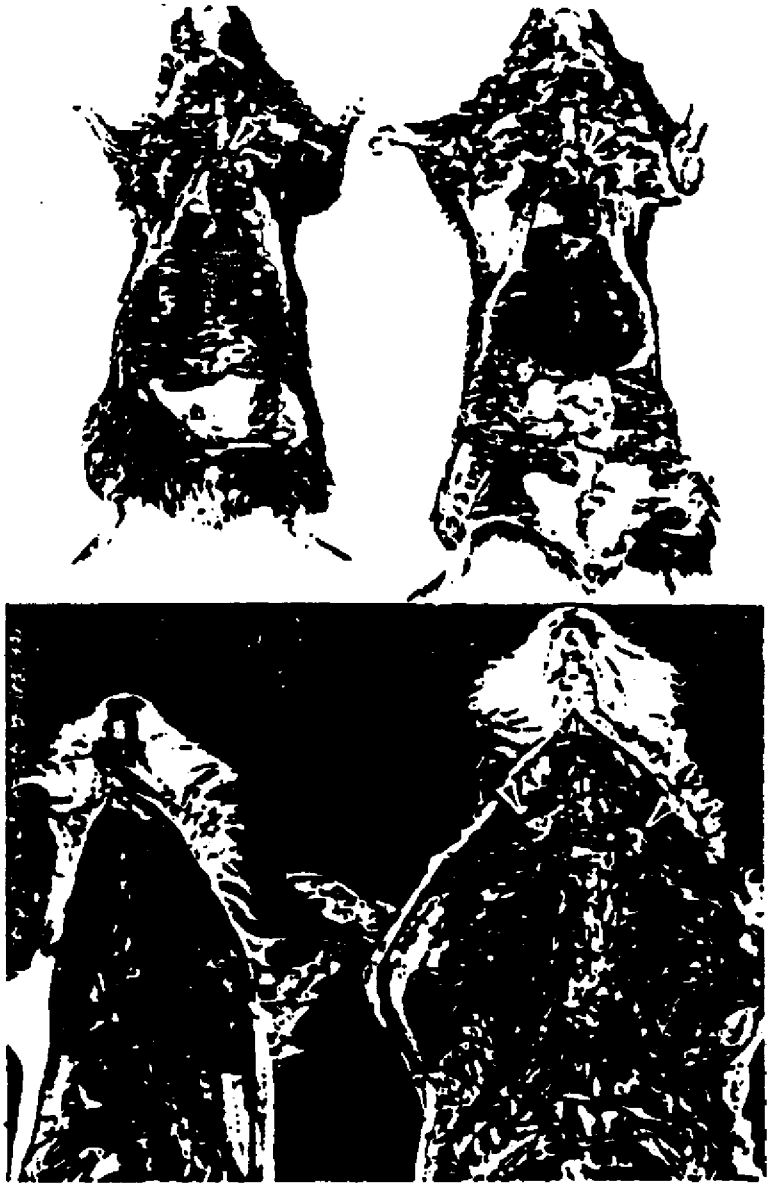

Fig. 5.5. Top: control (right) and TCDD-exposed mouse (left). Note the lack of body fat, mottled liver and extremely small thymus (arrow) in treated mouse. The thymus should fill the anterior thorax and extend over the base of the heart as seen in the control mouse. Bottom: control (right) and TCDD-exposed guinea pig (left) showing marked atrophy of the thymus. Note that the location (just posterior to the mandible) of the thymus (arrows) in the guinea pig is different than most species of animals.

MONS 225383



Fig. 5.6. Photomicrographs showing progressive stages of involution of the thymus from guinea pigs exposed to hexa-CDD. Top left: normal thymus showing dark highly cellular cortex compared to the less dense medulla; top right: thymus 7 days after exposure to TCDD. The vacuolated areas in the cortex are macrophages which have phagocytized necrotic lymphocytes. Necrotic debris is also present within and around Hassal's corpuscles; bottom left: thymus 30 days after exposure showing almost complete loss of the cortex and necrotic debris in the medulla; bottom right: thymus 60 days after exposure. Very little necrotic debris remains and lymphocytes are starting to repopulate the cortex.

NDNS 225384

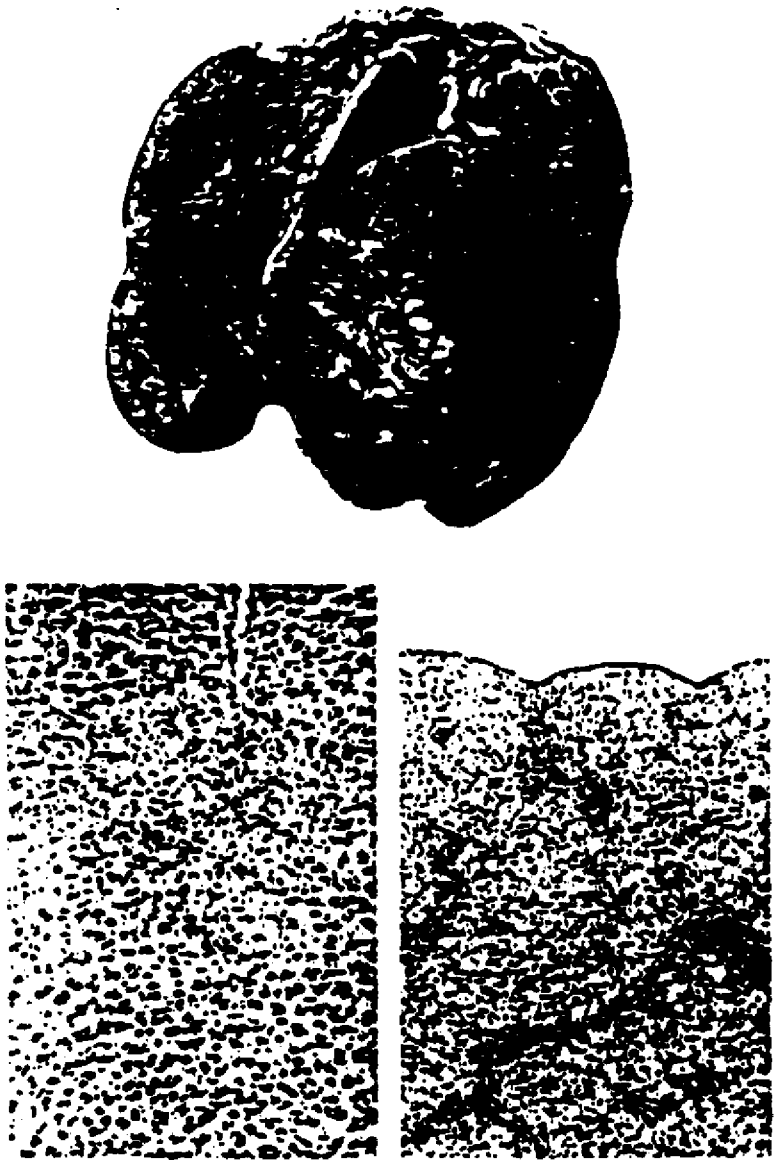

Fig. 5.7. Liver (top) from a chicken exposed to PCB showing dark hemorrhagic and necrotic areas. Photograph courtesy of Dr. Bhola N. Gupta, NIEHS. Photomicrograph (bottom left) of the liver of a rabbit exposed to PCBs shows an area of necrosis and enlarged hepatocytes. Section of liver (bottom right) from a mouse exposed to CDD shows a nodular surface due to hepatocellular enlargement. An inflammatory cell infiltrate is present along the interlobular plates.

MONS 225385

doplasmic reticulum (Fig. 5.8), especially the smooth (SER) type (Adamson and Weeks, 1973; Nishizumi, 1970; Hinton et al., 1978). An increase in the lipid content of hepatocytes is also observed, particularly in those species of animals which show overt hepatotoxicity (Vos et al., 1974). Occasionally the lipid vacuoles are surrounded by concentric laminated SER (Kimbrough et al., 1972).

The most severe liver lesions occur in rabbits (Vos and Beems, 1971) and chickens (Vos and Koeman, 1970). In acute lethal exposures large areas of necrosis with hemorrhage (Fig. 5.7), fatty change and hyaline degeneration are found randomly distributed throughout the hepatic parenchyma and are often apparent on macroscopic examination (Schultz, 1957). In more chronic exposures similar but less severe changes are observed with the additional finding of varying degrees of intrahepatic bile duct hyperplasia. In rodents hemorrhage is not a prominent feature and necrosis is usually in the form of a scattered single cell variety, especially near the central vein with subsequent fibrous proliferation (Jones and Butler, 1974). Central lobular fibrosis was also noted in the horse poisoning episode previously described (Kimbrough et al., 1977). Concomitantly there is an infiltration of a mixed cell type of inflammatory cells, particularly along the lobular plates (Gupta



Fig. 5.8. Electron micrograph from the liver of a control cow (left) and one exposed chronically to CDDs and CDFs. Note the marked proliferation and dilatation of the smooth endoplasmic reticulum (arrows). N = nucleus, M = mitochondria. Dark granules are glycogen.

MONS 225386

and Moore, 1979). A brownish amorphous pigment, which has been identified as ceroid (Itokawa et al., 1976), may also be observed in hepatocytes as well as in Kupfer cells of rats (Kimbrough et al., 1972). This pigment is particularly striking in PBB-exposed rodents (Kimbrough et al., 1978a). Liver lesions in rodents appear to be very persistent and have been observed 14 months after a single exposure to PBBs (Kimbrough et al., 1978b). Secondary (indirectly related to toxemia) effects such as bacterial or parasitic hepatitis may be more severe in intoxicated animals and in this way distort or complicate the interpretation of liver lesions in "field" exposures. The carcinogenic potential of these compounds for the liver will be discussed later in this chapter.

The use of long wavelength (366 nm) ultraviolet light on tissues (particularly the liver) from intoxicated mice, rats and birds for the presence of red fluorescence as an indication of excess porphyrin accumulation is often useful in establishing the degree of intoxication (Gupta et al., 1980). The more toxic isomers of these compounds are some of the most potent porphyrinogenic chemicals ever studied (Goldstein, 1979; Goldstein et al., 1973). The porphyrinogenic potential of these compounds is discussed in depth in Chapter 8.

The extrahepatic biliary system appears to be a target for intoxication from these classes of chemicals in certain species of animals. This is most evident in those species of animals which show the least liver toxicity. The monkey (McConnell et al., 1978a; Moore et al., 1979) and to a lesser degree cattle (Sikes and Bridges, 1952; McConnell et al., 1980), sheep (Gutenmann and Lisk, 1975) and horses (Kimbrough et al., 1977) show marked hyperplasia and hypertrophy of the epithelium lining either or both the common bile duct and gall bladder (Fig. 5.9). Again, this lesion is time–dose related. One explanation for this lesion may be due to the fact that a principle route of elimination of these chemicals and their metabolites is via the bile (Matthews and Kato, 1979). Perhaps the biliary epithelium in these animal species is particularly sensitive to these chemicals.

The only other organ which shows a dramatic weight effect is the testicle. While the male in all species of animals appears to be more resistant (higher LD_{50}) to the overall toxicity of these compounds, the testicle often shows dramatic changes especially in lethally exposed animals (McConnell et al., 1978b). The lesion varies from almost complete atrophy of seminiferous components to the development of abnormal (multinucleated) types of cells (Fig. 5.10). Interstitial (Leydig) cells are unaffected. The reproductive ramifications of this phenomenon will be discussed later in this chapter.

Overall these toxic compounds seem to have a predilection to cause pathological changes in epithelial tissues, both cutaneous and internal. This is particularly apparent in nonhuman primates and is noteworthy in this species in that the lesions mimic to some degree what is observed in humans.

The clinical picture of the cutaneous manifestations of intoxication in nonhuman primates have been described earlier. They are extremely important because of their unique qualities which make them useful in a diagnostic setting, especially changes

NONS 225387



Fig. 5.9. Gall bladder mucosa from a control monkey (left) and from one exposed to a lethal amount of TCDD. The epithelial lining in the treated monkey is markedly hyperplastic with inflammation and the formation of mucous-filled cysts.

in the Meibomian glands of the eyelid. In fact, lesions of the eyelid are the most sensitive morphologic indication of intoxication in monkeys. In general the microscopic changes observed in the skin (chloracne), eyelids and ear canal have a common pathogenesis (McConnell et al., 1979). They are all related to changes in sebaceous or modified sebaceous glands as the case may be and associated hair follicles. In essence the sebaceous glands undergo atrophy with a metaplastic change to a keratinizing form of stratified squamous epithelium (Fig. 5.11). Later, all that remains is the central duct which enlarges due to impaction with keratinaceous debris, and it may eventually rupture with secondary granulomatous inflammation. Therefore, the function of the oily secretions normally provided by these glands is abated and leads to the clinical manifestations of dry skin, chloracne, excess lacrimation, photophobia and crusty debris in the external auditory canal (Fig. 5.11). Concomitantly, there is hyperkeratosis of hair follicles with resultant dilatation (Fig. 5.11). The reported appearance of a dull hair coat and alopecia which have been reported in spontaneous poisonings by these chemicals in horses and cattle may also be related to changes in the hair follicles and sebaceous glands, but this has not been studied in the same depth as in monkeys and rabbits. Severe as these lesions may be, they are apparently reversible if exposure ceases (McNulty, pers. comm.).

Hyperkeratosis of the skin is also reported and is best exemplified in the

MONS 225388

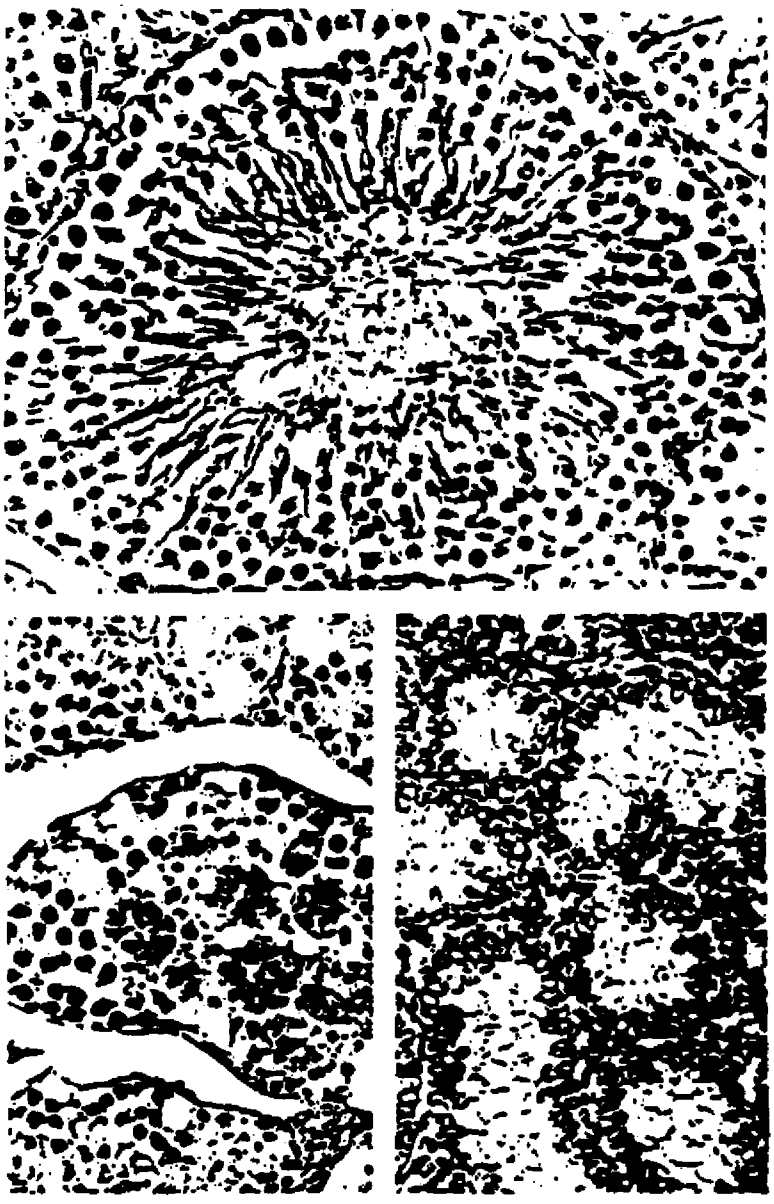

Fig. 5.10. Seminiferous tubule from an untreated animal (top), CDD-treated mouse (lower left) and BN-treated guinea pig (lower right). Necrosis and giant cell formation of seminiferous components are observed in mice while atrophic changes are more characteristic in guinea pigs. Relatively high (lethal) levels of these chemicals are required to produce testicular lesions of this magnitude.

NONS 225389

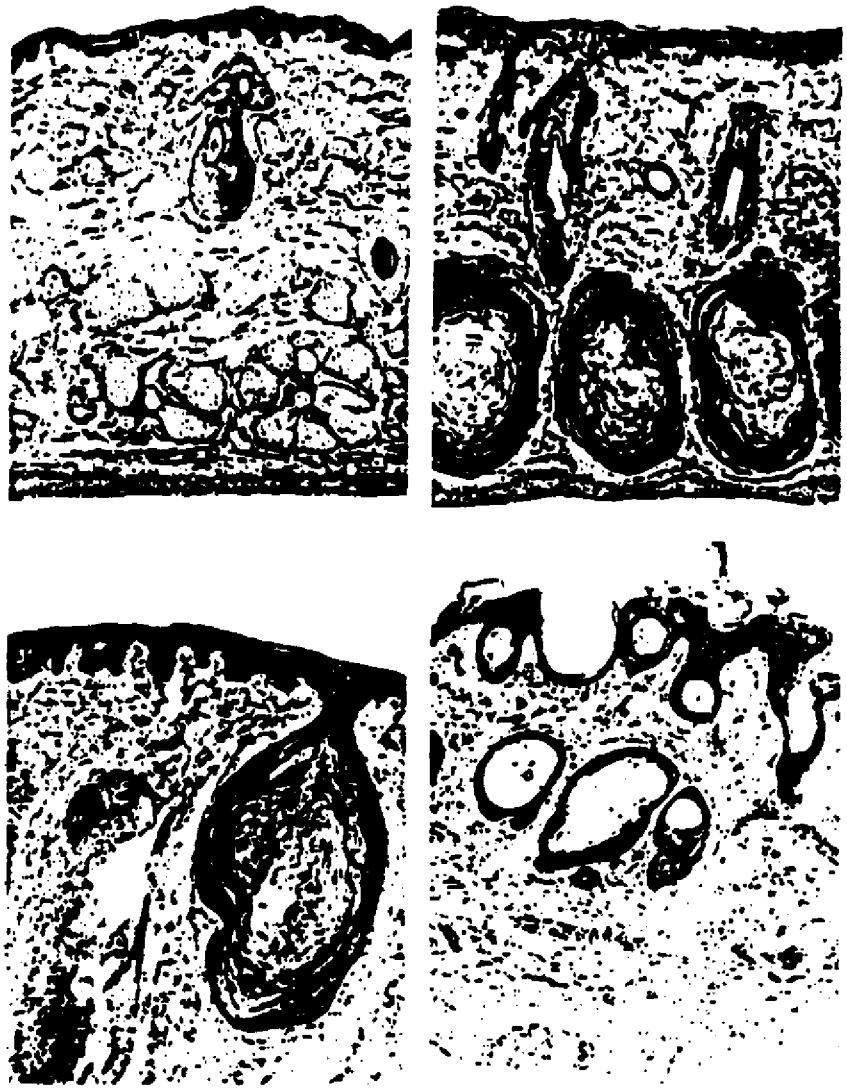

Fig. 5.11. The microscopic appearance of the effects of CDD and CDF on the eyelids, skin, and ear canal of rhesus monkeys. The ducts of the meibomian glands of the eyelid from a monkey exposed to TCDD (top right) are hyperkeratotic, dilated and filled with keratinaceous debris. The sebaceous portions of the glands have undergone complete atrophy. Compare to a similar section of normal eyelid (top left). A hair follicle (bottom left) from the face of a monkey exposed to TCDF shows a similar lesion and is referred to as chloracne. The external auditory canal (bottom right) from a monkey exposed to TCDF shows a similar lesion of the ceruminous glands.

MONS 225390

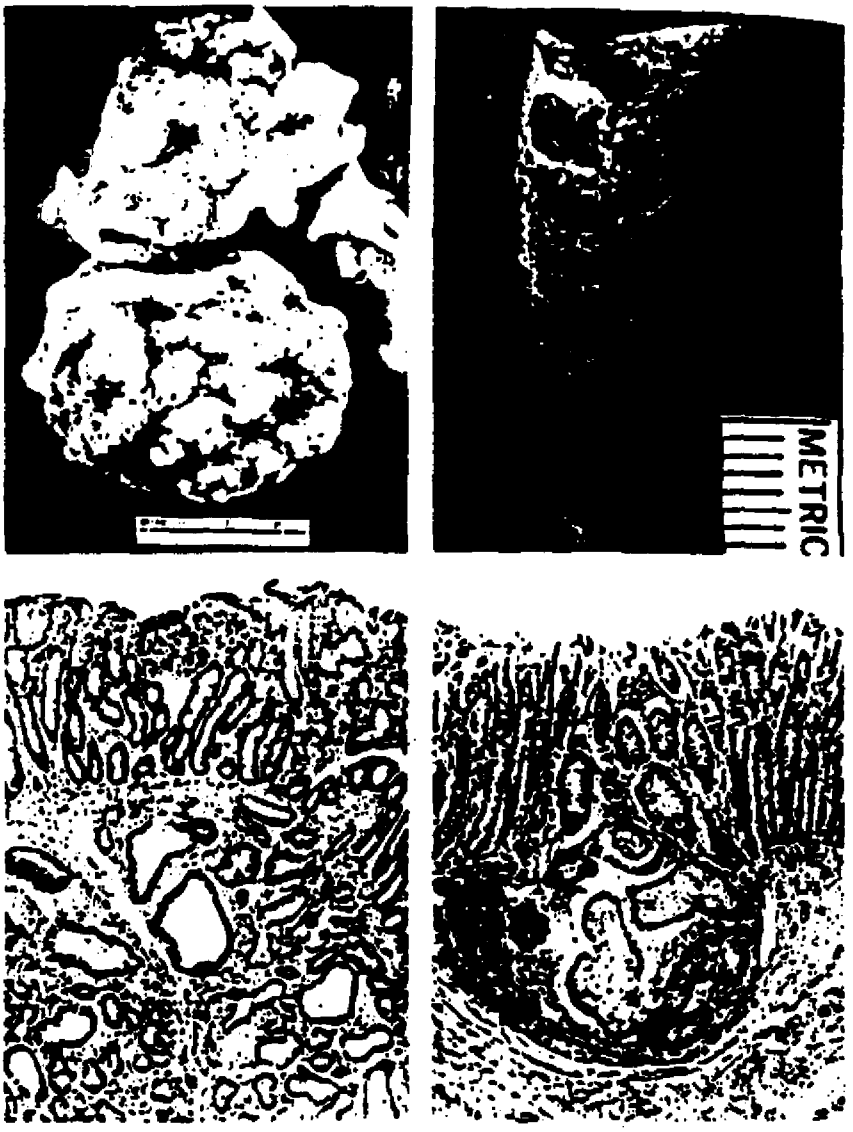

Fig. 5.12. Gross (top left) and subgross (top right) appearance of the stomach of a monkey exposed to PCBs. The mucosal surface is rough and thickened with pitted ulcerated areas. The cut surface shows marked thickening (top portion) with cysts near the base. The bottom portion is of normal thickness for comparison. The photomicrograph from the stomach of a monkey exposed to TCDF (bottom left) shows cystic dilatation of the crypts with downgrowth beneath the lamina propria. The colon (bottom right) shows a similar but less severe lesion.

MONS 225391

'X-disease' problem that occurred in cattle exposed to highly chlorinated naphthalenes (Olafson, 1947), although it is found to lesser degrees in other animal species showing skin lesions. In affected areas the cornified epithelium becomes markedly thickened with the accumulation of exuberant amounts of keratin.

It has been suggested that these lesions mimic to some degree those observed in vitamin A deficiency (Kimbrough, 1974) and, in fact, cattle exposed to PCNs have lower levels of serum vitamin A (Marsh et al., 1956). Monkeys dying of PCB toxicity also showed a reduction in vitamin A stores of the liver although serum levels were in the normal range (McConnell et al., 1979). This mechanistic theory has not been studied in depth; however, the author found that parenteral injection of high levels of retinoic acid did not alter the LD_{50} in guinea pigs. Perhaps there is a defect in the ability of the host to utilize vitamin A at the cellular level.

The epithelial tissues of the alimentary tract also show lesions, especially in the nonhuman primate. A most striking lesion is observed in the stomach of monkeys exposed chronically to all classes of these compounds (Allen et al., 1974, 1977; Lushbaugh, 1947; Moore et al., 1979). Large multiple papillary neoplastic-like growths, almost fungoid in shape, develop in the glandular portion of the stomach (Fig. 5.12). Areas of ulceration are often found within and between these growths. The microscopic appearance of this growth is characterized by hyperplasia and metaplasia. The mucosa is often several times normal thickness (Fig. 5.12), but with a minimal amount of disorganization. The glands are composed almost entirely of mucous cells having replaced the parietal cells which remain only at the base of the glands (Becker et al., 1979). Exuberant mucous production is evident with dilatation of crypts and at times a cyst-like appearance. This glandular tissue often grows downward in an aggressive fashion into the subjacent lamina propria, again with the formation of cysts (Fig. 5.12). However, there has never been any observation of vascular invasion or metastases. Variable amounts of submucosal edema and inflammation add to the thickened appearance. Areas of ulceration, hemorrhage and inflammation are often found within the lesion. While the mucosa between the growths may be of normal thickness, it also is devoid of parietal cells, again having been replaced by mucous cells. This hypertrophic lesion often extends a short distance into the duodenum.

In monkeys this lesion has been referred to as 'Simian gastropathy' (Scotti, 1973) and is of extreme diagnostic usefulness. Lesions to be considered in a differential diagnosis include the granuloma produced by the parasite *Nochtia nochti* (Boone and Sandground, 1939) and gastric carcinoma. Both are readily differentiated with standard pathological criteria.

A similar but less severe lesion has been described in the colon of monkeys exposed to these chemicals. It has been referred to as 'colitis cystica profunda' since it resembles that condition of humans (Scotti, 1975). At necropsy small focal areas of erosion and/or ulceration are suspected. Microscopically, the hyperplastic response is of an invasive nature with downgrowth of mucous epithelium into and through the lamina propria, with the formation of cysts accompanied at times with intense

MONS 225392

inflammation (Fig. 5.12). Papillary formation is not a feature of the lesion in the large intestine. This lesion has not been described in other animal species but the reported incidence of diarrhea and other intestinal disorders in domestic animals suffering from intoxication from these chemicals suggests that this lesion should be looked for.

The urinary tract appears to be quite sensitive to these chemicals in certain animal species but is relatively unaffected in others. Monkeys, guinea pigs and cattle have been reported to be affected. The basic response is hyperplasia of the transitional epithelium which may extend from the terminal portions of the collecting ducts of the renal medulla to the renal pelvis, ureter and urinary bladder (McConnell et al., 1979). The lesion does not appear to extend into the urethra. Affected collecting ducts and the renal papillae are lined by 3 to 4 cell layers as compared to the normal 1 or 2. A similar doubling or even tripling of the number of epithelial cells is found in the renal pelvis, ureter and urinary bladder (Fig. 5.13). A striking severe papillary hyperplasia has been reported in the urinary bladder of cattle exposed to pentachlorophenol (PCP) contaminated with dioxins and furans (McConnell et al., 1980). The urinary bladder lesion was attributed to the contaminants since it was not observed in cattle exposed to an equal amount of pure PCP.

Kidney lesions have been described with some of these compounds, especially the terphenyls (Adamson and Weeks, 1973). The primary effect is on the epithelial cells lining the proximal convoluted tubules. The earliest change is disruption and distortion of mitochondria followed by necrosis. However, in most studies kidney lesions are not apparent, at least with light microscopy.

While the urinary tract changes are of considerable diagnostic value, they are somewhat subtle and usually require careful examination of the tissues to be recognized. It has been postulated that this hyperplastic response or lack of it may be related to animal species differences in the rate and route of elimination of these chemicals from the body (McConnell et al., 1978b). For example, it is known that monkeys secrete a higher proportion of a given dose of TCDD via the urine than rats which do not exhibit this lesion (Van Miller et al., 1976).

Another lesion of diagnostic significance (at least in avian species) is the presence of fluid accumulation, i.e., edema, ascites, hydropericardium and to a lesser extent hydrothorax (Norback and Allen, 1973). In fact, it is this lesion which leads to the term 'chick edema disease' as noted before. Affected birds may show massive accumulation of clear and at times gelatinous fluids in the body. Microscopically the fluid is acellular with fine strands of fibrin.

Changes in the thyroid and decreased thyroxine levels (as noted before) have been reported in some species of animals exposed to these classes of chemicals (Collins et al., 1977; McConnell et al., 1980; Sleight et al., 1978). The associated morphologic changes reported were the presence of smaller thyroid follicles in both rats exposed to PCBs and cattle exposed to dioxins. Ultrastructural examination of the follicular epithelium of PCB-exposed rats revealed projections of cytoplasm into the adjacent colloid which were interpreted as compensatory hypertrophy in response to the lowered thyroxine levels (Collins et al., 1977).

MONS 225393



Fig. 5.13. Photomicrographs of the renal papilla from a normal guinea pig (top left) and one exposed to a lethal dose of CDD (top right). Note the marked hyperplasia of the pelvic epithelium. This hyperplastic response is also evident in the urinary bladder of guinea pigs exposed to these types of chemicals. (Bottom left: low magnification; bottom right: higher magnification.)

MONS 225394

Other lesions are less specific and often are the result of general debilitation. All animals dying of intoxication show a striking lack of body fat, and that still present often shows serous atrophy. Often the animals appear as if they had starved to death, although they usually eat and drink to some degree until just prior to death when they become too weak to do so. Hemorrhage (subcutis, gastrointestinal tract, heart, liver and adrenal gland) has also been described in some species and it has been suggested that the compounds interfered with clotting mechanisms due to decreased numbers of platelets in these cases. However, data is meager in support of these claims. Atrophy of the zona glomerulosa of the adrenal cortex in guinea pigs has been reported in lethal exposure of dioxins but it is not observed in animals exposed to the same dose which survive (McConnell et al., 1978b).

In summary, the lesions produced by these agents are similar within a given species of animal provided the same relative dose is used over the same period of time. While the pathologic syndrome differs to some degree with the length of exposure, the difference is more quantitative than qualitative. Also, in natural outbreaks of toxic exposure the disease syndrome may differ from that observed in the experimental setting owing to exposure to mixtures of chemicals and the presence of secondary infectious or nutritional factors. Tissue levels (especially fat and liver) may be of some use in establishing exposure but may be of little value in proving causation of disease.

Reviews. General reviews on the toxicity of these classes of compounds include:

1. Aust and Shull, 1978
2. Brinkman and Reymer, 1976
3. Buckley, 1976
4. Delvaux et al., 1975
5. DiCarlo et al., 1978
6. Fishbein, 1974
7. Jamieson, 1977
8. Kimbrough, 1974
9. Kover, 1975
10. McConnell and Moore, 1979
11. Moore, 1973, 1978a, 1978b
12. Nicholson and Moore, 1979
13. Ramel, 1978
14. Sandermann, 1974
15. Syrowatka and Jurek, 1975
16. Young et al., 1978

5.3. Carcinogenesis

The carcinogenic potential of PCBs (Allen and Norback, 1977) and dioxins (Kimbrough, 1979) have been studied but this information on dibenzofurans,

MONS 225395

naphthalenes or terphenyls is not available. PCBs have been shown to produce hepatocellular carcinomas and neoplastic nodules in rats (Kimbrough et al., 1975; Kimura and Baba, 1973) and hepatomas in mice (Kimbrough and Linder, 1974). Interestingly, the appearance of liver tumors in rats (Ito et al., 1974) and mice (Nagasaki et al., 1972) caused by Japanese commercial mixtures of PCBs (Kanechlor 300, 400, 500) is somewhat proportional to the degree of chlorination: conforming to the relatively greater general toxicity of the higher chlorinated mixtures. Kanechlors have also been shown to promote the induction of tumors by benzene hexachloride (Nobuyuki et al., 1973). Rats exposed to American PCBs (Aroclors) also showed a carcinogenic response of the liver of rats (Kimbrough et al., 1975) and mice (Kimbrough et al., 1974). A single oral exposure of 1 g/kg of PBBs has also been shown to cause liver tumors in rats (Kimbrough et al., 1978b).

Adenofibrosis (cholangiofibrosis), a lesion consisting of a mixture of proliferating fibrous connective tissue and bile ducts has also been observed in rats (Kimbrough et al., 1972, 1973) and mice (Kimbrough and Linder, 1974) exposed chronically to PCBs. While the significance of this lesion is not known and it is technically a non-neoplastic lesion, it often occurs concomitantly with hepatocellular carcinoma in rodents (Kimbrough, 1979) and therefore deserves mention under this subject. The carcinogenic potential of PCBs for other organs of the body has not been demonstrated.

Dioxins, specifically TCDD has also been shown to be carcinogenic in rats with females showing a higher incidence of tumors at a given dose. In addition to liver tumors, neoplastic lesions in the lungs and oral and nasal epithelia were also observed (Kociba et al., 1978, 1979; Van Miller et al., 1977). No carcinogenic response was observed in mice exposed to a single toxic dose of TCDD (100 μg/kg) and then held for 35 weeks (Kouri et al., 1978). However, 35 weeks is not long enough to test carcinogenicity. TCDD also did not show any tumor initiating capacity in the two-stage mouse skin system (DiGiovanni et al., 1977).

In summary, those classes of compounds studied show a definite carcinogenic potential, particularly for the liver. In addition, the carcinogenic potential appears to parallel the general toxicity of the various isomers. Kimbrough (1979) has reviewed the carcinogenic potential of these compounds.

5.4. Reproduction

The reproductive effects from intoxication with these classes of chemicals have been studied in depth with only the dioxins and PCBs. Little or no information is available on the furans, naphthalenes and terphenyls. Additionally, while a great deal of information can be found on the reproductive effects in females, very little work has been done on male animals. Considering the fact that primarily men are at risk in the work place, definitive studies on the effects on the reproductive capacity of male animals are needed.

The first reported suggestion of reproductive dysfunction as a result of intoxica-

NOMS 225396

tion with these compounds was observed in a study of women exposed during [illegible] to PCBs in Yusho, Japan (Kuratsune, 1976) (see Chapter 9B) for details of this incident. Following this, several studies were conducted in rhesus monkeys to assess the reproductive effects of PCBs, PBBs and CDDs. In general, the results were similar for the three compounds (Allen et al., 1979).

The earliest indication of adverse reproductive effects in female monkeys is an elongation of their menstrual cycles with an increase in menstrual bleeding. Females then show an inability to conceive when bred to untreated males or there are early abortions and resorptions. Offspring may be born dead or are weak and smaller than normal at birth (Barsotti et al., 1976; Lambrecht et al., 1978). Necropsy examination of these infants shows typical hypoplastic lesions in the thymus, spleen and bone marrow as described earlier in this chapter. If surviving offspring are allowed to nurse their mothers, the cutaneous manifestations and typical clinical syndrome become rapidly apparent with the associated lesions in the skin, eyelids and stomach (Allen and Barsotti, 1976). The progressive nature of the syndrome in the infants has been attributed to excretion of the compounds in milk (Barsotti and Allen, 1976). If the infants are removed from their exposed mothers and placed on milk replacer, they show a gradual improvement (Carstens et al., 1979) although they still may show abnormal behavioral development (Bowman et al., 1978).

If the female monkeys are removed from the experimental diet they eventually regain their reproductive capacity, although offspring still tend to be smaller than normal and experience a greater frequency of spontaneous diseases normally found in primate facilities (Allen et al., 1979). A PCB poisoning outbreak in a primate production facility has been described (Altman et al., 1979) which closely mimics the reproductive problems described experimentally. In this case, the monkeys also slowly recovered after the source of exposure was removed.

As noted before, there is a meager amount of information on the reproductive dysfunction in male animals. However, as part of the above studies in female monkeys, a limited evaluation of male reproductive function was conducted with PCBs and TCDD. In summary, decreased sperm counts and male infertility were observed, but it required a higher dose of a given chemical to produce this effect than in female monkeys (Barsotti et al., 1976). Microscopic examination of testicular tissue from these animals revealed a marked reduction of seminiferous components with normal appearing interstitial tissue (Allen and Carstens, 1967). Complete recovery was noted after a period of 12 months in the PCB-exposed monkeys; recovery in TCDD-exposed animals was not studied (Allen et al., 1979). Degenerative testicular lesions have also been observed in rodents exposed to these compounds, but relatively high doses are required to produce this effect (McConnell and Moore, 1979). A rapid decrease in semen quality followed by a complete absence of sperm was observed in a bull following feeding of chlorinated naphthalenes (Vlachos et al., 1955).

A severe decrease in the reproduction rate of mink was observed in commercial ranches which fed a diet containing fish contaminated with PCBs (Auerlich et al.,

NONS 225397

1971; Platonow and Karstad, 1973). This has subsequently been substantiated experimentally in mink using fish spiked with PCBs at a level found in commercially available fish (Jensen et al., 1979). This additional evidence shows that mink are extremely sensitive to these classes of chemicals. Similarly, it has been suggested that PCBs may be responsible for the drastic decrease in the number of seals in the Baltic Sea due to a decrease in the reproductive abilities of exposed animals (Jensen et al., 1979).

Single and multiple generation studies of TCDD in rats revealed dose-related alterations in reproductive capacity which included decreases in litter size (number) at birth, gestation survival (proportion of pups born alive), and neonatal survival and growth (Khera and Ruddick, 1973; Murray et al., 1979). Cross-mating studies did not show any interference with male fertility (Murray et al., 1979). Some of this reproductive dysfunction may be related to morphologic alterations in the ovaries and uterus (Kociba et al., 1976).

PCBs, PBBs and CNs have been shown to cause a decrease in egg production, hatchability and viability of chicks from exposed chickens (Keplinger et al., 1971; Polin and Ringer, 1979; Pudelkiewicz et al., 1959) and other birds (Dahlgren and Linder, 1971). Eggs from exposed birds contain a relatively high amount of these chemicals compared to other tissues of the body, and this may represent a significant method of decreasing the body burden in avian species.

In summary, these classes of compounds have a profound depressive effect on reproductive capacity, especially in female animals. In most species fetal wastage is more of a problem than fertility, and those offspring born from exposed mothers are abnormally small and weak. Allen et al. (1979) reviewed the reproductive effects of these chemicals in primates.

5.5. Teratology

The first indication that these compounds had teratologic potential was in the study of 2,4,5-trichlorophenoxyacetic acid (2,4,5-T) in mice and rats (Courtney et al., 1970). This study showed that commercial 2,4,5-T caused cleft palate and cystic kidneys in the offspring, but subsequently it was clearly shown that this teratogenic effect was primarily due to contamination of the 2,4,5-T with TCDD rather than 2,4,5-T itself (Courtney and Moore, 1971), which in its analytical form requires very high doses to produce this effect (Neubert and Dillman, 1972). There is also preliminary evidence that TCDD causes similar developmental anomalies in the soft palate of monkeys (Zingeser, 1979).

Several reproductive and teratogenic studies have been conducted with PCBs (particularly the Aroclors), but in contrast to their definite deleterious effects on reproduction, malformations have not been encountered (Keplinger et al., 1971; Villeneuve et al., 197); Curley et al., 1973). A possible exception to the negative teratogenic results of PCBs was a study in chickens where Aroclor 1242 was injected into the yolk sac of the egg (McLaughlin et al., 1963). The chicks derived from these

MONS 225398

eggs showed various bony anomalies of the head. An embryotoxicity study [illegible] relatively high levels of PBBs in rats also failed to demonstrate teratogenicity (Yoshimura et al., 1972).

One of the more important results of intoxication by these compounds in the [illegible] and offspring of exposed mothers is the effect on neonatal growth and development. In every study where this has been evaluated, the offspring do not survive as well, grow at a slower rate and are retarded in their development (Kimbrough et al., 1978a). Development of the immune system is particularly suppressed (Faith and Moore, 1977; Vos and Moore, 1974). In addition to in utero exposure, offspring are exposed to significant amounts of these chemicals via their mothers milk. In fact, lactation is one of the most efficient methods for mammals to reduce their body burden of these chemicals (Gutenmann and Lisk, 1975). Dioxins have been found in the milk of cows long after exposure ceased (Firestone et al., 1979).

In summary, there is some variance in the teratologic potential of these compounds and it is difficult to make generalizations because information is lacking on CNs, CDFs and terphenyls. The teratogenic potential of these latter compounds would depend to some degree upon their ability to cross the placenta and accumulate in the fetus. This aspect is discussed in Chapter 4.

5.6. Mutagenicity

Most of the information available on the mutagenic potential of these chemicals is on the CDDs, specifically TCDD. Unfortunately, the results are somewhat ambiguous in that some studies show TCDD to be a mutagen while other experiments suggest the opposite (Wassom et al., 1977/1978).

A dominant lethal assay in rats was negative, even at doses of TCDD which were clearly toxic to the dams (Khera and Ruddick, 1973). A cytogenetic study of bone marrow cells from rats given graded doses of TCDD orally showed a dose-related increased incidence of cells with chromosome breaks in both male and female animals although the mitotic index was normal (Green et al., 1977). Cytological studies using cells from the African blood lily showed that TCDD caused a dramatic inhibition of mitosis (Jackson, 1972).

In vitro studies of TCDD in *E. coli* Sd-4 showed a reversion to streptomycin independence, a base-pair substitution mutation (Hussain et al., 1972). However, in the same study, using another base-pair substitution strain, *S. typhimurium* TS-1530 was not mutated but a frameshift mutation in *S. typhimurium* TS-1532 was observed. A subsequent study with *S. typhimurium* TS-1532 substantiated that TCDD was mutagenic in this strain but was equivocal or not mutagenic in other strains (Seiler, 1973). Less toxic dioxin isomers have not been found to be mutagenic to date (Commoner, 1976; Green and Moreland, 1972).

Single PCB isomers have only rarely been studied for their mutagenic potential. However, several commercial preparations have been investigated and, as with the dioxins, the results are not clear-cut. Dominant, lethal mutations were not observed

MONS 225399

in rats (Green et al., 1975b), nor were chromosomal aberrations found in the bone marrow and spermatogonia of rats (Green et al., 1975a) exposed to relatively high levels of Aroclor 1242 and 1254. Also, no chromosomal aberrations were found in human lymphocyte cultures exposed to Aroclor 1254 (Huopingarner et al., 1972) although they were observed in second generation ring dove embryos exposed to the same compound (Peakall et al., 1972). Two PCB mixtures (Aroclors 1221 and 1268) and 2,2',5,5'-tetrachlorobiphenyl were studied in a bacterial system (*S. typhimurium* TA-1538) in the presence of a rabbit liver microsomal activation fraction. Aroclor 1221 and the tetra-PCB showed mutagenic activity while Aroclor 1268 did not (Wyndham et al., 1976).

Fewer mutagenicity studies have been conducted with PBBs. An absence of chromosomal aberrations with PBB (FireMaster) and a lack of C-mitosis synergism of PBB and colchicine was reported in male mice (Wertz and Ficsor, 1978). However, synergism of PBB with colchicine for mitotic arrest was observed in the bone marrow of rats using a similar experimental design (Fiscor and Wertz, 1976). 4-Bromobiphenyl was found to be highly mutagenic in *S. typhimurium* TA-1538 after metabolic activation with a liver microsomal enzyme fraction (Kohli et al., 1978).

Mutagenic information is not available on the CDFs and CNs. In summary, it appears that the mutagenic potential of these chemicals is equivocal; at most, they would be considered weak mutagens. However, to evaluate the cytogenetics or mutagenic properties properly it would be necessary to study individual isomers because their toxicity is directly related to the structural characteristics of the chemical.

References

Adamson, I.Y.R. and Weeks, J.L. (1973) The LD_{50} and chronic toxicity of reactor terphenyls. Arch. Environ. Health 27, 69–73.

Aftosmis, J.G., Culik, R., Lee, K.P., Sherman, H. and Wartiz, R.S. (1972) Toxicology of brominated biphenyls. I. Oral toxicity and embryotoxicity. Toxicol. Appl. Pharmacol. 22, 316.

Allen, J.R. and Barsotti, D.A. (1976) The effects of transplacental and mammary movement of PCBs on infant rhesus monkeys. Toxicology 6, 331–340.

Allen, J.R. and Carstens, L.A. (1967) Light and electron microscopic observations in Macaca mulatta monkeys fed toxic fat. Am. J. Vet. Res. 28, 1513–1526.

Allen, J.R., Carstens, L.A. and Barsotti, D.A. (1974) Residual effects of short-term, low-level exposure of nonhuman primates to polychlorinated biphenyls. Toxicol. Appl. Pharmacol. 30, 440–451.

Allen, J.R. and Norback, D.H. (1977) Carcinogenic potential of the polychlorinated biphenyls. In: Hiatt, H.H., Watson, J.D. and Winsten, J.A. (Eds.), Origins of Human Cancer. Cold Spring Harbor Labs, New York, pp. 173–186.

Allen, J.R., Barsotti, D.A., Van Miller, J.P., Abrahamson, L.J. and Lalich, J.J. (1977) Morphological changes in monkeys consuming a diet containing low levels of 2,3,7,8-tetrachlorodibenzo-p-dioxin. Food Cosmet. Toxicol. 15, 401–410.

NONS 225400

Allen, J.R., Lambrecht, L.K. and Barsotti, D.A. (1978) Effects of polybrominated biphenyl in nonhuman primates. J. Am. Vet. Med. Assoc. 173, 1485–1489.

Allen, J.R., Barsotti, D.A., Lambrecht, L.K. and Van Miller, J.P. (1979) Reproductive effects of halogenated aromatic hydrocarbons on nonhuman primates. Ann. N.Y. Acad. Sci. 320, 419–425.

Allman, S.H., New, A.E., McConnell, E.E. and Ferrell, T.L. (1979) Spontaneous outbreak of polychlorinated biphenyl (PCB) toxicity in rhesus monkeys (Macaca mulatta): Clinical observations. Lab. Animal Sci. 29, 661–665.

Aulerich, R.J., Ringer, R.K., Seagren, H.L. and Youatt, W.G. (1971) Effects of feeding coho salmon and other Great Lakes fish on mink reproduction. Can. J. Zool. 49, 816–818.

Aust, S.D. and Shull, L.R. (1978) Workshop on scientific aspects of polybrominated biphenyls. Environ. Health Perspect. 23, 1–367.

Barsotti, D.A. and Allen, J.R. (1976) The association of trans-placental and mammary movement of PCBs with infant morbidity and mortality. Am. J. Pathol. 82, 28a–29a.

Barsotti, D.A., Marlar, R.J. and Allen, J.R. (1976) Reproductive dysfunction in rhesus monkeys exposed to low levels of polychlorinated biphenyls. Food Cosmet. Toxicol. 14, 99–103.

Barsotti, D.A., Abrahamson, L.J. and Allen, J.R. (1979) Hormonal alterations in female rhesus monkeys fed diets containing 2,3,7,8-tetrachlorodibenzo-p-dioxin. Bull. Environ. Contam. Toxicol. 21, 463–469.

Bastomsky, C.H. (1977) Enhanced thyroxine metabolism and high uptake goiters in rats after a single dose of 2,3,7,8-tetrachlorodibenzo-p-dioxin. Endocrinology 101, 292–296.

Beatty, P.W., Holscher, M.A. and Neal, R.A. (1976) Toxicity of 2,3,7,8-tetrachlorodibenzo-p-dioxin in larval and adult forms of Rana catesbeiana. Bull. Environ. Contam. Toxicol. 16, 578–581.

Becker, G.M., McNulty, W.P. and Bell, M. (1979) Polychlorinated biphenyl-induced morphologic changes in the gastric mucosa of the rhesus monkeys. Lab. Invest. 40, 373–383.

Bell, W.B. (1953) Relative toxicity of the chlorinated naphthalenes in experimentally produced bovine hyperkeratosis (x-disease). Vet. Med. Sm. Anim. Clin. 48, 135–140.

Biocca, M., Moore, J.A., Gupta, B.N. and McKinney, J.D. (1976) Toxicology of selected symmetrical hexachlorobiphenyl isomers: I. Biological responses in chicks and mice. In: National Conference on Polychlorinated Biphenyls. EPA-560-6-75-004, Environmental Protection Agency, Office of Toxic Substances, Washington, D.C., pp. 67–72.

Boone, C. and Sandground, J.H. (1939) On the production of gastric tumors, bordering on malignancy, in Javanese monkeys through the agency of Nochtia Nochti, a parasitic nematode. Am. J. Cancer 37, 173–185.

Bowes, G.W., Mulvihill, M.J., Simoneit, B.R., Burlingame, A.L. and Risebrough, R.W. (1975) Identification of chlorinated dibenzofurans in American polychlorinated biphenyls. Nature (London) 256, 305–307.

Bowman, R.E., Heironimus, M.P. and Allen, J.R. (1978) Correlation of PCB body burden with behavioral toxicology in monkeys. Pharmacol. Biochem. Behav. 9, 49–56.

Brinkman, U.A.Th. and Reymer, H.G.M. (1976) Polychlorinated naphthalenes. J. Chromatog. Chromatog. Rev. 127, 203–243.

Brock, W.E., Jones, E.W., MacVicar, R. and Pope, L.S. (1957) Chlorinated naphthalene intoxication in sheep. Am. J. Vet. Res. 18, 625–630.

Buckley, J.L. (Ed.) (1976) National Conference on Polychlorinated Biphenyls, EPA-560-6-75-004, Environmental Protection Agency, Office of Toxic Substances, Washington, D.C., pp. 1–471.

Buu-Hoi, N.P., Pham-Huu Chanh, Sesqué, G., Agum-Gelade, M.C. and Saint-Ruf, G. (1972a) Enzymatic functions as targets of the toxicity of 'dioxin' (2,3,7,8-tetrachlorodibenzo-p-dioxin). Naturwissenschaften 59, 173–174.

MONS 225401

Buu-Hoi, N.P., Pham-Huu Chanh, Sesque, G., Agum-Gelade, M.C. and Saint-Ruf, G. (1972b) Organs as targets of 'Dioxin' (2,3,7,8-tetrachlorodibenzo-p-dioxin) intoxication. Naturwissenschaften 59, 174–175.

Cagen, S.Z. and Gibson, J.E. (1978) Stimulation of biliary function following polybrominated biphenyls. Environ. Health Perspect. 23, 233–239.

Carrell, J.S., Webb, N.C. and Mabis, A.J. (1969) Identification and crystal structure of a hydropericardium-producing factor: 1,2,3,7,8,9-hexachlorodibenzo-p-dioxin. Acta Crystallogr. Sect. B. 150–156.

Carstens, L.A., Barsotti, D.A. and Allen, J.R. (1979) Exposure of infant rhesus macaques (Macaca mulatta) to polychlorinated biphenyls. In: Animals as Monitors of Environmental Pollutants. National Academy of Sciences, Washington, D.C., pp. 339–345.

Carter, C.D., Kimbrough, R.D., Liddle, J.A., Cline, R.E., Zack, M.W., Barthel, W.F., Kochler, R.E. and Phillips, P.E. (1975) Tetrachlorodibenzodioxin: an accidental poisoning episode in horse arenas. Science 188, 738–740.

Case, A.A. (1971) Shepherd's clinic: disaster. Sheep Breeder Sheepman 91, 24–26.

Case, A.A. and Coffman, J.R. (1973) Waste oil: toxic for horses. Vet. Clin. N. Am. 3, 273–277.

Collins, W.T., Capen, C.C., Kasza, L., Carter, C. and Dailey, R.E. (1977) Effect of polychlorinated biphenyl (PCB) on the thyroid gland of rats. Am. J. Pathol. 89, 119–136.

Commoner, B. (1976) Reliability of bacterial mutagenesis techniques to distinguish carcinogenic and noncarcinogenic chemicals. EPA-600/1-76-022, Environmental Protection Agency Report, Washington, D.C., pp. 1–103.

Conklin, P.J. and Fox, F.R. (1978) Environmental impact of pentachlorophenol and its products – a round table discussion. In: Rao, K.R. (Ed.), Pentachlorophenol. Plenum Press, New York, pp. 389–394.

Courtney, K.D. and Moore, J.A. (1971) Teratology studies with 2,4,5-trichlorophenoxyacetic acid and 2,3,7,8-tetrachlorodibenzo-p-dioxin. Toxicol. Appl. Pharmacol. 20, 396–403.

Courtney, K.D., Gaylor, D.W., Hogan, M.D., Falk, H.L., Bates, R.R. and Mitchell, I. (1970) Teratologic evaluation of 2,4,5-T. Science 168, 864–866.

Curley, A., Burse, V.M. and Grim, M.E. (1973) Polychlorinated biphenyls: Evidence of transplacental passage in the Sherman rat. Food Cosmet. Toxicol. 11, 471–476.

Dahlgren, R.B. and Linder, R.L. (1971) Effects of polychlorinated biphenyls on pheasant reproduction. J. Wildl. Manage. 35, 315–319.

Davidson, I. and Henry, J.B. (1969) Todd-Sanford: Clinical Diagnosis by Laboratory Methods, 14th Edn., W.B. Saunders, Philadelphia.

Dehaus, E.L., Versrraete, J., Hautfenne, A., DeSart, F. and Goffin, G. (1975) Polychlorodibenzo-p-dioxins. Toxicology 3, 187–206.

DiCarlo, F.J., Seifter, J. and DiCarlo, V.J. (1978) Assessment of the hazards of polybrominated biphenyls. PB-285/532, National Technical Information Service, Springfield, Va., pp. 1–15.

DiGiovanni, J., Viaje, A., Berry, D.L., Slaga, T.J. and Juchau (1977) Tumor-initiating ability of 2,3,7,8-tetrachlorodibenzo-p-dioxin (TCDD) and Aroclor 1254 in the two-stage system of mouse skin carcinogenesis. Bull. Environ. Contam. Toxicol. 18, 552–556.

Dunckel, A.E. (1975) An updating on the polybrominated biphenyl disaster in Michigan. J. Am. Vet. Med. Assoc. 167, 838–841.

Faith, R.E. and Moore, J.A. (1977) Impairment of thymus-dependent immune function by exposure of the developing immune system to 2,3,7,8-tetrachlorodibenzo-p-dioxin (TCDD). J. Toxicol. Environ. Health 3, 451–464.

Firestone, D. (1973) Etiology of chick edema disease. Environ. Health Perspect. 5, 59–66.

Firestone, D., Clower, M., Barsotti, A.P., Teske, R.H. and Long, P.E. (1979) Polychlorodibenzo-p-dioxin and pentachlorophenol residues in milk and blood of cows fed technical pentachlorophenol. J. Agr. Food Chem. 27, 1171–1176.

MONS 225402

Firminger, H.I. (1955) Histopathology of carcinogenesis and tumors in the liver of rats. J. Natl. Cancer Inst. 15, 1427–1442.

Fissor, G. and Wertz, G.F. (1976) Polybrominated biphenyl teratogenic, embryotoxic effect in rat. Mutation Res. 38, 188.

Fishbein, L. (1974) Toxicity of chlorinated biphenyls. Annu. Rev. Pharmacol. 14, 139–154.

Friel, J.P. (1974) Dorland's Illustrated Medical Dictionary, 25th Edn., W.B. Saunders, Philadelphia, pp. 1623.

Goldstein, J.A. (1979) The structure–activity relationships of the halogenated biphenyls as enzyme inducers. Ann. N.Y. Acad. Sci. 320, 164–178.

Goldstein, J.A., Hickman, P., Bergman, H. and Vos, J.G. (1973) Hepatic porphyria induced by 2,3,7,8-tetrachlorodibenzo-p-dioxin in the mouse. Res. Commun. Chem. Pathol. Pharmacol. 6, 919–928.

Green, S. and Moreland, F.S. (1975) Cytogenetic evaluation of several dioxins in the rat. Toxicol. Appl. Pharmacol. 33, 161.

Green, S., Carr, J.V., Palmer, K.A. and Oswald, E.J. (1975a) Lack of cytogenetic effect in bone marrow and spermatogonial cells in rats treated with polychlorinated biphenyls (Aroclors 1242 and 1254). Bull. Environ. Contam. Toxicol. 13, 14–22.

Green, S., Sauro, F.M. and Friedman, L. (1975b) Lack of dominant lethality in rats treated with polychlorinated biphenyls (Aroclors 1242 and 1254). Food Cosmet. Toxicol. 13, 507–510.

Green, S., Moreland, F. and Sheu, C. (1977) Cytogenetic effect of 2,3,7,8-tetrachlorodibenzo-p-dioxin on rat bone marrow cells. F.D.A. By-Lines, No. 6, 292–294.

Greig, J.B., Jones, G., Butler, W.H. and Barnes, J.M. (1973) Toxic effects of 2,3,7,8-tetrachlorodibenzo-p-dioxin. Food Cosmet. Toxicol. 11, 585–595.

Gupta, B.N. and Moore, J.A. (1979) Toxicologic assessments of a commercial polybrominated biphenyl mixture in the rat. Am. J. Vet. Res. 40, 1458–1468.

Gupta, B.N., Vos, J.G., Moore, J.A., Zinkl, J.G. and Bullock, B.C. (1973) Pathologic effects of 2,3,7,8-tetrachlorodibenzo-p-dioxin in laboratory animals. Environ. Health Perspect. 5, 125–140.

Gupta, B.N., McConnell, E.E., Harris, M.W. and Moore, J.A. (1980) Six-month exposure of a commercial polybrominated biphenyl mixture in the rat and mouse. Toxicol. Appl. Pharmacol., in press.

Gutenmann, W.H. and Lisk, D.J. (1975) Tissue storage and excretion in milk of polybrominated biphenyls in ruminants. J. Agric. Food Chem. 23, 1005–1007.

Hansel, W., Olafson, P. and McEntee, K. (1955) The isolation and identification of the causative agent of bovine hyperkeratosis (x-disease) from a processed feed concentrate. Cornell Vet. 45, 94–101.

Harris, M.W., Moore, J.A., Vos, J.G. and Gupta, B.N. (1973) General biological effects of TCDD in laboratory animals. Environ. Health Perspect. 5, 101–109.

Hass, J.R., McConnell, E.E. and Harvan, D.J. (1978) Chemical and toxicologic evaluation of FireMaster BP-6. J. Agr. Food Chem. 26, 94–99.

Hinton, D.E., Glaumann, H. and Trump, B.F. (1978) Studies on the cellular toxicity of polychlorinated biphenyls (PCBs). I. Effect of PCBs on microsomal enzymes and on synthesis and turnover of microsomal and cytoplasmic lipids of rat liver – a morphological and biochemical study. Virchows Arch. B Cell Pathol. 27, 279–306.

Hoopingarner, R., Samuel, A. and Krause, D. (1972) Polychlorinated biphenyl interactions with tissue culture cells. Environ. Health Perspect. 1, 155–158.

Huber, W.G. and Link, R.P. (1962) Toxic effects of hexachloronaphthalene on swine. Toxicol. Appl. Pharmacol. 4, 257–262.

Hussain, S., Ehrenberg, G. Lofroth, G. and Gejvall, T. (1972) Mutagenic effects of TCDD on bacterial systems. Ambio 1, 32–33.

NOMS 225403

Hwang, S.W. (1973) The effects of 2,3,7,8-tetrachlorodibenzo-p-dioxin on the biliary excretion of indocyanine green in rat. Environ. Health Perspect. 5, 227–231.

Inagami, K. and Koga, T. (1969) Experimental study of hairless mice following administration of rice oil used by a 'Yusho' patient. Fukuoka Acta Med. 60, 548–553.

Ito, N., Nagasaki, H., Makiura, S. and Arai, M. (1974) Histopathological studies on liver tumorigenesis in rats treated with polychlorinated biphenyls. Gann 65, 549–549.

Itokawa, Y., Yagi, N., Kaiso, H., Kamohara, K. and Fujiwara, K. (1976) Influence of diet on the induction of hepatic ceroid pigment in rats by polychlorinated biphenyls. Toxicol. Appl. Pharmacol. 36, 131–141.

Jackson, W.T. (1972) Regulation of mitosis. 3. Cytological effects of 2,4,5-trichlorophenoxyacetic acid and of dioxin contaminants in 2,4,5-T formulations. J. Cell Sci. 10, 15–25.

Jackson, T.F. and Halbert, F.L. (1974) A toxic syndrome associated with the feeding of polybrominated biphenyl-contaminated protein concentrate to dairy cattle. J. Am. Vet. Med. Assoc. 165, 437–439.

Jamieson, J.W.S. (1977) Polybrominated biphenyls in the environment. Economic and technical review report, EPS-3-EC-77-18. Environmental Protection Service, Ottawa, Canada, pp. 1–71.

Jensen, S., Jansson, B. and Olsson, M. (1979) Number and identity of anthropogenic substances known to be present in Baltic seals and their possible effects on reproduction. Ann. N.Y. Acad. Sci. 320, 436–448.

Jones, G. and Butler, W.H. (1974) A morphological study of the liver lesion induced by 2,3,7,8-tetrachlorodibenzo-p-dioxin in rats. J. Pathol. 112, 93–97.

Jones, E.L. and Kriszek, H.A. (1962) A technic for testing acnegenic potency in rabbits applied to the potent acnegen 2,3,7,8-tetrachlorodibenzo-p-dioxin. J. Invest. Dermatol. 39, 511–517.

Kay, K. (1977) Polybrominated biphenyls (PBB) environmental contamination in Michigan, 1973–1976. Environ. Res. 13, 74–93.

Keplinger, M.L., Fancher, O.E. and Calandra, J.C. (1971) Toxicologic studies with polychlorinated biphenyls. Toxicol. Appl. Pharmacol. 19, 402–403.

Khera, K.S. and Ruddick, J.A. (1973) Polychlorodibenzo-p-dioxins: Perinatal effects and the dominant lethal test in Wistar rats. In: Blair, E.H. (Ed.), Chlorodioxins–Origins and Fate. Advances in Chemistry Series 120, American Chemical Society, Washington, D.C., pp. 70–84.

Kimbrough, R.D. (1974) The toxicity of polychlorinated polycyclic compounds and related compounds. Crit. Rev. Toxicol. 2, 445–489.

Kimbrough, R.D. (1979) The carcinogenic and other chronic effects of persistent halogenated compounds. Ann. N.Y. Acad. Sci. 320, 415–418.

Kimbrough, R.D. and Linder, R.E. (1974) Induction of adenofibrosis and hepatomas of the liver of Balb. cd mice by polychlorinated biphenyl (Aroclor 1254). J. Natl. Cancer Inst. 53, 547–552.

Kimbrough, R.D., Linder, R.E. and Gaines, T.B. (1972) Morphological changes in the liver of rats fed polychlorinated biphenyls. Arch. Environ. Health 25, 354–364.

Kimbrough, R.D., Linder, R.E., Burse, V.W. and Jennings, R.W. (1973) Adenofibrosis in the rat liver. Arch. Environ. Health 27, 390–395.

Kimbrough, R.D., Squire, R.A., Linder, R.E., Strandberg, J.D., Montali, R.J. and Burse, V.W. (1975) Induction of liver tumors in Sherman strain female rats by polychlorinated biphenyl Aroclor 1260. J. Natl. Cancer Inst. 55, 1453–1459.

Kimbrough, R.D., Carter, C.D., Liddle, J.A., Cline, R.E. and Phillips, P.E. (1977) Epidemiology and pathology of a tetrachlorodibenzo-p-dioxin poisoning episode. Arch. Environ. Health 32, 77–86.

Kimbrough, R.D., Buckley, J., Fishbein, L., Flamm, G., Kasza, L., Marcus, W., Shibko, S. and Teske, R. (1978a) Animal toxicology. Environ. Health Perspect. 24, 173–185.

NONS · 225404

Kimbrough, R.D., Burse, V.W. and Liddle, J.A. (1978b) Persistent liver lesions in rats after a single oral dose of polybrominated biphenyls (FireMaster FF-1) and concomitant PBB tissue levels. Environ. Health Perspect. 23, 265–273.

Kimmig, J. and Schultz, K.H. (1957) Chlorinated aromatic cyclic ethers as a cause of the so-called chloracne. Naturwissenschaften 44, 337–338.

Kimura, N.T. and Baba, T. (1973) Neoplastic changes in the rat liver induced by polychlorinated biphenyl. Gann 64, 105–108.

Kociba, R.J., Keeler, P.A., Park, C.N. and Gehring, P.J. (1976) 2,3,7,8-Tetrachlorodibenzo-p-dioxin (TCDD): results of a 13-week oral toxicity study in rats. Toxicol. Appl. Pharmacol. 35, 553–574.

Kociba, R.J., Keyes, D.G., Beyer, J.E., Carreon, R.M., Wade, C.E., Dittenber, D.A., Kalnins, R.P., Frauson, L.E., Park, C.N., Barnard, S.D., Hummel, R.A. and Humiston, C.G. (1978) Results of a two-year chronic toxicity and oncogenicity study of 2,3,7,8-tetrachlorodibenzo-p-dioxin in rats. Toxicol. Appl. Pharmacol. 46, 279–303.

Kociba, R.J., Keyes, D.G., Beyer, J.E., Carreon, R.M. and Gehring, P.J. (1979) Long-term toxicologic studies of 2,3,7,8-tetrachlorodibenzo-p-dioxin (TCDD) in laboratory animals. Ann. N.Y. Acad. Sci. 320, 397–404.

Kohli, J., Wyndham, C., Smythe, M. and Safe, S. (1978) Metabolism of bromobiphenyls. Biochem. Pharmacol. 27, 1245–1249.

Kouri, R.E., Rude, T.H., Jogiekar, R., Dannette, P.M., Jerina, D.M., Atlas, S.A., Owens, I.S. and Nebert, D.W. (1978) 2,3,7,8-Tetrachlorodibenzo-p-dioxin as a carcinogen causing 3-methylcholanthrene-initiated subcutaneous tumors in mice genetically "nonresponsive" at Ah locus. Cancer Res. 38, 2777–2783.

Kover, F.D. (1975) Environmental hazard assessment report: chlorinated naphthalenes. EPA-560 8-75-001, Environmental Protection Agency, Office of Toxic Substances, Washington, D.C., pp. 1–36.

Kuratsune, M. (1976) Epidemiologic studies on Yusho. In: Higuchi, K. (Ed.), PCB Poisoning and Pollution, Academic Press, New York, pp. 9–24.

Lambrecht, L.K., Barsotti, D.A. and Allen, J.R. (1978) Responses of nonhuman primates to a polybrominated biphenyl mixture. Environ. Health Persp. 23, 139–145.

Lillie, R.J., Cecil, H.C., Bitman, J. and Fries, G.F. (1974) Differences in response of caged white leghorn layers to various polychlorinated biphenyls (PCBs) in the diet. Poultry Sci. 53, 726–732.

Linder, R.E., Gaines, T.B. and Kimbrough, R.D. (1974) The effect of polychlorinated biphenyls on rat reproduction. Food Cosmet. Toxicol. 12, 63–77.

Lushbaugh, C.C. (1947) Experimental hyperplastic gastric polyposis in monkeys. J. Natl. Cancer Inst. 7, 313–320.

Marsh, C.L., Olson, C. and Blore, I.C. (1956) Observations on collagen, vitamin A, and ascorbic acid in bovine hyperkeratosis. Am. J. Vet. Res. 17, 410–414.

Matthews, H.B. and Kato, S. (1979) The metabolism and disposition of halogenated aromatics. Ann. N.Y. Acad. Sci. 320, 131–137.

McConnell, E.E. and McKinney, J.D. (1978) Exquisite toxicity in the guinea pig to structurally similar halogenated dioxins, furans, biphenyls and naphthalenes. Toxicol. Appl. Pharmacol. 45, 298.

McConnell, E.E. and Moore, J.A. (1979) Toxicopathology characteristics of the halogenated aromatics. Ann. N.Y. Acad. Sci. 320, 138–150.

McConnell, E.E., Hass, J.R., Altman, N. and Moore, J.A. (1979) A spontaneous outbreak of polychlorinated biphenyl (PCB) toxicity in Rhesus monkeys (Macaca mulatta): Toxicopathology. Lab. Animal Sci. 29, 666–673.

McConnell, E.E., Moore, J.A. and Dalgard, D.W. (1978a) Toxicity of 2,3,7,8-tetrachlorodibenzo-p-dioxin in Rhesus monkeys (Macaca mulatta) following a single oral dose. Toxicol. Appl. Pharmacol. 43, 175–187.

MONS 225405

McConnell, E.E., Moore, J.A., Haseman, J.K. and Harris, M.W. (1978b) The comparative toxicity of chlorinated dibenzo-p-dioxins in mice and guinea pigs. Toxicol. Appl. Pharmacol. 44, 335–356.

McConnell, E.E., Moore, J.A., Gupta, B.N., Rakes, A.H., Luster, M.I., Goldstein, J.A., Haseman, J.K. and Parker, C.E. (1980) The chronic toxicity of technical and analytical pentachlorophenol in cattle. I. Clinicopathology. Toxicol. Appl. Pharmacol. 52, 468–490.

McKinney, J.D., Chae, K., Gupta, B.N., Moore, J.A. and Goldstein, J.A. (1976) Toxicological assessment of hexachlorobiphenyl isomers and 2,3,7,8-tetrachlorodibenzofuran in chicks. Toxicol. Appl. Pharmacol. 36, 65–80.

McKinney, J.D., Singh, P., Levy, L. and Walker, M.P. (1980) High toxicity and carcinogenic potential of certain halogenated aromatic hydrocarbons: some structure activity relationships. In: Walters, D.B. (Ed.), Safe Handling of Chemical Carcinogens, Mutagens, and Teratogens and Highly Toxic Substances, Vol. II, Ann Arbor Science Publishers, Ann Arbor, Mich., pp. 421–438.

McLaughlin, J., Marliac, G.P., Kerrett, M.J., Murchler, M.K. and Fitzhugh, O.G. (1963) The injection of chemicals into the yolk sac of fertile eggs prior to incubation as a toxicity test. Toxicol. Appl. Pharmacol. 5, 760–771.

McNulty, W.P. Oregon Regional Primate Center, Beaverton, Oregon.

McNulty, W.P. and Griffin, D.A. (1976) Possible polychlorinated biphenyl poisoning in Rhesus monkeys (Macaca mulatta). J. Med. Primatol. 5, 237–246.

Mercer, H.D., Teske, R.H., Condon, R.J., Furr, A., Meerdink, G., Buck, W. and Fries, G. (1976) Herd health status of animals exposed to polybrominated biphenyls (PBB). J. Toxicol. Environ. Health 2, 335–349.

Moore, J.A. (1973) Perspective on chlorinated dibenzodioxins and dibenzofurans. Environ. Health Perspect. 5, 1–313.

Moore, J.A. (1978a) Toxicity of 2,3,7,8-tetrachlorodibenzo-para-dioxin. In: Ramel, C. (Ed.), Chlorinated Phenoxy Acids and Their Dioxins, Ecol. Bull. (Stockholm) 27, 134–144.

Moore, J.A. (1978b) Long-term hazards of polychlorinated dibenzodioxins and polychlorinated dibenzofurans. IARC Internal Technical Report 78/001, International Agency for Research on Cancer, Lyon, pp. 1–57.

Moore, J.A., McConnell, E.E., Dalgard, D.W. and Harris, M.W. (1979) Comparative toxicity of three halogenated dibenzofurans in guinea pigs, mice, and rhesus monkeys. Ann. N.Y. Acad. Sci. 320, 151–163.

Murray, F.J., Smith, F.A., Nitschke, K.D., Humiston, C.G., Kociba, R.J. and Schwetz, B.A. (1979) Three-generation reproduction study of rats given 2,3,7,8-tetrachlorodibenzo-p-dioxin (TCDD) in the diet. Toxicol. Appl. Pharmacol. 50, 241–252.

Nagasaki, H., Tomii, S., Mega, T., Marugami, M. and Ito, N. (1972) Hepatocarcinogenicity of polychlorinated biphenyls in mice. Gann Jap. J. Cancer Res. 63, 805.

Neal, R.A., Beatty, P.W. and Gasiewicz, T.A. (1979) Studies on the mechanisms of toxicity of 2,3,7,8-tetrachlorodibenzo-p-dioxin (TCDD). Ann. N.Y. Acad. Sci. 320, 204–213.

Nelson, N., Hammond, P.B., Nisbet, C.T., Sarofirm, A.F. and Drury, W.H. (1972) Polychlorinated biphenyls – environmental impact. Environ. Res. 5, 249–362.

Neubert, D. and Dillmann, I. (1972) Embryotoxic effects in mice treated with 2,4,5-trichlorophenoxyacetic acid and 2,3,7,8-tetrachlorodibenzo-p-dioxin. Naunyn-Schmiedeberg's Arch. Pharmacol. 272, 243–264.

Nicholson, W.J. and Moore, J.A. (1979) Health effects of halogenated aromatic hydrocarbons. Ann. N.Y. Acad. Sci. 320, 1–730.

Nishizumi, M. (1970) Light and electron microscope study of chlorobiphenyl poisoning. Arch. Environ. Health 21, 620–632.

Nishizumi, M. (1978) Acute toxicity of polychlorinated dibenzofurans in CF-1 mice. Toxicol. Appl. Pharmacol. 45, 209–212.

MONS 225406

Sobuyuki, I., Nagasaki, H., Arai, M., Makiura, S., Sugihara, S. and Hirao, K. (1978) Histopathologic studies on liver tumorigenesis induced in mice by technical polychlorinated biphenyls and its promoting effect on liver tumors induced by benzene hexachloride. J. Natl. Cancer Inst. 51, 1637–1646.

Norback, D.H. and Allen, J.R. (1973) Biological responses of the nonhuman primate, chicken, and rat to chlorinated dibenzo-p-dioxin ingestion. Environ. Health Perspect. 5, 233–240.

Norback, D.H., Engblom, T.F. and Allen, J.R. (1975) Tissue distribution and excretion of tetrachlorodibenzo-p-dioxin in the rat. Toxicol. Appl. Pharmacol. 32, 330–338.

Oishi, S., Idema, M. and Fukuda, H. (1978) Comparative toxicity of polychlorinated biphenyls and dibenzofurans in rats. Toxicol. Appl. Pharmacol. 43, 13–22.

Olafson, P. (1947) Hyperkeratosis (X-disease) of cattle. Cornell Vet. 37, 279–291.

Peakall, D.B., Lincer, J.L. and Bloom, S.E. (1972) Embryonic mortality and chromosomal alterations caused by Aroclor 1254 in ring doves. Environ. Health Perspect. 1, 103–104.

Platonow, N.S., Karstad, L.H. and Saschenbrecker, P.W. (1973) Tissue distribution of polychlorinated biphenyls (Aroclor 1254) in cockerels: Relation to the duration of exposure and observations on pathology. Can. J. Comp. Med. 37, 90–95.

Polin, D. and Ringer, R.K. (1978) PBB fed to adult female chickens: Its effect on egg production, reproduction, viability of offspring, and residues in tissues and eggs. Environ. Health Perspect. 23, 283–290.

Polin, D., Ringer, R.K. and Aust, S.D. (1979) Effect of congeners of polybrominated biphenyls on hatchability of chicken eggs. I. 2,2',4,4',5,5'-hexabromobiphenyl vs. PBB. Proc. Soc. Exp. Biol. Med. 161, 44–47.

Pudelkiewicz, W.J., Boucher, R.V., Caffenbach, E.W. and Miller, R.C. (1959) Some physiological responses of New Hampshire chickens to a mixture of penta- and hexachloronaphthalenes. Poultry Sci. 38, 424–430.

Ramel, C. (1978) Chlorinated phenoxy acids and their dioxins. Ecological Bull. 27, Swedish Natural Science Research Council, Stockholm, Sweden, pp. 1–302.

Rappe, C. (1979) Dioxins, dibenzofurans and other polyhalogenated aromatics: production, use, formation, and destruction. Ann. N.Y. Acad. Sci. 320, 1–18.

Ringer, R.K. and Polin, D. (1977) The biological effects of polybrominated biphenyls in avian species. Fed. Proc. 36, 1894–1898.

Rowe, J.Q., Ramsey, J.C., Wentzler, T.H., Hummel, R.A. and Gehring, P.J. (1976) The fate of 2,3,7,8-tetrachlorodibenzo-p-dioxin following single and repeated oral doses to the rat. Toxicol. Appl. Pharmacol., 36, 209–226.

Sandermann, W. (1974) Polychlorierte aromatische Verbindungen als Umweltgifte. Naturwissenschaften 61, 207–213.

Sanger, V.L., Scott, L., Handy, A., Gale, C. and Pounden, W.D. (1958) Alimentary toxemia in chicken. J. Am. Vet. Med. Assoc. 133, 172–176.

Schulz, K.H. (1957) Klinische und experimentelle Untersuchungen zur Ätiologie der Chloracne. Arch. klin. Exp. Dermatol. 206, 589–596.

Schwetz, B.A., Norris, J.M., Sparschu, G.L., Rowe, V.K., Gehring, P.J., Emerson, J.L. and Gerbig, C.G. (1973) Toxicology of chlorinated dibenzo-p-dioxins. Adv. Chem. 120, 55–69.

Scott, T. (1973) Simian gastropathy with submucosal glands and cysts. Arch. Pathol. 96, 403–408.

Scott, T. (1975) Colitis cystica profunda in Rhesus monkeys. Lab. Animal Sci. 25, 55–60.

Seiler, J.P. (1973) A survey on the mutagenicity of various pesticides. Experientia 29, 622–623.

Shoya, S. (1974) Polychlorinated biphenyl poisoning in chickens. Jpn. Agr. Res. Otr. 8, 43–46.

Sikes, D. and Bridges, M.E. (1952) Experimental production of hyperkeratosis ('X-disease') of cattle with a chlorinated naphthalene. Science 166, 506–507.

MONS 225407

Simpson, C.F., Pritchard, W.R. and Harms, R.H. (1959) An endotheloisis in chickens and turkeys caused by an unidentified dietary factor. J. Am. Vet. Med. Assoc. 134, 410–416.

Sleight, S.D., Mangkoewidjojo, S., Akoso, B.T. and Sanger, V.L. (1978) Polybrominated biphenyl toxicosis in rats fed an iodine-deficient, iodine-adequate, or iodine-excess diet. Environ. Health Perspect. 23, 341–346.

Syrowatka, T. and Jurek, A. (1975) Incidence and toxicity of polychlorinated derivatives of dibenzo-p-dioxin, dibenzofuran and naphthalene. Roczn. PZH, 26, 623–634.

Thigpen, J.E., Faith, R.E., McConnell, E.E. and Moore, J.A. (1975) Increased susceptibility to bacterial infection as a sequela of exposure to 2,3,7,8-tetrachlorodibenzo-p-dioxin. Infect. Immun. 12, 1319–1324.

Van Logten, M.J., Gupta, B.N., McConnell, E.E. and Moore, J.A. (1980) Role of the endocrine system in the action of 2,3,7,8-tetrachlorodibenzo-p-dioxin (TCDD) on the thymus. Toxicology, in press.

Van Miller, J.P., Lalich, J.J. and Allen, J.R. (1977) Increased incidence of neoplasms in rats exposed to low levels of 2,3,7,8-tetrachlorodibenzo-p-dioxin. Chemosphere 10, 625–632.

Van Miller, J.P., Marlar, M.J. and Allen, J.R. (1976) Tissue distribution and excretion of tritiated tetrachlorodibenzo-p-dioxin in non-human primates and rats. Food Cosmet. Toxicol. 14, 31–34.

Van Putten, L.M., Van Bekkum, D.W. and De Vries, M.J. (1970) A severe chronic intoxication in a monkey colony. In: Balner, H. and Beveridge, W.I.B. (Eds.), Infections and Immunosuppression in Subhuman Primates, Munksgaard, Copenhagen, pp. 56–166.

Villeneuve, D.C., Grant, D.G., Khera, L., Clegg, D.J., Baer, H. and Phillips, W.E.J. (1971) The fetotoxicity of a polychlorinated biphenyl mixture Aroclor 1254 in the rabbit and in the rat. Environ. Physiol. 1, 67–71.

Vlachos, K., McEntee, K., Olafson, P. and Hansel, W. (1955) Destruction and restoration of spermatogenesis in a bull experimentally poisoned with highly chlorinated naphthalene. Cornell Vet. 45, 198–204.

Vos, J.G. and Beems, R.B. (1971) Dermal toxicity studies of technical polychlorinated biphenyls and fractions thereof in rabbits. Toxicol. Appl. Pharmacol. 19, 617–633.

Vos, J.G. and Koeman, J.H. (1970) Comparative toxicologic study with polychlorinated biphenyls in chickens with special reference to porphyria, edema formation, liver necrosis and tissue residues. Toxicol. Appl. Pharmacol. 17, 656–668.

Vos, J.G. and Moore, J.A. (1974) Suppression of cellular immunity in rats and mice by maternal treatment with 2,3,7,8-tetrachlorodibenzo-p-dioxin. Int. Arch. Allergy Appl. Immunol. 47, 777–794.

Vos, J.G., Moore, J.A. and Zinkl, J.G. (1974) Toxicity of 2,3,7,8-tetrachlorodibenzo-p-dioxin (TCDD) in C57Bl-6 mice. Toxicol. Appl. Pharmacol. 29, 229–241.

Wagener, K. (1951) Hyperkeratosis of cattle of Germany. J. Am. Vet. Med. Assoc. 119, 133–137.

Wassom, J.S., Huff, J.E. and Loprieno, N. (1977/1978) A review of the genetic toxicology of chlorinated dibenzo-p-dioxins. Mutation Res. 47, 141–160.

Wertz, G.F. and Fiscor, G. (1978) Cytogenetic and teratogenic test of polybrominated biphenyls in rodents. Environ. Health Perspect. 23, 129–132.

Wiessberg, J.B. and Zinkl, J.G. (1973) Effects of 2,3,7,8-tetrachlorodibenzo-p-dioxin upon hemostasis and hematologic function in the rat. Environ. Health Perspect. 5, 119–124.

Wyndham, C., Devenish, J. and Safe, S. (1976) The in vitro metabolism, macromolecular binding and bacterial mutagenicity of 4-chlorobiphenyl, a model PCB substrate. Res. Commun. Chem. Pathol. Pharmacol. 15, 563–570.

Young, G., Petkau, A. and Hoogstraten, J. (1969) Chronic toxic effects of polyphenyl mixtures. Am. Ind. Hyg. Assoc. J. 30, 7–19.

Young, A.L., Calcagni, J.A., Thalken, C.E. and Tremblay, J.W. (1978) The toxicology,

MONS 225408

environmental fate, and human risk of herbicide orange and its associated dioxin. United States Air Force Technical Report OEHL-TR-79-92, Aerospace Medical Division (AFSC), Brooks Air Force Base, Texas.

Zingeser, M.R. (1979) Anomalous development of the soft palate in rhesus macaques (*Macaca mulatta*) prenatally exposed to 2,3,7,8-tetrachlorodibenzo-p-dioxin. Teratology 19, 44A–45A.

Zinkl, J.G., Vos, J.G., Moore, J.A. and Gupta, B.N. (1973) Hematologic and chemical clinical chemistry of 2,3,7,8-tetrachlorodibenzo-p-dioxin in laboratory animals. Environ. Health Perspect. 5, 111–118.

NONS 225409

ACUTE AND CHRONIC TOXICITY, CARCINOGENESIS, REPRODUCTION, TERATOGENESIS AND MUTAGENESIS IN ANIMALS

MCCONNELL E E

HALOGENATED BIPHENYLS, TERPHENYLS, NAPHTHALENES, AND DIBENZODIOXINS

1980

109-158

MONS 225410