PLAINTIFF'S EXHIBIT
SA 384

Adequate experimental trial should precede the clinical use of any untested plastic material in surgery.

References

57. Simonds, H. R., and Ellis, C. *Handbook of Plastics*. 1043 pp. New York: D. Van Nostrand Company, Incorporated, 1943.
58. Bailey, R. L. *Polyesters Used in Britain as Impregnants in British Aircraft Cloth*. E. I. du Pont de Nemours and Company, Incorporated.
59. Meyers, L. Intravenous catheterization. *Am. J. Nursing* 45:930, 1945.
60. Poppe, J. K., and de Univerta, H. R. Treatment of syphilitic aneurysms by cellophane wrapping. *J. Thoracic Surg.* 15:166-175, 1946.
61. Ingraham, F. D., Alexander, E., Jr., and Matson, D. D. Unpublished data.
62. Huelsebusch, J. B., Foter, M. J., and Gibby, I. W. Effect of rubber tubing upon stability of penicillin and streptomycin solutions. *Science* 104:479, 1946.
63. Wheeldon, T. Use of cellophane as permanent tendon sheath. *J. Bone & Joint Surg.* 21:191-196, 1939.
64. McKeever, D. C. Use of cellophane as interposition membrane in synovectomy. *J. Bone & Joint Surg.* 41:576-580, 1945.
65. Harley, G. H., and Breck, L. W. Cellophane in bone and joint surgery. *Am. J. Surg.* 68:219-231, 1945.
66. Donati, D. Ricerche sperimentali sull'uso del cellophane in plastiche dorsali di varia grandezza. *Bull. d. sc. med., Bologna* 109:425-432, 1937.
67. Christyakov, N. L. Use of cellophane in treatment of wounds. *Am. Rev. Soviet Med.* 3:490-493, 1946.
68. Page, I. H. Method for producing persistent hypertension by cellophane. *Science* 89:273, 1939.
69. *Idem*. Production of persistent arterial hypertension by cellophane perinephritis. *J. A. M. A.* 113:2046-2048, 1939.
70. Graef, I., and Page, I. H. Pathological anatomy of cellophane perinephritis. *Am. J. Path.* 16:211-222, 1940.
71. Denibus, F. W. Effect of cellophane perinephritis on granular cells of juxtaglomerular apparatus. *Arch. Path.* 32:211-216, 1941.
72. Pearse, H. E. Experimental studies on gradual occlusion of large arteries. *Ann. Surg.* 112:923-937, 1940.
73. *Idem*. Experimental studies on gradual occlusion of large arteries. *Tr. Am. S. A.* 58:443-457, 1940.
74. Gross, R. E. Complete surgical division of patent ductus arteriosus: report of fourteen successful cases. *Surg., Gynec. & Obst.* 78:36-43, 1944.
75. Harper, F. R., and Robinson, M. F. Occlusion of infected patent ductus arteriosus with cellophane. *Am. J. Surg.* 64:296-306, 1944.
76. Harrison, P. W., and Chandy, J. Subclavian aneurysm cured by cellophane sheath. *Ann. Surg.* 118:478-481, 1943.
77. Grant, F. C., and Norcross, N. C. Repair of cranial defects by cranioplasty. *Ann. Surg.* 110:488-512, 1939.
78. Nev, K. W. Repair of cranial defects with celluloid. *Am. J. Surg.* 44: 394-399, 1939.
79. Smith-Petersen, M. N. Arthroplasty of hip: new method. *J. Bone & Joint Surg.* 21:269-288, 1939.
80. Baker, D. R. New type of plastic hip cup for arthroplasty or for use as artificial femoral head. *Guthrie Clin. Bull.* 11:133, 1942.
81. Bettes, J. E. Suture studies: new sutures. *Arch. Surg.* 41:1414-1425, 1940.
82. Blaine, G. Experimental observations on use of absorbable and non-absorbable plastics in bone surgery. *Brit. J. Surg.* 33:245-250, 1946.
83. Hooper, W. C., Martin, G. J., and Thompson, M. R. Methyl cellulose solution as plasma substitute. *Am. J. Surg.* 56:629-635, 1942.

CASE RECORDS OF THE MASSACHUSETTS GENERAL HOSPITAL

Weekly Clinicopathological Exercises

FOUNDED BY RICHARD C. CABOT

TRACY B. MALLORY, M.D., *Editor*

BENJAMIN CASTLEMAN, M.D., *Associate Editor*

EDITH E. PARRIS, *Assistant Editor*

CASE 33111

Presentation of Case

A thirty-seven-year-old Swedish asbestos worker entered the hospital because of cough and chest pain.

Two and a half years before admission the patient had developed a cough, nasal congestion, nasal discharge, fever and shortness of breath that had persisted one week and had been followed by a dull, aching pleuritic pain along the left costal margin. He was hospitalized for a week and then rested at home for four months. In the hospital about 1000 cc. of fluid was removed from the left side of the chest. Subsequently, he returned to work and felt well except for a morning cough productive of small amounts of odorless white sputum. Occasional chest pain and exertional dyspnea were also noted. A year and a half later there was an insidious onset of weakness and fatigability and a gradual loss of 25 pounds in weight. Three months before entry the pleuritic pains became persistent, and the weakness and dyspnea severe, and the patient slept propped on two pillows. Repeated sputum smears were negative for tubercle bacilli.

The patient's work consisted in cutting asbestos insulating board; he denied exposure to undue amounts of dust. There was no history of exposure to tuberculosis.

Physical examination revealed the patient to be orthopneic and breathing rapidly at a rate of 30 per minute, with a dry, hacking cough and clubbed fingers. There was a slight, shotty, generalized lymphadenopathy. Respiratory expansion on the left was diminished, as were tactile and vocal fremitus and breath sounds. On the right there were increased bronchovesicular breath sounds and scattered dry rales. The heart and mediastinum were shifted to the right, and the apical beat was maximal in the right midclavicular line. There was a ticktack rhythm with a rate of 110, and a pulsus paradoxicus. The abdomen was normal.

The temperature was 100°F. The blood pressure was 128 systolic, 70 diastolic.

Examination of the blood disclosed a red-cell count of 4,900,000 and a white-cell count of 12,200, with 77 per cent neutrophils, 16 per cent lymphocytes and 7 per cent monocytes. The urine and stools were normal. X-ray examination showed numerous discrete areas of increased density scattered over the right lung; pressing on the lower trachea and left main bronchus and deviating them to the right was a large mass measuring 11 cm. in diameter (Fig. 1). A small amount of aerated lung was seen at the periphery of the mass. There was either fluid or, more probably, dense pleural thickening and collapsed lung between the mass and the lateral costal margin. The left lower-lung field was almost completely opaque.

In the hospital the patient's condition became steadily worse. Further x-ray studies showed displacement of the esophagus to the right (Fig. 2), extensive periosteal new bone formation of the left upper ribs, slight displacement of the stomach to

the left, enlargement of the spleen and the suggestion of a retroperitoneal mass rotating the left kidney. Three attempted thoracenteses failed to encounter fluid, although the needle was inserted to a depth of 5 cm. No acid-fast organisms were found in the sputum. Tuberculin tests were negative in a 1:1000 dilution. The patient became extremely weak and dyspneic and perspired constantly. He died on the thirty-seventh hospital day.



FIGURE 1. *Roentgenogram of the Chest, Showing Opacity on the Left and Multiple Nodules in the Right Lung.*

DIFFERENTIAL DIAGNOSIS

DR. DONALD S. KING: This seems to be the old problem of a tumor in the lung with a decision to be made regarding the kind of tumor. As in most cases, the decision will be based largely on the x-ray appearance.

One should comment first on the occupation. This man worked with asbestos, cutting insulating board. Exposure to asbestos causes lung changes but never, in my experience, to the extent that was present in this case. I believe that asbestosis was not a factor in the illness and that, if present, it was of secondary importance.

The next question concerns tuberculosis. The onset of the disease was two and a half years before the final hospital admission, with fever for a week. About 1000 cc. of fluid was removed, following which the patient was discharged from the hospital. He then rested at home for four months, returned to work and remained in good condition for a year. This could have been pleurisy with effusion, perhaps tuberculous. Many sputum examinations, however, showed no tubercle bacilli, and shortly before death a tuberculin skin test was negative in a 1:1000 dilution. In any event, the evidence for tuberculosis does not seem sufficient to justify that diagnosis in addition to what I believe was a tumor. My diagnosis is tumor, with fluid that was secondary to the tumor and not due to tuberculosis or other infection.

The x-ray films present a different picture on each side of the chest. On the right side there are many nodules, which are better shown in some films than others. In my experience, rounded nodular shadows of this sort have always been caused by metastatic tumor, either from some spot elsewhere in the lung or from some place outside the chest. If the tumor was metastatic from outside the lung, it could have been from above the clavicles or below the diaphragm, or there could have been metastases from a primary bronchiogenic cancer in

the left lung or from a mediastinal tumor. I should like to ask Dr. Schatzki whether he has ever seen rounded shadows of this size and density that were not due to tumor.

DR. RICHARD SCHATZKI: Yes.

DR. KING: I stand corrected on that point.

DR. SCHATZKI: That does not mean that this was not a tumor.

DR. KING: I have never seen rounded shadows of this size and distribution with silicosis, tuberculosis air left in the left lung is the small amount seen in the left upper lung. The films do not show what is going on lower down.

DR. KING: So you will not help regarding the position of the tumor — that is, whether it is in the lung or outside the lung?

DR. SCHATZKI: I think that I could help if I was allowed to.

DR. KING: I think that it would be all right; how about it, Dr. Castleman?



FIGURE 2. *Roentgenogram of the Chest and Abdomen following a Barium Swallow, Showing Displacement of the Esophagus and Stomach by a Mass in the Left Side of the Chest.*

x in fact anything, and I therefore believe that the process in the right lung was definitely a metastatic tumor. The x-ray film of the left side of the chest shows a large, round mass displacing the trachea and the left main bronchus to the right. Is the tumor in the lung itself or in the mediastinum?

DR. SCHATZKI: The same mass is visible on this film in the same position. I do not believe that one could try to delineate the exact outline of the tumor when so little air is present. Other criteria should be used to demonstrate the mass. The only

DR. BENJAMIN CASTLEMAN: By all means.

DR. KING: I need a great deal of help.

DR. SCHATZKI: There is some definite evidence of a large mass outside the lung. The first indication is the position of the esophagus, which is displaced far to the right side by a mass. This mass has a diameter much larger than the mass in the upper-lung field, and therefore it cannot be a tumor in the lung. The second point is the position of the fundus of the stomach, which is pushed downward in contrast to what one would expect with a lung tumor

that has produced collapse. Thirdly, the ribs, if anything, are spaced farther apart than on the normal side, which is again unusual for a lung that has collapsed.

DR. KING: I should have committed myself before I asked that question, but I agree with your conclusions. I cannot be sure that this was not a bronchiogenic carcinoma of the left upper lobe, but my opinion is against that diagnosis. There was also involvement in the left lower lobe. I suppose that this also may have been a tumor. Do you want to commit yourself on that, Dr. Schatzki?

DR. SCHATZKI: I think that I know the answer. It is obvious, as I have said, that there was something outside the lung; otherwise, the stomach would not have been displaced or the ribs separated.

DR. KING: Do you think that it was a tumor or fluid?

DR. SCHATZKI: I believe that it was a tumor.

DR. KING: That is what I believe.

Let us go down to the abdomen. Was the spleen enlarged or was it displaced downward? I should like to omit the spleen if I may.

DR. SCHATZKI: So far as I am concerned, it may be excluded.

DR. KING: Was the stomach involved?

DR. SCHATZKI: There is no evidence of involvement of the stomach. It was displaced, but this was due to the low position of the left leaf of the diaphragm.

DR. KING: Was the liver enlarged? And was the displacement of the stomach to the left due to such enlargement?

DR. SCHATZKI: The liver was not enlarged so far as I can tell.

DR. KING: This is an intravenous pyelogram showing a retroperitoneal mass rotating the left kidney.

DR. SCHATZKI: Both kidneys are low in position, and I am wondering if what we see is not again due to the low position of the diaphragm.

DR. KING: You do not see the retroperitoneal mass?

DR. SCHATZKI: Not that I can be sure of. I do not see the outline of the kidneys so well as I should like to. The upper pole of the right kidney is clearly seen, but the upper pole of the left kidney is not.

DR. KING: I suppose that you have helped all you can. Do you want to say anything more?

DR. SCHATZKI: Yes; there are some rib changes.

DR. KING: You mean the periosteal changes in the rib? I have seen such changes only with pus. Have you seen periosteal changes with large tumor masses?

DR. SCHATZKI: We have seen them in patients who did not have empyema but who had a chronic nonspecific process in the lung.

DR. KING: The films show the periosteal changes clearly, and I am inclined to agree.

Actually, we have no evidence of any source of tumor outside the chest, but the possibility of tumors in the pharynx and the thyroid gland should be mentioned because findings similar to those in this case follow metastases from malignant tumors in those areas. We are not justified, however, in making such a diagnosis with the evidence at hand. Below the diaphragm there is no indication of disease of the stomach, pancreas, liver or kidney. These films at first suggested that the testicle or the prostate was the primary source, or perhaps a so-called "hypernephroma." This is a fairly characteristic picture for metastases from the testicle or prostate, but we have no evidence to make that diagnosis. There does not seem to me to be any justifiable source for the tumor outside the chest, and we are back to the problem of what this tumor was.

Was it bronchiogenic or mediastinal? We have seen exactly this picture with teratomas of the mediastinum that have eventually broken loose. If it was a lung tumor I lean toward a bronchiogenic carcinoma with metastases to the right lung and possibly the retroperitoneal area. The findings were not quite consistent with those of bronchiogenic carcinoma because such tumors are usually not large enough to push the mediastinum to the other side unless a great deal of fluid is present. Also, the rib changes were more like those with a large tumor mass that had been pressing on that area for some time. The process had been going on for perhaps two and a half years. My diagnosis is a mediastinal tumor, probably a teratoma, with metastases to the right lung. I do not believe that the tumor was a lymphoma, although again that must always be considered. I doubt whether it was a bronchiogenic carcinoma with metastases.

DR. F. DENNETTE ADAMS: How do you exclude lymphoma?

DR. KING: I do not exclude it. I have not seen x-ray findings such as these with lymphoma, which usually causes more symptoms than this man had for two and a half years. The other conditions I have named seem likelier.

DR. ALFRED KRAMES: Is it not unusual for fluid due to tumor to subside for so long a time?

DR. KING: Yes; that is one of the things against trying to explain the whole picture as tumor. I agree that subsidence of all symptoms for a year after the removal of 1000 cc. of fluid in a case of tumor is not usual. I wanted to make the diagnosis of tuberculosis, but I could not.

DR. CHARLES L. SHORT: I saw this patient on the ward, and I went through much the same line of reasoning as Dr. King has. From the history my impression was tuberculosis, but from the x-ray findings that certainly could not have been the primary diagnosis. I do not believe that most of us went so far as Dr. King in being willing to say that the tumor was primary in the chest. We thought of lymphoma and for that reason small

doses of x-ray therapy were given, without effect on the lesion. We were able to get a needle biopsy shortly before death. A mass developed above the left clavicle about 5 cm. in diameter, and we thought that there was also a mass in the epigastrium.

DR. KING: Such metastases would be against my diagnosis. A primary carcinoma of the lung would be likelier to metastasize to the neck, although lymphoma could do so.

CLINICAL DIAGNOSIS

Carcinoma of lung, probably metastatic.

DR. KING'S DIAGNOSIS

Mediastinal teratoma, with metastases to right lung.

ANATOMICAL DIAGNOSIS

Mesothelioma of pleura and pericardium, with metastases to right lung and retroperitoneal lymph nodes.

PATHOLOGICAL DISCUSSION

DR. CASTLEMAN: The left lung was completely encased on all sides by a thick, hard, somewhat



FIGURE 3. *Photograph of Coronal Section of the Left Lung, Showing Complete Encasement by the Pleural Tumor.*

shiny, fibrous tumor compressing the lung into a small fraction of its normal volume. In places this thickening of the pleura or tumor tissue involving the pleura measured as much as 8 cm. (Fig. 3). There were multiple tumor nodules in the right lung, but no involvement of the pleura. This was a sharp contrast to the left lung, which was free from any parenchymatous tumor nodules. The heart and pericardium together weighed 1100 gm. The heart itself was perfectly normal, the increase in weight being due to the tremendous thickening of the visceral pericardium, which measured as

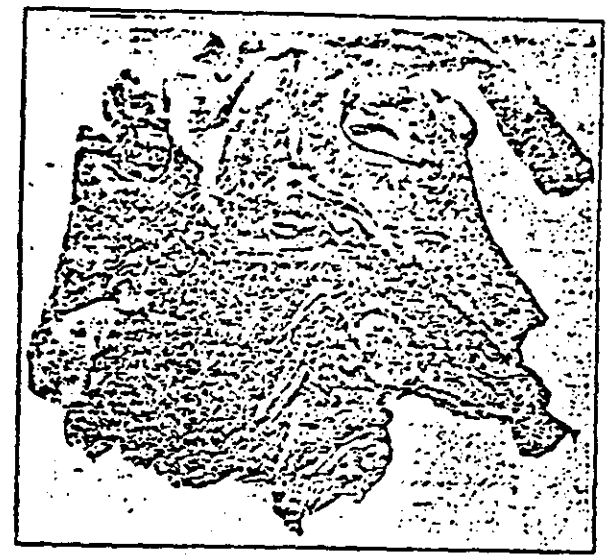

FIGURE 4. *Photograph of the Heart, Showing Neoplastic Involvement of the Visceral Pericardium.*

much as 3 or 4 cm. in thickness (Fig. 4). This gross picture of involvement of the pericardium and



FIGURE 5. *Photomicrograph of the Mesothelioma.*

pleura fits in with the diagnosis of mesothelioma. We examined the bronchi carefully throughout the left lung and found no evidence of tumor within a

bronchus, near a bronchus or in the lung itself. The nodules in the right lung were well circumscribed in the parenchyma away from the bronchi and were definitely metastatic. We were quite certain that we could rule out bronchiogenic or primary carcinoma of the lung. The bronchial lymph nodes contained no tumor. We searched every organ for a primary source, but we were unable to find any.

The histology of the tumor was typical of what has been described as a mesothelioma (Fig. 5). The cells in some areas were cuboidal and arranged around fibrous stalks giving a pseudopapillary pattern. In other areas the cells were large, irregular and closely packed. Some were multinucleated, and others seemed to be forming mucinous material.

A number of papers have been written to the effect that there is no such tumor as mesothelioma of the pleura, that the cells lining the pleura do not form tumors and that these tumors really arise from a small focus in the lung. We have held a similar opinion for a long time. This is perhaps the first case in which we believed that there was actually such a tumor. It certainly fits in with most of the cases of mesothelioma of the pleura that have been reported.*

DR. KING: I do not consider that it is fair to have given me a case with a diagnosis against which you, as pathologists, have been talking for twenty years. I could never make Dr. Mallory accept a diagnosis of mesothelioma of the pleura.

DR. CASTLEMAN: He has been sold on this one. The lesion in the abdomen was retroperitoneal tumor, but there was no tumor elsewhere.

DR. ADAMS: What was the large lesion in the left lung?

DR. CASTLEMAN: It was merely nodularity due to the pleural tumor.

*Klemperer, P., and Rabin, C. B. Primary neoplasms of pleura. *Arch. Path.* 11:385-412, 1931.

CASE 33112

PRESENTATION OF CASE

A seventy-two-year-old Polish housewife entered the hospital in coma.

Eleven days before entry the patient had received a slight back injury in an automobile accident. A physician examined her at that time and found only slight spasm along the lumbar muscles. Three days later the physician was called again because the patient complained of slight bleeding supposedly from the vagina; he could find no evidence of bleeding. Six days before entry the patient began to have frequent episodes of abdominal cramps. These continued daily. Three days later the abdomen was distended, with marked tenderness and a mass in the right lower quadrant. The patient was taken to another hospital, where a plain film of the abdomen and a barium enema showed an abrupt, shelf-like obstruction in the lower sigmoid, with a markedly dilated large bowel, particularly on the right, and beginning small-bowel dilatation. Routine urine examinations were said to have been negative. There was a slight leukocytosis, and the blood sugar was 196 mg. per 100 cc. On the following day the patient appeared acutely ill. The abdomen was greatly distended, and the patient complained of abdominal pain. No organs or masses could be felt. The pulse was about 115. On the same day an emergency cecostomy was performed under a local anesthetic. There was an increased amount of clear, straw-colored fluid in the peritoneal cavity. The colon and cecum were greatly distended, and a large amount of fluid and gas was removed by trocar suction. A glass Mixter tube was fixed in place by sutures. Following the operation the patient was said to have improved for a while, but the abdominal symptoms subsequently reappeared. She was transferred to this hospital on the afternoon of the second postoperative day.

The patient was known to have hypertension. A sister had diabetes.

Physical examination revealed an obese, disoriented woman. The left border of the heart extended beyond the midclavicular line, but the heart sounds were normal. There were coarse rhonchi, which cleared on coughing, in both lower lobes. The abdomen was distended, tense and slightly tender. Peristalsis was limited to a few tinkles. The diaphragm was high on both sides but moved to percussion. The cecostomy appeared to be functioning well.

The temperature was 100°F., the pulse 120, and the respirations 30. The blood pressure was 110 systolic, 70 diastolic.

A Levine tube was passed immediately on entry, and 500 cc. of brownish fluid, as well as considerable gas, was aspirated from the stomach. The patient also received 600 cc. of 5 per cent dextrose in water and oxygen. During the night she became extremely disturbed, tore up the oxygen tent and pulled out the intravenous drip and stomach tubes. The cecostomy drained 1680 cc. of fluid, and 646 cc. of urine was passed on the first hospital day. On the morning of the second hospital day the distention appeared to be slightly less, and peristaltic tinkles were somewhat more frequent. The tongue was dry.

The temperature was 102°F., the pulse 130, and the respirations 30. The blood pressure was 100 systolic, 60 diastolic.

Examination of the blood showed a hemoglobin of 16.3 gm. per 100 cc., a hematocrit of 50 and a white-cell count of 9700, with 85 per cent neutrophils. The total protein was 8.5 gm. and the non-protein nitrogen 100 mg. per 100 cc.; the carbon