CA/ Abbot 16

American Journal of Pathology 89(1) 1977

MA. (F)

Effect of Polychlorinated Biphenyl (PCB) on the Thyroid Gland of Rats

Ultrastructural and Biochemical Investigations

William T. Collins, Jr., DVM, Charles C. Capen, DVM, PhD.
Louis Kasza, DVM, PhD, Celester Carter, BS, and Robert E. Dailey, MS

MAR 2 0
MAR 29 1978

Polychlorinated biphenyls (PCB) produced ultrastructural lesions in thyroid follicular cells and reductions in serum thyroxine levels in rats that were time- and dose-dependent. *The acute effects (4 week) of PCB (50 and 500 ppm) consisted of an* accumulation of lysosomal bodies and colloid droplets in follicular cells with abnormalities of microvilli on the luminal surface. The chronic administration (12 week) of PCB (50 and 500/250 ppm) resulted in a striking distention of many follicular cells with large lysosomal bodies with strong acid phosphatase activity and colloid droplets, blunt and abnormally branched microvilli, and mitochondrial vacuolation. These ultrastructural alterations in follicular cells were associated with a highly significant reduction in serum thyroxine with both the low and the high dose of PCB. Follicular cells remained responsive to the lowered thyroxine level after feeding PCB for 4 and 12 weeks and underwent moderate compensatory hypertrophy and hyperplasia. Thyroid follicles were smaller than in controls and were lined by more columnar cells that occasionally formed papillary projections into the colloid. Residual ultrastructural alterations persisted for 12 weeks following cessation of feeding the compound, and serum thyroxine levels were significantly lower than in control rats. However, 35 weeks after discontinuing PCB, thyroid follicular cells were similar to those in controls and serum thyroxine levels had returned to normal. The striking ultrastructural lesions in follicular cells produced by feeding PCB to rats appeared to contribute to the lowering of serum thyroxine levels, *in combination with the known stimulation of peripheral thyroxine metabolism* by these compounds. Certain metabolic alterations produced by PCB intoxication in experimental animals and human beings may be related to an alteration in thyroid function. (Am J Pathol 89:119–136, 1977)

THE WIDESPREAD CONTAMINATION of the environment with polychlorinated biphenyls (PCB) has been well documented in several recent reports.[1-4] Polychlorinated biphenyls are prepared by the chlorination of biphenyl and are complex mixtures containing isomers of chlorobiphenyls with different chlorine content. These compounds, because of their noninflammability, high dielectric constant, and plasticizing abilities, have gained widespread use in industry as dielectric fluids in capacitors and transformers, hydraulic and heat transfer fluids, as well as plasticizers and solvents in adhesives and sealants. The escape of PCB into the

From the Department of Veterinary Pathobiology, College of Veterinary Medicine, The Ohio State University, Columbus, Ohio, and the Divisions of Pathology and Toxicology, Bureau of Foods, Food and Drug Administration, Washington, D. C.

Supported by Grants GM-1052 and RR-05463 from the National Institutes of Health, US Public Health Service, and by Contract 223-74-2094 from the Food and Drug Administration.

Accepted for publication May 10, 1977

Address reprint requests to Dr. Charles C. Capen, *Department of Veterinary Pathobiology*, The Ohio State University, College of Veterinary Medicine, 1925 Coffey Road, Columbus, OH 43210

degeneration.
lear lobe from
10—Transfor-
ies are evident
enveloped by

MONS 001186

environment through sewage outfalls and industrial disposal into waterways plus their long half-life have led to detectable levels in the adipose tissue of a large proportion of the human population.[5] Polychlorinated biphenyl residues have been detected in rivers and oceans and tissues of fish, wildlife, cattle, and poultry.[2,5,7] Escape of PCB into the air from plasticized materials, leakage of lubricants, hydraulic and heat transfer fluids, and leaching from waste dumps also may contribute significant amounts of PCB to the environment. The disease-producing capability of these compounds has been documented in human beings, cattle, and poultry following accidental contamination of foodstuffs with PCB.[8-10]

Intoxication with PCB results in the production of lesions in several organ systems. In the liver, PCB is a potent inducer of microsomal enzymes, resulting in the proliferation of smooth endoplasmic reticulum in hepatocytes, and it may cause fatty degeneration and necrosis.[11-13] Epidermal hyperplasia and hyperkeratosis, porphyria, and degeneration of lymphoid tissues and kidney have been reported following PCB intoxication.[14-16] Polychlorinated biphenyl also has been shown to have an adverse effect on reproduction and growth in several different animal species.[16-18]

Recent evidence indicates that PCB may cause alterations in thyroid structure and thyroxine metabolism. In birds administered PCB, there is enlargement of the thyroid gland and alteration of ^{131}I uptake by follicular cells.[19,20] The administration of PCB to rats resulted in an increased ^{131}I uptake, lowered serum thyroxine concentration, reduced protein-binding of thyroid hormone, and increased conjugation of thyroxine and excretion of thyroxine-glucuronide in the bile.[21-24] These findings suggest that some of the metabolic alterations produced by intoxication with PCB may be related to alterations in thyroid structure and function. Therefore, the objectives of this investigation were to a) evaluate the histopathologic, histochemical, and ultrastructural changes in thyroid follicular cells produced by the acute and chronic administration of high and low doses of PCB to rats, b) correlate the structural alterations in follicular cells with changes in serum thyroxine concentration, and c) investigate the persistence of the effects of PCB on the ultrastructure of thyroid follicular cells and serum thyroxine levels.

Materials and Methods

Eight-week-old male Osborne-Mendel rats (FDA colony) were fed Purina rat chow mixed with Aroclor 1254 (Monsanto Co., Inc., St. Louis, Mo.) at concentrations of 50 and 500 parts/million (ppm) for 4 and 12 weeks. The PCB was mixed into the pulverized feed using corn oil as a vehicle. Control rats received a similar diet with 3% corn oil but without PCB and were housed in a separate room. The delayed and long-term delayed effects of

MONS 001187

PCB on the thyroid were investigated by feeding rats 50 and 500 ppm PCB mixed into rat chow for 12 weeks followed by 12- and 35-week intervals in which the rats received no [illegible] the compound prior to euthanasia. Rats in the high dose groups received 500 ppm of [illegible] for the first 6 weeks but were switched to 250 ppm for the last 6 weeks because of anorexia and weight loss. At euthanasia, rats from the high dose group had a similar body weight as control rats. All diets were stored at −25 C in hexane-cleaned metal containers until use. The animals were housed individually in stainless steel cages with wire mesh bottoms. The daily lighting schedule was 12 hours of light followed by 12 hours of darkness. Feed and water were available *ad libitum*.

Thyroid glands were collected from 5 rats at each time interval (4 weeks, 12 weeks, 12 weeks with 12-week recovery, and 12 weeks with 35-week recovery) and dose level (0, 50, and 500 ppm PCB) for ultrastructural evaluation. The rats were killed immediately at the end of each experimental interval using carbon dioxide asphyxiation, and their thyroid glands were collected for electron microscopic, histopathologic, and histochemical evaluation. Tissue for electron microscopy was minced immediately under fixative into 0.5 to 1.0 cu mm blocks, fixed in cold 3% glutaraldehyde with 0.1 M sodium cacodylate buffered at pH 7.4, postfixed in 1% osmium tetroxide in s-collidine, dehydrated in graded ethanols, transferred to propylene oxide, and embedded in Epon (Shell Chemical Company, New York, N.Y.). Thin sections were cut with a diamond knife on a LKB or Reichert Ont/2 ultramicrotome and floated on a water bath buffered at pH 7.4. Sections were stained with uranyl acetate and lead citrate and were examined with a Philips 200 and 300 electron microscope.

Five additional rats from each time interval and dose level were used for histochemical evaluation of the thyroid gland and serum levels of thyroid hormone. Tissues for histochemistry were collected in dry ice at necropsy. Acid phosphatase naphthol-AS-BI reaction was evaluated on selected thyroid sections from rats in all experimental groups.[28] Thyroid glands for histopathologic evaluation were fixed in phosphate-buffered formalin and stained with hematoxylin and eosin and the periodic acid–Schiff reaction. Serum thyroxine levels were determined in 5 rats at each time interval and dose level of PCB by radioimmunoassay (Bio-Science Laboratories, Van Nuys, Calif.).

Results

Histopathology and Histochemistry

Control Rats

The thyroid glands of control rats in all groups were similar histologically and will be described together. They were composed of prominent follicles lined by a single layer of cuboidal and low columnar epithelial cells (Figure 1). Follicular cells had a lightly eosinophilic cytoplasm and a centrally placed, round, basophilic nucleus. Colloid in the follicular lumens was either homogeneous or slightly vacuolated near the periphery. Thyroid C cells were present in small clumps of three to four cells between follicles or as individual cells within follicular walls. Interfollicular capillaries were separated from follicles by a thin basement membrane.

Low Dose Polychlorinated Biphenyl (50 ppm) for Four Weeks

Thyroid glands were slightly enlarged, and follicles were small and

MONS 001188

lined by a single layer of columnar epithelium. The cytoplasmic area of follicular cells was lightly eosinophilic and vacuolated. Acid phosphatase activity in follicular cells was increased compared to control rats.

High Dose Polychlorinated Biphenyl (500 ppm) for Four Weeks

Thyroid glands were enlarged and were composed of small, irregularly shaped follicles lined by single or multiple layers of columnar epithelial cells. Papillary projections of hyperplastic follicular cells extended into the lumens of some follicles (Figure 2). Numerous cytoplasmic processes projected into the colloid from the apical surface of follicular cells. Acid phosphatase activity in the cytoplasm of follicular cells was increased compared to control values.

Low-Dose Polychlorinated Biphenyl (50 ppm) for Twelve Weeks

Thyroid glands were enlarged and were composed of small follicles lined by single or multiple layers of columnar cells. Cytoplasmic processes extended from the apical surfaces of follicular cells into the colloid. The cytoplasm of follicular cells was vacuolated, and the nucleus was basally situated. Acid phosphatase activity in follicular cells was strong and increased compared to control rats (Figure 3).

High-Dose Polychlorinated Biphenyl (500/250 ppm) for Twelve Weeks

Thyroid glands had changes similar to those described in rats fed 500/250 ppm PCB for 4 weeks. Papillary projections of hyperplastic follicular cells and prominent cytoplasmic processes extended into the colloid (Figure 4). The cytoplasmic area of follicular cells appeared vacuolated and had strong acid phosphatase activity.

Delayed Effects of Polychlorinated Biphenyl

Thyroid follicles in rats receiving either 50 or 500/250 ppm PCB for 12 weeks followed by an interval of 12 weeks without PCB prior to euthanasia were lined by a single layer of columnar cells. Multiple layers of follicular cells with papillary and cytoplasmic projections were not present in thyroids of rats from this group. The cytoplasm of follicular cells only had occasional vacuoles, and there was peripheral scalloping of colloid.

Long-Term Delayed Effects of Polychlorinated Biphenyl

Thyroid glands of rats fed either 50 or 500/250 ppm PCB for 12 weeks and followed by an interval of 35 weeks without PCB prior to euthanasia were similar to those of control rats. Thyroid follicles were large and lined by a single layer of cuboidal to low columnar cells. The cytoplasm of

MONS 001189

follicular cells was uniformly eosinophilic, and the nucleus was located centrally. There was only a mild increase in acid phosphatase activity in follicular cells compared to controls.

Ultrastructural Evaluation of Thyroid Glands

Control Rats

Thyroid glands of control rats from all groups were similar and were composed of follicles lined by a single layer of cuboidal cells situated on a thin basement membrane. The cytoplasm contained long profiles of rough endoplasmic reticulum with numerous cisternae containing a finely granular electron-dense material. The cisternae appeared as long narrow spaces and were not dilated. The Golgi apparatus was of moderate size and composed of flattened layers of smooth membranes associated with small dense granules. Mitochondria with transverse cristae were scattered throughout the cytoplasmic area. A narrow layer of electron-dense apical vesicles was present near the luminal border immediately beneath the microvilli. Microvillar projections from the luminal surface were uniform in width and length. Occasional membrane-limited colloid droplets and small, round lysosomal bodies were present in the cytoplasm.

Low-Dose Polychlorinated Biphenyl (50 ppm) for Four Weeks

Follicular cells were larger and more columnar than in controls (Figure 5). Profiles of rough endoplasmic reticulum were numerous, and their cisternae frequently were dilated with a finely granular material. The Golgi apparatuses were more prominent than in controls and were associated with many small granules. The oval nucleus was basally placed in follicular cells. Microvilli were shortened and irregular in shape and had abnormal branching (Figure 6). Long projections of follicular cell cytoplasm often extended from the apical surface into the luminal colloid (Figure 7). Electron-dense apical vesicles appeared to accumulate immediately beneath the microvilli. Large abnormally shaped lysosomal bodies with a heterogeneous internal structure were present in greater numbers than in control rats.

High-Dose Polychlorinated Biphenyl (500 ppm) for Four Weeks

Follicular cells were more columnar than in controls and occasionally were present in multiple layers lining thyroid follicles (Figure 8). The cytoplasmic area contained long profiles of rough endoplasmic reticulum that was often irregularly dilated by a finely granular material. Mitochondria were frequently swollen and had disrupted cristae compared

MONS 001190

to thyroids in control rats. The basally located nucleus was oval and contained coarsely granular chromatin. Striking changes were detected in the microvilli on the luminal border of follicular cells as described for the previous group. Microvilli were shortened and irregularly branched. Areas of the luminal surface of follicular cells were devoid of microvilli. These areas often had large cytoplasmic projections into the luminal colloid. Numerous apical vesicles were present immediately beneath the altered luminal surface. Membrane-limited colloid droplets and abnormally large electron-dense lysosomal bodies were increased in numbers within the cytoplasm.

Low-Dose Polychlorinated Biphenyl (50 ppm) for Twelve Weeks

Follicular cells were more columnar than in control rats and had small profiles of rough endoplasmic reticulum irregularly dilated with finely granular material. The Golgi apparatus was compressed near the nucleus and was less extensive than in controls. Mitochondria were large but frequently were swollen and had disrupted cristae. There was a marked reduction in the number and length of microvilli on the luminal surface of follicular cells. The surface of follicular cells was irregular and had large projections of apical cytoplasm that extended into the colloid. There was a marked increase in large, membrane-limited colloid droplets in the cytoplasm. In addition, lysosomal bodies were increased in follicular cells of rats of this group. They were extremely electron dense, irregular in size and shape, and occasionally appeared to be fused with the colloid droplets.

High-Dose Polychlorinated Biphenyl (500/250 ppm) for Twelve Weeks

Thyroid follicles were lined by single or occasionally multiple layers of columnar cells. The Golgi apparatus and rough endoplasmic reticulum were less well developed in follicular cells due to the abnormal accumulation of numerous lysosomal bodies and colloid droplets (Figure 9). The cytoplasmic area of some hypertrophied follicular cells appeared to be distended by the large numbers of lysosomal bodies and colloid droplets. Mitochondria were more irregular and swollen with disrupted cristae than were those in rats from any of the other experimental groups. Microvilli on the luminal surfaces of most follicular cells appeared to be abnormally short, blunt, and branched (Figure 10). Extensive areas of the luminal surface of follicular cells were devoid of microvilli, and occasionally unique cytoplasmic projections extended into the colloid. These changes were similar but more extensive than those in rats receiving 50 ppm PCB for 12 weeks.

MONS 001191

Delayed Effects of Low-Dose (50 ppm) Polychlorinated Biphenyl

Follicular cells were more columnar than in control rats and often had hypertrophied cytoplasmic area (Figure 11). There was less evidence of multiple layers of follicular cells lining follicles than in the previous experimental groups. Mitochondrial swelling and disruption of cristae were less evident than in rats killed immediately after receiving PCB for 12 weeks. Microvilli on the luminal surface were fewer in number and shorter than in control rats but were more normal in shape than those in rats receiving PCB for 12 weeks and killed immediately. Few apical vesicles were present beneath the microvilli. The number of irregularly shaped extremely dense lysosomal bodies remained greater compared to controls.

Delayed Effects of High-Dose (500/250 ppm) Polychlorinated Biphenyl

Thyroid follicles were lined either by tall columnar or hypertrophied cuboidal cells, but there was less evidence of multiple layers of follicular cells than in rats receiving PCB for 12 weeks and then killed. The rough endoplasmic reticulum was less well developed than in controls, and the Golgi apparatus was small. Occasional mitochondria were swollen and had disrupted cristae. Microvilli on the luminal surface of some follicular cells were short and blunt; however, many cells had normal appearing microvilli. Large cytoplasmic projections from the luminal surface were observed infrequently. Numerous irregular lysosomal bodies and colloid droplets also were present in follicular cells.

Long-Term Delayed Effects of Low and High-Dose Polychlorinated Biphenyl

Follicular cells of rats receiving either 50 or 500/250 ppm of PCB for 12 weeks followed by an interval of 35 weeks without PCB were similar, ultrastructurally, to those of control rats (Figure 12). The endoplasmic reticulum was well developed and consisted of long profiles with narrow cisternae containing a finely granular material. Dilated profiles of endoplasmic reticulum were present, but they were considerably reduced when compared to previous experimental groups. The Golgi apparatus was prominent and was associated with numerous dense granules. Mitochondria in follicular cells were present in similar numbers as in control rats. Only an occasional mitochondrion was swollen with disruption of cristae. Microvilli in the luminal surface were numerous and had a normal configuration. Many apical vesicles were present immediately beneath the microvilli. Lysosomal bodies and colloid droplets were markedly decreased in most follicular cells compared to previous experimental groups. Lysosomal bodies present in follicular cells resembled those in controls

MONS 001192

and were round, with a more homogeneous internal structure. Only a few follicular cells contained numerous irregularly shaped lysosomes similar to those in the previous experimental groups. The residual ultrastructural alterations in follicular cells of rats from this group appeared to be minimal by comparison to all other PCB-treated rats.

Ultrastructural alterations were not detected in thyroid C cells related to PCB administration.

Serum Thyroxine

The serum thyroxine concentrations of control and experimental rats fed PCB were determined by radioimmunoassay, and groups were compared statistically using the Student *t* test (Table 1). Thyroxine levels were significantly reduced in rats fed 50 and 500/250 ppm PCB daily for 4 and 12 weeks. The greatest reduction in serum thyroxine levels occurred at 12 weeks in rats receiving the high dose of PCB (Table 1). Serum thyroxine levels had returned toward normal values in rats administered either high or low doses of PCB for 12 weeks followed by a 12-week recovery interval without PCB prior to euthanasia, but they remained significantly lower than in control rats (Table 1). In rats receiving PCB for 12 weeks followed by a 35-week interval without PCB the serum thyroxine had returned to within the normal range (Table 1).

Discussion

The daily feeding of polychlorinated biphenyl compounds to rats produced striking ultrastructural alterations in thyroid follicular cells and in the metabolism of thyroid hormone. There was a progressive accumulation of large, abnormally shaped lysosomal bodies with strong acid phosphatase activity and numerous colloid droplets in follicular cells. Mitochondria

Table 1—Serum Thyroxine Levels (Mean ± SE) of PCB-Treated and Control Rats Determined by Radioimmunoassay

Rat group	Acute effects (4 weeks PCB) (μg/dl)	Chronic effects (12 weeks PCB) (μg/dl)	Delayed effects (12 weeks PCB; 12 weeks no PCB) (μg/dl)	Long-term delayed effect (12 weeks PCB; 35 weeks no PCB) (μg/dl)
Controls	6.66 ± 0.3	7.18 ± 0.4	7.86 ± 0.8	6.18 ± 0.9
50 ppm PCB	4.80 ± 0.3†	1.96 ± 0.2‡	4.90 ± 0.1*	5.86 ± 1.2
500/250 ppm PCB	2.10 ± 0.2‡	1.78 ± 0.08‡	3.01 ± 0.8†	6.02 ± 1.3

N = 5 rats per dose and interval.
* $P < 0.025$.
† $P < 0.005$.
‡ $P < 0.001$.

MONS 001193

were swollen, and cristae often were disrupted. The lowest dose of polychlorinated biphenyl (50 ppm) administered to rats in this investigation for 4 weeks resulted in the formation of blunt, irregularly branched microvilli with unique cytoplasmic projections into the luminal colloid. These ultrastructural changes were interpreted to be a direct effect of PCB and were associated with a significant decrease in serum thyroxine levels after 4 weeks.

Follicular cells in rats receiving PCB for 4 and 12 weeks were hypertrophied and more columnar than in controls. They often were present in multiple layers lining thyroid follicles and occasionally extended as papillary projections of hyperplastic follicular cells into the lumen. The rough endoplasmic reticulum and Golgi apparatus were well developed in follicular cells and numerous apical vesicles were present near the luminal surface. These ultrastructural changes suggesting increased secretory activity were interpreted to be a compensatory reaction by follicular cells to the lowered blood thyroxine levels and were similar to those reported following thyroid stimulation by thyrotrophin.[20,30] These findings are consistent with the report of Bastomsky,[31] who detected increased ^{131}I uptake by the thyroid gland following PCB administration in rats. In birds, this effect of PCB appears to be accentuated and results in a goitrous enlargement of the thyroid gland.[19] A similar compensatory hypertrophy and hyperplasia of follicular cells has been produced in animals by other polycyclic hydrocarbon compounds which also are inducers of hepatic microsomal enzymes.[20,29-32]

More severe ultrastructural lesions were observed in thyroid follicular cells with the higher dose (500/250 ppm) of PCB or with chronic administration of the compound. After feeding the high dose of PCB for 12 weeks, extensive areas of the luminal surface of follicular cells were devoid of microvilli, and abnormal cytoplasmic projections extended into the lumen. Increased numbers of abnormal lysosomes and numerous colloid droplets accumulated in the cytoplasm of follicular cells, resulting in displacement and compression of the rough endoplasmic reticulum and Golgi apparatus. Serum thyroxine levels were markedly decreased in rats that had severe ultrastructural lesions in follicular cells after receiving either the low or high dose of PCB for 12 weeks.

Residual effects of PCB on thyroid structure and function were observed in rats evaluated 12 weeks after the last dose; however, minimal alterations persisted in follicular cells after 35 weeks. Microvilli were fewer in number and shorter than in controls after 12 weeks' recovery; large accumulations of lysosomal bodies and colloid droplets remained in the cytoplasm; and serum thyroxine levels had increased compared to rats

MONS 001194

fed PCB for 12 weeks and killed immediately but were still significantly lower than in controls. These residual effects presumably were related to the long half-life of PCB and storage in adipose tissue.[22] Follicular cells of rats fed PCB for 12 weeks followed by an interval of 35 weeks prior to evaluation were similar ultrastructurally to controls, and serum thyroxine levels had returned to within the normal range.

The striking ultrastructural alterations in thyroid follicular cells of rats following PCB administration probably contributed in part to the highly significant decrease of serum thyroxine levels in experimental rats. In spite of the alterations in microvillar structure, follicular cells appeared capable of taking up colloid droplets by endocytosis. However, the increased number of lysosomal bodies with strong acid phosphatase activity in experimental rats appeared unable to interact with colloid droplets in a normal manner and hydrolyze the cleavage of active thyroid hormone from the molecular structure of thyroglobulin in colloid droplets. This resulted in a striking accumulation of colloid droplets and lysosomal bodies after chronic administration of PCB, resulting in a displacement of synthetic organelles such as the endoplasmic reticulum and Golgi apparatus.

In addition to the direct effect on follicular cells, PCB compounds are known to significantly enhance the peripheral metabolism of thyroxine and to reduce the binding of thyroid hormones to serum proteins. This results in a lowering of the levels of serum thyroxine and protein-bound iodine in rats.[21] The biliary excretion of thyroxine is enhanced (four to fivefold) by PCB, and following intravenous injection of ^{125}I-thyroxine there is an increased proportion of biliary ^{125}I as thyroxine-glucuronide.[23] The increased hepatic conjugation of thyroxine to glucuronic acid and excretion in the bile in rats receiving PCB probably are secondary to the induction of hepatic microsomal thyroxine-UDP glucuronyltransferase.[24]

The results of this investigation and other studies reported in the literature demonstrated a highly significant reduction in serum thyroxine by PCB. The lowering of circulating thyroxine levels by PCB is dose- and time-dependent and appears to be the combined result of a direct effect on thyroid follicular cells with an interference in hormone secretion plus an enhanced peripheral metabolism of thyroxine. Some of the metabolic alterations produced by PCB intoxication in experimental animals and human beings such as decreased weight gain,[9,10] reduced feed efficiency,[10] decreased reproductive performance,[18] and skin lesions with hyperpigmentation may be related to an alteration in thyroid function.

References

1. Gustafson CG: PCB's—prevalent and persistent. Environ Sci Technol 4:814–819, 1970

MONS 001195

2. Kolbye AC: Food exposures to polychlorinated biphenyls. Environ Health Perspect 1:85–88, 1972
3. Polychlorinated biphenyls—environmental impact: A review by the panel of hazardous trace substances. Environ Res 5:249–362, 1972
4. Kimbrough RD: The toxicity of polychlorinated polycyclic compounds and related chemicals. CRC Crit Rev Toxicol 2:445–498, 1974
5. Hammond AL: Chemical pollution: Polychlorinated biphenyls. Science 175:155–156, 1972
6. Finklea J, Priester LE, Creason JP, Hauser T, Hinners T, Hammer DI: Polychlorinated biphenyl residues in human plasma expose a major urban pollution problem. Am J Public Health 62:645–51, 1972
7. Price NO, Young RW, Dickinson JK: Pesticide residues and polychlorinated biphenyl levels in diets, urine, and fecal matter of preadolescent girls. Proc Soc Exp Biol Med 139:1280–1283, 1972
8. Kuratsune M, Yoshimura T, Matsuzaka J, Yamaguchi A: *Epidemiologic study on yusho, a poisoning caused by ingestion of rice oil contaminated with a commercial brand of polychlorinated biphenyls.* Environ Health Perspect 1:119–128, 1972
9. Platonow NS, Saschenbrecker PW, Funnell HS: Residues of polychlorinated biphenyls in cattle. Can Vet J 12:115–118, 1971
10. Harris JR, Rose L: Toxicity of polychlorinated biphenyls in poultry. J Am Vet Med Assoc 161:1584–1586, 1972
11. Kimbrough RD, Linder RE, Gaines TB: Morphological changes in livers of rats fed polychlorinated biphenlys: Light microscopy and ultrastructure. Arch Environ Health 25:354–364, 1972
12. Grant DL, Moodie CA, Phillips WEJ: Toxicodynamics of Aroclor 1254 in the male rat. Environ Physiol Biochem 4:214–225, 1974
13. Kasza L, Weinberger MA, Carter C, Hinton DE, Trump BF, Brouwer EA: Acute subacute, and residual effects of polychlorinated biphenyl (PCB) in rats. II Pathology and electron microscopy of liver and serum enzyme study. J Toxicol Environ Health 1:689–703, 1976
14. Vos JG, Beems RB: Dermal toxicity studies of technical polychlorinated biphenyls and fractions thereof in rabbits. Toxicol Appl Pharmacol 19:617–633, 1971
15. Vos JG, Koeman JH: Comparative toxicologic study with polychlorinated biphenyls in chickens with special reference to porphyria, edema formation, liver necrosis, and tissue residues. Toxicol Appl Pharmacol 17:656–668, 1970
16. Hansen LG, Wilson DW, Byerly CS: Effects on growing swine and sheep of two polychlorinated biphenyls. Am J Vet Res 37:1021–1024, 1976
17. Hansen LG, Byerly CS, Metcalf RL, Bevill RF: Effect of a polychlorinated biphenyl mixture on swine reproduction and tissue residues. Am J Vet Res 36:23–26, 1975
18. Ax RL, Hansen LG: Effects of purified polychlorinated biphenyl analogs on chicken reproduction. Poult Sci 54:895–900, 1975
19. Jefferies DJ, Parslow JL: Effect of one polychlorinated biphenyl on size and activity of the gull thyroid. Bull Environ Contam Toxicol 8:306–310, 1972
20. Hurst JG, Newcomer WS, Morrison JA: Some effects of DDT, toxaphene, and polychlorinated biphenyl on thyroid function in Bobwhite Quail. Poult Sci 53:125–133, 1974
21. Bastomsky CH: Effects of a polychlorinated biphenyl mixture (Aroclor 1254) and DDT on biliary thyroxine excretion in rats. Endocrinology 95:1150–1155, 1974
22. Bastomsky CH, Wyse JM: Enhanced thyroxine metabolism following cutaneous application of microscope immersion oil. Res Commun Chem Pathol Pharmacol 10:725–733, 1975
23. Bastomsky CH, Murthy PV, Banovac K: Alterations in thyroxine metabolism produced by cutaneous application of microscope immersion oil: Effects due to polychlorinated biphenyls. Endocrinology 98:1309–1314, 1976

MONS 001196

24. Bastomsky CH, Murthy PV: Enchanced *in vitro* hepatic glucuronidation of thyroxine in rats following cutaneous application or ingestion of polychlorinated biphenyls. Can J Physiol Pharmacol 54:23–26, 1976
25. Burstone MS: Histochemical comparison of naphthol AS-phosphates for the demonstration of phosphatases. J Natl Cancer Inst 20:601–616, 1958
26. Lupulescu A, Petrovici A: *Ultrastructure of the Thyroid Gland*. Basel, S. Karger, 1968, pp 54–55
27. Seljelid R, Helminen HJ, Thies C: Effect of long-term suppression and stimulation of rat thyroid with special reference to lysosomes. Exp Cell Res 69:249–258, 1971
28. Wetzel BK, Spicer SS, Wollman SH: Changes in fine structure and acid phosphatase localization in rat thyroid cells following thyrotropin administration. J Cell Biol 25:593–618, 1965
29. Fregly MJ, Waters IW, Straw JA: Effect of isomers of DDD on thyroid and adrenal function in rats. Can J Physiol Pharmcol 46:59–66, 1968
30. Jefferies DJ, French MC: Avian thyroid: Effect of p,p'-DDT on size and activity. Science 166:1278–1280, 1969
31. Jefferies DJ, French MC: Changes induced in the pigeon thyroid by p,p'-DDE and dieldrin. J Wildl Management 36:24–30, 1972
32. Bichert EP, Prahlad KV: Effects of DDT and its metabolites on thyroid of the Japanese quail, *Coturnix coturnix japonica*. Poult Sci 51:196–200, 1972
33. Braunberg RC, Dailey RE, Brouwer EA, Kasza L, Blaschka AM: Acute, subacute, and residual effects of polychlorinated biphenyl (PCB) in rats. I. Biologic half-life in adipose tissue. J Toxicol Environ Health 1:683–688, 1976

Figure 1 (H&E. × follicles + Papillary the follic cells (ar cells (ar weeks +

MONS 001197









Figure 1—Follicles lined by cuboidal epithelium and containing partially vacuolated colloid (C) in thyroid gland of rat (H&E, × 315). Figure 2—Irregularly sized follicles in thyroid gland of rats fed 500/250 ppm PCB for 4 weeks. Many follicles (*F*) were smaller than in control rats, were lined by tall columnar epithelium, and contained sparse colloid. Papillary projections of hyperplastic follicular cells (*arrow*) and apical cytoplasmic processes (*arrowheads*) extend into the follicular lumens. (H&E × 315) Figure 3—Strong acid phosphatase reaction in apical portions of hyperplastic follicular cells (*arrow*) of rats fed 50 ppm PCB for 12 weeks (× 315). Figure 4—Papillary projections of hyperplastic follicular cells (*arrows*) extend into the *lumen of a* thyroid follicle lined by tall columnar cells. Rat fed 500/250 ppm PCB for 12 weeks. (H&E, × 315)

Figure 5—Thyroid follicular cell with expanded cytoplasmic area containing numerous dilated profiles of rough endoplasmic reticulum (*E*), a large Golgi apparatus (*G*), vacuolated mitochondria with disrupted cristae, and prominent lysosomal bodies (*L*). Microvilli are short and abnormal in shape (*arrows*), and portions of the apical cytoplasm (*P*) project into the follicular lumen. Rat fed 50 ppm PCB for 4 weeks. (× 11,000).

Figure 6—Apical surface of thyroid follicular cell with abnormally short, branched microvilli (*arrows*) and cytoplasmic projections (*P*) extending into the follicular lumen. Rat fed 50 ppm PCB for 4 weeks. (× 26,000)

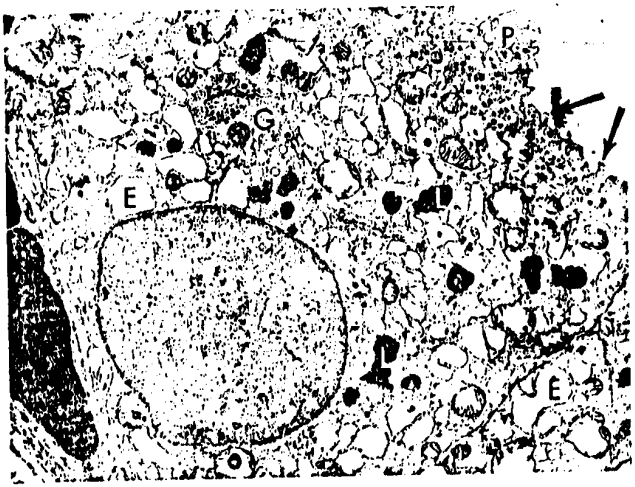

5



6

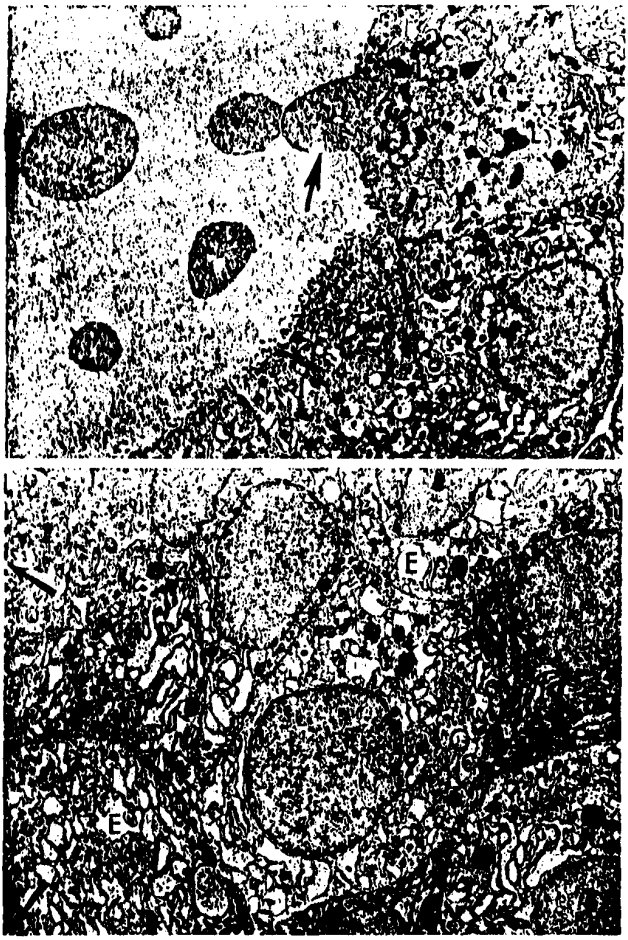

Figure 7—Follicular cell with large apical cytoplasmic processes (*arrow*) extending into follicular lumen. The hypertrophied follicular cells contain dilated profiles of rough endoplasmic reticulum (*E*), colloid droplets (*C*), and many large lysosomal bodies (*L*). Rat fed 50 ppm PCB for 4 weeks. (× 5800) **Figure 8**—Multiple layers of hyperplastic follicular cells lining thyroid follicle. The large cytoplasmic area of follicular cells contains numerous dilated profiles of rough endoplasmic reticulum (*E*) and large Golgi apparatuses (*G*). Microvilli extending into the follicular lumen (*L*) are short and abnormally branched (*arrows*). Rat fed 500/250 ppm PCB for 4 weeks. (× 5800)

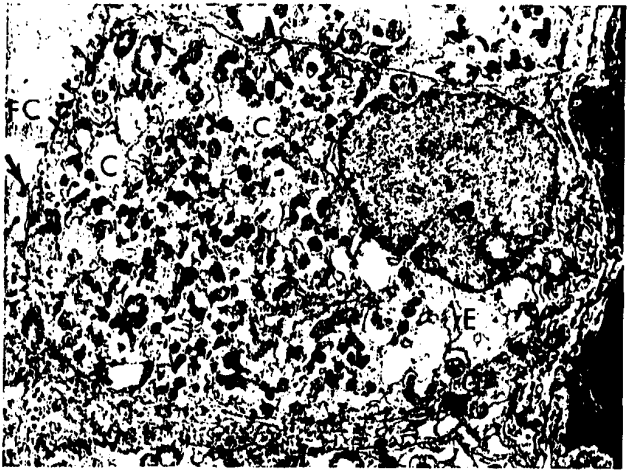

9



10

Figure 9—Thyroid follicular cell with an expanded cytoplasmic area filled with closely packed colloid droplets (C) and large lysosomal bodies (L). The rough endoplasmic reticulum (E), Golgi apparatus, and mitochondria are poorly developed and compressed by the numerous colloid droplets and lysosomes. Short microvilli (arrow) extend into follicular colloid (FC). Rat fed 500/250 ppm PCB for 12 weeks. (× 4700) Figure 10—Large membrane-limited colloid droplets (C) and numerous lysosomal bodies (L) in thyroid follicular cell of a rat fed 500/250 ppm PCB for 12 weeks. Short, abnormally branched microvilli (arrow) project from the apical surface of the follicular cell into the lumen. (× 23,800)

MONS 001202



11

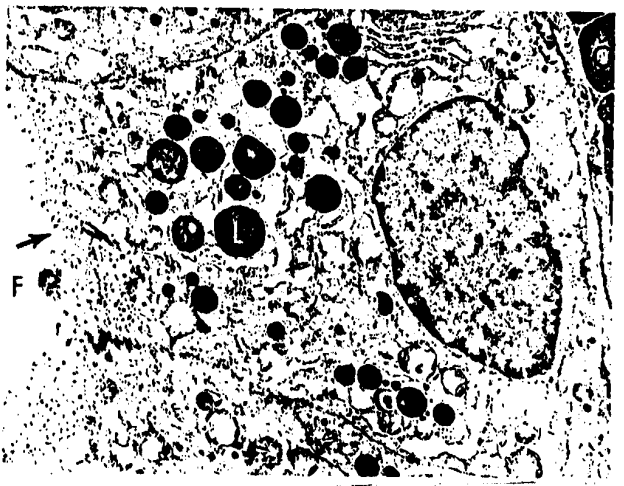

12

Figure 11—Tall columnar follicular cells with markedly increased numbers of lysosomal bodies and short abnormally shaped microvilli lining a thyroid follicle. The cytoplasmic area is filled with large irregularly shaped lysosomes (*L*), colloid droplets (*C*), and dilated profiles of rough endoplasmic reticulum (*E*). Rat fed 50 ppm PCB for 12 weeks followed by a 12-week interval with no PCB prior to euthanasia. (× 5700) **Figure 12**—Thyroid follicular cell with similarly developed microvilli (*arrow*) and cytoplasmic organelles as in control rats, except for a moderate increase in the numbers of round lysosomal bodies (*L*). Rat fed 50 ppm PCB for 12 weeks followed by a 35-week interval with no PCB prior to euthanasia. *F* = follicular lumen, *C* = interfollicular capillary. (× 10,300).

MONS 001203

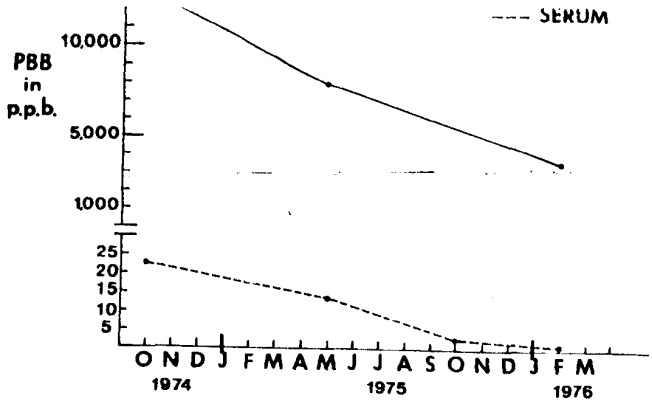

Figure 2. PPB Level v. Time

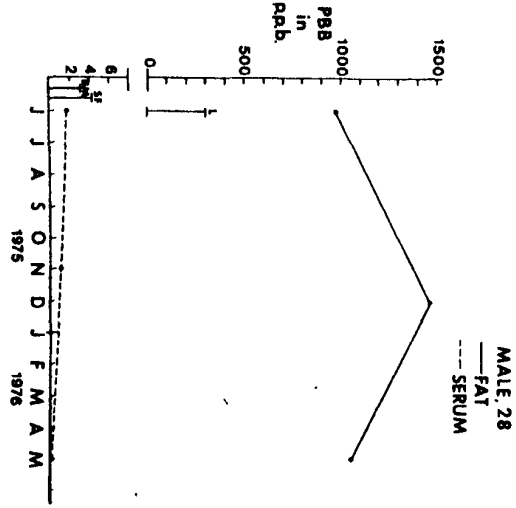

Figure 3. PPB Level v. Time

MEDICAL LIBRARY
MONS 001204

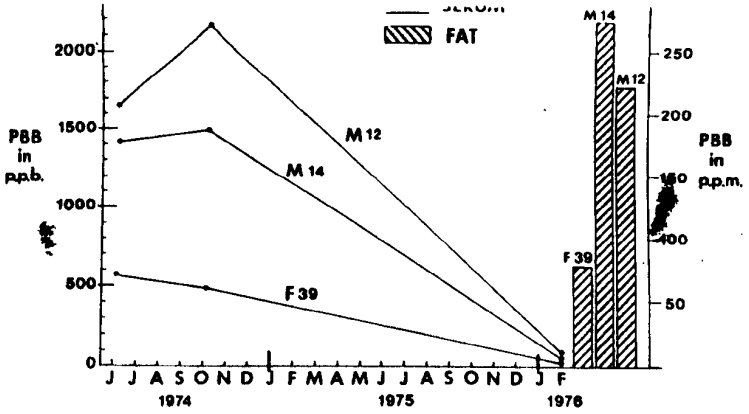

Figure 4. PPB Level v. Time

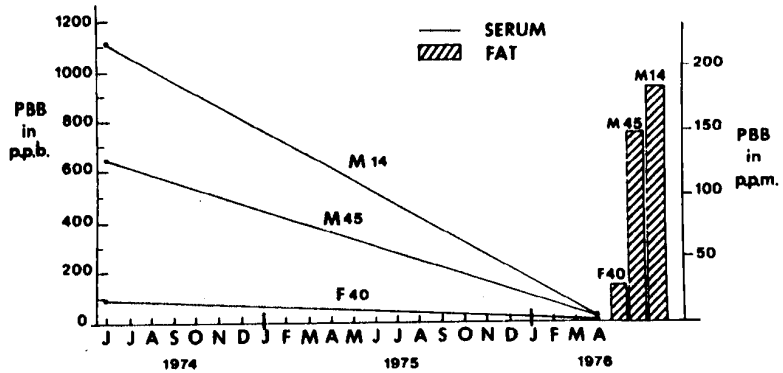

Figure 5. PPB Level v. Time

MONS 001205