Exp Toxic Pathol 1992; 44: 55–58
Gustav Fischer Verlag Jena

Department of Histology, Fraunhofer Institute of Toxicology and Aerosol Research, Hannover, Germany

Atypical malignant mesotheliomas with osseous and cartilaginous differentiation after intraperitoneal injection of various types of mineral fibres in rats

S. RITTINGHAUSEN, H. ERNST, H. MUHLE and U. MOHR

With 4 figures and 1 table

Received: February 11, 1991; Accepted: February 14, 1991

Address for correspondence: Dr. S. RITTINGHAUSEN, Fraunhofer Institute of Toxicology and Aerosol Research, Nikolai-Fuchs-Straße 1, D-W-3000 Hannover 61, Germany

Key words: atypical malignant mesothelioma; osseous differentiation; cartilaginous differentiation; abdominal cavity; asbestos; mineral fibres; rat

Summary

The histopathological appearance of malignant mesotheliomas with osseous and cartilaginous differentiation is described in detail. Bone and cartilage occurred in mixed and sarcomatoid mesotheliomas which were induced by intraperitoneal injection of various types of asbestos fibres (asbestos cement, crocidolite, UICC-amosite, UICC-chrysotile B, Calidria-chrysotile). Bone or cartilage were found in 32.7% of mixed mesothelioma and in 12.8% of sarcomatoid mesotheliomas.

Introduction

Malignant mesotheliomas are markedly variable in morphological appearance. Three different histological types can be distinguished: epithelioid, sarcomatoid (mesenchymal), and mixed neoplasms. A few cases of mesotheliomas with cartilaginous and osseous differentiation have been described in man (GOLDSTEIN 1979; MCCAUGHEY 1958; YOUSEM and HOCHHOLZER 1987). Exposure of affected patients to asbestos was evident in some of the cases (GOLDSTEIN 1979; YOUSEM and HOCHHOLZER 1987). The present report describes the histopathological features of malignant mesotheliomas with osseous and cartilaginous differentiation which occurred in the abdominal cavity of female Wistar rats after intraperitoneal injection of different types of asbestos.

Material and Methods

Suspensions of selected types of mineral fibres were injected twice intraperitoneally into female Han:WIST rats (Central Institute for Laboratory Animal Breeding, Hannover) with a time interval of one week between the injections. Fibres were suspended in 2 ml 0.9% saline (*p*H 6–8). For details see POTT et al. (1976). Types of mineral fibres and gravimetric doses are presented in table 1.

The rats were 11–12 weeks old at the start of the study and weighed 230 g. The number of animals was 50 in each group. They were kept in groups of a maximum of 8 in Macrolon® cages (type IV) during the first year of the study. Afterwards, they were caged individually in Macrolon® cages (type II) to avoid losses by cannibalism. Rats were maintained under standard laboratory conditions (22 ± 2 °C, relative humidity 55 ± 5%, air exchange rate 8 times/h) and were given a commercial cereal-based diet (RMH-GS, Hope Farms, Woerden, Netherlands) and water *ad libitum*.

The animals were killed when moribund or with obvious clinical signs indicating abdominal neoplasms. Surviving rats were killed 130 weeks after the initial treatment. A complete necropsy was performed on all animals. Tumours were fixed in 10% formalin and representative samples of the neoplasms were embedded in paraffin wax. Sections (4 µm) were stained routinely with hematoxylin and eosin.

Results

Experimental data and frequency of tumours found are given in table 1. Malignant mesotheliomas with multiple metastases in the abdominal cavity and infiltration into various organs were observed in rats of groups 1, and 4–8.

The overall frequency of sarcomatoid tumours in positive groups was 15.6% and of these 12.8% had foci with bone and/or cartilage. The overall frequency of mixed tumours in positive groups was 18.3% and of these 32.7% had foci of bone and rarely cartilage.

The great majority (21/23) of these tumours revealed only focal osseous differentiation. Only 2 neoplasms additionally had areas with chondroid appearance. One was a mixed and one a sarcomatoid malignant mesothelioma.

Histologically, mixed malignant mesotheliomas consisted of an epithelioid component forming either sheets of cells or papillary projections and sarcomatoid parts composed of bund-

PLAINTIFF'S
EXHIBIT
SA-524

Table 1. Frequency (in %) of animals with malignant mesotheliomas.

	Type of fibres	Total dose (mg) i. p.	No.	Total Sarcomatoid Type	Sarcomatoid Type with Bone/Cartil.	Total Mixed Type	Mixed Type with Bone/Cartil.	Epithelioid Type	Total Incidence
1	Asbestos Cement	60 mg	50	18 (36)	0	15 (30)	7 (14)	5 (10)	38 (76)
2	Cement	50 mg	50	0	0	0	0	0	0
3	Wollastonite	30 mg	50	0	0	0	0	0	0
4	Crocidolite	3 mg	50	5 (10)	0	14 (28)	4 (8)	13 (26)	32 (64)
5	Calidria-Chrysotile	3 mg	50	1 (2)	1 (2)	2 (4)	0	2 (4)	5 (10)
6	Calidria-Chrysotile	1 mg	50	0	0	1 (2)	0	0	1 (2)
7	UICC-Amosite	30 mg	50	9 (18)	2 (4)	10 (20)	5 (10)	13 (26)	32 (64)
8	UICC-Chrysotile-B	1 mg	50	6 (12)	2 (4)	13 (26)	2 (4)	12 (24)	31 (62)
9	Vehicle Control	2 ml	50	0	0	0	0	0	0

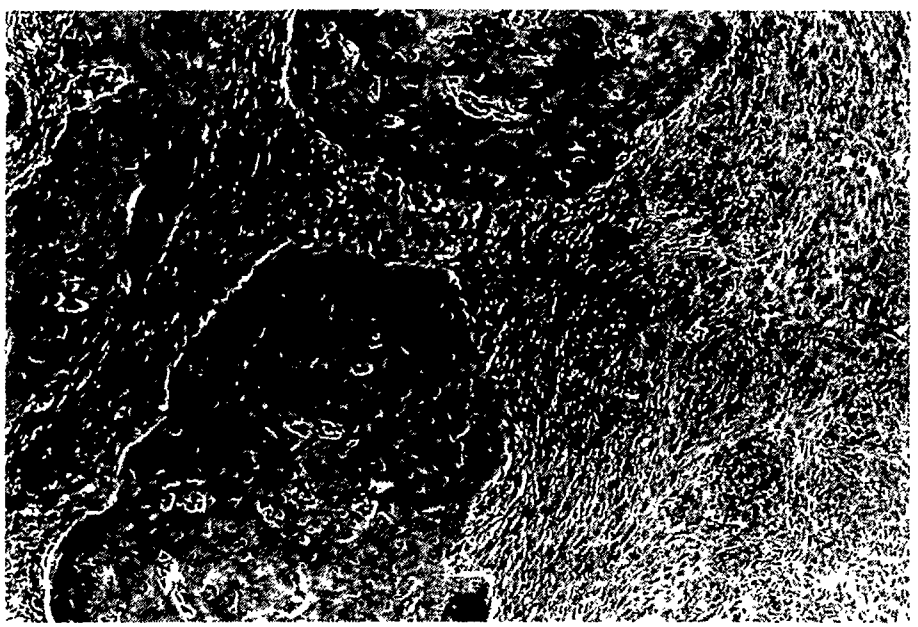

Fig. 1. Plaques of osteoid embedded in sarcomatous tissue in a malignant mesothelioma induced by intraperitoneal injection of crocidolite. H. E., x 192.

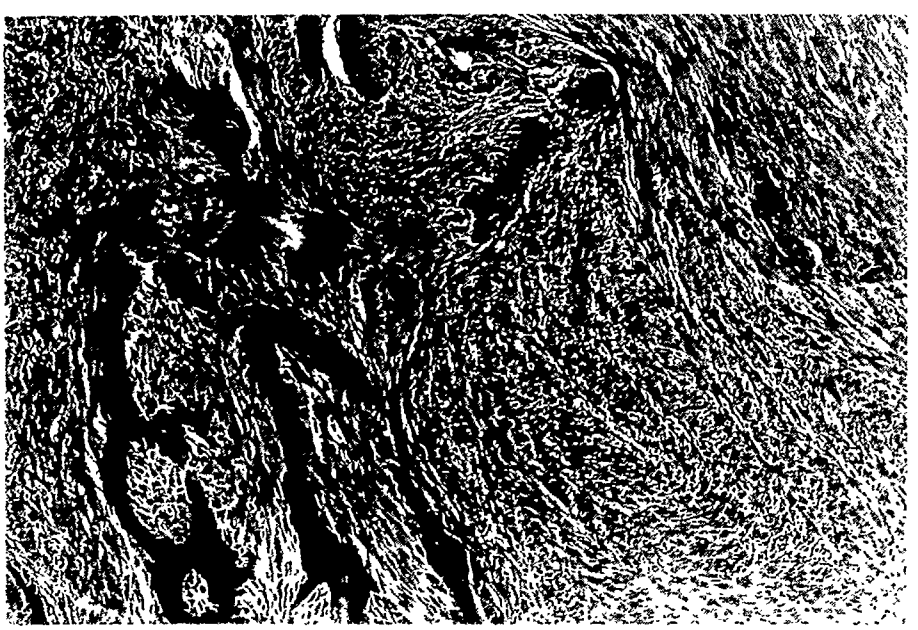

Fig. 2. Spicules and trabeculae of bone embedded in sarcomatous tissue in a malignant mesothelioma induced by crocidolite. H. E., x 192.

Total
Inciden

38 (76)
0
0
32 (64)
5 (10)
1 (2)
32 (64)
31 (62)
0



Fig. 3. Cartilage, osteoid and calcified osteoid in a malignant mesothelioma induced by intraperitoneal injection of UICC-Amosite. H. E., x 192.

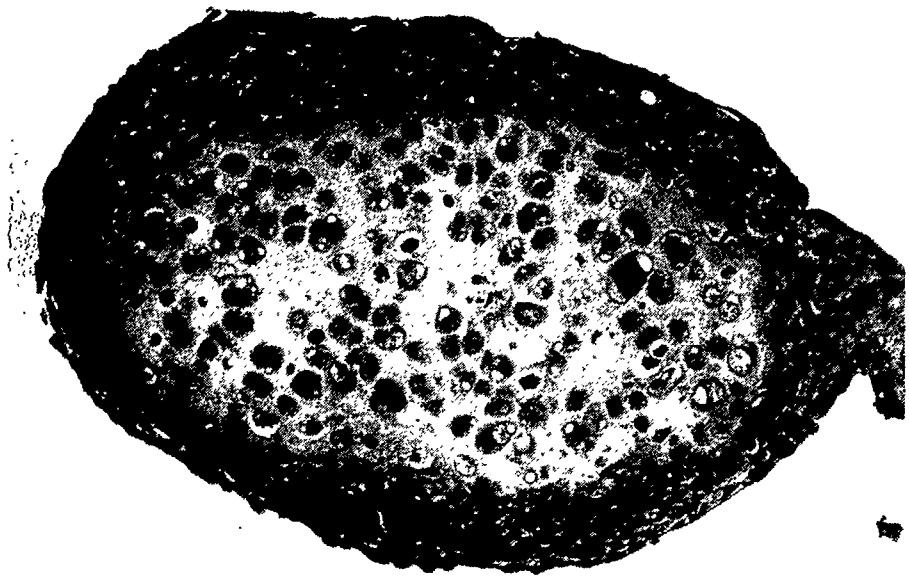

Fig. 4. Island of cartilaginous differentiation surrounded by villous proliferation of tumour cells on the surface of a malignant mesothelioma induced by asbestos cement. H. E., x 307.

les of elongated cells with abundant collagen fibres between the bundles. Sarcomatoid mesotheliomas consisted entirely of the latter cell type. Areas with osseous or cartilaginous differentiation were found exclusively within the sarcomatoid parts of the tumours. Osteoid was arranged in plaques (fig. 1) or broad trabeculae between the bundles of mesothelioma cells. Osteoblasts were found within the osteoid. Various stages of calcification up to distinct irregular spicules of bony tissue (fig. 2) could be observed among the various neoplasms. Size of areas with osseous differentiation and degree of calcification varied greatly among different sites of the same tumour as well as among different tumour-bearing animals. In only 2 neoplasms were foci of cartilage observed. They were found adjacent to areas with osseous differentiation (fig. 3) as well as in the form of solitary islands of cartilage (fig. 4).

Discussion

A few cases of osseous and cartilaginous differentiation in malignant mesotheliomas have been reported in man (GOLDSTEIN 1979; MCCAUGHEY 1958; YOUSEM and HOCHHOLZER 1987). All of them occurred in the thoracic cavity. YOUSEM and HOCHHOLZER (1987) reported that in 5 of 6 cases in which an exposure history was taken an asbestos exposure was documented. One of the 2 patients described by GOLDSTEIN (1979) worked in an amosite mine. To our knowledge, there have been no previous reports of either spontaneous or induced peritoneal mesotheliomas with osseous or cartilaginous tissue in rats or other laboratory animals.

The tumours reported in this study occurred in female Wistar rats after intraperitoneal injection of different types of

mineral fibres. Their histological appearance was quite similar to the neoplasms reported in man. In contrast to these findings, no osseous or cartilaginous differentiation was observed in malignant mesotheliomas of male Wistar rats induced by intraperitoneal injection of UICC-chrysotile and UICC-crocidolite (SHIN and FIRMINGER 1973). Since the sex of the animals in their study was different from our study, we cannot completely exclude the possibility that hormonal factors influenced the results. Furthermore, the male rats used by SHIN and FIRMINGER received much higher doses of chrysotile and crocidolite (50 mg in a single dose compared to 3 mg) and their study was terminated much earlier (14 months after injection). Because of these differences in treatment one could argue that perhaps a dose-dependend, slower development of the neoplasms might have been the prerequisite for the osseous and cartilaginous differentiation in the tumours of our study. We are aware, however, that other and unknown environmental and experimental influences could also be the cause for the different findings.

Extraskeletal osteosarcoma must be considered as a differential diagnosis of the tumours described above. Extraskeletal osteosarcoma has been observed in man in the thoracic cavity (COHN and HALL 1968; IKEDA et al. 1974), but patients lacked an asbestos-exposure history. In one particular case, an extraskeletal osteosarcoma was reported to be present in the abdominal cavity of a male Balb/c mouse given amosite by intraperitoneal injection (SUZUKI and KOHYAMA 1984). The spontaneous occurrence of an extraskeletal osteosarcoma in an aged rat originating from the soft tissues of the thoracic cavity was described by MINATO et al. (1988). The tumour consisted of various cells representing features of osteoblasts in different developmental stages. The presence of epithelial cells in mixed mesotheliomas with osseous differentiation of this study is the most important distinguishing feature for differentiation from extraskeletal osteosarcomas. Much more difficult is the differentiation of sarcomatoid (mesenchymal) mesotheliomas with osseous differentiation from extraskeletal osteosarcomas. Since bone was only a minor part of the tumours without epithelial cells and the sarcomatoid component resembled closely that of sarcomatoid mesotheliomas without osseous differentiation, they were interpreted as a special type of malignant mesothelioma.

References

1. COHN L, HALL A D: Extraosseous osteogenic sarcoma of the pleura. Ann Thorac Surg 1968; **5**: 545–549.
2. GOLDSTEIN, B: Two malignant pleural mesotheliomas with unusual histology. Thorax 1979; **34**: 375–379.
3. IKEDA T, ISHIHARA T, YOSHIMATSU, et al.: Primary osteogenic sarcoma of the mediastinum. Thorax 1974; **29**: 582–588.
4. MCCAUGHEY W T E: Primary tumors of the pleura. J Pathol Bacteriol 1958; **56**: 517–529.
5. MINATO Y, YAMAMURA T, TAKADA H, et al.: An extraskeletal osteosarcoma in an aged rat. Jpn J Vet Sci 1988; **50**: 259–261.
6. POTT F, FRIEDRICHS K H, HUTH F: Ergebnisse aus Tierversuchen zur kanzerogenen Wirkung faserförmiger Stäube und ihre Deutung im Hinblick auf die Tumorentstehung beim Menschen. Zbl. Bakt. Hyg, I Abt. Orig B: 1976; **162**: 467–505.
7. SHIN M L, FIRMINGER H I: Acute and chronic effects of intraperitoneal injection of two types of asbestos in rats with a study of the histopathogenesis and ultrastructure of resulting mesotheliomas. Am J Pathol 1973; **70**: 291–314.
8. SUZUKI Y, KOHYAMA, N: Malignant mesothelioma induced by asbestos and zeolite in the mouse peritoneal cavity. Environm Res 1984; **35**: 277–292.
9. YOUSEM S A, HOCHHOLZER L: Malignant mesotheliomas with osseous and cartilaginous differentiation. Arch Pathol Lab Med 1987; **111**: 62–66.

2C 4599 F

1/ 44. Volume
March 1992

EXPERIMENTAL AND TOXICOLOGIC PATHOLOGY

Official Journal of the Gesellschaft für Toxikologische Pathologie



UT SOUTHWESTERN
MEDICAL CENTER
AT DALLAS
MAY
NOT TO BE TAKEN
FROM LIBRARY

ISSN 0940-2993

Exp Toxix Pathol · Jena · 44(1992) · pp. 1–60

SEMPER BONIS ARTIBUS
GUSTAV FISCHER
JENA · STUTTGART · NEW YORK