...y must be taken into consideration, there is little evidence to support it: administration of magnesium sulfate to rats under withdrawal had little apparent effect on behavior, weight, or excretion of magnesium in these rats; bone and muscle magnesium concentrations of morphine-treated rats were not statistically different from those of control animals. Nevertheless, it is not unusual to observe normal magnesium concentrations in tissues in the presence of either hypo or hypermagnesemia (Walser, 19...).

Since hypermagnesemia is often associated with an augmentation of magnesium clearance (McCance and Widdowson, 1939), the increase in magnesium excretion observed here could be explained on that basis. The augmentation in urinary magnesium excretion could also be due to the diuretic effect of chronic morphine treatment, which is associated with an increase in sodium, potassium, calcium, and urea excretion (Marchand and Denis, 1968); it is well known that an osmotic diuresis causes an augmentation in urinary magnesium excretion (Walser, 1967). Since morphine was administered in the form of the sulfate, the anion could be responsible for the increase in urine output (Walser and Browder, 1959). However, it has previously been shown that nalorphine ...cks the diuretic effect of chronic morphine administration (Marchand ... Denis, ...68).

ACKNOWLEDGMENTS

The authors wish to thank the Medical Research Council of Canada for financial support and Miss Claudette Lamoureux for her able technical assistance.

REFERENCES

McCance, R. A., and Widdowson, E. M. (1939). LXIV: The fate of calcium and magnesium after intravenous administration to normal persons. *Biochem. J.* **33**, 523–529.

Marchand, C., and Denis, G. (1968). Diuretic effect of chronic morphine treatment in r... *J. Pharmacol. Exp. Ther.* **162**, 331–337.

Martin, W. R. (1963). Strong analgesics. In: *Physiological Pharmacology* (W. S. Root and F. G. Hofmann, eds.), Vol. 1, pp. 275–312. Academic Press, New York.

Vachon, M., and Marchand, C. (1970). The influence of morphine on magnesium metabolism in rats. *J. Pharmacol. Exp. Ther.* **172**, 122–127.

Wacker, W. E. C., and Parisi, A. C. (1968). Magnesium metabolism. *New Engl. J. Med.* **278**, 772–776.

Wals... M. (1967). Magnesium metabolism. In: *Reviews of Physiology, Biochemistry and Exp...aental Pharmacology* (R. Jung, K. Kramer, O. Krayer, E. Lehnartz, F. Lynen, A. V. Muralt, U. Trendelenburg, H. H. Weber, and O. Westphal, eds.), pp. 252–254. Springer, New York.

Walser, M., and Browder, A. A. (1959). Ion association. III. The effect of sulfate infusion on calcium excretion. *J. Clin. Invest.* **38**, 1404–1411.

PLAINTIFF'S EXHIBIT 1316

STLCOPCB4031810

Dermal Toxicity Studies of Technical Polychlorinated Biphenyls and Fractions Thereof in Rabbits

J. G. Vos and R. B. Beems

Institute of Veterinary Pathology and Institute of Veterinary Pharmacology and Toxicology, University of Utrecht, Biltstraat 172, Utrecht, The Netherlands

Received October 5, 1970

Dermal Toxicity Studies of Technical Polychlorinated Biphenyls and Fractions Thereof in Rabbits. Vos, J. G., and Beems, R. B. (1971). *Toxicol. Appl. Pharmacol.* **19**, 617–633. A significant difference in toxicity between 3 polychlorinated biphenyl (PCB) preparations was found in a prior study: Clophen A 60 and Phenoclor DP6 showing the highest, Aroclor 1260 the lowest, toxicity (Vos and Koeman, 1970). A subsequent study revealed the presence of tetra- and pentachlorodibenzofuran in Phenoclor and Clophen (Vos *et al.*, 1970). In the present study, application of 118 mg of the 3 PCB's (5 times per wk, for 38 days) on the back skin of rabbits also resulted in differences in toxicity.

PCB-induced skin lesions were hyperplasia and hyperkeratosis of the epidermal and follicular epithelium. Histopathology of the liver included centrolobular degeneration, centrolobular liver cell atrophy, focal necrosis, and cytoplasmic hyalin degeneration. Definite hyperplasia and hyperkeratosis of the follicular epithelium of the ear skin were seen after the topical application of fractions of Phenoclor and Clophen eluted from chromatographic columns with 25% diethylether in hexane. The fraction from Aroclor caused a minimal hyperplasia and hyperkeratosis of the follicular epithelium. PCB-induced kidney lesions were hydropic degeneration of the convoluted tubules and tubular dilatation with the presence of casts. This dilatation was demonstrated also by a significantly increased relative percentage of the diameter which corresponds to the space of Bowman. Moreover, thymus atrophy and lymphopenia were found. Fecal coproporphyrin and protoporphyrin excretion was increased.

Polychlorinated biphenyls (PCB) have been identified in tissues of fish and wildlife in many countries (Jensen, 1966; Holmes *et al.*, 1967; Holden and Marsden, 1967; Koeman *et al.*, 1967; Risebrough *et al.*, 1968; Koeman *et al.*, 1969; Jensen *et al.*, 1969; Duke *et al.*, 1970; Prestt *et al.*, 1970).

PCB preparations are extremely stable, oily fluids with very low aqueous solubility. They are used as lubricants, as heat transfer media, in protective coatings for wood, metal, and concrete, and for many other applications. Which of these applications has contributed to the present environmental contamination has not yet been established.

Inhalation and feeding experiments in rats with 65% chlorinated PCB resulted in liver injury (Drinker *et al.*, 1937; Bennett *et al.*, 1938). Liver damage and skin lesions have been described after inhalation, ingestion, and application to the skin using rabbits, guinea pigs, and mice (von Wedel *et al.*, 1943). Hydropericardium occasionally accompanied by abdominal edema was found in chicks fed PCB (McCune *et al.*, 1962; Flick

Vos and Koeman, 1970). Epithelial and follicular hyperplasia and hyperre found after application of PCB on the skin of rabbits (Adams *et al.*, taneous injection of 42% chlorinated PCB in rats, guinea pigs, and rabbits iver injury and skin lesions, which were essentially those of chlor ne l). Follicular hyperkeratosis is an important feature of the occupat l n as chloracne, which is characterized by the appearance of papules, come- ysts. It may develop after exposure to some highly chlorinated aromatic Examples are chlorinated naphthalenes (Greenburg *et al.*, 1939; Hambrick, y and Kligman, 1957) and chlorinated phenols (Hofmann, 1957; Bauer *et* iberg *et al.*, 1964). The active compounds in chlorinated phenols have been chlorinated dibenzodioxins (chlorinated diphenylene dioxides) which as contaminants in the synthesis of chlorophenols (Bauer *et al.*, 1961). (acute yellow atrophy), whether accompanied by chloracne lesions or not, bed in people engaged in the manufacture of the chlorinated hydrocarbons l4; Braun, 1955; Behrbohm, 1959). Also for the PCB's there are early re- upatio chloracne (Jones and Alden, 1936; Schwartz, 1936). The present- PCB does not seem to have led to this kind of difficulty.

int difference in toxicity between 3 samples of commercial PCB preparations a previous study (Vos and Koeman, 1970), despite the marked resemblance romatograms and the mass spectra (Koeman *et al.*, 1969). One hundred per ty, centrolobular liver necrosis, and sc and abdominal edema were found s fed the samples of Clophen A60 and Phenoclor DP6. Hydropericardium d in nearly all chicks fed these PCB's, and was only occasionally seen in ith Aroclor 1260. Porphyria was found as a general PCB effect (Vos and 70).

thesis that in some technical PCB mixtures toxic factor(s) responsibl emalike lesions and the liver necrosis were present has been the subject of . By means of column fractionation, gas chromatography, and mass spec- hniques, tetra- and pentachlorodibenzofuran were identified as the toxic ie samples of Clophen A60 and Phenoclor DP6 (Vos *et al.*, 1970).

ults suggest that PCB's contaminated with polychlorodibenzofurans may chlo e and associated lesions when applied to the skin of experimental test t... possibility the present study was undertaken.

METHODS

samples, which contain an average of 60% chlorine, were obtained m France (Phenoclor DP6), Bayer in Germany (Clophen A60 Lot No. 912434) nto in the United States (Aroclor 1260 Lot No. AK-3).

ale New Zealand rabbits, 5 mo old and weighing 2500–3050 g, were used in They received pelleted food (Cunicon I, Trouw and Co., Amsterdam) and itum. The animals were distributed at random into 4 groups of 4 animals, eighed weekly.

of approximately 10 × 15 cm on the backs was clipped, the remaining hair with a shaving powder (90 g barium sulfide, 105 g zinc oxide, and 180 g l the resulting small skin abrasions were allowed to heal for 3 days.

The 3 PCB's were dissolved in isopropanol (118 mg PCB/ml). One ml of PCB solution or of isopropanol as a control was dropped daily, 5 times a wk, on an area of 5 × 10 cm by means of a calibrated syringe. In order to minimize eventual ingestion of the PCB, the animals were held for 7 hr in restraining boxes, after which time they were returned to their wire cages (2 animals per cage).

In order to study the porphyrogenic action of the PCB preparations in the same rabbits, pooled samples of the feces of the 4 groups were analyzed weekly for coproporphyrin and protoporphyrin contents (Rimington, 1961), using a Beckman spectrophotometer.

The animals which survived the 38-day test period (27 applications of 118 mg PCB) were killed. At necropsy, performed on all animals that died or were killed, a gross pathologic examination was carried out, including macroscopic examination in ultraviolet light using red fluorescence as an indication of porphyria. In order to get information on the fecal excretion of coproporphyrin and protoporphyrin of the individual animal, feces collected from the cecum were analyzed.

Hematologic examination included hemoglobin and hematocrit determinations, leukocyte and differential leukocyte counts. Clinical chemical determinations were made of serum glutamic–oxaloacetic transaminase and glutamic–pyruvic transaminase (Reitman and Frankel, 1957) using a Beckman/Spinco 151 spectrocolorimeter.

The weights of body, liver, kidneys, spleen, heart, and adrenals were recorded. The skin, liver, spleen, kidney, pancreas, ovary, heart, lung, thymus, mesenteric lymph node, stomach, small intestine, cecum, large intestine, and skeletal muscle were fixed in 10% buffered formalin and embedded in Paraplast. Sections (7 μ and 2 μ) were stained with hematoxylin-eosin. For detailed histology, selected sections were stained with Perls, Azan, PAS, Ziehl-Neelsen, Congo red, and thioflavine. Moreover, cryostat sections of formalin-fixed livers and kidneys were stained with Sudan black. Thioflavine-stained sections, unstained Paraplast-embedded sections, and unmounted cryostat sections of liver, kidney and small intestine were examined in a fluorescence microscope.

Prompted by the observation of tubular dilatation in the kidneys in previous studies after PCB ingestion (McCune *et al.*, 1962; Vos and Koeman, 1970), measurements were made on random samples of capsules of Bowman and glomeruli in 2-μ kidney sections. Measurements of one axis of the greatest diameter of both capsule and glomerulus were made of 25 renal corpuscles in a straight traverse across the cortex of each kidney. The relative percentage of the diameter which corresponds to the space of Bowman, as an index of dilatation of the nephron, was calculated from the measurements of each renal corpuscle.

An additional experiment was made with the chromatographic fraction (column eluted with 25% diethylether in hexane) of the 3 PCB's, containing tetra- and pentachlorodibenzofuran in the case of Phenoclor DP6 and Clophen A60 (Vos *et al.*, 1970), to determine the dermal toxicity of this fraction. Aliquots of 600 mg of the 3 PCB mixtures were fractionated (Vos *et al.*, 1970). The 25% diethylether-hexane fractions were evaporated and dissolved in 0.6 ml of ethanol. Four female albino rabbits (3 test animals and 1 control), 2 mo of age and weighing 1550–1750 g, were used as the experimental animals. A 0.2-ml portion of the ethanol solution was applied weekly, for 3 wk, to an area of 4 cm^2 on the inside of the rabbit ear. The opposite ear served as a control. The

STLCOPCB4031811

STLCOPCB403181 2

TABLE 5

PATHOLOGIC FINDINGS IN LIVERS OF RABBITS TREATED WITH PCB FOR 38 DAYS, AND OF CONTROL ANIMALS[a]

	Phenoclor				Clophen				Aroclor				Control			
			b		*b*		*b*	*b*								
Fatty degeneration	2	2	1	1	1	1	1	—	—	—	1	2	—	—	—	—
Centrolobular loss of glycogen	—	1	2	1	2	1	1	2	—	—	1	—	—	—	—	—
Centrolobular degeneration	1	2	—	1	1	2	1	2	—	1	1	1	—	—	—	—
Focal hydropic degeneration	—	1	—	—	—	2	2	—	—	1	—	2	—	—	—	—
Focal necrosis	—	1	—	—	2	2	2	2	—	—	1	2	—	—	—	—
Centrolobular liver cell atrophy	2	1	1	2	2	1	2	1	—	—	—	1	—	—	—	—
Enlargement of nuclei	2	1	—	1	2	2	2	2	1	—	1	2	—	—	—	1
Cytoplasmic hyalin degeneration	1	—	1	2	2	1	2	2	—	—	—	1	—	—	—	—
Ceroid pigment in Kupffer cells	—	1	—	2	1	1	1	1	—	2	1	2	—	—	—	—
Periportal fibrosis	2	—	2	1	1	1	2	2	1	—	1	1	—	—	—	—

[a] Severity of lesion: 1 = slight, 2 = marked.
[b] Animals that died during the experiment.



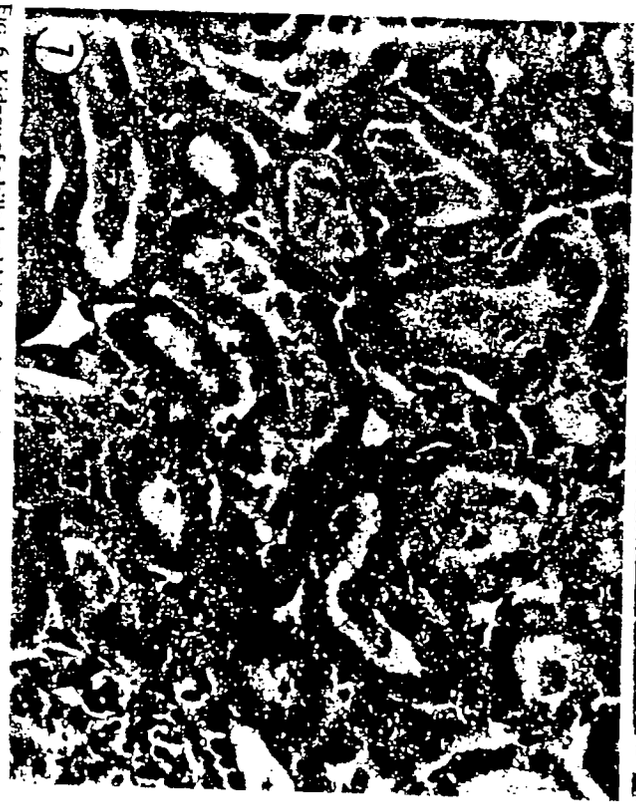

FIG. 6. Kidney of a killed rabbit from the Aroclor-treated group showing hydropic de
nuclear pycnosis of the convoluted tubules (1). A slightly distended space of Bowman
(2). Hematoxylin and eosin, ×375.



FIG. 7. Kidney section of the same animal as shown in Fig. 6, showing

tubules (Fig. 6) was found in half of the animals. Nuclear pycnosis, rhexis
the tubular epithelial cells were seen in all animals. Tubular dilatation, acc
the presence of casts of necrotic epithelial cells (Fig. 7), was found in half o

TABLE 6

DIAMETER MEASUREMENTS (μ) OF RENAL CORPUSCLES OF KILLED RABBITS TREATED WITH PCB FOR 38 DAYS, AND OF CONTROL ANIMALS[a]

	N	Capsule of Bowman	Glomerulus	Relative % of the diameter corresponding to the space of Bowman
Treated animals	8	94.5 (76.4–105.8)	82.2 (69.4–96.2)	12.5 (8.1–22.1)[b]
Controls	4	91.5 (86.0– 96.5)	85.2 (79.4–90.4)	6.5 (5.0– 7.9)

[a] Mean values; the range is shown in parentheses.
[b] Significantly different from controls, $P < 0.005$.

The tubular lesions explain the results of the diameter measurements of the renal corpuscles (Table 6).

Hemosiderin was found in the splenic macrophages of the test animals in greater quantities than in the controls. Moreover, a reduction in the number of germinal centers in the spleens as well as in the lymph nodes was found in the PCB groups. Atrophy of the cortex of the thymus was a common finding in the PCB-treated animals. No evidence of PCB-induced damage was found in the sections of the other organs.

Experiment with the Diethylether-Hexane Fractions on the Ear Skin of Rabbits

The four animals did not differ in weight gain during the test period. After two weeks of topical applications of the fraction from the 3 PCB samples, follicular keratosis was seen in both rabbits treated with the fraction of Phenoclor and Clophen. After 3 weeks when the animals were killed, the changes were more apparent (Fig. 8). The polar fraction of Aroclor did not give rise to gross changes.



FIG. 8. Chloracne-like lesions on the inside of a rabbit's ear skin treated weekly, for 3 weeks, with the 25% diethylether in hexane fraction from Clophen. Note the follicular keratosis in the treated ear (1) as compared with the control (2).

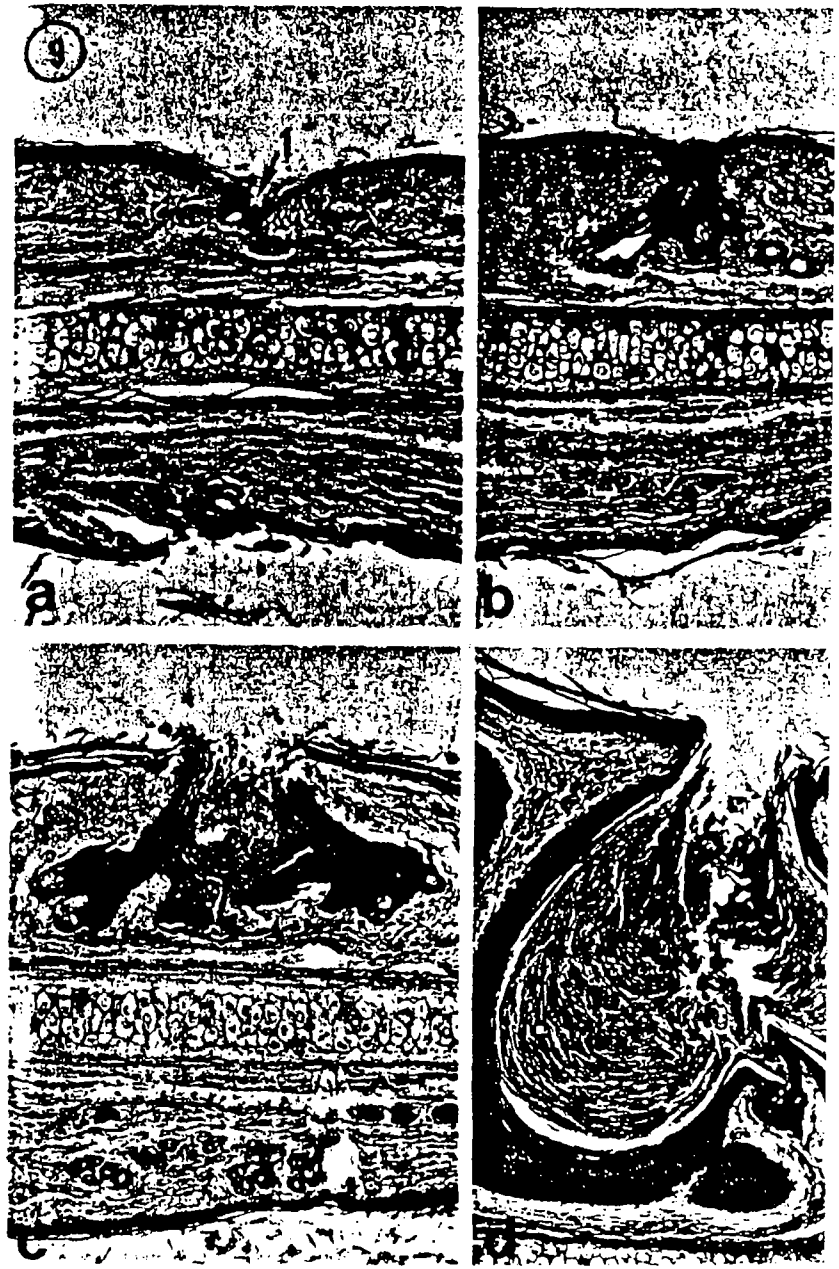

FIG. 9. Response of the inside of the rabbit's ear after topical application of the 25% c hexane fractions from technical polychlorinated biphenyls as seen in hematoxylin and eo ×60.

(a) Skin of control animal treated with ethanol. Note the hair follicle at 1, sebaceous glan and cartilage at 3. (b) Ear skin of the animal treated with the fraction from Aroclor. Some and hyperkeratosis of the follicular epithelium can be seen. (c) Ear skin of the rabbit trea fraction from Clophen. Considerable hyperplasia and hyperkeratosis of the follicular (d) Ear skin of the rabbit treated with the fraction from Phenoclor. Part of a section that sh severe lesion. The gravity of the response was in general the same as seen in Fig. 9c. Note t hair follicle with prominent hyperplasia and hyperkeratosis of the

STLCOPCB4031813

Histologically, hyperplasia and hyperkeratosis of the follicular epithelium with the presence of many keratohyalin granules (Fig. 10) were evident in the ear skin of the animal treated with the Phenoclor and Clophen fractions (Fig. 9c and d). This comedone formation was topically most pronounced in the rabbit treated with the Phenoclor fraction (Fig. 9d). Sebaceous gland tissue was decreased by treatment with both fractions (Fig. 10). Only mild hyperplasia and hyperkeratosis of the follicular epithelium was noted in the animal treated with the fraction of Aroclor (Fig. 9b). Hyperplasia and hyperkeratosis of the epidermal epithelium were also seen in the rabbits treated with the Phenoclor (Fig. 9d) and Clophen fractions but not in the animal treated with the Aroclor fraction.



FIG. 10. Higher magnification of the ear skin shown in Fig. 9d. Hyperplasia and hyperkeratosis of the follicular epithelium with the presence of many keratohyalin granules (*1*). Note also a diminution (differentiation) of the sebaceous gland tissue (*2*). Hematoxylin and eosin. ×375.

No red fluorescence was recorded at examination of the total body and of liver sections in ultraviolet light. Liver sections of the test animals showed centrolobular vacuolisation, which stained positive with Sudan black.

DISCUSSION

An increase in fecal excretion of coproporphyrin and protoporphyrin induced by PCB is as readily established in the rabbit (Table 1) as in the chicken (Vos and Koeman, 1970). Absence of porphyria in animals treated with the toxic fractions indicates that PCB itself is porphyrogenic.

Liver and kidney lesions, except the loss of glycogen, the enlargement of nuclei, [illegible]

confirm the observations of Miller (1944). The lymphopenia (Table 3), the r number of germinal centers in the spleens and lymph nodes, the atrophy of the of the thymus, and the atrophy of the white pulp and lymphoid foci found in the of chicks fed PCB (Vos and Koeman, 1970) are strong indications for an immu pressive effect. This may need further study, particularly with regard to the ex which these observations are due to stress (release of glucocorticoids).

It can be concluded that dermal application of PCB mixtures causes, besides th on the skin, systemic lesions of liver, kidneys, and lymphoid tissue.

From the response of the back skin and the liver of the rabbit to the 3 PCB m and from the response of the ear to the 25% diethylether-hexane fractions, it concluded that there are definite quantitative differences in toxicity, at least betw samples that were used in the present and the prior studies. The extent to whic samples are representative of the normal commercial output has not been studi prior study (Vos *et al.*, 1970), it appeared that the fraction of Clophen A60 was sible for the toxicity of the PCB mixture, which also can be assumed to be tru case of our samples of Phenoclor and Aroclor. From the response of the ear ski fractions it can be concluded that the presence of tetra- and pentachlorodibenz in Clophen A60 and Phenoclor DP6, found by mass spectrometry (Vos *et al.*, 1 definitely proved. The presence of a smaller quantity of toxic impurity in Aroclo compared with the Clophen and Phenoclor samples, is likely, considering the pericardium found in chicks fed with Aroclor (Flick *et al.*, 1965) and also cons the present results. Preparation of pure PCB is therefore necessary for a comp study. Uncontaminated PCB should be available.

These findings suggest that chloracne lesions induced by chlorinated napht and chick-edema-like lesions in chickens (Pudelkiewicz *et al.*, 1959) may also b toxic impurities, as in the case of PCB's and chlorinated phenols (Bauer *et al.* Coal tar, which is an important source for naphthalene, may contain traces of d furan (Fieser and Fieser, 1956). Chlorination of technical naphthalene could t produce chlorinated dibenzofuran.

Since PCB is a porphyrogenic chemical, it is possible that the skin lesions in r to PCB are a combination of chloracne and acquired porphyria cutanea tarda. *et al.* (1964) found an etiologic relationship between the chloracne in workers in the manufacture of dichlorophenol and trichlorophenol and acquired p cutanea tarda.

From the present and prior studies (Vos and Koeman, 1970; Vos *et al.*, 19 concluded that it is important to take into account, in the evaluation of toxic of PCB, the possibility that PCB samples may differ in an important respect: sence of toxic impurities. The interpretation of residue data in wildlife is very cated for this reason.

ACKNOWLEDGMENTS

The authors are grateful to Mr. H. Baart de la Faille, dermatologist (Depar Dermatology, Hospital of the State University, Utrecht) and Dr. P. Kanaar, derm (Department of Dermatology, Hospital of the State University, Leiden)

STLCOPCB4031814

REFERENCES

ADAMS, E. M., IRISH, D. D., SPENCER, H. C., and ROWE, V. K. (1941). The response of rabbit skin to compounds reported to have caused acneform dermatitis. *Ind. Med., Ind. Hyg. Surg.* **2**, 1–4.

BAUER, H., SCHULZ, K. H., and SPIEGELBERG, U. (1961). Berufliche Vergiftungen bei der Herstellung von Chlorphenol-Verbindungen. *Arch. Gewerbepathol. Gewerbehyg.* **18**, 535–555.

BEHRBOHM, P. (1959). Über Gefahren beim Umgang mit chlorierten Phenolen. *Deut. Gesundheitsw.* **14**, 614–619.

BENNETT, G. A., DRINKER, C. K., and WARREN, M. F. (1938). Morphologic changes in the livers of rats resulting from exposure to certain chlorinated hydrocarbons. *J. Ind. Hyg. Toxicol.* **20**, 97–123.

BLEIBERG, J., WALLEN, M., BRODKIN, R., and APPLEBAUM, I. L. (1964). Industrially acquired porphyria. *Arch. Dermatol.* **89**, 793–797.

BRAUN, W. (1955). *Chlorakne, Monographien zur Zeitschrift "Berufsdermatosen."* Band 3. Editio Canter, Aulendorff, Würtemberg, Germany.

DRINKER, C. K., WARREN, M. F., and BENNETT, G. A. (1937). The problem of possible systemic effects from certain chlorinated hydrocarbons. *J. Ind. Hyg. Toxicol.* **19**, 283–311.

DUKE, T. W., LOWE, J. I., and WILSON, A. J. (1970). A polychlorinated biphenyl (Aroclor 1254) in the water, sediment, and biota of Escambia Bay, Florida. *Bull. Environ. Contamin. Toxicol.* **5**, 171–180.

FIESER, L. F., and FIESER, M. (1956). *Organic Chemistry*, 3rd ed., pp. 527–531. Reinhold, New York.

FLICK, D. F., O'DELL, R. G., and CHILDS, V. A. (1965). Studies of the chick edema disease. Similarity of symptoms produced by chlorinated biphenyl. *Poultry Sci.* **44**, 1460–1465.

GREENBURG, L., MAYERS, M. R., and SMITH, A. R. (1939). The systemic effects resulting from exposure to certain chlorinated hydrocarbons. *J. Ind. Hyg. Toxicol.* **21**, 29–38.

HAMBRICK, G. W. (1957). The effect of substituted naphthalenes on the pilosebaceous apparatus of rabbit and man. *J. Invest. Dermatol.* **28**, 89–103.

HOFMANN, H. T. (1957). Neuere Erfahrungen mit hochtoxischen Chlorkohlenwasserstoffen. *Naunyn-Schmiedebergs Arch. Exp. Pathol. Pharmakol.* **232**, 228–230.

HOLDEN, A. V., and MARSDEN, K. (1967). Organochlorine pesticides in seals and porpoises. *Nature (London)* **216**, 1274–1276.

HOLMES, D. C., SIMMONS, J. H., and TATTON, J. O'G. (1967). Chlorinated hydrocarbons in British wildlife. *Nature (London)* **216**, 227–229.

JENSEN, S. (1966). Report of a new chemical hazard. *New Sci.* **32**, 612.

JENSEN, S., JOHNELS, A. G., OLSSON, M., and OTTERLIND, G. (1969). DDT and PCB in marine animals from Swedish waters. *Nature (London)* **224**, 247–250.

JONES, J. W., and ALDEN, H. S. (1936). An acneform dermatergosis. *Arch. Dermatol. Syph.* **33**, 1022–1034.

KOEMAN, J.H., OSKAMP, A. A. G., VEEN, J., BROUWER, E., ROOTH, J., ZWART, P., v. d. BRO[illegible] E., and VAN GENDEREN, H. (1967). Insecticides as a factor in the mortality of the sandwich tern (*Sterna sandvicensis*). *Meded. Rijksfac. Landbouwwetensch. Gent* **32**, 841–854.

KOEMAN, J. H., TERNOEVER DE BRAUW, M. C., and DE VOS, R. H. (1969). Chlorinated biphenyls in fish, mussels and birds from the river Rhine and the Netherlands coastal area. *Nature (London)* **221**, 1126–1128.

MCCUNE, E. L., SAVAGE, J. E., and O'DELL, B. L. (1962). Hydropericardium and ascites in chicks fed a chlorinated hydrocarbon. *Poultry Sci.* **41**, 295–299.

MILLER, J. W. (1944). Pathologic changes in animals exposed to a commercial chlorinated diphenyl. *Publ. Health Rep.* **59**, 1085–1093.

PORTA, E. A., and HARTROFT, W. S. (1969). *Pigments in Pathology* (M. Wolman, ed.), p. 2[illegible] Academic Press, New York.

PRESTT, I., JEFFERIES, D. J., and MOORE, N. W. (1970). Polychlorinated biphenyls in wild birds in Britain and their avian toxicity. *Environ. Pollution* **1**, 1–26.

PUDELKIEWICZ, W. J., BOUCHER, R. V., CALLENBACH, E. W., and MILLER, R. C. (1959). Some physiological responses of New Hampshire chickens to a mixture of penta- and hexachloronaphthalenes. *Poultry Sci.* **38**, 424–430.

REITMAN, S., and FRANKEL, S. (1957). A colorimetric method for the determination of serum glutamic oxaloacetic and glutamic pyruvic transaminase. *Amer. J. Clin. Pathol.* **28**, 56–63.

RIMINGTON, C. (1961). Quantitative determination of porphobilinogen and porphyrins in urine and faeces. Broadsheet No. 36 of the Association of Clinical Pathologists. Copies may be obtained from Dr. R. B. H. Tierney, Pathology Laboratory, 75, Boutport Street, Barnstaple, Devon.

RISEBROUGH, R. W., RIECHE, P., PEAKALL, D. B., HERMAN, S. G., and KIRVEN, M. N. (1968). Polychlorinated biphenyls in the global ecosystem. *Nature (London)* **220**, 1098–1102.

SCHWARTZ, L. (1936). Dermatitis from synthetic resins and waxes. *Amer. J. Publ. Health* **26**, 586–592.

SHELLEY, W. B., and KLIGMAN, A. M. (1957). The experimental production of acne by chlorinated and hexachloronaphthalenes. *A.M.A. Arch. Dermatol.* **75**, 689–695.

STRAUSS, N. (1944). Hepatotoxic effects following occupational exposure to Halowax (chlorinated hydrocarbons). *Rev. Gastroenterol.* **11**, 381–396.

VAN DER WAERDEN, B. L. (1957). *Mathematische Statistik*, pp. 269–284. Springer, Berlin.

VON WEDEL, H., HOLLA, W. A., and DENTON, J. (1943). Observations on the toxic effects following from exposure to chlorinated naphthalene and chlorinated phenyls with suggestions for prevention. *Rubber Age (New York)* **53**, 419–426.

VOS, J. G., and KOEMAN, J. H. (1970). Comparative toxicologic study with polychlorinated biphenyls in chickens with special reference to porphyria, edema formation, liver necrosis and tissue residues. *Toxicol. Appl. Pharmacol.*, **17**, 656–668.

VOS, J. G., KOEMAN, J. H., VAN DER MAAS, H. L., TEN NOEVER DE BRAUW, M. C., and DE VOS, R. H. (1970). Identification and toxicological evaluation of chlorinated dibenzofurans and chlorinated naphthalene in two commercial polychlorinated biphenyls. *Food Cosmet. Toxicol.* **8**, 625–633.

STLCOPCB4031815