PLAINTIFF'S EXHIBIT

ASA-680

ACTA PATHOLOGICA ET MICROBIOLOGICA SCANDINAVICA
SUPPLEMENTUM 181, 1966

ASBESTOS BODIES AND PLEURAL PLAQUES IN A FINNISH SERIES OF AUTOPSY CASES

BY
LAURI MEURMAN

MUNKSGAARD
KOPENHAGEN 1966

ASARCO ELP 0002997

ASBESTOS BODIES AND PLEURAL PLAQUES IN A FINNISH SERIES OF AUTOPSY CASES

ASARCO ELP 0002998

ACTA PATHOLOGICA ET MICROBIOLOGICA SCANDINAVICA
SUPPLEMENTUM 181, 1966

FROM THE CENTRAL HOSPITAL OF KUOPIO AND THE DEPARTMENT OF PATHOLOGICAL ANATOMY, UNIVERSITY OF TURKU, FINLAND.

ASBESTOS BODIES AND PLEURAL PLAQUES IN A FINNISH SERIES OF AUTOPSY CASES

BY
LAURI MEURMAN

MUNKSGAARD
KOPENHAGEN 1966

ASARCO ELP 0002999

Translated by
Eva Palmgren

Revised by
Jean Margaret Perttunen

PRINTED IN FINLAND
BY SAVON SANOMAIN KIRJAPAINO OY
KUOPIO 1966

ASARCO ELP 0003000

CONTENTS

INTRODUCTION 7

SURVEY OF THE LITERATURE 8

The asbestos minerals 8

Asbestosis 9

Asbestos bodies 11

The specificity of asbestos bodies 13

The occurrence of asbestos bodies in the lungs without occupational exposure to asbestos dust 15

Patho-anatomical changes of the pleura in asbestosis 16

Roentgenological observations on pleural plaques in asbestosis 18

Pleural plaques in so-called non-occupational asbestosis 20

Pleural plaques in other pneumoconioses 22

Pleural plaques and exposure to mixed dusts 24

Bilateral plaque-like pleural changes in cases without any history of exposure to dust 24

The pleural plaques as compared with similar changes in other serous membranes 26

Asbestos and malignancy 27

The occurrence of asbestos bodies in the parietal and visceral pleura 29

PROBLEMS 31

MATERIAL 33

PART I 36

OCCURRENCE OF ASBESTOS BODIES IN ROUTINE AUTOPSY CASES 36

Methods 36

Results 37

A. General frequency of asbestos bodies in autopsy subjects aged 15 years and older 37

B. Influence of domicile on the occurrence of asbestos bodies in the lungs 38

C. Density of asbestos bodies in histological lung sections 43

D. Morphology and location of the asbestos bodies found in subjects not employed in asbestos industries 45

E. Influence of occupation on the frequency of asbestos bodies in the lungs 50

Summary of the results 51

ASARCO ELP 0003001

PART II 53

FIBROTIC THICKENING OF THE PARIETAL PLEURA (PLEURAL PLAQUES) 53

Methods 53

Results 54

A. Frequency of pleural plaques in autopsy subjects aged 15 years and older 54
B. Pathological anatomy of the plaques 57
C. Histology of the plaques 62
D. Calcium content of the plaques 66
E. The roentgenographic calcification of the pleural plaques as compared with the histological findings 69
F. Occurrence of lipids in the plaques 72
G. Asbestos bodies in the parietal pleura 72
H. Relationship between pleural plaques and asbestos bodies in the lungs 73
I. Thickness of the pleural plaques 75
J. Changes in the visceral pleura and their relationship to the occurrence of asbestos bodies in the lungs 75
K. Relationship between plaques in the parietal pleura and chronic dieseases of the lungs or the cardiovascular system 79
L. Comparison of plaque formation in the pleura and in the peritoneum and pericardium 82
M. Pleural plaques in domestic animals 83

Summary of the results 83

DISCUSSION 87

GENERAL SUMMARY 97

ACKNOWLEDGEMENTS 99

REFERENCES 101

ASARCO ELP 0003002

INTRODUCTION

This study deals in particular with the fibrotic, usually calcified plaques, resembling sugar icing, which may be encountered on the inner surface of the chest.

Notwithstanding their frequency, established in pilot studies perfomed at the Central Hospital of Kuopio and also in other parts of Finland, these lesions have seldom been mentioned in the literature. No major significance has been accorded to them as signs of disease.

In an extensive roentgenological investigation, *Kiviluoto* (1960) showed that those subjects in his series who exhibited calcified plaques on the inner surface of the thorax had mostly lived in the vicinity of one or other of the two open-cut asbestos mines in eastern Finland. He held that bilateral calcified thickening of the parietal pleura is due to inhalation of asbestos dust, and he called this condition non-occupational endemic asbestosis.

Since one of the above-mentioned asbestos mines is situated in the region of the Central Hospital of Kuopio, the autopsy material available at this hospital seemed to constitute a good basis for an attempt to throw further light on the question of whether the occurrence of fibrotic plaques is associated in some way or other with exposure to asbestos dust.

When acting over a long period of time, asbestos dust is known to cause pneumoconiosis of a type called asbestosis. Furthermore, convincing statistical evidence has been produced to the effect that the risk of lung cancer is more than ten times greater in asbestos workers than in other, unselected populations.

During the last few years several reports have been published, moreover, which indicate that the frequency of diffuse mesothelioma, a malignant pleural or peritoneal tumour previously considered to be very rare, has increased very significantly among those groups of the population that are subject to occupational or environmental exposure to asbestos dust. Although this tumour is obviously very infrequent in Finland, lung cancer is relatively common.

The facts enumerated above constitute the background of the present investigation, the purpose of which was to elucidate the frequency and mode of occurrence in Finland of both asbestos dust and the above-mentioned pleural lesions.

ASARCO ELP 0003003

SURVEY OF THE LITERATURE

The asbestos minerals

Asbestos is the name of a group of minerals having in common the feature that they readily split lengthwise into fibres down to molecular dimensions (*Vorwald et al.* 1951). Chemically, the various kinds of asbestos consist of hydrous magnesium silicate, with the addition of varying amounts of iron, calcium, magnesium, sodium, potassium or aluminium. On the basis of differences in chemical and atomic structure, two subgroups are distinguished, i.e. serpentine and amphibole asbestos. Serpentine asbestos has a greater flexibility than amphibole asbestos and is more readily soluble (*Sundius et al.* 1938, *Kouvo* 1960).

Typical features of all asbestos minerals are their incombustibility, their high chemical resistance to both acids and bases, their low thermal and electrical conductivity and the flexibility of their fibres, which enables them to be spun (*Behrens* 1956).

These properties in asbestos were utilized even in ancient times. According to Herodotos, in 450 B.C. asbestos was used among the Greeks as cremation cloth (*Gloyne* 1938). In the Middle Ages, Charlemagne is known to have had a table cloth woven of asbestos, which was cleaned by passing through fire (*Stewart et al.* 1931).

In Finland, asbestos was used some 4500 years ago, during the Stone Age, to increase the incombustibility and tenacity of ceramic pottery. As far as can be judged from archaeological findings, asbestos ceramics were a Finnish invention. This kind of pottery was made for some 3000 years, or until about 500 A.C. After this time, the practice of mixing the clay with asbestos seems to have fallen into oblivion (*Meinander* 1954).

Owing to its special physical and chemical properties, asbestos has become an indispensable raw material of modern industry. Its wide and varied applications are illustrated by the fact that asbestos is reckoned to be an integral part of at least 300 industrial products. Among the most important are various insulating materials for

ASARCO ELP 0003004

pipes, boilers, locomotives, ship-building, flooring, roofing, walls, electrical equipment, etc. Asbestos is an ingredient in fire-proof cement and bricks. The automobile industry uses asbestos in brake linings, clutch plates and rust-preventing materials. In various textiles in which incombustibility is demanded, asbestos has been used traditionally, and it is also used in textiles which have to withstand acids, in laboratory filters and other laboratory utensils. Furthermore, the plastic industry uses asbestos as an ingredient *(Aurola et al.* 1954, *Behrens* 1956, *Thomson et al.* 1963).

The richest asbestos deposits are situated in Canada (Thetford, three-quarters of the world production), South Africa, USA (Arizona) and the Soviet Union (Ural). In Europe, there are minor asbestos deposits in Italy and Finland *(Behrens* 1956, *Bohlig et al.* 1960).

In Finland, anthophyllite asbestos is a fairly common mineral, but only one asbestos mine is worked today, e.g. the Paakkila mine in east Finland, on the border of Northern Savo and Northern Karelia, in a region known since the Stone Age for its asbestos deposits. The mine produces anthophyllite asbestos, which belongs to the amphibole group. The annual output has been about 10,000 metric tons. In the same region another asbestos mine has been run, the Maljasalmi mine in the commune of Kuusjärvi, in which mining began in 1944 and was given up in 1952. The Paakkila mine has been worked since 1919 (*Aurola et al.* 1954, *Kiviluoto* 1960).

Asbestosis

The first report on the injurious influence of asbestos was published by *Murray* in 1900. At the London Charing Cross Hospital he had treated a 33-year-old man who had been working in the charding room of an asbestos factory. The patient stated that he was the only survivor of ten men who started working in that room simultaneously. The others had died "presumably as the result of their occupation". This patient, too, succumbed and the autopsy finding was pulmonary fibrosis. On microscopic examination, "spicules of asbestos" were detected in his lungs (*Cooke* 1927).

Obviously *Murray*'s paper did not become generally known, since only a few reports on pulmonary diseases due to asbestos dust appeared during the following two decades *(Marchand* 1906, *Fahr et al.* 1914, *Cooke* 1924). In these, *Murray*'s article was not mentioned. Research concerning the pathogenicity of asbestos dust was not inten-

ASARCO ELP 0003005

sified until 1927. At the annual meeting of the British Medical Association in Edinburgh that year, *Cooke* and *Stuart McDonald* reported on an autopsy case in which histological studies of lung sections revealed fibres corresponding to the asbestos fibres encountered in nature. In addition, they described "curious bodies" which they had detected in the lung sections and assumed to be due in some way or other to asbestos dust.

After this, numerous investigations were published which established that the pulmonary fibrosis of asbestos workers was caused by inhalation of asbestos dust. The term asbestosis, introduced by *Fahr* in 1914, was adopted. Particularly during the nineteen-thirties, the symptoms, signs, pathological anatomy and prognosis of this condition were the subject of intense research. Whilst it may be stated that these aspects became thoroughly elucidated, the pathogenesis of asbestosis has remained obscure (*Gloyne* 1938, *Behrens* 1956, *Bohlig et al.* 1960).

A typical patho-anatomical feature of asbestosis is a diffuse fibrosis of the lung tissue, which contrasts sharply with the nodular fibrosis of silicosis. As a rule, it is most marked in the lower and middle portions of the lungs, whilst concomitant emphysema often occurs in the upper portions (*di Biasi* 1938). The lungs are firm and leathery, and the cut surface feels as if fine sand had been sprinkled over it. Histological examination reveals an increase in peribronchial interlobar and perivascular connective tissue, and thickening of the alveolar septa until some alveoli are obliterated, whereas others may show emphysema and cuboidal epithelial metaplasia in the terminal respiratory passages. The latter exhibit, in addition, an accumulation of histiocytes (dust cells) and foreign body giant cells. The increased connective tissue is composed of thin collagen and reticular fibres and is relatively poor in cells. Here and there it shows slight or moderate infiltration of lymphocytes and plasma cells and frequently also of erythrocytes (*Cooke* 1927, *McDonald* 1927, *Simson* 1928, *Stewart* 1928, *Gloyne* 1929, *Egbert* 1935, *di Biasi* 1938, *Noro* 1946).

The bronchi usually exhibit oedema and squamous metaplasia (*Lynch et al.* 1935), which is attributed to mechanical irritation caused by the asbestos fibres. A causal relationship has also been suggested between this metaplasia and the high rate of lung carcinoma among asbestos workers (*Nordmann* 1938).

Apart from the above-mentioned, more or less non-specific changes in the lungs, the presence of asbestos fibres and numerous asbestos bodies is conditional for a diagnosis of asbestosis. The dust

ASARCO ELP 0003006

fibres are scattered everywhere in the lung, both inside the alveoli and in the interstitium. Owing to their double refraction they can be detected in polarized light. They are even in thickness and vary in length from a few micra to over 300. They are often either entirely or partially phagocytized by histiocytes or foreign body giant cells (*Gloyne* 1938).

Asbestos bodies

The asbestos bodies consist of a central core of asbestos fibre and a coat made up of proteins and rich in iron compounds (*Gloyne* 1929). These peculiar bodies, for which various designations have been used, e.g. "curious bodies" (*Cooke* 1927, *McDonald* 1927), "asbestosis bodies" (*Stewart et al.* 1929) or "asbestos bodies" (*Gloyne* 1929) — German: Asbestosiskörperchen, French: corps d'amiante — are elongated structures varying in shape. They are always unbranched and as a rule straight, but sometimes curving and usually measure 20—50 μ in length and 3—7 μ in thickness (*Beger* 1933). Their shape has been described as dumb-bell, drumstick, necklace, sausage, etc.

In unstained histological sections the asbestos bodies are golden yellow or yellowish brown, and unlike the asbestos fibres they are not doubly refractive. Owing to their iron-containing protein encrustation the asbestos bodies give a strong iron reaction, as was shown by *Marchand* (1906) and *Fahr et al.* (1914).

In typical cases of asbestosis, asbestos bodies are found in large numbers. *Beger* (1933), who attempted to count them, arrived at 1.3 million per ccm of lung tissue. He estimated the number of asbestos bodies in ordinary histological sections at about 8000 per sq.cm. In medium magnification they are thus present in abundance in all fields, and can be distinguished without any difficulty.

Notwithstanding the large number of relevant investigations, the question of the developmental mechanism of the asbestos bodies has remained unsettled (*Bohlig et al.* 1960). Only some species of laboratory animals seem to react by formation of such bodies when kept in an artificially dusted atmosphere. The best results have been obtained with guinea-pigs, but experiments with mice, cats and monkeys have also fairly often been successful. By contrast, attempts to produce asbestos bodies in rabbits have usually failed, and in dogs and rats always, although in these species, too, the inhalation of asbestos dust results in pulmonary fibrosis (*Gardner et al.* 1931, *Gardner* 1938, *Vorwald et al.* 1951, *Wagner* 1963).

ASARCO ELP 0003007

It has been stated that the formation of asbestos bodies is dependent on the movement of the affected organs, since these bodies are found only in organs which are continuously in motion, such as the lungs and muscles, and never in relatively immobile tissues such as the skin (*Gardner* 1938).

It is striking that on mineralogical analysis of asbestos bodies recovered from the lungs of patients with asbestosis, only amphibole asbestos has been detected, although serpentine asbestos is much more widely used and asbestosis occurs among the workers in serpentine asbestos mines and mills, too (*Beger* 1933, *Sundius et al.* 1938, *Kühn* 1941, *Ruska* 1942). Serpentine asbestos is more flexible and therefore better suited for spinning, and for industrial purposes it is regarded as the most important type of asbestos. It is more readily dissolved than amphibole asbestos, and the hypothesis has been advanced that it becomes completely dissolved in the human lung (*Gloyne* 1951, *Knox et al.* 1954, *Holt et al.* 1964), as it does in the cat in a relatively short time (*Vorwald et al.* 1951). In laboratory animals, asbestos bodies have been produced with serpentine asbestos, too, although to a lesser extent than with amphibole asbestos (*Wagner* 1963).

Obviously, amphibole asbestos dissolves poorly, if at all, in the human lung. In any event this mineral has been found in the lungs decades after exposure to asbestos dust has ceased (*Lynch* 1937, *König* 1960).

In vitro, asbestos bodies have been produced in egg albumin (*Beger* 1933) and even in tap-water (*Wagner* 1958). It is generally believed that asbestos bodies have no pathologic significance (*Behrens* 1951). They are only the end results of a reaction between the asbestos fibre and the organism. Attempts to produce pulmonary fibrosis by injecting asbestos bodies into the lungs of laboratory animals have been unsuccessful (*Vorwald et al.* 1951). The fact that certain animal species develop pulmonary fibrosis as a result of exposure to asbestos dust, although they do not exhibit asbestos bodies, constitutes further evidence in favour of the view that these bodies lack pathogenic significance (*Vorwald et al.* 1951). On the other hand, it has recently been suggested that asbestos bodies nonetheless might play a part in the development of pulmonary fibrosis in such a way that in connection with their possible disintegration certain fibrogenic factors are released (*Holt et al.* 1964, *Knox* 1964).

In human lungs, asbestos bodies may be found in both the alveoli and the peribronchial and perivascular connective tissue. Some lie free while others have been phagocytized by histiocytes. In addition,

ASARCO ELP 0003008

they may be encountered in the pulmonary regional lymph nodes, although in small numbers.

Occasionally, asbestos bodies have also been found outside the thoracic cavity, e.g. in the spleen (*Stewart et al.* 1931, *Lynch* 1937, *Leicher* 1954, *König* 1960). Furthermore, such bodies have been detected in the maxillary and frontal sinuses and in the tonsils (*König* 1960). By roentgen spectrographic methods asbestos has been detected in a peritoneal mesothelioma *(Leicher* 1954).

Whilst in silicosis the greatest harm is caused by the finest dust, it appears that the longer asbestos fibres are more harmful than the shorter ones. According to *Gardner et al.* (1931), only asbestos fibres over 3 μ long, and according to *Vorwald et al.* (1951), fibres over 20 μ long, are capable of causing pulmonary fibrosis in laboratory animals. Lately, however, contrary views have also been expressed (*Holt et al.* 1964). According to these, either the shortest, perhaps invisible, asbestos particles or, by contrast, relatively long bodies exert the most injurious influence, the latter when they undergo dissolution.

Asbestos bodies have been found in the sputa of workers occupationally exposed to asbestos dust, but the reports of various authors differ in regard to frequency. *Simson et al.* (1931) reported positive findings in 48 out of 50 subjects working in an asbestos mine. *Bohlig et al.* (1960), on the other hand, observed asbestos bodies in the sputa of only 6.6 per cent of 716 patients with various grades of asbestosis. Without a record of exposure to asbestos dust and the presence of the clinical features typical of asbestosis (dyspnoea, impairment of pulmonary function) and roentgenologically detectable lung fibrosis, asbestos bodies in the sputum do not justify a diagnosis of asbestosis. They are only regarded as evidence that exposure has occurred to asbestos dust at some stage in life *(Lynch* 1937, *Gloyne* 1938, *Bohlig* 1960).

The specificity of asbestos bodies

Stewart's (1928) hypothesis that the presence of asbestos bodies is pathognomonic of asbestosis has not proved tenable. Apart from the fibrous minerals belonging to the asbestos group, particles of many other sparingly soluble dusts may, when present in the lungs, become incrusted with a protein-containing cover and thus show a striking, or even complete, morphological resemblance to asbestos bodies. The fibres forming the core of these so-called pseudo-asbestos

ASARCO ELP 0003009

bodies have been identified as follows by the authors mentioned below:

Cooke (1932, 1935): biotite-fusain.
Sundius et al. (1938): hornblende-rutil.
Luton et al. (1947): diatomaceous earth.
Gloyne et al. (1949): graphite.
Glauser et al. (1951): carborundum and graphite.
Langer (1952): diatomaceous earth.

In addition, numerous cases have been described in which asbestos bodies or pseudo-asbestos bodies were found although no history of occupational exposure to asbestos dust could be elicited:

Marchand (1906): In a worker in a dye factory; in a stove-builder's wife.

Tylecote et al. (1931): In a coal miner.

Stewart et al. (1932): In a man who had lived near an asbestos mill.

Williams (1934): In 8 coal miners out of 28, and in one control case out of 3.

Cooke (1935): In an unstated number of cases in different occupational states, including house-wives.

Lynch (1937): In a coal shute worker, a house-maid and a cotton press worker. Furthermore, in a considerable proportion of patients who had died of heart failure.

di Biasi (1938): In 3 cases of pneumoconiosis (not due to asbestos dust).

Löblich (1938): In 5 out of 7 patients with diatomaceous earth pneumoconiosis.

Gardner (1940): "In a dozen or more" patients without any history of exposure to dust.

Porro et al. (1942): In all subjects in a series of 5 talc workers.

Hunt (1956): In a talc worker.

Gough (1959): "In some cases" of byssinosis.

Wagler et al. (1962): In a person who had worked in the vicinity of an asbestos factory.

The formation of asbestos bodies does not seem to be dependent on the chemical composition of the mineral fibres. This view is supported, among other things, by certain results obtained by *Vorwald et al.* (1951) in animal experiments. These investigators were able to produce asbestos bodies with brucite ($Mg\ OH_2O$), which is fibrous like the minerals of the asbestos group, but differs chemically from these in that it contains no silicate. *Behrens* (1956) even suggested that the name asbestos body (Asbestosiskörperchen) should be aban-

ASARCO ELP 0003010

doned and regarded "curious body", the term originally used by *Cooke* (1927), as more adequate to denote these formations. *Gloyne* (1951), too, rejected the name asbestos body and suggested "pneumoconiosis body" as a substitute. Thus, the hypothesis put forward by *Cooke* in 1927, that "curious bodies" arise from a non-specific reaction to any sparingly soluble fibrous foreign body present in the lungs, has later been confirmed. Asbestosis is the only disease, however, in which asbestos bodies are an essential feature of the histological picture of the lungs (*Gloyne* 1951).

The occurrence of asbestos bodies in the lungs without exposure to asbestos dust

During the last few years, some authors have performed systematic studies on the occurrence of asbestos bodies in the lungs. In sputa remitted to the Kimberley Hospital for examination for tuberculosis, *Sleggs et al.* (1961) found asbestos bodies in 115 cases without any history of occupational exposure to asbestos dust. The total number of specimens examined was not mentioned.

The first extensive study on the frequency of asbestos bodies in an autopsy series was performed by *Thomson et al.* (1963) at a hospital in Cape Town. The series comprised 500 consecutive autopsy subjects aged 15 years and older. In 26.4 per cent asbestos bodies were detected in lung smears (i.e. by the method presented by *Stewart* in 1928). The frequency of asbestos bodies increased with age, roughly speaking, although a lower value was observed in the age group 45—54 years. The frequency was higher in males than in females, the respective figures being 30.4 and 20 per cent. Great differences were noted between the various races, the frequency of asbestos bodies being only 16 per cent in the Whites and 58 per cent in the Africans. Between these, the Coloureds showed a frequency of 23.7 per cent.

Using the same method, *Thomson et al.* (cited by *Cauna et al.* 1965) obtained almost the same result, i.e. a frequency of 27.2 per cent in Miami, USA.

Hourihane (1964), in London, examined histological lung sections for asbestos bodies in 50 consecutive autopsy cases. They were all negative, but in a series of 50 cases of lung cancer he found asbestos bodies in three cases.

Elmes et al. (1965), using the same method, studied a series of 200 male autopsy cases from Belfast, Northern Ireland, in the age range 50—69 years. Cases with lung cancer were excluded. Asbestos bodies were found in 14 per cent in the age group 50—59 years and in

ASARCO ELP 0003011

27 per cent in the group 60—69 years. Furthermore, in 100 cases of bronchial carcinoma these investigators found asbestos bodies in the lungs in 20 per cent. The difference between the cancer group and the non-malignant group is insignificant. By contrast, in cases of mesothelioma, asbestos bodies were found in the lungs in 88 per cent, which made a significant difference as compared with the control group.

Using *Thomson's* technique in a study on 100 autopsy cases from Pittsburgh, USA, and its surroundings, *Cauna et al.* (1965) found asbestos bodies in 41 per cent. The density in the individual cases was mostly low, only one to ten bodies per 400 low power fields being detected (16 mm objective). By contrast, when they investigated histological lung sections from the same cases, routinely stained by the haematoxylin and eosin method, they found asbestos bodies in only four cases. These authors, too, noted a somewhat higher frequency of asbestos bodies in men (47 per cent) than in women (34 per cent). The only case exhibiting asbestos bodies in somewhat greater density was a 63-year-old man who had been a sales engineer for a pump company.

In the investigations hitherto performed on autopsy cases, the frequency of asbestos bodies has been 0—41 per cent. The methods used have varied somewhat.

As a rule, the series investigated have consisted of urban populations. *Thomson et al.* (1963) expressed the opinion that in cities asbestos dust constitutes a modern hazard. These authors are concerned about the future, since they anticipate that lifelong inhalation of asbestos dust may eventually result in a limited basal asbestosis in almost the entire urban population. At the same time diffuse mesothelioma of the pleura and peritoneum will perhaps in future increase so much as even to exceed lung cancer in frequency. This apprehension is due to the suspicion that mesothelioma, as will be discussed later, perhaps develops as a complication of asbestosis, or even as a result of only slight inhalation of asbestos dust — a suspicion supported in particular by the frequency of mesothelioma in South Africa and the frequent occurrence of asbestos bodies in these cases.

Patho-anatomical changes of the pleura in asbestosis

Apart from pulmonary fibrosis, an increase in connective tissue is observable in asbestosis in the visceral pleura, particularly in the basal and medial surfaces ot the latter *(Cooke* 1927, *di Biasi* 1938,

ASARCO ELP 0003012

Gloyne 1933, 1938, *Lynch et al.* 1948, *Wagner* 1960). This change appears as patches with ill-defined borders or as a diffuse increase in collagenous connective tissue, resulting in a leathery feel of the lung surface. On the roentgenogram the lesion has a ground glass appearance *(Gloyne* 1933, 1938, *Behrens* 1956). The thickening of the visceral pleura is not related to the degree of roentgenographically discernible pulmonary fibrosis. The pleura may show considerable thickening even if the pulmonary fibrosis is only slight *(Fehre* 1956, *Bohlig et al.* 1960), and on the other hand, it may be quite normal, although the lungs exhibit marked fibrosis *(Lynch* 1955). In the less affected areas, as a rule in the upper lobes, the transparency of the pleura remains normal or even increases on account of pulmonary emphysema. As the disease progresses, the thickened portions of the visceral pleura may consist of stiff, yellowish "horn-like plaques", 2—3 inches in diameter *(Gloyne* 1933, 1938.) On histological examination, the pleura as a rule exhibits patches of fibrin and absence of epithelium over extensive areas. The submesothelial layer is thickened owing to an increase in connective tissue fibres and capillaries.

Tough, as a rule sessile, adhesions of old standing are frequent in asbestosis and often eventually obliterate the pleural cavity. In other cases the pleural cavity remains free, however, notwithstanding the thickening of the pleura. Mostly, only the basal portions of the lungs are fused *(Gloyne* 1933, *Bohlig et al.* 1960).

In experiments on guinea-pigs, *Gardner et al.* (1931) observed pleural changes which they regarded as "chronic fibrous pleurisy" in only a few individuals.

Although the literature on asbestosis is very extensive today, changes in the parietal pleura are mentioned in only a few papers, and in these only in general terms and incidentally. Often it is not even possible to decide whether changes in the parietal or the visceral pleura are meant. This may be due to the fact that in the presence of adhesions it is difficult to distinguish the pleurae, and consequently parietal lesions may in many cases have been taken for changes in the visceral pleura.

Gloyne (1938) stated that the lesions in the parietal pleura were of the same kind as those in the visceral pleura except that horn-like plaques were absent. Later, plaque formation has been observed in the parietal pleura with an open pleural cavity. *Fehre* (1956) cited a personal communication according to which bilateral thickening and calcification of the parietal pleura alone and an open pleural cavity had been observed at autopsy performed on a moulder of "Steinholz" (magnesia cement mixed with sawdust, etc.) who had been subjected

ASARCO ELP 0003013

to occupational exposure to talc, asbestos and mica. Furthermore, bilateral plaques in the parietal pleura with an open pleural cavity were observed by *Müller* (1958) at autopsy on a case of asbestosis and in two autopsy cases mentioned by *Fehre* (1958) in his discussion of *Müller's* report. In one of these, there was a history of exposure to talc and asbestos dust, and in the other there had, in addition, been exposure to diatomaceous earth.

In an extensive autopsy series, comprising 73 cases of asbestosis, *Wagner* (1960) observed a dense cartilage-like layer in both the parietal and the visceral pleura in some cases. "Horn-like plaques" of the type described by *Gloyne* (1938) he found in only one case, but he mentioned that he had often encountered them in biopsy specimens from both the parietal and the visceral pleura. Histologically, they consisted of dense hyaline fibrous tissue with foci of calcification.

Furthermore, in a report on a case of asbestosis in which thoracoscopy revealed cancer of the pleura (malignant blastoma, pleural endothelioma), *Weiss* (1953) described porcelaneous plaque formation on the surface of the diaphragm and thickening of the entire parietal pleura. In addition, the latter showed finely nodular elevations, in places somewhat whitish in appearance. As far as can be judged from the description, these lesions were pleural plaques, which were thus concomitant with a malignant pleural tumour and asbestosis in a case with an open pleural cavity.

In a case of asbestosis concurrent with bronchial carcinoma, *Isselbacher et al.* (1953) observed "plaque-like" thickening of both the peritoneal and the thoracic surface of the diaphragm and of the surface of the liver. On histological examination the plaques were found to consist of hyaline connective tissue, and to measure up to 0.5 cm in thickness.

Roentgenological observations on pleural plaques in asbestosis

Jacob et al. (1955) were the first to draw attentition to the calcification of the pleura occurring in asbestosis. In 5 per cent of a series comprising 343 patients with asbestosis they observed peculiar patchy calcifications on both sides. Among 31 insulation workers (exposed to asbestos dust owing to the presence of asbestos in the insulation mass), *Frost et al.* (1956) found bilateral pleural calcification in 8. *Müller* (1958) stated that a feature typical of asbestosis is the presence of extensive shell-like calcifications on the basal and middle

ASARCO ELP 0003014

fields and on the diaphragmal domes. According to *Hurwitz* (1961), calcified pleural plaques are typical of mild cases of asbestosis. In addition, he stated that pleural lesions are much more frequent in asbestosis than roentgenologically discernible fibrotic changes of the lungs. Pleural fibrosis he regarded as a non-specific sign, whilst he held bilateral calcifications, particularly in the lower middle fields but also in the anterior upper fields and on the diaphragm and the mediastinal surfaces, to be more specific. Such changes are seen in some other pneumoconioses, too, but not in silicosis. *Hurwitz* emphasized that in extensive roentgenological investigations performed in South Africa on workers in gold, coal, copper, iron, chrome and manganese mines, calcified pleural plaques were not observed in a single case.

In a paper on pneumoconioses, *Kleinfeldt et al.* (1959) stated that in asbestosis there not infrequently occurs a marked pleural reaction with pleural and pericardial plaque formation. The authors pointed out that a similar picture is seen in tremolite talc pneumoconiosis.

In patients with asbestosis and pleural mesothelioma, *Sleggs et al.* (1961) found old-standing pleuritic changes. They stated that while leural thickening *per se* in asbestosis is non-specific in character, sclerotic pleurisy with plaque formation constitutes a readily recognizable and rather typical entity. In the majority of cases of mesothelioma, neither these changes nor any other roentgenological signs of asbestosis were present.

In a series of 651 cases of asbestosis, *Müller* (1962) observed calcification in 6 per cent of patients with slight asbestosis, whilst in severer cases, of grade III, the percentage of pleural calcification rose to 38. This finding is in contrast to *Hurwitz's* theory that pleural changes are typical of mild asbestosis, in particular.

Lawson (1963) described two patients with roentgenologically discernible plaques who had a history of long-continued exposure to asbestos.

According to *Oosthuizen et al.* (1964), calcified pleural plaque formation is highly suggestive of exposure to asbestos, particularly if tuberculous pleurisy, calcified haemothorax and talc pneumoconiosis can be excluded. During a roentgenological investigation of 2383 cases in northwestern Cape and northeastern Transvaal, 166 cases of definite uncomplicated asbestosis were found. Of these, 59 showed calcified plaques as the only sign of asbestosis.

Cartier (1964) detected pleural plaques in 126 cases among the workers in eight asbestos mines in Canada. He regarded pleural plaques as a pathological entity different from asbestosis; since in

ASARCO ELP 0003015

most cases the former exist without any signs of asbestosis and most cases of asbestosis, even if they are far advanced, show no signs of pleural plaques. He suggested that plaques may be due to another dust factor than that which causes asbestosis, and that the specific aetiological factor of plaque formation has not yet been identified.

In a recent report on a case of asbestosis, *Stahlmann et al.* (1965) mentioned that bilateral calcified pleural plaques with curved outlines were a typical finding.

Contrary findings have also been published, however. An extensive roentgenological mass investigation performed by *Smith* (1952) on various groups of workers exposed to dust is of particular interest. Among 261 asbestos workers, none exhibited pleural calcification. By contrast, calcareous deposits in the pleura were observed in 6.6 per cent of talc workers.

Pleural plaques in so-called non-occupational asbestosis

In 1960, *Kiviluoto* published an extensive roentgenological investigation on the occurrence of pleural calcification among people living in the vicinity of the two asbestos mines in Finland. He showed that bilateral calcification of the parietal pleura was common among the population living near the asbestos mines but not occupationally exposed to asbestos, whilst this finding was very infrequent among those living at a greater distance from the mines. The only factor in common to all subjects exhibiting pleural calcification in the absence of a history or roentgenological signs of pulmonary or pleural disease or haemothorax, seemed to be that they had lived in the vicinity of an asbestos mine. On the basis of his results, *Kiviluoto* created a new concept, non-occupational endemic asbestosis. Another noteworthy observation was that pulmonary fibrosis was not detectable in most cases with pleural calcification. Marked fibrosis was present in only 12 per cent, and slight fibrosis in a further 12 per cent.

There is a certain discrepancy between this finding and the results of another Finnish roentgenological study on asbestosis *(Wegelius* 1947), in which no case of pleural calcinosis was detected among 126 cases of occupational asbestosis. This discrepancy *Kiviluoto* attributed to different modes of exposure to asbestos dust. Asbestos workers are exposed to a much higher concentration of dust for a shorter time than those living near an asbestos mine, who are subject to slighter exposure for a life-time. The formation of pleural calcareous plaques

ASARCO ELP 0003016

seems to require a very long time, since the youngest subject in whom lesions were observed was 30 years old. The localization of the plaques in the parietal pleura established in most of the cases investigated roentgenologically, was confirmed by autopsy in one case and by biopsy in another. In these, plaques were found only on the parietal pleural surface in the dorsal and basal portions of the thoracic cavity. Histologically the plaques showed collagenous fibrosis, the central part of which was calcified. The visceral pleura was found to be normal, and no asbestos bodies were detected in the lungs or on the pleural surfaces in routine histological stainings. By contrast, in the autopsy case, from the lungs fibres were recovered which were identified mineralogically as anthophyllite asbestos.

Bilateral patchy pleural calcinosis is a phenomenon which has long been familiar to Finnish roentgenologists working in Northern Savo and Northern Karelia. The concentration of these cases in the mining communes had also been noticed before *Kiviluoto* related this observation to the theory of exposure to asbestos dust. On fluoroscopy of the chest the local roentgenologists have been able to surprise their patients by "reading" their domicile from their lungs. Calcifications have been the "visiting-cards" of the inhabitants of the mining communes, as the local roentgenologists say *(Pyykönen, Raunio, Sipilä* 1960).

In a mass miniature roentgenological investigation comprising almost the entire population of Finland, *Raunio* (1965) found bilateral patchy pleural calcification in about 9 per cent of the population of one of the mining communes (Tuusniemi) and in about 6.4 per cent in the other (Kuusjärvi), whilst in other rural communes the corresponding figure was usually below 0.01 per cent. Slightly higher figures were only obtained in the communes bordering the mining communes.

The data available from other parts of the world concerning the occurrence of pleural calcification of the "non-occupational-asbestosis type" are scanty. In the city of Dresden, Germany, *Anspach* (1962) detected 244 cases of pleural calcification, 59 of which were asbestos workers and 118 subjects who lived in the vicinity of asbestos factories, the majority at a distance of 1.8 km from them. In 37 of his cases no history of exposure to asbestos dust could be elicited. In 32 of these, calcification was bilateral. On the basis of his results, *Anspach* did not regard bilateral pleural calcification as pathognomonic of asbestosis. In his opinion previous exposure to asbestos dust is conditional for a diagnosis of asbestosis. By contrast, *Anspach* held that if calcification is typical and a history of exposure to asbestos

ASARCO ELP 0003017

dust can be elicited, then a diagnosis of asbestosis is justified even in the absence of roentgenologically demonstrable pulmonary fibrosis and signs of disturbance of the respiratory or cardiovascular function.

Typical asbestosis with bilateral pleural plaques was described by *Wagler et. al.* (1962) in a man who had worked near an asbestos factory in Dresden. In Canada *(Cartier* 1964) and South Africa *(Wagner* 1964) results have been obtained which support *Kiviluoto's* theory concerning endemic asbestosis. The first data on environmental asbestosis were published by *Stewart et. al.* (1932). These authors observed typical pulmonary fibrosis and asbestos bodies in a man who had lived in the vicinity of an asbestos factory, but who was not known ever to have been inside the factory. Pleural calcinosis was not mentioned in their report, but the parietal and visceral layers of the pleura were thickened and almost completely fused on both sides.

Pleural plaques in other pneumoconioses

Before the occurrence of pleural calcification in the form of plaques had been described in asbestosis, this phenomenon had been observed to some extent in talc workers. It was mentioned for the first time in a report on roentgenological mass investigations of workers in talc mines and mills, performed in the USA, in which the lesion was detected in 6.3 per cent *(Siegal et al.* 1943). In this report the denomination "talc plaques" was introduced. Talc dust may cause pulmonary fibrosis, roentgenologically resembling the diffuse fibrosis occurring in asbestosis *(Nuck et al.* 1939). Other features which the two conditions have in common are the so-called ground glass appearance, a kind of soft haziness seen on the roentgenograms, and the diffuse thickening of the pleura, which in talcosis is more marked in the basal and middle fields of the lungs, just as is pulmonary fibrosis. Emphysema is frequently encountered in the upper parts of the lungs in talcosis, too. Talc plaques occur in the peripheral portions of the lung fields. Initially, they were believed to be situated in the subpleural tissues, under the visceral pleura, and they were also sometimes observed on the pericardium. The appearance of the plaques varies from linear, homogeneous and sharply demarcated shadows a few centimetres long to irregular extensive patches of varying density *(Siegal et al.* 1943). In a report on an autopsy case of talcosis *Hobbs* (1950) mentioned that the parietal pleura exhibited thick irregular bands of rubbery consistency, occupying the intercostal spaces on both sides. In an extensive roentgenological mass survey of workers

ASARCO ELP 0003018

exposed to various kinds of dust, *Smith* (1952) detected pleural calcinosis in 6.6 per cent of tremolite talc workers, in 1.6 per cent of mica workers, in 1.5 per cent of bakelite workers (talc and mica are ingredients of bakelite), in 1.7 per cent of calcimine workers, but not at all in asbestos workers (261 cases examined). In one autopsy case a dense "calcified plaque" was found to the left on the surface of the parietal pleura. Histologically, it consisted of dense, non-hyaline fibrous tissue, showing diffuse calcification and necroses.

Winkler (1961), too, mentioned plaque formation on the parietal pleura in talcosis, particularly on the surface of the diaphragm, pericardially and in the basal portions of the lateral walls of the chest, but also on the interlobar surfaces. He described the lesions as consisting either of loose connective tissue or of massive layers of collagen.

Just as is the case with the plaques found in asbestosis, those occurring in talc pneumoconiosis have been described almost solely on the basis of roentgenological investigations. No thorough pathoanatomical studies have been performed.

In this connection it should be mentioned that certain authors have detected asbestos bodies in talc pneumoconiosis, too *(Porro et al.* 1942, *Hunt* 1956, *Kleinfeldt et al.* 1959). It is a well-known fact that talc dust often contains tremolite, which is a calcium-magnesium silicate *(Siegal et al.* 1943) Like asbestos, it often occurs as needle-like fibres, and this feature is so conspicuous that it justifies the classification of tremolite as a subgroup of amphibole asbestos *(Nuck et al.* 1939, *Siegal et al.* 1943, *Smith* 1952, *Kiviluoto* 1960). In their survey of pneumoconioses, *Kleinfeldt et al.* (1959) wrote as follows: "Peculiar to asbestos and the asbestine variety of talc (tremolite talc) is the presence of 'asbestos bodies' ". Furthermore, *Gardner* (according to *Siegal et al.* 1943) stated that the talc mineral occurring in the region which was studied by *Siegal et al.* also contains anthophyllite.

Pulmonary fibrosis, pleural fibrosis and pleural plaque formation thus seem to be features common to asbestosis and tremolite talc pneumoconiosis, and possibly also to other types of talc pneumoconiosis. In addition, asbestos body formation in the lungs is caused by both asbestos and tremolite talc. The fibres of tremolite talc dust ought not to be harmful, since they are under 15 μ long *(Siegal et al.* 1943), for *Vorwald et al.* (1951) found that fibres under 20 μ do not cause pulmonary fibrosis in laboratory animals. In view of the number of unsettled points relating to this problem, however, such a conclusion seems to be rash at the present juncture. *Gardner et al.* (1931), for instance, held that the borderline value for the length of injurious fibres is only 3μ.

ASARCO ELP 0003019

Pleural plaques and exposure to mixed dusts

In the foregoing, *Smith's* (1952) study was mentioned, the subject of which was the pleural calcinosis occurring among workers exposed to various dusts. Many dusts consist of several minerals, calcimine and bakelite, for instance, containing asbestos as one of the ingredients. *Fehre's* (1956) investigation was performed on "Steinholz" moulders, who are exposed not only to dust from asbestos but to talc and mica dust as well. *Stephanopoulos* (1962) described two typical cases of bilateral pleural calcinosis without any history of pleural or pulmonary disease to afford an explanation of the finding. Both these subjects had long ago been exposed to dust of a kind that could not be accurately defined, probably to mixed dust. One of them had been working in a brick kiln, the other in a shell jacket factory. In actual fact, human beings hardly ever live in conditions in which they are exposed to dust of only one kind, as is the case with laboratory animals *(Gloyne* 1951). Hence it is very difficult to evaluate the possible causal relationship between the occurrence of pleural plaques and exposure to a certain kind of dust.

Bilateral plaque-like pleural changes in cases without any history of exposure to dust

In the literature, occasional reports are found on bilateral pleural calcinosis, interpreted as resulting from previous inflammation or attributed to unknown causes. Obviously, roentgenologically discernible bilateral pleural calcification occurs very infrequently, and the number of relevant patho-anatomical reports is very small. *Boffano* (1961) stated that bilateral pleural calcification is of very rare occurrence. He published roentgenograms of a case exhibiting bilateral calcification of the same type as has been described in asbestosis and talcosis, but mentioned nothing about exposure to dust. *Kiviluoto* (1960) found in the literature some reports of "idiopathic" bilateral pleural calcinosis. A history of inflammation was mentioned in the cases of bilateral pleural calcinosis described by *Sörensen* (1926) in Denmark, *Kjerp* (1932) in Finland and *Claus* (1962) in Germany. In the last-mentioned case the patho-anatomical observations were also described. The plaques were situated in the parietal pleura and arranged like talc plaques. Histologically, they consisted of dense collagenous connective tissue which was hyaline and very poor in nuclei and blood vessels. Between the collagen fibres, calcified deposits were found. In this case there was a history of

ASARCO ELP 0003020

bilateral pleuro-pneumonia thirteen years before death. *Claus* emphasized that the fibrotic thickening of the parietal pleura corresponded anatomically to the so-called sugar icing (Zuckerguss) sometimes occurring on the surface of the liver, spleen, intestines, pericardium and pleura.

A similar case of sugar icing of the pleura was described by *Brosig* (1939).

The patho-anatomy of corresponding pleural plaques was described by *Lauche* (1928). He stated that drop-shaped or nodular, coralliform white plaques, consisting of firm, fibrous, hyaline connective tissue, were sometimes observed on the costal pleura. Occasionally, they also contained calcium, coal pigment, and cartilage, or even bone. *Lauche* regarded these formations as resulting from pleurisy. His paper does not reveal whether the lesions were bilateral.

Tivenius (1963) described pleural plaques in 10 cases (5 bilateral) in Göteborg in which biopsy specimens were taken at thoracotomy. Thoracoscopy revealed scattered plaques, which were whitish-yellow and slightly elevated, 2 to 3 mm thick, with a rough surface and distinctly demarcated. They varied in size from that of confetti to hat of the palm of the hand. Sometimes the diaphragm, too, was covered with plaques, but such lesions were not observed on the visceral pleura. Histologically, the plaques consisted of "fibrous hyaline sclerotic connective tissue", and at least in one case the plaque was in part calcified. In *Tivenius*'s cases both the roentgenograms and the histopathological features were apparently identical with those described in asbestosis and talcosis, but nothing is mentioned regarding exposure to dust. According to *Tivenius*, Swedish pathologists encounter such pleural plaques "now and then" not only on the parietal, but also on the visceral pleura, and he states that they are relatively common findings on thoracoscopy, too. Their aetiology is defined as "obscure".

From *Tivenius*'s statement concerning the observations made by Swedish pathologists, and also from the experience of Finnish pathologists (*Järvi* 1963, *Saxén* 1963) it may be assumed that calcareous thickening of the pleura in the form of plaques, as described in the foregoing, is by no means a rare condition. Consequently, it seems obvious that the lesion in question has been regarded as an insignificant, incidental finding, which has not been considered worth while to report. *Tivenius* drew attention to these plaques for the reason that on the roentgenogram they may simulate tumours and thus, if misinterpreted, may lead to unnecessary thoracotomy.

ASARCO ELP 0003021

In a recent roentgenological mass investigation performed in a certain district in south Bohemia, *Marsová* (1964) detected pleural calcifications in 241 cases out of 44549. No history of exposure to talc, asbestos or mica could be elicited. All the subjects showing pleural calcification were agricultural workers. *Marsová* suggests that exposure to a certain mineral containing calcium (Kalcofen of Chynov) might be involved, since it is possible that this had been used as a fertilizer to raise the calcium content of the soil, which is known to be very low in the district in question. Kalcofen contains small amounts of tremolite.

The pleural plaques as compared with similar changes in other serous membranes

In those few papers in which the patho-anatomy of pleural plaques has been described, these lesions have been denoted by various terms like "cartilage-like layer" *(Lauche* 1928, *Brosig* 1939, *Wagner* 1960, *Tivenius* 1963), sugar icing *(Lauche* 1928, *Brosig* 1939, *Claus* 1962), "horn-like" formations *(Gloyne* 1938, *Wagner* 1960), porcelaneous thickening *(Weiss* 1953), "yellow bands of rubbery consistency" *(Hobbs* 1950), "hard yellow plaques" *(Kiviluoto* 1960).

The lesions have been found to consist of hyaline, calcified collagenous connective tissue *(Lauche* 1928, *Brosig* 1939, *Fehre* 1958, *Wagner* 1960, *Claus* 1962, *Tivenius* 1963) or callagenous fibrosis *(Kiviluoto* 1960) or non-hyaline fibrous tissue *(Smith* 1952). It is thus obvious — as pointed out by *Brosig* (1939), *Claus* (1962) and others — that the pleural change involved is in point of fact a lesion of the kind that has long been known under the name of "Zuckerguss" *(Curschmann* 1884) or "frosting" or "sugar icing". It has been encountered on the peritoneal surface of the liver and spleen, in particular, but also on the pericardium and occasionally on the intestinal serosa *(Borrmann* 1927). However, similar lesions were observed long ago on the pericardium and pleura, too *(Siegert* 1898), usually in conjunction with similar changes in the serous membranes of other cavities *(Gofferjé,* cited by *Borrmann* 1927). It is known that this process as a rule affects more than one serous cavity (the pleural cavities, pericardium, peritoneum) and that the most conspicuous changes are almost invariably found in the vicinity of the diaphragm. This has generally been attributed to mechanical factors (the respiratory movements of the diaphragm and cardiac activity). Apart from sugar icing, the following names have been used, according to *Borrmann* (1927): polyserositis fibrosa *(Gofferjé),* progres-

ASARCO ELP 0003022

sive hyaloserositis *(Nicholls)*, perivisceritis, linite plastique (French authors) and polyorromenitis (Italian authors).

Furthermore, *Pick* used the designation pericarditic pseudo-liver cirrhosis, since he believed that the process began by shrinkage of the pericardial sac, subsequently leading to venous stasis and thus to cirrhosis of the liver and ascites, and to thickening of the liver and spleen capsules *(White* 1955). This theory has not gained any wide acceptance, since isolated "sugar icing" is also of frequent occurrence *(Borrmann* 1927). In this type of serous lesion no microorganism has ever been detected, and no causal relationship has been demonstrated between any known disease and the "sugar icing" of serous membranes. Hence, the condition has been regarded as idiopathic in origin *(Borrmann* 1927, *Brosig* 1939, *Lubarsch* 1927).

When occurring on the surface of the spleen, the same kind of lesion has been called perisplenitis chronica cartilaginea or "Zuckergussmilz" *(Lubarsch* 1927) or hyaline fibrous perisplenitis *(Boyd* 1953). It has been reported in long-standing ascites, but also in connection with senile atrophy and on the coats of enlarged spleens. The lesion occurs as patches varying in size, sometimes enclosing the whole spleen. *Lubarsch* (1927) suggested that it may develop as a consequence of such mechanical factors as friction and pressure.

Asbestos and malignancy

The relationship between lung cancer and asbestosis has attracted attention since 1935, when the first reports on patients with asbestosis associated with lung cancer were published *(Lynch et al.* 1935, *Gloyne* 1935). According to many later statistical studies the frequency of lung cancer seems to be particularly high among patients with asbestosis and also among asbestos workers, irrespective of whether they have had asbestosis.

The most noteworthy recent statistical data are given below.

	Asbestosis No. of cases	Lung cancer No. of cases	%
Merewether (1949)	235	31	13.2
Gloyne (1951)	121	17	14.1
Bonser et al. (1955) ..	72	14	
König (1960)	36	11	
Buchanan (1963)	556	124	22.3
Jacob (1963)	105	18	
	Asbestos workers		
Doll (1955)*	105	18	
	Insulation workers		
Selikoff et al. (1965) ..	307	53	17.3

ASARCO ELP 0003023

In extensive autopsy series the frequency of lung cancer has mostly been 2—6 per cent *(Wedler* 1943). Today, the majority of investigators seem to accept exposure to asbestos as a factor increasing the risk of lung cancer. Others, however, hold that the situation is not so dismal as it would seem from the statistical data, since the studies in question have been performed without applying the principles of epidemiological research and on the basis of autopsy series which always are somehow or other selected *(Braun et al.* 1958, *Bohlig et al.* 1960).

It has been stated that the lung cancer of asbestos workers exhibits certain special features. It is not dependent on the degree of severity of the pulmonary fibrosis *(Jacob* 1963). It occurs at a relatively early age and rather frequently in women, too. In four cases of five, the lung cancer associated with asbestosis affects the lower lobe, whilst in the general population lung cancer in more than half the cases occurs in the upper lobe *(Hinson* 1965). Squamous cell carcinoma is said to be particularly common in asbestosis *(Nordmann* 1938, *Jacob* 1963). The carcinoma often appears after a long latent period, counted from the cessation of exposure to dust, at a time when all asbestos fibres ought long ago to have changed into asbestos bodies in which form they cause no mechanical damage.

In Germany, lung cancer associated with asbestosis is accepted as an occupational disease entitling to compensation (*Weiss* 1943).

During the last few years, interest has mainly been directed towards the clarification of the causal relationship between exposure to asbestos and malignant diffuse mesothelioma of the pleura or peritoneum, a type of tumour previously regarded as rare. Mesothelioma has chiefly been observed in subjects with a record of occupational exposure to asbestos dust and in persons whose domicile was in the vicinity of asbestos mines or factories (environmental exposure).

The most recent statistical data on the association of mesothelioma and exposure to asbestos dust are given in the table below.

	Mesothelioma No. of cases	Exposure to asbestos No. of cases
Thomson (1962)	7	6
Fowler et al. (1964)	2	2
Hourihane (1964)	34	15
Owen (1964)	17	14
Wagner (1964)	78	76
Elmes et al. (1965)	12	32
Selikoff et al. (1965)	7	7

ASARCO ELP 0003024

It has been emphasized that the exposure may be slight and often remote in time, having occurred, perhaps, some forty years earlier.

Wagner (1960) drew attention to the fact that in cases of mesothelioma, the patients have almost invariably been exposed to a special kind of asbestos, i.e. crocidolite (blue asbestos), which is mined on the Cape asbestos fields in South Africa. From the same kind of asbestos, *Harington* (1962) was able to isolate small amounts of polycyclic aromatic hydrocarbons, e.g. the well-known cocarcinogen 3—4 benzpyrene. Apart from crocidolite, there is another type of asbestos, amosite, which also contains these substances but to a lesser extent. It is not yet known with certainty whether mesothelioma is associated with exposure to crocidolite asbestos dust only, since this tumour has also been observed in cases exposed to other kinds of asbestos, and sometimes without any history of exposure.

Wagner (1962) succeeded in producing mesothelial tumours in rats by injecting various kinds of asbestos into the pleural cavity. The lesion was not entirely specific for asbestos, however, since in some control animals similar tumours developed from exposure to silica dust.

In general, the carcinogenic effect of asbestos has been attributed to the chronic influence of the mechanical irritation caused by this mineral *(Weiss* 1953, *Leicher* 1954, *König* 1960).

According to certain reports, the frequency of cancer of the stomach, too, seems to be increased among asbestos workers *(König* 1960, *Selikoff et al.* 1964).

The occurrence of asbestos bodies in the parietal and visceral pleura

Against the background of the formation of parietal pleural plaques and fibrosis and adhesions of the visceral pleura in asbestosis and, on the other hand, the abundant occurrence of malignant pleural tumours which has lately been observed and related to even slight exposure to asbestos dust, it seemed to be of some interest to investigate to what extent asbestos fibres spread through the lung parenchyma to the pleura. This question has hitherto attracted relatively little attention.

According to *Gloyne* (1938), asbestos bodies are sometimes found in the pleura, too, although in small numbers and as a rule only as short fragments. He suggested that the longer bodies perhaps do not penetrate as far as the periphery. The asbestos bodies occur in groups

ASARCO ELP 0003025

and are surrounded by connective tissue. Furthermore, *di Biasi* (1938) detected asbestos in pleural adhesions. In guinea-pigs *Gardner et al.* (1931) observed small numbers of asbestos bodies "outside the lungs" and "in areas of chronic fibrous pleurisy". By contrast, *Wagner et al.* (1960) did not detect asbestos bodies outside the elastic lamellae on the surface of the lung in any instance in a series of 73 cases of asbestosis. Similar results were obtained by *Lynch et al.* (1948). In an autopsy case described by *Egbert* (1935), asbestos bodies were found in the thickened pleura. According to *Leicher* (1954), *Wedler* (1954) observed that asbestos spicules may penetrate the pleura.

Very interesting in this connection is a case of a pleural tumour described by *Weiss* (1953), in which histopathological examination revealed asbestos bodies in the tumour tissue, which at many points bulged from the lung surface into the pleural cavity. As previosly mentioned (p. 00), at thoracoscopy of this patient plaque-like formations were detected in the pleura.

It is thus obvious that asbestos bodies may be encountered outside the lungs, in the pleura, although only in some cases and in small numbers. I have not seen any report of asbestos bodies occurring in the parietal pleura when the pleural cavity was open. Such bodies have not been found detached in the pleural cavity, either, but it should perhaps be added that nobody seems ever to have looked for them in this site.

ASARCO ELP 0003026

PROBLEMS

Asbestos bodies

1) How frequently do asbestos bodies occur in the lungs?
2) What is the age and sex distribution of asbestos bodies?
3) Does the domicile influence the occurrence of asbestos bodies in the lungs?
4) What is the density of asbestos bodies in individual cases in a non-occupational series?
5) What is the morphology of asbestos bodies found in a non-occupational series?
6) Is there any correlation between the presence of asbestos bodies and occupation (apart from work in asbestos mines and factories)?

Pleural plaques

1) How frequently do plaques occur in the parietal pleura?
2) What is the age and sex distribution of pleural plaques?
3) Does the domicile influence the occurrence of pleural plaques?
4) What is the location of pleural plaques in the thoracic cavity?
5) What is the pathological anatomy of the pleural plaques?

Relationship between asbestos bodies and pleural plaques

1) Do asbestos bodies occur in the pleural plaques?
2) Do asbestos bodies occur in the lungs in cases exhibiting pleural plaques?

Relationship between pleural plaques and diseases of the lungs and cardiovascular system

Is there any correlation between the occurrence of pleural plaques and chronic diseases of the heart or lungs?

ASARCO ELP 0003027

Relationship between pleural plaques and similar lesions in the other serous cavities

Are plaque-like lesions in the peritoneum concurrent with pleural changes of this type?

Occurrence of plaques in domestic animals

Do pleural plaque-like changes occur in domestic animals in the vicinity of asbestos mines?

ASARCO ELP 0003028

MATERIAL

The material consists of consecutive routine autopsy subjects aged 15 years and older. It was collected from three Finnish hospital districts (see map in Fig. 1) and is correspondingly classified into three groups. Group 1 was collected at the Central Hospital of the University of Turku and consists of cases from the southwest coast of this country. The autopsies were performed at the Department of Pathological Anatomy of the University of Turku in the spring of 1964. Group 2 consists of cases from the region of Northern Savo in east Finland. Most autopsies were performed by myself at the Central Hospital of Kuopio during the years 1963—1964. All subjects who had been employed in an asbestos mine or industry were omitted from this group. Group 3 consists of autopsies performed in spring 1964 at the Department of Pathological Anatomy of the University of Oulu on subjects who came from the northwest coast of Finland.

The series consists of a total of 438 consecutive autopsy cases distributed over the above-mentioned regions as follows:

Group 1: 91 cases
Group 2: 255 „
Group 3: 92 „

For the purpose of studying more closely a possible neighbourhood effect of asbestos mines, all subjects aged 15 years and older from Tuusniemi commune in Northern Savo that had been examined post mortem at the Central Hospital of Kuopio between Jan. 1960 and June 1965 were studied. The village of Paakkila in this commune is the site of the only asbestos mine and mill that are worked in Finland today. The group in question consisted of 15 cases. From another commune in Northern Savo, Maaninka (Fig 3), a corresponding number of autopsy cases from the same period were collected to serve as controls. These two groups were not included in any other analysis performed in the present study.

Since the present material consists of routine autopsy cases from general hospitals, it is primarily selected. Therefore, it does not fulfil

ASARCO ELP 0003029

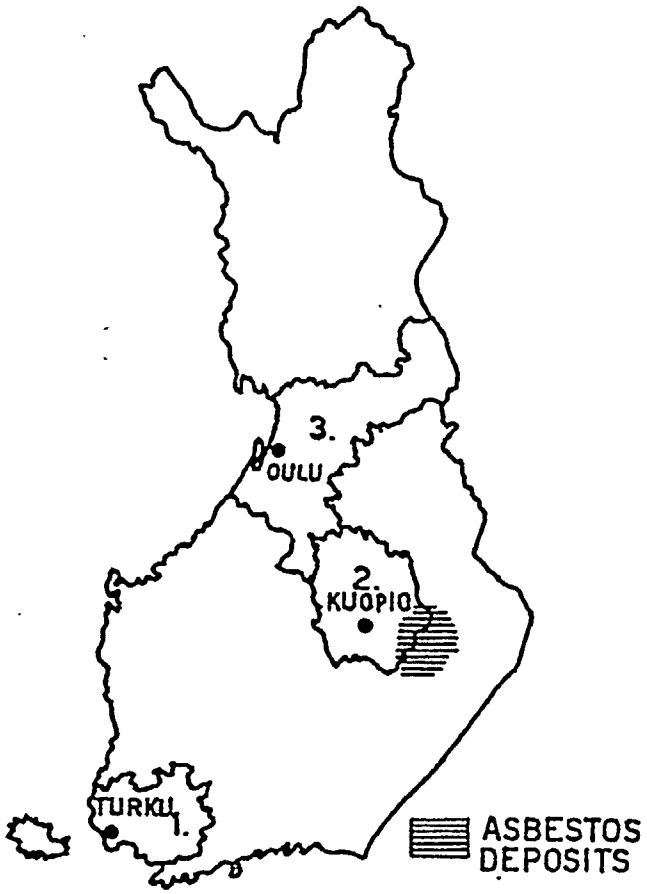

Fig. 1. Map showing the three Central Hospital districts of Finland, the autopsy material of which formed the basis of the present study.

ASARCO ELP 0003030

the strict criteria of an epidemiological investigation. Taking this into account the data collected in the present study were not, as a rule, regarded as suitable for statistical treatment. Nonetheless, the study of an autopsy series is the only possible basis for evaluating the occurrence of asbestos dust, or any factors that may produce asbestos bodies, and of parietal pleural plaques. Hence, it was considered of some interest to present the statistical data as such.

In regard to the relationship between the frequency of pleural plaques and asbestos bodies a statistical analysis of significance was made. In this the χ^2 *test* for 2 x 2 contingency table was used. On this point the statistical analysis was regarded as emphasizing a relationship which, on the basis of the observations made, seemed to be obvious, but which it was difficult to express merely with the aid of the numerical results. In those other few instances where the significance of the differences between two means was considered to be of interest, the *t-test* was used.

ASARCO ELP 0003031

Part I

OCCURRENCE OF ASBESTOS BODIES IN ROUTINE AUTOPSY CASES

METHODS

In order to count the asbestos bodies present all available lung specimens were collected from the present series of cases. One to four specimens were taken from pieces obtained from apparently healthy-looking portions of the lungs. An attempt was thus made to avoid tissue affected by tuberculosis, cancer or other destructive processes. The specimens were fixed in formol and embedded in paraffin. Sections were cut at 20μ and iron staining, i.e. the Prussian blue reaction of Wicklein — Falkenberg (*Romeis* 1948), was performed in order to facilitate the detection of asbestos bodies (see Plate I, b,c). For general histological examination van Gieson's stain was used.

Asbestos bodies were counted by systematic microscopic inspection of the entire surface of four sections in each case. As a rule, the sections measured about one sq. cm. The four sections were chosen as far as possible from different specimens. Scanning was performed with medium magnification (10:1 objective), and higher magnification was used for positive identification.

The following criteria were used for accepting foreign bodies as asbestos bodies: A typical elongated shape, symmetrical structure, a segmented, brushy or smooth surface, iron-positive encrustation and a length of over 20 μ. In some cases a refractive central core was of help in the identification.

Personal data were obtained from the hospital records and supplemented, when necessary, by enquiries at the official registries.

ASARCO ELP 0003032

RESULTS

A. General frequency of asbestos bodies in autopsy subjects aged 15 years and older

Among a total of 396 consecutive autopsy subjects aged 15 years and older, collected from three Finnish hospital districts (Fig. 1), lung specimens were available in 264 cases (66.6 per cent).

The cases were classified as positive or negative according to the presence or absence of asbestos bodies, irrespective of their numbers. As evaluated on this basis, the positive cases numbered 152 (57.6 per cent).

When the cases were classified into 10-year groups, the age distribution seen in Table 1 was obtained. Asbestos bodies were found in the lungs in all age groups examined. The proportion of positive cases in the different age groups varied somewhat, but no rise in frequency with increasing age was discernible. The oldest groups contained a somewhat lower proportion of positive cases than the middle-aged, but variations also occurred among the various middle-aged groups. In the group 46—55 years the frequency of asbestos bodies was lower than in the preceding and following groups. *Thomson et al.* (1963) made the same observation, without being able to offer any definite explanation.

TABLE 1

Age distribution of asbestos bodies in the whole series.

Age group, yrs.	Finding of asbestos bodies								
	Group 1		Group 2		Group 3		Groups 1—3		Total
	positive	negative	positive	negative	positive	negative	positive	negative	
15—25			3	3	1		4	3	7
26—35	2	1	6	4		1	8	6	14
36—45	1	1	8	3	1		10	4	14
46—55	6	5	17	10		4	23	19	42
56—65	17	8	28	16	8	6	53	30	83
66—75	22	10	18	17	4	4	44	31	75
76—	3	8	5	7	2	4	10	19	29
Total	57	33	85	60	16	19	152	112	264

On comparing the frequency of asbestos bodies in males and females, the following result was obtained:

Among a total of 148 males (56 per cent of the whole series), asbestos bodies were found in 89 (60.1 per cent).

ASARCO ELP 0003033

Among a total of 116 females (44 per cent of the whole series), asbestos bodies were found in 63 (54.3 per cent).

The proportion of positive cases was somewhat higher among the men, but the difference was insignificant.

As will be shown later, all those cases in which asbestos bodies occurred in relatively great numbers were men, however. Thus, classification into positive and negative cases is liable to give a misleading idea of the situation. In point of fact, asbestos bodies were mostly found in greater abundance in the men than in the women, but owing to the wide individual variation in the density of asbestos bodies, statistical analysis of this point was impossible.

B. Influence of domicile on the occurrence of asbestos bodies in the lungs

In order to find out whether differences in the occurrence of asbestos bodies in the lungs are observable between the inhabitants of different parts of Finland, material was collected from three hospital districts situated in different parts of the country (groups 1, 2 and 3, Fig. 1).

The distribution of the material of lung specimens between the different groups was as follows:

In group 1, consisting of 91 cases, lung specimens were obtained from 84 (about 92 per cent).

In group 2, consisting of 214 cases, specimens were obtained in 145 cases (about 70 per cent).

In group 3, comprising 92 cases, specimens were obtained from 35 (about 38 per cent).

In the various groups, asbestos bodies were found as follows:

Group 1, in 51 cases, or 60.7 per cent
Group 2, „ 85 „ „ 58.6 „ „
Group 3, „ 16 „ „ 45.7 „ „

No clear differences were observed between the inhabitants of different parts of the country in regard to the frequency of asbestos bodies. It is striking that although some of the cases in group 2 came from a region with asbestos deposits and an asbestos mine, this was not reflected as an increase in the frequency of asbestos bodies in the whole group.

The diagram in Fig. 2 shows the distribution of the cases in all three groups according to domicile and sex. Each group is divided into rural and urban cases.

ASARCO ELP 0003034

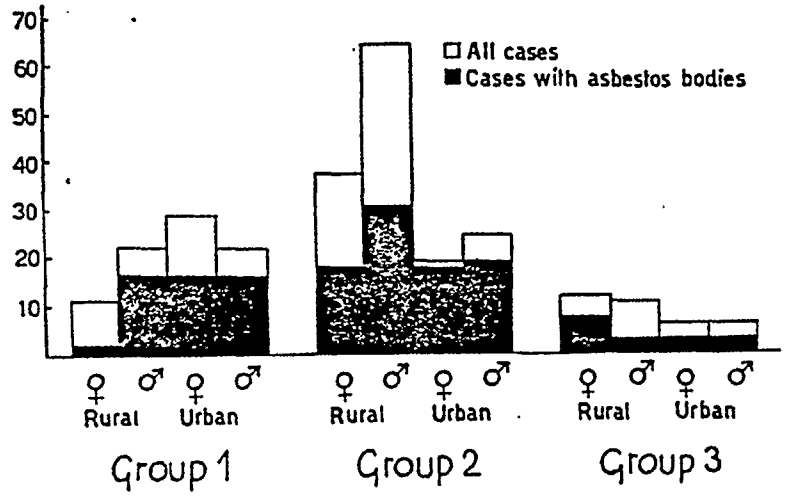

Fig. 2. Sex and residential distribution of 264 cases examined for asbestos bodies.

The total number (groups 1—3) of rural cases was 157, and of these 77 had asbestos bodies in the lungs. The proportion of positive cases in the rural population was 49 per cent.

The urban cases numbered 107 and asbestos bodies were detected in 75 (70 per cent).

The frequency of asbestos bodies was thus much higher in the urban population than in the rural population, Nonetheless, every second subject among the rural population had asbestos bodies in the lungs. This is a very interesting finding, considering that hitherto the occurrence of asbestos bodies has only been studied among urban populations, and the inhalation of asbestos dust has been regarded as mainly a hazard of cities. The high frequency of asbestos bodies among the rural cases is particularly noteworthy in view of the fact that in Finland the population density is very low, being in the region of group 2, for instance, only 11.4 persons per sq. km (*Statistical Year Book of Finland* 1963). In the present study no attempt was made to check whether the subjects had moved from the countryside to a town or *vice versa*, but since urbanization is in progress in this country, it was regarded as justified to assume that those who had indicated a rural community as their domicile, had probably lived most of their lives on the countryside. By contrast, the group of urban cases may comprise many persons who had only lived in a town for a short time. If it had been possible to collect a separate

ASARCO ELP 0003035

group of individuals who had spent all their lives in a town, it is possible that the difference between the urban and rural populations would have proved to be greater still.

Since the region inhabited by group 2 comprises asbestos deposits and the only asbestos mine that is being worked in Finland, these cases were subjected to closer analysis. The map in Fig. 3 shows the area of asbestos deposits at the eastern border of the district of the Central Hospital of Kuopio and the situation of the Paakkila asbestos mine, as well as the domiciles of the subjects investigated. All rural cases are marked at their sites of residence; different symbols are used for males and females, and the presence of asbestos bodies is indicated by blackening of the symbols. It is seen that in the town of Kuopio, the centre of the district, postive cases were detected in relatively greater numbers than in the countryside, but among the rural population no clear concentration of positive findings in the area of the asbestos deposits was observed. In making the map, just as in the calculation of frequency, cases were treated as positive even if only one asbestos body was found in the lung sections examined.

For further analysis, group 2 was divided into two subgroups in such a way that those who had lived within 50 km from the asbestos mine were distinguished from the remainder, who had lived farther away. It then emerged that in the former group, asbestos bodies were found in the lungs in the majority of cases (16 out of 24), whilst in the other group the finding was positive in somewhat less than half the cases (32 out of 75). All urban cases were omitted from this analysis, and so were those coming from the industrial community of Juankoski, which from the standpoint of the present study is comparable to a town. When the absolute number of asbestos bodies per four sections was taken into account, it was found that in the 16 positive cases coming from the vicinity of the asbestos mine the average number of asbestos bodies was 5.2, whilst in the 32 positive cases in the other group the corresponding figure was 3.0. The material included only one case from the mining village, i.e. a lorry-driver's assistant aged 18, whose lung sections exhibited 11 asbestos bodies. The results seem to indicate that asbestos dust may spread relatively far into the surroundings of an asbestos mine, although no significant differences could be demonstrated owing to the wide individual variations in the number of asbestos bodies detected.

In order to investigate further the possibility of a neighbourhood effect of the asbestos mine, a group of 15 subjects from the asbestos mining commune (Tuusniemi) was compared with a group of 15 cases from another commune (Maaninka), situated in the western

ASARCO ELP 0003036

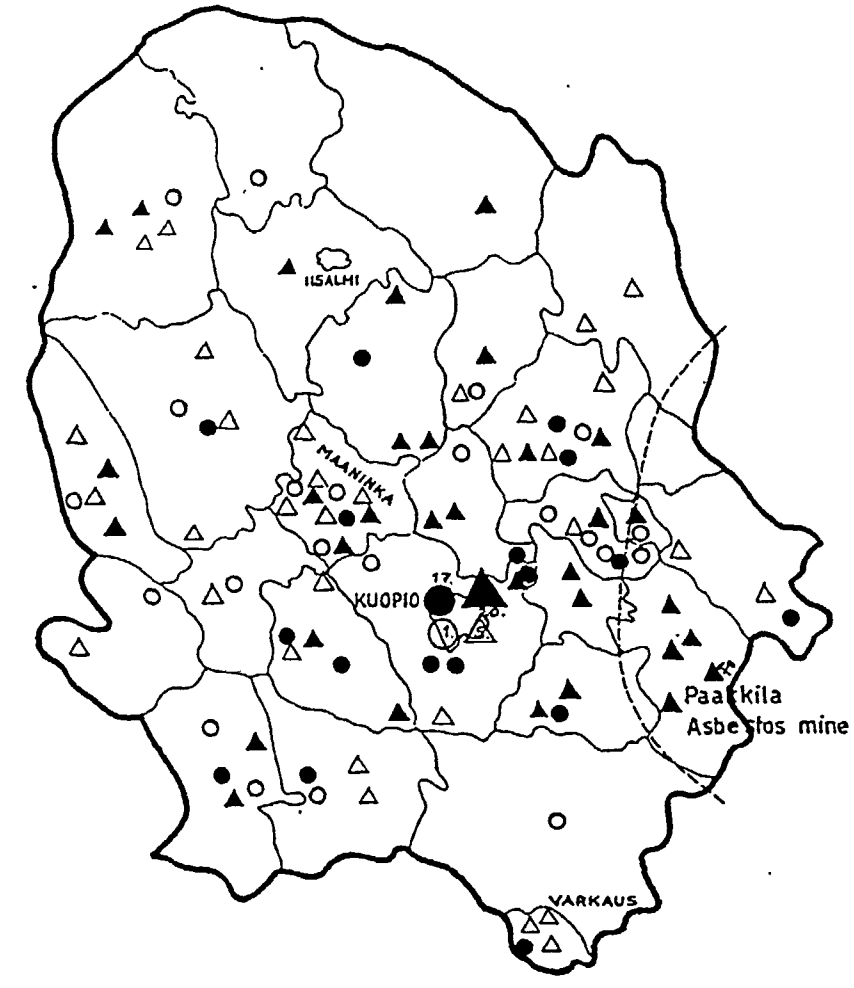

Fig. 3. Map showing the geographical distribution of the cases in group 2 coming from the Central Hospital of Kuopio. The area of asbestos deposits at the eastern border of the district is indicated with a broken line.

ASARCO ELP 0003037

TABLE 2

Cases from the commune of Tuusniemi, where the Finnish anthophyllite asbestos mine is situated (asbestos area), and from the commune of Maaninka (area without asbestos).

Asbestos area (Tuusniemi)

Autopsy no.	Age yrs.	No. of asbestos bodies	Occupation	Distance from mine, km	Plaque on pleura
146—60	69	291	Farmer	3	+
52—61	70	7	—„—	20	+
23—63	63	—	—„—	20	—
74—63	46	1	Labourer	18	—
132—63	72	4	Farmer	12	+
102—64	34	8	Labourer	8	+
105—64	18	11	Lorry-driver's assistant	1	+
113—64	42	6	Farmer's wife	16	+
129—64	73	5	Foreman	16	—
139—64	63	13	Manager	8	+
26—65	56	68	Farmer	1	—
31—65	78	7	Labourer's wife	20	+
50—65	67	—	Farmer's wife	18	—
70—65	47	27	—„— —„—	15	+
137—65	55	7	Farmer	20	+
Total		455			

Area without asbestos (Maaninka)

Autopsy no.	Age yrs.	No. of asbestos bodies	Occupation	Distance from mine, km	Plaque on pleura
3—63	68	4	Farmer	>60	+
33—63	76	—	—„—	„	—
102—63	63	—	—„—	„	—
107—63	65	—	—„—	„	—
112—63	59	—	—„—	„	+
44—64	48	—	Labourer's widow	„	—
39—64	76	—	Farmer	„	+
52—64	55	2	Teacher	„	+
67—64	56	—	Farmer's widow	„	—
68—64	81	7	Labourer's widow	„	—
88—64	57	5	Fisherman	„	+
137—64	60	—	Farmer's wife	„	—
147—64	50	—	Labourer	„	+
11—65	66	—	—„—	„	—
58—65	73	—	Farmer	„	—
Total		18			

ASARCO ELP 0003038

part of the hospital district, as was mentioned in the foregoing (p. 00). The results are shown in Table 2.

A statistical analysis based on these two groups showed that the frequency of asbestos bodies was very highly significantly ($p<0.001$) greater in the population of Tuusniemi (the asbestos mining commune). However, the number of asbestos bodies per case was only almost significantly greater ($0.5<p<0.1$) in Tuusniemi than in Maaninka.

C. Density of asbestos bodies in histological lung sections

In general, the number of asbestos bodies found in the individual cases was very low. In the majority of cases, only one to four bodies were found in all four sections together. Among the total number of positive cases in the three groups, i.e. 152, there were only 17 in which ten or more asbestos bodies were detected. The age, occupation, sex and number of asbestos bodies in these cases are shown in Table 3. All except two were men.

TABLE 3

Cases with ten or more asbestos bodies in the lungs in four sections examined.

Autopsy no.	Occupation	Age yrs.	No. of asbestos bodies	Thickness of pleural plaque (mm)	Bilateral plaque
6—63	Storeman in an ironmongery	52	43	4	+
26—63	Labourer	54	12	2.5	+
32—63	Engine shed worker (demolisher of engine insulations)	60	43	5	+
75—63	Labourer	68	40	0.4	+
99—63	Forestry technician's wife	68	10	3	—
114—63	Welder	45	40	4.5	+
153—63	Builder's worker	57	50	2.5	+
6—64	Sempstress	50	18	3.3	+
66—64	Engineer	61	23	3.0	+
105—64	Lorry-driver's assistant	18	11	2.3	+
79—64	Plumber	59	250 (c.)	3	+
103—64	Stoker	70	17	2	+
84—64	Carpenter	60	25	3	+
101—64	Tailor	53	12	2	—
107—64	Mason	71	25	3	+
132—64	Storekeeper in an ironmonger's and car-dealer's firm	64	41	(total obliteration of pleural space)	
180—64	Repair-shop worker	55	11	4.5	+

ASARCO ELP 0003039

Since asbestos bodies were detected in the majority of the present autopsy cases, it seemed arbitrary to regard a case as negative solely because four sections had contained no asbestos bodies. Hence, the effect of the number of sections examined on the chance of finding asbestos bodies in positive cases was analysed by classifying the material according to section in which the first asbestos body was found. As is seen in Table 4, in most cases the very first section contained asbestos bodies, but there were also a large number of cases in which bodies were not found until the last section.

TABLE 4

Classification of the 152 positive cases according to section in which the first asbestos body was found and the corresponding mathematically expected numbers.

	No. of cases	
	Observed	Expected
1st section	72	69.6
2nd „	39	42
3rd „	24	25.3
4th „	17	15.2

This analysis made it possible to estimate the probability of detecting asbestos bodies, by the method employed in the present study, in the lung sections of subjects whose lungs contain such bodies. By the method of maximum likelihood it was found that the probability is 0.398 when only one lung section is examined, 0.869 when four sections are examined, and 0.994 if ten sections are studied. By this calculation it was found that in the present series of subjects aged 15 years and older the true frequency of asbestos bodies was 66.3 per cent, and that asbestos bodies were detected in 86.9 per cent of the positive cases.

In Table 4, in which the cases are classified in groups according to section in which the first asbestos body was found, the number of cases is in each group compared to the mathematically expected number.

In order to find out whether the site of the specimens studied influenced the result, specimens from all the lung segments of three subjects were examined for asbestos bodies by the method previously described. In two cases the specimens were taken from the left lung, and in one case from the right. Fig. 4 shows the number of asbestos bodies found in specimens of the various lung segments. It goes

ASARCO ELP 0003040

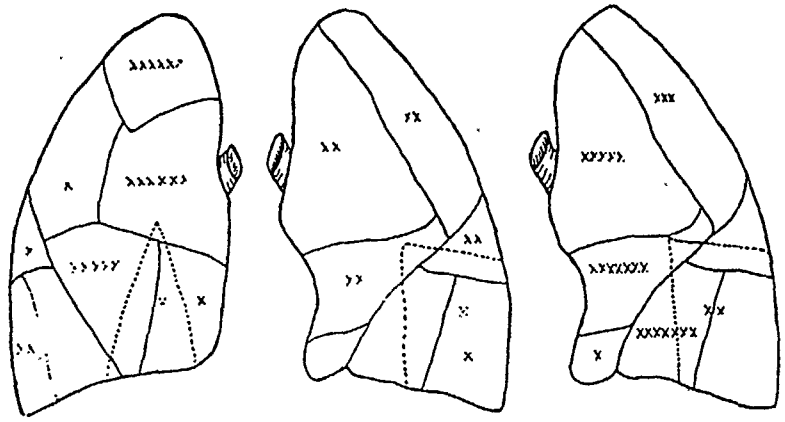

Fig. 4. Schematic representations of three lungs from different cases showing the asbestos body count in each lung segment.

without saying that the scanty material does not allow of any definite conclusions regarding the distribution of asbestos bodies between the various portions of the lung, but it seems probable that the site from which the specimen is taken is of no major significance. If asbestos bodies are present in the lungs in appreciable numbers, they are readily found in any part of the lung.

D. Morphology and location of the asbestos bodies found in subjects not employed in asbestos industries

Morphologically, the asbestos bodies found in the present material corresponded to the descriptions presented by previous authors (*McDonald* 1927, *Beger* 1933, *Gloyne* 1938). As a rule, they measured 20—40 μ (Figs. 5—12 and Plate I, b, c) but sometimes even 150 μ. Both curved and straight forms occurred, although the former were less frequent. The surface showed wide variations from entirely smooth to segmented structures resembling a necklace or a vertebral column. Furthermore, some asbestos bodies were serrated or brushy in outline. Often an unstained, refractive central core was observable, which sometimes peeped out at the ends of the protein encrustation (Figs. 7, 8). The end was often bulb- or ball-shaped (Figs. 8, 9). Occasionally, the asbestos bodies were very slightly iron-positive, thin, even, non-segmented spicules (recently inhaled, accord-

ASARCO ELP 0003041

ing to *Beger* 1933). The iron reaction was sometimes observable in only part of the asbestos body, although the encrustation seemed to cover the whole fibre like a thin, yellowish membrane. The asbestos bodies were not doubly refractive, and no attempt was made to detect asbestos fibres with the aid of polarized light or a dark-field technique. Thus, quite recently aspirated asbestos fibres were certainly not counted. Sometimes iron-positive, smooth balls were seen, which in size resembled the segments of asbestos bodies, but these were omitted from the count.

In a few cases the asbestos bodies were partially or entirely phagocytized by macrophages (Fig. 12). Foreign body giant cells, which are typical of asbestosis *(Gloyne* 1933), were found in only one case. In this, the number of asbestos bodies was the greatest recorded in the present study, i.e. 250. Occasionally, the asbestos bodies were situated inside the alveoli, but mostly they were in part, at least, located in the interstitium. Furthermore, in many cases asbestos bodies were found in the perivascular lymphatics among coal pigment. In these cases accumulations of coal pigment to some extent masked the asbestos bodies.



Fig. 5. Photomicrograph of an asbestos body of necklace-shape in an alveolar space. The body was about 100 μ in length. Wicklein-Falkenberg iron staining. × 105.

ASARCO ELP 0003042



Fig. 6. An intra-alveolar, broken asbestos body, length 33 μ. Wicklein-Falkenberg iron staining. × 450.



Fig. 7. High magnification of the same body as in Fig. 6. The central core can be seen protruding through the lower end of the encrustation. Oil immersion. × 900.

ASARCO ELP 0003043



Fig. 8. A typical asbestos body with the central core partly visible through the thinnest segments of the encrustation and protruding from the lower end. Length about 50 μ. Wicklein-Falkenberg iron staining. Oil immersion. × 900.



Fig. 9. A dumb-bell-shaped asbestos body, length about 55 μ. Wicklein-Falkenberg iron staining. × 450.

ASARCO ELP 0003044



Fig. 10. A curved asbestos body found in interstitial connective tissue of a lung. It was surrounded by lymph cells. The total length of this body was about 90 μ. Wicklein-Falkenberg iron staining. Oil immersion. × 900.



Fig. 11. An asbestos body embedded in connective tissue, length about 100 μ. Wicklein-Falkenberg iron staining. × 450.

ASARCO ELP 0003045



Fig. 12. A dumb-bell-shaped asbestos body, 90 μ in length, partly phagocytized by two macrophages. Wicklein-Falkenberg iron staining. × 450.

Severe pulmonary fibrosis was not observed in a single case exhibiting asbestos bodies. In some specimens with numerous bodies there seemed to be a slight increase in the amount of connective tissue, particularly in the form of scattered thickening and collagenization of alveolar septae. As similar mild fibrosis was seen now and then in lungs with no asbestos bodies, however, it could not with any certainty by attributed to asbestos dust inhalation.

E. *Influence of occupation on the frequency* of asbestos bodies in the lungs

For this part of the study all male farmers from groups 1—3 were compared with a group of male workers from the building trade or other related occupations. The latter were collected solely from the rural population. The results were as follows:

In a group of 49 farmers, with a mean age of 63.7 years, asbestos bodies were found in 23 cases (47 per cent).

In a group of 21 workers from the building or other comparable trades, with a mean age of 54.8 years, asbestos bodies were found in 14 cases (67 per cent).

ASARCO ELP 0003046

As regards the quantity of asbestos bodies, the average number per positive case was 1.6 among the farmers and 8.2 in the other group. The difference is very highly significant ($p<0.001$). On the basis of this finding it seems obvious that those working in the building or other comparable trades run a greater risk of inhaling dust causing asbestos bodies than agricultural workers.

A similar conclusion may be drawn when those 17 cases in which ten or more asbestos bodies were detected are analysed from the standpoint of occupation (Table 3). This group did not comprise a single farmer, but at least eleven persons who could be regarded as workers in the building trade.

SUMMARY OF THE RESULTS

Asbestos bodies.

1) Asbestos bodies were encountered in the lungs of 57,6 per cent, at least, of Finnish autopsy subjects aged 15 years and older. In actual fact this figure is obviously too low, since the number of positive cases seems slowly to rise as the number of sections examined is increased.

2) No consistent rise in the frequency of asbestos bodies was observed with increasing age. The frequency of asbestos bodies was nearly the same in the two sexes, but among those relatively few cases in which bodies were observed in somewhat greater abundance, the majority were men.

3) Asbestos bodies were more frequent in the urban than in the rural population. In a hospital district comprising asbestos deposits and an asbestos mine, the frequency of asbestos bodies was not significantly higher than in two other districts in which no asbestos mines or factories are situated. By contrast, in a group of cases from the asbestos mining commune, asbestos bodies were found more frequently than in a control group from another commune in the same district. The difference was very highly significant. It seems possible that bodies were also more numerous in the individual cases in the population living in the vicinity of the asbestos mine.

4) It seems that in an unselected series of autopsy cases the density of asbestos bodies is usually very low in the positive cases.

5) The size and shape of the asbestos bodies did not differ from what has been observed in asbestosis.

ASARCO ELP 0003047

6) In cases with a definite or probable history of occupational exposure to asbestos, asbestos bodies seem to occur in somewhat greater abundance than in the general population. This applies in particular to workers in the building and related trades. In such cases asbestos bodies were found more frequently and in greater numbers than in a control group of farmers, and the difference was very highly significant.

On evaluating the possible significance of the presence of asbestos bodies in the lungs, their relative abundance should also be taken into account, since such bodies seem to occur to some extent in the majority of subjects aged 15 years and older. In the relatively few cases of the present series in which asbestos bodies were found in somewhat greater numbers, they were nonetheless very scanty as compared with the findings in true asbestosis, and there was no pulmonary fibrosis of any significant degree in these cases.

ASARCO ELP 0003048

Part II

FIBROTIC THICKENING OF THE PARIETAL PLEURA (PLEURAL PLAQUES)

Occurrence, anatomy, histology, relationship to the occurrence of asbestos bodies in the lungs and to chronic diseases of the lungs and heart

METHODS

In the present study the expressions pleural plaque and scattered fibrotic thickening of the parietal pleura are used to denote lesions on the inner surface of the thoracic cavity, visible at autopsy with the naked eye and appearing as yellowish-white or greyish-white patches against the reddish background of the normal pleura. The histological criterion for accepting a lesion as a plaque was that the connective tissue in the thickened area was arranged like basket-weave in undulating layers parallel to the pleura. In the most typical cases the connective tissue always showed this structure, and for this reason very thin whitish pleural patches were classified as plaques only if they exhibited connective tissue of this type.

Before the collection of material for the present study was begun, the pathologists who were to perform the autopsies were informed of the purpose of the investigation and asked to pay particular attention to changes on the internal surfaces of the thoracic cavity. This was of importance for the reason that small, light-coloured patches in the posterior portion of the thorax are apt to escape attention because they usually become covered with sanguineous fluid during the performance of the autopsy.

The specimens taken from the pleura were fixed in formol and embedded in paraffin. Some of the specimens were stored in formol for later lipid staining. General staining was perfomed with van Gieson's technique. For calcium staining Alizarine Red and van Kossa's method were used in parallel. The elastic fibres were stained

ASARCO ELP 0003049

by Verhoeff's technique, and staining for iron was performed by Wicklein — Falkenberg's method (*Romeis* 1948). For lipid staining, Scarlet Red and Sudan Black B were used.

Personal data and descriptions of the gross anatomy of the parietal pleura were obtained from the autopsy records. Measurements of the thickened portions of the pleura were made with an ocular micrometer from histological sections, which in all cases were taken as far as possible perpendicular to the pleural surface. The specimens were taken from the thickest areas of the plaques, as judged by eye. Since this method was obviously not very exact, estimation of the thickest point being difficult at autopsy, the values recorded may in individual cases have differed appreciably from the true values. However, by these measurements the dimensions of the plaque were roughly estimated.

RESULTS

A. Frequency of pleural plaques in autopsy subjects aged 15 years and older

Table 5 shows the frequency of plaques in the area of the parietal pleura in an unselected series of Finnish autopsy subjects aged 15 years and older, collected from three hospital districts (groups 1, 2 and 3, Fig. 1). The total number of cases was 438. In 172 of these

TABLE 5

Cases with pleural plaques among 438 autopsies from three hospital districts in Finland.

	Group 1 (91 autopsies)			Group 2 (255 autopsies)			Group 3 (92 autopsies)		
	No. of cases	Mean age yrs.	%	No. of cases	Mean age yrs.	%	No. of cases	Mean age yrs.	%
Bilateral plaques (without adhesions)	31 (23)	64.2 (64.1)	34.1	76 (38)	58.6 (57.3)	29.8	12 (6)	65.6 (61.2)	13
Unilateral plaques	21	61.4	23.1	57	27.4	10.6	5	67.4	5.4
All plaque cases	52	63.1	57.1	103	58.3	40.4	17	66.1	18.5
No plaque found	39	65.8	42.9	152	59.8	59.6	75	61.1	81.5

ASARCO ELP 0003050

(39.3 per cent), plaques of varying size were observed in either one or both halves of the thoracic cavity.

Since a unilateral fibrotic plaque may result from tuberculosis, empyema or haemothorax, the cases with bilateral plaques were considered separately from the remainder of the material. In the majority of cases showing plaques, the lesions were bilateral. Furthermore, pleural adhesions may be caused by a previous inflammatory process. Hence, Table 5 shows the number of cases with bilateral plaques in which no kind of adhesions was present and the pleural cavity was thus entirely open. Over half the bilateral cases, or 67 out of 119, were of this kind.

The frequency of pleural plaques in the different hospital districts varied. It was lowest in group 3, which comprised autopsy cases from the northwest coast of Finland. In this region the frequency of plaques was lower than in groups 1 and 2. The same result was obtained when only bilateral cases were taken into account. By contrast, the frequency of bilateral plaques was more or less the same in groups 1 and 2. The region of group 2 comprises asbestos deposits and an asbestos mine, whilst neither asbestos deposits nor any particular asbestos industries are situated in the region of group 1. But in this group the majority were urban cases coming from the city of Turku, the centre of the region and the site of a variety of industries, including shipyards.

The sex distribution of pleural plaques is shown in Table 6. Only bilateral cases have been taken into account. The majority of the cases (85 out of 119) were men.

TABLE 6

Sex distribution of 119 subjects with bilateral plaques.

	No. of cases							
	Group 1	(mean age, yrs.)	Group 2	(mean age, yrs.)	Group 3	(mean age, yrs.)	Total	%
Men	21	62.2	52	57.3	12	65.6	85	71.5
Women	10	68.4	24	61.4	—	—	34	28.5
Total	31	64.2	76	58.6	12	65.6	119	100

The effect of the domicile on the occurrence of plaques was analysed in the same way as in the first part of this study in regard to the frequency of asbestos bodies, i.e. by dividing the material into rural and urban cases on the basis of the place indicated in the hospital record as the patient's last domicile. Of the total of 438 cases,

ASARCO ELP 0003051

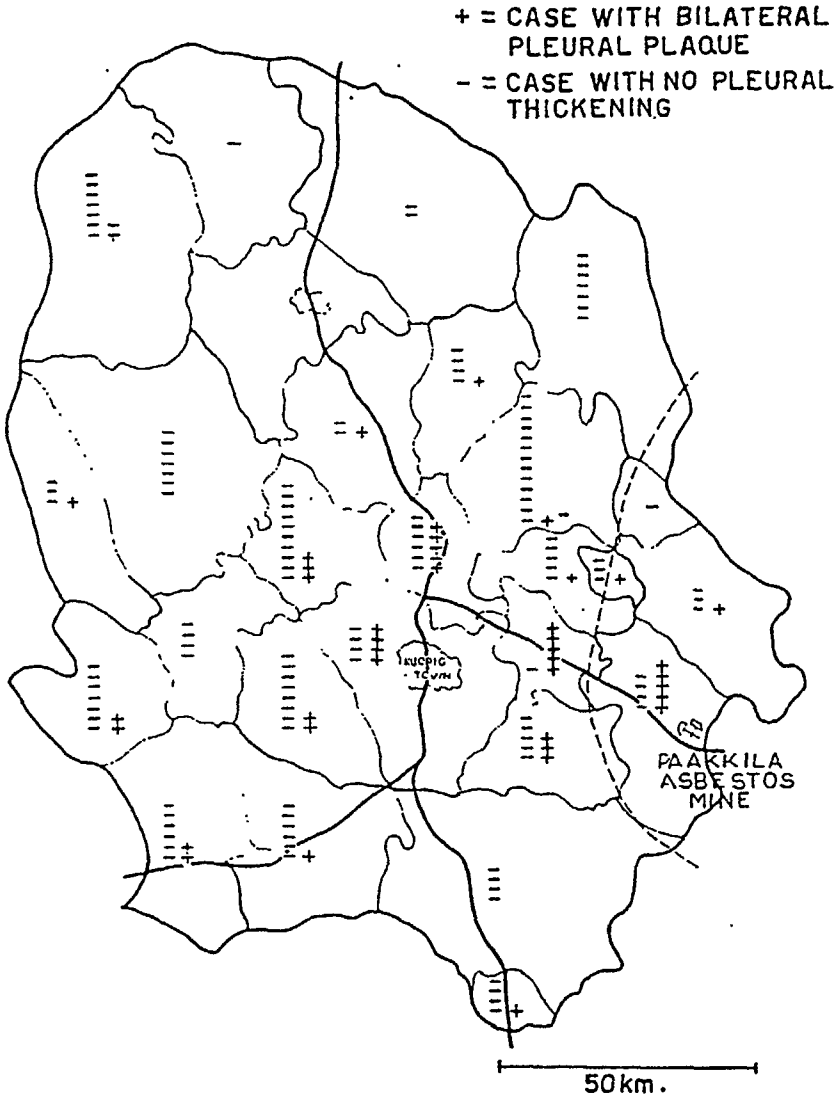

Fig. 13. Map showing the residential distribution of the rural cases with bilateral plaques and cases with no pleural plaque in group 2. The cases are marked in columns in their residential communes. Note the concentration of plaque cases in the communes around the main road between the Paakkila asbestos mine and the town of Kuopio.

ASARCO ELP 0003052

277 were rural. Among these, 88 exhibited either unilateral or bilateral plaques. The frequency of plaques in the rural population was thus 31.8 per cent. The corresponding figures for the urban population were 161 cases in all and 84 exhibiting plaques, which gave a frequency of 52.2 per cent.

In group 2, which comprised cases from the surroundings of the asbestos mine, the various rural communes were compared from the standpoint of the occurrence of bilateral plaque cases and plaque-free cases. The results are as seen on the map in Fig. 13. In only two rural communes were the cases with plaques more numerous than those without. One of these communes is the site of the asbestos mine and mill and the other is the neighbouring commune, through which the main road leads to the town of Kuopio, the centre of this district. The geographical distribution of cases with plaques thus roughly corresponds to the distribution of cases with asbestos bodies (cf. Fig. 3, p. 00).

The age distribution of the cases with pleural plaques is shown in Table 7. Plaques were found in all age groups, but relatively less frequently in those under 30 and over 80 years old. Thus, the situation resembled that seen in regard to the age distribution of asbestos bodies (Table 1).

TABLE 7

Age distribution of the cases with and without plaques in the whole series.

	No. of cases							
	15—19 yrs.	20—29 yrs.	30—39 yrs.	40—49 yrs.	50—59 yrs.	60—69 yrs.	70—79 yrs.	80—90 yrs.
Plaque	1	2	8	13	51	52	40	6
No plaque	6	8	12	22	52	83	60	22
Total	7	10	20	35	103	135	100	28

B. Pathological anatomy of the plaques

As a rule, the plaques observed on the parietal pleura were localized to the area of the seventh to tenth ribs in the posterior portion of the chest (Plate I, a). The thickest plaques, and often the only ones present, were found in this area (Fig. 14). They varied in size from just discernible specks to areas the size of a palm, and sometimes even covered the entire posterior lower portion of the pleura. In more advanced cases the plaques were readily detected,

ASARCO ELP 0003053

PLATE I

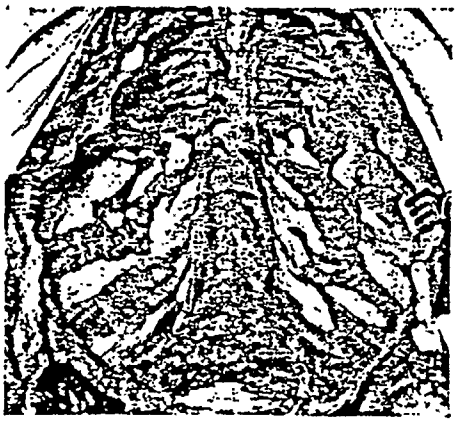

a



b



c

Plate I, a Photograph of an emptied thoracic cavity showing typical bilateral pleural plaques resembling sugar-icing. Notwithstanding a plaque thickness of 3.5 mm, calcification was not dense enough to make the plaques visible on a routine roentgenogram of the chest. Only 2 asbestos bodies were found in the lungs. b Photomicrograph of a typical asbestos body stained for iron. c Two asbestos bodies in lung tissue stained by van Gieson's method.

ASARCO ELP 0003054

being very conspicuous (Figs. 15, 23). They formed a curved slope of patches with irregular outlines, extending medially from the above-mentioned area lateral to the vertebrae and, in the other direction, laterally obliquely upwards in a winding course towards the cartilaginous borders of the second and third ribs. These thickened areas of the pleura were often more or less fused. In bilateral cases the two halves were often mirror images of each other.

The plaques situated at the level of the seventh to tenth ribs in the posterior, lower portion of the thorax were usually irregular in shape, whilst those situated on the lateral wall of the chest were often elongated and narrow. The latter frequently followed the direction of the ribs, although bridges between them and irregular processes extending in various directions occurred in abundance. Their course was not nearly so uniform as that of the strands of fatty tissue often seen on the inner surface of the thoracic cavity, under the pleura (Fig. 14). These strands closely followed the direction of the ribs. In the lateral portions of the chest the plaques were usually situated at the level of the sixth to ninth ribs. Furthermore, plaques were often concentrated in an area in the anterolateral portion of the thorax at the level of the second to fourth ribs, the most typical site being found lateral to the cartilaginous part of the chest. In this area the shape of the plaques was again more bizarre.

On the surface of the diaphragm plaques were found in almost all cases in which such lesions occurred in other sites. Here, too, their localization was very uniform. They were situated on the central tendon, and they seldom extended onto the muscular part of the diaphragm. They were concentrated in the lateral dorsal portion of the tendinous part of the diaphragm, in a site near the border of the muscular part. In advanced cases the plaques on the diaphragm sometimes measured as much as 10 cm in diameter. Here, too, the shape of the plaques was bizarre.

A typical, but less common, location of plaques was the pleural surface of the pericardial sac. In this site they were found on the right side in an area between the atrium and the middle lobe of the right lung, and on the left between the atrium and the mediastinal surface of the upper lobe. Plaques so situated were only encountered in 14 cases, and in 8 of these the lesion was confined to the left side, whilst in the remaining 6 cases it was bilateral. On this parietal pericardial surface of the pleura plaques were observed only in cases also exhibiting them on the other pleural surfaces. It thus seemed that this location of plaques indicated a more advanced stage of plaque formation.

ASARCO ELP 0003055



Fig. 14. The left costal pleura bluntly removed and spread on a flat surface. The costal line is still shown by the strands of fatty tissue following the ribs. The two arrows to the left indicate two thin "beginning?" pleural plaques.

Pleural plaques were never found in the phrenico-costal sinus or below the eleventh rib. They were very seldom seen in the anterior portion of the thorax at the level of the cartilaginous part of the ribs, although in some cases they extended as far as the sternal surface. Paravertebral plaques were usually situated in the lower portion of the thoracic cavity. They were located somewhat higher than the adjacent plaques in the posterior portion, as a rule on the lateral surfaces of the fifth to ninth vertebral bodies.

An interesting observation was that plaque formation seemed to occur in areas of the pleural surface which were free of adhesions. In cases with unilateral total obliteration of the pleural cavity plaques were often encountered in abundance on the other side, which was unfused. If adhesions were present only in part of the cavity, the plaques were concentrated in the free portions. On the other hand, the presence of plaques did not prevent the formation of adhesions, since such lesions were now and then found beneath the adhesions.

ASARCO ELP 0003056

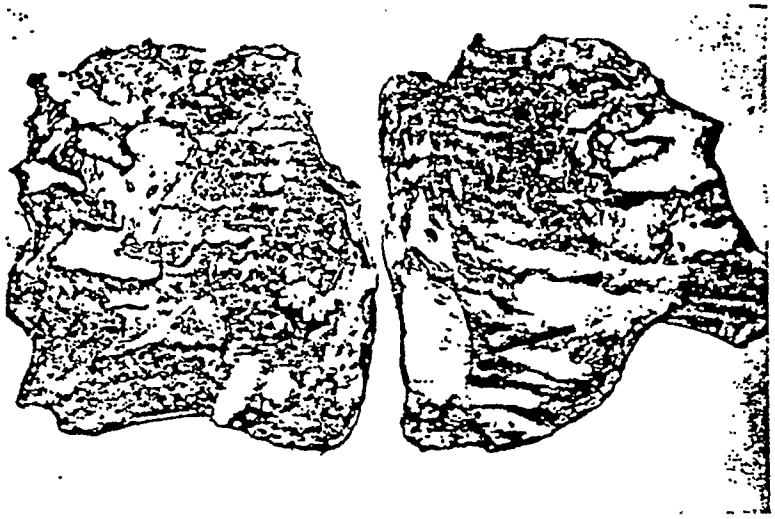

Fig. 15. The costal pleura bluntly dissected from both sides. The plaques stand out clearly and the predilectional locations can be seen. The series of plaques on each side follows a line from the posterior lower area through the lateral middle area to the anterior upper area of the thoracic wall.

The thickest pleural plaques were very typical in appearance. The classic comparison to sugar icing or frosting (Zuckerguss), as is seen on serous membranes, particularly on the coat of the spleen (chronic hyaline-sclerotic perisplenitis), perfectly describes the appearance of the plaques (Fig. 15). Their colour was the white of porcelain or pearls, or sometimes ivory, and they projected more or less abruptly like a plateau above the level of the surrounding reddish, transparent normal pleura. The plaques felt stiff, leathery and firm, but relatively seldom contained any clearly calcified, hard spots. If they did, their consistency was lime-hard and they fractured when bent, whilst they could usually be bent like leather. Plaques which on gross inspection were calcified, were often yellowish grey and transparent, and closely resembled calcified atherosclerotic aortic plaques. As a rule, the surface of the plaques was smooth, but in many cases it was nodular, as if the plaque were packed with split peas (Fig. 25). Sometimes the margins of the lesions were hollowed out from underneath, even so much that the rim bulged into the pleural cavity (Figs. 15, 25). Often pits of various sizes were observed in the otherwise smooth surface of the plaque. Usually the plaque commenced abruptly, like a step, but the thinner plaques sometimes

ASARCO ELP 0003057

arose more gradually, without any sharp demarcation from the normal pleura. From the margins of the lesions streaks often extended radially into the surrounding tissue, as if the plaque contracted the pleura.

The whole costal pleura, including the plaques, was readily removed bluntly from the underlying intercostal muscles and ribs. The plaques situated on the diaphragm could not be peeled off in this way, however, since in this site the pleura is more firmly attached to the structures underneath (*Kivikanervo et al.* 1947). This blunt removal constituted a differential-diagnostic criterion by which plaques could be distinguished from exostotic projections, which sometimes occurred on the pleural surface of the ribs like strings of beads. The latter could not be removed without a sharp chisel.

The pleural plaques were readily distinguished from the subpleural adipose tissue which was light yellow and soft, and closely followed the course of the ribs, bulging into the intercostal spaces (Fig. 14).

The macroscopically calcareous plaques were usually situated in the anterolateral portion of the thorax, at the anterior upper end of the spiral-shaped series of plaques in the region of the cartilaginous border of the second to fourth ribs and lateral to these. The calcium content did not seem to be in any way related to the thickness of the plaques, since in the cases showing calcified plaques there were sometimes equally thick or even thicker and more extensive, but grossly uncalcified plaques observable in the posterior lower portion of the thoracic cavity.

C. Histology of the plaques

The pleural plaques were almost invariably composed, either in part or entirely, of coarse collagenous connective tissue, the fibres of which were arranged upon each other in a flatly undulating fashion in such a way that the top of one wave touched the bottom of the next (Figs. 16 and 17). Sections made perpendicularly to the plate-like plaque thus showed a reticular texture, in which the meshes resembled stretched benzene rings. Obviously the fibres were twisted around each other in the same way as in basket-weave (Fig. 18). The coarse connective tissue in the plaques contained very few fibrocyte nuclei or thin-walled capillaries. The collagen fibres were more strongly refractive than those in ordinary coarse collagenous tissue, in which the wavy fibres follow the same course, like curls.

ASARCO ELP 0003058



Fig. 16. Photomicrograph of the margin of a typical pleural plaque sectioned transversely. Pleural surface in the upper right corner. van Gieson staining. × 45.

Histologically, too, the structure of the connective tissue of the plaques corresponded completely to that of the tissue seen in so-called sugar icing. The latter has often been described as hyaline, although its histological structure is neither homogeneous nor transparent. The same kind of coarse collagenous connective tissue resembling basket-weave also occurs in atherosclerotic plaques. Furthermore, it is found at many other sites, e.g. in the capsules of the nodules in a nodular thyroid gland and occasionally in old scars from myocardial infarctions. In the normal pleural tissue surrounding the plaques this type of collagenous connective tissue did not occur (Figs. 16, 19).

In no case was granulation tissue or fibrinous exudation observed in the plaques or at their margins. Now and then the pleural mesothelial cells were preserved and formed a layer of cuboidal cells which extended from the normal pleura to the surface of the plaque. Usually, however, the layer of mesothelial cells was absent, obviously owing to autolytic disintegration post mortem. At the margins of the plaques, the transition from collagenous basket-weave-like connective tissue to ordinary wavy collagenous tissue was very abrupt. Under the plaques a layer of ordinary collagenous connective tissue was

ASARCO ELP 0003059



Fig. 17. Basket-weave type collagenous connective tissue in pleural plaque. van Gieson staining. × 220.



Fig. 18. Photomicrograph of a pleural plaque sectioned tangentially, showing how the bundles of collagen are arranged irregularly in a trabecular fashion. van Gieson staining. × 110.

ASARCO ELP 0003060



Fig. 19. The margin of a pleural plaque. Note the sharpness of the transition from basket-weave type to the normal curly collagenous fibres of normal pleura. van Gieson staining. × 110.

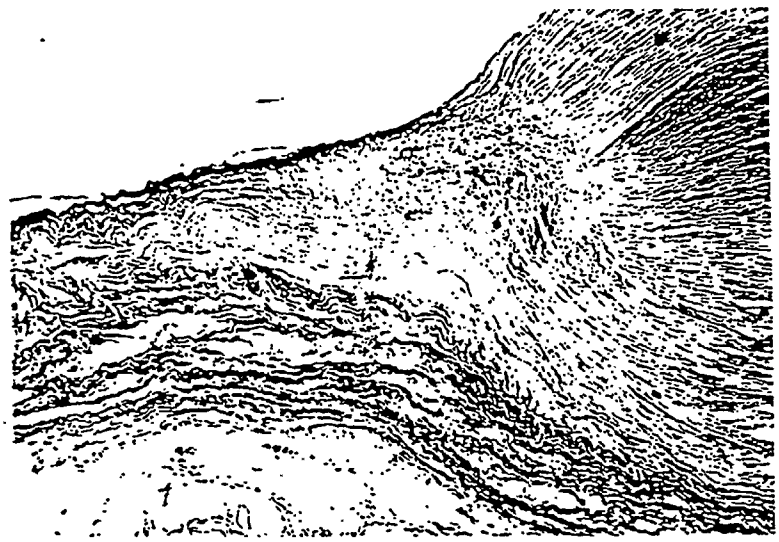

Fig. 20. The margin of a pleural plaque. Note continuation of the normal collagenous and elastic layers below the plaque area. Verhoeff's elastin stain. × 110.

ASARCO ELP 0003061



Fig. 21. Elastic layers below the plaque tissue. Verhoeff's elastin stain. × 220.

found, which appeared to be a continuation of the surrounding pleural connective tissue (Fig. 19).

Deeper beneath the collagenous tissue of the plaques there was usually a layer of adipose tissue, and here and there between this and the collagenous layer dilated capillaries and lymphatics were seen. Round these, small or moderately large aggregations of lymph cells were often encountered, and in some cases plasma cells were also seen. At the margins of the plaques these inflammatory cells seldom occurred in greater abundance.

The plaques seemed always to have developed between the layer of mesothelial cells and the normal collagenous pleural connective tissue. This was most clearly demonstrated by staining for elastic tissue, which showed the elastic lamellae continuing unbroken from the surrounding pleura beneath the plaques. The structure and amount of the elastic lamellae did not seem to change or be in any way affected by the plaques which developed upon them (Figs. 20, 21).

D. Calcium content of the plaques

This part of the study was performed on 75 consecutive cases from group 2 showing typical plaques. Sections from these were

ASARCO ELP 0003062

stained for calcium compounds by van Kossa's technique and with Alizarine Red. A positive reaction was obtained in a total of 65 cases (86.7 per cent).

The degree of calcification showed wide individual variations and it also varied in specimens from different sites in the same case. Sometimes calcium staining was positive only at certain points, but in other cases the plaques seemed to be heavily calcified throughout. According to the theory regarding the pathogenesis of the plaques advanced by *Kiviluoto* (1960), calcification begins in the necrotized internal portion of the plaque. *Kiviluoto* assumed that the plaques develop from a fibrinous exudate formed in response to the scratching of sharp asbestos dust fibres and that this exudate becomes organized and is later condensed into collagenous connective tissue. Dystrophic calcification (*Aschoff* 1923) was assumed to take place as the nutrition of the dense central portion becomes impaired.

In the description of the morphology of the plaques (p. 00), it was already pointed out that the fibrinous exudate and the stage characterized by the presence of granulation tissue, which *Kiviluoto*'s theory presupposes, were not observed in the present material. The plaques seemed to be "primarily chronic", consisting from the outset of collagenous connective tissue resembling basket-weave and showing scanty nuclei. The irregular accumulation of calcium in different layers of the plaques, detected in this part of the present study, is also incompatible with *Kiviluoto*'s theory regarding the pathogenesis.

The calcium compounds occurred as fine granules along the course of the collagen fibres, leaving the optically empty "meshes" in the basket-weave-like connective tissue free. The only regular feature in the location of the calcareous deposits was that they ceased abruptly at the point where the basket-weave-like connective tissue changed into normal pleural tissue (Fig. 22). In the interior of the plaque, calcium compounds were sometimes found in the wavy collagenous connective tissue and not only in the tissue of basket-weave type. Consequently, the deposition of calcium compounds cannot be the cause of the change in structure of the connective tissue into the basket-weave type seen in the plaque. By contrast, it seems possible that this kind of connective tissue — perhaps as a result of poor nutrition — is susceptible to secondary, dystrophic calcification.

Furthermore, in regard to the accumulation of calcium the thought presented itself that it might be comparable with the calcification of the media of the arteries that occurs with advancing age (*Gray et al.* 1953).

ASARCO ELP 0003063



Fig. 22. Calcification of pleural plaque as demonstrated by Alizarine Red staining. The calcium compounds (black in this photomicrograph) are concentrated only in the plaque tissue to the right. × 45.

From the standpoint of this hypothesis the relationship between age and sex on the one hand and the calcium content of the plaques on the other was analysed in cases showing typical bilateral plaques. Since calcium compounds were determined only in a small fraction of the specimen, no definite conclusions can be drawn regarding the calcium content of the whole specimen or the possible absence of calcium in some parts. Thus, the results of this analysis are only tentative.

The mean age of the 75 cases in which this point was studied was 58.6 years. Their age and sex distribution was as follows:

No. of males with plaques showing positive staining for calcium compounds	45,	mean	age	58.0	years
No. of males with plaques not responding to calcium staining	6	„	„	51.3	„
No. of females with plaques showing positive staining for calcium compounds	20	„	„	62.2	„
No. of females with plaques not responding to calcium staining	4	„	„	57.5	„

On the basis of these figures it would seem that calcified plaques occur in elderly people more often than in younger individuals, irrespective of sex.

ASARCO ELP 0003064

E. The roentgenographic calcification of the pleural plaques as compared with the histological findings

Since calcium was often detected in the plaques on histological examination (in 86.7 per cent), although bilateral calcification of the pleura is a rare roentgenographic finding, it was considered of interest to ascertain how often histologically demonstrable calcium was visible on routine roentgenograms of the chest.

Among the 75 autopsy cases of group 2 which were histologically studied for calcium compounds there were 24 with bilateral pleural plaques in which chest roentgenography had been performed during the terminal illness. In only two of these were pleural calcareous deposits visible on the roentgenogram, and even in these only unilaterally and as a relatively weak, irregular patchy shadow. Histologically, a clearly positive calcium reaction was obtained in 20 of these cases. As was to be expected, the histological test for calcium thus proved to be much more sensitive than roentgenographic chest examination. The latter method obviously reveals only the most heavily calcified pleural plaques. This seems to explain the discrepancy between the roentgenographic and anatomical findings.

On comparing previous roentgenographic findings and the present observations on autopsy cases, one is struck by the fact that the roentgenologists have as a rule described calcifications in the middle and lateral fields of the thorax, whilst the pathologists have found these lesions to be concentrated in the posterior lower portions of the chest. This discrepancy may be accounted for by the observation made in the present study that the plaques in the anterior upper portion of the thoracic cavity were more heavily calcified, although equally thick or even thicker plaques were found in the posterior lower portion and on the diaphragm. The phenomenon in question is illustrated by Figs. 23 and 24, which are macroscopic post-mortem roentgenograms of the series of pleural plaques found in one and the same hemithorax. The heavier calcification of the lesions in the anterior upper portion of the chest is clearly discernible. Figs. 25 and 26 show the roentgenological distribution of calcium compounds in a thick, heavily calcified pleural plaque.

The roentgenograms used in the comparison presented above were pictures taken routinely at the hospital, there being no intention of studying the pleura in particular. It is possible that pleural plaques could be better demonstrated by a special technique, in particular by using soft-ray roentgenography. It is obvious, however, that a much higher calcium concentration is required for roentgeno-

ASARCO ELP 0003065



Fig. 23. The left costal pleura removed bluntly and spread on a flat surface. The lower posterior and paravertebral plaques are seen to the left.



Fig. 24. Roentgenogram of the same pleural leaf as in *Fig. 23.* Note the distribution of the calcareous deposits in the plaques. The heaviest calcification is seen in the anterolateral plaques.

ASARCO ELP 0003066

Fig. 26. Roentgenogram of the same plaques as in *Fig. 25.*

Fig. 25. Peculiar, almost pedunculated plaques on the parietal pleura.

ASARCO ELP 0003067

graphic visualization than for histochemical demonstration. By contrast, the thickness of the plaque does not seem to be of any major significance, since in the two cases with roentgenographically demonstrable calcifications the plaque was 1.3 mm in thickness in one case and 3 mm in the other.

It may be mentioned that calcium was not observed on the roentgenogram in a case with pleural plaques measuring 4.5 mm in thickness and with typical plaques on the pericardial surface as well.

No clear correlation was observed between calcium concentration and density of asbestos bodies. Among those 24 cases in which roentgenograms were available, there were 2 with over 10 asbestos bodies in four sections counted (45 in one and 23 in the other), but in neither was calcium demonstrable roentgenographically. Histologically, too, the calcium concentration was low in one and only moderate in the other.

Thus, from both the roentgenographic and the histological results it is evident that the calcification of the pleura does not increase with an increase in the number of asbestos bodies present in the lungs. In order to draw any definite conclusions regarding this point a larger material would be necessary, however.

F. Occurrence of lipids in the plaques

From among the cases in group 2, ten typical specimens of plaques, differing in thickness, were chosen for study of the lipid concentration. A total of six plaques showed varying, but small amounts of lipids at some sites. A positive result was obtained with Scarlet Red in four cases and with Sudan Black B in two additional cases. Lipids occurred as finely granular drops on the surface of the fibres of collagen and possibly also inside them, but not between them, in the meshes of the basket-weave-like tissue. Doubly refractive lipids were not observed.

G. Asbestos bodies in the parietal pleura

In not a single case were asbestos bodies found in the parietal pleura either in the plaques or in the normal tissue. All cases were scanned for asbestos bodies using van Gieson staining, and in ten cases the results were checked by staining for iron. Furthermore, the plaque tissue was examined in polarized light but no asbestos fibres were detected.

ASARCO ELP 0003068

H. Relationship between pleural plaques and asbestos bodies in the lungs

The question of whether any relationship exists between the occurrence of pleural plaques and of asbestos bodies in the lungs was analysed on the basis of those 229 cases of groups 1 and 2 in which the asbestos bodies had been counted. In group 3, lung specimens were available in only half the cases, and these were therefore omitted from the analysis. The results are shown in Table 8. All cases with plaques were included, irrespective of whether the lesion was unilateral or bilateral. The two groups together contained 124 cases with plaques. In 98 of these (79 per cent) asbestos bodies were present in the lungs in varying numbers.

TABLE 8

All cases with plaques in groups 1 and 2 in which asbestos bodies were counted.

	No. of cases					
	Group 1			Group 2		
	Asbestos bodies			Asbestos bodies		
	present	absent	total	present	absent	total
Pleural plaques	38	11	49	60	15	75
No plaque	13	22	35	27	43	70
Total	51	33	84	87	58	145

When groups 1 and 2 were combined, the difference between the number of cases in which asbestos bodies in the lungs were associated with plaques on the parietal pleura and the cases with no such association was very highly significant ($\chi^2=39.5$. D. of F=1. $P<0.001$).

The probability of the following four possible combinations was calculated by the χ^2 test:

1) Asbestos bodies in the lungs and plaques on the parietal pleura.

2) Asbestos bodies in the lungs and no plaques on the parietal pleura.

3) No asbestos bodies in the lungs and plaques on the parietal pleura.

4) No asbestos bodies in the lungs and no plaques on the parietal pleura.

It was found to be very highly significantly more probable that asbestos bodies in the lungs occur in conjunction with plaques on the

ASARCO ELP 0003069

parietal pleura than that asbestos bodies and plaques occur separately ($\chi^2 = 39.5$; $p < 0.001$).

However, as appears in Table 8, asbestos bodies were also a frequent finding in cases with no pleural plaques, being encountered in 38 per cent. This is understandable, considering that asbestos bodies were found in small numbers, at least, in about 60 per cent of subjects aged 15 years and older, as was shown in Part I, whilst plaques occurred in only about 40 per cent. The occurrence of asbestos bodies in the lungs does not, therefore, necessarily mean that plaques are present in the parietal pleura.

On the other hand, it is also seen from Table 8 that no asbestos bodies were found in the lungs in 26.5 per cent of the cases showing plaques. Consequently, pleural plaques are not confined to subjects with asbestos bodies in the lungs.

Since bilateral plaques have been regarded as typical of asbestosis or talcosis, the bilateral cases were analysed separately (Table 9). Their total number was 84. In 72 of these (85.7 per cent), asbestos bodies were found in the lungs.

TABLE 9

Cases with bilateral plaques in groups 1 and 2.

	Group 1			Group 2			Groups 1 and 2	
	no. of cases	%	mean age yrs.	no. of cases	%	mean age yrs.	no. of cases	%
Asbestos bodies	24	85,7	64.5	48	85.7	58.0	72	85.7
No asbestos bodies	4	14.3	58.2	8	14.3	60.2	12	14.3
Total	28	100	63.6	56	100	58.3	84	100

Furthermore, the present results were analysed from the standpoint of the number of asbestos bodies found in the lungs in the individual cases. Pleural plaques were found to be present in all but one of the 17 cases in which ten or more asbestos bodies were detected (cf. Table 3), the exception being a case which exhibited total obliteration of the pleural cavity. From this the conculsion may be drawn that when the lungs contain asbestos bodies in exceptional numbers, pleural plaques will mostly be found in the parietal pleura. This, in turn, supports the view that in the majority of cases showing pleural plaques there is a causative factor that is somehow or other related to the presence of asbestos bodies.

ASARCO ELP 0003070

I. Thickness of the pleural plaques

In all the cases with bilateral plaques, the thickness of the latter was measured at the point estimated to be thickest. The results varied from 0.2 to 7 mm. The mean thickness in the different groups was as follows:

Group 1	2.0 mm	(range	0.5—7.0 mm),	no. of	cases:	29
Group 2	2.4 „	(„	0.2—7.0 „),	„	„	„ :	76
Group 3	2.2 „	(„	1.0—5.0 „),	„	„	„ :	12

There were no clear differences between the various groups in regard to thickness of the plaques.

An attempt was made to investigate whether any correlation could be demonstrated between the thickness of the pleural plaques and the number of asbestos bodies in the lungs, but owing to the wide individual variations in the number of asbestos bodies, the material was not suitable for statistical analysis of this point.

The observations made, however, did not indicate that the thickness of the plaques bore any relationship to the number of asbestos bodies in the lungs.

J. Changes in the visceral pleura and their relationship to the occurrence of asbestos bodies in the lungs

In group 2, in which the autopsies were performed by myself, special attention was paid to the possible occurrence of changes in the lungs and their surfaces, in particular, of the kind encountered in asbestosis. Diffuse fibrotic thickening of the visceral pleura was not observed in a single case. Nonetheless, in some cases in which the parietal pleura exhibited typical and relatively thick pleural plaques, there were dispersed, greyish-red fibrous processes on the surface of the lungs resembling thin, broken fibrotic adhesions. When the lungs were very cautiously removed, it was found that these processes were not attached to the parietal pleura. They were to be encountered anywhere on the surface of the lungs, except on the interlobar surfaces. In regard to location they did not correspond to the plaques on the parietal pleura, being particularly frequent and extensive in the corner of the lower lobe which corresponds with the phrenicocostal sinus. Microscopically, they were distinguished as tufted papillary proliferations of the pleural surface, sometimes covered by a well preserved layer of cuboidal mesothelial cells (Fig. 27). As a

ASARCO ELP 0003071

rule, the mesothelial cells only occurred in one layer, but occasional sites showed several layers. The stroma of these papillary formations consisted either of loose connective tissue, showing an abundance of dilated capillaries filled with blood, or of collagenous connective tissue more or less poor in cells. It often contained lymph cells and histiocytes in great numbers. These papillary processes were thus identical with inflammatory papillary hyperplasia of the pleura and other serous membranes.

Furthermore, in some cases with plaques the visceral pleura exhibited small greyish thickened patches. These could be observed on the interlobar surfaces, too. They varied in size from one to 15 mm in diameter, and in shape they were mostly elongated and relatively narrow. On histological examination they were found to consist of collagenous connective tissue, often covered by a layer of cuboidal mesothelial cells. Occasionally this connective tissue was oedematous (Fig. 28), but mostly it was compact. The collagen fibres were not arranged in a basket-weave-like fashion, as was the pattern of the plaques on the parietal pleura. In these patches no calcareous deposits were observed.

In connection with the counting of asbestos bodies in the lungs, special attention was paid to the possible presence of asbestos bodies in the pleural surface. In one case, in which the pleural surface showed papillary hyperplasia as described above, one asbestos body was found projecting from the end of a papillary process into the pleural cavity. In another case (a plumber whose lung sections contained 250 asbestos bodies) some typical, long asbestos bodies were detected outside the elastic lamellae of the lung surface, in the thickened, proliferating portion of the pleura (Fig. 29). In the remainder of the cases the asbestos bodies were always found in the lungs, within the elastic lamellae. In two cases not belonging to the present series, which exhibited typical pleural plaques and tufted processes of the visceral pleura, a large number of sections were made. In both cases typical asbestos bodies were observed. They were situated outside the elastic lamellae, in the areas where the visceral pleura showed proliferation and thickening.

Table 10 is a list of all those cases in group 2 which exhibited thickening or tufted proliferation of the visceral pleura as described above. It may be seen that of a total of 20 cases, 17 showed typical plaques on the parietal pleura and 16 had asbestos bodies in the lungs. Furthermore, a comparison with Table 3 reveals that almost all cases in group 2 in which ten or more asbestos bodies were found in the lungs, belonged to the group exhibiting thickening of the visceral

ASARCO ELP 0003072



Fig. 27. Lung surface showing tufted papillary mesothelial proliferation. van Gieson staining. × 45.



Fig. 28. Visceral pleural thickening consisting of loose oedematous connective tissue. An 18-year-old man from the asbestos mining village (Paakkila). First stage of visceral pleural fibrosis? van Gieson staining. × 45.

ASARCO ELP 0003073



Fig. 29. Lung surface with an asbestos body in loose thickened visceral pleura. The coal pigment (black spots) round the lymph vessels "identifies" the lung tissue. Wicklein-Falkenberg iron staining. × 45.



Fig. 30. Mesothelial papillary proliferation of the visceral pleura resembling so-called benign (inflammatory?) mesothelioma. van Gieson staining. × 500.

ASARCO ELP 0003074

pleura. By contrast, among the cases with plaques on the parietal pleura not showing these changes of the visceral pleura, there were only two with more than ten asbestos bodies (11 in one and 12 in the other).

It thus seems that if tufted proliferation or patchy thickening of the visceral pleura as described in the foregoing are observed in a case, this will most probably also show plaques in the parietal pleura and relatively abundant asbestos bodies in the lungs. Likewise, if asbestos bodies are found in relative abundance, the lesions in question are likely to be found in the visceral pleura. It seems possible, therefore, that in the majority of cases tufted papillary proliferative formations and patchy thickening of the visceral pleura bear a causal relationship to the presence of asbestos bodies in the lungs. Since these changes are regarded as inflammatory, they may, of course, in some cases be due to minor inflammations of the lung. An inflammatory process in the lung may, in turn, result from physical or chemical irritation caused by asbestos dust. Particular attention was paid to these changes of the visceral pleura for two reasons: Firstly, because they were the only, slight lesions encountered in the visceral pleura, even when the parietal pleura exhibited extensive changes in the form of plaques. Secondly, because histologically they resembled so-called benign mesothelioma (Figs. 27, 30) (*Brown et al.* 1951).

K. Relationship between plaques in the parietal pleura and chronic diseases of the lungs or the cardiovascular system

Attention was also paid to the occurrence of diseases of the lungs and of cardiovascular diseases in the cases with plaques, on the one hand, and in the plaque-free cases on the other.

Since plaques were a common finding, being encountered in the present material in 39.3 per cent of subjects aged 15 years and older, it seemed reasonable to look for the cause of the lesion among the most frequent chronic pulmonary and cardiovascular diseases, i.e. pulmonary emphysema, stasis of the lung, chronic heart disease and tuberculosis.

This part of the study was limited to group 2, in which all cases were examined by myself and in which the asbestos bodies in the lung sections were counted.

Pulmonary emphysema was regarded as established if microscopic examination of the lungs revealed some degree of this condition, irrespective of whether it was mentioned in the autopsy record. This criterion was chosen for the reason that macroscopic evaluation of

ASARCO ELP 0003075

TABLE 10

Cases showing thickening or mesothelial proliferation of the visceral pleura (group 2).

Autopsy no.	Plaque		Thickness of plaque mm	Number of asbestos bodies	Age years	Sex	Domicile		Occupation	Visceral pleura	
	bi-lateral	uni-lateral				m=male f=female	urban	rural		thick-ened	pa-pillary
6—63	+		4	43	51	m	+		Storeman in an iron-mongery		+
32—63	+		5	50	60	m	+		Demolisher of engine insulations, moulder of white metal		+
132—63	+		3.5	4	72	m		+	Farmer	+	
58—63	+		1.2	3	46	m	+		Colonel		+
75—63		+	1.3	50	68	m	+		Unskilled worker	+	
99—63		+	3	10	68	f	+		Forestry technician's wife	+	
114—63	+		4.5	40	45	m	+		Welder	+	
143—63	+		5	8	84	m	+		Property-owner	+	
144—63	+		2.5	7	51	m		+	Farmer		+
153—63	+		2.5	40	57	m		+	Builder's worker		+
157—63	+		4.5	3	53	m	+		Storeman	+	
4206—63	+		3.5	1	77	m	+		Farmhand	+	
6—64	+		3.3	18	50	f		+	Sempstress		
66—64	+		3	23	61	m	+		Engineer	+	
73—64	+		4	8	53	m		+	Farmer		+
94—64	+		0.9	—	69	m		+	Farmer	+*	
105—64	+		2.3	11	18	m		+	Lorry-driver's assistant		+
31—64			—	—	71	m	+		Precentor	+**	
127—63			—	—	65	m		+	Farmer		+
42—63			—	—	61	f		+	Female telephone operator	+***	

*(tuberculous apical scar in lung specimen)
**(bullous emphysema in lung specimen)
***(LED-lung fibrosis)

ASARCO ELP 0003076

emphysema may be difficult owing to the presence of marked terminal pulmonary oedema.

Among 77 cases with plaques, emphysema was noted in 30, or 38.9 per cent. Of the remaining 68 cases, which were plaque-free, 25, or 36.8 per cent, showed emphysema.

Consequently emphysema could not be regarded as a plaque-promoting factor.

The criteria used for pulmonary stasis were that hyperaemia and the presence of haemosiderin pigment in the alveolar phagocytes were detected on microscopic examination of the lungs and that changes were observed in the heart which might have caused a circulatory disturbance. Haemosiderin was demonstrated by the Prussian blue reaction.

Stasis was observed in a total of 46 cases, i.e. in 26 cases out of 77 with plaques, or 35.1 per cent, and in 20 plaque-free cases out of 68, or 29.4 per cent.

Thus, stasis did not seem to be in any way correlated with plaque formation.

Heart disease is in this connection used to denote cardiac infarction and its sequelae. Furthermore, even though no cardiac insufficiency had been observed clinically, hypertrophy of the heart was included in the group if the enlargement was out of proportion to body weight. If the wall thickness of the right ventricle exceeded 5 mm and the left ventricle was normal, the case was counted among those with heart disease. In addition, valvular lesions, fibrosis of the myocardium of unknown origin and aortic aneurysms were included if they were associated with cardiac insufficiency.

As evaluated on this basis, 80 cases exhibited heart disease. The distribution was as follows: Among the 77 cases with plaques, there were 45 with heart disease, or 58.4 per cent. The 68 plaque-free cases included 35, or 51.5 per cent, with heart disease. Although the former group showed a somewhat higher frequency of heart disease, the difference was insignificant.

As tuberculous cases all those were regarded in which recent or old tuberculous changes in the lungs, tracheobronchial lymph nodes or any other organs, e.g. the kidneys, were mentioned in the autopsy record or revealed by the histopathological examination.

On this basis a total of 40 cases of tuberculosis were found. Among the 77 cases with plaques, 23, or 29.9 per cent, had recent or latent tuberculosis. Of the 68 plaque-free cases 17, or 25.0 per cent, were tuberculous. Consequently, tuberculosis did not influence the formation of plaques.

ASARCO ELP 0003077

This analysis of the relationship between the occurrence of pulmonary and cardiovascular diseases and the presence of pleural plaques clearly shows that the former cannot be regarded as a factor influencing the formation of plaques.

In this connection it may be mentioned that the distribution of lung cancer between the cases with and without plaques in group 2 was also studied. Primary carcinoma of the lung was present in seven cases. Of these, three showed plaques and four were plaque-free. The cases with plaques were all unilateral. Asbestos bodies were found in small numbers in three cancer cases and not at all in four. The material is too small, however, to allow of any conclusions in regard to either the relationship between plaques and carcinoma or the relationship between asbestos bodies and carcinoma.

L. Comparison of plaque formation in the pleura and in the peritoneum and pericardium

It was considered of interest to investigate whether the formation of pleural plaques is an isolated phenomenon, involving only the pleura, or an expression of a general "fibroplastic diathesis" of the serous membranes. In group 2, examined by myself, the cases showing plaque-like lesions of the peritoneum and pericardium as well were studied from this standpoint. In the peritoneum, typical thickened patches of "sugar icing" type, resembling the pleural plaques, were found in five cases. These changes were localized to the capsule of the spleen. They were relatively small, mostly the size of a nail. In two cases the plaques were numerous and in the remaining three cases there was only one. Histologically, they corresponded completely to the plaques encountered in the pleura. In two cases the lesions were found at the site of a post-infarction scar and in a third case, too, the plaque was situated on the surface of a necrotized area of the spleen. In the remaining two cases no lesions of the parenchyma were observed under the plaques, which measured 1—2 cm in diameter. In these cases plaques were also detected in the pleural cavity. In the remaining three cases showing plaques on the spleen, no plaque formations were found on the pleura.

The surface of the heart relatively often showed thin fibrous patches which rose gradually, without any clear line of demarcation, over the surrounding tissue and contained no basket-weave-like connective tissue. No other kind of thickening was encountered in the pericardium. On the pleural surface of the parietal pericardium

ASARCO ELP 0003078

plaque formations were observed in 14 cases, as previously described (p. 00).

On the basis of these findings it may be stated that pleural plaque formation does not in general seem to be associated with similar changes in the peritoneum or pericardium. This, in turn, seems to indicate that thickening of the pleura in the form of plaques is not an expression of a general fibroplastic diathesis of the serous membranes but is an isolated phenomenon, usually involving only the parietal pleura.

M. Pleural plaques in domestic animals

In 300—400 carcases of cattle from the asbestos mining commune (Tuusniemi), which the veterinarian in charge (*O.-M. Heikinheimo*) had inspected during the last two years, pleural plaque-like changes had not been observed on the inner surface of the thorax in a single case. The number of pig carcases inspected during the same period was about 600, and in these the finding was likewise negative. The age of the cows at the time of slaughter was estimated at about six to ten years.

SUMMARY OF THE RESULTS

Pleural plaques.

1) Thickening of the parietal pleura in the form of plaques was a very common finding in the present series of Finnish autopsy subjects aged 15 years and older. The frequency was 39.3 per cent. In about 70 per cent of cases of plaques, the lesion was bilateral.

2) Age did not seem to influence the occurrence of plaques to any appreciable degree, although their frequency was lower in the oldest and youngest age groups than in the groups between. The youngest case showing plaques was a lorry-driver's assistant aged 18, who had lived in the asbestos mining commune. In this case one of the plaques measured 2.3 mm at the thickest point.

Bilateral plaques were clearly more frequent among the male subjects than among the female ones. Of the bilateral cases in the present series 72 per cent were men.

3) The frequency of cases with plaques was about the same in two of the three hospital districts investigated in different parts of

ASARCO ELP 0003079

Finland, whilst in the third it was lower. Plaques proved to be an equally common finding in a district in southwest Finland with no asbestos deposits and no particular asbestos industries, as in a district in east Finland with an asbestos mine and mill and extensive anthophyllite asbestos deposits near its eastern border. Plaques were encountered in 52.2 per cent of the urban population and in 31.8 per cent of the rural population.

Bilateral pleural plaque cases were more frequent than plaque-free cases only in the asbestos mining commune and its neighbouring commune, which is traversed by the main road to the nearest city.

4) Plaques were regularly encountered in the same areas of the chest. The areas of predilection were 1) the central tendon of the diaphragm, 2) the posterior lower portion and the paravertebral surface of the costal pleura, 3) the middle portion of the lateral surface of the costal pleura and 4) the upper anterolateral surface of the costal pleura. Plaques were more seldom found on the pleural surface of the pericardium. They were never detected in the area opposite to the apices of the lungs or in the phrenico-costal sinus, lower than the eleventh rib. Plaque formation was not found to affect the corners of the chest. Of the cases with plaques, more than half showed no adhesions, and when these were present, the plaques were situated in areas free from them.

5) The plaques were irregular in shape and varied in size. The mean thickness of the plaques in the present material, as measured at the thickest point, was 2—2.4 mm in the various groups, the range being 0.2—7.0 mm. They were clearly, and as a rule abruptly, elevated above the level of the surrounding tissue like a plateau. Their surface was shiny, smooth or nodular, and their colour was a porcelaneous or pearly white, or sometimes ivory. The consistency was leathery or, if the calcium concentration was high, hard as lime. They could readily be removed entire from the inner surface of the thoracic cavity, together with the normal pleura. The plaques were found to be formations of the same kind as has been described in the literature as "Zuckerguss" or "sugar icing".

The plaques consisted of rough collagenous connective tissue in which the fibres were arranged in wavy layers resembling basket-weave. This tissue was poor in nuclei and blood vessels. Plaques seemed to develop between the layer of mesothelial cells and the elastic lamellae of the pleura, obviously in such a way as to cover the original pleural connective tissue. Plaque formation was not associated with inflammatory reactions and the lesion appeared to be "primarily chronic" in nature.

ASARCO ELP 0003080

As a rule, the plaques contained calcium, but the concentration and distribution of the latter in different parts of the lesion were irregular. The accumulation of calcium seemed to be a secondary phenomenon dependent on age.

Although calcified plaques of the parietal pleura were often observed on gross autopsy inspection, they were seldom seen on routine roentgenograms of the chest, obviously owing to the mostly low calcium content of the plaques.

Relationship between asbestos bodies and pleural plaques.

1) Asbestos bodies could not be detected in the plaques.

2) As a rule, there was a positive correlation between the occurrence of asbestos bodies in the lungs and of pleural plaques, although many exceptions were found. Among the cases with bilateral plaques, 85.7 per cent exhibited asbestos bodies in the lungs. On the other hand, asbestos bodies in the lungs were a more frequent finding than plaques in the pleura. About 40 per cent of the cases showing asbestos bodies in the lungs were free from pleural plaques. When asbestos bodies were found in the lungs in relative abundance, plaques were regularly present in the pleura. In the majority of cases the development of plaques on the parietal pleura and the occurrence of asbestos bodies in the lungs seemed to have some aetiological factor in common. It seemed, however, that not even bilateral plaques invariably signified the presence of asbestos bodies in the lungs.

In a few cases asbestos bodies were found in the visceral pleura, outside the elastic lamellae of the lung. At these sites in the pleura tufted papillary mesothelial proliferation occurred. In cases with exceptionally large numbers of asbestos bodies in the lungs, small fibrotic thickened areas or mesothelial proliferation as just described were particularly often encountered. The location of these lesions did not correspond to the sites of plaques in the parietal pleura.

Not a single case in the present series showed diffuse fibrosis in such a degree as is typical of asbestosis.

Relationship between pleural plaques and diseases of the lungs and the cardiovascular system.

No correlation was observed between the frequency of plaques and the occurrence of the commonest chronic diseases of the lungs or heart.

ASARCO ELP 0003081

Relationship between pleural plaques and similar lesions in the other serous cavities.

In the cases with pleural plaques similar lesions were usually not present on the peritoneum.

Occurrence of plaques in domestic animals.

Plaque-like pleural changes were not observed in cattle or pigs from the asbestos mining commune.

ASARCO ELP 0003082

DISCUSSION

As was already mentioned in the Introduction, the main objective of the present study was to clarify the possible causal relationship between exposure to asbestos dust and the occurrence of parietal pleural plaques. The question was approached from the standpoint of pathological anatomy, i.e. by investigating the frequency of asbestos bodies in the lungs and of plaques on the parietal pleura and by analysing the relationship between these two parameters. In the present series of autopsy cases the frequency of asbestos bodies was 57.6 per cent. This figure is considerably higher than the values reported from other parts of the world, which is particularly noteworthy considering that the Finnish series comprises both rural and urban cases. The investigations published by other authors have mainly been performed on urban populations from big, densely inhabited cities with numerous factories. In Cape Town, for instance, there are seven firms dealing with asbestos (*Sleggs et al.* 1961). Nonetheless, asbestos bodies were encountered in only 26.4 per cent of subjects aged 15 years and older (*Thomson et al.* 1963). Furthermore, it should be recalled that the most extensive asbestos deposits are situated in South Africa (*Sleggs et al.* 1961). In Pittsburgh, USA, a frequency of asbestos bodies of 41 per cent was noted (*Cauna et al.* 1965). In Belfast, Northern Ireland, the frequency of asbestos bodies among men aged 50—69 years was 14—27 per cent (*Elmes et al.* 1965). From Miami, USA, *Thomson et al.* (1964) reported a frequency figure of 27.2 per cent.

The discrepancies between the results obtained seem to be attributable in part, at least, to differences in method. In the present study thick lung sections, stained for iron (the Prussian blue reaction), were used. That this technique greatly facilitates the detection of asbestos bodies (see Plate I, b, c) is borne home by the results of *Cauna et al.* (1965). When these investigators counted asbestos bodies from lung smears they arrived at a frequency of 41 per cent, whilst the result was only 4 per cent when the same series was studied on the basis of histological sections without any special

ASARCO ELP 0003083

staining. When asbestos bodies are scanty, it may be difficult to recognize them in sections stained with haematoxylin and eosin or van Gieson. Moreover they are often masked by coal pigment. With iron staining the asbestos bodies are clearly visualized owing to the richness of iron compounds in their coating. It seems obvious that asbestos bodies may be more accurately counted from histological sections than from smears, since both the free bodies and the bodies enclosed in the connective tissue are included in sections, whilst it is only the intra-alveolar asbestos bodies that can be expected to be squeezed out with the fluid to be smeared.

When the present Finnish series of autopsy cases was analysed in detail, the frequency of cases with asbestos bodies in the lungs was found to be much lower in the rural population than in the urban population. Nonetheless, small numbers of asbestos bodies were observed in about half the rural cases, too.

When an attempt is made to explain the frequent occurrence of asbestos bodies among the rural population, the question presents itself of whether atmospheric pollution is so heavy that asbestos fibres are borne with the wind over the Finnish countryside, hundreds of kilometres from towns and asbestos mines. According to *Laamanen et al.* (1964), asbestos dust has been recovered from the air at a distance of 27 km from the Paakkila asbestos mine, although in very small amounts and mainly in the form of short fibres. Nonetheless, it seems unlikely that asbestos dust enters the lungs as a result of general atmospheric pollution for the reason, among other things, that if this were true, the dust ought to be encountered in about equal amounts in all subjects of the same age and show a steady increase with advancing age. Since asbestos is very insoluble — amphibole asbestos, which is the group to which the Finnish anthophyllite asbestos belongs, hardly dissolves at all (*Beger* 1933, *Sundius et al.* 1938, *König* 1960, *Thomson et al.* 1963) — it seems more probable that asbestos dust (or some other dust consisting of relatively insoluble fibres) enters the lungs as a result of occasional exposure at some period in life. The use of asbestos is so common today that practically everybody runs the risk of inhaling asbestos dust both in the home and at the place of work (*Thomson et al.* 1963).

In most cases in which asbestos bodies were found in somewhat greater abundance, it seemed probable that some kind of occupational exposure to asbestos dust had occurred. Such a record was obvious in at least 11 of those 17 cases in which over ten asbestos bodies were detected.

As compared with the content of asbestos bodies in the lungs in

ASARCO ELP 0003084

a typical case of asbestosis, however, the numbers observed in the individual cases in the present series were very small. According to *Beger* (1933), in typical asbestosis the number of asbestos bodies per sq. cm of lung field is about 8000. In the present study the majority of cases exhibited a total of one to four asbestos bodies in all four sections studied, and the sections were estimated to measure an average of one sq. cm. This would, then, mean only about 1/32,000—1/8,000 of the number of asbestos bodies in true asbestosis. It is thus understandable that none of the present cases exhibited any of the histological changes typical of asbestosis.

Thomson et al. (1963) found that among the inhabitants of Cape Town the frequency of asbestos bodies in the lungs rose with increasing age. However, the frequency curve showed an unexplained drop in the age group 45—54 years. To some degree the same phenomenon was observed in the present study for the age group 46—55 years. The present results differ from those of *Thomson et al.* in that a decrease in the proportion of positive cases was again noted in the oldest age groups. This is in agreement with *Gloyne*'s (1951) observation that in long-standing cases of asbestosis the number of asbestos bodies in the lungs tended to be smaller than in recent cases. One can only speculate whether this means that asbestos does eventually dissolve.

According to *Thomson et al.* (1963), the women in Cape Town had asbestos bodies in the lungs decidedly less frequently than the men. In my Finnish series no clear difference was observed in this respect, but the number of asbestos bodies in the individual cases was obviously higher among the men. This finding seems to be due to more frequent occupational exposure to asbestos dust among the men.

The question of whether asbestos dust is inhaled in larger amounts by the inhabitants of the immediate surroundings of an asbestos mine than by the rural population in general could not be settled on the basis of the present material owing to the great individual variation in the density of asbestos bodies. However, the fact that asbestos bodies were found in the lungs of almost all subjects from the asbestos mining commune investigated may, perhaps, be interpreted as evidence of general atmospheric pollution with asbestos dust in the immediate surroundings of the asbestos mine.

It was not within the scope of the present study to determine whether the central fibre in the asbestos bodies belonged to the asbestos group of minerals or whether some other, poorly soluble particle (pseudo-asbestos body) was involved. Since only morphological criteria were used, it is possible that is was not always

ASARCO ELP 0003085

asbestos that the core of the bodies was composed of. At all events the *Working Group on Asbestos and Cancer* (1965), a subcommittee of the *International Union Against Cancer*, has expressed the view that in practice, little difficulty is found in distinguishing the genuine form from pseudo-asbestos bodies. "The other types usually have a carbon black center, a shape which is other than linear, but the body that can mimic an asbestos body completely is the small one found in talcosis, which may be tremolite, a form of asbestos." Although tremolite talc fibres resemble the minerals of the asbestos group in regard to both chemical and physical structure, the central core cannot have been tremolite talc, since the dust particles of this mineral do not exceed 20 μ (*Siegal et al.* 1943), and only bodies with a minimum length of 20 μ were accepted as asbestos bodies in the present study. This fact is worth mention because a tremolite talc mine is in use near the eastern border of the region where the subjects of group 2 had lived (Maljasalmi, in the commune of Kuusjärvi). Nonetheless, neither talc granulomas nor talc fibres were observed in a single case in my series.

Roentgenographically discernible, calcified pleural plaques occurring symmetrically and bilaterally have been regarded as an effect of exposure to talc dust (*Siegal et al.* 1943) or asbestos dust (*Jacob et al.* 1955, *Frost et al.* 1956). When *Kiviluoto* (1960) detected similar calcifications in the inhabitants of the surroundings of two Finnish asbestos mines, he introduced the concept of endemic non-occupational asbestosis. The most significant feature of this condition, in his view, was the occurrence of bilateral calcified pleural plaques, whilst pulmonary fibrosis was considered to be slight or absent. In regard to the pathogenesis of the plaques, *Kiviluoto* advanced the theory that the sharp points of asbestos fibres or of spicules resembling them protrude through the visceral pleura into the pleural cavity. When on respiration the parietal pleura and the lung surface rub against each other, the points of the fibres scratch the parietal pleura. A slight but continuous fibrinous exudation results, which is gradually organized and a fibrous plaque develops. Finally, the centre of the plaque is calcified owing to nutritional causes.

When *Siegal et al.* (1943) described so-called talc plaques, they brought forward the hypothesis that talc fibres cause multiple minor haemorrhages in the lungs and pleural surface, with calcification resulting in the same way as in haemothorax, which is a recognized cause of pleural calcification (*Lauche* 1928, *Zuppiger* 1952). According to this theory, mechanical factors in conjunction with

ASARCO ELP 0003086

haemorrhages (perhaps chemical factors?) are thus responsible for the calcification of the pleura.

Less precise theories concerning the cause of bilateral pleural calcification have also been advanced. *Stephanopoulos* (1962), for instance, suggested that an intervention of some organic factor might be involved, perhaps in the form of a disturbance of the acid-base balance in the pleura or as an expression of an individual idiosyncrasy. *Claus* (1962), too, seems to believe that the individual reactive pattern plays a part. He pointed out that the serous membranes of certain individuals obviously respond by fibrosis to various stimulations (noxa).

Smith (1952) brought forward the theory that plaques may be caused by disturbances in the magnesium and calcium balance, and emphasized that both these minerals are present in tremolite talc. He suggested that the chemical composition of certain dusts may in some specific way stimulate the mechanism of calcium deposition.

According to *Fehre* (1956), plaques obviously result from the aspiration of silicate dust, although the latter probably acts in conjunction with some other noxa.

Brosig (1939) described a case with typical pleural plaques in which there was no history of exposure to dust. In regard to the developmental mechanism he adopted a view corresponding with *Lubarsch*'s (1927) theory concerning the formation of "sugar icing" (Zuckerguss) on the capsule of the spleen. The latter author regarded the plaques as comparable with the so-called soldier's spots or milk spots commonly found on the visceral surface of the pericardium, in particular. According to *Mönckeberg* (1924), these milk spots may result from pressure and friction. The above-mentioned authors did not believe that inflammatory changes were involved in plaque formation, at least not invariably, since blood pigment, round cells and granulation tissue are not observed in the lesions in question. Furthermore, they considered the plaques to be "primarily chronic" in nature, without any intermediate stages, which also argues against an inflammatory aetiology. So far no convincing evidence has been advanced in support of any theory of the pathogenesis of plaque formation.

A typical feature of plaque formation as it appeared in my material was the regular location of the lesions in certain sites in the thoracic cavity, whilst other sites were always free from them. If the thoracic cavity is likened to a cone, it appeared that plaques did not develop at its apex or angles. That the lesions thus "avoided" certain sites may, perhaps, be interpreted as evidence that mechanical

ASARCO ELP 0003087

factors are involved. The possibility that some part is played by the varying pressure and stretching to which the pleura is subjected on respiration seems to be a reasonable hypothesis. If stretching occurs in a cone-shaped structure with elastic walls, the effect will be greatest in those parts which are farthest from the apex. The regular avoidance of the corners in the location of the plaques fits in with this hypothesis.

Stretching and variations in pressure cannot, however, be regarded as the only cause of plaque formation, since plaques are not found in all individuals. Long-standing, severe inflammations such as empyema and tuberculosis often lead to thickening and calcification of the pleura *(Lauche* 1928, *Heymer* 1950, *Boyd* 1953), but then the process is usually unilateral and the pleural leaves become fused. Therefore, such an inflammation cannot well be considered to be a contributory factor. By contrast, in seeking for other possible, milder inflammation-promoting factors asbestiform dust suggests itself. If sharp asbestiform fibres cause persistent slight exudation and multiple minute haemorrhages in the lungs, the exudate will leak into the pleural space where resorption will take place mainly through the parietal pleura *(Brock et al.* 1931, *Loeschcke* 1934). In this way asbestos dust can be assumed to cause slight persistent occult haemothorax. As already mentioned, the latter condition is known to cause pleural calcification *(Lauche* 1928, *Zuppiger* 1952).

If the pleural plaques are compared with the connective tissue thickening which occurs in other parts of the body and is characterized by a basket-weave-like arrangement of the lamellae, it is striking that the latter lesions, too, are regularly associated with increased pressure. This is exemplified, for example, by the basket-weave-like collagenous thickening often encountered on the capsules of the degenerated, swollen nodules in an adenomatous goitre and in the scars resulting from cardiac infarction and in part, also, by atherosclerotic plaques. Minute haemorrhages and secondary calcification are typical features of the last-mentioned lesions, too.

On the basis of the present results, the frequency of pleural plaques in the Finnish population was calculated as 39.3 per cent. Morphologically, the plaques did not differ from the fibrotic thickening of serous membranes previously described in the medical literature, e.g. under the name of "sugar icing", German: "Zuckerguss" *(Curschmann* 1884). Such thickening has been reported to occur on the capsule of the spleen and liver and on the pericardium, in particular. Since lesions of this kind have often been found simultaneously on the serous surfaces in several cavities, the name poly-

ASARCO ELP 0003088

serositis chronica fibrosa has been used by some authors *(Gofferjè,* cited by *Borrmann* 1927). Both the pleural plaques in the present material and the above-mentioned "sugar icing" consist of coarse collagenous connective tissue poor in nuclei, which occur as irregular patches of varying size. Other features common to the pleural lesions observed by me and the lesions described by previous authors in other sites are their calcification, their low lipid content and their "primarily chronic" nature. A peculiarity of the pleural plaques is their tendency to occur symmetrically, bilaterally, and regularly in certain sites on the parietal pleura. They do not seem to be associated with systemic polyserositis; the phenomenon is isolated and confined to the pleura. Pleural plaques seem to be of common occurrence, whilst similar plaques on the peritoneum and pericardial surface are relatively infrequent. When sugar icing occurs as polyserositis, lesions may be encountered in the pleural cavity, too, though as a rule to a lesser extent than on the surfaces of the spleen, liver and pericardium, and often the pleura is not affected at all *(Siegert* 1898).

Although, to the best of my knowledge, the occurrence of pleural plaques has not previously been studied systematically either in Finland or elsewhere, this is a phenomenon that has long been well known to Finnish pathologists. In the nineteen-thirties, for instance, such lesions were frequently observed *(Järvi* 1963). In Sweden, too, pathologists and thoracoscopists encounter them now and then *(Tivenius* 1963).

When the geographical distribution of the present pleural plaque material was analysed, it was found that bilateral lesions were equally common in two hospital districts situated far from each other, one in southwest Finland, the other in the eastern part of the country. By contrast, the frequency was markedly lower in the third district studied, which is situated in north Finland. Notwithstanding the fact that the material was collected at autopsies performed by various pathologists, who may have interpreted the criteria differently, the difference in the frequency observed seems to be real for the following reason: If in one group stricter criteria had been used than in the remainder, and only markedly thicker fibrotic pleural patches had been accepted as plaques, the mean thickness of the plaques ought to be higher in this group. This was not the case, however; the mean thickness of the plaques was about the same in all groups. The frequency of asbestos bodies was also somewhat lower in group 3 than in the other two groups.

As mentioned above, in groups 1 and 2 the frequency of bilateral plaques was approximately the same. If asbestos dust is accepted as

ASARCO ELP 0003089

an aetiological agent, exposure to this kind of dust ought to be equally prevalent in the two districts in question. It seems possible that this is true, considering that the district of group 2 comprises an asbestos mine and mill but only a few industries, whilst group 1 was collected from a district without any asbestos mine but comprising numerous industries which are likely to spread asbestos dust.

In the present study the theory of a causal relationship between asbestos dust and plaque formation was, moreover, corroborated by the relatively frequent occurrence of plaques in the communes surrounding the asbestos mine. Cases with bilateral plaques were more numerous than plaque-free cases only in the mining commune and its neighbouring commune. Furthermore, it emerged that pleural plaques occurred more often in men than in women. Almost all subjects in whom asbestos bodies were found in relatively large numbers (ten or more per four lung sections) were males. Further evidence in favour of an asbestos dust aetiology is constituted by the observation that asbestos bodies occurred much more often (the difference being very highly significant) in association with pleural plaques than in plaque-free cases. I also had the opportunity to study autopsy material from the Central Hospital of Tampere, which represents a highly industrialized district. Among 48 consecutive adult uni- or bilateral plaque cases, 36 (85.7 per cent) exhibited asbestos bodies. Thus, the frequency of asbestos bodies in this district, the fourth Finnish hospital district studied, was the same as the frequency in the pooled bilateral plaque cases in the remainder of the material.

The theory that asbestos dust is a cause of pleural plaque formation is supported, moreover, by the fact that in all cases exhibiting asbestos bodies in relative abundance, pleural plaques were present except in one case, in which the pleural cavity was entirely obliterated. Asbestos bodies were, however, never observed in the parietal pleura. Only in a few cases were such bodies found outside of the elastic lamellae of the visceral pleura, which may be taken as evidence in favour of *Kiviluoto's* theory, cited in the foregoing (p. 00), concerning the pathogenesis of pleural plaques. Since lung specimens were not taken from selected sites on the surfaces opposite to those showing plaques, it is impossible to decide whether the few asbestos bodies recovered from the visceral pleura were, perhaps, obtained precisely from these.

The present study revealed no correlation between the common chronic pulmonary or cardiovascular diseases and the occurrence of pleural plaques. In regard to stasis, no such relationship was to be expected, since it is known that even hydrothorax of long standing

ASARCO ELP 0003090

usually heals without any permanent changes *(Bell* 1956, *Giese* 1960). Unfortunately, it was not possible to take into account the commonest, perhaps, of all inflammatory diseases of the lung, i.e. chronic bronchitis, although this condition would seem a likely cause of bilateral plaques owing to its symmetrical involvement and the concomitant cough with resulting marked variations in intrathoracic pressure and tension. Furthermore, it was outside the scope of this study to clarify the content of other particles of dust in the lungs, e.g. silica (SiO_2) and coal. In my material these dusts would probably have been detected in amounts corresponding to the occurrence of asbestos dust, i.e. in the urban population in greater amounts than in the rural population, and more frequently in workers in the machinery and building trades than in farmers. According to *Bohlig et al.* (1960), plaque formation is not, however, a typical feature of silicosis or anthracosis. *Hurwitz* (1961), too, stated that plaques are not encountered in other miners than those exposed to asbestos dust. In the latter, on the other hand, they are strikingly frequent, at least as revealed roentgenologically (*Müller* 1962, *Cartier* 1964).

On the other hand, certain of my observations seem to argue against the hypothesis that asbestos dust is the cause of pleural plaque formation. Asbestos bodies were not found in the lungs in all cases showing plaques, although the number of sections studied was in some cases increased to ten. The plaques covered only part of the parietal pleura and were sharply demarcated, although asbestos dust obviously spreads relatively evenly and diffusely in the interior, at least, of the lungs.

Although on the basis of Finnish roentgenological mass surveys there seems to be a concentration of cases of calcified pleural plaques in the surroundings of the asbestos mine, such plaques are a frequent finding in patho-anatomical studies in general. This, too, might be regarded as evidence against the theory that the plaques have a specific asbestos dust aetiology. In order to account for the discrepancy between the patho-anatomical and roentgenological results, one is forced to look for a possible difference between the plaques encountered in material coming from the vicinity of the asbestos mine and the plaques occurring in the remainder of the population. It was shown in this study that morphologically the former did not differ from the latter. But a difference seems to exist in regard to the degree of calcification, in that the plaques of those living in the vicinity of the asbestos mine are more heavily calcified. *Kiviluoto* (1960) pointed out that calcification is a process requiring a long time. In the surroundings of an asbestos mine, slight exposure to the

ASARCO ELP 0003091

dust begins in early childhood. Hence, it may be assumed that plaque formation, too, begins early in life, and that in the middle-aged the process of calcification has reached a stage when calcareous deposits become visible on the roentgenogram. In the present material this hypothesis is corroborated by the observation that the youngest subject with bilateral plaques — a lorry-driver's assistant aged 18 years — came from the asbestos mining village. He exhibited well developed but moderately calcified bilateral plaques, which were not visible on roentgenograms of the thorax.

The results of the present study seem to indicate that there is a causal relationship between exposure to asbestos dust (or some other fibrous dust capable of producing asbestos bodies) and the formation of bilateral pleural plaques. This relationship need not necessarily be direct, however. It seems possible that the occurrence of asbestos dust in the lungs may be associated with a condition which, in turn, leads to the development of plaques.

Although in my material asbestos bodies were found in the majority of cases in a Finnish routine autopsy series, their scantiness showed that the amount of asbestiform dust inhaled generally is too small to cause pulmonary fibrosis of the degree that is typical of asbestosis, or any other pathological changes. The pleural plaques, too, seem to be of no significance from the standpoint of the health of the individual. The point at issue does not seem to be whether asbestiform dust is present in the lungs but how much of it there is.

It has been alleged that even small amounts of asbestos dust may cause malignant diffuse mesothelioma. If this is true, the development of such malignancy as a result of slight exposure to asbestiform dust seems, in any event, to be a relatively rare phenomenon, since not a single mesothelioma was encountered in the present series.

Whether cancer of the lung occurs more frequently among subjects who inhale asbestos dust in exceptional amounts is a question which requires a much more extensive material for its solution, considering that lung cancer is fortunately a relatively infrequent disease, whilst the occurrence of asbestiform dust in the lungs is common.

ASARCO ELP 0003092

GENERAL SUMMARY

The occurrence of asbestos bodies in the lungs and of fibrotic thickening in the form of plaques on the parietal pleura was investigated in a Finnish routine autopsy series collected from the central hospitals of three different regions. In one of these regions an anthophyllite asbestos mine is situated. The whole material comprised 438 autopsy subjects aged 15 years and older.

In 264 cases asbestos bodies were counted in histological lung sections stained for iron. In 57.6 per cent of these cases asbestos bodies were found in small numbers, as a rule only one to four bodies per four sections. The larger the number of sections examined, the greater was the likelihood of detecting positive cases. Asbestos bodies were more frequent among the urban than among the rural population, and in the latter, they were very highly significantly more abundant among workers handling machines and workers in the building trade than among the farmers. The frequency was not higher among the men than among the women, but in the men asbestos bodies were more numerous. In the various districts studied the frequency was largely the same. In the population of the commune which is the site of the above-mentioned asbestos mine, the frequency of asbestos bodies was very highly significantly higher than in a typical farming commune in the same region. The asbestos bodies were typical in appearance and did not differ from those encountered in occupational asbestosis. Their mean length, too, appeared to be the same.

Among 438 cases, 39.3 per cent showed either unilateral or bilateral thickening of the parietal pleura in the form of plaques. Bilateral lesions were noted in 27.2 per cent. In 56.3 per cent of these the pleural cavity was open. Plaques were observed in 52.2 per cent of the urban population and in 31.8 per cent of the rural population. In the rural districts, cases with bilateral plaques were more frequent than plaque-free cases only in the asbestos mining commune and in one of its neighbouring communes. Plaques were more frequent among the men than among the women. They occurred in all age groups examined, but were less frequent in those under 30 and over

ASARCO ELP 0003093

80 years of age. The youngest subject in whom plaques were observed was an 18-year- old man who had lived in the asbestos-mining village.

Anatomically, the plaque formations resembled sugar icing or frosting (German: Zuckerguss). They were encountered only in the parietal pleura, where they formed sheets varying in size and bizarre in shape and were either smooth or nodose, being then composed of glistening elevations resembling split peas. The borders of these sheets were clearly defined, and they were tough like leather or sometimes lime-hard. Usually plaques occurred on the surface of the tendinous part of the diaphragm or in the lower posterior, middle lateral and upper anterior portions of the thorax, but they were never located in the phrenico-costal sinus or above the second rib. In the most advanced cases plaques were also present on the pleural surface of the pericardial sac, either on the left side only or on both sides.

Histologically, the plaques consisted of rough collagenous connective tissue resembling basket-weave and exhibiting a few nuclei but no necroses. Mostly, calcareous deposits were present in some parts of the lesions. The calcification was secondary. There were no signs of inflammation, and the plaques seemed to be "primarily chronic" in nature. They appeared to have developed between the layer of mesothelial cells and the layer of original pleural collagenous and elastic connective tissue. The thickness of the plaques varied from 0.2—7 mm, the mean in the various groups being 2—2.4 mm as measured at the thickest point. As a rule, the calcium content was too low to be visible on routine roentgenograms.

Asbestos bodies in the lungs and pleural plaques occurred more often in conjunction than separately, the difference being very highly significant. In the cases with bilateral pleural plaques asbestos bodies were present in 85.7 per cent. In those 17 cases in which asbestos bodies were particularly abundant, pleural plaques were found in all except one. In this case the pleural cavity was completely obliterated.

The most common chronic cardiovascular and lung diseases occurred equally often in cases showing plaques as in cases without them. The relationship between the occurrence of plaques and the possible presence of other dusts in the lungs, e.g. silica and coal dust, was not analysed.

The present results seem to indicate that pleural plaque formation, in particular when it is bilateral, and the occurrence of asbestos bodies in the lungs have some aetiological factor in common. The dust which induces the formation of asbestos bodies does not, however, seem to be the sole cause of plaque formation.

ASARCO ELP 0003094

Diffuse interstitial fibrosis of the lungs of a clearly pathological degree was not observed in a single case, but in the cases exhibiting asbestos bodies in relatively great numbers, the visceral pleura often showed patchy fibrosis or tufted mesothelial proliferation, resembling microscopically benign (inflammatory?) mesothelioma. Asbestos bodies were seldom encountered in the visceral pleura, although they were abundant in the lungs.

From the standpoint of the health of the individual, neither the small number of asbestos bodies frequently present in the lungs, nor thickening of the parietal pleura in the form of fibrotic plaques, seem to be harmful.

ACKNOWLEDGEMENTS

My former teacher Professor *Osmo Järvi*, M.D., Head of the Department of Pathological Anatomy, University of Turku, has generously assisted me with expert advice concerning various problems that have turned up in connection with my daily work and the accomplishment of the present study. Furthermore, he placed the material of his institute at my disposal. For all this I wish to express my sincere thanks.

This study was undertaken at the suggestion of Docent *Raimo Kiviluoto*, M.D., who, moreover, allowed me to draw on his extensive knowledge of the problems relating to asbestos. My indebtedness to Doctor Kiviluoto is deeply felt.

I owe especial thanks to Professor *Erkki Saxén*, M.D., for his generous interest in my work and for inspiring criticism.

During the course of this investigation I have in various ways bothered a number of persons, who have always willingly assisted me. In particular, I wish to mention Professor *Leo Noro*, M.D. and Doctor *Seppo Sipilä*, M.D.

My thanks are due to Professor *Kaj Dammert*, M.D., Head of the Department of Pathological Anatomy, University of Oulu, who kindly gave me the opportunity to use the material of his institute for the sake of control. The pathologists and technical assistants of the Departments of Pathological Anatomy of the Universities of Turku and Oulu helped me in collecting the material of the present study. I am indebted to them all for this additional work, but wish to mention in particular Mr. *A. Salo*, laboratory technician at the Turku institute.

ASARCO ELP 0003095

I wish to express my gratitude to the librarians Mr. *A. Heikel*, Mag. phil., Mrs. *Aili Ryynänen*, Mag phil., and Mrs. *Kyllikki Räsänen*, Mag. phil., who showed personal initiative in procuring the relevant literature.

Furthermore, my thanks are due to Mr. *H. Alikoski*, Lic. Phil., who performed the statistical analyses.

Last, but not least, I wish to thank Mrs. *Anna-Liisa Jalo*, my laboratory technician for many years, who made the histological preparations skilfully and with untiring patience, besides doing her own routine work.

This study was supported by a grant from the Damon Runyon Memorial Fund for Cancer Research.

Kuopio, December 1965.

Lauri Meurman

ASARCO ELP 0003096

REFERENCES

ANSPACH, M.: Sind Pleuraverkalkungen pathognomonisch für eine Asbestose? Int. Arch. Gewerbepath. Gewerbehyg. 19:108—120, 1962.

ASCHOFF, L.: Pathologische Anatomie. Gustaw Fischer, Jena 1923.

AUROLA, E. et VESASALO, A.: Suomen asbestiesiintymistä ja niiden teknillisestä käytöstä. Geokemiallisia julkaisuja 54. Geologinen tutkimuslaitos, Helsinki 1954. (Finnish text with English summary.)

BEGER, P.J.: Über die Asbestosiskörperchen. Virchows Arch. path. Anat. 290: 280—353, 1933.

BEHRENS, W.: Über experimentelle Asbestosis. Schweiz. Z. Path. 14:275—297, 1951.

BEHRENS, W.: Silicatosen. In Mohr, L. et Stachelin, R.: Handbuch der Inneren Medizin. 4. Aufl. 4. Bd. Teil III, Spez. Teil II. 871—887. Springer Verlag, Berlin—Göttingen—Heidelberg 1956.

BELL, E. T.: A text book of pathology. Lea & Febiger, Philadelphia 1956.

di BIASI, W.: Zur pathologischen Anatomie der Lungenasbestose. Arch. Gewerbepath. Gewerbehyg. 8:139—155, 1938.

BOFFANO, M.: Calcificazioni pleuriche. Minerva med. 52:555—571, 1961.

BOHLIG, H., JACOB, G. et MÜLLER, H.: Die Asbestose der Lungen. Genese, Klinik, Röntgenologie. Georg Thieme Verlag, Stuttgart 1960.

BONSER, G. M., FAULDS, J. S. and STEWART, M. J.: Occupational cancer of the urinary bladder in dye-stuffs operatives and of the lung in asbestos textile workers and iron ore miners. Amer. J. clin. Path. 25:126—134, 1955.

BORRMANN, A.: Über Polyserositis chronica fibrosa und verwandte Zustände. (Ein Fall von Zuckergussdarm.) Virchows Arch. path. Anat. 264:700—729, 1927.

BOYD, W.: A text-book of pathology. An introduction to medicine. VI ed., Henry Kimpton. London 1953.

BRAUN, D. C. et TRUAN, D. T.: An epidemiological study of lung cancer in asbestos miners. Arch. industr. Hyg. 17:634—653, 1958.

BROCK, R. C. et BLAIR, E. A.: The importance of the respiratory movements in the formation and absorption of pleural fluids. J. thorac. Surg. 1:50—74, 1931.

BROSIG, W.: Zuckerguss der Pleura. Zbl. allg. Path. Anat. 71:52—55, 1939.

BROWN, W. J. et JOHNSON, L. C.: Postinflammatory "tumors" of the pleura; three cases of pleural fibroma of the interlobar fissure. Milit. Surg. 109:415—424; 1951.

BUCHANAN, W. D.: Quoted by Knox, J. F.: Asbestosis general and epidemiological. In Congrés International sur l'Asbestose, Caen (France) 29—30 Mai 1964. Rapports et discussions. Chambre Syndicale de l'amiante, Paris.

ASARCO ELP 0003097

CARTIER, P.: Empoussierage facteur étiologique de l'asbestose — plaques pleurales dans l'industrie de l'amiante. In Congrés International sur l'Asbestose, Caen (France) 29—30 Mai 1964. Rapports et discussions. Chambre Syndicale de l'amiante, Paris.

CARTIER, P.: Quoted by Staublungenerkrankungen und ihre Differentialdiagnose, edited by H. Bohlig, Georg Thieme Verlag, Stuttgart 1964.

CAUNA, D., TOTTEN, R. S. et GROSS, P.: Asbestos bodies in human lungs at autopsy. J. Amer. med. Ass. 192:371—373, 1965.

CENTRAL STATISTICAL OFFICE, Finland: Statistical year book of Finland 1963. (Finnish text with English summary.)

CLAUS, H. G.: Eine ungewöhnliche doppelseitige Pleuraverkalkung. Fortschr. Röntgenstr. 97:812—815, 1962.

COOKE, W. E.: Fibrosis of the lungs due to the inhalation of asbestos dust. Brit. med. J. 3317:147, 1924.

COOKE, W. E.: Pulmonary asbestosis. Brit. med. J. 3491:1024—1925, 1927.

COOKE, W. E.: Silico-anthracosis presenting curious bodies similar to those in asbestosis. Brit. med. J. 3718:656—657, 1932.

COOKE, W. E.: Modern views on silicosis. J. Hyg. (Lond.) 35:207—218, 1935.

CURSCHMANN, H.: Zur Differential-Diagnostik der mit Ascites verbundenen Erkrankungen der Leber und des Pfortadersystems. Dtsch. med. Wschr. 10:564—565, 1884.

DOLL, R.: Mortality of lung cancer in asbestos workers. Brit. J. industr. Med. 12:81—86, 1955.

EGBERT, D. S.: Pulmonary asbestosis. Report of a case with necropsy findings. Amer. Rev. Tuberc. 31:25—34, 1935.

ELMES, P. C., Mc CAUGHEY, W. T. E. et WADE, O. L.: Diffuse mesothelioma of the pleura and asbestos. Brit. med. J. 5431:350—353, 1965.

FAHR, T. et FEIGEL: Demonstrationen: Preparate und Mikrophotogramme von einem Falle von Pneumoconiose. Münch. med. Wschr. 61:625, 1914.

FEHRE, W.: Über doppelseitige Pleuraverkalkungen infolge beruflicher Staubeinwirkungen. Fortsch. Röntgenstr. 85:16—25, 1956.

FEHRE, F.: Discussion to MÜLLER, H.: Über schwere Formen der Asbestose. In Die Staublungenerkrankungen, Band 3, 561—564, edited by K. W. Jötten and W. Klosterkötter, Dietrich Steinkopff Verlag, Darmstadt 1958.

FOWLER, P. B. S., SLOPER, J. C. et WARNER, E. C.: Exposure to asbestos and mesothelioma of the pleura. Brit. med. J. 5403:211—213, 1964.

FROST, J., GEORG, J. et MÖLLER, P. F.: Asbestosis with pleural calcification among insulation workers. Dan. med. Bull. 3:202—204, 1956.

GARDNER, L. U.: Etiology of pneumoconiosis. J. Amer. med. Ass. 111:1925—1936, 1938.

GARDNER, L. U.: The pathology and roentgenologic manifestations of pneumoconiosis. J. Amer. med. Ass. 114:535—545, 1940.

GARDNER, L. U. et CUMMINGS, D. E.: Studies on experimental pneumoconiosis. VI. Inhalation of asbestos dust: its effect upon primary tuberculous infection. J. industr. Hyg. 13:65—81, 97—114, 1931.

GIESE, W.: Die Atemorgane. In Kaufmann's Lehrbuch der speziellen pathologischen Anatomie, Band II, 3. Teil, Lfr. 6, edited by M. Staemmler, Walter de Gruyter & Co., Berlin 1960.

ASARCO ELP 0003098

GLAUSER, A. et RÜTTNER, J. R.: Über Pseudo-Asbestosekörperchen (sogenannte Karborund und Graphitkörperchen). Experientia (Basel) 7:275—276, 1951.

GLOYNE, S. R.: The presence of the asbestos fibre in the lesions of asbestos workers. Tubercle (Edinb.) 10:404—407, 1929.

GLOYNE, S. R.: The morbid anatomy and histology of asbestosis. Tubercle (Edinb.) 14:445—451, 493—497, 1933.

GLOYNE, S. R.: Two cases of squamous carcinoma of the lung occurring in asbestosis. Tubercle (Edinb.) 17:5—10, 1935.

GLOYNE, S. R.: In Silicosis and asbestosis, edited by A. J. Lanza, Oxford University Press 1938.

GLOYNE, S. R.: Pneumoconiosis. A histological survey of necropsy material in 1205 cases. Lancet 6659:810—814, 1951.

GLOYNE, S. R., MARSHALL, G. et HOYLE, C.: Pneumoconiosis due to graphite dust. Thorax (Lond.) 4:31—38, 1949.

GOFFERJÉ: Einige Fälle von Polyserositis fibrosa. Inaug. — Diss. München 1905. Quoted by Borrmann, A.: Virchows Arch. path. Anat. 264:700—729, 1927.

GOUGH, J.: Occupational pulmonary diseases. In Modern trends in pathology, edited by D. H. Collins, Butterworth, London 1959.

GRAY, S. H., HANDLER, F. D., BLACHE, J. O., ZUCKNER, J. et BLUMENTHAL H. T.: Aging process of aorta and pulmonary artery in Negro and White races. Arch. Path. 56:238—253, 1953.

HARINGTON, J. S.: Occurrence of oils containing 3:4 benzpyrene and related substances in asbestos. Nature (Lond.) 193:43—45, 1962.

HEYMER, A.: Krankheiten der Atmungsorgane. In Lehrbuch der inneren Medizin I. Band. edited by H. Dennig, Georg Thieme Verlag, Stuttgart 1950.

HINSON, K. F. W.: Cancer of the lungs and other diseases after exposure to asbestos dust. Brit. J. Dis. Chest. 59:121—129, 1965.

HOBBS, A. A. jr.: A type of pneumoconiosis. Amer. J. Roentgenol. 63:488—497, 1950.

HOLT, P. F., MILLS, J. et YOUNG, D. K.: The early effects of chrysotile asbestos dust on the rat lung. J. Path. Bact. 87:15—23, 1964.

HOURIHANE, D. O. B.: The pathology of mesotheliomata and an analysis of their association with asbestos exposure. Thorax (Lond.) 19:268—278, 1964.

HUNT, A. C.: Massive pulmonary fibrosis from the inhalation of talc. Thorax (Lond.) 11:287—294, 1956.

HURWITZ, M.: Roentgenologic aspects of asbestosis. Amer. J. Roentgenol. 85:256—262, 1961.

ISSELBACHER, K. J., KLAUS, H. et HARDY, H. L.: Asbestosis and bronchogenic carcinoma. Report of one autopsied case and review of the available literature. Amer. J. Med. 15:721—732, 1953.

JACOB, G.: Zur Todesursachenstatistik bei der Asbestlungenfibrose. Mschr. Tuberc. Bekampf. 6:132—138, 1963.

JACOB, G. et BOHLIG, H.: Die röntgenologischen Komplikationen der Lungenasbestose. Fortschr. Röngenstr. 83:515—525, 1955.

JÄRVI, O.: Personal communication 1963.

ASARCO ELP 0003099

KIVIKANERVO, K. et TUOVINEN, P.: On the anatomy of the parietal pleura and adjoining tissues. Ann. Med. exp. Fenn. 25:293—301, 1947.

KIVILUOTO, R.: Pleural calcification as a roentgenologic sign of non-occupational endemic anthophyllite-asbestosis. Acta radiol. (Stockh.) suppl. 194, 1960.

KJERP, G.: Pleural calcification. Acta radiol. (Stockh.) 13:334—348, 1932.

KLEINFELD, M. et GIEL, G. P.: Pneumoconiosis. J. chron. Dis. 9:117—133, 1959.

KNOX, J. F.: Asbestosis general and epidemiological. In Congrés International sur l'Asbestose, Caen (France) 29—30 Mai 1964. Rapports et discussions. Chambre Syndicale de l'amiante, Paris.

KNOX, F. J. et BEATTIE, J.: Distribution of mineral particles and fibers in the lung after exposure to asbestos dust. Arch. industr. Hyg. 10:30—36. 1954.

KOUVO, O.: Mineralogical appendix. In Pleural calcification as a roentgenologic sign of non-occupational endemic anthophyllite-asbestosis. By R. Kiviluoto. Acta radiol. (Stockh.) suppl. 194, 1960.

KUHN, J : Übermikroskopische Untersuchungen an Asbeststaub und Asbestlungen. Arch. Gewerbepath. Gewerbehyg. 10:473—485, 1941.

KÖNIG, J.: Über die Asbestose. Arch. Gewerbepath. Gewerbehyg. 18:159—204. 1960.

LAAMANEN, A., NORO, L. et RAUNIO, V.: Observations on pollution caused by asbestos. In The occupational medical foundation and institute of occupational health. Annual report 1964, p. 41, edited by L. Noro. Saariston Kirjapaino Oy, Helsinki 1965.

LANGER, E.: Pseudoasbestosekörperchen bei Silicose. Zbl. allg. Path. path. Anat. 88:137, 1952.

LAUCHE, A.: Die Entzündungen des Brustfells. In Handbuch der speziellen pathologischen Anatomie und Histologie, edited by F. Henke et O. Lubarsch, Band 3, teil 1, p. 869. Julius Springer Verlag, Berlin 1928.

LAWSON, J. P.: Exposure to asbestos dust. Brit. med. J. 5327: 401, 1963.

LEICHER, F.: Primärer Deckzellentumor des Bauchfells bei Asbestose. Arch. Gewerbepath. Gewerbehyg. 13:382—392, 1954.

LOESCHCKE, H.: Experimentelle Untersuchungen über Saftstrom und Resorptionswege. Virchows Arch. path. Anat. 292:281—309, 1934.

LUBARSCH, O.: Pathologische Anatomie der Milz. In Handbuch der speziellen pathologischen Anatomie und Histologie, edited by F. Hencke et O. Lubarsch, Band I, teil 2, p. 373. Julius Springer Verlag, Berlin 1927.

LUTON, P., CHAMPEIX, J. et FAURE, P.: La signification de la présence de corps asbestosiques dans l'expectoration des travailleurs de l'amiante. Arch. Mal. prof. 8:56—68, 1947.

LYNCH, K. M.: Pulmonary asbestosis. IV The asbestos body and similar objects in the lung. J. Amer. med. Ass. 109:1974—1978, 1937.

LYNCH, K. M.: Pathology of asbestosis. Arch. idustr. Health. 11:185—188, 1955.

LYNCH, K. M. et CANNON, W. M.: Asbestosis. VI Analysis of forty necropsied cases. Dis. Chest. 14:874—885, 1948.

LYNCH, K. M. et SMITH, W. A.: Pulmonany asbestosis III: Carcinoma of the lung in asbesto-silicosis. Amer. J. Cancer. 24:56—64, 1935.

ASARCO ELP 0003100

LÖBLICH, H. J.: Zur pathologischen Anatomie der Kieselgurlunge. In Die Staublungenerkrankungen, Band 3. p. 550, edited by K. W. Jötten et W. Klosterkötter. Dietrich Steinkopff Verlag, Darmstadt 1938.

MARCHAND, F. Über eigentümliche Pigmentkristalle in den Lungen. Verh. dtsch. path. Ges. 10:223—228, 1906.

MARSOVÁ, D.: Beitrag zur Ätiologie der Pleuraverkalkungen. Z. Tuberk. 121: 329—334, 1964.

Mc DONALD, S.: Histology of pulmonary asbestosis. Brit. med. J. 3491:1025, 1927.

MEINANDER, C. F.: Die Kiukaiskultur. J. Archeol. Soc. of Finland. 53: 160—167 1954.

MEREWETHER, E. R. A.: Annual report of the Chief Inspector of factories for the year 1947. 1949: 79—81, 1949. H. M. Stationery Office. London, England.

MÜLLER, H.: Über schwere Formen der Asbestose. In Die Staublungenerkrankungen. Band 3. edited by K. W. Jötten et W. Klosterkötter, Dietrich Steinkopff Verlag, Darmstadt 1958.

MÜLLER, H.: Pleuraverkalkunken bei der Asbeststaublunge. Radiol. diagn. (Berl.) 3:33—38, 1962.

MÖNCKEBERG, J. G.: Erkrankungen des Hertzbeutels. In Handbuch der speziellen pathologischen Anatomie und Histologie, edited by F. Hencke et O. Lubarsch. Band II. p. 557. Julius Springer Verlag, Berlin 1924.

NORDMANN, M.: Der Berufskrebs der Asbestarbeiter. Z. Krebsforsch. 47:288—302. 1938.

NORO, L.: On the histology of asbestosis. Acta path. microbiol. scand. 23:53—59, 1946.

NUCK, K. et SZCZEPANSKI, W.: Talk und Talkstaublunge. Arbeitsmedizin 9: 1—39. 1939. Johan Ambrosius Barth Verlag, Leipzig 1939.

OOSTHUIZEN, S. F., THERON, C. P. and SLUIS-CREMER, G. K.: Calcified pleural plaques in asbestosis. An investigation into their significance. Med. Proc. 10:496—501, 1964.

OWEN, W. G.: Diffuse mesothelioma and exposure to asbestos dust in the Merseyside area. Brit. med. J. 5403: 214—218, 1964.

PORRO, F. W., PATTON, J. R. et HOBBS jr. A. A.: Pneumoconiosis in the talc industry. Amer. J. Roentegenol. 47:507—524, 1942.

PYYKÖNEN, L.: Personal communication 1960.

RAUNIO, O.: Personal communication 1960.

RAUNIO, V.: Personal communication 1965.

ROMEIS, B.: Mikroskopische Technik. 15 ed., p. 282. R. Oldenburg, München 1948.

RUSKA, H.: Übermikroskopische Untersuchungen an Asbeststaub und Asbestlungen. Arch. Gewerbepath. Gewerbehyg. 11:575—578, 1942.

SAXÉN, E.: Personal communication 1963.

SELIKOFF, I. J.: CHURG, J. et HAMMOND, E. C.: Asbestos exposure and neoplasia. J. Amer. med. Ass. 188:22—26, 1964.

SELIKOFF, I. J., CHURG, J. et HAMMOND, E. C.: Relation between exposure to asbestos and mesothelioma. New Engl. J. Med. 272:560—565, 1965.

SIEGAL, W., SMITH, A. R. et GREENBURG, L.: The dust hazard in tremolite talc mining including roentgenological findings in talc workers. Amer. J. Roentgenol. 49:11—29, 1943.

ASARCO ELP 0003101

SIEGAL, W., SMITH, A. R. et GREENBURG, L.: Study of talc miners and millers. Industr. Bull. 22:434—437, 1943.

SIEGERT, F.: Über die Zuckergussleber (Curschmann) und die pericarditische Pseudolebercirrhose (Pick). Virchows Arch. path. Anat. 153:251—292. 1898.

SIMSON, F. W.: Pulmonary asbestosis in South Africa. Brit. med. J. 3516: 885—887, 1928.

SIMSON, F. W. et STRACHAN, A. S.: Asbestosis bodies in the sputum: A study of specimens from fifty workers in an asbestos mill. J. Path. Bact. 34: 1—4, 1931.

SIPILÄ, S.: Personal communication 1960.

SLEGGS, C. A., MARCHAND, P. et WAGNER, J. C.: Diffuse pleural mesotheliomas in South Africa. S. Afr. med. J. 35:28—34, 1961.

SMITH, A. R.: Pleural calcification resulting from exposure to certain dusts. Amer. J. Roentgenol. 67:375—382, 1952.

STACHLMANN, W. et WORTH, G.: Differentialdiagnose der Staublungenerkrankungen. Radiologe 5:128—136, 1965.

STEPHANOPOULOS, C.: Pleural calcifications following dust exposure. Acta tuberc. scand. 42:228—232, 1962.

STEWART, H. L., BUCHER, C. J. et COLEMAN, E. H.: Asbestosis. Report of two cases. Arch. Path. 12:909—916, 1931.

STEWART, M. J.: Pulmonary asbestosis. Brit. med. J. 3536:675, 1928.

STEWART, M. J.: The immediate diagnosis of pulmonary asbestosis at autopsy. Brit. med. J. 3553: 509, 1928.

STEWART, M. J. et HADDOW, A. C.: Demonstration of the peculiar bodies of pulmonary asbestosis ("asbestosis bodies") in material obtained by lung puncture and in the sputum. J. Path. Bact. 32:172, 1929.

STEWART, M. J., TATTERSALL, N. et HADDOW, A. C.: On the occurrence of clumps of asbestos bodies in the sputum of asbestos workers. J. Path. Bact. 35:737—741, 1932.

SUNDIUS, N. et BYGDÉN, A.: Der Staubinhalt einer Asbestosislunge und die Beschaffenheit der sogenannten Asbestosiskörperchen. Arch. Gewerbepath. Gewerbehyg. 8:26—70, 1938.

SÖRENSEN, H. P.: Om pleuritis calcificans. Ugeskr. Laeg. 88:866—868, 1926.

THOMSON, J. G.: Mesothelioma of pleura or peritoneum and limited basal asbestosis. S. Afr. med. J. 36:759—760, 1962.

THOMSON, J. G.: Asbestos and urban dweller, read before the Conference of Biological Effects of Asbestos, New York, Oct. 19, 1964.

THOMSON, J. G., KASCHULA, R. O. C. et MACDONALD, R. R.: Asbestosis as a modern urban hazard. S. Afr. med. J. 37:77—81, 1963.

TIVENIUS, L.: Benign pleural lesios simulating tumour. Thorax (Lond.) 18: 39—44, 1963.

TYLECOTE, F. E. et DUNN, J. S.: Asbestosis-like bodies in a lung of a coal-miner who had never worked in asbestos. Lancet 221:632—633, 1931.

VORWALD, A. J., DURKAN, T. M. et PRATT, P. C.: Experimental studies of asbestosis. Arch. industr. Hyg. 3:1—43, 1951.

WAGLER, F., MÜLLER, H. et ANSPACH, M.: Gibt es eine endemische Asbestose? Z. ges. Hyg. 8:246—255, 1962.

ASARCO ELP 0003102

WAGNER, J. C.: A preliminary experimental assessment of the significance of asbestos bodies. In Die Staublungenerkrankungen. Band 3, pp. 566—569, edided by K. W. Jötten et W. Klosterkötter, Dietrich Steinkopff Verlag, Darmstadt 1958.

WAGNER, J. C.: Some pathological aspects of asbestosis in the Union of South Africa. In Proceedings of the pneumoconiosis conference, Johannesburg 1959, pp. 372—382, edited by A. J. Orenstein, London (Churchill) 1960.

WAGNER, J. C.: Experimental production of mesothelial tumours of the pleura by implantation of dusts in laboratory animals. Nature (Lond.) 196: 180, 1962.

WAGNER, J. C.: Asbestosis in experimental animals. Brit. J. industr. Med. 20: 1—12, 1963.

WAGNER, J. C.: The pathology of asbestosis in South Africa. A thesis accepted by the University of the Witwatersrand for the degree of Doctor of Medicine 1962.

WAGNER, J. C.: Quoted by Staublungenerkrankungen und ihre Differentialdiagnose, p. 49, edited by H. Bohling. Georg Thieme Verlag, Stuttgart 1964.

WAGNER, J. C., SLEGGS, C. A. et MARCHAND, P.: Diffuse pleural mesothelioma and asbestos exposure in the North West Cape Province. Brit. J. industr. Med. 17:260—271, 1960.

WEDLER, H-W.: Asbestose und Lungenkrebs. Dtsch. med. Wschr. 69:575—576, 1943.

WEDLER, H-W.: Arbeitsmedizin, Heft 24. Johan Ambrosius Barth Verlag, Leipzig 1947. Quoted by Leicher, F.: Arch. Gewerbepath. Gewerbehyg. 13: 382—392, 1954.

WEGELIUS, C.: Changes in the lungs in 126 cases of asbestosis observed in Finland. Acta radiol. (Stockh.) 28:139—152, 1947.

WEISS, A.: Pleurakrebs bei Lungenasbestose, in vivo morphologisch gesichert. Medizinische 1953:93—94, 1953.

WHITE, P. D.: Chronic constrictive pericarditis (Pick's disease) treated by pericardial resection. Lancet II Sept. 7, 539—548, 597—603, 1935.

WILLIAMS, E.: "Curious bodies" found in the lungs of coal workers. Lancet II: Sept. 8, 541—542, 1934.

WINKLER, A. W.: Die Talkstaublunge. In Handbuch der ges. Arbeitsmedizin, II Band. Berufskrankheiten, 2. Teilband., edited by E. W. Baader. Verl. Urban & Schwarzenberg, München 1961.

WORKING GROUP ON ASBESTOS AND CANCER: Report and Recommendations of the Working Group Convened under the Auspices of the Geographical Pathology Committee of the International Union Against Cancer. Arch. environm. health 11:221—229, 1965.

ZUPPIGER, A.: Pleuraerkrankungen. In H. R. Schinz, W. E. Baensch, E. Friedl et E. Euhlinger: Lehrbuch der Röntgendiagnostik, Band III, Teil I, Georg Thieme Verlag, Stuttgart 1952.

ASARCO ELP 0003103