TOXICOLOGY AND APPLIED PHARMACOLOGY 30, 440–451 (1974)

Residual Effects of Short-Term, Low-Level Exposure of Nonhuman Primates to Polychlorinated Biphenyls[1]

J. R. ALLEN, L. A. CARSTENS, AND D. A. BARSOTTI

Department of Pathology, University of Wisconsin Medical School, and Regional Primate Research Center, University of Wisconsin, Madison, Wisconsin 53706

Received February 23, 1974; accepted May 13, 1974

Residual Effects of Short-Term, Low-Level Exposure of Nonhuman Primates to Polychlorinated Biphenyls. ALLEN, J. R., CARSTENS, L. A. AND BARSOTTI, D. A. (1974). *Toxicol. Appl. Pharmacol.* 30, 440–451. Six adult female rhesus monkeys were fed the polychlorinated biphenyl (PCB) Aroclor 1248 at a level of 25 ppm for 2 months. Facial edema, alopecia, and acne developed within 1 month, and one animal died as a result of PCB intoxication 2 months after removal from the experimental diet. In addition to the above changes, this animal had anemia, hypoproteinemia, severe hypertrophic, hyperplastic gastritis, and bone marrow hypoplasia. Polychlorinated biphenyl concentrations in samples of subcutaneous adipose tissue obtained from all experimental animals averaged 127 μg/g fat at the time the experimental diet was discontinued. Eight months later the PCB content of the adipose tissue had decreased to 34 μg/g fat. However, the five surviving animals continued to show clinical signs and lesions of PCB intoxication. An infant born to one of these PCB-fed females was small and had over 25 μg PCB/g of adrenal and adipose tissue. These data attest to the toxicity of short-term, low-level exposure to PCBs in nonhuman primates and to the persistence of the toxic effects long after exposure has been eliminated.

The polychlorinated biphenyls (PCBs) have been used extensively for diverse industrial purposes during the past 40 years. There have been a number of accidental exposures to workers involved in PCB production (Jones and Alden, 1936; Good and Pensky, 1943). These persons invariably developed chloracne of varied severity depending largely on the magnitude of their exposure. It was not until 1966, when previously unidentified chromatographic peaks of organochlorine insecticide residues were identified as PCBs (Jensen, 1966), that the widespread contamination of the environment by these compounds was recognized. Perhaps the most obvious effect of the PCBs on the wildlife population occurred in fish-eating birds that resided near heavily populated coastal areas. Following the consumption of fish containing high levels of PCBs, these birds experienced decreased hatchability of their eggs, excessive chick mortality, and teratological abnormalities in their offspring (Risebrough *et al.*, 1968;

[1] Supported in part by U.S. Public Health Service Grants Nos. ES-00472 and RR-00167 from the National Institutes of Health and the University of Wisconsin Sea Grant Program. The authors express appreciation to L. J. Abrahamson, T. L. Durkin, and J. J. Scheffler for technical assistance. Primate Center Publication No. 13-036.

Copyright © 1974 by Academic Press, Inc.
All rights of reproduction in any form reserved.
Printed in Great Britain

Exh. 3

DSW 029166

STLCOPCB4013128

Holmes *et al.*, 1967; Presst *et al.*, 1970). In 1968, the public health significance of the PCBs became acutely apparent when over 1000 Japanese consumed rice oil that had been contaminated with PCBs (Kuratsune, 1969). Exposed persons developed nausea, lethargy, subcutaneous edema of the face, and chloracne within a short period. These signs and lesions were more severe in adolescents and young adults. The infants born of exposed mothers were small, had brownish-grey discoloured skin, and an abnormal ocular discharge. These abnormalities have persisted in many of the exposed persons for over 4 years (Kuratsune *et al.*, 1972).

The present study addresses itself to the protracted effects of low-level, short-term exposure to PCBs on sexually mature, female nonhuman primates. These data indicate that total doses of PCBs between 250 and 400 mg given over a 2-month period are capable of producing morbidity and mortality. It has been established that relatively high tissue concentrations of the PCBs as well as many of the previously reported signs and lesions which developed following exposure have persisted in these animals for a period in excess of 10 months. In addition, an infant born to one of these animals contained relatively high levels of PCBs in some of its tissues.

METHODS

Twelve adult female rhesus monkeys (*Macaca mulatta*), ranging in age from 7 to 10 years and having an average weight of 5.6 kg, were used. Each had previously delivered at least one live infant, and their monthly menstrual cycles had been recorded for at least 2 years prior to the initiation of this experiment. Following the determination that these animals had normal hemograms and serum chemistry values (Tables 1 and 2), six

TABLE 1

HEMATOLOGICAL CHANGES IN A MONKEY FOLLOWING 2-MONTH EXPOSURE TO A DIET CONTAINING AROCLOR 1248

	Time following exposure (months)				
	0	1	2	3	4
Hb (g/100 ml)	13.2	11.7	10.3	9.3	8.6
Hct (%)	38	36	32	29	27
WBC ($\times 10^3$/mm^3)	5.5	9.7	13.3	10.4	8.4
Neutrophils (%)	29	58	74	81	88

animals were placed on a diet containing 25 ppm of the PCB Aroclor 1248[2] for 2 months while the remaining animals served as controls. The PCB-fed animals were subsequently removed from the experimental diet and placed on commercially prepared monkey chow.

Throughout the course of the experiment the animals were observed daily for clinical changes. Complete blood counts and serum chemistry determinations were performed biweekly, while the animals were on the experimental diet, and monthly thereafter (Allen and Ahlgren, 1968). Biopsy specimens of subcutaneous abdominal fat were

[2] Monsanto Co., Inc., St. Louis, MO.

DSW 029167

STLCOPCB4013129

TABLE 2

MODIFICATIONS IN THE SERUM CHEMISTRY OF A MONKEY FOLLOWING 2-MONTH EXPOSURE TO A DIET CONTAINING AROCLOR 1248

	Time following exposure (months)				
	0	1	2	3	4
Total protein (g/100 ml)	7.4	6.9	5.5	5.6	5.1
Albumin/globulin	1.60	1.16	0.77	0.80	0.62
Total lipid (mg/100 ml)	520	495	450	400	270
Cholesterol (mg/100 ml)	157	75	73	88	73
Triglycerides (mg/100 ml)	66	132	61	71	43
BUN (mg/100 ml)	13	14	16	15	12
SGPT (R–F units)	21	16	22	15	126

obtained from each animal at the beginning of the third and tenth month of the experiment for gas–liquid chromatographic (glc) analysis. At the beginning of the tenth month a laparotomy was performed on the controls and five surviving experimental animals and a 15-g liver biopsy specimen was obtained for glc and biochemical analysis. The latter included a determination of DNA, RNA, and protein concentration in the liver homogenates and RNA, protein, cholesterol, and phospholipids in the hepatic microsomal fractions. Microsomal enzyme activities of *N*-demethylase, nitroreductase, esterase, glucose-6-phosphatase, cytochrome P-450, and aromatic hydroxylase were determined. The procedures employed in these analyses have previously been reported (Norback and Allen, 1972). For chromatographic analysis fat samples were homogenized in hexane (500 mg/20 ml) and subsequently evaporated under dry nitrogen in a 40°C waterbath. Cleanup of the extracted material prior to analysis was carried out in a disposable pipet microcolumn (Curley *et al.*, 1971) containing silica gel 60 (0.05–0.2 mm) by elution with a 1:1 benzene–hexane mixture. Levels of PCBs were quantitated in a Hewlett-Packard 7620A chromatograph employing a ^{63}Ni electron capture detector. A Pyrex column packed with Gaschrom Q (80–100 mesh) coated with 2% SE-30 was operated at 170°C with argon–methane (95:5%) as the carrier gas and at a flow rate of 40 ml/min.

A complete necropsy was performed on the one animal that died during the course of the experiment. Sections of tissues from each organ were fixed in 10% neutral buffered formalin for 24 hr, dehydrated and embedded in paraffin. Five-micrometer sections were stained with periodic acid-Schiff and mucicarmine. Liver tissue obtained for electron microscopy was fixed in veronal–acetate-buffered osmium tetroxide, dehydrated in ethanol, cleared in propylene oxide, and embedded in an epon–araldite mixture (Mollenhauer, 1964). Sections were cut and stained with toluidine blue for light-microscopic evaluation. Thin sections were cut and stained with uranyl acetate for electron microscopy.

Portions of the stomach, small intestine, large intestine, kidney, pancreas, skeletal muscle, heart, liver, brain, adrenals, skin, and adipose tissue were obtained from the one monkey that died, in order to determine tissue PCB concentrations. The procedure employed in evaluating these tissues was similar to that described for the adipose tissue with the exception of brain, where acetone (500 mg:20 ml) (Jennings, 1968) was used

DSW 029168

STLCOPCB4013130

for extraction. In order to obtain a live infant and placental tissue for PCB analysis, a full-term cesarian section (160th day of gestation) was performed on the one female which became pregnant. The infant was subsequently sacrificed and tissues obtained for PCB analysis and histological evaluation.

RESULTS

During the 2 months that the animals received PCB in their diet, the average daily food intake per animal was 175 g for five animals and 300 g for one animal. At these levels of ingestion, the five animals received a total dose of approximately 260 mg while the sixth animal consumed nearly 450 mg PCB.



FIG. 1. Facial edema is depicted in a monkey given 25 ppm PCB for 1 month. Note the swollen lips and eyelids and absence of eyelashes. Small pustules are vaguely discernible on the upper lip, nose, and forehead.

The animal that consumed the most food began to lose hair and develop obvious edema of the lips and eyelids by the end of the first month (Fig. 1). Within 6 weeks, similar but less severe changes were observed in the other animals. As the experiment progressed, these changes became more severe. By the third month extensive alopecia was apparent in all of the animals. Small pustules involving hair follicles were particularly obvious around the mouth, cheeks, and neck. Within 4 months the eyelids of two animals were so edematous that only a small slit-like opening existed between the upper and lower eyelids. All animals developed a moderate to severe pruritis.

DSW 029169

STLCOPCB4013131

Major hematological changes were limited to the one animal that consumed the greatest amount of the PCB diet (Table 1). There was a decrease in hemoglobin and hematocrit and the development of an absolute neutrophilia that was particularly obvious during the third and fourth months of the experiment. Decreases in the levels of total serum protein, lipids, cholesterol, and triglycerides were also recorded (Table 2). Electrophoretic patterns of the serum protein revealed a decrease in albumin and an



FIG. 2. Hypertrophy and hyperplasia, primarily of the mucous secreting cells of the gastric mucosa, were present in the stomach of a monkey that died 2 months following the discontinuation of a diet containing 25 ppm PCB. Note the invasion through the muscularis mucosa into the underlying submucosa by these glandular elements (→). Large epithelial-lined cysts filled with mucus and cell debris (C) are present in the submucosa. H and E; ×40.

increase in the percentage of the globulin fractions (Table 2). On the 128th day of the experiment, the animal that had consumed the largest amount of PCB in her diet expired. Her body weight had decreased from 5.9 to 3.9 kg due primarily to anorexia during the 2 months prior to death.

The major gross findings at autopsy included generalized alopecia, significant subcutaneous edema, and acne. In addition, there was an acute hyperplastic gastritis

DSW 029170

STLCOPCB4013132

involving the entire stomach lining. The thickness of the stomach wall averaged 2 cm as compared to a normal thickness of 2 mm. Due to the variation in the degree of hypertrophy, the mucosal surface of the stomach was markedly irregular. Widespread focal hemorrhage and ulcerations were also prominent. With the exception of the pale, semifluid bone marrow, the other tissues appeared normal.

Microscopically, there was disruption of the morphological features of the gastric

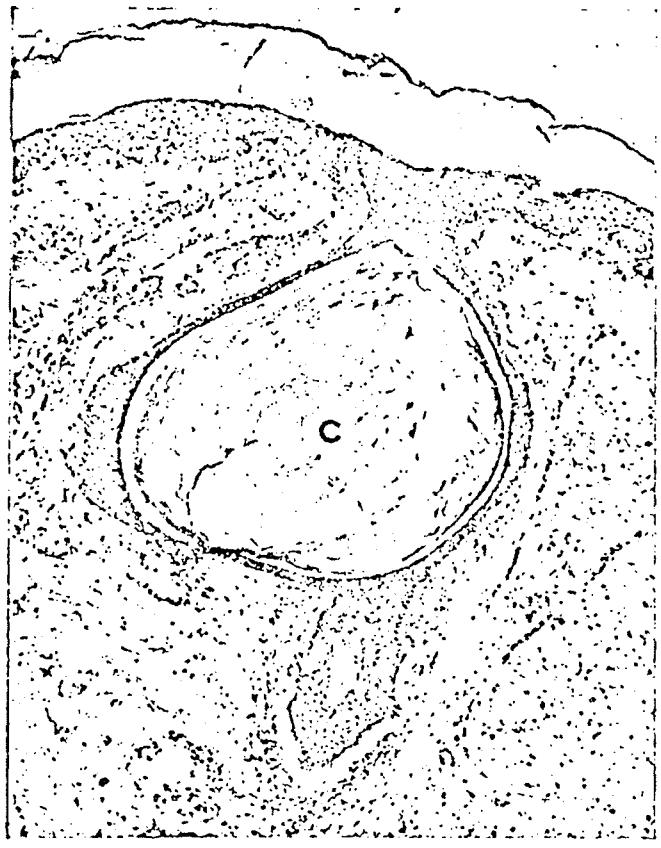

FIG. 3. Large keratin cysts (C) developed in the hair follicles, particularly of the face, in monkeys exposed to PCBs. Tissue from animal that died following exposure to a diet containing 25 ppm PCB for 2 months. H and E; × 60.

mucosa, caused by numerous large mucin-filled cysts (Fig. 2). The hyperplastic epithelium penetrated the muscularis mucosae with many mucosal epithelial elements present in the submucosa. The tissue surrounding the submucosal epithelium was invariably edematous. Occasionally, large epithelial-lined cysts that developed in the submucosa were ruptured and were associated with an acute inflammatory response. Dehiscence of these mucin-filled cysts on the surface of the gastric mucosa appeared to be conducive to the development of the gastric ulcerations that were grossly evident.

DSW 029171

STLCOPCB4013133

Other tissues showing microscopic changes were the skin, liver, and bone marrow. Numerous hair follicles, particularly of the face, were filled with keratin (Fig. 3). In addition, there was hyperplasia of the follicular epithelium and inflammation characterized by edema and acute inflammatory cells of the surrounding tissue. Throughout the liver there were focal areas of necrosis that had elicited an acute inflammatory response. In addition, the enlarged hepatocytes contained numerous small lipid droplets distributed in the abundant eosinophilic cytoplasm. Particularly prominent were the large lipid droplets that prevailed in the cytoplasm of the Kupffer cells. The hypocellularity of the bone marrow was related to a paucity of red cell precursors. All other tissues were normal microscopically.

TABLE 3

POLYCHLORINATED BIPHENYL CONTENT OF ADIPOSE TISSUE FROM MONKEYS EXPOSED TO 25 ppm AROCLOR 1248 IN THEIR DIETS FOR 2 MONTHS

	Time following exposure	
Animal No.	0 months (μg/g)	8 months (μg/g)
C-44	153	50
E-43	143	28
F-47	104	30
G-19	122	9[a]
1112	99	14
1360	142	50

[a] Necropsy tissue taken on 128th day of experiment.

TABLE 4

POLYCHLORINATED BIPHENYL CONTENT OF TISSUES OBTAINED FROM AN ANIMAL THAT DIED 68 DAYS FOLLOWING 2-MONTH EXPOSURE TO 25 ppm AROCLOR 1248

Tissue	Weight (g)	PCB content (μg/g)
Fat	—	9.3
Liver	156	8.9
Brain	94	8.5
Stomach	—	2.2
Skin	—	1.5
Adrenals	3.2 (2)	1.2
Thyroid	2.2	1.7
Small intestine	—	1.0
Large intestine	—	1.0
Muscle	—	1.0
Kidney	28 (2)	0.6
Pancreas	13.2	0.01

DSW 029172

STLCOPCB4013134

All animals maintained a regular menstrual cycle throughout the experiment. At the beginning of the fifth month and after having been removed from the experimental diet for 3 months, attempts were made to breed the five surviving experimental animals and six control animals. These females were placed with mature male monkeys for 48 hr during the ovulatory period as determined by the appearance of the sex skin and cyclic pattern of each female. Three of the females were thought to have conceived as a result of their showing characteristic postconceptional bleeding, absence of the subsequent menstrual period, and enlarged uteri. However, two of these animals experienced either

TABLE 5

POLYCHLORINATED BIPHENYL CONTENT OF TISSUES OBTAINED FROM MOTHER AND INFANT FOLLOWING CONSUMPTION OF AROCLOR 1248 BY THE MOTHER PRIOR TO PREGNANCY

Organ	Weight (g)	PCB content (μg/g)
Mother		
Liver	—	56.3
Fat	—	50.0
Placenta	—	0.9
Infant		
Fat	—	27.70
Adrenals	0.2	24.40
Liver	11.9	0.01
Muscle	—	0.98
Brain	52.9	0.29
Kidneys	2.8	0.10
Large intestine	—	0.08
Small intestine	—	0.52
Stomach	—	0.55
Lung	6.1	0.21
Skin	—	0.31

fetal resorption or abortion during their second month of pregnancy, as there was regression in uterine size and reestablishment of menstruation. The third animal carried her fetus to term. Although this infant was well developed, its body weight was considerably lower than the average rhesus infant (375 g vs 544 ± 101 g) (Kerr *et al.*, 1969). Examination of the tissues showed no gross or microscopic lesions. During the subsequent 5 months the nonpregnant females were bred on at least two separate occasions without becoming pregnant. All of the control animals became pregnant during this period and subsequently delivered normal offspring.

Biopsies of abdominal subcutaneous fat immediately after discontinuation of the experimental diet contained an average of 127 μg PCB/g fat (Table 3). This concentration of PCB had decreased to a mean level of 34 μg/g fat by the end of the 10th month of the experiment. Polychlorinated biphenyl content in the fat of the animal that died showed a much greater decline than the other monkeys, decreasing from 122 to 9 μg. The PCB concentrations of other tissues obtained at necropsy are shown in Table 4.

The transplacental movement of the PCBs was demonstrated in the one infant that

DSW 029173

STLCOPCB4013135

was born of the PCB-fed mother 8 months following discontinuation of the experimental diet (Table 4). The concentration of PCB in the tissues of the infant was relatively low with the exception of the adrenals and adipose tissue. In addition, concentrations of PCB in the placenta were much greater than those in most of the tissues obtained from the infant (Table 5).

TABLE 6

CHROMATOGRAPHIC DATA ON TISSUES OBTAINED FROM RHESUS MONKEYS EXPOSED TO AROCLOR 1248[a]

Retention time (sec)	Standard	Adipose tissue				Liver tissue			
		1112[b] (%)	G-19[c] (%)	C-44[d] (%)	W-25[e] (%)	1112 (%)	G-19 (%)	C-44 (%)	W-25 (%)
57	0.12	3.51	—	7.70	—	—	—	—	—
73	2.85	—	—	—	—	—	—	—	—
82	4.07	—	—	—	—	—	—	—	—
102	18.45	—	—	—	—	—	5.43	—	—
130	6.91	—	—	—	—	—	—	—	—
146	1.52	—	—	2.80	—	—	—	—	—
156	1.30	—	—	—	—	—	—	—	—
201	40.12	16.05	—	10.49	—	21.60	35.66	—	49.18
236	2.86	15.99	85.00	7.58	—	—	—	2.68	50.81
306	10.61	52.25	14.79	0.30	11.34	0.07	2.58	—	—
392	7.65	12.18	—	50.96	4.14	—	46.68	96.85	—
472	3.46	—	—	20.14	76.79	78.31	9.62	—	—
507	0.03	—	—	—	7.17	—	—	—	—
μg PCB/g tissue		26.73	9.28	50.03	27.69	33.95	8.93	56.33	0.01

[a] Data refer to the relative areas of the various peaks expressed as percent of the total. Standard refers to Aroclor 1248 prior to injection.
[b] Nonpregnant female tissue, 8 months after being removed from the PCB diet.
[c] Necropsy tissue from animal that died 2 months after removal from PCB diet.
[d] Tissue taken from female at time of cesarian section, 8 months after PCB diet.
[e] Infant tissue taken immediately following cesarian delivery.

The glc patterns obtained from the fat and hepatic tissue of the PCB-fed animals indicated a near absence of peaks of lower retention time (Table 6). It is of interest that the isomers present in the adipose tissue of the less severely affected animals closely resembled those located in the liver of the animal that died. Furthermore, fewer PCB isomers were present in the tissues of the infant than in the mother.

Ultrastructural evaluation of liver biopsy specimens taken after 10 months revealed a proliferation of the smooth endoplasmic reticulum of the hepatic cells. A majority of the Kupffer cells contained enormous fat droplets that caused the cytoplasmic organelles to be located around the periphery of the cell and the nuclei to assume eccentric positions.

Biochemically, there was no significant difference in the content of RNA, DNA, and protein of the liver homogenates. The protein, RNA, phospholipids, and cholesterol of the microsomal fractions were quite similar to those of the controls. Glucose-6-phosphatase and esterases were decreased, while aromatic hydroxylase, *N*-demethylase,

DSW 029174

STLCOPCB4013136

and nitroreductase were quite similar in microsomal fractions from the control and experimental animals (Table 7). Cytochrome P-450 was slightly greater in the experimental group.

TABLE 7

HEPATIC CHANGES IN MONKEYS 10 MONTHS FOLLOWING 2-MONTH EXPOSURE TO A DIET CONTAINING 25 ppm AROCLOR 1248[a]

Analysis	Control	Experimental
Liver homogenate		
DNA (mg/g liver)	2.86 ± 0.33	3.09 ± 0.15
RNA (mg/mg DNA)	1.82 ± 0.15	1.80 ± 0.14
Protein (mg/mg DNA)	94.6 ± 11.2	90.5 ± 4.1
Microsomal Fraction		
Protein (mg/g liver)	18.7 ± 6.2	27.1 ± 4.2
RNA (μg)[b]	81.4 ± 23.3	71.9 ± 6.0
Phospholipid (μg)[b]	514 ± 49	534 ± 36
Cholesterol (μg)[b]	16.6 ± 4.6	14.7 ± 1.7
Glucose-6-phosphatase (μmol PO_4/15 min)[b]	2.14 ± 0.20	1.77 ± 0.29[c]
Esterase (μmol *p*-nitrophenol/min)[b]	5.16 ± 0.47	3.99 ± 0.36[c]
Aromatic hydroxylase (nmol *p*-aminophenol/30 min)[b]	13.5 ± 9.4	16.1 ± 1.7
N-Demethylase (nmol formaldehyde/30 min)[b]	167 ± 60	126 ± 36
Nitroreductase (nmole *p*-aminobenzoate/hour)[b]	29.4 ± 9.6	24.6 ± 2.9
Cytochrome P-450 (nmol)[b]	0.603 ± 0.082	1.03 ± 0.17[c]

[a] Values are means ± SD.
[b] Per mg microsomal protein.
[c] Difference from control group statistically significant ($p < 0.05$), Student's t test.

DISCUSSION

The data presented in this report further clarify the similarity in responses of nonhuman primates and man to PCB exposure. The clinical signs and lesions which were recorded in nonhuman primates fed diets containing 100 and 300 ppm PCB became obvious as rapidly as in animals given 25 ppm (Allen and Norback, 1973; Allen *et al.*, 1973). In addition, morbidity and mortality were equally severe in the animals receiving the two higher concentrations and only slightly less severe in those exposed to lower concentrations. These data suggest that the PCBs are extremely toxic to nonhuman primates over a relatively wide dose range.

The lower concentrations of PCB that were employed in these studies are only five times greater than those permissible in certain foods consumed by man. This seems to be of particular significance in that the PCBs are not readily excreted from the body.

DSW 029175

STLCOPCB4013137

It has been reported that over 90% of ingested PCBs are absorbed from the gastrointestinal tract and deposited primarily in the fatty tissues (Albro and Fishbein, 1972; Allen *et al.*, 1974). It has recently been shown that rats given 100 ppm PCB continued to show increasing tissue levels for periods in excess of 1 year (unpublished observations). These data indicate that, when small amounts of PCBs are ingested over an extended period, tissue concentrations increase eventually to reach toxic proportions. Perhaps of equal importance is the observation that following food deprivation, when endogenous sources of energy are required, there is mobilization of adipose tissue and along with it the fat-stored PCB, as perhaps was the case in the one animal that died (Allen *et al.*, 1974). This relocation of PCBs in the body may augment their toxicity. Massive exposure of the liver to PCBs, such as could occur during periods of illness associated with anorexia, would be conducive to the development of hepatic necrosis, fatty infiltration and degeneration of the liver, and decreased liver function (Hutterer *et al.*, 1968; Allen *et al.*, 1973) that could lead to hepatic failure and death.

Data obtained from the present experiment indicate that a large percentage of the tissue PCBs returned to the liver are not redeposited in fat depots but are progressively excreted. When the PCBs were removed from the diet of the one animal that died, the PCB fat concentration was 122 μg/g tissue. However, within 2 months this value had decreased to approximately 9 μg/g. Similar but less dramatic changes occurred in the five other animals. It is of interest that the glc patterns of the PCBs in the liver of the dead animal closely resembled those usually recorded for adipose tissue, thus further suggesting a migration of the PCBs from the depot fat to the liver.

Polychlorinated biphenyls must also show a predilection for newly formed adipose tissue. Even though PCBs were eliminated from the diet of the mother for 3 months prior to conception, the fat and adrenals of her infant contained relatively high levels of PCBs. It is also of interest that fewer PCB isomers were present in the infant fat than in the adipose tissue and liver of the mother.

The nonhuman primate, like man, does not show a rapid recovery from the effects of PCB intoxication. Many of the persons who consumed the PCB-containing rice oil in the Yusho outbreak continued to experience deleterious effects several years following exposure (Kuratsune *et al.*, 1972). Similar observations made on nonhuman primates show that 8 months following PCB exposure adipose tissue concentrations of PCB remain relatively high, acne continues to be apparent, and subcutaneous edema and alopecia of the face persist.

There are many factors that must be taken into consideration when the toxic effects of the PCBs in a given animal are evaluated. As an example, of the six animals employed in the present experiment, one died approximately 2 months after being taken off the PCB diet. This animal had consumed considerably more PCB than the others. However, her subcutaneous fat contained slightly less PCB than some of the animals and more than others. In addition, there was no appreciable difference in the number and percentage of isomers present in the tissues of the monkey that died when compared with those in the tissues of the surviving animals.

The major difference, other than the variation in food consumption, that separated the animal that died from the others was the severe gastritis that was present in this one animal. Undoubtedly the greater gastric mucosal exposure to the PCBs was sufficient to cause more severe changes in the stomach of this animal than was experienced

DSW 029176

STLCOPCB4013138

by the others. As a result of the hypertrophic, hyperplastic gastritis, and multiple gastric ulcers, the animal did not eat well during the last 2 months of life. This lack of food consumption was undoubtedly responsible for the decrease in serum protein and the 35% reduction in body weight experienced by this animal.

REFERENCES

ALDRO, P. W. AND FISHBEIN, P. (1972). Intestinal absorption of polychlorinated biphenyls in rats. *Bull. Environ. Contam. Toxicol.* 8, 26–31.

ALLEN, J. R., ABRAHAMSON, L. J. AND NORBACK, D. H. (1973). Biological effects of polychlorinated biphenyls and triphenyls on the subhuman primate. *Environ. Res.* 6, 344–354.

ALLEN, J. R. AND AHLGREN, S. (1968). A comparative study on the hematological changes in the *Macaca mulatta* monkey and on the human female during pregnancy. *Amer. J. Obster. Gynecol.* 100, 894–903.

ALLEN, J. R. AND NORBACK, D. H. (1973). Polychlorinated biphenyl and triphenyl induced gastric mucosal hyperplasia in primates. *Science* 179, 498–499.

ALLEN, J. R., NORBACK, D. H. AND HSU, I. C. (1974). Tissue modifications in monkeys as related to absorption, distribution and excretion of polychlorinated biphenyls. *Arch. Environ. Contam. Toxicol* 2, 86–94.

CURLEY, A., BURSE, V. W., GRIM, M. E., JENNINGS, R. W. AND LINDER, R. E. (1971). Polychlorinated biphenyls: Distribution and storage in body fluids and tissues of Sherman rats. *Environ. Res.* 4, 481–495.

GOOD, C. K. AND PENSKY, N. (1943). Halowax acne (cable rash): Cutaneous eruptions in marine electricians due to certain chlorinated naphthalenes and diphenyls. *Arch. Dermatol. Syphilol.* 48, 251–257.

HOLMES, D. C., SIMMONS, J. H. AND TATTON, J. O'G. (1967). Chlorinated hydrocarbons in British wildlife. *Nature (London)* 216, 227–229.

HUTTERER, F., SCHAFFNER, F., KLION, F. M. AND POPPER, H. (1968). Hypertrophic, hypoactive smooth endoplasmic reticulum: A sensitive indicator of hepatotoxicity exemplified by dieldrin. *Science* 161, 1017–1019.

JENNINGS, R. W. (1968). Biological sample clean-up for chlorinated hydrocarbon and organophosphorus analysis using electron capture gas-liquid chromatography. American Chemical Society, Division of Agricultural and Food Chemistry, Abstracts 125, 156.

JENSEN, S. (1966). Report of a new chemical hazard. *New Sci.* 32, 612.

JONES, J. W. AND ALDEN, H. S. (1936). An acneform dermatergosis. *Arch. Dermatol. Syphilol.* 33, 1022–1034.

KERR, G. R., KENNAN, A. L., WAISMAN, H. A. AND ALLEN, J. R. (1969). Growth and development of the fetal rhesus monkey. I. Physical growth. *Growth* 33, 201–213.

KURATSUNE, M. (1969). An epidemiologic study on "Yusho" or chlorobiphenyl poisoning. *Fukuoka Acta Med.* 60, 513.

KURATSUNE, M., YOSHIMURA, T., MATSUZAKA, J. AND YUMAGUCHI, A. (1972). Epidemiologic study of Yusho, a poisoning caused by ingestion of rice oil contaminated with a commercial brand of polychlorinated biphenyls. *Environ. Health Persp.* 1, 119–128.

MOLLENHAUER, H. G. (1964). Plastic embedding mixtures for use in electron microscopy. *Stain Technol.* 39, 111–114.

NORBACK, D. H. AND ALLEN, J. R. (1972). Chlorinated triphenyl induced extensions of the hepatic endoplasmic reticulum. *Proc. Soc. Exp. Biol. Med.* 139, 1127–1131.

PRESST, I., JEFFERIES, D. J. AND MOORE, N. W. (1970). Polychlorinated biphenyls in wild birds in Britain and their avian toxicity. *Environ. Pollut.* 1, 3–26.

RISEBROUGH, R. W., REICHE, P., PEAKALL, D. B., HERMAN, S. G. AND KIRVEN, M. N. (1968). Polychlorinated biphenyls in the global ecosystem. *Nature (London)* 220, 1098–1102.

DSW 029177

STLCOPCB4013139