STATE OF NEW YORK
DEPARTMENT OF ENVIRONMENTAL CONSERVATION

In the Matter of

Alleged Violations of Sections 17-0501, 17-0511, and 11-0503 of the Environmental Conservation Law of the State of New York by

General Electric Company

Respondent

TESTIMONY OF

DR. RENATE KIMBROUGH

FILE NO. 2833

Q. Please state your name and business address.

A. Dr. Renate Kimbrough, Center for Disease Control, Atlanta, Georgia.

Q. State your position at the Center for Disease Control and your prior work and educational experience.

A. I am a Medical Research Officer in the Toxicology Branch of the Center for Disease Control, Department of Health, Education, and Welfare. A copy of my Curriculum Vitae and a list of publications are attached to my testimony as Exhibit "1". For the past thirteen years I have been engaged in the study of the toxicity and related effects of pesticides and other chemical substances on animals and man.

Q. During the course of your work have you ever studied polychlorinated biphenyls (PCBs)?

A. Yes; I have studied and continue to study PCBs.

Q. What are PCBs?

A. Commercially produced chlorinated biphenyls are mixtures of biphenyls with different numbers of chlorine atoms. As the percent of chlorine increases, the chlorinated biphenyls become more viscous. Because of inherent qualities, PCBs are widely used in a variety of industrial situations. The sole

manufacturer of PCBs in the United States is the Monsanto Company. However, PCBs are also manufactured in other parts of the world by other manufacturers and imported into the United States.

Q. When and why did you begin work with PCBs?

A. I first became involved in the study of PCBs in the latter part of 1969 when I was directed to study two polychlorinated biphenyls, Aroclor 1254 and Aroclor 1260, both products of Monsanto. At that time little was known about the long-term toxicity of these compounds. Since they had been detected in food destined for human consumption there was increasing concern about their effects.

Q. Please state the experiments you conducted and the results thereof.

A. Initially, we embarked on a study to determine the acute oral toxicity of these compounds. We mixed PCB Aroclor 1254 and Aroclor 1260 with peanut oil and gave this to Sherman Strain rats as a single dose by stomach tube at different concentrations. We determined that the dose that would kill half of the animals, that is the oral "LD 50" for adult rats, was between 4,000 and 10,000 mg per kg bodyweight of the animal. This means that these particular polychlorinated biphenyls are not especially acutely toxic to rats. These results were published and a copy is appended to this testimony as Exhibit "2".

We later studied the single dose oral toxicity of these two compounds in weanling male rats. We found that polychlorinated biphenyls are more toxic to young animals. The single dose oral LD 50 for Aroclor 1254 was 1,295 mg/kg and the single dose oral LD 50 for Aroclor 1260 was 1,315 mg/kg. This study was published and a copy is appended as Exhibit "3".

In addition to this study, we also incorporated Aroclor 1254 and Aroclor

1260 at different concentrations into the diet of Sherman Strain rats (male and female) and fed them this diet for a period of eight months. The lowest dose fed the rats in this study was 20 ppm of the two compounds. This is equivalent to a daily dietary intake of 1.4 to 1.6 mg per kg bodyweight per day. At this dietary level we found that, when fed Aroclor 1254 the livers of both the male and female rats were enlarged. When fed Aroclor 1260, only the male rats had enlarged livers. This liver enlargement was determined by weighing the livers of the animals when we sacrificed them at the end of the study. The weight of the livers (direct weight and the weight expressed on a percentage of bodyweight basis) was then compared to those of the control animals.

We also examined the livers with a light microscope. This examination showed that the liver cells of all ten male rats fed Aroclor 1260 and 7 of the ten male rats fed Aroclor 1254 at the 20 ppm dietary level were larger than those of the control rats. Three of the 10 female rats fed Aroclor 1260 also exhibited larger liver cells than the control animals. These livers also occasionally contained cells that showed inclusions on the cytoplasm or that had a foamy cytoplasm. In other words, the cytoplasm* of some of these liver cells was not normal. Additionally, higher dietary levels of PCBs produced more of an effect in the livers. These effects adenofibrosis (scarring of the liver with proliferated epithelial cells) and, at a dietary level of 100 ppm or more, an increased amount of lipid (fat) within the cytoplasm of the liver cells. The lipid accumulation in these cells indicates that the cell is either unable to metabolize the lipid or that the lipid transport of the cell is impaired.

* The cytoplasm of a cell is the protoplasm that surrounds the nucleus. A great deal of the metabolism of a cell is conducted in the cytoplasm.

Enlargment of the liver cells is usually accompanied by an increase in smooth endoplasmic reticulum. An increase in smooth endoplasmic reticulum can be detected by examining the livers with an electron microscope. Upon such an examination we found an increase in smooth endoplasmic reticulum in the livers of all the animals that had ingested the Aroclors in this study. An increase in smooth endoplasmic reticulum is usually accompanied by an increase in the function of the microsomal enzymes of the liver cells. This is considered an adaptive change. These microsomal enzymes are attempting to metabolize the chemicals that the animals have ingested in order to excrete these chemicals. However, this enzyme induction may have harmful effects in that it may increase the metabolism of steroid and therapeutic drugs and thereby render such drugs less effective. It may also change an inert parent compound into a chemical that is more active and may thus have a deleterious effect.

We also observed that the livers of rats, particularly at high dietary levels of PCBs, contained a brown pigment and that some of this pigment fluoresced when the livers were held under ultraviolet light. We assumed that the fluorescence in the livers was due to an increase in liver porphorins. At this time it is not known whether this defect in porphorin metabolism occurs only in animals or whether it could occur in humans as well. If this condition were produced in humans, this could lead to photoaensitivity reactions of the skin (abnormal blistering and desquamation of the skin upon exposure to ultraviolet light, such as sunlight). This study has been published and is appended to my testimony as Exhibit "4".

Because of the adenofibrosis that we observed in the study described above, we conducted additional studies to see whether: (1) this lesion could

particularly attracted to and stored in such tissue. A concentration of 1,000 ppm in adipose tissue would be equivalent to 1 gm in a kg of adipose tissue or a concentration of .1%. This study shows that the PCBs that were studied are very persistent in the animal. Even after exposure to PCBs was discontinued for 10 months, certain portions of the PCB mixtures were still present in the animals in an appreciable amount.

We also studied the storage of Aroclor 1242 and Aroclor 1016 in Sherman Strain rats, when these compounds were fed in the diet. The highest concentrations of PCBs were found in adipose tissue, namely 143 ppm (143 mgPCB/kg adipose tissue) for Aroclor 1242 and 236 ppm for Aroclor 1016 following a dietary consumption of 3-7 mgPCB/kg bodyweight per day of 100 ppm of these PCB mixtures for 6 and 8 months respectively. Following cessation of exposure, a major proportion of the PCBs were eliminated over a 6 months period. Microscopic examination of the livers of rats that had consumed these PCB mixtures (Aroclor 1016 or 1242) showed liver cells with vacuolated cytoplasm indicative of lipid accumulation and occasionally liver cell necrosis (tissue breskdown) and hemorrhage (bleeding). The published report of this study is appended to this testimony as Exhibit "6". In the published study attached to my testimony is Exhibit "7", we fed Aroclor 1254 to inbred male mice of the Balb/cj strain, at a dietary level of 300 ppm (49.8 mg/kg bodyweight/day) for 11 months. We again were able to observe adenofibrosis in the mice. In addition, we found that out of a total of 22 surviving mice, 9 had a total of 10 hepatic tumors. These tumors measured from 0.1 to 1.5 cm in diameter. These tumors were composed of liver cells and we classified them as hepatomas. Dr. H. L. Stewart, Pathologist and Consultant for the National Cancer Institute, reviewed these slides and concurred with our diagnosis. Since this paper was

written I have adapted for application to mice the liver tumor classification outlined at a workshop on rat liver tumors held by leading experts in the field in 1974. According to that classification, these tumors represent neoplastic nodules.

In the first feeding study mentioned above (Exhibit "2") we found a bladder tumor in one of the female rats. This rat had been fed Aroclor 1260 at a dietary level of 100 ppm, equivalent to a dietary intake of about 7.2 mg/kg. Since we did not know whether this single tumor occurred coincidentally or whether it was caused by the consumption of Aroclor 1260, we began a study in early 1972 in order to obtain further information with respect to this problem..

This study has been submitted for publication and is attached as Exhibit "8". A total of 400 female weanling Sherman Strain rats were divided into two groups of 200 each. We fed one group, the experimental group, 100 ppm of Aroclor 1260 for almost 21 months. The dietary intake of PCBs in these animals is shown in figure #2 of this study (Exhibit "1"). This dietary intake ranged from about 11.6 mg per kg per day when the animals were young and consumed more food, to a level of 4.3 mg/kg/day when the animals were older. The rats were sacrificed when they were 23 months old and autopsies and microscopic examination of tissues were performed on most organs of a total of 173 control animals and 184 experimental animals. The only distinct difference that was found between the experimental animals (those fed Aroclor 1260) and the control animals was the occurrence of hepatic tumors in the experimental animals.

I personally made sections for microscopic study of all formalin-fixed tissues of these rats. On gross inspection of the livers I found that almost all of the livers (170 out of 184) of the experimental animals had from a few

to multiple, elevated, tan nodules (a protuberance or a knotty localized swelling) on the surface. Additional nodules were usually seen on sectioning. These nodules varied from 0.1 to several centimeters in diameter. On examination of organs with the unaided eye, I personally use the term "nodule" for something that upon microscopic examination I expect to be a neoplasm. A neoplasm is any abnormal or autonomous growth of tissue, either benign or malignant. The livers of the control animals did not look at all like the livers of the experimental animals when they were examined with the unaided eye. The surface of the livers of the control animals was smooth; nodules were observed only in one liver of one control rat out of a total of 173 control rats.

Following microscopic examination of the liver sections we divided the liver lesions that were noted on examination with the unaided eye into three groups. We classified the liver tumors of 26 rats as hepatocellular carcinomas (malignant lesions) and the liver tumors of 144 rats out of 184 animals as neoplastic nodules. In addition, 182 out of 184 rats had other changes in their livers that we classified as foci or areas. In the control animals the one liver that, on examination with the unaided eye, was very nodular turned out, on microscopic examination, to be a hepatocellular carcinoma. None of the other livers of the 173 control rats showed any neoplastic nodules; foci or areas were found in only 28 out of the control 173 rats.

We made this decision from the morphological appearance of the liver lesion under the light microscope. The results of this study indicate a spectrum of a response of the liver to a hepatocarcinogenic agent. The same spectrum can be elicited with established carcinogens. At the previously

mentioned tumor workshop in December, 1974, this same spectrum of response of the liver to hepatocarcinogenic agents was outlined by an international group of experts in this field.

Q. Have you performed any experiments on reproductive effects of PCBs?

A. We also conducted a reproduction study in Sherman Strain rats. The rats in this study were fed PCBs (Aroclor 1254 and Aroclor 1260) from the beginning of the experiment when they were three to four weeks old, until they were killed. Exposure to PCBs thus ranged from 179 to 328 days. Groups of parent rats consisting of 10 males and 20 females were fed PCBs at various dietary levels. The dietary levels that were used were 0, 1, 5, 20, 100 and 500 ppm. The corresponding dietary levels on a mg/kg/bodyweight per day basis are approximately 0, 0.06, 0.32, 1.5, 7 and 35 mg per kg bodyweight per day. These reproduction studies were carried on through two generations. The lowest dietary level that affected reproduction in rats fed Aroclor 1254 was 20 ppm. These rats had fewer pups per litter. Aroclor 1260 had an effect on reporduction only at the dietary level of 500 ppm.

Offspring of the rats were usually killed when they were 21 days old. Upon performing autopsies it was found that the liver weight of pups that had been produced and raised by rats that were fed dietary levels as low as 5 ppm of either Aroclor 1254 or 1260 were increased compared to the liver weights of those pups where the parents had received a control diet. Microscopic examinations of the tissues (mainly the liver) of both the adults as well as the pups that were killed were also conducted. Again, as has been pointed out in previous studies, the abnormal findings were confined to the liver and were similar to those already described in the study appended as Exhibit 2. In addition, neoplastic nodules in the livers of some of the parent rats

that were fed either Aroclor 1254 or Aroclor 1260 were noted similar to those described above in the long-term feeding study with Aroclor 1260 . For example, neoplastic nodules were in 3 of 7 livers examined of female rats fed the dietary level of 20 ppm Aroclor 1254 for a total of 328 days.

When the findings in this study are considered together with the findings in the 2-year feeding study where 100 ppm of Aroclor 1260 was fed to 200 female rats, it appears that long-term exposure (18-24 months) to PCBs at these dietary levels produces a carcinogenic response in the liver of the rat.

Q. In your opinion are the effects you have observed correlated to the percentage of chlorine contained in the PCB mixture tested?

A. Although I have not performed experiments with all of the commercially available mixtures of PCBs, from my own experience and the experience of others (Ecobichon and Comeau; Toxicology and Applied Pharmacology, 99, 94-305; 1975), the percent chlorine of PCBs is not the significant factor in the toxicity of these chemicals. What is important is the composition, i.e. the proportion of individual chlorobiphenyls in the different commercial mixtures of PCBs.

Q. Please summarize the results of your experiments.

A. As a result of my studies, it was determined that PCBs are persistant in the animal, are primarily stored in adipose tissue, and induce pathological changes in the liver of rodents, including enlargement of the liver, lipid accumulation, accumulation of a brown pigment, and, following long-term dietary exposure, a hepatocarcinogenic response. Additionally, we found that PCBs affect reproduction in rodents.

Reprinted from the Archives of Environmental Health
November 1972, Volume 25
Copyright 1972, American Medical Association

Morphological Changes in Livers of Rats Fed Polychlorinated Biphenyls

557

Light Microscopy and Ultrastructure

Renate D. Kimbrough, MD; Ralph E. Linder; and Thomas B. Gaines, Chamblee, Ga.

Male and female Sherman strain rats were fed polychlorinated biphenyls Aroclor 1260 and Aroclor 1254 at 0, 20, 100, 600 and 1,000 ppm in their diet. Rats received the dietary levels for eight months. Light microscopic changes consisted of hypertrophy of the liver cells, inclusions in the cytoplasm, brown pigment in Kupffer cells, lipid accumulation, and, at the higher dietary levels, adenofibrosis. Ultrastructural changes of the livers of exposed animals consisted of an increase in smooth endoplasmic reticulum and atypical mitochondria. Lipid vacuoles were occasionally surrounded by concentric membranes. The epithelial component of adenofibrosis consisted of goblet cells and cells that resembled the epithelium which lines the bile ducts. In general, the effect of Aroclor 1254 on the liver was more pronounced than that of Aroclor 1260.

Polychlorinated biphenyls (PCBs) are widely distributed in the environment.[1] They are marketed in the United States under the trade name Aroclor followed by a four digit number with the last two digits indicating the percent of chlorine. They were first marketed in the 1930s. Jones and Alden[2] reported a case of chloracne in a worker who had been heavily exposed to a chlorinated biphenyl. Miller[3] reported pathological changes in animals exposed to a commercial chlorinated biphenyl. He studied rats, rabbits, and guinea pigs, and found liver damage in all series of experiments, as well as skin changes in the animals receiving subcutaneous injections or applications of the material to the skin. Liver damage was most pronounced in the guinea pig. The rat livers had intercellular hyaline bodies in addition to the fatty degeneration that was observed in all three species. Bennett and his co-workers[4] also reported that Aroclors affected the livers of rats. Von Oettingen[5] discusses these earlier findings in his book "*The Halogenated Hydrocarbons: Toxicity and Potential Dangers.*" After the Second World War, the PCBs were increasingly used for moisture proofing, sealing, impregnation, and vapor suppression in prolonging the residual life of insecticides and as fire retardants. They can be found in synthetic resins, synthetic and natural rubber, cellulose resins, paint, varnish, wax, asphalt, and allyl starch. They have also been used in printing inks, textile dyes, and as heat transfer fluid. In 1968, an outbreak of poisoning that involved at least 600 people occurred in western Japan where rice bran oil was contaminated with Kanechlor 400, a PCB.[6] The contamination of the oil occurred because PCBs used as heat exchangers in the manufacturing process leaked into the oil through pinholes in the pipes. This incident prompted Nishizumi[7] to study the effect of PCBs on the livers of mice and monkeys. He found a large amount of acidophilic material in the cytoplasm of hepatocytes and fatty vacuoles. Using electron microscopy, he observed "myelin figures" in the cytoplasm, and an increase in smooth endoplasmic reticulum and lipid droplets.

More recently, PCBs leaked into fishmeal from a heat exchanger of a processing plant in North Carolina. The contaminated fishmeal was fed to adult chickens and breeders. The contamination was discovered when the eggs from the breeders did not hatch. Some of the chickens also exhibited symptoms of chick edema.[8] The fact that PCBs can produce chick edema has been described repeatedly.[9-11]

Contaminants may be at least partially responsible for some of these toxic effects.

Submitted for publication Jan 18, 1972; accepted April 28.

From the Chamblee Toxicology Laboratory, Environmental Protection Agency, Chamblee, Ga.

Read in part before the 12th annual meeting of the Society of Toxicology, Williamsburg, Va. March 5-9, 1972.

Reprint requests to Chamblee Toxicology Laboratory, Environmental Protection Agency, 4770 Buford Hwy, Chamblee, Ga 30341 (Dr. Kimbrough).

Exhibit 2, 4

MONS 204972

Chlorinated dibenzofuran and chlorinated naphthalenes have been found as contaminants in two European commercial PCBs.[12] It is possible that other PCBs are also contaminated with these or other highly toxic substances.[13] The effect of two PCBs, Aroclor 1254 and Aroclor 1260, on Sherman strain rats, was studied in our laboratory to gain better insight into the toxicity of these commercial products. The Aroclor 1260 was from the same lot as that studied by Vos and Koeman.[11]

Materials and Methods

Sherman strain rats were used in these experiments. The animals were caged individually and weighed weekly. To determine the single dose oral LD_{50}, Aroclor 1254 and 1260 were given in peanut oil to groups of ten rats/dosage level by stomach tube as described by Gaines.[14] Survivors were observed for a minimum of 15 days after treatment. The method of Litchfield and Wilcoxon[15] was used to calculate the LD_{50} values.

When the Aroclors were fed in the diet they were dissolved in ether and mixed with cornstarch. The ether was allowed to evaporate and the Aroclor-cornstarch mixture was mixed into increasing amounts of ground chow. In the feeding studies, 3 to 4-week-old male and female rats were distributed in groups of ten rats of each sex according to a table of random numbers. Their food consumption was measured during the second, fifth, 11th, 22nd, and 30th week of exposure to the dietary levels of 0, 100, 500, and 1,000 ppm, and at similar intervals in the groups fed 20 ppm and their controls. The rats fed 20 ppm were set up at a later date than the other dietary levels. For

Table 1.—Mean Body Weight Gain and Liver Weights of Rats Fed Aroclor 1260*

Sex	Dietary Level (ppm)	Dosage Level (mg/kg/day)	Weight Gain (gms)	Liver Weights (gms)	Relative Liver Weights: Fraction of Body Weight (%)	Relative Liver Weights: Difference From Controls
M	0	0	451	14.56	2.59	...
M	100	6.5	463	18.87	3.23	$P<.001$
M	500	32.8	398	22.01	4.25	$P<.001$
M	1,000	71.4	351	22.46	4.91	$P<.001$
F	0	0	256	11.23	3.12	...
F	100	7.2	253	12.20	3.40	$P>.10$
F	500	38.2	185	12.67	4.52	$P<.001$‡
F	1,000†	72.4	148	15.85	6.35	...
M	0	0	435	12.77	2.39	...
M	20	1.4	455	16.63	3.02	$P<.001$
F	0	0	226	11.94	3.74	...
F	20	1.6	233	12.68	3.86	$P>.50$

* In diet for eight months; ten rats/group. † Only two animals survived. ‡ For the actual liver weight $P>.05$.

Table 2.—Mean Body Weight Gain and Liver Weights of Rats Fed Aroclor 1254*

Sex	Dietary Level (ppm)	Dosage Level (mg/kg/day)	Weight Gain (gms)	Liver Weights (gms)	Relative Liver Weights: Fraction of Body Weight (%)	Relative Liver Weights: Difference From Controls
M	0	0	484	14.14	2.44	...
M	100	6.8	459	16.01	2.92	$P<.025$
M	500	36.4	315	24.48	5.95	$P<.001$
F	0	0	244	10.59	3.19	...
F	100	7.5	235	11.86	3.62	$P>.05$†
F	500	37.6	158	18.93	7.47	$P<.001$
M	0	0	453	13.96	2.53	...
M	20	1.4	439	15.38	2.90	$P<.025$
F	0	0	238	11.21	3.34	...
F	20	1.6	249	12.49	3.72	$P<.025$

* In diet for eight months; ten rats/group.
† Equal numbers of rats fed 100 ppm and 20 ppm, respectively, for same length of time did not show significant increase in actual liver weight ($P<.1$ and $>.05$); however, the increase in relative liver weight was significant $P<.01$.

MONS 204973

this reason, a second group of controls for each sex was added to the experiments (Tables 1 and 2). All animals that were fed PCB as well as their controls were used in reproduction studies. The results of the reproduction studies will be reported separately. At autopsy, the tissues were fixed in a buffered 4% solution of formaldehyde (formalin). They were stained with hematoxylin-eosin for light microscopic study. Selected liver sections were cut on the cryostat and stained with Oil red O. Perls' stain for iron and a PAS stain were also performed on a few selected livers. Tissue from the livers of two male and two female rats at each dietary level except 20 ppm were minced and fixed in chilled 5% buffered glutaraldehyde for two hours, postfixed for two hours in 1% osmic acid (osmium tetroxide), dehydrated through changes of alcohol and propylene oxide, and embedded in resin. Sections were cut with a glass knife, stained with lead citrate and uranyl acetate, and examined with the electron microscope. In a preliminary experiment, Aroclor 1254 at the dietary level of 1,000 ppm for three months killed most of the rats. Tissue from this preliminary experiment was examined only under the light microscope.

Results

There was considerable varintion, in both sexes, in the acute, oral, toxic effects of Aroclor 1260 and 1254 at various dosage levels. It was impossible to calculate LD_{50} values. The data indicated that the LD_{50} values were about 4,000 to 10,000 mg/kg for both mixtures. Autopsies of rats killed by either mixture revealed hemorrhage into the lung, stomach, and pancreas. Foci of ulceration surrounded by a severe inflammatory reaction were observed primarily in the duodenum and occasionally in the glandular part of the stomach.

When the material was fed in the diet over a period of time, porphyria was observed in a number of animals poisoned with either mixture. The liver fluoresced most consistently under the UV light. Occasionally, fluorescence of bones, serum, and urine was observed. A more detailed study of this phenomenon will be reported later.

When Aroclor 1260 was fed daily to groups of ten male and ten female rats each

Table 3.—Light Microscopic Findings in the Liver of Rats Fed Aroclor 1260*

Dietary Level (ppm)	Sex	Enlarged Hepato-cytes	Inclusions in Cytoplasm	Adeno-fibrosis	Increased Lipid	Foamy Cytoplasm	Pigment
0	M	...	...	...	...	...	...
20	M	10	9	...	...	3	...
100	M	10	9	...	10	...	...
500	M	10	4	...	10	7	1
1,000	M	10	6	2	10	9	2
0	F	...	...	...	...	...	...
20	F	3	...	...	...	...	...
100	F	7	2	1	10	...	1
500†	F	9	5	1	9	8	6
1,000‡	F	6	...	4	7	4	2

* In their diet for eight months; ten rats/group. † Only nine animals were studied. ‡ Only seven animals were studied.

Table 4.—Light Microscopic Findings in the Liver of Rats Fed Aroclor 1254*

Dietary Level (ppm)	Sex	Enlarged Hepato-cytes	Inclusions in Cytoplasm	Adeno-fibrosis	Increased Lipid	Foamy Cytoplasm	Pigment
0	M	...	...	...	...	...	...
20	M	7	1	...	...	1	...
100	M	10	7	1	10	10	3
500	M	10	2	10	10	4	2
0	F	...	...	...	...	...	...
20	F	...	...	...	...	...	1
100	F	10	7	7	10	9	10
500†	F	9	2	9	9	2	7

* In their diet for eight months; ten rats/group.
† Only nine tested since one rat that died showed too much autolysis.

MONS 204974



Fig 1.—Liver section of male rat fed 500 ppm Aroclor 1260 for eight months. Note foamy cytoplasm of many of hepatocytes (hematoxylin-eosin ×125).



Fig 2.—Section of liver from male rat fed 1,000 ppm Aroclor 1254 for eight months illustrating adenofibrosis. Note area of fibrosis which surrounds ductules of glandular cells. Cellular debris, polymorphonuclear leukocytes, or mucus can be observed in lumen of ductules (hematoxylin-eosin ×125).

at dietary levels of 0, 20, 100, 500, and 1,000 ppm for eight months, none of the control rats and none of the male rats fed the mixture died. One female fed 100 ppm died after six months exposure and two females fed 500 ppm died after one and two months exposure. Eight females fed 1,000 ppm died within two to six months after onset of the experiment. The rats fed 500 and 1,000 ppm Aroclor 1260 in their diet gained less weight than the controls. At autopsy, the livers of all male rats fed Aroclor 1260 weighed significantly more than the livers of the controls (Table 1). The livers of the female rats were larger also but a significant weight difference was not observed, except that at 500 ppm the percent of body weight of the livers was increased as a result of the reduced weight gain of these animals (Table 1).

Grossly, the livers of the exposed animals were soft and often yellowish brown or dark olive. Grayish-white, firm, glistening areas, measuring up to 0.5 cm in diameter, were seen on cross section in a number of livers. The dark livers showed pink-orange fluorescence under the UV light.

Fig 3.—Area of adenofibrosis as in Fig 2 from female rat fed 500 ppm Aroclor 1254 for eight months. Area was examined under electron microscope (Fig 8-10) (toluidine blue ×300).

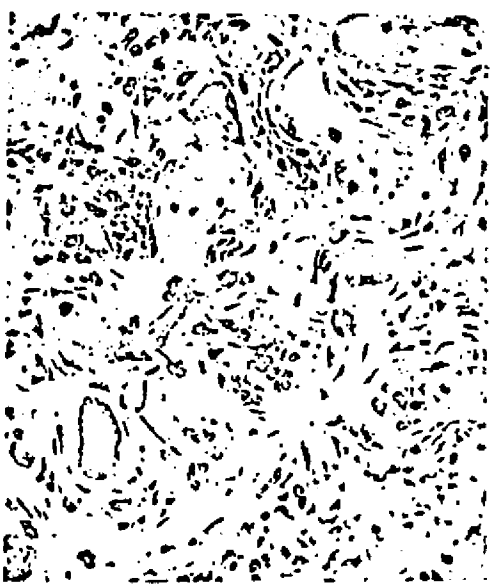

MONS 204975

The incidence of the various light microscopic findings of the livers are given in Table 3. They consisted of hypertrophy of the individual liver cells. Often the nuclei were hyperchromatic and showed pleomorphism, and occasional mitotic figures were observed. The cytoplasm had either large vacuoles or appeared foamy (Fig 1). Eosinophil inclusions identical to those described in the liver of rats that have been exposed to DDT,[16] mirex,[17] or dieldrin[18] were also observed. The Kupffer cells and perivascular macrophages of some livers contained a brown pigment. Frozen sections of livers containing the brown pigment fluoresced pink under UV light which is consistent with the presence of porphyrin. Some of the pigment showed a positive staining reaction for iron with Perls' stain as well. In addition to these findings, some livers also exhibited focal areas of fibrosis which contained glandular structures (Fig 2 and 3) that either formed strands or dilated cystic ducts that were filled with cellular debris (polymorphonuclear leukocytes) or a mucus-like PAS-positive substance. The glandular cells had a pale, scanty, basophilic cytoplasm and usually a hypochromatic nucleus. The areas of adenofibrosis corresponded to the grayish-white, glistening areas described grossly. The glandular epithelium appeared stratified in some areas. Electron microscopic study revealed (Fig 4 to 10) an increase in smooth endoplasmic reticulum (Fig 5) in the hepatocytes of all but the control rats (Fig 4). Many large and small lipid vacuoles and occasional atypical mitochondria were also seen. At the dietary level of 100 ppm, dark and light cells, dilated bile ducts, and granular cytoplasmic inclusions were additional findings (Fig 6). At the dietary level of 500 and 1,000 ppm, concentrically arranged membranes which surrounded lipid vacuoles were also observed. They have been previously described in livers of rats fed DDT and dieldrin.[18] The cytoplasm of many cells had a loosened-up, "moth eaten" appearance (Fig 7), with occasional vacuoles containing a few strands of electron-dense material. These cells corresponded to the hepatocytes with foamy cytoplasm observed under the light microscope. Widening of intercellular spaces, occasional phagocytized red blood cells, and an increase in collagen were observed. The nodular, grayish-white areas (Fig 8) that represented

Fig 4.—Section from normal male rat liver. N, nucleus; M, mitochondria; RER, rough endoplasmic reticulum; SER, smooth endoplasmic reticulum (lead citrate, uranyl acetate ×13,490).



MONS 204976



Fig 5.—Section from male rat liver fed 100 ppm Aroclor 1260 for eight months. Note large amount of smooth endoplasmic reticulum. SER, smooth endoplasmic reticulum; M, mitochondria; N, nucleus (lead citrate, uranyl acetate ×34,200).

Fig 6.—Section from liver of female rat fed 500 ppm Aroclor 1260 for eight months. Note small and large vacuoles within cytoplasm, some filled with lipid and others with strands of dark granular material (arrows). V, vacuoles; M, mitochondria; CB, cell border; BC, bile canaliculus; RER, rough endoplasmic reticulum; SER, smooth endoplasmic reticulum (lead citrate, uranyl acetate ×13,490).



MONS 204977



Fig 7.—Section from liver of male rat fed 1,000 ppm Aroclor 1260 for eight months. Note "moth-eaten" appearance of the cytoplasm (lead citrate, uranyl acetate ×13,490).

Fig 8.—Section from liver of female rat fed Aroclor 1254 for eight months. Note large amount of collagen, fibroblasts, and epithelial cells lining a ductule. C, collagen; FB, fibroblast; N, nucleus; EC, epithelial cell (arrow); DL, lumen of ductule (lead citrate, uranyl acetate ×5,320).



MONS 204978

extensive foci of adenofibrosis consisted of fibroblasts and a great deal of collagen that surrounded rosettes of epithelial cells. These cells were cuboidal or columnar in shape. The free surface was lined by microvilli, and cells contained large, pale nuclei. The cytoplasm was granular, with many ribosomes and a few endoplasmic membranes. Some of these liver duct cells contained a great deal of mucus and resembled goblet cells similar to those observed in the intestinal tract (Fig 9). The cytoplasm contained tonofilaments and, particularly near the duct lumen, the boundaries between adjacent cells were marked by prominent terminal bars (Fig 10).

In a preliminary study in which 1,000 ppm Aroclor 1254 was fed in the diet to ten male and ten female rats, five of the males and eight of the females died. At autopsy of the exposed animals, the livers were pale and enlarged and contained firm, grayish-white, glistening areas. One male rat that died after 49 days exposure showed only slight enlargement of the liver cells. The hepatocytes of all the other exposed rats were enlarged, vacuolated often with hyperchromatic—sometimes enlarged and sometimes pyknotic—nuclei which occasionally displayed mitotic figures. Varying degrees of fibrosis around the bile ducts were observed. Hyperplasia and proliferation of glandular cells simulating bile ducts were also seen in these areas. In some areas, the sinusoids were dilated and contained cellular debris, lined by small "compressed" hepatocytes. A brown pigment was seen within the macrophages. A few livers stained with Oil red O showed a large amount of red staining (lipid) material. The animals that died not only had liver lesions but also suffered from severe pulmonary congestion and, in a few instances, from massive hemorrhages into the soft tissue or the peritoneal cavity.

When 500, 100, 20, and 0 ppm Aroclor 1254 were fed to the rats for eight months, two males and one female rat died at 500 ppm, but none died at the lower dietary levels. The rats fed 500 ppm Aroclor 1254 gained less weight than the controls. The

Fig 9.—Section from same liver as Fig 8. Note goblet cell containing mucus and degenerated cells within lumen of ductule. C, collagen; EC, epithelial cell; N, nucleus; CB, cell border (arrow); DL, lumen of ductule (arrow); MU, mucus goblet cell (lead citrate, uranyl acetate ×11,400).



MONS 204979



Fig 10.—Higher magnification of two epithelial cells from Fig 9 showing T, tonofilaments; D, desmosomes; N, nucleus; M, mitochondria; CB, cell border (lead citrate, uranyl acetate ×34,200).

livers of the exposed groups were larger than those of the controls (Table 2). This was significant in all but the female rats fed 100 ppm. At autopsy, the livers of the exposed animals, particularly at the higher dietary levels, were soft, yellowish-brown, or dark olive. Firm, grayish-white, glistening areas were seen, especially in those fed higher PCB levels. Occasionally, the liver surface was nodular. These livers also fluoresced when exposed to UV light. The light microscopic findings are given in Table 4. The observed changes in the livers of exposed rats were quite similar to those described for Aroclor 1260, except that all male rats at 500 ppm and one male rat at 100 ppm had areas of adenofibrosis in their liver, while none of the males demonstrated this at the respective dietary levels of Aroclor 1260. In the females, the incidence of adenofibrosis was much higher at the same dietary levels of Aroclor 1254 than in those fed Aroclor 1260. The electron microscopic examination of the different liver changes summarized in Table 4 corresponded to those already described for Aroclor 1260.

The main difference between the two compounds was the much higher incidence of adenofibrosis at a lower dietary level of Aroclor 1254. When fed over a period of time, Aroclor 1260 seemed to be more toxic to female rats. Such a sex difference could not be established for Aroclor 1254.

Comment

Aroclor 1260 and 1254 have a definite effect on the liver. This effect is more pronounced with Aroclor 1254 when all morphologic changes of equivalent dietary levels of Aroclor 1254 and 1260 are compared. All dietary levels tested so far showed an increase in the size of the individual liver cells and often an increase in the liver weights. Accumulation of fat was observed at 100 ppm, and it was very pronounced at the higher dietary levels. The incidence of cytoplasmic inclusions was higher at the lower dietary levels. This is probably due to the fact that at the higher dietary levels most of the cytoplasmic components have been replaced by lipids. The pigment observed in the Kupffer cells showed a positive prussian blue reaction and represented, at least in part, hemosiderin. The fluorescence of the livers under UV light was caused by the presence of porphyrin, which resulted in the dark discoloration of the liver.

An additional finding in the livers was the presence of grayish-white, glistening areas which microscopically corresponded to adenofibrosis. This lesion consisted of glandular, often mucus-producing, epithelial cells forming ductules. They were surrounded by fibrosis. Synonyms for this lesion are cholangiofibrosis, bile duct proliferation, bile duct adenomatosis, and fibroadenoma. Stewart

MONS 204980

and Snell[10] give an excellent description of adenofibrosis of the liver of rats. The authors concluded that "adenofibrosis is a contracting lesion built up by the incorporation and transformation of normal (hepatic cords) and pathologic (pseudotubules) components of the surrounding liver. Thus far there is no convincing evidence that adenofibrosis is a precancerous lesion." Adenofibrosis, for instance, has been described in livers of rats fed butter yellow (p-dimethylaminoazobenzene).[20] Recently, Reuber[21] fed hamsters 2-acetamidofluorene or 2-diacetamidofluorene and produced adenocarcinomas. He thought that some of these carcinomas originated from bile ducts. The author interpreted adenofibrosis as cholangiofibrosis, suggesting that adenofibrosis in the rat was a precancerous lesion and was identical to the lesions he observed in hamsters which, in his opinion, also represented a precancerous lesion. He postulated that the observed cholangiocarcinomas developed from the adenofibrosis. Glaser and his colleagues[22] produced a highly malignant transplantable tumor, derived from the liver of a hamster fed 2-acetylaminofluorene, that did not appear to be malignant in the donor but showed changes similar to the adenofibrosis described in this paper. It is possible that the malignant lesion was not simply derived from the adenofibrosis-type lesion but from cells that already manifested irreversible preneoplastic changes that were not microscopically detectable.

Miller[9] found fatty livers, liver necrosis, and inclusions in the cytoplasm of the hepatocytes in rats that had been exposed to a biphenyl with 42% chlorination. He did not mention adenofibrosis in his report. However, he studied a different biphenyl and his animals were exposed to the chemical for much shorter periods of time. Nishizumi[7] studied the effect of a biphenyl with 48% chlorination in monkeys and mice. The longest exposure time was 26 weeks. He described enlargement of the liver, fatty changes, granular cytoplasm of the hepatocytes, increase in size of Kupffer cells and hepatocytes, and a brown pigment in some of these cells, but did not observe adenofibrosis. At some stages of exposure he observed, with the electron microscope, an increase in the smooth endoplasmic reticulum, variation in the appearance of mitochondria, and an increase in the number of microbodies, as well as "myelin figures" which seem to be similar to the concentrically arranged membranes that have been described in rats after exposure to chlorinated hydrocarbons.[15] The increase in liver weights and the observation of inclusions in the cytoplasm has been reported for several persistent insecticides.[16-18] To our knowledge adenofibrosis has not been produced with chemicals such as DDT, dieldrin, pyrethrum, piperonyl butoxide, and mirex. Unlike Nishizumi's findings,[7] an increase in the number of microbodies was not observed in the rats fed PCBs in this study.

The increase in smooth endoplasmic reticulum has also been observed with other chemicals, and it is not surprising that chlorinated biphenyls induce microsomal enzymes.[23-25]

Study of the adenofibrosis under the electron microscope shows the epithelial component of the lesion consisting of two types of cells—goblet cells and epithelial cells with granular cytoplasm, tonofilaments, and desmosomes. The latter cells resemble the epithelial cells lining the bile ducts rather than hepatocytes. The epithelial cells are reminiscent of "oval" cells which are thought to represent ductular cells. However, the oval cells are smaller and have a hyperchromatic nucleus.[26] Whether they develop originally from bile duct epithelium or from other cells in the liver needs further investigation. The fact that adenofibrosis has not been observed in previous feeding studies with PCBs may have a variety of reasons such as the length of exposure, the animal species or rat strain, and the composition of PCB given to the rats. Contamination of PCBs with traces of other chemicals such as chlorinated dibenzodioxins, chlorinated dibenzofurans, or chlorinated naphthalenes may also be responsible. Vos and Koeman[11] checked Aroclor 1260 of the same lot and also did not demonstrate any contaminants. However, preliminary chemical analyses of this lot of Aroclor 1254 suggest possible contamination with a chlorinated dibenzofuran. This is still under investigation.[27]

The significance of adenofibrosis will be further investigated in order to establish whether it is an irreversible lesion and whether it is transplantable. From experi-

MONS 204981

ence with DDT and other chlorinated hydrocarbons, it can be deduced that the liver enlargement, as expressed by hypertrophy of the liver cells and the observation of inclusions in the cytoplasm, is reversible after cessation of exposure.

The observed porphyria, which was also noted by Vos and Koeman,[11] and the effect of PCBs on the liver, particularly the adenofibrosis, make it necessary to reevaluate our present concept of the toxicity of PCBs. Additional information is also needed on the interaction of PCBs with substances such as alcohol, chlorinated hydrocarbons, sex hormones, lead, and, of course, the various contaminants that may or may not be present in the PCBs. The quality of the diet may have an impact on the effect of PCBs. The findings described in this paper support the conclusion of Lichtenstein et al[28]—that the toxicity of the PCBs decreases as the level of chlorination increases.

Richard L. Moore assisted with the animal tests. Estelle C. Gray did the statistical analysis. Linda W. Anderson and Annie R. Alford prepared the tissues.

Aroclor 1254 (lot No. AK-38) and Aroclor 1260 (lot No. AK-3) were provided gratis by Monsanto Chemical Co, St. Louis, Mo.

References

1. Risebrough RW, Rieche P, Peakall DB, et al: Polychlorinated biphenyls in the global ecosystem. *Nature* 220:1,078-1,102, 1968.

2. Jones JW, Alden HS: An acneform dermatergosis. *Arch Derm Syph* 33:1,022-1,034, 1936.

3. Miller JW: Pathologic changes in animals exposed to a commercial chlorinated diphenyl. *Public Health Rep* 59:1,085-1,093, 1944.

4. Bennett GA, Drinker CK, Warren MF: Morphological changes in the livers of rats resulting from exposure to certain chlorinated hydrocarbons. *J Indust Hyg Toxicol* 20:97-123, 1938.

5. Von Oettingen WF: *The Halogenated Hydrocarbons: Toxicity and Potential Dangers*, publication 414. US Public Health Service, 1955, pp 306-307.

6. Kuratsune M, Morikawa Y, Hirohata T, et al: An epidemiologic study on "yusho" or chlorobiphenyls poisoning. *Acta Med (Fukuoka)* 60:513-532, 1969.

7. Nishizumi M: Light and electron microscope study of chlorobiphenyl poisoning: In mouse and monkey liver. *Arch Environ Health* 21:620-632, 1970.

8. Pichirallo J: PCB's: Leaks of toxic substances raises issue of effects regulations. *Science* 173:899-902, 1971.

9. McCune EL, Savage JE, O'Dell BL: Hydropericardium and ascites in chicks fed a chlorinated hydrocarbon. *Poult Sci* 41:295-299, 1962.

10. Flick DF, O'Dell BG, Childs VA: Studies of the chick edema disease: III. Similarity of symptoms produced by feeding chlorinated biphenyls. *Poult Sci* 44:1,402-1,405, 1965.

11. Vos JG, Koeman JH: Comparative toxicologic study with polychlorinated biphenyls in chickens with special references to porphyria, edema formation, liver necrosis and tissue residues. *Toxic Appl Pharmacol* 17:656-668, 1970.

12. Vos JG, Koeman JH, van der Maas HL, et al: Identification and toxicological evaluation of chlorinated dibenzofuran and chlorinated naphthalenes in two commercial polychlorinated biphenyls. *Food Cosmet Toxic* 8:625-655, 1970.

13. Kimbrough RD: Toxicity of chlorinated hydrocarbons and related compounds including chlorinated dibenzodioxins and chlorinated dibenzofurans: A review. *Arch Environ Health* 25:125-131, 1972.

14. Gaines TB: The acute toxicity of pesticides to rats. *Toxic Appl Pharmacol* 2:88-99, 1960.

15. Lichtfield JJ, Wilcoxon F: A simplified method of evaluating dose-effect experiments. *J Pharmacol Exp Ther* 96:99-133, 1949.

16. Kimbrough RD, Gaines TB, Hayes WJ: Combined effect of DDT, pyrethrum, and piperonyl butoxide on rat liver. *Arch Environ Health* 16:333-341, 1968.

17. Gaines TB, Kimbrough RD: Oral toxicity of mirex in adult and suckling rats: With notes on the ultrastructure of liver changes. *Arch Environ Health* 21:7-14, 1970.

18. Kimbrough RD, Gaines TB, Linder RE: The ultrastructure of livers of rats fed DDT and dieldrin. *Arch Environ Health* 22:460-467, 1971.

19. Stewart HL, Snell KC: The histopathology of experimental tumors of the liver of the rat: A critical review of the histopathogenesis. *Acta Unio Internationalis Contra Cancrum* 13:770-803, 1957.

20. Edwards JE, White J: Pathologic changes with special reference to pigmentation and classification of hepatic tumors in rats fed p-dimethylaminoazobenzene (butter yellow). *J Nat Cancer Inst* 2:157-183, 1941.

21. Reuber MD: Histogenesis of cholangiofibrosis and well differentiated cholangiocarcinoma in Syrian hamsters given 2-acetoaminofluorene or 2-diacetoamidofluorene. *Gann* 59:239-246, 1968.

22. Glaser OG, Newberne PM, Gabliks J, et al: Transplantable malignant cholangiocarcinoma from hamster liver. *Arch Environ Health* 23:137-141, 1971.

23. Street JC, Urry FM, Wagstaff DJ, et al: Comparative effects of polychlorinated biphenyls and organochlorine pesticides in induction of hepatic microsomal enzymes. Read before the 158th meeting of the American Chemical Society, Pesticide Chemistry Division, New York, 1969.

24. Villeneuve DC, Grant DL, Phillips WEJ, et al: Effects of PCB administration on microsomal enzyme activity in pregnant rabbits. *Bull Environ Cont Tox* 6:120-128, 1971.

25. Litterst CL, Farber TM, Baker AM, et al: Effect of Aroclors on hepatic microsomal enzymes in the rat, abstracted. *The Pharmacologist* 13:288, 1971.

26. Grisham JW, Harteroft WS: Morphologic identification by electron microscopy of "oval" cells in experimental hepatic degeneration. *Lab Invest* 10:317-332, 1961.

27. Cuiley A, Burse VW, Jennings R: Metabolite or contaminant of Aroclor 1254 found in rat urine. Read before the national meeting of the American Chemical Society, Division of Pesticide Chemistry, Boston, 1972.

28. Lichtenstein EP, Schulz KR, Fuhremann TW, et al: Biological interaction between plasticizers and insecticides. *J Econ Entom* 62:761-765, 1969.

Printed and Published in the United States of America

MONS 204982

Fd Cosmet. Toxicol. Vol. 12, pp. 63–77. Pergamon Press 1974. Printed in Great Britain

THE EFFECT OF POLYCHLORINATED BIPHENYLS ON RAT REPRODUCTION

R. E. LINDER*, T. B. GAINES and R. D. KIMBROUGH

Bio-Effects Branch, Primate and Pesticides Effects Laboratory, Environmental Protection Agency, 4770 Buford Highway, Chamblee, Georgia 30341, USA

(*Received 15 August 1973*)

Abstract—Reproduction, pathology and acute toxicity were studied in Sherman rats exposed to the polychlorinated biphenyls, Aroclor 1254 and Aroclor 1260. Rats exposed to Aroclor 1254 at dietary levels of 20 ppm or more had fewer pups per litter than the controls in the F_{1b} and F_2 generations. The 100 ppm exposure level of Aroclor 1254 increased mortality in the F_{1b} offspring and markedly decreased mating performance of the F_{1b} adults. The 500 ppm dietary level of Aroclor 1260 reduced litter size and decreased survival in the F_1 litters. Dietary levels of 5 ppm Aroclor 1254 and 100 ppm Aroclor 1260 had no effect on reproduction in rats exposed through two generations. Liver weights were increased in 21-day-old F_1 male weanlings at the 1 ppm level of Aroclor 1254 and in either sex of F_1 and F_2 weanlings at 5 ppm or higher levels of both Aroclor 1254 and 1260. Histological changes in the liver and increased liver weights were observed in adult rats exposed to the higher levels. Pregnant rats given Aroclor 1254 at the rate of 100 mg/kg/day on days 7–15 of gestation produced grossly normal litters, but only 30·1% of the pups survived to weaning. Reproduction and pup survival were not affected at dosage rates of 50 mg Aroclor 1254/kg/day or 100 mg Aroclor 1260/kg/day. Oral LD_{50} values in 3–4-wk-old male rats were 1295 and 1315 mg/kg for Aroclors 1254 and 1260, respectively. The iv LD_{50} for Aroclor 1254 in adult females was 358 mg/kg.

INTRODUCTION

Reproductive defects due to commercial mixtures of polychlorinated biphenyls (PCBs) have been reported in experimental birds (Dahlgren, Linder & Carlson, 1972) and mammals (Ringer, Aulerich & Zabik, 1972). Porphyria (Vos & Koeman, 1970), microsomal-enzyme induction (Street, Urry, Wagstaff & Blau, 1969) and liver damage (Kimbrough, Linder & Gaines, 1972; Miller, 1944) have also been reported in experimental animals exposed to PCB mixtures.

The present investigation was initiated in 1970 to study the effects on reproduction and pathology produced by two American-made PCB mixtures sold under the trade-names Aroclor 1254® and Aroclor 1260®. Aroclor 1254 contains 54% (w/w) chlorine and is composed of 11% tetra-, 49% penta-, 34% hexa- and 6% heptachlorobiphenyls; Aroclor 1260 has 60% (w/w) chlorine, with a composition of 12% penta-, 38% hexa-, 41% septa-, 8% octa- and 1% nonochlorobiphenyls (Thruston, 1971). An almost complete identification of isomers in Aroclor 1254 and Aroclor 1260 has been obtained (Sissons & Welti, 1971). Since 1970, the Monsanto Co., the only US manufacturer of PCBs, has voluntarily reduced sales of Aroclor mixtures and has taken steps to limit their use to closed systems (Monsanto Co., 1971).

The present communication is an account of reproduction studies in rats. Also included are acute toxicity values from preliminary studies and comments on pathology and haematology in animals from the reproduction experiments. A detailed account of the liver pathology of the F_0 rats given 20 ppm and higher dietary levels has been published (Kimbrough *et al.* 1972).

*Present address: United States Environmental Protection Agency, National Environmental Research Center, Research Triangle Park, North Carolina 27711.

®Registered trademark of the Monsanto Company.

Exhibit 3

MONS 204983

EXPERIMENTAL

Animals and materials. All animals used in the studies were Sherman-strain rats produced under specific-pathogen-free conditions. Aroclor 1254 (Lot AK-38) and Aroclor 1260 (Lot AK-3) were supplied by Monsanto Industrial Chemicals Company, St. Louis, Mo.

Experimental design and conduct

LD_{50} studies. The single-dose oral LD_{50} was determined for Aroclor 1254 and 1260 in weanling male rats (3–4 wk old). The iv LD_{50} was determined in adult females for Aroclor 1254. Between five and eight groups, each of ten rats, were used to obtain each LD_{50} value. The procedure described by Gaines (1969) was followed for oral dosing; Aroclor 1254 or Aroclor 1260 was dissolved in peanut oil and the solution was administered by oral intubation at the rate of 5 ml/kg. For iv dosing, Aroclor 1254 was first dissolved in peanut oil. One part of this solution was added to nine parts of a 1% lecithin–saline suspension and homogenized. This formulation was administered in a single injection via the tail vein at the rate of 5 ml/kg. A control group of five rats received 10% peanut oil in lecithin–saline in the same volume. Survivors were observed for 10–14 days.

Two-generation reproduction studies. For these studies the rats were fed either untreated ground laboratory chow (control) or ground chow fortified with Aroclor 1254 or Aroclor 1260. The Aroclors were dissolved in ether and mixed with cornstarch. The ether was allowed to evaporate and the Aroclor–cornstarch mixture was mixed into increasing amounts of ground chow. Aroclor 1254 was fed at dietary levels of 0 (control), 1, 5, 20 and 100 ppm, while Aroclor 1260 was fed at levels of 0, 5, 20 and 100 ppm. Because exposure schedules had to be staggered, a specific control group was added each time one or more treated groups were started on a dietary regimen. The F_0 rats were started on the diets at 3–4 wk of age and the F_{1b} rats at weaning. Exposure was continuous through mating, gestation and lactation until the rats were killed. Ten males and 20 females were fed at each dietary level in both the F_0 and F_{1b} generations. The F_0 males at each dietary level and half of the females were caged individually. Other F_0 females and all the F_{1b} rats were caged in groups except during the reproduction cycle. Body weights were recorded weekly on F_0 rats, except during the reproduction phase, and food consumption was measured during wk 2 and 5, the week before each mating and the week after weaning of the F_{1a} litters. F_{1b} rats were weighed when started on the diet, during the week before mating and at sacrifice.

The F_0 rats were pair-mated when 3 and 7 months old to produce the F_{1a} and F_{1b} generations, respectively. Breeding-stock F_{1b} rats were selected at weaning from all available litters and pair-mated when 3 months old to produce the F_{2a} generation. F_{1b} rats on dietary levels of 0, 20 and 100 ppm Aroclor 1254 were mated a second time when 8 months old to produce the F_{2b} generation. Viability counts of offspring were made at birth, day 3, day 7 and day 21 (weaning). Litters were inspected daily for condition and the presence of dead pups. After the F_{1b} offspring had been weaned, ten adult F_0 rats of each sex were killed and their livers were weighed and fixed for histological examination. Following the weaning of the F_{2b} generation, for Aroclor 1254, and the F_{2a} generation, for Aroclor 1260, haematological values (total leucocyte count, haematocrit, haemoglobin and differential leucocyte count) were determined on ten adult F_{1b} rats of each sex at the dietary levels of 0, 20 and 100 ppm. These rats were then killed and weights of the spleen, heart, lungs, brain, kidneys, testes and liver were recorded. Tissues were fixed for microscopic study.

MONS 204984

At lower dietary levels, haematology was not done and only the livers were weighed. At dietary levels of 5 ppm or less of both Aroclors, one male and one female weanling from each of ten litters from each generation were killed at 21 days of age and the livers were weighed. F_{2a} weanlings at dietary levels of 0, 20 and 100 ppm Aroclor 1254, and F_{1b} and F_{2b} weanlings at levels of 0, 20 and 100 ppm Aroclor 1260 were killed in the same manner and the livers were fixed for further study.

One-generation reproduction studies. Preliminary studies were conducted on both Aroclors at dietary levels of 0, 100 and 500 ppm. The experimental design was the same as that described for the two-generation studies, except that only ten females were used. This study was terminated after the F_{1b} offspring had been weaned. Rats fed 500 ppm Aroclor 1254 were bred only once. Haematology values and organ weights were determined and tissues were examined microscopically on the F_0 rats.

Post-implantation exposure studies. Stock rats 100 days old were pair-mated. Insemination was verified by microscopic inspection of a daily vaginal smear. Counting the day of insemination as day 0, the females were dosed by oral intubation on days 7–15 of gestation (a total of nine doses). To maintain a constant dose volume on a body-weight basis, Aroclor 1254 or 1260 was dissolved in peanut oil at appropriate concentrations and these formulations were administered at the rate of 5 ml/kg body weight, based on day 7 of pregnancy. Aroclor 1254 was given at dosage levels of 0 (peanut oil only), 10, 50 and 100 mg/kg/day. Aroclor 1260 was given at dosage levels of 0 and 100 mg/kg/day. The females were allowed to deliver and the litters were observed through weaning.

Tissue preparation. Tissues were fixed in buffered 4% formaldehyde solution and stained with haematoxylin and eosin for microscopic examination. An Oil Red O stain on fixed frozen sections was used on occasional livers to demonstrate lipids.

Statistics and calculations

LD_{50} values were calculated by the method of Litchfield & Wilcoxon (1949). A *t* test was used for comparing the litter sizes, organ weights, body weights and haematological parameters of the treated groups with those of the control groups. Survival percentages of offspring were compared by the Mann–Whitney *U* test as proposed by Weil (1970). Food consumption values were arrived at by averaging the consumption of both males and females over the five periods in which food was measured.

RESULTS

LD_{50} studies on Aroclor 1254 and 1260

The single-dose oral LD_{50} for Aroclor 1254 in weanling male rats was 1295 mg/kg with 95% confidence limits of 1136–1476 mg/kg. The lowest lethal dose tested was 1200 mg/kg, and 1000 mg/kg produced mild diarrhoea. Signs of toxicity at lethal levels were diarrhoea, depression and salivation, with death occurring in 1–3 days.

For Aroclor 1260, the single-dose oral LD_{50} in weanling males was 1315 mg/kg with 95% confidence limits of 1174–1473 mg/kg. The lowest lethal dose tested was 1000 mg/kg. 800 mg/kg produced no signs of toxicity. Rats given lethal doses developed diarrhoea and depression, with death occurring in 1–7 days.

Under the same test conditions the estimated oral LD_{50} for Aroclor 1254 and 1260 in adult rats was 4–10 g/kg (Kimbrough *et al.* 1972).

The single-dose iv LD_{50} for Aroclor 1254 in adult female rats was 358 mg/kg with 95%

MONS 204985

confidence limits of 328–390 mg/kg. The lowest lethal dose tested was 300 mg/kg; 250 mg/kg produced dyspnoea, depression, diarrhoea and salivation soon after dosing. Most rats died within 25–110 min, but at the highest dose (400 mg/kg), death occurred as soon as 5 min after dosing in some animals. Rats that survived appeared normal after 48 hr. In the control group, which received the formulation vehicle only, one rat developed mild diarrhoea.

Preliminary one-generation reproduction studies on Aroclor 1254 and 1260

The reproduction summary for the Aroclor 1254 feeding studies is presented in Table 1. Exposure for 67 days (at the time of pair-mating) to 500 ppm Aroclor 1254 (37·0 mg/kg/day) resulted in fewer litters, smaller litter sizes and 100% mortality by day 3 in the F_{1a} pups. The survival of offspring of the rats fed 100 ppm (7·2 mg/kg/day) for 67 and 186 days before mating was reduced, only 85·9 and 68·1% of the pups surviving to weaning in the F_{1a} and F_{1b} generations, respectively. Litter sizes from both matings were smaller, but the difference was not statistically significant. The mean body weight of the 100 ppm pups at weaning was 7·8 and 10 g less than that of the controls for the F_{1a} and F_{1b} generations, respectively. This difference was probably dose-related, as the treated litters were smaller, but a statistical evaluation was not done. In general the pups appeared small, but otherwise were normal at weaning.

Aroclor 1260 fed at a dietary level of 500 ppm (35·4 mg/kg/day) for 67 and 186 days prior to mating markedly reduced live-litter size and survival-to-weaning in the F_{1a} and F_{1b} generations (Table 2). No effect on reproduction was observed in rats fed 100 ppm (6·9 mg/kg/day) in either the F_{1a} or F_{1b} generations.

The F_0 rats in the one-generation studies were sacrificed after exposure for 8 months. Organ-weight analysis indicated that the liver was the primary organ affected. As reported in the previous paper, the livers in male rats receiving either Aroclor 1254 or 1260 at dietary levels of 100 and 500 ppm were heavier than in controls; this was also observed in females fed Aroclor 1254 at levels of 100 and 500 ppm or Aroclor 1260 at 500 ppm (Kimbrough *et al.* 1972). The testes-to-body weight ratios of F_0 rats fed Aroclor 1254 or 1260 at the 500 ppm level were greater than those of the controls ($P < 0·025$). The difference in actual weight of the testes, however, was not significant. This observation may reflect the reduced body-weight gain observed in all F_0 rats fed the 500 ppm level of both Aroclors. No difference in other organ weights was found.

After 8 months exposure, terminal haematological values in F_0 rats indicated a reduction in haemoglobin and haematocrit ($P < 0·005$) in both sexes fed 500 ppm Aroclor 1254 or 1260. The haematocrit was reduced in males ($P < 0·05$) on 100 ppm Aroclor 1260, but haemoglobin values were normal in this group. The total leucocyte count was normal in rats fed Aroclor 1260, but there was a shift in the differential count. The number of lymphocytes was increased in females ($P < 0·005$) fed 100 and 500 ppm Aroclor 1260 and in males ($P < 0·05$) fed 500 ppm. A corresponding decrease ($P < 0·05$) in polymorphonuclear leucocytes was observed. Differential values for rats fed Aroclor 1254 were normal, but an increase ($P < 0·001$) in total leucocytes was observed in the 500 ppm females.

Two-generation reproduction studies on Aroclor 1254

F_0 rats fed 100 ppm Aroclor 1254 (7·6 mg/kg/day) for 62 or 188 days before mating produced smaller litters than the controls in both the F_{1a} and F_{1b} generations (Table 1). Survival-to-weaning was not affected in the F_{1a} offspring. Only 73·6% of the 100 ppm F_{1b} pups

MONS 204986

Most
as soon
er 48 hr.
oped mild

nted in Table
ber 1254 (37·0
ily by day 3 in
day) for 67 and
ring to weaning
as were smaller,
of the 100 ppm
and F_{1b} gene-
ted litters were
eared small, but

67 and 186 days
g in the F_{1a} and
rats fed 100 ppm

ure for 8 months
ected. As reported
54 or 1260 at diet-
s also observed in
at 500 ppm (Kim-
oclor 1254 or 1260
25). The difference
vation may reflect
level of both Aroc-

s indicated a reduc-
0 ppm Aroclor 1254
n Aroclor 1260, but
ount was normal in
The number of lym-
Aroclor 1260 and in
polymorphonuclear
54 were normal, but
pm females.

ys before mating pro-
rations (Table 1). Sur-
the 100 ppm F_{1a} pups

Table 1. *Reproduction and pup survival in groups of rats fed Aroclor 1254*

Generation	Dietary level (ppm)	Parental exposure (days)†	No. of females mated	No. of litters		Litter sizes‡		Total pups/group				Survival (%)	Mean body weight at weaning (g)
								Born (found)		Alive at			
				Born‡	Weaned	At birth	At weaning	Dead	Alive	Day 3	Weaning		
F_{1a}	0§	67	10	8	7	11·1	10·6	3	89	86	85	95·5	39·2
	100§	67	10	9	8	9·4	8·1	6	85	78	73	85·9	31·4
	500§	67	10	4 (2)	0	4·0*	—	5	8	0	0	0	—
	0	62	20	17	17	12·4	11·8	0	211	205	201	95·3	38·7
	20	62	20	19	19	11·7	11·5	3	222	220	219	98·6	38·3
	100	62	20	19	19	10·7*	10·3	10	204	199	196	96·1	32·9
	0	67	20	18	18	11·2	11·1	2	202	203	200	99·0	39·5
	1	67	20	16	15	9·2	9·1	3	147	145	145	98·6	42·3
	5	67	20	17	17	10·8	10·8	1	184	184	183	99·5	42·1
F_{1b}	0‡	186	10	7	7	11·6	11·6	1	81	81	81	100	37·9
	100§	136	10	8	6	11·8	8·0	0	96	74	64	68·1**	27·9
	0	188	20	17	17	12·3	11·1	2	209	194	189	90·4	37·1
	20	188	20	18	18	10·4*	10·1	1	188	187	181	96·3	39·0
	100	188	20	20	19	9·5**	7·0	6	189	164	139	73·6	32·1
	0	201	20	18	18	12·3	11·0	6	222	211	198	89·2	40·7
	1	201	20	18	17	11·1	9·8	3	200	194	176	88·0	35·0
	5	201	20	20	19	11·1	10·2	2	222	218	203	91·4	38·9
F_{2a}	0	129	20	18	18	12·5	12·2	0	225	221	220	97·8	35·5
	20	129	20	17	17	10·6*	10·1	5	181	174	171	94·5	36·8
	100	129	20	7 (2)	4	7·2**	5·6	7	36	29	28	77·8**	35·2
	0	125	20	19	19	11·7	11·5	3	223	220	218	97·8	37·4
	1	125	20	15	15	11·7	11·5	0	175	174	173	95·9	37·2
	5	125	19	17	17	12·1	11·7	1	205	199	198	96·6	35·7
F_{2b}	0	274	20	17	16	12·7	11·3	4	216	201	191	88·4	31·9
	20	274	20	12	12	9·6**	8·5	6	115	103	102	88·7	36·1
	100	274	20	4 (2)	2	3·5**	3·5	7	7	7	7	100·0	38·3

† Conception to mating for the parents of the F_{1a} and F_{1b} generations.
‡ Numbers in parentheses indicate numbers of litters in which no live offspring were found.
§ Number of live offspring/live litter born.
‖ One-generation study.
Values marked with asterisks differ significantly from the control value: *$P < 0.05$; **$P < 0.005$.

MONS 204987

survived to weaning, but this was not statistically significant ($P = 0.058$). Because of the poor condition of a number of the 100 ppm F_{1b} pups, all were held for 30-days post-weaning observation. Fifteen of these pups died within 30 days of weaning. The mean body weights of the 100 ppm F_1 generation pups from either mating was about 6 g less than the controls at weaning. This is probably significant, since the treated litters contained fewer pups. A reduction in litter size was also observed in the F_{1b} generation at 20 ppm (1·5 mg/kg/day).

F_{1b} rats bred after exposure for 129 or 274 days (conception to mating) to 20 or 100 ppm had smaller litters than the controls (F_{2a} and F_{2b} generations). A marked decrease in mating performance was observed in the 100 ppm group, in which only seven and four litters were born in the F_{2a} and F_{2b} generations, respectively. In each case two litters contained no viable offspring when first observed. The data also suggest a decrease in mating performance at 20 ppm, at which level only 12 F_{2b} litters were produced. Survival-to-weaning was reduced in the 100 ppm F_{2a} offspring. All 100 ppm F_{2b} offspring survived to weaning, but this is of little significance since only seven pups were found alive. No effect on reproduction was observed in rats fed 5 ppm (0·32 mg/kg/day) or 1 ppm (0·06 mg/kg/day) through two generations.

Although reproduction was not affected at lower dietary levels of PCBs, an increase in liver weight in 21-day-old weanlings was found at all levels tested (Table 2). At 5 ppm or higher, the liver-to-body weight ratios of weanlings were increased in both sexes in both

Table 2. *Mean liver weights of 21-day-old rats from parents fed Aroclor 1254 or 1260*

Aroclor	Generation	Dietary level (ppm)	Liver weight			
			Males		Females	
			g	% of body weight	g	% of body weight
1254	F_{1a}	0	1·40	3·69	1·38	3·83
		1	1·81*	4·01*	1·63	3·91
		5	1·92*	4·34*	1·86*	4·43*
	F_{1b}	0	1·58	3·69	1·58	3·84
		1	1·54	3·94*	1·49	3·92
		5	1·77	4·63*	1·72	4·75*
	F_{2a}	0	1·37	3·81	1·28	3·74
		20	2·26*	5·78*	2·23*	6·08*
		100	2·63*	6·93*	2·67*	7·10*
	F_{2b}	0	1·63	3·78	1·42	3·63
		1	1·49	3·74	1·36	3·69
		5	1·56	4·23*	1·38	4·09*
1260	F_{1a}	0	1·54	3·66	1·57	3·92
		5	1·73	4·18*	1·70	4·39*
	F_{1b}	0	1·59	3·73	1·55	3·93
		20	2·06*	5·04*	2·14*	5·18*
		100	2·59*	6·33*	2·59*	6·48*
	F_{2a}	0	1·35	3·59	1·29	3·90
		5	1·58	4·01*	1·52*	4·07*
	F_{2b}	0	1·65	3·82	1·64	4·02
		20	2·06*	5·21*	1·94	5·06*
		100	2·50*	6·12*	2·49*	6·85*
	F_{3a}	0	1·41	3·85	1·36	3·83
		5	1·66*	4·21*	1·60*	4·25*

*Values marked with an asterisk differ significantly from the control value: $*P < 0.05$.

MONS 204988

the F_1 and F_2 generations, but at 1 ppm the liver enlargement was observed only in the F_{1a} and F_{1b} male weanlings. No liver-weight increase was found in either sex of the 1 ppm F_2 weanlings.

In 10-month-old F_{1b} rats, an increase in liver-to-body weight ratios was observed in both sexes at 100 ppm, but at 20 ppm it was seen only in the males (Table 3). At 5 ppm or less no increase in liver weight was found in 6-month-old F_{1b} rats or in F_0 rats exposed for 10 months. Both sexes of F_0 rats fed 20 ppm or more Aroclor 1254 for 8 months had enlarged livers (Kimbrough *et al.* 1972). The testes-to-body weight ratios were increased ($P < 0.001$) in 100 ppm F_{1b} adult males. Body-weight gains of adults in all the test groups were comparable to those of the controls except in the F_{1b} females at 100 ppm, which gained less weight than the controls (Table 3). Reduced haemoglobin ($P < 0.005$) and haematocrit ($P < 0.025$) were observed in female F_{1b} adults at 100 ppm, while F_{1b} males at this level had reduced ($P < 0.05$) haemoglobin only. Haematological values at lower levels were normal. No dose-related signs of toxicity were observed in adult F_0 or F_{1b} rats fed 100 ppm or less.

Two-generation reproduction study on Aroclor 1260

No effect on reproduction was observed in rats fed Aroclor 1260 at levels of 100, 20 or 5 ppm (7·4, 1·5 and 0·39 mg/kg/day) through two generations (Table 4). The liver-to-body weight ratios of 21-day-old pups were increased at all dietary levels (Table 2). This effect was observed at the lowest level tested (5 ppm) in all generations.

An increase in liver-to-body weight ratios was observed at all dietary levels in F_{1b} males between 5 and 7 months old, but only at 100 ppm in the F_{1b} females (Table 3). After 8 months exposure, an increase in liver weight was observed at 20 and 100 ppm in F_0 males but not in females (Kimbrough *et al.* 1972). No effect on liver weight was found in either sex of F_0 rats fed 5 ppm for 8 months. The testes-to-body weight ratios of the 100 ppm F_{1b} males were increased ($P < 0.05$); at 20 ppm the increase was not significant. Body-weight gain in all test groups was comparable to the control groups. Haematological values were normal in the 20 ppm F_0 adults and in F_{1b} adults at 100 ppm or less. No signs of toxicity were observed in any of the test animals.

Post-implantation exposure studies on Aroclor 1254 and 1260

The data on reproduction and survival of offspring from females dosed during organogenesis is summarized in Table 5. Nine oral doses of Aroclor 1254 (100 mg/kg/day) given on days 7–15 of gestation resulted in a decrease in the survival of the pups. At this dose only 30·1% of the offspring of the treated group survived to weaning, compared with 98·2% in the control group, and the mean body weight of the test pups was 7·1 g less than that of the controls at weaning. No effect was observed in the groups receiving 50 mg/kg/day or less.

No effect on reproduction or survival was observed with Aroclor 1260 given at a rate of 100 mg/kg/day.

Summary of pathology after treatment with Aroclor 1254 and 1260

A detailed account of the liver pathology in the F_0 rats fed Aroclor 1254 or 1260 at 20 ppm or higher dietary levels has been published (Kimbrough *et al.* 1972). Of the rats considered in the current report, similar changes were observed in the liver of adult rats, particularly in the F_{1b} generations at the higher dietary levels. The incidence of the various

MONS 204989

Table 3. *Body weight, liver weight and liver pathology of F_0 and F_{1b} adult rats fed Aroclor 1254 or 1260.*

Generation	Sex	Exposure (days)	Dietary level (ppm)	Terminal body weight (g)	Liver weight		No. of livers examined	Liver pathology (no. of livers affected)						
					g	% of body weight		Enlarged hepatocytes	Inclusions	Foamy cytoplasm	Pigment	Fibrous strands	Adenofibrosis	Nodules
Aroclor 1254														
F_0	M	310	0	601	15·22	2·53	10	0	0	0	0	0	0	0
			1	602	15·88	2·60	10	0	0	0	0	0	0	0
			5	614	15·37	2·51	10	0	0	1	2	0	0	0
	F	313	0	370	10·34	2·80	10	0	0	0	1	0	0	0
			1	358	10·14	2·84	10	1	0	0	4	0	0	0
			5	362	10·66	2·94	10	4	1	0	3	0	0	0
F_{1b}	M	328	0	588	14·51	2·47	10	0	0	0	0	0	0	0
			20	602	16·11*	2·67*	8	8	3	7	1	0	0	0
			100	554	19·43*	3·54*	10	10	5	7	4	2	3	1
	F	328	0	349	9·92	2·85	10	0	0	0	0	0	0	0
			20	340	9·41	2·78	7	7	2	5	7	0	0	3
			100	300*	10·53	3·60*	10†	10	2	8	9	3	5	7
F_{1b}	M	190	0	475	11·13	2·34	10	0	0	0	0	0	0	0
			1	453	11·14	2·44	10	0	0	0	0	1	0	0
			5	495	12·19	2·46	10	2	0	2	0	1	0	0
	F	190	0	287	8·27	2·87	10	0	0	0	0	0	0	0
			1	294	8·44	2·86	10	1	1	0	0	4	0	0
			5	299	8·92	2·98	10	1	0	0	0	1	0	0
Aroclor 1260														
F_0	M	250	0	563	14·45	2·57	10	1	0	0	0	0	0	0
			5	567	15·06	2·65	10	3	0	2	0	0	0	0
	F	250	0	322	10·09	3·13	10	0	0	0	0	0	0	0
			5	331	10·80	3·25	10	1	0	0	0	0	0	0
F_{1b}	M	179	0	472	12·68	2·65	10	0	0	0	0	0	0	0
			20	494	14·72*	2·99*	10	8	5	4	0	0	0	0
			100	509	16·63*	3·27*	10	10	10	3	0	0	0	1
	F	179	0	297	9·66	3·27	10	0	0	0	0	0	0	0
			20	304	10·30	3·40	10	6	0	0	0	0	0	0
			100	304	11·14*	3·70*	10	9	0	1	5	2	1	2
F_{1b}	M	217	0	492	11·97	2·43	10	0	0	0	0	0	0	0
			5	505	13·16	2·60*	10	7	2	2	1	0	0	0
	F	217	0	279	7·93	2·84	10	0	0	0	0	0	0	0
			5	286	8·49	2·96	10	2	0	0	0	0	0	0

† Necrosis in two livers.
Values marked with an asterisk differ significantly from control group: * $P < 0·025$.

MONS 204990

								0	0	0	0	0	0

† Necrosis in two livers.
Values marked with an asterisk differ significantly from control group: $^{*}P < 0{\cdot}025$.

Table 4. *Reproduction and pup survival in groups of rats fed Aroclor 1260*

Generation	Dietary level (ppm)	Parental exposure (days)†	No. of females mated	No. of litters		Litter size‡		Total pups/group				Survival (%)	Mean body weight at weaning (g)
								Born (found)		Alive at			
				Born	Weaned	At birth	At weaning	Dead	Alive	Day 3	Weaning		
F_{1a}	0§	67	10	9	9	12·3	12·2	2	111	111	110	99·1	37·0
	100§	67	10	8	8	11·6	11·6	0	93	93	93	100·0	35·6
	500§	67	8	8	3	8·5**	3·3	10	68	55	26	38·2*	35·3
	0	63	20	19	19	11·7	11·2	2	223	217	213	95·5	40·9
	20	68	20	17	17	11·8	11·3	0	201	193	191	95·0	39·3
	100	63	20	17	17	11·6	11·2	1	197	192	191	97·0	38·0
	0	71	20	19	19	11·7	11·4	0	222	218	216	97·3	33·8
	5	71	20	18	18	12·1	11·8	1	217	213	212	97·7	38·5
F_{1b}	0§	186	10	9	8	12·1	10·3	1	109	96	93	85·3	40·9
	100§	186	9	5	5	11·0	10·8	0	55	54	54	98·2	36·2
	500§	186	8	6	2	6·7**	2·3	1	40	38	14	35·0	40·7
	0	187	20	17	17	11·1	11·0	6	189	189	187	98·9	40·8
	20	187	20	16	16	11·9	11·4	1	191	191	183	95·8	41·0
	100	187	20	13	13	10·4	10·1	5	135	131	131	97·0	39·2
	0	188	20	17	16	10·3	9·2	10	175	160	156	89·1	36·1
	5	188	19	16	15	11·2	10·6	2	179	171	170	95·0	39·3
F_{2a}	0	128	20	18	18	10·9	10·3	1	197	187	185	93·9	40·3
	20	128	20	19	19	11·3	11·1	1	215	213	211	98·1	38·7
	100	128	20	20	20	10·1	9·9	1	201	200	197	98·0	38·6
	0	127	20	13	13	11·8	11·6	1	153	152	151	98·7	34·8
	5	127	20	18	18	11·8	11·6	0	213	212	209	98·1	38·5

† Conception to mating for parents of the F_{2a} generation.
‡ Numbers of live offspring/live litter born.
§ One-generation study.
Values marked with asterisks differ significantly from the control value: $^{*}P < 0{\cdot}025$; $^{**}P < 0{\cdot}001$.

MONS 204991

Table 5. *Reproduction and survival of pups from dams dosed orally with Aroclor 1254 or 1260 on days 7–15 of pregnancy*

Dose (mg/kg/day)	No. of females treated	No. of litters		Litter size†		Total pups/group				Survival (%)	Mean body weight at weaning (g)
						Born (found)		Alive at			
		Born	Weaned	At birth	At weaning	Dead	Alive	Day 3	Weaning		
					Aroclor 1254						
0	9	9	9	12·3	12·1	0	111	110	109	98·2	37·9
100	9	7	5	11·9	3·6	8	83	64	25	30·1*	30·8
0	10	10	10	11·9	11·8	0	119	119	118	99·1	40·6
10	9	9	9	12·1	12·0	0	109	109	108	99·1	37·6
50	10	10	10	13·4	12·7	0	134	131	127	94·8	30·5
					Aroclor 1260						
0	12	12	12	12·0	11·5	4	144	140	138	95·8	33·9
100	12	12	11	11·7	10·3	10	140	135	124	88·6	33·9

† No. of live offspring/litter born.
The value marked with an asterisk differs significantly from the control value; $^*P < 0.001$.

MONS 204992



Fig. 1. Section of rat liver, showing a hepatic nodule measuring 0·2 cm in diameter surrounded by normal liver cells (arrow at margin of hepatic nodule). The hepatocytes within the nodule are larger than those of the surrounding tissue and stain less well. Haematoxylin and eosin × 100.

MONS 204993

DISCUSSION

The results of our studies confirm the capability of some commercial PCB mixtures to alter reproductive processes in mammals. Our data are in general agreement with those of Keplinger, Fancher & Calandra (1971), who observed effects on mating performance and/or pup survival in rats fed 100 ppm Aroclor 1242 or 1254, but found no effect at the same dietary level of Aroclor 1260. In our study, 20 ppm Aroclor 1254 affected litter size and probably decreased mating performance in the second mating of the F_{1b} rats. The trend suggested the possibility that even lower levels might affect reproduction in subsequent generations, but M. L. Keplinger (personal communication 1973) found no effect through three generations in rats fed 10 ppm Aroclor 1254. Reproductive failure in mink exposed to PCBs has also been reported (Ringer *et al.* 1972). Although actual PCB consumption on a mg/kg basis was not reported, the mink is apparently more sensitive to PCB exposure than the rat, since levels of 1 and 5 ppm Aroclor 1254 affected reproduction after only 4 months' exposure. In the present study in rats, fewer pups per litter were observed at dietary levels of 500 ppm Aroclor 1260 and of 20 ppm or more of Aroclor 1254. Reported litter sizes are based on the pups found, but since it is common for the dam to eat dead or defective offspring, the reduced litter size probably reflects decreased fertility and/or increased perinatal and foetal mortality.

Aroclor 1254 (100 mg/kg/day) given to pregnant rats during gestation produced no effect on the viability or morphology of foetuses examined on day 22 of gestation (Villeneuve, Grant, Khera, Clegg, Baer & Phillips, 1971). In the present study under a similar dosing regimen, dams dosed orally during gestation with Aroclor 1254 (100 mg/kg/day) gave birth to litters that were grossly normal, but only 30-1% of the pups survived to weaning. Since PCBs are excreted in milk (Curley, Burse & Grim, 1973; Fries, 1972), it is possible that PCB ingestion via the milk contributed to the increased mortality of pups observed in both the post-implantation and dietary-exposure studies. The milk of rats 11 days after the last of nine daily doses of Aroclor 1254 (50 mg/kg/day) contained 66 ppm of PCB-derived material (Curley *et al.* 1973). Kimbrough *et al.* (1972) estimated the oral LD_{50} for Aroclor 1254 and 1260 at 4–10 g/kg in adult rats. From the oral LD_{50} values in weanlings in the present study (about 1300 mg/kg), it is evident that the Aroclor mixtures tested are considerably more toxic to immature rats than to adults. Although we have no acute toxicity data for PCBs in neonates, nor figures on their milk consumption, it is possible that lacteal exposure could approach a toxic level in suckling rats at the higher exposure levels.

In both the dietary and post-implantation studies, direct PCB exposure occurred *in utero*, since PCBs have been shown to cross the placenta (Curley *et al.* 1973; Grant, Villeneuve, McCully & Phillips, 1971). PCBs have been reported in eggs (Peakall, 1971) and embryonic mortality has been observed in birds treated experimentally with commercial PCB mixtures (Dahlgren *et al.* 1972; Peakall, Lincer & Bloom, 1972). Dahlgren *et al.* (1972) also reported a decrease in survival and a depression of weight gain in 6-wk-old pheasant chicks from hens treated with Aroclor 1254. In the present studies, similar effects were observed in young rats at the higher exposure levels of Aroclor 1254. Besides a reduction in observed litter size, there was additional evidence of late foetal mortality in the group given 100 ppm Aroclor 1254, no live offspring being found in four of the F_2 litters. Thus it is apparent that some PCB mixtures affect the embryo in both mammalian and avian systems, although the mechanism of this effect remains undefined.

Although the suckling rats ate some of the Aroclor-treated diet for 4–5 days before weaning, it is probable that the observed increase in liver weight in 21-day-old rats was

MONS 204994

due to PCB exposure via the mothers' milk. Curley *et al.* (1973) also observed a liver-weight increase in weanlings from dams dosed only during gestation. When Aroclor 1254 was given during pregnancy to rabbits, maternal liver weight was increased but not foetal liver weight on day 29 of gestation (Villeneuve *et al.* 1971), thus eliminating the possibility that placental transfer of PCB was the cause of the liver-weight increase seen in weanlings. When adult rats of the F_{1b} generation were killed after dietary exposure for 5–6 months, liver weights at the lower dietary levels were comparable to those in the controls except in males given 5 ppm Aroclor 1260. Presumably once exposure via the milk ceased, the livers returned to normal in spite of a continued low dietary intake of PCB. At a dietary level of 1 ppm Aroclor 1254, only the male weanlings of the F_{1a} and F_{1b} generations had enlarged livers. The absence of this effect in the F_{2a} weanlings is inconsistent. One explanation could be the credibility of the 1 ppm formulation. Problems inherent in consistently reproducing a 1 ppm formulation, as well as contamination of the basal diet with PCBs, are possible sources of error. Over the last 18 months this laboratory has analysed the basal diet for PCB contamination at 6-wk intervals. Most values have been less than 0·1 ppm, but occasionally values of up to 0·5 ppm have been found. The latter level of contamination would introduce a 50% error in a 1 ppm formulation. It is likely that 1 ppm in the parental diet is very near a threshold effect level for the observed liver-weight increase in weanling rats.

At the lower dietary levels, adverse effects were not observed in weanling rats, which exhibited only an increase in liver weight. However, Aroclor 1254 fed to 1-month-old rats at the 100 ppm dietary level (approximately 7·9 mg/kg/day) increased cytochrome *P*-450 and liver weight after 2 days and microsomal protein after 3 days, while a single oral dose of 10 mg/kg increased cytochrome *P*-450 after 24 hr (Goldstein, Hickman & Jue, 1973). A 50–70% increase in nitroreductase activity was observed with Aroclor 1254 and 1260 fed to rats at a dietary level of 0·5 ppm for 4 wk (Litterst, Farber, Baker & Van Loon, 1972). In view of these reports it is very probable that offspring in the reproduction studies, even those involving the lowest levels of PCBs, were subject to inductive effects.

Acknowledgements—We wish to thank Mr. R. L. Moore for assistance with the animal tests, Mrs. Estelle C. Gray for statistical analysis and Mrs. Linda W. Anderson and Mrs. Annie R. Alford for preparation of tissues.

REFERENCES

Bennett, G. A., Drinker, C. K. & Warren, M. F. (1938). Morphological changes in the livers of rats resulting from exposure to certain chlorinated hydrocarbons. *J. ind. Hyg. Toxicol.* 20, 97.

Curley, August, Burse, V. W. & Grim, Mary E. (1973). Polychlorinated biphenyls: Evidence of transplacental passage in the Sherman rat. *Fd Cosmet. Toxicol.* 11, 471.

Dahlgren, R. B., Linder, R. L. & Carlson, C. W. (1972). Polychlorinated biphenyls: their effect on penned pheasants. *Envir. Hlth Perspec.* 1, 89.

Fries, G. F. (1972). Polychlorinated biphenyl residues in the milk of environmentally and experimentally contaminated cows. *Envir. Hlth Perspec.* 1, 55.

Gaines, T. B. (1969). Acute toxicity of pesticides. *Toxic. appl. Pharmac.* 14, 515.

Goldstein, J. A., Hickman, P. & Jue, D. L. (1973). Hepatic porphyria induced by polychlorinated biphenyls (PCBs): Relationship between porphyria, delta-aminolevulinic acid synthetase and cytochrome P-450. Presented at the FASEB 57th Annual Meeting, 15–20 April 1973, Atlantic City, New Jersey.

Grant, D. L., Villeneuve, D. C., McCully, K. A. & Phillips, W. E. J. (1971). Placental transfer of polychlorinated biphenyls in the rabbit. *Envir. Physiol.* 1, 61.

Keplinger, M. L., Fancher, O. E. & Calandra, J. C. (1971). Toxicologic studies with polychlorinated biphenyls. Presented at the Tenth Annual Meeting, Society of Toxicology, 7–11 March 1971, Washington, D.C.

Kimbrough, R. D., Linder, R. E. & Gaines, T. B. (1972). Morphological changes in livers of rats fed polychlorinated biphenyls. *Archs envir. Hlth* 25, 354.

MONS 204995

Litchfield, J. T., Jr. & Wilcoxon, F. (1949). A simplified method of evaluating dose-effect experiments. *J. Pharmac. exp. Ther.* 96, 99.
Litterst, C. L., Farber, T. M., Baker, A. M. & Van Loon, E. J. (1972). Effect of polychlorinated biphenyls on hepatic microsomal enzymes in the rat. *Toxic. appl. Pharmac.* 23, 112.
Miller, J. W. (1944) Pathologic changes in animals exposed to a commercial chlorinated diphenyl. *Publ. Hlth Rep., Wash.* 59, 1085.
Monsanto Co. (1971). Monsanto releases PCB data. *Chem. Engng News*, 6 December, p. 15.
Peakall, D. B. (1971). Effect of polychlorinated biphenyls on the egg-shells of ring doves. *Bull. envir. contam. & Toxicol. (U.S.)* 6, 100.
Peakall, D. B., Linder, J. L. & Bloom, S. E. (1972). Embryonic mortality and chromosomal alterations caused by Aroclor 1254. *Envir. Hlth Perspec.* 1, 103.
Ringer, R. K., Aulerich, R. J. & Zabik, M. (1972). Effect of dietary polychlorinated biphenyls on growth and reproduction in mink. *American Chemical Society Reprints of Papers* 12 (2), 149.
Sissons, D. & Welti, D. (1971). Structural identification of polychlorinated biphenyls in commercial mixtures by gas-liquid chromatography, nuclear magnetic resonance and mass spectrometry. *J. Chromat.* 60, 15.
Street, J. C., Urry, F. M., Wagstaff, D. J. & Blau, A. D. (1969). Comparative effects of polychlorinated biphenyls and organochlorine pesticides in ioduction of hepatic microsomal enzymes. Presented at 158th Meeting of the American Chemical Society, 8–12 September 1969, New York.
Thruston, A. (1971). Quantitative analysis of PCBs. *PCB Newsletter*. No. 3, 28 July.
Villeneuve, D. C., Grant, D. L., Khera, K., Clegg, D. J., Baer, H. & Phillips, W. E. J. (1971). The fetotoxicity of a polychlorinated biphenyl mixture (Aroclor® 1254) in the rabbit and in the rat. *Envir. Physiol.* 1, 67.
Vos, J. G. & Koeman, J. H. (1970). Comparative toxicologic study with polychlorinated biphenyls in chickens with special reference to porphyria, edema formation, liver necrosis, and tissue residues. *Toxic. appl. Pharmac.* 17, 656.
Weil, C. S. (1970). Selection of the valid number of sampling units and a consideration of their combination in toxicological studies involving reproduction, teratogenesis or carcinogenesis. *Fd Cosmet. Toxicol.* 8, 177.

L'effet des biphényles polychlorurés sur la reproduction du rat

Résumé—On a étudié la reproduction, la pathologie et les indices d'intoxication aiguë chez des rats auxquels on administrait l'un ou l'autre des biphényles polychlorurés Aroclor 1254 et Aroclor 1260. Les rats qui recevaient l'Aroclor 1254 à raison de 20 ppm ou plus du régime avaient des nichées moins nombreuses que les animaux témoins aux générations F_{1b} et F_2. La dose de 100 ppm d'Aroclor 1254 a fait augmenter la mortalité dans la génération F_{1b} et fait nettement diminuer les performances d'accouplement des adultes de cette génération. Administré à raison de 500 ppm du régime, l'Aroclor 1260 a fait diminuer l'importance des nichées et le taux de survie des nichées F_1.

Des taux de 5 ppm d'Aroclor 1254 et de 100 ppm d'Aroclor 1260 sont restés sans effet sur la reproduction des rats soumis à ces régimes pendant deux générations. Le poids du foie a augmenté chez les mâles F_1 âgés de 21 jours au régime à 1 ppm d'Aroclor 1254 et chez les mâles et femelles F_1 et F_2 sevrés des groupes à 5 ppm ou plus d'Aroclor 1254 ou 1260. Des modifications histologiques du foie et des augmentations du poids de cet organe ont été observées chez les rats adultes qui recevaient les plus fortes doses. Des femelles gravides qui avaient reçu 100 mg d'Aroclor 1254/kg de poids vif et par jour du 7ème au 15ème jour de gestation ont mis bas des nichées à peu près normales, mais seulement 30,1% de ces jeunes ont survécu au sevrage. La reproduction et le taux de survie des jeunes n'ont pas été influencés par les doses de 50 mg d'Aroclor 1254/kg/jour et de 100 mg d'Aroclor 1260/kg/jour. Les valeurs DL_{50} orales chez les rats mâles âgés de 3–4 semaines étaient de 1295 mg/kg d'Aroclor 1254 et de 1315 mg/kg d'Aroclor 1260. La LD_{50} intraveineuse d'Aroclor 1254 était de 358 mg/kg chez les femelles adultes.

MONS 204996

Adenofibrosis in the Rat Liver

With Persistence of Polychlorinated Biphenyls in Adipose Tissue

Renate D. Kimbrough, MD; Ralph E. Linder; Virlyn W. Burse; Ralph W. Jennings, Chamblee, Ga

Fifty male Sherman strain rats were fed 500 ppm of a polychlorinated biphenyl (PCB) (Aroclor 1254) for six months. Five each were killed zero, one, two, three, four, six, eight, and ten months after exposure to Aroclor had ceased. The livers of these rats were examined by light and electron microscopy. Liver lesions persisted although exposure to PCBs ceased.

Ten months after exposure ceased, 1,192 ppm PCBs were still present in the rats' adipose tissue and 22.65 ppm in the rat livers.

Aroclor patterns found in the tissues by electron capture gas chromatography differed from patterns of dietary Aroclors. Mass spectral analysis of liver and adipose tissue revealed three major Aroclor components with masses of 324, 358, and 392. These contained isotopic clusters indicative of the presence of $C1_5$, $C1_6$, and $C1_7$, respectively.

In a previously reported study[1] Sherman strain rats were fed polychlorinated biphenyls (PCBs) (Aroclor 1254 and Aroclor 1260). The rats developed characteristic morphological changes in the liver. These changes consisted of hypertrophy of the liver cells, a brown pigment in Kupffer cells, lipid accumulation in the cytoplasm of hepatocytes and, at the higher dietary levels, adenofibrosis. Because of the wide distribution of PCBs in the environment[2] and their persistence, the hepatic lesion was studied further. The present study was undertaken to see whether, once exposure to PCBs was stopped, the morphological changes produced in the liver might disappear.

Submitted for publication March 8, 1973; accepted April 19.

From the Environmental Protection Agency, Bio-Effects Branch, Chamblee, Ga.

Reprint requests to 165 Avery Dr NE, Atlanta 30309 (Dr. Kimbrough).

Materials and Methods

A total of 50 male weanling, specific-pathogen-free, random-bred Sherman strain rats were tagged individually and group-caged, ten rats per cage. They were given Aroclor 1254 in their diet for six months. The dose of 500 ppm, which is equivalent to an average daily intake of 36.4 mg/kg body weight,[3] was chosen because in the previous study all ten exposed male rats developed adenofibrosis within a period of eight months. The Aroclor was mixed into ground laboratory chow as previously described.[1] After six months of

Fig 1.—Area of adenofibrosis in liver section consisting primarily of ducts surrounded by flattened epithelium. Ducts are surrounded by little fibrosis (hematoxylin-eosin, original magnification × 150).



Fig 2.—Rat liver section showing cluster of small columnar cells resembling pancreatic tissue adjacent to blood vessel. Hepatocytes surrounding lesion are vacuolated (hematoxylin-eosin, original magnification × 175).



Exhibit 5, 7

MONS 204997

Use of the present method produces an average slope around 1. For nickel, the slope changes from 0.222 in acid, to 0.066 in this organic base.

Since copper and zinc concentrations are determined after dilution, and therefore subject to a certain amount of dilution error, a National Bureau of Standards sample (No. 1577) of bovine liver was subjected to the same procedure and analyzed. The copper recovery was 113% ± 5.0%, and zinc, 112% ± 6% in three separate analyses.

The precision of the method in repeated analyses of control and exposed lung tissue is presented in Table 2. All lungs were divided into approximately five equal portions and each portion analyzed for cadmium, nickel, and zinc. The standard deviations for each lung varied from a low of 0.02 ppm to 1.56 ppm, depending somewhat on the exposure to the inhaled metal. Within measured ranges of cadmium and nickel concentrations, 200 to 300 mg of wet tissue from an exposed animal are necessary for precision. If the animal is unexposed, 300 to 400 mg are required for the cadmium analysis. Although one would not expect any difference in the nickel concentration before or after exposure to cadmium, the nickel concentration was below the level of detection in the control animals. Sample weights can be reduced by as much as 90% to 95% for the analysis of zinc and copper.[7]

Using the data given in Table 3, the total amount of cadmium recovered from the lung was calculated and compared with the total amount of cadmium present in the inhalation chamber during that period, as well as with the estimated amount of cadmium inhaled by the rats. It can be seen that the percent retained (6% to 20%) of that "inhaled," is larger by a factor of 50 than the amount retained from the total exposure. These figures are somewhat comparable to those reported in the literature,[12] which for short acute exposures varied from 6% to 13% for rats, and under chronic conditions, lasting eight months, are estimated at 2% for rabbits. Both of these studies were performed at higher exposure levels than those in the present experiments. Under the conditions of the present study, all animals are exposed to a relatively small particle size, (80% are less than 0.53μm in diameter[10] which for cadmium oxide would be relatively soluble. The animals were killed 16 hours after removal from the chamber, and the total exposures were not large. Experiments performed in these laboratories after five- to six-week exposure periods, to be reported in the future, do not show much increase in lung retention. Under the conditions of these experiments then, it would appear that of the cadmium oxide aerosol absorbed, a substantial portion remains in the lung.

In summary, data have been presented to illustrate a fast and relatively precise method for the analysis of cadmium and nickel in animal tissues.[13] The technique has been used to measure cadmium concentrations in the rat lung after exposure to cadmium oxide aerosols.

This investigation was supported by the National Institute of Occupational Safety and Health grant 5-R01-OH-00347-02.

Emil Pfitzer, PhD, assisted in the construction of inhalation experiments.

William Barkley ran the inhalation chambers. Tony Horstman, PhD, performed the particle sizing.

References

1. Friberg L, Piscator M, Nordberg G: Problems of analysis, In *Cadmium in the Environment*. Cleveland, Chemical Rubber Co, 1971, p 16.

2. Christian G, Feldman F: *Atomic Absorption Spectroscopy*. New York, Wiley-Interscience Publishers, 1970.

3. *Analytical Methods for Atomic Absorption Spectrophotometry*. Norwalk, Conn, Perkin-Elmer Co, 1971.

4. Pulido P, Fuwa K, Vallee B: Determination of cadmium in biological materials by atomic absorption spectrophotometry. *Anal Biochem* 14: 393-401, 1966.

5. *Packard Technical Bulletin*, publication 60518, Downers Grove, Ill, Packard Instrument Co, 1970.

6. MacGee J: Characterization of mammalian tissues and microorganisms by gas-liquid chromatography. *J Gas Chromatogr* 6:1672-1673, 1970.

7. Jackson AJ, Michael LM, Schumacher HJ: Improved tissue solubilization for atomic absorption. *Anal Chem* 44:1064-1065, 1972.

8. Mustafa MG, Cross DG: Pulmonary alveolar macrophage. *Biochemistry* 10:4176-4185, 1971.

9. Bingham E, et al: Alveolar macrophages: Reduced number in rats after prolonged inhalation of lead sesquioxide. *Science* 162:1297-1299, 1968.

10. Horstman S, et al: Aerosols of lead, nickel, and cadmium: A method of generating soluble and insoluble compounds. *Arch Environ Health* 26:75-77, 1973.

11. Sunderman FW: Measurements of nickel in biological materials by atomic absorption spectrometry. *Am J Clin Pathol* 44:181-188, 1965.

12. Friberg L, Piscator M, Nordberg G: Metabolism, In *Cadmium in the Environment*. Cleveland, Chemical Rubber Co, 1971, pp 27-66.

13. Murthy L, et al: Atomic absorption determination of zinc, copper, cadmium and lead in tissues solubilized by aqueous tetramethylammonium hydroxide. *Anal Biochem*, to be published.

MONS 204998



Fig 3.– Section of hepatic tissue in latter part of recovery phase illustrating numerous small lipid vacuoles (LV) (lead citrate-uranyl acetate, original magnification × 51,300).

Fig 4.– Portion of hepatocyte with tubules of endoplasmic reticulum (ER) arranged in disorderly fashion. N represents nucleus; M, mitochondria (lead citrate-uranyl acetate, original magnification × 20,235).



MONS 204999

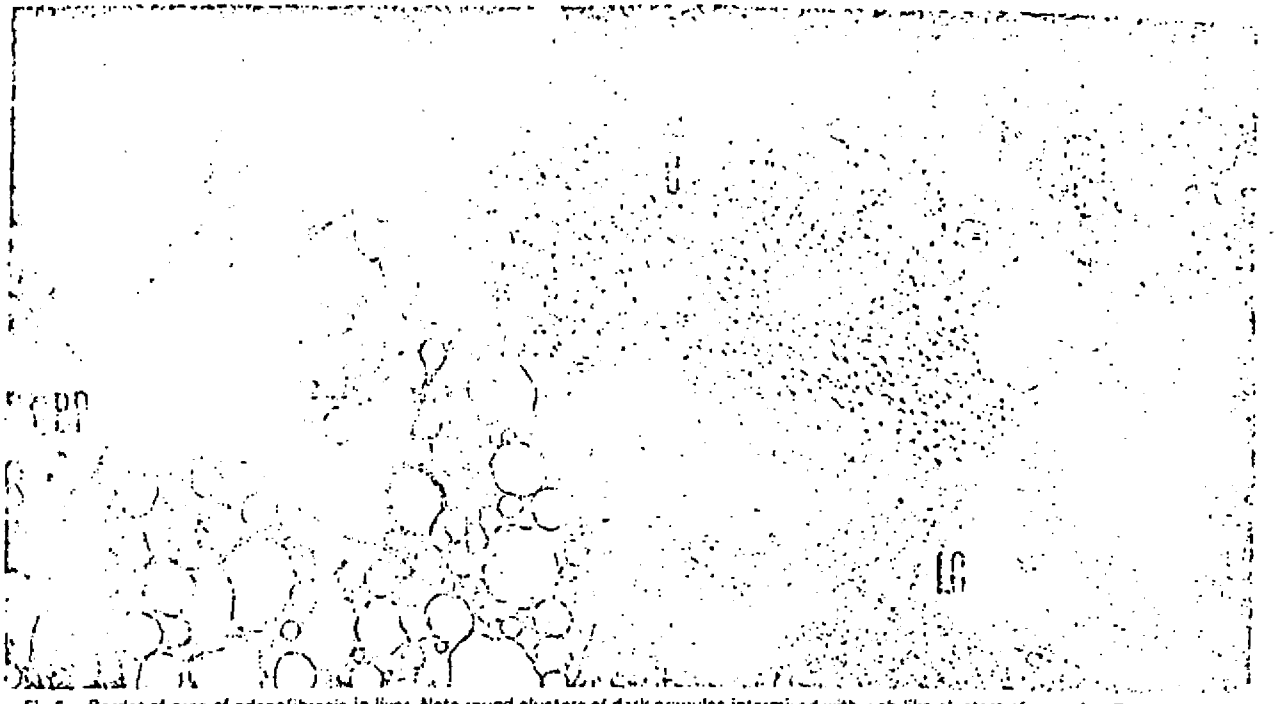

Fig 5.—Border of area of adenofibrosis in liver. Note round clusters of dark granules intermixed with web-like clusters of vacuoles. These formations illustrate appearance of brown pigment (BP). C represents collagen; LC, liver cell (lead citrate-uranyl acetate, original magnification ×20,235).

receiving the experimental diet, the rats received no more Aroclor and were fed plain laboratory chow. At this time five rats were killed. Additional killings of five randomly selected rats were made one, two, three, four, six, eight, and ten months after exposure to PCB had been discontinued. At autopsy the livers were removed, weighed, and the tissue fixed in phosphate-buffered 5% glutaraldehyde for three hours for electron microscopic examination, post-fixed in 1% osmium tetroxide, embedded in maraglass, sectioned with a glass knife, and stained with lead citrate and uranyl acetate. Tissue for the light microscope was fixed in 4% buffered formaldehyde solution and stained with hematoxylin and eosin. Frozen tissue of selected formalin-fixed hepatic tissue was cut on the cryostat and stained with oil red O to demonstrate lipids. At the time of the last sacrifice, ten months after exposure to PCB-containing diets had been discontinued, adipose tissue and liver from seven previously exposed rats and the adipose tissue and liver from two rats of the same age that had been fed only plain chow were analyzed for the presence of PCBs by electron capture (EC) gas chromatography according to methods described by Curley et al.[4]

In order to determine which Aroclor constituents were of such chemical stability that they remained at a measurable residual level ten months after dietary intake had ceased, adipose and hepatic composites were analyzed by gas chromatography-mass spectrometry. The conditions for mass spectral analysis were as follows: the mass spectrometer was interfaced with a gas chromatograph and equipped with a mass marker accurate within ±0.3 mass units. The gas chromatographic column temperature was 220 C; flash heater, 235 C; glass-coiled column, 3.05 m × 0.64 cm; 1.5% OV-17/1.95% QF-1 on 60/80 mesh chromosorb "W" (high performance, acid washed, dimethyldichlorosilane treated), helium pressure; 0.84 kg/sq cm; flow rate (rotameter setting 3), 45 ml/min; separator temperature, 225 C; source energy, 70 ev; accelerating voltage 3.5 kv; trap current 60μamp; box current 50μamp, and leak current 8μamp.

Results

During the course of the experiment three rats died. The livers of the rats that were killed at the time exposure to Aroclor 1254 was discontinued were enlarged, with average weights of 6.32% of the body weight. When the experimental diets had been discontinued for four months, the liver made up only 3.6% of the body weight, and after eight months recovery the average weight amounted to 3.34% of the average body weight. The fraction of the body weight for the liver in control adult male rats ranges from 2.44% to 2.59%.[4]

Forty livers were studied microscopically. The hepatocytes were enlarged in 39 livers and all 40 livers showed either vacuolated or foamy cytoplasm because of increased lipid accumulation. Cytoplasmic inclusions similar to those described previously[4] were observed in the livers of 24 rats. Adenofibrosis, which in many instances was very extensive, was present in 36 of the 40 livers, and a brown pigment was noted in the Kupffer cells and other macrophages in 25 livers. Of the four rats that did not develop adenofibrosis, one each was killed two and six months after the poisoned diets were discontinued. The other two rats without adenofibrosis were killed ten months after onset of exposure. The adenofibrosis ranged in size from grayish white lesions measuring 0.5 to 1 cm to areas of 5 cm with a pitted surface. Quite often the lesion was multicentric. The adenofibrosis[4] is illustrated in Fig 1 and 2. In this study the appearance of

MONS 205000

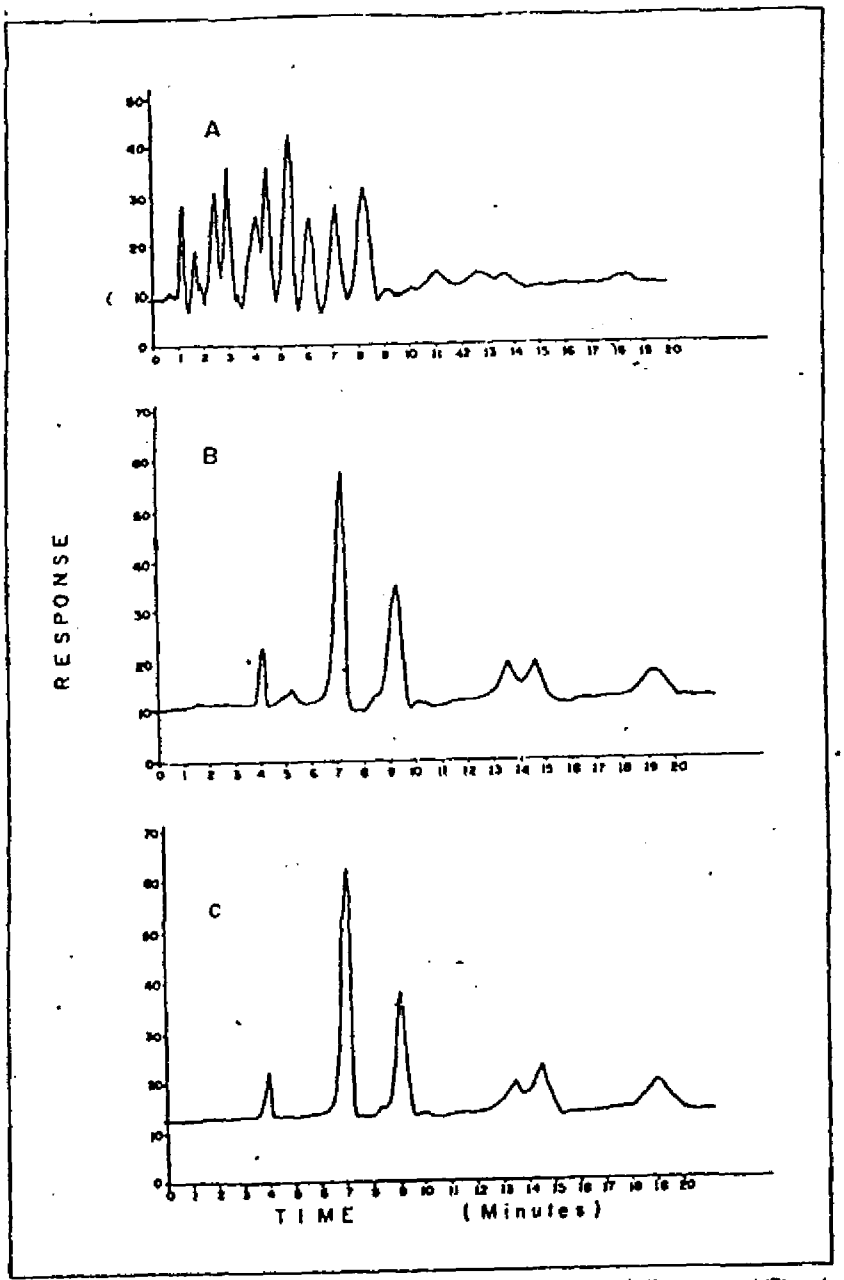

Fig 6. – Gas chromatographic traces of Aroclor 1254 standard (A), hepatic tissue extract (B), and extract of adipose tissue (C). Response expressed as percentages, with 100% = 1.0 inv.

the lesion, particularly when it was extensive, varied a great deal. Small lesions consisted predominantly of glandular pale-staining epithelial cells that formed ducts and were surrounded by very little fibrosis. The larger lesions had extensive fibrosis and contained collagen, and often the ducts which were formed by the epithelial pale-staining cells were markedly dilated. The dilated ducts contained mucus or necrotic debris, and at times formed small cysts measuring up to 0.5 cm in diameter. Small dilated ducts were lined by columnar epithelium, and larger ones by flattened epithelium (Fig 1).

In areas of extensive fibrosis, and also adjacent to blood vessels in areas of normal hepatic parenchyma (Fig 2), clusters of small glandular cells were seen in 15 of the livers which resembled the epithelium observed normally in the pancreas. These small clusters of pancreatic-like tissue have not previously been described in the livers of rats or of other species. Special stains for esterase, esterase with sodium taurocholate, and tryptophan showed a positive reaction indicative of salivary gland tissue. The significance of these cells is presently not understood. Normally tissue of a pancreatic type is not observed in the livers of our rats. Clusters of small columnar epithelial cells resembling pancreatic tissue also occurred in portal triads without being surrounded by typical adenofibrosis. In the present study, one to two rats at each killing showed these small columnar cells with highly acidophilic cytoplasm and a small, round nucleus.

In the older animals, the fibrosis was quite extensive in some instances and the glandular proliferation was present mainly at the periphery of the lesion. Signs of regression of the lesion were not noted, except for the disappearance of epithelial cells from the center of the lesion. Furthermore the lipid accumulation and the hypertrophy of the hepatic cells remained constant throughout the study. Extensive areas of necrosis were observed in three of the 40 livers.

In addition to the change described previously,[1] electron microscopic examinations of sections of liver tissue showed numerous small lipid vacuoles in the cytoplasm of many hepatocytes, particularly in the latter part of the recovery phase (Fig 3). The smooth and rough endoplasmic reticulum was arranged in a disorderly fashion (Fig 4). Many of the mitochondria were atypical and surrounded by double membranes.

The electron microscopic appearance of the brown pigment present in the macrophages and Kupffer cells is illustrated in Fig 5. Large clusters of dark granular material, intermixed with lipid vacuoles, were observed, as well as round clusters of granular material about the size of mitochondria. In our previous studies it was found that at least some of this pig-

MONS 205001

ment contained iron[4] but in addition high concentrations of uroporphyrin (75% 8-carboxyporphyrins and 25% 7-carboxyporphyrins) were found in the livers,[5] which could account for some of the pigment. In addition to these findings, oil red O stain demonstrated granules of red-staining lipid material in the area of the brown pigment.

Since the morphological changes in the liver did not disappear, the remaining seven rats were killed after a ten-month recovery phase and their adipose tissue and livers analyzed for Aroclor. In adipose tissue, the concentrations of PCBs ranged from 924 ppm to 1,688 ppm, with an arithmetic mean of 1,192 ppm. The concentrations in the liver ranged from 17.30 ppm to 26.24 ppm, with an arithmetic mean of 22.65 ppm. The PCB levels in control adipose and liver tissues were <1.0 ppm.

The gas chromatogram obtained from the EC analysis of adipose tissue did not differ from that of liver, but was significantly different from standard Aroclor 1254. An average of seven peaks was observed as a residue in the tissues. Under these gas chromatographic conditions, at least 18 peaks have been observed in the standard material (Fig 6). The difference in gas chromatographic patterns between stored and ingested Aroclor has been observed before in this laboratory and by other researchers in the field.[6,7]

The total ion current (TIC) chromatogram for the liver tissue composite is shown in Fig 7. Mass spectral analysis revealed the presence of only three major Aroclor components with masses of 324, 358, and 392. These components contained isotopic clusters indicative of the presence of Cl_4, Cl_5, and Cl_6, respectively. Adipose tissue analysis by mass spectrometry revealed the same patterns. Although only three different molecular components were present, examination of the EC and TIC chromatograms coupled with measured intensities from multiple scanning of eluting peaks indicates that stereoisomers of these three molecules are obviously present. Peaks 1 to 3 (Fig 7) did not contain any

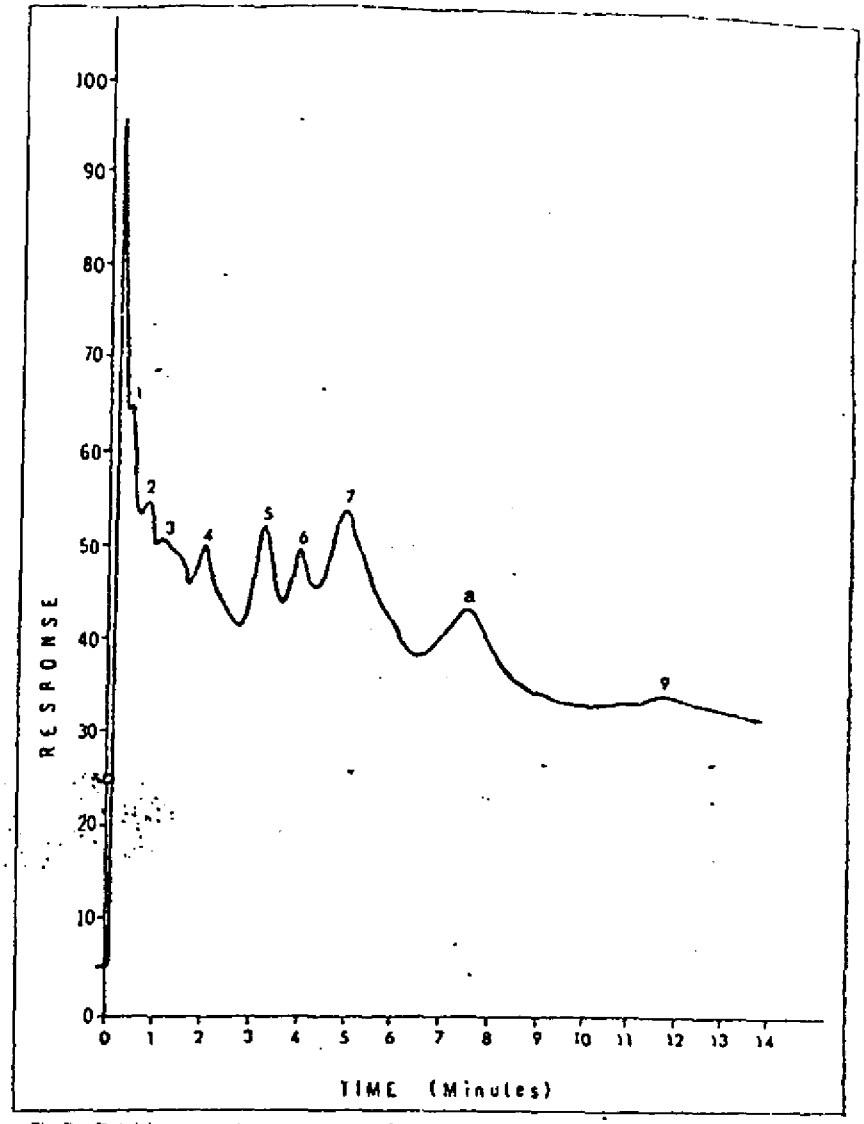

Fig 7.—Total ion current chromatogram of sample of composite liver. Response expressed as percentages, with 100% = 10.0 mv.

chlorinated moieties, while other peaks observed in the liver TIC contained the following molecular ions: peak 4 (324); peaks 5 to 7 (392 and 358); and peaks 8 to 9 (392).

Comment

The adenofibrosis of the liver produced in this study and the one previously reported[1] is the result of Aroclor consumption. Whether the Aroclor itself, or a contaminant such as a chlorinated dibenzofuran, is responsible still needs to be resolved.

A study of the lesion shows that epithelial proliferation occurs in the periphery, while the central portion of the lesions contains primarily fibrous tissue. The present study does not completely resolve the question of reversibility of this lesion since the storage levels of PCBs in adipose tissue and liver may have been sufficiently high to stimulate continued growth of the altered hepatic tissue. The levels in the liver suggest that a constant low-level turnover of PCBs takes place in the rats. In a previous study, Curley et al[1] found levels of 10,000 ppm Aroclor 1254 in adipose tissue of rats that had been fed 500

MONS 205002

ppm of the mixture in their diet for eight months. This finding indicates that a great deal of the Aroclors had been mobilized from the adipose tissue and excreted in the present study. The storage levels found ten months after onset of recovery are in the same range of those of rats fed 100 ppm PCBs in their diet for eight months.[3] The dietary level of 100 ppm produces a much lower incidence of adenofibrosis,[1] and it is possible that adenofibrosis represents a permanent lesion, particularly since the percent of body weight of the livers had decreased.

The Aroclors found in the tissues differed from those fed in the diet. Metabolism of lower chlorinated biphenyls is considered as a possible explanation for the differences observed analytically between consumed and stored PCB. Earlier work of Block and Cornish[8] has shown that biphenyls and chlorobiphenyls can be hydroxylated and excreted in the urine of rabbits. A more recent study by Hutzinger et al[9] indicates that the rat is capable of hydroxylating mono-, di-, and tetrachlorobiphenyls, but not hexachlorobiphenyls. Since Aroclor 1254 averages five chlorines per molecule, it is conceivable that the heavier chlorinated moieties could remain as a residue.

P-dimethylaminoazobenzene also produces adenofibrosis. Edwards and White[10] and Bennett et al[11] described the lesion in rats when a mixture of chlorinated naphthalenes and chlorinated diphenyls were fed. Unfortunately, the finding was not well described in Bennett et al's report, but Edwards and White mentioned Bennett et al's finding as another example of the induction of adenofibrosis by chemicals in an excellent description of the lesion. A critical review of the histopathogenesis of this lesion was made by Stewart and Snell[12].

The presence of the brown pigment in Kupffer cells and macrophages is of interest and was to a lesser extent also observed in the earlier study.[1] Electron microscopic examination of the pigment shows that particularly the large clusters of it resemble very closely illustrations of ceroid pigment.[13] Experimentally ceroid pigment can be produced by hemorrhage into fatty tissues rich in unsaturated fatty acids, particularly in the absence of an antioxidant (vitamin E deficiency). Ceroid pigment is commonly referred to as lipofuscin. These lipid pigments are at times associated with hemosiderin and may contain iron-positive granules as in the present case.[1] Ceroid granules were also described by Edwards and White in the livers of rats fed butter yellow. Bennett et al also observed a brown pigment in rats fed a mixture of chlorinated naphthalenes and chlorinated biphenyls. These authors claimed that it failed to stain in a manner characteristic of either hemosiderin or hemofuscin. The porphyrins demonstrated in the livers of our rats fed Aroclor may also contribute to the overall pigment deposits. Ceroid pigment increases in people with age and has therefore been called "*Abnutzungspigment*" by the Germans. Attempts have been made to relate it to senility. It has been associated with neuronal ceroid-lipofuscinosis (Batten disease) in man. In minks, a disease called yellow fat disease[14] is associated with the accumulation of excessive amounts of ceroid in adipose tissue. The accumulation of ceroid in mink can be prevented by addition of vitamin E to the diet. It occurs when the food rations contain high percentages of fish scrap. However, Gorham et al suggest that other factors may also be involved, since high dietary percentages of fish scrap did not promote growth as well as the stock ration, even when vitamin E was added to the diet. These observations raise the question whether high doses of vitamin E, and possibly the addition of choline to the diet, could prevent or minimize the observed effects of PCBs on the liver of our rats.

Richard L. Moore assisted with the animal tests.

Linda W. Anderson assisted with preparation and interpretation of the electronmicrographs.

Annie R. Alford performed the tissue preparations.

H. L. Stewart, MD, and the tissue laboratory of the National Cancer Institute, Bethesda, Md. performed evaluations of liver slides.

References

1. Kimbrough RD, Linder RE, Gaines TB: Morphological changes in liver of rats fed polychlorinated biphenyls. *Arch Environ Health* 25: 354-364, 1972.

2. Risebrough RW, et al: Polychlorinated biphenyls in the global ecosystem. *Nature* 220: 1078-1102, 1968.

3. Curley A, et al: Polychlorinated biphenyls. Distribution and storage in body fluids and tissues of sherman rats. *Environ Res* 4:481-495, 1971.

4. Kimbrough RD, Gaines TB, Linder RE: The ultrastructure of livers of rats fed DDT and dieldrin. *Arch Environ Health* 22:460-467, 1971.

5. Goldstein JA, Hickman P, Jue D: Hepatic porphyria induced by polychlorinated biphenyls (PCB's): Relationship between porphyria, δ-aminolevulinic acid synthetase and cytochrome P-450, abstracted. *Fed Proc* 32:702, 1973.

6. Grant DL, Phillips WEJ, Villeneuve DC: Metabolism of a polychlorinated biphenyl (Aroclor 1254) mixture in the rat. *Bull Environ Contam Toxicol* 6:102-112, 1971.

7. Vos JG, Koeman JH: Comparative toxicologic study with polychlorinated biphenyls in chickens with special reference to porphyria, edema formation, liver necrosis and tissue residues. *Toxicol Appl Pharmacol* 17:656-668, 1970.

8. Block WD, Cornish HH: Metabolism of biphenyl and 4-chlorobiphenyl in the rabbit. *J Biol Chem* 234:3301-3302, 1959.

9. Hutzinger O, et al: Polychlorinated biphenyls: metabolic behavior of pure isomers in pigeons, rats, and brook trout. *Science* 178:312-313, 1972.

10. Edwards JE, White J: Pathologic changes with special reference to pigmentation and classification of hepatic tumors in rats fed p-dimethylaminoazobenzene (butter yellow). *J Natl Cancer Inst* 2:157-183, 1941.

11. Bennett GA, Drinker CK, Warren MF: Morphological changes in the livers of rats resulting from exposure to certain chlorinated hydrocarbons. *J Ind Hyg Toxicol* 20:97-131, 1938.

12. Stewart HL, Snell KC: The histopathology of experimental tumors of the liver of the rat. A critical review of the histopathogenesis. *Acta Unio Int Contra Cancrum* 13:770-805, 1957.

13. Hartroft WS: Observation and interpretation of lipid pigments (lipofuscins) in the pathology of laboratory animals. *Crit Rev Toxicol* 1:379-411, 1972.

14. Gorham JR, Baker GA, Poe N: Observations on the etiology of yellow fat disease in mink: Preliminary report. *Vet Med* 46:100-102, 1951.

MONS 205003

Organochlorine Pesticide Content of Human Adipose Tissue in Karachi

Hafiez Ahmad Mughal, MPhil, M. Ataur Rahman, PhD, Karachi, Pakistan

The organochlorine group of pesticides, because of their persistence in tissue, are suspected of having adverse effects on human health. The present article is a report on the concentration of seven organochlorine compounds in the stored fat of 60 subjects from the Karachi, Pakistan, area who gave no history of occupational exposure to pesticides. The results indicate that people living in this city are heavily exposed to DDT, moderately exposed to benzene hexachloride (BHC), and only lightly exposed to aldrin/dieldrin. The extent of the exposure to pesticides was not related to the age, sex, type of material, residential location of subjects, or period during which samples were collected. The higher mean concentration of dichlorodiphenyl dichloroethane (DDD) in the postmortem specimens is probably due to microbial metabolism of DDT under anaerobic conditions after death.

In Pakistan, huge quantities of organochlorine pesticides are sprayed for public health and agricultural purposes. The Malaria Eradication Project has used DDT for a long time. The Agricultural Department employs aldrin, dieldrin, endrin, benzene hexachloride (BHC), γ-BHC, toxaphene, and so forth for protection of various crops. The practice of domestic spraying of insecticides, including DDT and BHC, is not uncommon, yet no information has been available as to the occurrence of chlorinated pesticides in the body fat of the general population in this country.

In 1965, Egan et al[1] reported the case of a Pakistani immigrant to the United Kingdom whose body fat contained 54 ppm of total DDT-equivalent in contrast to the mean concentration of 3.3 ppm in the body fat of the local population. This indicated that the pesticide pollution problem in Pakistan might be an acute one. It was, therefore, considered desirable to determine the extent to which the general population had been exposed to organochlorine pesticides by estimation from the mean concentration in human fat.

Materials and Methods

Thirty-nine specimens of human adipose tissue were obtained during surgical operations performed at Jinnah Postgraduate Medical Centre in Karachi from December 1970 through October 1971. Twenty-one specimens of omental fat were collected during postmortem examinations by the police surgeon in Karachi. All the specimens were kept in specially cleaned, glass-stoppered bottles; the biopsies in a freezer, and autopsy material in formaldehyde solution (4%). The particulars of age, sex, occupation, residence, diagnosis of the subject, and date of collection of the specimen were noted. As far as it could be ascertained, none of the subjects was occupationally exposed to any pesticides.

A 3- to 5-gm portion from each specimen was extracted with hexane in the presence of anhydrous sodium sulphate, so that 20 ml of the extract represented 1.00 gm of the tissue. The content of extractable lipid was determined by evaporating 5.0 ml at room temperature and weighing the residue. A fresh aliquot of the hexane extract containing about 2.0 gm of fat was freed from fat and other interfering substances by means of dimethylformamide partition and column chromatography by the method of deFaubert Maunder et al.[2] Preparative thin layer chromatography (TLC) was used for further clean-up of each concentrated extract from the evaporator and separated into two fractions. Activated silica gel plates were used with hexane-acetone (99:1) as the solvent system. Three fourths of the eluted upper zone containing *p,p'*-dichlorodiphenyl dichloroethylene (DDE), *o,p'*-DDT, and *p,p'*-DDT were subjected to Schechter-Haller[3] colorimetric analysis as modified by Mattson et al,[4] so that both DDT and DDE could be determined. The whole of the lower and the remainder of the upper eluted zones were mixed and quantitatively analyzed by the TLC method of Kovacs.[5] The experimental limits of the latter method were as follows: *p,p'*-DDE, 0.05 ppm; *o,p'*-DDT, 0.05 ppm; *p,p'*-DDT, 0.05 ppm; *p,p'*-DDD, 0.02 ppm; β-BHC, 0.003 ppm; γ-BHC, 0.003 ppm; and dieldrin, 0.006 ppm. By both methods, the recoveries of added pesticides ranged between 75% and 102%. The DDE and DDD values have been calculated and expressed as DDT by multiplying the values of these residues by 1.115 and 1.108, which are ratios of molecular weights of DDT with DDE and DDD, respectively.

Submitted for publication Nov 14, 1972; accepted May 31, 1973.

From the Department of Biochemistry, Jinnah Postgraduate Medical Centre, Karachi, Pakistan. Mr. Mughal is now with the Department of Pathology, King Edward Medical College, Lahore, Pakistan.

Reprint requests to Department of Biochemistry, Jinnah Postgraduate Medical Centre, Karachi, Pakistan (Dr. Rahman).

MONS 205004

Polychlorinated Biphenyls

Storage, Distribution, Excretion, and Recovery: Liver Morphology After Prolonged Dietary Ingestion

Virlyn W. Burse; Renate D. Kimbrough, MD; Ellen C. Villanueva, MS; Ralph W. Jennings; Ralph E. Linder; G. Wayne Sovocool, PhD

Rats were fed 100 ppm of Aroclor 1242 (6.6 to 3.89 mg/kg/day) or 100 ppm Aroclor 1016 (6.9 to 3.5 mg/kg/day). Plasma, kidneys, urine, brain, liver, and adipose tissue were analyzed for polychlorinated biphenyl (PCB) residues at 0.5, one, two, four, six, eight, and ten months of exposure. In additional groups fed the experimental diet for six months, PCB tissue levels were determined two, four, five, and six months after the exposure to PCBs was discontinued. PCBs were highest in adipose tissue where a steady state was approached in two and reached in 4 months. Little PCB-derived material was excreted in urine.

After discontinuing PCB exposure, Aroclor 1016 was eliminated more rapidly from the organs than Aroclor 1242. Measurable residue levels were still present after five (Aroclor 1016) and six (Aroclor 1242) months of recovery. Microscopic examination of the liver showed enlarged liver cells with vacuolated cytoplasm and inclusions.

The use and replaceability of polychlorinated biphenyls (PCBs) has recently been reviewed.[1] Because of their extensive use in the past and their slow biodegradability, PCBs are now widely distributed in the environment.[2,3] Recently the use of these materials in the United States has been restricted to closed systems. A new PCB, Aroclor 1016, which is a good dielectric and heat transfer fluid has been proposed. It contains a lower percentage of the higher PCBs and should prove to be less persistent in the environment. The higher PCBs appear to be more persistent, as evidenced by mass spectral residue analysis of environmental samples.[4,5]

It is the purpose of this paper to report results of feeding studies conducted in rats with Aroclor 1016 and Aroclor 1242. Aroclor 1242 in its general make-up is very similar to Aroclor 1016, it only lacks the higher PCBs (Papageorge, written communication, June 1973). The Aroclors differ in the percentages of fixed chlorine, 43% ± 0.5% (1242) vs 41.3% ± 0.5% (1016). Aroclor 1242 contains 9% biphenyls with five or more chlorines and Aroclor 1016 contains 1% biphenyls with five or more chlorines.

MATERIALS AND METHOD

Aroclors 1242 and 1016 were of electrical grade, lot No. KB-05-415 and KB-06-756, respectively. The PCBs were fed in parallel experiments to male Sherman strain rats, 61 to 73 days old. A total of 158 rats was divided into two groups of 27 and two groups of 52 rats each according to a table of random numbers. The rats were group caged and weighed weekly. Their food consumption was measured, one week prior to each scheduled killing. The groups of 52 rats were fed the experimental diets that contained 100 ppm of Aroclor 1016 or Aroclor 1242. The control rats were fed ground laboratory chow ad libitum.

The PCBs were incorporated into the diets by dissolving them in ether and pouring this solution onto 100 gm of corn starch. The ether was evaporated and the PCB cornstarch mixture diluted with increasing amounts of ground chow in an electric mixer.

The following killing schedule was observed (Table 1): one control and four rats fed Aroclor 1016 or 1242 were killed two weeks after onset of the experiment. Four additional rats of each experimental group were killed one and two months after onset of the experiment. The further killing of four experimental rats for each PCB mixture as well as four controls that served for both experimental groups were made four, six, eight, and ten months after onset of the experiment. After six months feeding, the experimental diets were discontinued on 18 randomly selected rats for each PCB mixture. These rats were fed plain chow and four for each PCB mixture were killed together with four control rats at two, four, and five or six months (Table 2) of recovery. Twenty-four hours prior to each killing the rats were housed in individual metabolism cages and urine was collected. During the 24-hour period prior to death, none of the rats in the study was fed a fortified diet. Oxalated blood was obtained by cardiac puncture from rats anesthetized with ether. The animals were killed by exsanguination and liver, fat, kidney, and brain tissues were collected. The liver was weighed and the tissues were frozen for chemical analysis. Liver tissue from the animals killed at four months and at subsequent killings were also fixed in buffered 4% formaldehyde for microscopic examination, and stained with hematoxylin-eosin. Liver tissue at four months of exposure to Aroclor 1016 and at six months of exposure to Aroclor 1242 together with an equal number of controls for electron microscopic examination was fixed in chilled, buffered 5% glutaraldehyde for two hours, postfixed in 1% osmium tetraoxide, dehydrated through changes of alcohol and propylene oxide, and embedded in resin. Sections were cut with a glass knife, stained with lead citrate and uranyl acetate, and examined with an electron microscope.

The analytical methods used for the determination of PCB-derived materials have been described previously.[6] Briefly, 100 to 200 mg of fat, brain, kidney, and liver or 1 to 2 ml of plasma were extracted with hexane. Brain was extracted with acetone, the solution evaporated to dryness

Submitted for publication May 10, 1974; accepted July 17.

From the Environmental Protection Agency, Chamblee Toxicology Laboratory, Chamblee, Ga (Mr. Burse, Dr. Kimbrough, Ms. Villanueva, Mr. Jennings, and Mr. Linder) and the NERC, EPA, Research Triangle Park, NC (Dr. Sovocool). Mr. Burse is currently with the US Consumer Product Safety Commission, Atlanta; Dr. Kimbrough is with the Center for Disease Control, Toxicology Branch, Atlanta; Ms. Villanueva is with the Coca-Cola Export Corporation, Atlanta; Mr. Jennings is with the Environmental Protection Agency, Region IV, Atlanta; and Mr. Linder is with the Pesticides and Toxic Substances Effects Laboratory, NERC, EPA, Research Triangle Park, NC.

Reprint requests to the Toxicology Branch, Center for Disease Control, 1600 Clifton Rd, NE, Atlanta, GA 30333 (Dr. Kimbrough).

Exhibit 6

MONS 205005

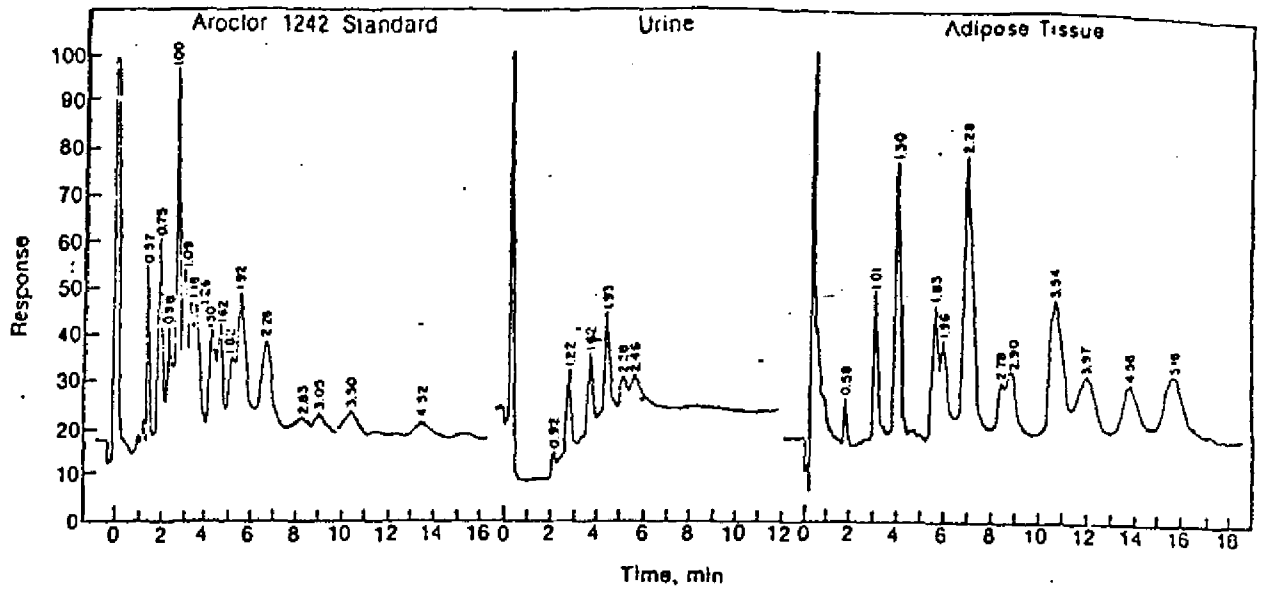

Fig 1.—Chromatograms of Aroclor 1242: 3.66 ng, an extract of urine: 4.5 mg, and adipose tissue: 0.027 mg from a male rat fed a diet containing 100 ppm Aroclor 1242 for eight months.

Table 1.—Mean Concentration and Standard Error of PCB-Derived Materials in Tissues of Four Rats Per Killing Fed 100 ppm Aroclor 1242 or 1016

Months on Diet	Plasma		Kidneys		Urine*		Brain		Liver		Adipose Tissue	
	Aro 1242	Aro 1016	Aro 1242	Aro 1016	Aro 1242	Aro 1016	Aro 1242	Aro 1016	Aro 1242	Aro 1016	Aro 1242	Aro 1016
0.5	0.081	0.182	0.68	0.63	<0.02	0.075	<0.25	1.52	0.55	1.46	35	69
	±0.000	±0.017	±0.15	±0.08	...	±0.042	...	±0.75	±0.08	±0.24	± 2.4	± 4
1	0.180	0.175	0.51	1.58	<0.01	0.008	<0.25	3.05	1.48	3.05	85	103
	±0.030	±0.028	±0.13	±0.11	...	±0.000	...	±0.13	±0.10	±0.28	± 10	± 8
2	0.310	0.331	1.44	2.74	<0.02	0.162	<0.25	3.40	3.24	3.88	92	182
	±0.057	±0.010	±0.18	±0.19	...	±0.038	...	±0.13	±0.30	±0.36	± 1.5	± 12
4	0.219	0.372	1.84	4.78	0.030	0.259	0.56	3.18	3.94	7.40	115	214
	±0.028	±0.040	0.27	±0.24	±0.02	±0.083	±0.08	±0.23	±0.72	±0.79	± 11	± 18
6	0.526	0.384	1.89	3.21	0.026	0.275	1.69	2.98	4.21	7.86	110	236
	±0.150	±0.024	±0.47	±0.48	±0.000	±0.112	±0.25	±0.44	±0.57	±0.75	± 13	± 9
8	0.240	0.394	2.14	2.07	0.168	0.057	1.63	2.64	4.56	5.97	143	221
	±0.052	±0.014	±0.41	±0.06	±0.04	±0.017	±0.24	±0.38	±0.61	±0.94	± 6	± 10
10	0.172	0.334	3.13	1.84	<0.01	0.021	2.05	2.70	6.39	8.70	133	180
	±0.014	±0.040	±0.50	±0.38	...	±0.000	±0.08	±0.36	±0.68	±0.34	± 15	± 9

* Confirmed qualitatively by Coulson conductometry.

Table 2.—Mean Concentration and Standard Error of PCB-Derived Material in Tissues of Four Rats Two, Four, Five, or Six Months After They Had Been Fed 100 ppm Aroclor 1242 or 1016 for Six Months

Months Recovery	Plasma		Kidneys		Urine		Brain		Liver		Adipose Tissue	
	Aro 1242	Aro 1016	Aro 1242	Aro 1016	Aro 1242	Aro 1016	Aro 1242	Aro 1016	Aro 1242	Aro 1016	Aro 1242	Aro 1016
2	0.438	0.154	2.07	1.08	0.02	0.033	1.06	1.40	4.32	2.25	60	104
	±0.091	±0.034	±0.40	±0.27	±0.01	±0.004	±0.24	±0.07	±0.72	±0.32	± 3.7	± 13
4	0.149	0.193	1.84	1.82	<0.01	0.008	1.22	1.35	3.46	3.13	44	36
	±0.000	±0.050	±0.27	±0.44	...	±0.002	±0.53	±0.21	±1.04	±0.78	± 9	± 6
5*	...	0.062	...	0.44	...	0.006	...	0.38	...	1.06	...	28
	...	±0.011	...	±0.14	...	±0.002	...	±0.06	...	±0.09	...	± 1
6*	0.122	...	0.34	...	0.004	...	0.51	...	0.97	...	24	...
	±0.026	...	±0.06	...	±0.000	...	±0.06	...	±0.35	...	± 5	...

* Experiment had to be prematurely terminated.

MONS 205006

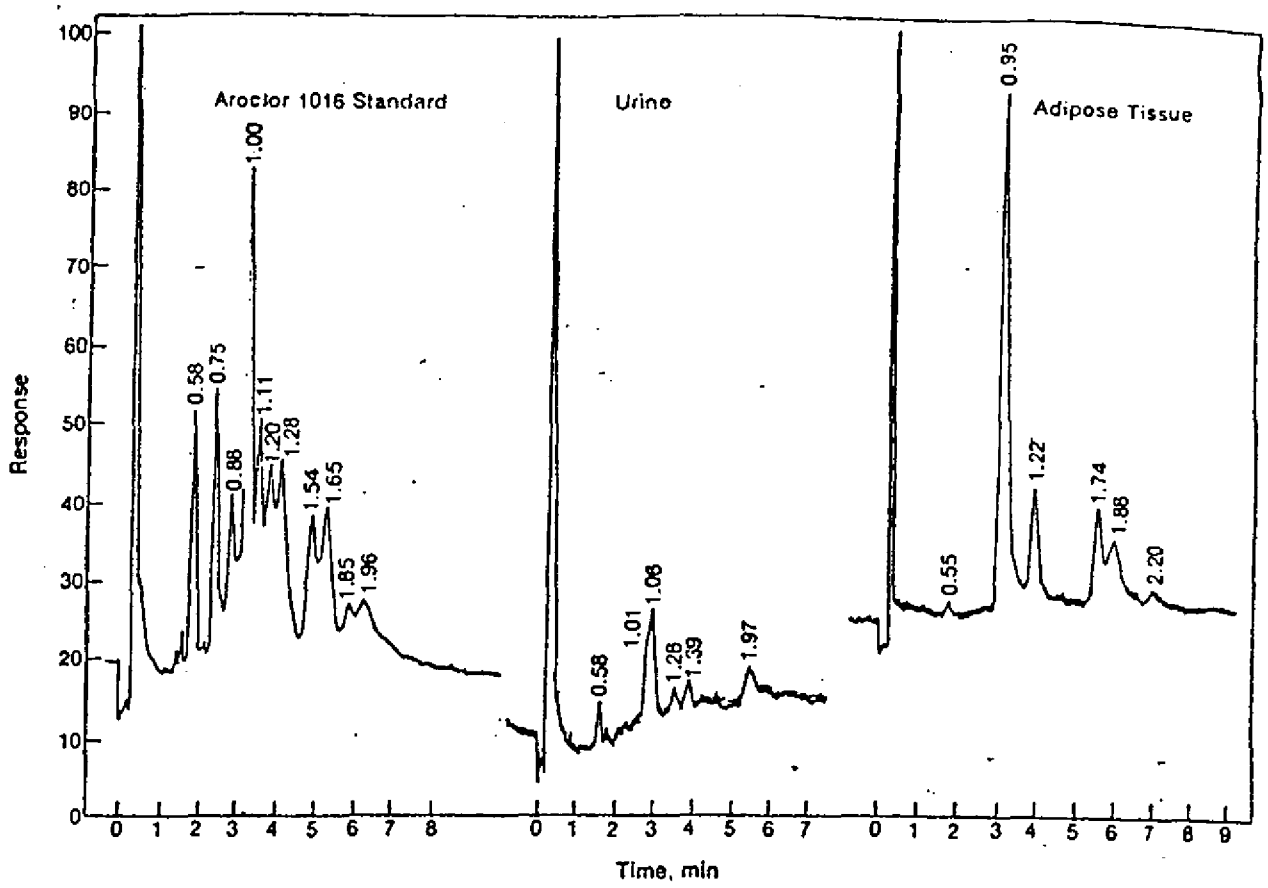

Fig 2.—Chromatograms of Aroclor 1016: 2.84 ng, extract of urine: 5.4 mg, and adipose tissue: 0.008 mg from a male rat fed a diet containing 100 ppm Aroclor 1016 for eight months.

Table 3.—Incidence of Microscopic Changes Observed in Livers of Rats Fed Aroclor 1242 or 1016

Length of Exposure	Enlarged Hepatocytes		Vacuolated Cytoplasm		Inclusions		Brown Pigment		Foamy Cytoplasm		Foci of Necrosis Hemorrhage	
	Aro 1242	Aro 1016	Aro 1242	Aro 1016	Aro 1242	Aro 1016	Aro 1242	Aro 1016	Aro 1242	Aro 1016	Aro 1242	Aro 1016
4	2/4	4/4	...	1/4	...	...	...	...	...	...	...	1/4
6	4/4	4/4	3/4	1/4	3/4	3/4	...	...	...	...	...	...
8	4/4	3/4	3/4	...	3/4	...	2/4	...	...	...	1/4	...
10	4/4	4/4	4/4	1/4	1/4	...	2/4	...	2/4	...	...	...
6 mo exp 2 mo rec	2/4	1/4	3/4	1/4	1/4	...	...	...	...	...	...	...
8 mo exp 4 mo rec	3/3	3/3	1/3	1/3	1/3	1/3	...	...	...	...	...	...
8 mo exp* 8 mo rec	3/4	...	...	...	2/4	...	...	...	...	...	...	...

* Only rats fed Aroclor 1242 were examined microscopically.

and the solute taken up in hexane. Urine, 10 to 20 ml, was extracted at approximately pH 7 with hexane. Each sample in a volume of 0.5 ml was eluted from a microsilica gel column using a 1:1 benzene-hexane mixture.

Samples were analyzed with a tritium source electron capture detector operated in the direct current mode at 12 v. Quantitation of the standard and of the different kinds of samples was based in each instance on total response in peak heights. However, as reported more fully below, there were qualitative differences in the peaks for the standard, the urine, the tissues collected during dosing, and the tissues collected after dosing was discontinued. Under these circumstances exact quantitation is impossible, but the use of total response in peak heights is considered to offer the best estimate of quantitation.

RESULTS

The rats did not suffer from any overt clinical symptoms of poisoning. During the course of the experiment five rats that were fed Aroclor 1016 and one rat that was fed Aroclor 1242

MONS 205007

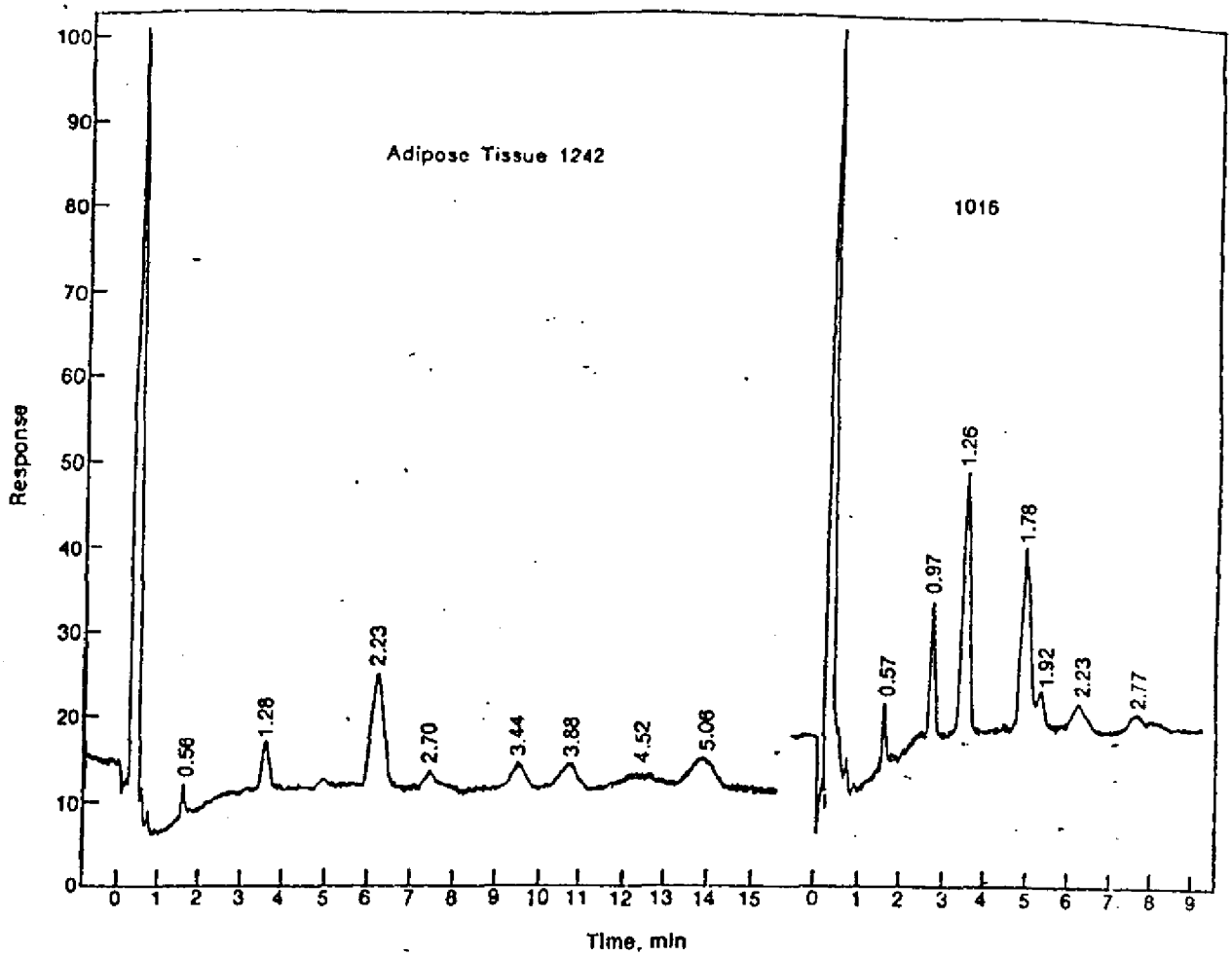

Fig 3.—Chromatograms of adipose tissue: 0.011 mg from a rat fed a diet containing 100 ppm Aroclor 1242 for six months and six months of a control diet; 0.016 mg from a rat fed a diet containing 100 ppm Aroclor 1016 for six months and a control diet for five months. (Relative retention times were computed relative to the most intense electron capturing peak present in Aroclor 1016 or 1242. All gas chromatographic columns were composed of 1.5% OV-17/1.95% QF-1 on 100/120 Gas Chrom Q.)

died. The cause of death was not established. No difference between the experimental and the control rats was observed in the body weight gain and the food consumption. As the rats aged food consumption decreased relative to their body weight. The amount of Aroclor 1242 consumed by the rats ranged from 6.6 mg/kg body weight/day to 3.89 mg/kg body weight/day, and the amount of Aroclor 1016 consumed by the rats ranged from 6.9 mg/kg body weight/day to 3.5 mg/kg body weight/day.

At autopsy the organs appeared grossly normal except for one rat fed Aroclor 1016 that had leukemia (a disease that occurs occasionally spontaneously in our colony). The liver weights of the experimental animals did not differ from those of the controls.

The concentrations of the PCB-derived materials are given in Table 1. The observed levels in adipose tissue are also shown in Fig 1. The highest concentrations for both compounds were found in adipose tissue, ranging from 35 to 143 ppm for Aroclor 1242 and 69 to 236 ppm for Aroclor 1016. The levels for brain, liver, and kidney were lower. The concentrations in urine and plasma were always less than 1 ppm. In adipose tissue a steady state of storage of both compounds was approached in about two months and essentially achieved in four months.

Gas chromatographic traces for all tissues were similar to those obtained from adipose tissue. The traces obtained from urine analysis had an entirely different appearance. The different profiles obtained from adipose tissue, urine, and the PCB standards are illustrated in Fig 1 to 3. When the peaks in the PCB standards were compared with the peaks obtained from PCB-derived material stored in the adipose tissue, it was found that some of the early peaks were absent, the intensity of others was enhanced, and peaks also emerged that were observed only as "shoulders" in the standard. This observation suggests either preferential absorption from the gastrointestinal tract, or prefer-

MONS 205008

ential metabolism, distribution, and excretion in the rats or both.

The urine samples show a very different pattern. This suggests that certain isomers are excreted by the kidneys, that the products excreted in the urine are polar metabolites, or that nonchlorinated moieties responded to the electron capture detector. However, a positive response was obtained with a conductometric detector (Coulson).

Residue levels arising from Aroclor 1016 ingestion were generally found to be higher than for Aroclor 1242,

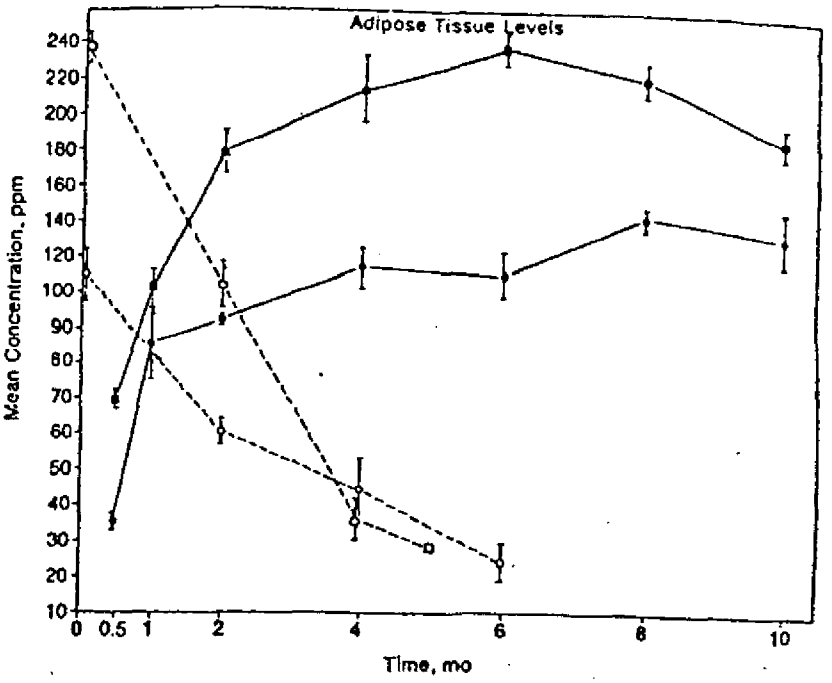

Fig 4.—Residues resulting from a continuous diet of a 100 ppm concentration of Aroclor 1016 (■) or Aroclor 1242 (·) for a period of ten months. Residues following a continuous diet for only six months and recovery for five months for Aroclor 1016 (□) and for six months for Aroclor 1242 (○) are illustrated by the broken lines. Each point represents the mean and standard error (I) of four rats.

Fig 5.—Liver of rat fed Aroclor 1016 for four months. Note dilated vesicles of smooth endoplasmic reticulum (SER). Some of the mitochondria are degenerated and others show an increased number of parallel arranged cristae (lead citrate, uranyl acetate, ×35,000).



MONS 205009

with the exception of the residues observed in the kidneys. However, this was not true for all organs at every killing. After a ten-month feeding period the concentration of both PCBs in the liver was about the same, while at four months almost twice as much Aroclor 1016 as Aroclor 1242 was found. The levels found in adipose tissue indicate a very sharp rise during the first month for Aroclor 1242, while Aroclor 1016 also maintains a sharp rise through the second month. After two months of exposure no appreciable increase was observed in adipose tissue of rats exposed to either Aroclor 1016 or 1242.

Very little PCB-derived material was excreted in the urine, and the excretion was very erratic. When rats were fed Aroclor 1242 they only excreted measurable amounts during four to eight months of exposure. Rats fed Aroclor 1016 excreted measurable amounts at each urine collection. The variation in urinary excretion of PCB-derived material has been observed previously in this laboratory[4] and by other workers in the field.[1]

The data resulting from the analysis of tissues from rats that were fed the respective PCB-containing diets for six months and were then continued on plain chow for various intervals up to six months are given in Table 2. The concentrations found in adipose tissue are also illustrated in Fig 4. Storage of material as detected by gas chromatography decreased more rapidly following discontinuation of dosing in rats previously fed Aroclor 1016 than in those previously fed Aroclor 1242. Following a recovery period of six months the residue levels in adipose tissue were 21.8% of those observed after a six-month exposure period to Aroclor 1242. Following a recovery period of five months the residue levels in adipose tissue of rats fed Aroclor 1016 were only 11.8% of the concentration found after six months of ingestion of this material. The gas chromatographic traces obtained from the adipose tissue following recovery from exposure to the PCB mixtures are shown in Fig 3. (Relative retention times were computed relative to the most intense electron capturing peak present in Aroclor 1016 or 1242. All gas chromatographic columns were composed of 1.5% OV-17/1.95% QF-1 on 100/120 Gas Chrom Q.) If these results are compared with those obtained earlier from adipose tissue, a slight decrease in the number of peaks as well as a difference in the relative heights of the peaks is noticed.

Composite urine and fat samples from rats fed Aroclor 1242 and 1016 continuously for varying time periods were analyzed by gas chromatography-mass spectrometry. Spectra resulting from the composite adipose tissue analysis showed primarily tri- and tetrachlorobiphenyls, for both PCB mixtures. Trace amounts of penta- and hexachlorobiphenyls were found in the Aroclor 1016 composites, while significant amounts of pentachlorobiphenyls and hexachlorobiphenyls were found in the composites obtained from rats that were fed Aroclor 1242.

Spectra from urine composites of rats fed Aroclor 1016 revealed the presence of the same molecular ions observed in the adipose tissue composites, with the exception of hexachlorobiphenyl. Dichlorohydroxybiphenyls (DCHB) and trichlorohydroxybiphenyls (TCHB) were also observed. Dichlorohydroxybiphenyl was more abundant.

Spectra from urine composites of rats fed Aroclor 1242 revealed the presence of the same molecular ions observed in adipose tissue, with the noted absence of hexachlorobiphenyl. In contrast to Aroclor 1016, hydroxylated chlorobiphenyls were not observed in any of the spectra resulting from Aroclor 1242 urine composite analysis.

The incidence of the various microscopic changes observed in the liver is given in Table 3. Light microscopic examination of the liver of rats fed the two PCBs showed enlarged hepatocytes predominantly in the center of the lobules. Occasional hepatocytes had coarsely vacuolated cytoplasm or contained inclusions within the cytoplasm. The cytoplasm of some of the hepatocytes was finely vacuolated and a brown pigment was noticed in the Kupffer cells and macrophages of some of the livers of the experimental rats fed Aroclor 1242 but not in rats fed Aroclor 1016.

Vacuolation of the cytoplasm of the liver cells was more consistently observed in the livers of rats fed Aroclor 1242. Generally not much difference was seen in the incidence of the various changes between the two experimental groups. All of the observed changes have to be considered as mild alterations that have been observed with a number of chlorinated cyclic chemicals.

Four and six months after exposure to the PCBs was discontinued the hepatocytes were still larger than those of the controls, but only one out of three rats showed vacuolated cytoplasm or inclusions within the cytoplasm. Since the number of animals was small, these results have to be interpreted with reservation; however, it appears that the morphological changes encountered following exposure to Aroclor 1242 and 1016 are reversible and disappear gradually after dosing is stopped. Except for the hemorrhage and necrosis observed in one animal in each experimental group no evidence of serious liver damage was encountered.

The livers of rats from the controls were normal when studied with the light microscope. Sections of four livers of rats fed Aroclor 1242 for six months and of four rats fed Aroclor 1016 for four months were also studied under the electron microscope, together with the same number of controls. The livers of the control animals showed occasional lipid vacuoles but no abnormal changes. The livers of the experimental rats fed both PCB compounds showed an increase in smooth endoplasmic reticulum, an increase in the number of lipid vacuoles, and atypical mitochondria. Stacking of membranes within the mitochondria was also observed (Fig 5). Except for one animal that showed lymphocytic leukemia, no other abnormal findings were made on gross inspection of the organs at autopsy. It must be emphasized, however, that the only organ examined microscopically was the liver, since it was this organ that was primarily affected by Aroclor 1254 and Aroclor 1260 as pre-

MONS 205010

viously reported from our laboratory.[5,6]

COMMENT

Levels of PCB-derived components found in adipose tissue reached a level of 92 ppm (Aroclor 1242) and of 182 ppm (Aroclor 1016) after two months' exposure of rats to a diet containing 100 ppm, with little increase thereafter. Although food consumption of the rats was the same in both groups, rats on Aroclor 1016 had higher residues. It is possible that Aroclor 1016 is absorbed better from the gastrointestinal tract than Aroclor 1242. Another possibility is that storage varies between the two compounds. The higher residue levels of Aroclor 1016 vs Aroclor 1242 could be attributable to PCB quantitation. It is known that the degree of chlorination and the position of the chlorine substitution contribute to the electron capturing properties of these compounds. In some instances their electron capture responses are not proportional to their concentration.[10,11] An alternative to quantitating the PCB derivatives in tissue could be complete chlorination of the biphenyls to decachlorobiphenyl.[12] Whether a combination of the various factors outlined contributed to the difference in the PCB concentration at similar exposure times is at present not known. The concentrations in the other organs were often higher for Aroclor 1016, and the residues that were built up in the tissues decreased faster for this compound once exposure to the PCBs was discontinued.

From previous experience with Aroclor 1254[4] equilibrium seems to be reached sooner, and elimination after exposure has been discontinued is more rapid with Aroclors 1242 and 1016.

Mass spectral identification of PCBs in composite fat and urine samples was based on: (1) the presence of the correct molecular ion, (2) characteristic chlorine isotopic clusters, and (3) observed fragmentation patterns. These were all in agreement with previously published data.

The presence of DCHB and TCHB in Aroclor 1016 urine composite is in keeping with published data on metabolic products for these compounds.[13] However, one would generally not expect the method of extraction employed here (hexane at pH 7) to extract these metabolic products since they are generally found bound in the urine as glucosiduronides,[14] and are detected following hydrolysis of the urine. It is feasible that small amounts of hydroxylated compounds could be found as free phenols and could then be chromatographed under selected conditions. As could be expected, the concentrations of the PCBs were much lower in the liver, kidneys, and brain than in adipose tissue, and even lower in plasma. Plasma concentration probably is not a very good indicator of the amount of PCBs stored in adipose tissue.

The morphological changes observed in the liver are similar to those observed with other chlorinated hydrocarbons.[15] They were generally mild, particularly when compared with findings made earlier with Aroclor 1254 and 1260.[4,5] Neither the pronounced lipid accumulation nor the adenofibrosis was observed in this study. However, some brown pigment was observed in the macrophages of the livers of some rats fed Aroclor 1242 but not Aroclor 1016. It was not determined whether the pigment represented ceroid or whether part of it was caused by an accumulation of hemosiderin and porphyrin in the liver. After feeding rats Aroclor 1242 and 1016 for six months, Goldstein et al[16] found an increase in liver uroporphyrin for Aroclor 1242 at this dietary level but not Aroclor 1016 at the same dietary level. Unfortunately the number of rats was not large enough to determine if the occasional liver cell necrosis and hemorrhage that was seen was related to the exposure to Aroclor 1242. From this study it may be concluded that both Aroclor 1242 as well as Aroclor 1016 are less persistent in the rat and have also less of an effect on the liver than either Aroclor 1254 or 1260.

Aroclors 1242 and 1016 were supplied by Monsanto Chemical Company, St. Louis.

J. Carney, R. Moore, J. Coule, and J. M. Tuck gave technical assistance.

References

1. Broadhurst MG: Use and replaceability of polychlorinated biphenyls. *Environ Health Perspect* 2:81-102, 1972.

2. Koeman JH, Ten Noever De Brauw MC, et al: Chlorinated biphenyls in fish, mussels and birds from the river Rhine and the Netherlands coastal area. *Nature* 221:1126-1128, 1969.

3. Risebrough RW, Riecke P, Peakall DB, et al: Polychlorinated biphenyls in the global ecosystem. *Nature* 220:1098-1102, 1968.

4. Hagley GE, Reichel WL, Cromartie E: Identification of polychlorinated biphenyls in two bald eagles by combined gas-liquid chromatography-mass spectrometry. *J Assoc Off Anal Chem* 53:251-261, 1970.

5. Zitko V, Hutzinger O, Choi PMK: Contamination of the Bay of Fundy-Gulf of Maine area with polychlorinated biphenyls, polychlorinated terphenyls, chlorinated dibenzodioxins, and dibenzofurans. *Environ Health Perspectives* 1:47-50, 1972.

6. Curley A, Burse VW, Grim ME, et al: Polychlorinated biphenyls: Distribution and storage in body fluids and tissues of Sherman rats. *Environ Res* 4:481-495, 1971.

7. Plantonow NW, Liptrap RM, Geissinger HD: The distribution and excretion of polychlorinated biphenyls (Aroclor 1254) and their effect on urinary gonadal steroid levels in the boar. *Bull Environ Contam Toxicol* 7:358-365, 1972.

8. Kimbrough RD, Linder RE, Burse VW, et al: Adenofibrosis in the rat liver. *Arch Environ Health* 27:390-395, 1973.

9. Kimbrough RD, Linder RE, Gaines TB: Morphological changes in livers of rats fed polychlorinated biphenyls. *Arch Environ Health* 25:354-361, 1972.

10. Zitko V, Hutzinger O, Safe S: Retention times and electron capture detector responses of some individual chlorobiphenyls. *Bull Environ Contam Toxicol* 6:160-163, 1971.

11. Rote JW, Murphy PG: A method for quantitation of polychlorinated biphenyl (PCB) isomers. *Bull Environ Contam Toxicol* 6:377-384, 1971.

12. Berg OW, Siosady PL, Bees GA: Column chromatographic separation of polychlorinated biphenyls from chlorinated hydrocarbon pesticides, and their subsequent gas chromatographic quantitation in terms of derivatives. *Bull Environ Contam Toxicol* 7:315-317, 1972.

13. Hutzinger O, Nash DM, Safe S: Polychlorinated biphenyls: Metabolic behavior of pure isomers in pigeons, rats, and brook trout. *Science* 178:312-314, 1972.

14. Block WD, Cornish HH: Metabolism of biphenyl and 4-chlorobiphenyl in the rabbit. *J Biol Chem* 234:3303-3307, 1959.

15. Kimbrough RD, Gaines TB, Linder RE: The ultrastructure of livers of rats fed DDT and dieldrin. *Arch Environ Health* 22:160-165, 1971.

16. Goldstein JA, Hickman P, Bergman H, et al: Induction of hepatic porphyria and drug metabolism by two polychlorinated biphenyls (PCBs) mixture containing 42% chlorine (Aroclor 1016 and 1242), abstract. *Fed Proc* 33:219, 1974.

MONS 205011

Safety Evaluation in the Home of Polyvinyl Chloride Resin Strip Containing Dichlorvos (DDVP)

John S. Leary; William T. Keane, DSc; Cleve Fontenot, MS; Edmund F. Feichtmeir, PhD; David Schultz; Bela A. Koos; Louis Hirsch, MD; Edward M. Lavor; Clifford C. Roan, PhD; Charles H. Hine, MD, PhD

In a period of two years a series of three-home studies involving 26 families in Arizona was conducted to further evaluate the safety of the dichlorvos (DDVP)-containing insecticide strip. Physical examination, hematologic and clinical chemistry measurements, blood cholinesterase assays, and analysis of air and food for dichlorvos were carried out. Exposures were designed to be exaggerated in that strips were used throughout the homes (averaging 7 to 11 per home) and replaced with fresh ones, either every three months for one year or monthly for six months.

Throughout the studies, all examinations and measurements revealed no adverse effect on health. The red cell cholinesterase activity also remained unaffected. A slight plasma cholinesterase depression of no toxicological importance was observed in the study where the strips were replaced monthly over six months.

In homes containing 8 to 18 strips, maximum air and food concentrations of dichlorvos averaged approximately 0.13 mg/cu m and 0.12 ppm, respectively.

Submitted for publication May 24, 1974; accepted July 25.

From the Shell Chemical Company, Houston (Mr. Leary and Mr. Fontenot); the law firm of Langerman, Begam and Lewis (Dr. Keane); the Shell Development Company, Modesto, Calif (Dr. Feichtmeir, Mr. Shultz, and Mr. Koos); Associates of Laboratory Medicine, Tucson (Dr. Hirsch and Mr. Lavor); the University of Arizona, Tucson (Dr. Roan); and the Hine Laboratories, San Francisco (Dr. Hine).

Read before the Tenth Annual Meeting of the Society of Toxicology, Washington, DC, March 7-11, 1971.

Reprint requests to The Shell Chemical Company, One Shell Plaza, Houston, TX 77001 (Mr. Leary).

Dichlorvos (2,2-dichlorovinyl dimethyl phosphate; DDVP) has been employed as an insecticide for the control of flying insects for a number of years. The early methods of application were conventional and included liquid and aerosol sprays.[1,2] More recently, the solid matrix or strip form has been widely used. The three studies reported here are based on vaporization of the active material from a polyvinyl chloride (PVC) solid formulation, the objective being to determine whether such products would affect health. Residue data for food under practical use conditions have been reported by Elgar and his co-workers[3-5] and by Collins and DeVries.[6]

Because of an interest in both the control of disease-carrying insects and the safety of pesticides used in man's environment, the US Public Health Service, in collaboration with the World Health Organization, conducted a series of animal and human safety studies[7-11] on dichlorvos. One basic finding common to all of the studies was the absence of any effect on acetylcholinesterase (A ChE) of the red blood cells (RBCs) of man, when the chemical was applied at insecticidal concentrations. The effect on plasma cholinesterase (P ChE) was either absent or minimal.

Zavon and Kindel[12] conducted the first studies involving exposure of volunteers to dichlorvos insecticide generators in dwellings of the type commonly found in the United States. Under practical conditions and at the recommended rate of one strip per 1,000 cu feet, no effect on the health of these people was found, and ChE values for plasma and RBCs remained within the normal range.

As a continuation of this type of investigation, a series of dwelling studies was conducted in Tucson, Ariz. The geographical area was selected to achieve exposures to maximum air concentration of dichlorvos under conditions of practical use, since it is known that the air concentration of dichlorvos generated by the strip varies directly with temperature and inversely with humidity (PE Porter, written communication, Oct 18, 1962).

The three studies were designated as Arizona I, II, and III—the order in which they were run. The objective of the first study was to determine whether or not exposure of humans to dichlorvos strips continuously over an entire year (by replacing the strips every three months) would affect health. Arizona II was conducted under very exaggerated conditions of exposure to the strips, which were replaced monthly during six months of exposure. The purpose of Arizona III was to secure more precise measurements of air concentrations, ChE activity, and food residues under conditions further conducive to maximal dichlorvos exposure.

METHODS AND MATERIALS

The methodology for each of the studies is given separately.

MONS 205012

INDUCTION OF LIVER TUMORS IN SHERMAN STRAIN FEMALE RATS BY POLYCHLORINATED BIPHENYL AROCLOR 1260 (R) [1,2]

Renate D. Kimbrough[3], Robert A. Squire[4], Ralph E. Linder[5], John D. Strandberg[6], Richard J. Montali[6], and Virlyn W. Burse[3]

1 Received

2 Supported in part by Public Health Service Contract No. 1-CP4-3300 and No. 1-CP4-3288 from the Division of Cancer Cause and Prevention, National Cancer Institute.

3 Toxicology Branch, Center for Disease Control, Public Health Service, U. S. Department of Health, Education & Welfare, Atalnta, Georgia 30333. Address reprint requests to R. D. Kimbrough.

4 National Cancer Institute, Bethesda, Maryland 20014

5 Environmental Protection Agency, Research Triangle Park, North Carolina 27711.

6 The Johns Hopkins University, School of Medicine, Baltimore, Maryland 21205

Exhibit 8

MONS 205013

SUMMARY

200 Sherman Strain female rats were fed 100 ppm of a polychlorinated biphenyl (Aroclor (R) 1260) for approximately 21 months, and 200 female rats were kept as controls. The rats were sacrificed when 23 months old. Twenty-six of 184 experimental rats and 1/173 control rats examined had hepatocellular carcinomas. None of the controls, but 146/184 experimental rats had neoplastic nodules in their liver and areas of hepatocellular alteration were noted in 28/173 controls and 182/184 experimental rats. It was concluded that the polychlorinated biphenyl Aroclor (R) 1260 had a hepatocarcinogenic effect in female Sherman Strain rats when fed in the diet. The incidence of tumors in other organs did not differ appreciably between the experimental and control groups.

INTRODUCTION

Polychlorinated biphenyls (PCB) have been used over the past 44 years as transformer, capacitor, and cooling fluids in various systems (1). They are excellent dielectrics and flame retardants which have found many new industrial uses, particularly in the past two decades. They are very persistent as environmental contaminants and were first established as pollutants in 1966 (2). The toxicity of these and related compounds has recently been reviewed (3).

In a preliminary feeding study in which the toxicities of two PCB mixtures (Aroclor(R) 1254 and Aroclor(R) 1260) were compared (4), a bladder tumor was found in one of 10 female rats fed 100 ppm Aroclor(R) 1260 in their diet. This bladder tumor at the time was tentatively classified as a poorly differentiated epidermoid carcinoma. Severe autolysis hampered the microscopic examination (Kimbrough personal communication). In order to establish whether this tumor had developed spontaneously or was induced by the PCB, 200 female rats were fed 100 ppm Aroclor(R) 1260. Another group of 200 females were kept as controls. This paper reports the results of this study.

MATERIALS AND METHODS

Four hundred 21-26 day old weanling, Sherman Strain[1], C.O.B.S., female rats, weighing 48-97 grams were distributed into 2 groups of 200 animals each according to a table of random numbers. The animals were housed 10 rats per cage in conventional humidity, light, and temperature controlled surroundings. Two hundred rats were fed plain ground Purina laboratory chow and 200 were fed the same diet containing 100 ppm Aroclor (R) 1260. Aroclor (R) 1260 was incorporated into the diet by dissolving 5.2 grams in ethyl ether, adding it to 100 g. corn starch and allowing the ether to evaporate. The PCB cornstarch mixture was blended with increasing amounts of ground chow. The diets were prepared fresh every 10-14 days. Random samples from the final mixes along with samples of control chow were taken at regular intervals to determine PCB levels, at first biweekly and later bi-monthly. The Aroclor (R) 1260 (Lot Number AK-3) was a gift from Monsanto Industrial Chemical Company, St. Louis, Missouri.

For the determination of the PCB levels, the samples were extracted for two hours on an automatic shaker using a 3:1 mixture of hexane: isopropanol (5). After filtration of the extract through glass wool, the extracts were washed with a 2% sodium chloride solution and dried with sodium sulfate. Samples were eluted through Florisil (6). The 6% fraction was collected and eluted through the silicic acid-celite column of Armour and Burke (7). The samples were analyzed by electron capture gas liquid chromatography and/or Coulson Conductometric gas liquid chromatography.

Footnote

1. The Sherman strain rats are descendants of the Sherman strain developed at Columbia University from the Osborne Mendel strain. They have been randomly bred in our own colony at the Center for Disease Control since 1950. They were cesarian obtained and barrier sustained. In the conventional rats the incidence of murine pneumonia was high. Since they have been C.O.B.S. rats this problem is no longer encountered.

During the first year of the study, three different batches of food, both when first received and after having been in the food cups for a week, were analyzed for aflatoxins (8).

The combined body weight of rats in each cage was recorded weekly until the rats were 6 months old, biweekly until 12 months and monthly thereafter. Individual weights were recorded only at the onset of the experiment and at death or sacrifice. The animals were observed briefly each day, and animals exhibiting debilitating signs or large tumors were removed from the group cage and housed individually. At each weighing the animals were examined individually and abnormalities were noted. Food consumption was measured on all rats during the first two weeks of the experiment, and then during weeks 5, 8, 11, and 20 and every 12 weeks thereafter. The dietary exposure of the experimental group to Aroclor (R) 1260 was discontinued 6 weeks before sacrifice. Autopsies were performed on all rats that died. When rats were 23 months old they were killed under ether anesthesia by severing the venae cavae. Tissues were fixed in 10% buffered formalin and stained with hematoxylin and eosin. Selected tissue sections were stained with periodic acid-Schiff, Wilder's reticulum, azure eosin, and Masson's trichrome. The following organs were studied microscopically: brain, pituitary, thyroid, parathyroid, trachea, esophagus, lungs, stomach, kidneys, heart, liver, spleen, adrenals, ovaries, uterus, urinary bladder, and tissue masses. The student t-test was used for comparing mean body weights and mean weight gain.

RESULTS

The PCB concentrations in the experimental diet ranged usually from 70-107 ppm. Occasionally lower values were found in the beginning of the study. The occurrence of low PCB concentrations in the experimental diet were later resolved by improving the method of extraction. PCBs in the control diets were less than 0.1 ppm and usually below the limit of detection. Aflatoxins were not detected in either diet. The sensitivity levels were 2.5 ppb aflatoxin B_1 and G_1 and 0.1 ppb aflatoxins B_2 and G_2. A recovery study in which aflatoxin B_1 was added to a portion of the feed showed 94% recovery.

No definite dose related signs of toxicity were observed in the test animals throughout the study. Comparative curves of body weight gain and food consumption on the basis of body weight, as well as PCB intake of the test group are given in Text-Fig. 1 and 2. A slight decline in the rate of weight gain of the test group compared to the control group began about 3 months after onset of the experiment. Mean final body weights were 420g (S.D.=72g, S.E.=5.4g) for the control group and 392g (S.D.=62g, S.E.=4.6g) in the test group; the difference was statistically significant ($p.<0.001$). Food consumption (Test-Fig. 2) was comparable in both groups throughout the study. Mean weight gain was 350g (S.D.=70g, S.E.=5.3g) and 323g (S.D.=60g, S.E.=4.5g) for the control/test groups respectively; the difference in weight gain was also statistically significant ($p<0.001$). PCB intake declined from 11.6 mg/kg/day during the first week of exposure to 6.1 mg/kg/day at 3 months of exposure and to 4.3 mg/kg/day at 20 months (Text-Fig. 2).

(Text-figure 1.) Average bodyweight of control rats and rats that consumed Aroclor 12(R)

(Text-figure 2.) Food intake of the control and experimental rats and the consumption of Aroclor (R) 1260 by the experimental rats

Figure 1 BODY WEIGHT

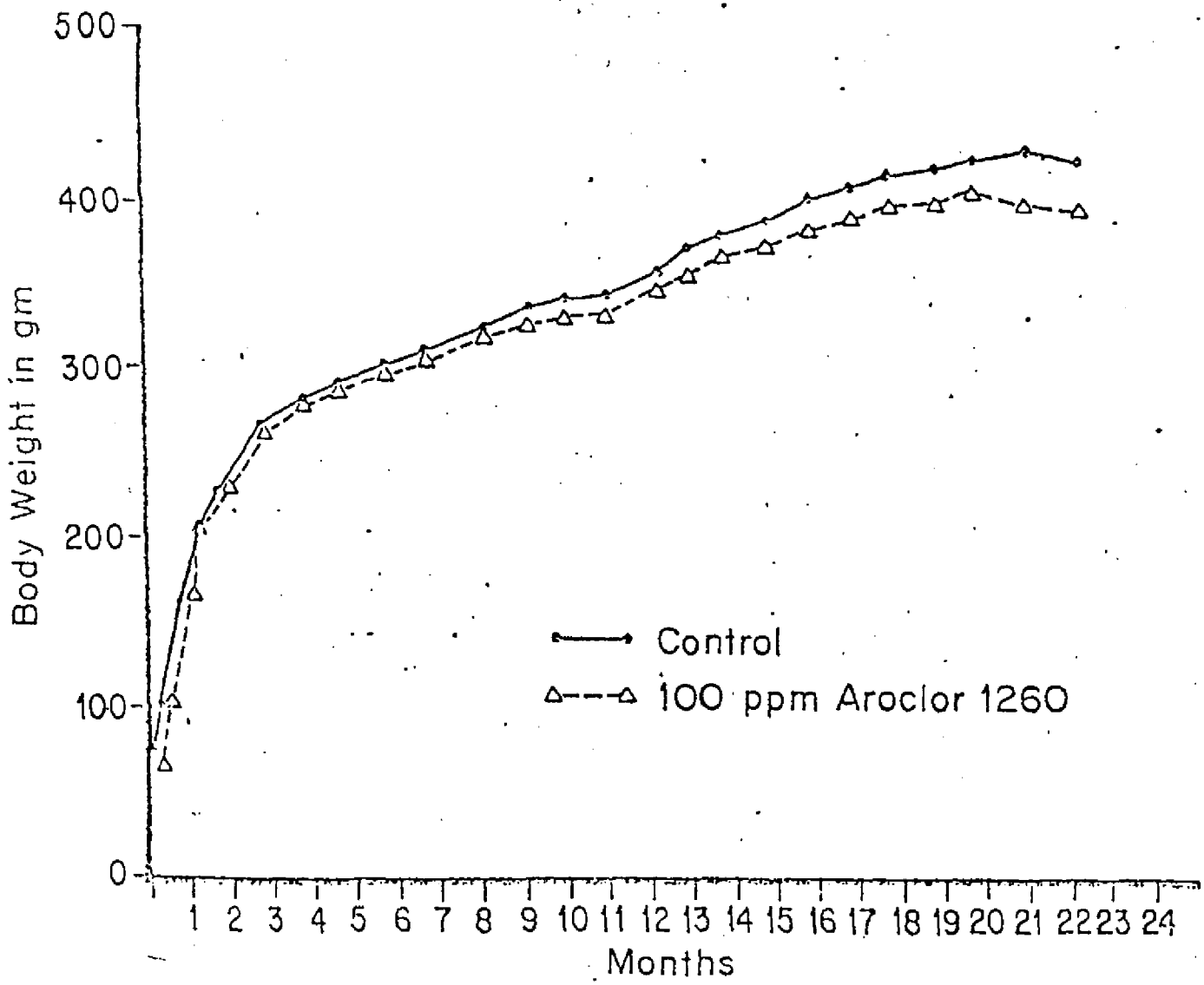

MONS 205019

Figure 2 FOOD INTAKE AND PCB CONSUMPTION

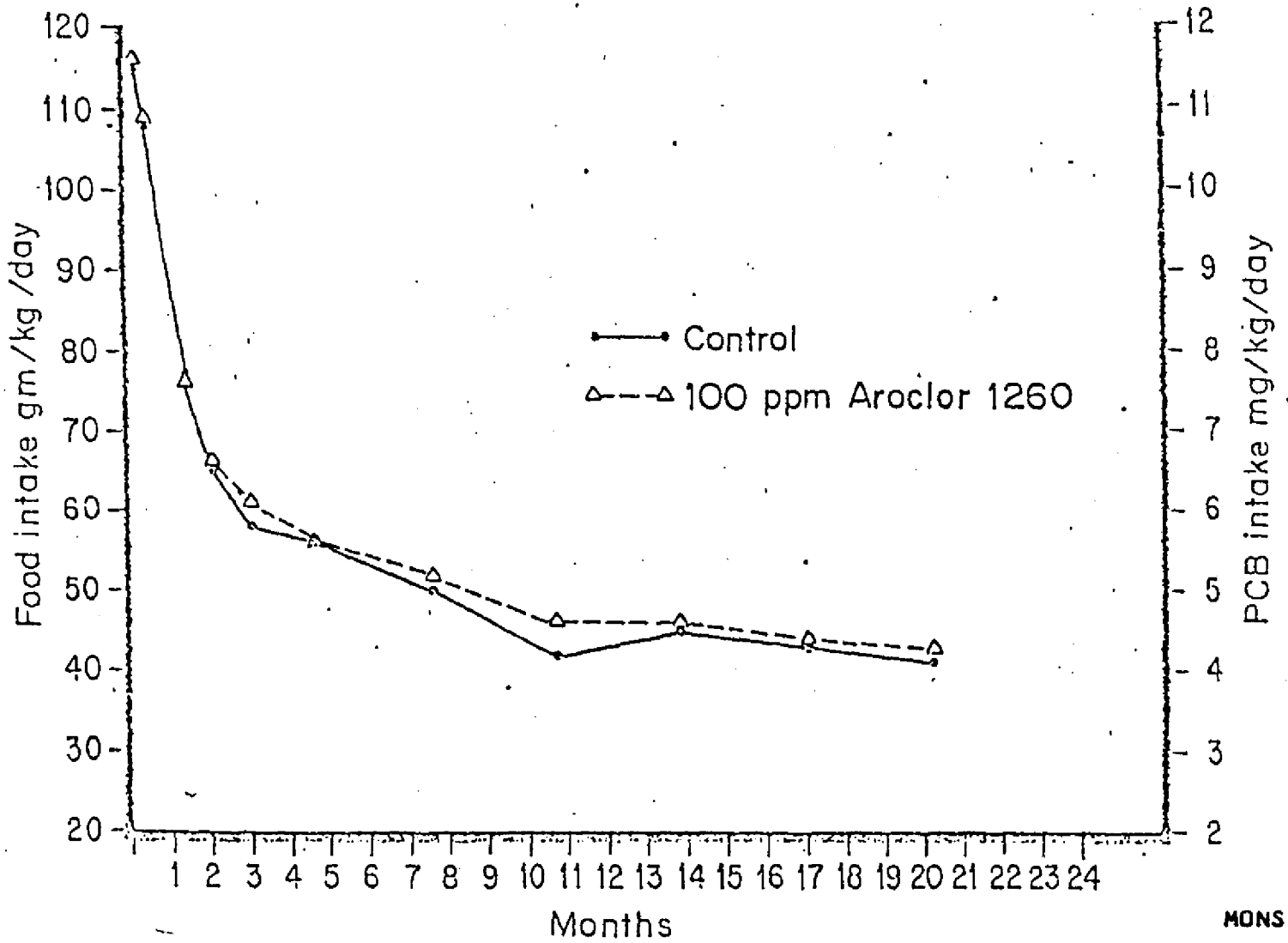

MONS 205020

PATHOLOGIC FINDINGS

173 control rats and 184 experimental animals were examined grossly and microscopically. This included 5 rats in the experimental group which were sacrificed 1-2 months before the final kill. The remaining rats were not included because of improper tissue fixation, or because they died very early in the experiment.

A consistent difference in the appearance of the livers was observed between the experimental and control groups. Almost all (170/184) livers of the experimental animals had from a few to multiple elevated tan nodules on the surface; additional nodules were usually seen on sectioning. These nodules varied from 0.1 to several centimeters in diameter, and in some animals replaced almost the entire liver. In contrast, the liver of only one control animal showed gross abnormalities and was markedly enlarged, nodular, tan and firm. In addition a variety of tumors of other organs was observed in both the experimental and the control groups. The incidence and type of tumors are given in Table 1.

Histologic examination showed that 26 experimental animals and the one control animal with enlarged, nodular livers had hepatocellular carcinomas. The additional 144 experimental animals with gross liver nodularity had hepatocellular nodules characteristic of neoplastic nodules (synonym hyperplastic nodule) (9). A recent workshop sponsored by The National Cancer Institute[2] recommended the term neoplastic nodules for these lesions, in order to more accurately indicate their biological significance. There were no nodules in control animals.

[2] Rat Liver Tumor Workshop. Silver Spring, Maryland, December 11-13, 1974. Sponsored by Carcinogenesis, DCCP, National Cancer Institute.

The hepatocellular carcinomas were well differentiated trabecular types (Fig. 1-3), except three in the experimental animals which had a glaudular, papillary pattern (Fig. 4). The trabecular tumors showed severe disruption of normal liver architecture and were usually easily recognized at low magnification. Liver plates were 2 or more cells thick in some areas and were arranged in haphazard linear, branching or pseudoglandular patterns. Different patterns were usually present in the same tumor. Blunt-ended plates, sinusoidal ectasia, and congestion were often present. The hepatocytes varied from relatively normal in appearance to enlarged, acidophilic or diffusely basophilic cells with large, hyperchromatic nuclei and prominent nucleoli. The cytoplasm often contained eosinophilic, inclusions within vacuoles. Mitotic figures were sometimes present. There were occasional foci of coagulative necrosis in cancerous areas, but no fibrosis or other evidence of chronic degenerative changes. Periodic-acid-Schiff (PAS) stains without diastase showed carcinomas to stain less intensely than uninvolved liver, suggesting a decrease in glycogen. Most of the carcinomas were more basophilic than the normal liver with azure eosin stain. No definite intravascular invasion was noted and no metastases were found.

Neoplastic nodules were generally spherical, well demarcated, and occupied areas equal to that of several liver lobules (Fig. 5). The cells in these nodules were generally enlarged and had either ground glass, diffusely basophilic or clear cytoplasm. Enlarged, hyperchromatic nuclei, double nuclei and mitotic figures were often present. The cytoplasm often contained inclusions similar to those in the carcinomas, except they were larger and appeared as whorled, concentric lamellae. In previous studies [3] these formations were shown to represent aggregates of smooth endoplasmic reticulum by electron microscopic examination. The normal liver architecture was absent within nodules and cells were in sheets or irregular plates. Portal areas and central veins were absent and sinusoids were dilated in some areas. At the periphery of the nodules the surrounding liver plates were tangentially arranged and narrowed due to compression (Fig. 6). Nodules varied in PAS positivity, but always differed from surrounding liver. Most nodules were more eosinophilic, and a few more basophilic than the normal liver with azure eosin stain.

In 182 treated and 28 control animals there were also foci or areas of hepatocytes with altered cytoplasm (Fig 7-9). In controls these were mostly collections of cells with water clear cytoplasm. In treated animals most affected cells were enlarged and had eosinophilic, ground glass appearing cytoplasm or were diffusely basophilic and smaller than normal cells. In basophilic areas, sinusoids were dilated and liver plates somewhat tortuous. In general the cells in these areas were similar to those in neoplastic nodules but there were no architectural alterations, and plates of involved liver cells merged with the surrounding liver.

No unusual features were noted in tumors of other organs and there were no apparent differences in incidence between experimental and control animals. Parafollicular thyroid tumors varied from small circumscribed nodules of pale, oval to spindle cells to masses which obliterated the gland and invaded the capsule. They were similar to those described by Boorman et al. (10). Other relatively frequent tumors included pituitary chromophobe adenomas, mammary fibroadenomas and endometrial polyps. Endometrial stromal sarcomas were also present in ten animals.

Only one bladder tumor was observed and that in a control animal. Therefore the occurrence of the bladder tumor in the previous experiment was apparently unrelated to the ingestion of Aroclor (R) 1260.

A few rats in the experimental group also showed areas of adenofibrosis, (synonym cholangiofibrosis) of the liver, a lesion described previously following the administration of Aroclor (R) 1260 (4).

DISCUSSION

The livers of treated animals showed neoplastic lesions in 170 of the 184 animals examined, and only one in 173 controls. Although only 26 of the lesions in treated animals were clearly carcinomas according to traditional histologic criteria, neoplastic nodules are part of the spectrum of response to hepatocarcinogens and must be included in the evaluation of tumorigenesis.

In the past, these liver lesions have been interpreted in a variety of ways, and different names have been used to report them such as nodular hyperplasia, hyperplastic nodules (11), hepatomas (12& 13) and hepatic nodules (14) Similar ambiguity exists in the classification of human liver lesions of this type (15).

Several studies using known carcinogens have demonstrated the development of liver nodules, indistinguishable from the neoplastic nodules in this study, prior to the appearance of carcinoma (11,16,17,18). In a recent review (9) the biology and significance of nodules and their relationship to hepatocellular carcinoma was thoroughly discussed. In our study, Aroclor(R) 1260 induced a spectrum of nodules and cancers in treated animals as outlined by the rat liver tumor workshop (footnote 2).

A few Japanese polychlorinated biphenyls and the American Product Aroclor 1254, have been shown to induce neoplastic liver lesions in rodents. In a study with male Balb/cj mice, nodules were observed in the liver after 11 months of exposure to Aroclor 1254 (19). The Japanese PCB's Kanechlor 400 and 500 have been reported to produce liver tumors in female Donryu rats and in male dd mice, respectively (20,21). PCBs have a promoting effect on liver tumor induction by benzene hexachloride (21) while they protected male Sprague-Dawley rats from the tumor inducing effect of the three hepatocarcinogens: 3'-methyl-4-dimethyl aminoazobenzen, N-2-fluorenylacetamide and diethylnitrosamine (22). The authors suggested that this protective effect may be due to the induction of microsomal enzyme by PCB's. The animals which were only treated for 20 weeks probably did not receive the material long enough for the PCBs to induce tumors.

Hepatocarcinogenicity by Aroclor 1260

It is presently not known whether mixtures of polychlorinated biphenyls that are primarily composed of isomers with four or less chlorines on the ring would also induce liver tumors, or whether only those mixtures that contain an appreciable proportion of penta-, hexa-, and hepta-chlorobiphenyl have this effect. Kanechlor 400 contains 3% di-, 32.8% tri-, 43.8% tetra-, 15.8% penta-, 4.6% hexachlorobiphenyl. Kanechlor 500 contains 5% tri-, 26% tetra-, 55% penta-, 13.% hexachlorobiphenyl[21]. Chlorinated dibenzofuran was found in one Kanechlor 400 sample (23).

The predominant compounds in Aroclor 1260 were hexachlorobiphenyls with significant level of heptachlorobiphenyl (24).

ACKNOWLEDGEMENT

The authors wish to thank Mr. Martin Goldstein, FDA, New Orleans District for the feed analysis for aflatoxins and Mr. Sol Cohen, FDA, Atlanta District for helpful suggestions. Mr. Richard Moore (EPA) assisted with the animal care and the autopsies.

MONS 205028

TABLE 1. The incidence and type of liver lesions and tumors of other organs examined histologically

ORGAN	TYPE OF LESION	INCIDENCE	
		Controls	Experimental
Liver	hepatocellular carcinoma	1/173	26/184
	neoplastic nodules	0/173	144/184
	foci or areas of cytoplasmic alteration	28/173	182/184
Thyroid	parafollicular cell tumor	37/160	18/166
Adrenal	pheochromocytoma	1/173	1/167
Pituitary	chromophobe adenoma	41/153	28/139
	carcinoma	0/153	1/139
Uterus	endometrial polyp	18/149	25/163
	adenocarcinoma	0/149	2/163
	sarcoma of the endometrial stroma	3/149	7/163
Urinary Bladder	transitional cell papilloma	1/167	0/169
Mammary gland	fibroadenoma	17/173*	13/184*
	adenocarcinoma	5/173*	1/184*

ORGAN	TYPE OF LESION	INCIDENCE Controls	Experimental
Salivary gland	fibrosarcoma	1/173*	0/184*
Lung	adenoma	2/173	2/184
Adipose tissue	lipoma	0/173*	2/184*
Brain	glioma	0/173	2/184
Ovary	granulosa theca cell tumor	5/149	0/163
	papillary adenoma	1/149	2/163
Hematopoietic System	granulocytic leukemia	1/173	0/184
	lymphoma	0/173	2/184
Kidney	hemangioma	0/173	1/184
Thymus	thymoma	1/173*	0/184*
Parathyroid	adenoma	0/173	2/184
Skin	fibroma	0/173*	1/184*

* Incidence based on gross detection with microscopic confirmation.

REFERENCES

1. Broadhurst, M.G.: Use and Replaceability of Polychlorinated Biphenyls. Environ. Health Perspect. No. 1:81-102, 1972.
2. Jensen, S.: A New Chemical Hazard. New Sci. 32:612, 1966.
3. Kimbrough, R.D.: The toxicity of polychlorinated polycyclic compounds and related chemicals. CRC Crit. Rev. Toxicol. 2:445-498, 1974.
4. Kimbrough, R.D., Linder, R.E., and Gaines, T.B.: Morphological changes in livers of rats fed polychlorinated biphenyls. Arch. Environ. Health 25:354-364, 1972.
5. Dawsey, L.H., Barthel, W.F., Schuttmann, R.L., and Girling, E.F.: U.S.D.A., A.R.S., Plant Pesticide Control Division, Southern Region Manual, pp 56-59, June 1965.
6. Mills, P.A.: Detection and Semiquantitative Estimation of chlorinated organic pesticide residues in foods by paper chromatography. J. Assoc. Off. Agri. Chem. 42:734-740, 1959.
7. Armour, J., and Burke, J.: Method for separating polychlorinated biphenyls for DDT and its analogs. J. Assoc. Off. Anal. Chem. 53:761, 1970.
8. Pons, W.A., Jr., Cucullu, A.F., and Lee, L.S.: Determination of aflatoxins in mixed feeds. Third International Congress of Food, Science and Technology (S.O.S./70), Washington, D.C., pp 705-711, 1970.
9. Farber, E.: Hyperplastic liver nodules. Chapter VIII. In: Methods in Cancer Research, Vol. 7, London, Acad. Press, N.Y., pp. 345-375, 1973.
10. Boorman, G.A., Van Boord, M., and Hollander, C.F.: Naturally occurring medullary thyroid carcinoma in the rat. Arch. Pathol. 94:35-41, 1972.

11. Epstein, S., Ito, N., Merkow, L., and Farber, E.: Cellular analysis of liver carcinogenesis: the induction of large hyperlastic nodules in the liver with 2-fluroenylacetamide or Ethionine and some aspects of their morphology and glycogen metabolism. Cancer Res. 27:1702-1711, 1967.

12. Vesselinovitch, S.D., and Mihailovich, N.: The induction of benign and malignant liver tumors by urethan in newborn rats. Cancer Res. 28:881-887, 1968.

13. Edwards, J.E., White, J.: Pathologic changes with special reference to pigmentation and classification of hepatic tumors in rats fed paradimethyl amino azo benzene (butter yellow). J. Natl. Cancer Inst. 2:157-183, 1941.

14. Popper, H., Sternberg, S.S., Oser, B.L., and Oser, M.: The carcinogenic effect of aramite in rats. Cancer 13:1035-1046, 1960.

15. Mays, E.T., Christopherson, W.M., and Barrows, G.H.: Focal nodular hyperplasia of the liver. Am. J. Clin. Pathol. 61:735-746, 1974.

16. Klavins, J.V., Kenney, T.D., and Kaufman, N.: Hepatic nodules resembling tumors in rats after administration and withdrawal of ethionine. Proc. Soc. Exp. Biol. Med. 89:540-543, 1965.

17. Popper, H., de la Huerga, J., and Yesinick, C.: Tumors due to prolonged ethionine feeding. Science, 118:80-82, 1953.

18. Wachstein, M., and Meisel, E.: Enzymatic histochemistry of ethionine induced liver cirrhosis and hepatoma. J. Histochem. Cytochem. 7:189-201, 195

19. Kimbrough, R.D., and Linder, R. E.: Induction of Adenofibrosis and hepatomas of the liver in BALB/cj mice by polychlorinated biphenyls (Aroclor 1254) J. Natl. Cancer Inst. 53:547-552, 1974.

20. Kimura, N.T. and Baba, T.: Neoplastic changes in the rat liver induced by polychlorinated biphenyl. Gann 64:105-108, 1973.

21. Ito, N., Nagasaki, H., and Aria, M., et al.: Histopathologic studies on liver tumorigenesis induced in mice by technical polychlorinated biphenyls and its promoting effect on liver tumors induced by benzene hexachloride. J. Natl. Cancer Inst. 51:1637-1646, 1973.

22. Makiura, S., Aoe, H., Sugihara, S., Hirao, K., Arai, M., and Ito, N.: Inhibitory effect of polychlorinated biphenyls on liver tumorigenesis in rats treated with 3'-Methyl-4-dimethylaminoazobenzene, N-2-Fluorenylace Fluorenylacetamide, and Diethylnitrosamine. J. Natl. Cancer Inst. 53: 1253-1257, 1974.

23. Roach, J.A.G. and Pomerantz, J.H.: The findings of chlorinated dibenzofurans in a Japanese polychlorinated biphenyl sample. Bull. Environ. Cont. Tox. 12:338-341, 1974.

24. Sissons, D. and Welti, D.: Structural identification of polychlorinated biphenyls in commercial mixtures by gas-liquid chromatography, nuclear magnetic reference and mass spectrometry. J. Chromatogr. 60:15-32, 1971.