ROLE OF LAPAROTOMY AND SPLENECTOMY IN THE MANAGEMENT OF HODGKIN'S DISEASE

LEONARD R. PROSNITZ, MD,* SHERWIN B. NULAND, MD,† AND MORTON M. KLIGERMAN, MD‡

We have performed laparotomy and splenectomy for 40 patients with untreated Hodgkin's disease as part of the initial diagnostic evaluation. Approximately 25% of patients who were felt to have disease limited to above the diaphragm, on the basis of the initial clinical and laboratory examination (including lymphangiography), were found to have abdominal disease on surgical exploration. Of the patients with abdominal disease, 75% had histologically involved spleens, which were seldom detected preoperatively. In none of these patients was the liver involved. About 50% of our patients with abdominal disease failed to have a contiguous pattern to their sites of involvement, which suggests that Hodgkin's disease may be multicentric in origin in some patients. The therapeutic benefits of splenectomy are also detailed. This operation appears to be a valuable procedure in the evaluation of patients with Hodgkin's disease and their subsequent management and expectation of cure with radical radiotherapy.

HODGKIN'S DISEASE IS PRESENTLY VIEWED AS a disorder which is localized at the onset and then spreads through adjacent lymph node areas before finally becoming generalized. The possibility that it is multicentric in origin in a certain percentage of patients has not been excluded, however. Noteworthy success in controlling the disease in its early stages has been achieved by aggressive radiation therapy. Approximately 80–90% of patients with Stage I and II disease survive 5 years. Fifty to sixty per cent of Stage I and II patients survive 5 years free of disease and are apparently cured.[3,6,12,13] Preliminary data indicate that similar results can be obtained with Stage III A patients.

To carry out curative radiation therapy of Hodgkin's disease, precise knowledge of the extent of the disease is essential. In order to visualize abdominal nodes, lower extremity lymphangiography was developed in the early 1960s. Despite initial enthusiasm for this procedure, conflicting information regarding its diagnostic accuracy has appeared in the literature. In our experience at Yale, results of lymphangiography have often been equivocal, with the diagnostic radiologist unable to say with a high degree of certainty whether the visualized abdominal nodes are abnormal or not. Furthermore, early diagnosis of abdominal disease seems to be quite important. New disease discovered in the abdomen after disease above the diaphragm has been treated has been associated with a poor prognosis.[13]

For these reasons, and with the knowledge of a similar study in progress at the Stanford Medical Center,[4] we began, in January 1969, to explore the abdomen surgically as part of the initial diagnostic workup and to remove the spleen at the same time. Unexpected findings in the first few patients so treated have led us to continue this program and to include virtually all new patients with Hodgkin's disease. Our purpose here is to report the findings obtained at laparotomy in previously untreated patients. We will describe the effects of this procedure on the staging and subsequent management of the patient and also the therapeutic benefits to be derived.

In addition, we have attempted to preserve ovarian function in women in the child-bearing age in whom pelvic irradiation is necessary by moving the ovaries to the midline and marking their position with metallic clips so

Supported by USPHS Grant CA 06519-08.

* Assistant Professor of Radiology, Department of Radiology, Yale University School of Medicine, New Haven, Conn.

† Senior Clinical Associate in Surgery, Department of Surgery, Yale University School of Medicine.

‡ Robert E. Hunter Professor of Radiology, and Chairman, Department of Radiology, Yale University School of Medicine.

Received for publication May 27, 1971.

they may subsequently be shielded.[17] Results of this procedure will be described.

METHODS

New patients with biopsy-proven Hodgkin's disease were first evaluated with a complete history and physical examination and a number of laboratory and x-ray tests. The latter procedures are listed in Table 1. The liver was considered positive if it was clinically enlarged or if any single liver function study (with the exception of a liver scan) was abnormal. If the spleen was palpable, it was considered positive. Significantly enlarged lymph nodes were considered to be involved. Occasionally, palpable nodes were felt to be not significant, e.g., in the inguinal areas. The patients were then tentatively staged according to the classification proposed by the conference on Hodgkin's disease at Rye, New York in 1965 (Table 2).[14] Equivocal lymphangiograms were considered negative and the patient staged as not having disease in the nodes in question, in accordance with the general principles of understaging patients with malignant disease when the exact stage is not certain. The histology was classified using the Rye Conference modification of the Lukes-Butler classification which divides Hodgkin's disease into the four subgroups of lymphocyte predominance, lymphocyte depletion, mixed cellularity, and nodular sclerosis.[10] Surgical exploration was then performed on almost all patients. It was not offered to those patients felt to have a medical contraindication to surgery or to those too ill with their Hodgkin's disease to have surgery initially. In 23 patients, the operation was done by one of us (S.B.N.). Surgery was carried out in a little more than half the patients before any radiation therapy was undertaken, and, in the remainder, the operation was performed between the irradiation of the cervical, axillary, mediastinal areas (mantle field), and abdominal irradiation. It was our initial feeling that splenectomy performed after the mantle field and before abdominal treatment might improve the hematologic tolerance to the treatment to a greater extent than if the splenectomy were performed before any radiation therapy had taken place. We will present some data on this point subsequently. All patients with systemic symptoms had the surgery performed prior to any radiation therapy, and all patients in whom there was any suspicion of Stage IV disease had their surgery performed prior to any treatment. Subsequent to surgical exploration becoming a consistent policy, only two patients have not had surgery. In one of these, the referring physician and a consultant hematologist advised against it.

TABLE 1. Diagnostic Procedures

X-ray studies
Chest x-ray with laminograms
Lymphangiogram
Intravenous pyelogram (done with lymphangiogram)
Inferior vena cavagram (if indicated)
Blood tests
CBC including platelet count
Reticulocyte count
All liver function studies including BSP
Prothrombin time
Partial thromboplastin time
Blood urea nitrogen
Serum creatinine
Serum copper
Haptoglobin
Coombs' test
Uric acid
5'Nucleotidase
Australia antigen
Skin tests
Tuberculin
Candida
Mumps
Trichophyton
DNCB
Miscellaneous
Bone marrow aspiration and biopsy
Liver and spleen scan
Electrocardiogram

The operation included the following:

1. Splenectomy. A generous portion of

TABLE 2. Staging of Lymphomas

Stage I. Disease limited to 1 anatomic region or to 2 contiguous anatomic regions on the same side of the diaphragm.

Stage II. Disease in more than 2 anatomic regions or in 2 noncontiguous anatomic regions on the same side of the diaphragm.

Stage III. Disease on both sides of the diaphragm but not extending beyond the involvement of lymph nodes, spleen and/or Waldeyer's ring.

Stage IV. Involvement of the bone marrow, lung parenchyma, pleura, liver, bone, skin, kidneys, gastrointestinal tract or any tissue or organ in addition to lymph nodes, spleen, or Waldeyer's ring.

A and B subclasses indicate absence or presence of systemic symptoms, respectively. The following documented symptoms are significant: a. fever; b. night sweats; c. pruritus.

splenic pedicle was resected as well and metallic clips placed along the course of the splenic artery to aid the radiotherapist in designing his treatment portals.

2. Biopsy of para-aortic nodes, particularly any that appeared suspicious or definitely involved on the lymphangiogram. Films were occasionally taken in the operating room to insure that the node in question had actually been removed.

3. Biopsy of any celiac axis, mesenteric, or porta-hepatic nodes that appeared at all suspicious.

4. Wedge and needle biopsy of the left lobe of the liver.

Details of the technical aspects of the surgical procedure and complications have been presented elsewhere.[11]

At almost all operations, the attending radiotherapist was present in the operating room. We have found this helpful to the surgeon in the placement of metal clips and removal of the precise para-aortic nodes that are desired for biopsy. In turn, the radiotherapist gains a direct knowledge of the location of intra-abdominal disease.

In most of our female patients who desired future child-bearing, moving of the ovaries was generally carried out at the same time as the laparotomy and splenectomy, although a separate incision in the lower abdomen was necessary. However, when grossly benign-looking tissue proved to be microscopically involved or when unsuspected disease was found in the abdomen, a second operation was performed to move the ovaries. We found it wise not to rely on a frozen section to make or exclude a histologic diagnosis of Hodgkin's disease, and thus it was always necessary to wait for the permanent sections.

RESULTS

From January 1969 through December 1970, 45 patients with Hodgkin's disease have undergone abdominal exploration. Five of these represented previously treated patients who were being reevaluated for new disease within the abdomen. The remaining 40 patients represented newly diagnosed and untreated patients. In the last 18 months, only two newly diagnosed patients have not had laparotomy, as previously mentioned.

The clinical data on the 40 patients explored are detailed in Table 3. The effect on staging of the patients subsequent to laparotomy is shown in Table 4. Of the 26 patients tentatively classified as Stage I or II before exploration, 7 had their staging advanced to Stage III. In no patient was the staging reduced, and none was found to be Stage IV.

The correlation of lymphangiography with subsequent abdominal findings is shown in Table 5. The lymphangiogram was read as positive in 14 cases. Thirteen were confirmed histologically, and one patient was not biopsied but the nodes appeared grossly positive. In the 13 negative lymphangiograms, however, 4 were histologically positive. Similarly, 2 of 11 equivocal lymphangiograms proved to be positive histologically. One additional patient had Stage II disease confined to the abdomen.

There was a high incidence of involvement of the spleen and splenic hilar nodes which, in our series, seldom was detected preoperatively. Of 21 patients with abdominal disease, 15 had positive spleens. Usually positive splenic hilar nodes accompanied a positive spleen, but two patients had positive hilar nodes, a negative spleen, and positive para-aortic nodes. One patient had positive hilar nodes as the only intra-abdominal pathology. The relationship of splenic weight to histologic involvement is shown in Fig. 1. In general, there was no correlation between the weight of the spleen and whether or not the organ was involved.

Liver disease was not suspected preoperatively in any of our patients and was not found at the time of surgery. Granulomatous changes of questionable significance were noted in the livers of several patients, as has been described by Kadin et al.[5]

The relationship of disease in the neck and in supraclavicular and mediastinal areas to the abdominal findings is shown in Table 6. Each area is considered independently of the others in relation to the abdominal findings. There was no distinctive pattern of involvement above the diaphragm which correlated with the presence of abdominal disease, in this series of patients. Of the total of 40 patients, 21 had Stage III disease after surgical exploration. If we assume that the mediastinum and/or the left supraclavicular nodes are contiguous areas to the para-aortic and splenic hilar nodes, as has been postulated,[4] 9 of these 21 patients failed to manifest contiguous spread of their disease. Seventeen of 18 patients with disease limited to above the diaphragm had involvement of contiguous areas. Thus, 10 of the total group of 40 showed evidence of noncontiguous disease.

TABLE 3. Preoperative and Surgical Findings in 40 Patients with Untreated Hodgkin's Disease

			Preoperative Impression								Postoperative Findings				
Patient	Age & sex	Histology*	Neck	Supra-clav.	Axilla	Medias-tinum	Lymphang-†iogram	Liver	Spleen	Tentative stage	Para-aortic	Splenic hilum	Spleen (wt. g)	Liver	Final stage
AB	31F	NS	L	L	L	+	±	–	–	IIA	–	–	–(153)	–	IIA
TM	47M	NS	–	–	L	–	–	–	–	IA	+	+	+(173)	–	IIIA
AS	29F	NS	–	R	–	+	+	–	–	IIIB	0‡	+	+(138)	0	IIIB
SL	22F	NS	–	R	–	+	+	–	–	IIIA	+	+	+(180)	–	IIIA
NH	7F	NS	–	R	–	+	+	–	–	IIIA	+	–	–(76)	–	IIIA
RS	26M	Mixed	R	–	–	–	–	–	–	IA	–	–	–(120)	–	IA
KM	24F	Mixed	L	–	–	+	+	–	–	IIIA	+	–	+(110)	–	IIIA
JM	18F	NS	–	L	–	–	–	–	–	IA	–	–	–(163)	–	IA
PF	17F	NS	L	L	–	+	±	–	–	IIA	–	–	–(170)	–	IIA
JB	18F	NS	R&L	L	R&L	–	+	–	–	IIIA	+	+	–(195)	–	IIIA
YD	20F	NS	L	–	–	+	±	–	–	IA	–	+	–(288)	–	IIIA
BC	9M	NS	R	R	–	–	–	–	–	IA	+	+	–(150)	–	IIIA
AH	24M	Mixed	L	L	R	–	–	–	–	IIA	+	+	+(185)	–	IIIA
FF	15M	NS	R	R	–	+	–	–	–	IIA	–	–	–(250)	–	IIA
DH	15M	Mixed	L	–	–	–	±	–	–	IA	–	–	–(230)	–	IA
DT	27M	NS	R&L	–	L	–	±	–	–	IIA	+	+	+(900)	–	IIIA
CC	31F	NS	–	–	–	+	±	–	–	IA	–	–	–(370)	–	IA
TJ	29M	NS	–	L	–	–	+	–	–	IVB	+	–	–(130)	–	IVB
DN	17F	Mixed	R	–	–	–	–	–	–	IA	–	–	–(260)	–	IA
SP	5F	LP	L	–	–	–	0	–	–	IA	–	–	–(150)	–	IA
DP	37M	LD	–	R	–	–	–	–	–	IB	+	+	+(150)	–	IIIB
CL	18F	Mixed	–	–	L	–	+	–	+§	IIIB	+	+	+(500)	–	IIIB
JG	25F	LD	–	L	L	+	–	–	+§	IIB	–	–	–(450)	–	IIB
WD	62M	Mixed	R	R&L	R&L	–	+	–	–	IIIA	+	+	+(150)	–	IIIA
EG	40F	NS	L	–	–	–	+	–	–	IIIA	+	–	–(116)	–	IIIA
WM	26M	Mixed	R&L	–	–	–	–	–	–	IA	–	–	–(520)	–	IA
DC	25F	Mixed	L	L	–	+	±	–	–	IIB	–	–	–(250)	–	IIB
JD	26M	LD	–	R	–	±	±	–	–	IA	0	–	–(200)	–	IA
ED	17F	Mixed	–	L	–	+	±	–	–	IA	+	–	+(110)	–	IIIA
FK	36F	Mixed	L	L	L	+	±	–	–	IIB	–	–	–(124)	–	IIB
RF	14F	NS	–	R&L	–	–	–	–	–	IA	–	–	–(140)	–	IA
SM	54M	NS	–	–	R&L	–	+	–	–	IIIA	+	+	+(439)	–	IIIA
LL‖	64M	Mixed	–	–	–	–	+	–	–	IIB	+	+	+(200)	–	IIB
EF	26M	Mixed	L	L	L	–	+	–	–	IIIB	+	+	+(205)	–	IIIB
PC	58M	NS	–	–	–	+	+	–	–	IIIB	+	+	+(330)	–	IIIB
TY	9M	LP	R&L	L	–	–	–	–	–	IIA	–	–	–(190)	–	IIA
DW	26M	NS	L	–	L	–	+	–	–	IIIA	+	+	+(210)	–	IIIA
MH	30F	NS	–	–	R	–	±	–	–	IA	–	–	0	–	IA
JW	20F	NS	R	–	–	+	–	–	–	IA	–	–	–(275)	–	IA
ES	35M	Mixed	–	–	R&L	–	–	–	–	IIA	–	–	–(190)	–	IIA

* NS = Nodular sclerosis; Mixed = Mixed cellularity; LP = Lymphocyte predominance; LD = Lymphocyte depletion.
† Equivocal lymphangiogram arbitrarily counted as negative for staging purposes.
‡ "0" indicates procedure or biopsy of site in question was not done.
§ Patient has known thalassemia minor and spleen was palpable. Preoperatively, it was not known if this was due to Hodgkin's diseaes or thalassemia.
‖ Patient presented with groin disease.

TABLE 4. Preoperative Staging vs. Finding at Laparotomy

	Preoperative Stage	Staging Advanced
I A	15	4
B	1	1
II A	7	2
B	4*	
III A	8	
B	4	
IV A		
B	1	
	40	7

* One patient classified as Stage II B had disease confined to below the diaphragm. Lymphangiogram and subsequent para-aortic node biopsy were both positive. Staging was not reduced in any patient.

The complications assocated with the operation were as follows: There were two superficial wound infections and one wound dehiscence. Two patients developed intestinal obstruction, one 18 months after the original surgery and one 2 months later. Both required reexploration and lysis of adhesions in the left upper quadrant. In one patient, the surgeon ligated the hepatic artery at the celiac axis. This was recognized at the time and corrected, but in the postoperative period, while on anticoagulants, the patient developed bleeding and then stress ulcer. He underwent vagotomy and gastroenterostomy and eventually made a full recovery.

TABLE 5. Surgical Findings vs. Lymphangiogram Interpretation

		Lymphangiogram interpretation*		
		Pos.	Neg.	Equivocal
Para-aortic nodes	+	13	4	2
	−	−	10	7
	Not biopsied	1	−	2
		14	14	11
Splenic hilum nodes	+	9	4	2
	−	5	10	9
		14	14	11
Liver	+	−	−	−
	−	14	14	11
		14	14	11
Spleen	+	10	3	2
	−	4	11	8
	Not removed	−	−	1
		14	14	11

* One patient did not have a lymphangiogram; therefore the total is 39 rather than 40 patients.

Repositioning of the ovaries was done in 6 patients. One of the 6 is an 8-year-old girl and obviously not assessable as yet. Four of the remaining 5 patients have resumed menstruation, although, in one instance, this took 18 months. No pregnancies have been attempted as yet.

In general, it has been our practice to have a break of 3 weeks between irradiation of the chest and abdomen in order to allow for bone marrow recovery. In 15 patients, laparotomy and splenectomy were carried out in this interval between treatments. Twenty-five patients had the operation before any treatment was given. The hematologic tolerance to therapy of both groups was good. The mean values of the white blood count, absolute granulocyte count, and platelet count during the course of radiotherapy were similar in both groups. Two patients, however, of the 25 who had the operation before any treatment, required interruption of radiotherapy of the abdominal field because of platelet depression. None of the 15 who had surgery between chest and abdominal irradiation required interruption of therapy because of bone marrow depression. Further data will be necessary before any conclusions can be drawn.

DISCUSSION

This report demonstrates that a significant percentage of patients with Hodgkin's disease who have no detectable abdominal disease on the initial clinical and laboratory examination prove to have disease within the abdomen when explored surgically. Approximately 25% of our pre-laparotomy Stage I and II patients were Stage III after operation. Furthermore, the spleen and splenic hilum were found to be involved in 15 of 40 patients, only one of whom had a palpable spleen clinically.

The limitations of lymphangiography are shown by the data. Of 13 patients with unequivocally negative lymphangiograms, 4 had histologically positive para-aortic nodes. Two of 11 patients with lymphangiograms interpreted as equivocal were subsequently found to have positive nodes. All of our patients with positive lymphangiograms, however, had histologically positive nodes. Previous reports in the literature attesting to the accuracy of lymphangiography must be interpreted with caution since histologic proof of the lymphangiogram interpretation has seldom been available.[1,2,16] It must also be kept in mind

that a limited sample of tissue is obtained at laparotomy and that a negative biopsy of a para-aortic node, for example, does not absolutely exclude disease being present in other nodes.

Our findings confirm, in many respects, those already reported by Glatstein et al.[4] These authors described 50 unselected, untreated patients with Hodgkin's disease in whom laparotomy and splenectomy were performed as part of the initial diagnostic workup. Of 27 patients who appeared to have Stage I or II disease on clinical and laboratory examination (including lymphangiography), 8 were found to have abdominal disease. Conversely, of 23 patients thought to have intra-abdominal disease, 8 were not confirmed histologically and are considered false positives. The 8 false negatives included 3 patients with equivocal lymphangiograms and positive nodes histologically, 2 patients with negative lymphangiograms and positive splenic hilar nodes, and 3 patients with histologically positive livers without clinical evidence of hepatic involvement. The 8 false positives included 2 false-positive lymphangiograms, 4 patients thought to have palpable spleens but which were histologically negative subsequently, and 2 patients felt to have liver involvement clinically but who were negative on biopsy. Similar results obtained in smaller numbers of patients at 3 separate institutions have been summarized by Ultmann.[18]

In our series, almost half of the patients with abdominal disease failed to have a contiguous pattern to their sites of involvement. All patients with Stage I and II disease with more than one node group involved had disease in contiguous sites and thus for the group as a whole, 25% had evidence of a noncontiguous pattern. This is an important contrast to the Stanford series of patients in whom spread appeared to be contiguous in 90%. These data suggest either random spread of disease or a multicentric origin in a significant number of patients with Hodgkin's disease.

The information obtained from surgical exploration appears to be of great importance and may help to explain why results of radical radiotherapy, although impressive, are not as good as might be expected. It is now reasonably well established that a dose of 4000 rads in 4 weeks time will control a local area of Hodgkin's disease approximately 90% of the time. Depending on the number of areas involved, the 5-year cumulative free-of-disease

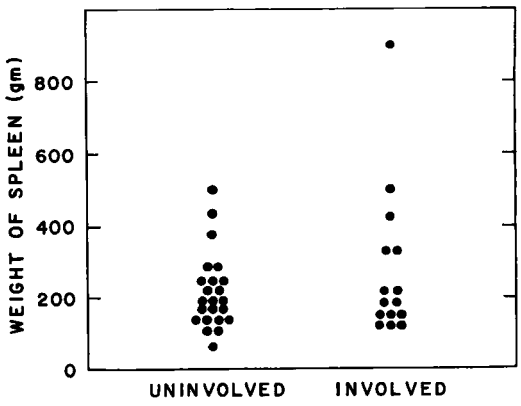

FIG. 1. Weight of spleen vs. histologic involvement.

rate for Stage I and II Hodgkin's disease should be 85–95%.[7] The published results are 55–65%, however.[3,6,12,13] This 30% difference between expectation and results corresponds surprisingly well to the 25–30% incidence of unsuspected disease found within the abdomen in patients who are apparently Stage I and II. This incidence of unsuspected abdominal disease found surgically may also help to explain the superior results obtained with total nodal irradiation as compared to extended field treatment recently reported by Johnson.[9] A fairly high incidence of reactivation of disease within the abdomen in patients with Stage I and II disease treated with a mantle portal has also been described by us and others.[8,13] In our experience, patients

TABLE 6. Relationship of Disease in the Neck, and Supraclavicular and Mediastinal Areas, to Abdominal Disease

		Abdomen	
		Positive	Negative
Neck	R +	2	5
	L +	7	6
	Both +	2	2
	Neg.	10	6
		21	19
Supraclavicular	R +	5	1
	L +	5	7
	Both +	1	1
	Neg.	10	10
		21	19
Mediastinum	+	8	8
	−	13	11
		21	19

developing new disease within the abdomen after treatment of areas above the diaphragm have a poor prognosis even when the involvement is apparently confined to lymph nodes and spleen.

All this points to the importance of early detection of abdominal disease if successful treatment with radical radiotherapy is to be carried out. Whether the same impressive cure rates obtainable with Stage I and II disease will be obtainable with Stage III A patients remains uncertain.

In addition to the diagnostic benefits derived from laparotomy and splenectomy, the operation facilitates subsequent radiotherapy in several ways. Treatment to the para-aortic nodes, splenic pedicle, and pelvic nodes may be done using one field, the "inverted Y." If the spleen were still in place, the volume of tissue in the field would be too large. The field would have to be split in two requiring an additional 4 weeks of therapy. Removal of the spleen also spares several important organs in or adjacent to the left upper quadrant of the abdomen from radiation therapy, i.e., the left kidney, left lower lobe of the lung, and stomach. We also have the impression that the hematologic tolerance to irradiation as well as to chemotherapy is improved following splenectomy.[15]

Despite our widespread use of laparotomy, we still consider lymphangiography to be a valuable procedure for the reasons outlined by Glatstein et al.[4] The most suspicious looking para-aortic nodes may be selected for biopsy. Opacification of the nodes aids the radiation therapist in the subsequent placing of the treatment portals. Persistence of the dye in the nodes allows them to be followed with plain films of the abdomen and to be observed for persistence or recurrence of disease.

Based on the findings at the time of surgery, our present treatment plan is as follows: If disease is found involving the abdominal nodes or spleen, all of the abdominal nodes are treated with the inverted Y field. If the lymphangiogram is equivocal and the surgical exploration negative, we still generally treat the inverted Y field, although management of such patients is more individualized, because of the limitations of the sampling procedure. With a negative lymphangiogram and negative exploration, the para-aortic nodes are treated prophylactically, but the pelvic nodes are not.

REFERENCES

1. Brickner, T. J., Boyer, C. W., and Perry, R. H.: Limited value of lymphangiography in Hodgkin's disease. *Radiology* 90:52–56, 1968.

2. Davidson, J. W., and Clarke, E. A.: Influence of modern radiological techniques on clinical staging of malignant lymphomas. *Canad. Med. Ass. J.* 99:1196–1204, 1968.

3. Easson, E. C.: Long-term results of radical radiotherapy in Hodgkin's disease. *Cancer Res.* 26:1244–1247, 1966.

4. Glatstein, E., Trueblood, H. W., Enright, L. P., Rosenberg, S. A., and Kaplan, H. S.: Surgical staging of abdominal involvement in unselected patients with Hodgkin's disease. *Radiology* 97:425–432, 1970.

5. Kadin, M. E., Donaldson, S. S., and Dorfman, R. F.: Isolated granulomas in Hodgkin's disease. *New Eng. J. Med.* 283:859–861, 1970.

6. Kaplan, H. S.: Long-term results of palliative and radical radiotherapy of Hodgkin's disease. *Cancer Res.* 26:1250–1253, 1966.

7. ———: Evidence for tumoricidal dose level in radiotherapy of Hodgkin's disease. *Cancer Res.* 26:1221–1224, 1966.

8. ———: Prognostic significance of the relapse free interval after radiotherapy in Hodgkin's disease. *Cancer* 22:1131–1136, 1968.

9. Johnson, R. E., Thomas, L. B., Schneiderman, M., Glenn, D. W., Faw, F., and Hafermann, M. D.: Preliminary experience with total nodal irradiation in Hodgkin's disease. *Radiology* 96:603–608, 1970.

10. Lukes, R. J., Craver, L. F., Hall, T. C., Rappaport, H., and Rubin, P.: Report of the Nomenclature Committee. *Cancer Res.* 26:1311, 1966.

11. Nuland, S. B.: Splenectomy as an adjunct to the treatment of Hodgkin's disease. *Conn. Med.* 34:851–855, 1970.

12. Peters, M. V.: Prophylactic treatment of adjacent areas in Hodgkin's disease. *Cancer Res.* 26:1232–1243, 1966.

13. Prosnitz, L. R., Hellman, S., von Essen, C. F., and Kligerman, M. M.: The clinical course of Hodgkin's disease and other malignant lymphomas treated with radical radiation therapy. *Amer. J. Roentgen.* 105:618–628, 1969.

14. Rosenberg, S. A.: Report of the Committee on the Staging of Hodgkin's disease. *Cancer Res.* 26:1310, 1966.

15. Salzman, J. R., and Kaplan, H. S.: Effect of prior splenectomy on hematologic tolerance during total lymphoid radiotherapy of patients with Hodgkin's disease. *Cancer* 27:471–478, 1971.

16. Takahashi, M., and Abrams, H. L.: The accuracy of lymphangiographic diagnosis in malignant lymphoma. *Radiology* 89:448–460, 1967.

17. Trueblood, H. W., Enright, L. P., Ray, G. R., Kaplan, H. S., and Nelsen, T. S.: Preservation of ovarian function in pelvic radiation for Hodgkin's disease, *Arch. Surg.* 100:236–237, 1970.

18. Ultmann, J. E.: Current status: The management of lymphoma. *Seminars Hemat.* 7:441–460, 1970.