were phagocytosed, and many of them were carried into the wall by migratory cells. Mononuclear leukocytes attracted to the area caused an appreciable thickening of the bronchiolar wall. After 16 months a delicate fibrosis made its appearance. The process evolved gradually, and the number of fine intercellular collagenous fibers steadily increased. As this fibrous deposit contracted, it partially closed and

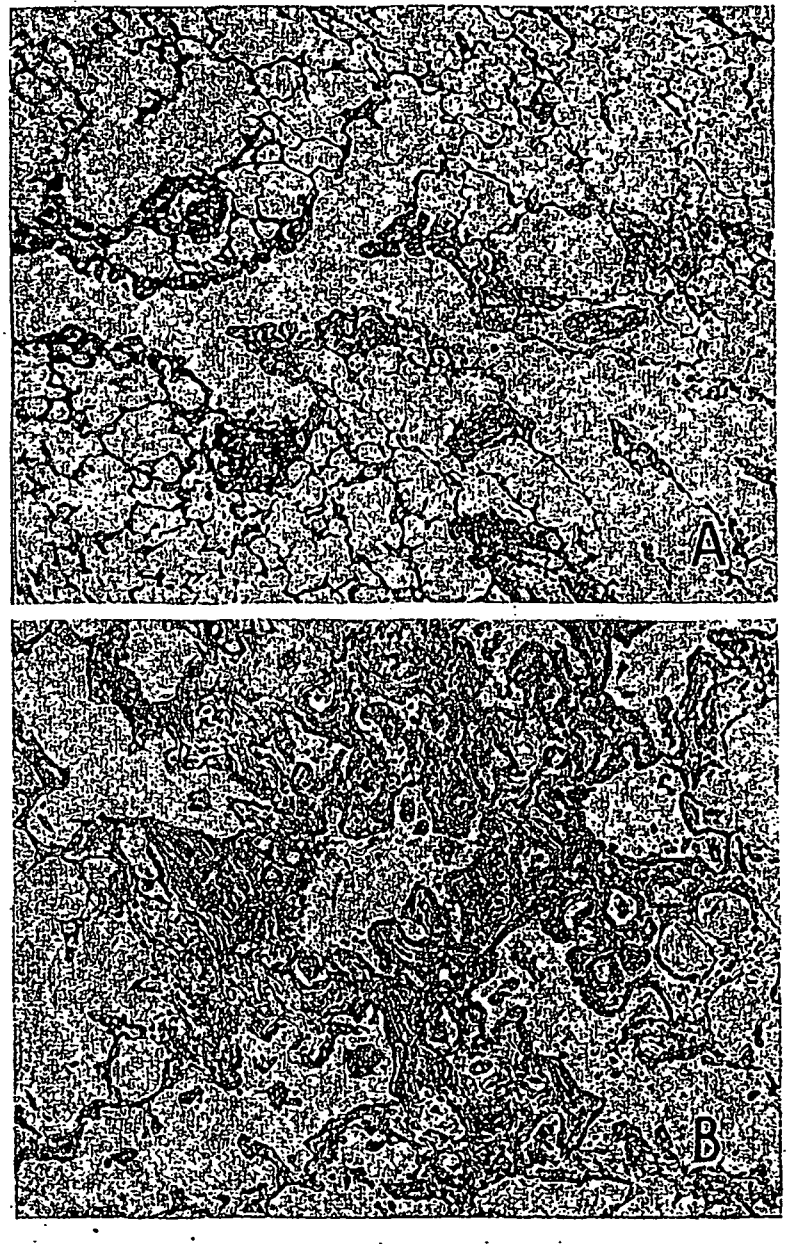

Fig. 3.—King's floats inhalation experiment: *A*, lung of a guinea pig with 12 months' exposure. It includes a respiratory bronchiole, at the left, branching and becoming an alveolar duct, at the right. Note the accumulation of cells in the wall of the bronchiole and in adjacent alveoli (× 130). *B*, lung of a guinea pig with 28 months' exposure. The field includes a bronchiole, at the center, with peribronchial fibrosis extending into the walls of adjacent alveoli. Note the cuboidal epithelium lining these alveoli. This is the so-called "adenomatoid" appearance (× 200).

distorted the alveoli, and with this change the alveoli became lined with cuboidal cells. The result was an adenoma-like appearance which frequently accompanies